UNIVERSAL
LIBRARY

OU_170536

UNIVERSAL
LIBRARY

ROSE AND CARLESS

MANUAL OF SURGERY

ROSE & CARLESS

MANUAL OF

SURGERY

For Students and Practitioners

BY

CECIL P. G. WAKELEY, C.B.

D.Sc., F.R.C.S., F.R.S.E., F.R.S.A., F.A.C.S., F.R.A.C.S

Fellow of King's College, London

SENIOR SURGEON, KING'S COLLEGE HOSPITAL; DIRECTOR OF SURGICAL STUDIES AND LECTURER IN SURGERY, KING'S COLLEGE HOSPITAL MEDICAL SCHOOL; SURGEON, BELGRAVE HOSPITAL FOR CHILDREN AND WEST END HOSPITAL FOR DISEASES OF THE NERVOUS SYSTEM; CONSULTING SURGEON, MAUDSLEY HOSPITAL AND TO THE ROYAL NAVY AND EMERGENCY MEDICAL SERVICE; HUNTERIAN PROFESSOR, ROYAL COLLEGE OF SURGEONS OF ENGLAND; CHAIRMAN OF THE COURT OF EXAMINERS, ROYAL COLLEGE OF SURGEONS; EXAMINER IN SURGERY TO THE UNIVERSITIES OF CAMBRIDGE AND DURHAM; FORMERLY EXAMINER IN SURGERY TO THE UNIVERSITIES OF LONDON, GLASGOW, BRISTOL AND TO THE NATIONAL UNIVERSITIES OF IRELAND AND WALES

Temporary Surgeon-Rear-Admiral

AND

JOHN B. HUNTER, *M.C.*

M.CHIR. CANTAB., F.R.C.S. ENG.

SURGEON, KING'S COLLEGE HOSPITAL; LECTURER IN SURGERY, KING'S COLLEGE HOSPITAL MEDICAL SCHOOL; SURGEON, ROYAL CHEST HOSPITAL; CONSULTING GENERAL SURGEON, THROAT, NOSE AND EAR HOSPITAL, GOLDEN SQUARE; EXAMINER IN SURGERY TO THE UNIVERSITY OF CAMBRIDGE, AND TO THE SOCIETY OF APOTHECARIES OF LONDON

SEVENTEENTH EDITION

VOLUME II

LONDON

BAILLIÈRE, TINDALL AND COX

7 & 8 HENRIETTA STREET, COVENT GARDEN

1943



THIS BOOK IS PRODUCED IN
COMPLETE CONFORMITY WITH THE
AUTHORISED ECONOMY STANDARD

CHAPTER XXVI.

AFFECTIONS OF THE SCALP AND CRANIUM.

Affections of the Scalp.

Wounds of the scalp are produced either by sharp or blunt instruments, by falls on the head, or by gunshot injuries. From the tension of the scalp over the cranium, it is possible for a blunt weapon, such as a policeman's truncheon, to cause a wound nearly as cleanly cut as if made with a sharp instrument. If the wound is superficial to the occipito-frontalis aponeurosis, but little harm is done; if, however, the layer of loose cellular tissue between the aponeurosis and the pericranium (the 'dangerous area') is opened up and infected, cellulitis (p. 61) is likely to ensue. The vascular supply of the scalp is so good that sloughing is uncommon, a large portion may be torn and bruised, and yet, if it is carefully washed and rendered aseptic, it will probably live. *Complete avulsion* of the scalp usually occurs in women from their hair being caught in machinery. The skin yields just above the ears and supra-orbital ridges, and the aponeurosis is cleanly torn off. Replacement is of course hopeless when separation is complete, and Thiersch-grafting must be relied on for obtaining an epithelial covering.

Treatment.—The hair should be cut away from the neighbourhood of the wound, which is purified in the usual way; the edges may be excised if badly bruised or very dirty. The iodine method of gaining asepsis (p. 278) is particularly useful in these injuries, and may limit the area to be shaved. Stitches should be of a non-absorbent variety, *e.g.* horsehair. Hæmorrhage from the scalp is often severe, owing to the density of the tissues, which prevents contraction and retraction of the divided vessels.

Hæmatoma of the scalp results from injuries that are not associated with solution of continuity of the surface. A similar condition is found in infants, due either to injury of the head during its passage through the mother's pelvis, or to its compression by forceps. Three varieties of cephal-hæmatoma have been described, *viz.*: (*a*) the *Superficial*, which, confined to the dense subcutaneous tissue, is necessarily small. (*b*) The *Subaponeurotic* occupies the loose tissue under the aponeurosis, and is only limited by its attachments. A large, soft, fluctuating swelling forms, upon which the scalp appears to float, bagging down over the eyes or occiput. It is often due to fracture of the underlying bone. (*c*) The *Subpericranial* is limited by the pericranium dipping down into the sutures around the bone with which it is connected. Most commonly it forms over one of the parietal bones in infants, presenting a soft, fluctuating swelling, which soon gains an indurated margin owing to a deposit of fibrin, and in this

condition may simulate a depressed fracture of the skull, inasmuch as the cup-like fluid centre allows the finger to sink in and touch bone below. The indurated margin, however, can be readily indented by the finger, whilst the edge is definitely raised above the surface of the cranium, and hence the sensation of a depression is only apparent.

Treatment.—All that is required is the application of evaporating lotions. There is hardly ever any need to lay open or drain these swellings unless underlying mischief is present.

Suppuration of the scalp is of common occurrence, arising usually from external infection, but being occasionally due to disease of the subjacent bones. The extent of the abscesses is limited by the same anatomical features as obtain in connection with hæmorrhage. Thus, a *subcutaneous* abscess is necessarily small in size, owing to the density of the tissues in which it is located; it arises most frequently as a result of eczema or impetigo, and is often due to the presence of pediculi, or to the action of irritants used in the cure of ringworm. A *subaponeurotic* abscess usually results from a penetrating wound, and is associated with cellulitis. A *subpericranial* abscess is rarely seen except in connection with injury or disease of the bony calvarium, and is limited to the affected region.

For **Erysipelas** and **Cellulitis** of the scalp, see pp. 119 and 61.

Tumours of the scalp are of many types.

Ordinary *traumatic aneurisms* or *arterio-venous* wounds of the temporal trunk are uncommon; they rarely attain any considerable size, and are readily treated by excision. A curious dilated and tortuous condition of one of the scalp arteries, most often the temporal, is occasionally seen, and is known as an *arterial varix*; it may be treated by complete excision.

Nævi of the scalp do not differ in their characters from those seen elsewhere, except that when situated over the anterior fontanelle they may derive a communicated impulse from the subjacent dura, and so be mistaken for a meningocele.

Cirsoid Aneurism is more frequently met with in the scalp than elsewhere, and chiefly involves the auriculo-temporal region, but may also spread in all directions, even downwards into the neck. In a few cases it has been preceded by a nævus, and sometimes there is a history of injury. A tumour of greater or less size is seen under the skin, consisting of distended, tortuous, pulsating, bluish-looking vessels, the arteries opening directly into cavernous spaces; it is easily emptied by pressure, but quickly refills. The patient often complains of headache and giddiness; the skin becomes thin and atrophic, the hair falls out, and finally ulceration may occur, the patient probably dying from hæmorrhage. The **Treatment** is eminently unsatisfactory, complete excision being the ideal cure, but this in bad cases is impracticable. If it be attempted, the incisions should be made wide of the disease, and the supplying vessels secured, if possible, between double ligatures before dividing them; if this precaution is not adopted, frightful hæmorrhage may result. It is necessary in some cases to deal with the tumour in separate segments, allowing time between the operations for the patient to recover from the loss of blood. Prob-

ably *diathermy*, combined with ligature of the main nutrient vessels, or of both external carotids, holds out the best chance of success.

Papillomata are not uncommon in the form of small, hard, warty outgrowths, giving rise to but little inconvenience, unless situated on some spot where the hat rests. They are easily removed.

Lipomata also occur, and are usually situated in front, arising from the deeper layers of the scalp or from the pericranium. They generally expand laterally and are flattened. Removal is readily effected.

Epithelioma also occurs, arising either from an irritated papilloma, or possibly in connection with a sebaceous cyst. As soon as a diagnosis is made, the growth should, if possible, be extirpated, and the resulting raw surface may be either left to granulate, or dealt with by Thiersch's method of skin-grafting.

Neuro-fibromatous growths sometimes involve the scalp, giving rise to irregular nodulated masses of soft tissue which may even hang around the root of the neck in large coils; it is then known as a **pachydermatocele** (p. 204). Excision is the treatment if the mass is not too large.

Sarcoma of the scalp is uncommon apart from a similar affection of the underlying bones. It develops as a large fleshy tumour which may pulsate or fungate, and usually grows rapidly, but is limited for some time by the aponeurosis of the occipito-frontalis. Treatment by a wide excision and Thiersch-grafting may be possible, but if the condition is at all advanced the only hope lies in the use of radium or the X-rays.

Dermoid Cysts are by no means uncommon in this region, their favourite situation being near the outer canthus, the temple, or the root of the nose. For a general description, see p. 225. They do not attain any great size, and may not become evident till after puberty. The underlying bone is often hollowed out from a defective development of the mesoblastic tissues around them, and a congenital opening may even exist through which a narrow neck passes, bringing the cyst into direct connection with the dura mater. The *treatment* consists in removal; but it is advisable to delay this till after puberty if the tumour seems at all fixed to the skull, or if the bone is felt to be defective beneath it, as in such cases the communication with the interior of the cranium is often shut off by that time.

Sebaceous Cysts (p. 454) find their most usual situation in the scalp, where they are frequently multiple. Their removal is best accomplished by transfixion, squeezing out the contents, and picking out the cyst wall by a pair of forceps without dissection. The wound is closed by one or two stitches.

Sebaceous Adenoma is most frequently seen on the scalp (p. 455).

Affections of the Cranium.

I. Congenital Affections.

1. In babies the ossification of the bones may be incomplete, constituting what is known as *aplasia cranii congenita*, and is due to a

cachectic condition of the mother. Occasionally a similar atrophic condition of the bones may persist through life, exposing the patient to increased risk from injuries which otherwise would do but little harm.

2. **Meningocele, Encephalocele,** and **Hydrencephalocele** consist of a protrusion of the dura mater, with or without part of the brain, through an opening in the cranial wall. They are due to defective intrusion of the mesoblastic tissues outside the primitive cerebral vesicle, so that part of the brain or its membranes remains superficial and extracranial. They occur most frequently at the root of the nose, and in the occipital region (Fig. 502), occasionally at the anterior or lateral fontanelle, or at the base of the skull. A *Meningocele* is simply a protrusion of the brain membranes containing cerebro-spinal fluid. It forms a soft, rounded, fluctuating swelling, attached to the skull by a base of greater or less size, and covered by skin, which may be thick and healthy, or thinned, bluish, and translucent when



FIG. 502.—MENINGOCELE OF THE FRONTAL REGION

the tumour is large. The vessels present in the skin are often dilated and nævoid. It increases in size and tension on any expiratory effort, such as coughing or crying, and it may be partially reducible, thus allowing the margins of the opening in the cranium to be defined. Symptoms of cerebral compression, convulsions, etc., are likely to be produced by such manipulation. An *Encephalocele* is a similar type of tumour, but contains brain substance, and pulsates almost synchronously with the heart; it is most commonly situated at the back of the skull. A *Hydrencephalocele,* or Meningo-encephalocele, is a condition in which the tumour contains both brain substance and fluid. Two varieties have been described—one in which there is a small protrusion of the brain associated with an ordinary meningocele, and the other in which the fluid is contained in a cavity communicating with one of the ventricles, and covered by a thin layer of brain substance. They are usually of considerable size, and situated in the occipital region, either above the tentorium, and then possibly associated with distension of the posterior cornu of one of the lateral ventricles,

or below that structure, the osseous defect extending in some cases as far as the foramen magnum, and a portion of the cerebellum being within the sac.

The **Prognosis** of these conditions is exceedingly grave. Fortunately, many of the subjects are born dead, or die soon after birth. In the more severe cases, idiocy and microcephaly are not uncommon, whilst sometimes hydrocephalus is present. The protrusion may increase steadily in size and finally burst, causing death by meningitis, or in more favourable cases it may remain stationary. In a meningocele, the subsequent growth of the bones may suffice to close the communication between the interior and the tumour, which thus becomes shut off, and remains as a cyst-like swelling, with the base fixed, and without pulsation or respiratory impulse.

Treatment.—Most cases should be left alone; but if the swelling is increasing, aseptic puncture and subsequent compression may hinder the process. A simple meningocele may possibly be cured in this way, but when the communication with the skull is small, it is often feasible to open the sac and suture the base securely.

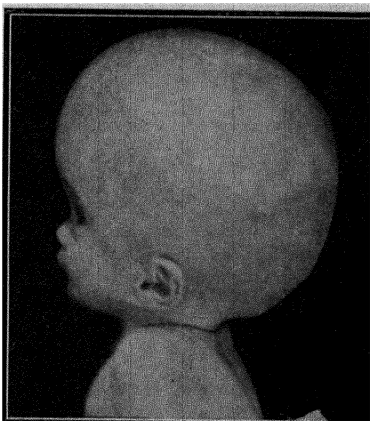

FIG 503.—ADVANCED HYDROCEPHALUS

II. **Acquired Affections** of the skull are atrophic, hypertrophic, inflammatory, or neoplastic in nature.

Acquired Atrophy of the skull occurs in many forms:

(*a*) *Craniotabes* is a condition met with during the first year of life, usually as a result of inherited syphilis (p. 662).

(*b*) *Senile* atrophy may affect the whole cranium, which becomes thinned and rarefied; or it may be localized, *e.g.* to the parietal bones, constituting hollow depressions which extend antero-posteriorly.

(*c*) Localized loss of substance may result from the pressure of tumours, such as Pacchionian bodies and aneurisms, from necrosis, or from traumatic and operative lesions. If these are at all extensive, the cerebral pulsations can be felt distinctly through the skin.

(*d*) *Essential Hydrocephalus* is always associated with atrophy and thinning of the cranium; it may be congenital, or may commence early in life (Fig. 503). It is produced in almost all cases by a distension of the lateral ventricles with fluid, the result of congenital malformation or of inflammatory affections of the base of the brain. Thereby the secretion of the cerebro-spinal fluid by the choroid plexuses may be increased beyond the functional capacity of the channels of exit (p. 867); or the escape of the fluid from the ventricles may be prevented by pressure or obstruction; or, finally, the communications with the venous sinuses may be blocked, in which case there

is some excess of fluid outside the brain as well as within it. The head becomes more and more distended (Fig. 504), the bones are expanded and thinned, and the sutural areas increased, whilst the brain is subjected to such pressure as may be incompatible with life. Fluctuation is distinctly felt, and the bones may crackle under the fingers; the face looks abnormally small, and the eyes protrude, owing to the depression of the orbital plates. **Treatment** is unsatisfactory. Tapping of the ventricles is useless, as even if a considerable amount of the fluid is withdrawn, and elastic pressure subsequently maintained, recurrence is almost inevitable. The only hope is to limit the formation of cerebro-spinal fluid from the ventricles of the brain. Dandy and others have perfected a technique and now obtain good results by using a ventriculoscope. The operation is performed through a small



The greatly enlarged cranium, the overhanging eyebrows, the staring eyes, the wasted features, and the attenuated body constitute a typical picture

burr hole just to one side of the mid-line in the occipital region. The dura mater is incised and any cortical vessels coagulated with the diathermy cautery. The cortex is carefully incised and the ventriculoscope introduced into the posterior horn of the lateral ventricle (Fig. 505). The fluid in the ventricle is aspirated and kept in a warm container so that it can be replaced at the end of the operation. The outer tube of the ventriculoscope is made of insulated bakelite, so that there is no fear of spreading coagulation when the cautery is used. The choroid plexus is inspected, a fine cautery is passed down the tube, and the majority of the plexus coagulated. When the plexus is completely shrunken, it can be removed with fine forceps. The cerebro-spinal fluid is returned and any deficit made good with Ringer's solution. Both choroid plexuses can be removed at one sitting, but

t is better to remove one at a time, an interval of one week intervening between the two operations.

After the operation the head is fixed in a light plaster bandage to prevent the escape of cerebro-spinal fluid.

(*e*) By *Microcephaly* is meant a condition of diminished size of the cranial cavity due to premature ossification of the sutures, and resulting from non-development of the brain. It is usually associated with idiocy, and possibly with cretinism. No treatment is of any permanent value.

Hypertrophic Changes of the Skull result from simple chronic inflammatory affections, or from injury, etc. Special types of enlarge-

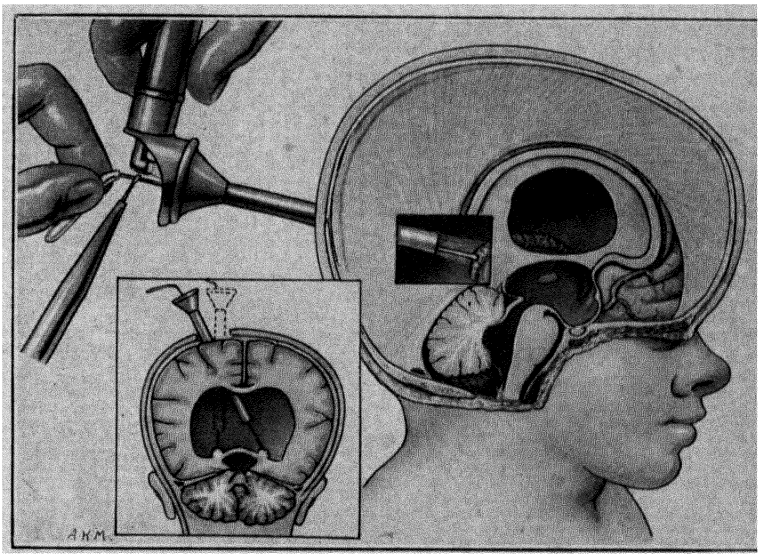

FIG. 503.—CAUTERIZING THE CHOROID PLEXUS BY MEANS OF A VENTRICULOSCOPE. The small inset shows how both ventricles can be dealt with at one sitting and through the same opening

nent are seen in inherited syphilis (p. 662), rickets (p. 664), osteitis deformans (p. 670), and acromegaly (p. 672). In leontiasis ossea (p. 961) the cranium becomes thickened and enlarged; but the cranial cavity is also encroached on, constituting what is known as *concentric* hypertrophy, in contrast to most of the other forms, which are *eccentric* in type.

Inflammatory Affections of the Cranial Bones.—The cranium is liable to any of the diseases which generally occur in bone.

1. **Acute Periostitis, or Pericranitis,** is usually infective in origin, following cellulitis of the scalp; it is likely to result in necrosis of the outer table.

2. **Acute Infective Osteomyelitis,** or acute necrosis, consists of an

acute inflammation of the diploe, due to pyogenic organisms, and either following an infected scalp wound or compound fracture, infective inflammation of one of the air-sinuses (especially the frontal sinus or mastoid antrum), or the operation necessary for its treatment, or a simple contusion of the bone in a person of low germicidal powers; it may also be pyæmic in origin. The symptoms and signs are those generally characteristic of the disease, being ushered in by a rigor, followed by headache, fever, and the development of a localized œdematous swelling, known as 'Pott's puffy tumour' (Fig. 544). The pericranium is stripped up by diffuse suppuration beneath it, and an abscess often forms between the bone and the dura mater. Necrosis of the whole thickness of the skull is likely to follow, but is usually limited by the sutures to the particular bone affected. Pyæmia and extension of the inflammation to the membranes, venous sinuses or brain are the chief dangers arising from it. The prognosis is always grave, even when early operative treatment is undertaken; apart from operation, it is almost hopeless. The *Treatment* consists in free external drainage, together with the removal of the outer table in early cases to enable the infected diploë to be removed. If signs of subcranial suppuration ensue (p. 894), the inner table must also be widely taken away. In the later stages, necrosed bone is removed when it has been set free.

3. **Chronic Periostitis** is occasionally met with in the form of a node. If independent of syphilis, it is usually the result of long-continued irritation, such as carrying baskets or weights on the head. *Treatment* consists in the discontinuance of the causative irritation, and there is no objection to chiselling away the node, if necessary.

4. **Tuberculous Disease** of the cranial bones is not common, it occurs as a primary phenomenon, or more commonly is secondary to a meningeal focus. It may start in the periosteum or diploë, leading to the formation of a node, or perhaps to expansion of the bone, and followed by suppuration and caries. When of meningeal origin, there is a considerable amount of erosion of the inner table, and possibly some necrosis; sooner or later the outer table is perforated and a subpericranial abscess forms. The amount of mischief in the outer table is no criterion of the extent of the disease within, and hence a thorough exploration is necessary. The prognosis in this variety is not good, unless active operative measures are taken at an early date, combined with suitable constitutional treatment.

5. **Syphilitic Disease** used to be exceedingly common, but is now seldom seen. It occurred usually in the tertiary stage, and affected most frequently the frontal and parietal bones. It has been already described (p. 659).

Tumours of the Cranial Bones.—The chief **Tumours** affecting the calvarium are osteomata and sarcomata.

Osteoma of the cranium (Fig. 71, p 198) occurs as a localized overgrowth of compact bone from the outer surface of the calvarium, from the inner, or from both. The frontal bone and external auditory meatus are the sites of election. If arising externally, a smooth,

rounded, globular swelling is produced, hard to the touch, quite painless, and fixed to the subjacent bone by a broad base; more than one may be present. If the main growth is internal, symptoms of cerebral irritation or pressure are produced. Osteomata are to be distinguished from inflammatory hyperostoses (usually of syphilitic origin) by their sharp limitation, absence of pain, and slower progress; whilst osteo-sarcomata are commonly rapid in growth, painful, and of unequal consistency in different parts. **Treatment** is rarely necessary. Small growths may be encircled in the crown of a trephine and thus removed. Large ones must be dealt with by an electric saw or burr, the bone being divided just outside the dense compact tissue, and thus the tumour is set free. No attempt should be made to chisel away those growths, as symptoms of concussion may follow the prolonged use of the chisel and mallet against the skull.

Sarcoma of the cranium originates from either the pericranium, the diploe, or the dura mater.

The *pericranial* variety consists of a round or spindle-celled tumour growing from the pericranium, and possibly attaining a considerable size. It may contain a certain amount of ossific deposit, or the tumour remains of a soft consistency, and then often pulsates. The subjacent bone is sometimes absorbed, and the dura mater affected secondarily. General infection of the system follows.

Central Sarcoma commences in the diploé and spreads both outwards and inwards. In this situation, however, a *myeloma* may develop, and simulates a sarcoma; its growth, however, is slower and it is covered with a thin layer of bone, which may crackle beneath the fingers. It is commonly secondary to sarcoma of the kidney.

Secondary Carcinoma of the cranial bones is by no means uncommon, and may follow cancers of the mamma, thyroid body, etc The growths are usually small and multiple, and may show pulsation. Neuralgia and persistent headache result from them.

III. Traumatic Affections of the Cranium.

Contusions of the Cranial Bones apart from fracture may lead to serious results. 1. Many of the inflammatory conditions of bone just described may be originated, *e g.* if the patient is in a condition of low germicidal power, acute osteomyelitis may follow; or chronic sclerosis and overgrowth of the bone, local or diffuse, may supervene. Syphilitic or tuberculous manifestations may be similarly lighted up if the patient is the subject of either of these diseases. 2. In addition to such osseous conditions, pus may form within the cranium outside the dura mater (*subcranial abscess*, p. 895), and necessitate operation. 3. The dura mater may be detached by a simple contusion, leading to meningeal hæmorrhage (p. 890). 4. Any of the cerebral lesions detailed hereafter may be produced. Contusions of the cranium must obviously never be treated lightly, even when they are associated with unbroken skin; much more are they serious when open, owing to the risks of infection.

Fractures of the Skull may be described for convenience under the

following headings: *Fissured Fractures of the Vault; Fractures of the Base* (usually fissured), and *Depressed or Punctured Fractures.*

1. **Fissured Fractures of the Vault** are always due to external violence, direct or indirect. In the former case the skull first yields at the injured spot, but the fissure may extend from it for some distance, in the latter the fracture results from the yielding of the skull when compressed beyond its natural limits of elasticity (Fig. 506).

A closed or simple fissure gives rise to no symptoms indicating its presence with certainty. There may be some amount of superficial

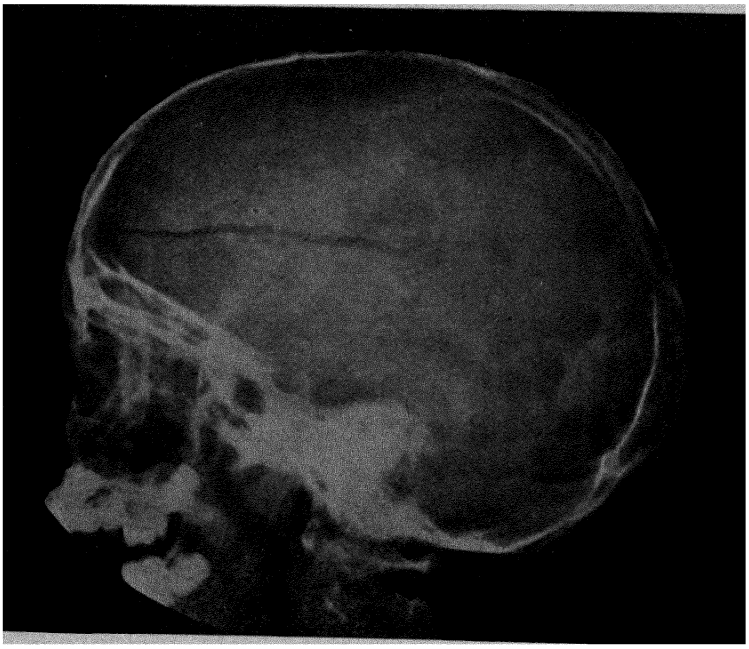

FIG. 506.—X-RAY OF FRACTURE OF THE VAULT OF THE SKULL IN A CHILD

ecchymosis and tenderness, but nothing more definite. When open, the line of fracture may be seen as a red streak, or even felt with the finger as an irregular ridge. It consists of a single longitudinal fissure, or may be starred; if uncomplicated, it is of but little importance, and needs nothing beyond general treatment and the maintenance of asepsis. Occasionally, however, a mass of protuberant callus forms on the inner aspect of the cranium at the site of fracture, or the dura mater becomes thickened by organization of effused blood; either of these lesions may give rise to chronic headache or discomfort, or even to traumatic epilepsy or insanity (p. 938).

Traumatic Cephal-hydrocele is the name given to a rare condition

following simple fractures of the vault, especially in children. It is characterized by the formation of a fluid swelling under the scalp, which pulsates synchronously with the heart-beat, and has a definite impulse on any expiratory effort; it varies in size from time to time and is sometimes partially reducible. It contains cerebro-spinal fluid, and communicates with either one of the lateral ventricles or the subarachnoid cavity. In one case it was proved on operation to be connected with an arachnoid cyst, due to a localized subarachnoid hæmorrhage. Probably it is wise to operate on these cases, as they will not get well of themselves.

2. **Fractures of the Base of the Skull** are almost always fissured, and only occasionally punctured or depressed.

Causes.—(*a*) *Violence may be directed to the vertex or to some part of the cranial convexity*, as from a blow or fall upon a hard substance. There has been a good deal of discussion as to how a fall on the vertex causes fracture of the base. Two main theories hold the field, each being probably responsible for a certain number of cases. (i.) Aran's theory of *irradiation* maintains that a fracture of the base is always due to direct extension of the fissure from the injured vertex, a proposition probably quite true in many cases, but insufficient to explain all. (ii.) A more recent idea, known as the *bursting or compression theory*, is based on the fact that the cranium is not a solid and totally unimpressionable body, but is highly elastic, as has been proved by the observation that hair and even pieces of skin have been found nipped in a fissured fracture of the vault, which had evidently gaped open and closed again. Moreover, it is very irregular in shape and of very variable strength and density, and the base is weakened by the presence of numerous foramina for the passage of spinal cord, vessels, and nerves; the base is also less elastic than the vault. Severe compression necessarily diminishes the diameter of the skull along the axis of greatest pressure, making it bulge in other diameters; if this exceeds the limits of elasticity of the bone, a fracture must result. Most commonly the lines of fracture are parallel to the direction of the compressing force, the bone thus bursting open along its convexity (fracture by bursting); less frequently it gives way at right angles to the direction of the force (fracture by compression). Inasmuch as the force is transmitted equally in all directions, the weakest and least elastic part is always most likely to give way, *viz.* the base. (*b*) *Direct or indirect injury* to the base of the skull is undoubtedly the cause of a certain number of fractures, and some of these are depressed, and not fissured, in character. Thus, the point of an umbrella or a stick may be thrust through the upper wall of the orbit, or up the nose through the cribriform plate of the ethmoid; the condyle of the jaw may be driven through the glenoid cavity into the middle fossa by a blow on the chin; direct injury from a fall or a stab may penetrate the occipital bone; whilst a gunshot wound in the mouth is another illustration of this kind of injury. (*c*) The *impact or resistance of the vertebral column against the occipital condyles* produces fractures in the posterior fossa which radiate from the foramen magnum, and may even occasion a ring-shaped fracture around

it (Fig. 508). They result from falling on the vertex into a soft mass, *e.g.* a bale of wool, or by alighting from a height on the heels or nates.

The fracture may run in any *direction*, longitudinal, oblique, transverse, etc., according to the direction of the compressing or fracturing force, and it may affect any part of the base, either being limited to one of the fossæ or involving all; it may follow the sutural lines in part, but it is no uncommon thing to see even the dense petrous bone traversed by a fissure (Fig. 507). Naturally, transverse fractures are more likely to be limited to one of the fossæ, whilst a longitudinal fissure may involve them all.

Some fractures of the base of the skull are closed in nature, but the majority are *open*. In the anterior fossa the fissure extends through the cribriform plate and nasal mucosa, and then lays open the nose; or a communication may be established with the external air through a penetrating wound in the orbit, or through the ethmoidal or sphenoidal sinuses. In the middle fossa a fracture through the base of the

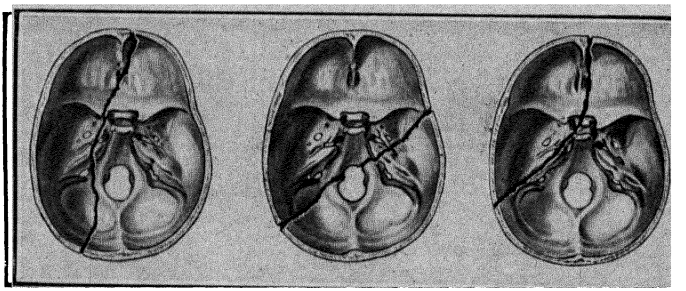

FIG 507 — DIAGRAM SHOWING THREE COMMON TYPES OF FRACTURE OF THE BASE OF THE SKULL

sphenoid opens the roof of the naso-pharynx, or the fracture may involve the tympanic cavity. In the posterior fossa the basi-occipital may be broken, and again the naso-pharynx opened, although the fracture here is more commonly closed.

Fractures of the base of the skull, though very serious, are by no means necessarily fatal, and since the introduction of antiseptic methods the results have immensely improved. The main *dangers* to be apprehended are: (i.) Damage to the base of the brain, including the pons and medulla, especially in cases where the foramen magnum is splintered from the impact of the spine against the condyles; (ii.) hæmorrhage arising either from the venous sinuses, or from the meningeal or cerebral arteries; and (iii.) infective meningitis, due to the fact that the injury not only fractures the bones, but also tears the dura mater, a grave addition to an open fracture.

The **Signs** of a fractured base are sometimes exceedingly equivocal, but for convenience may be arranged under four heads:

(1) *Signs of severe cerebral mischief* such as concussion of the brain and prolonged unconsciousness.

(2) *Hæmorrhage* manifests itself in various directions, according to the situation of the fracture.

In the *anterior fossa* there may be free bleeding from the nose, owing to the fracture extending through the cribriform plate of the ethmoid; but a portion of the blood may pass backwards into the pharynx, and, being swallowed, is perhaps subsequently vomited. More often, however, the line of fracture runs across the roof of the orbit, causing escape of blood into the areolar tissue of this cavity. The ecchymosis shows itself as a gradually developing subcutaneous distension, involving the lower lid, bluish-purple in colour at first, but passing later through the other stages of a bruise; there is probably no contusion of the skin, as in the ordinary black eye, which is at first reddish-purple, the ocular conjunctiva is considerably involved, but the effusion rarely extends above the cornea, and its posterior limits cannot be seen. The bleeding usually arises from laceration of the dura mater and bone, but, when abundant, may come from the cavernous sinus, and the eye may even be pushed forwards (proptosis); in some cases pulsation is to be felt within the orbit, and then a traumatic orbital aneurism or aneurismal varix is present.

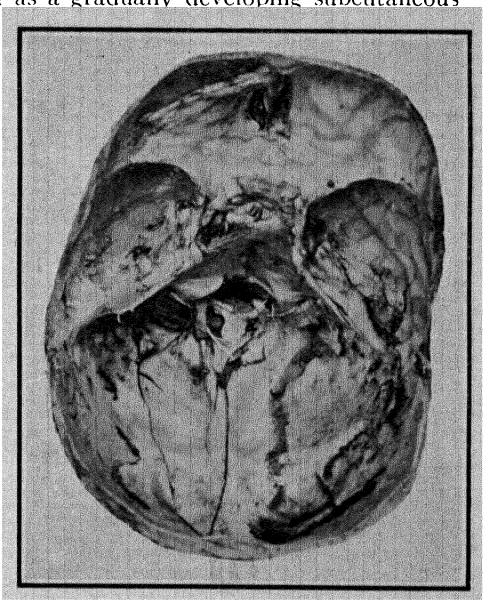

FIG 508.—BASE OF SKULL OF A CHILD AGED TEN, SHOWING FRACTURE INVOLVING POSTERIOR FOSSA

In the *middle fossa* the blood may enter the nose or mouth, a part being swallowed, but more commonly it escapes from the ears. Examination of the naso-pharynx and ear should always be made in serious head injuries, and if practicable by a specialist. It may be possible to see blood trickling in a thin stream from the Eustachian tube when there is no external evidence of bleeding; or the blood may collect in the tympanic antrum and be seen through an intact membrane as a dark bluish-black collection. If the bleeding is abundant, it probably comes from one of the vascular channels at the base of the skull, but if only slight in amount and of short duration, it may be induced by any of the following lesions, as well as by a fractured base, *viz.*: (*a*) A simple rupture of the membrana tympani, (*b*) separa-

tion of the cartilage of the pinna, with tearing of the lining of the external meatus; (*c*) fracture of the anterior and lower part of the tympanic plate, as by a blow on the jaw, which drives the condyle forcibly against it.

In the *posterior fossa* the bleeding is usually subcutaneous, showing itself around the mastoid process, and extending downwards amongst the muscles at the back of the neck.

(3) *Discharge of cerebro-spinal fluid* (p. 868) is an indication that a communication exists with the subdural space. The fluid may be discharged from one or both ears, but has also been met with coming from the nose or cranial vault; when from the ear, the dura mater has probably been laid open through the prolongation which accompanies the auditory nerve in the internal meatus by a fracture traversing the petrous bone. At first it is probably blood-stained, but soon becomes quite clear. The amount discharged may be small, but not unfrequently it comes away in large quantities, soaking the pillow and dressings, and, indeed, can sometimes be caught in a test-tube as it trickles from the meatus.

When the flow of fluid from the nose persists, the condition is known as *post-traumatic cerebro-spinal rhinorrhœa* and is one of the most serious complications of cranial injury. As a rule the fistula follows either a fracture involving the cribriform plates of the ethmoid or one involving the roof of the frontal sinus.

(4) Escape of brain substance from the ear has also occurred in a few instances, most of them fatal.

(5) *Lesions of the nerves* issuing from the base of the skull are occasionally produced. For symptoms, etc., see Chapter XV. The nerve most commonly involved is the facial, as it passes through the aqueductus Fallopii; the paralysis may develop either immediately, or more often about the second or third week after the injury, disappearing in about a month, and then evidently due to its implication in the callus (p. 406). A certain amount of deafness is often associated with it from injury to the auditory nerve. Fractures through the anterior fossa are often followed by loss of smell from injury to the olfactory nerves.

The **Prognosis** of a fractured base has much improved during recent years, as a result of the application of antiseptics to the auditory meatus. If the patient escapes death from acute cerebral complications, the bones of the skull unite rapidly, and a good result may be expected, although troublesome sequelæ may follow from the development of various types of late cerebral mischief, or from the injury sustained by nerves or vessels, or from their compression in callus or new bone.

Treatment.—Seeing that the chief danger to the patient arises from infection of the meninges, the greatest care must be directed towards preventing the access of bacteria. Unfortunately, it is impossible to apply dressings to the naso-pharynx, or even to wash it out thoroughly with antiseptics, and the only satisfaction about such cases is that the rareness of the loss of the cerebro-spinal fluid suggests

situation, whilst it has also been shown that in the majority of cases the upper part of the nasal cavity is aseptic. With the ear, however, things are very different. The pinna should be thoroughly cleansed, and the meatus, if no previous otorrhœa existed, should be gently but thoroughly irrigated with warm 1 in 20 carbolic lotion, or filled with 2½ per cent. tincture of iodine, which is then washed out with alcohol, any cerumen being taken away with forceps if possible. A large pad of sterilized gauze and wool should be bandaged over the ear and head, and replaced as often as necessary. The presence of chronic otorrhœa is obviously a serious complication, and may determine grave septic infection of the meninges. Opinions differ somewhat as to treatment under these circumstances. Some say that all such cases demand an immediate complete mastoid operation so as to protect the lesion in the base of the skull. Others, probably with justice, suggest that such a procedure may light up infection by interference, and counsel watchful delay, only opening up the mastoid process should symptoms suggest its necessity. It must not be forgotten that the escape of cerebro-spinal fluid through the ear is likely to wash infective material outwards and not inwards.

Beyond this, the treatment of fractured base is directed to the cerebral condition, and does not differ from that usually applied to head injuries, *viz.* cold to the shaved head, a smart calomel purge to start with, low diet, and absolute quiet in a dark room. In the absence of signs of cerebral irritation or inflammation, *viz.* increased rapidity of pulse, persistent headache, giddiness, etc., the patient may be allowed to sit up in bed at the end of a week, and his diet is gradually increased; but he should not be permitted to get out of bed for a fortnight, and even then must keep very quiet, and not think of returning to work for six or eight weeks.

Post-traumatic cerebro-spinal rhinorrhœa demands operative treatment because of the almost certain complication of meningitis, which is a common cause of death in those cases not operated upon. This is especially so when the rhinorrhœa commences some time after the head injury. Spontaneous healing is unlikely to occur if the condition has persisted for several weeks. Many operations have been devised for the closure of the fistula, amongst them being (*a*) excision of the tract and direct suture of the defect in the dura mater; (*b*) obliteration of the line of fracture by Horsley's wax; (*c*) obliteration of the defect by grafts of pericranial tissue, periosteum, fascia lata, or muscle. Such an operation demands the elevation of an osteoplastic flap in the frontal region and the discovery of the fistula by an extradural approach.

For the later management of head cases, see p. 885.

3. **Depressed or Punctured Fractures** usually involve the vault of the cranium, and are due to direct violence, either from a fall or blow, causing a closed or open fracture, or from a penetrating injury occasioning a punctured fracture (Fig. 509). In both cases there is often a considerable amount of comminution.

It is quite possible for the outer table to be broken and depressed without any injury to the inner, where an air cavity exists in the bone, or if the diploë is very thick; thus, the bone may be driven in over the frontal sinus without injury to its inner wall, or the mastoid may be similarly affected. The inner table has also been broken, and fragments even separated, as a result of a simple depression without fracture of the outer table; this rarely occurs in adults, but is not uncommon in children. Amongst the latter, it is also possible for a considerable depression to exist without any fracture of the inner table.

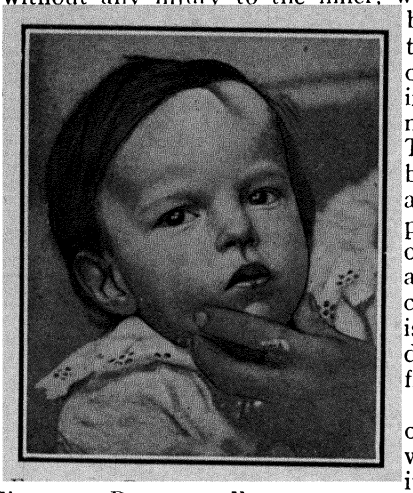

FIG 509.—DEPRESSED FRACTURE OF SKULL IN A CHILD

More usually both inner and outer tables are involved, and when this is due to force reaching it from without, the inner table is always more damaged than the outer, especially in the punctured variety (Figs. 510 and 511). When, however, the force is applied from within, as by a bullet which has traversed the brain, the outer table suffers more than the inner. The causes of this condition are similar from whichever side the force comes, but need only be considered when the violence acts from without. (*a*) The inner table is less supported than the outer, having merely the soft brain and dura mater within, and hence is extensively splintered, just as a nail driven through an unsupported piece of wood causes ripping up of its under surface. (*b*) The loss of momentum of the fracturing body will assist this; the greater the momentum of a penetrating body, the more cleanly it cuts, a smaller momentum breaking or splintering rather than cut-

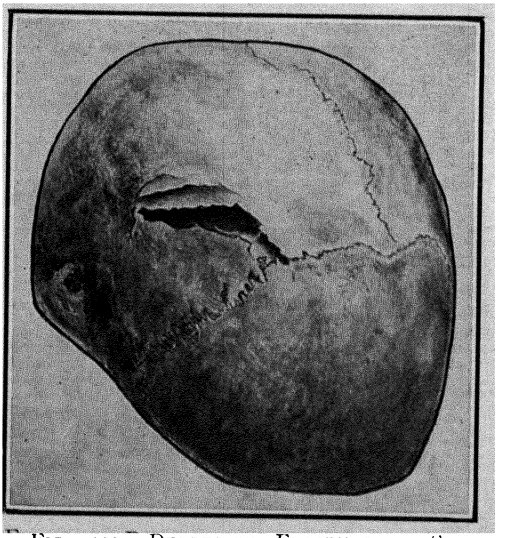

FIG 510.—DEPRESSED FRACTURE OF SKULL SEEN FROM WITHOUT

ting; of course, a considerable amount of force is expended in penetrating the outer table. (*c*) The débris caused by the injury to the outer table will add to the bulk of the penetrating body, and its wedge-like action still further increases the injury to the inner table. (*d*) All force tends to radiate and diffuse itself from the spot struck, and hence, if the outer table is first injured, the force will be disseminated over a more extensive area of the inner.

The **Symptoms** and **Signs** arising from a depressed fracture vary widely in their nature, and are partly due to the injury inflicted on the bone, partly to that sustained by the brain, whilst the infection or not of the wound is of the gravest significance.

Locally, when an external wound is present, one sees blood or cerebro-spinal fluid escaping, or even brain substance protruding.

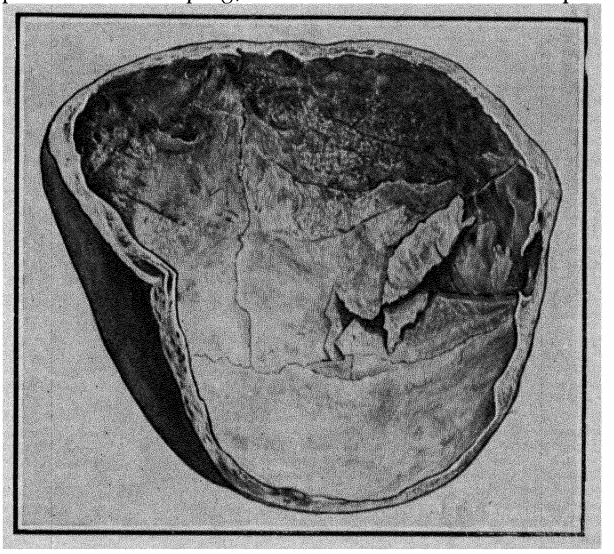

FIG 511.—DEPRESSED FRACTURE OF SKULL SEEN FROM WITHIN

The damage to the bone may be seen or felt, and the extent of the depression or comminution thus ascertained. When there is no external wound, a hæmatoma of variable size forms under the scalp, more or less obscuring the fracture. The character of the lesion is a matter of considerable importance from a prognostic point of view. When the bone shelves evenly in all directions, a *pond* or *saucer* fracture is said to be present, and this is tolerably amenable to treatment; when, however, the depression is sudden and complete, the detached portion lying below the level of the rest of the bone, it is termed a *gutter* fracture, and the prognosis is increasingly grave. The two forms are, however, often associated. Necessarily, considerable variations are met with in this type of fracture, according to the nature of the injury and the means by which it was inflicted. Thus,

if it is due to a fall on the vertex, there is often a ragged, irregular scalp wound, through which the depression can be seen or felt; if caused by the puncture of a sharp tool, such as a pickaxe, there is only a small external opening corresponding to the hole in the skull, in which the point of the instrument may be found embedded. A slicing cut with a sabre or hatchet produces a clean incision through the scalp, together with a linear groove in the skull, perhaps somewhat bevelled, which may or may not penetrate its whole thickness. Sometimes detached portions of the skull are raised above their ordinary level, constituting an *elevated* fracture; it is usually associated with depression of surrounding parts.

In a *closed depressed fracture* the patient usually suffers from concussion, followed almost immediately by compression, the latter due in part to the depressed bone, but mainly to exudation of blood and bruising of the brain; if this is at all extensive and remains unrelieved, a fatal result quickly follows. Where, however, the depression is but slight, the symptoms of compression may be absent or not marked, and the patient recovers, perhaps to become the subject of chronic headache, traumatic epilepsy or insanity at a later date, induced by the irritation of the dura mater and of the subjacent cortex. If the depressed fragments irritate the motor area, convulsions, spasms or paralysis may be thereby induced.

In an *open depressed or punctured fracture* the immediate effects are not necessarily severe, the patient perhaps not even suffering from concussion, though brain substance presents in the wound, the more limited the spot injured, the less the concussion. The explanation of this fact is that the blow has expended its force in fracturing the cranium, and hence does little harm to the brain, in the same way that a watch may receive but slight damage from a fall if the glass is broken, whilst if the latter remains intact the works are liable to suffer.

Left to itself, such a fracture is sure to become *infected*, and inflammation of the bone, brain, or membranes will follow.

Septic osteitis leads to necrosis of the fragments, which may be seen lying dead and yellow at the bottom of the wound, whilst the inflammation may either spread along the diploë to the surrounding bone, causing extensive necrosis with pyæmia, or between the bone and the dura mater, leading to a subcranial abscess.

When once the dura mater has been penetrated, inflammation is liable to spread to the meninges, and then a diffuse or localized suppurative meningitis, accompanied or not with a localized suppuration of the brain, will ensue. Even if the dura mater has not been opened by the injury, the irritation of depressed spicules of bone and the presence of a purulent exudation often lead to its ulceration at a later date. If there is a free external opening, allowing a ready exit to the discharge, and thus preventing tension, the process may be quite limited, and compression of the brain or diffuse septic meningitis is avoided; but if the fragments of bone are locked together as well as depressed, and the external wound is small, retention of inflammatory products may lead to their diffusion, and the symptoms of compression will soon become evident. A hernia cerebri may also form subsequently.

The **Treatment** of these cases is based on the belief that a patient runs greater risk from leaving a slight depression unrelieved than by making even what may prove to be an unnecessary exploration. The object of the operation is to protect the dura mater, if uninjured, from the irritation of the sharp edges of depressed fragments; to free the brain from the pressure of the depressed bone or of effused blood; and if the dura mater is torn, to remove hopelessly damaged brain

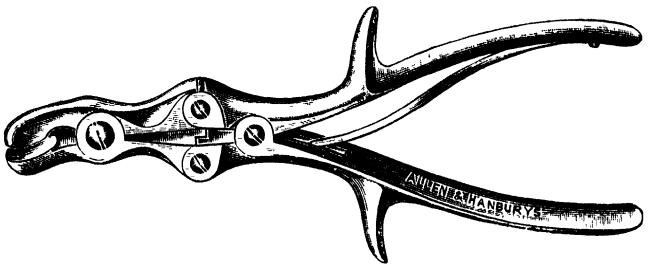

FIG. 512.—A USEFUL TYPE OF SKULL FORCEPS.
The multiple joints make its action easy, and no force is required when using this instrument

substance, or protect it as far as possible from the risks of infection, or to provide free drainage if infection is already present.

The indications for operation may be epitomized thus:

(i.) In all punctured fractures, operate.
(ii.) In all open depressed fractures, operate.
(iii.) In closed depressed fractures: In adults, always operate; in children, if gutter-shaped, operate; if pond-shaped, wait for symptoms, unless the fracture is a bad one.

When an operation has once been decided on, the sooner it is undertaken the better. The scalp should be shaved and thoroughly purified. An anæsthetic may or may not be given, according to the condition

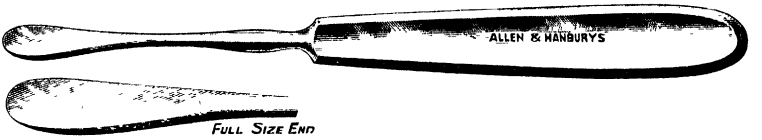

FIG. 513.—ADSON'S ELEVATOR.
A very useful instrument in elevating small portions of bone.

of the patient; if he is comatose, he requires no anæsthetic; if he is partially sensible, local infiltration anæsthesia should be employed, or gas and oxygen; chloroform is especially undesirable. In a *closed depressed fracture* a flap of scalp is turned down so as to avoid the presence of a cicatrix over the lesion in the bone. Having cleared away blood-clot and exposed the fracture, some loose fragments may be exposed, and the removal of these may permit of the introduction of an elevator (Fig. 513); if more room is required, skull forceps

(Fig. 512) must be used to enlarge the opening. If there are no loose fragments, an opening must be made with a trephine. The centre-pin is placed upon some firm undepressed bone as near the margin as possible (Fig. 514), and a circle of bone removed. An elevator can now be introduced, the fragments prised up into position, and the condition of the inner table investigated. Care must be taken in removing loose fragments not to tear the dura mater by injudicious violence, especially is this the case when the fracture lies over one of the venous sinuses. Sufficient bone must be taken away to allow the whole of the damaged area to be examined.

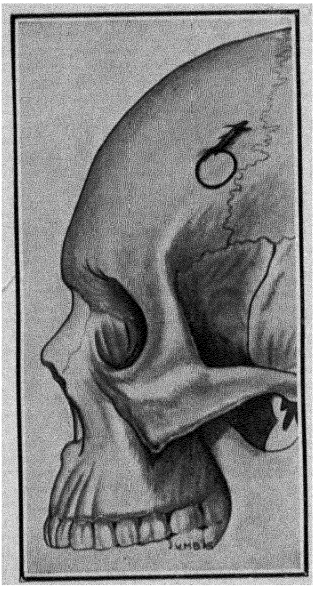

FIG. 514.—PUNCTURED FRACTURE OF SKULL, SHOWING SPOT FOR APPLICATION OF TREPHINE.

If the dura mater has been injured, brain substance mixed with blood may escape as soon as the flap is raised. When the bone has been dealt with, any protruding portion of cerebral material is removed, and the dura mater lightly stitched across the gap.

In an **open depressed fracture** the conditions vary much, and the surgical treatment must be modified to meet the requirements of the case. The general plan of treatment for penetrating gunshot wounds may be taken as a model. All patients injured in this way should be X-rayed prior to operation, so that the surgeon may know exactly whether or not fragments of bone have been driven into the brain, and some idea as to their depth may be reached. Local infiltration anæsthesia by novocain and adrenalin is to be preferred, but gas and oxygen may be administered after a dose of morphia, or ether by Shipway's apparatus; chloroform is contra-indicated.

After shaving and purification of the scalp the margins of the wound should be excised, and provision made for effective exposure of the bone, either by turning down a flap or by enlarging the original wound. The latter plan is that recommended by Cushing, *viz.* to make three radiating incisions which shall extend out sufficiently far to allow large flaps to be raised, thereby laying bare the bone around the lesion; such flaps can be brought together later on with but little tension and securely sutured.

The opening in the dura must be handled with the utmost consideration. If torn and dirty, the margins may be carefully trimmed; but as little tissue as possible must be removed, since protective adhesions may thereby be broken down, or cortical vessels injured.

The brain itself is gently explored, and foreign bodies or fragments

of bone driven in must be removed. In this stage gentle irrigation with sterilized normal salt solution at a temperature of about 110° F. will be useful, both to wash away disintegrated brain and blood, and to assist in hæmostasis. A large wound may permit of the entrance of a finger, and fragments may be removed by forceps; but for a small penetrating wound a soft catheter should be passed down the track, and softened brain and foreign bodies, or bits of bone, may be removed by suction. Disintegrated brain is removed by this means; normal brain tissue is not affected

Finally, it is recommended by Cushing that the track should be injected with a small quantity of the oily solution of dichloramine-T, and this is also gently applied to the margins of the wound in the dura mater, which is completely closed in suitable cases, or partly closed in others A drainage-tube or gauze pack may be placed down to the opening in the dura, but not through it. The scalp incisions are completely closed, unless drainage is employed; the more complete and thorough the operation, the less necessary is drainage, and whenever possible it should be avoided

Hæmorrhage from the cortex is sometimes troublesome, and if the bleeding vessel cannot be secured, a small fragment of muscle should be pressed over the bleeding point for some moments till it sticks, and then the bleeding will have ceased.

In civilian cases where a foreign body has been introduced, or a septic penetrating body such as the point of a pickaxe inflicted the wound, the above described procedure will be required. When, however, the lesion is not of this type, but inflicted by a blunt non-penetrating instrument, such as a poker, this elaborate procedure may be simplified, and after removing loose fragments of bone and brain the surface is washed over with hot salt solution, and covered up with dura mater, with or without drainage, as seems desirable.

In all cases the patient should be confined to bed, with the head slightly raised on a single pillow, and the general rules suitable to head injuries followed.

The symptoms and treatment of the intracranial complications of head injuries are dealt with in the next chapter.

CHAPTER XXVII.

AFFECTIONS OF THE BRAIN AND ITS MEMBRANES.

Cranio-Cerebral Topography.

It is scarcely necessary or desirable in a students' manual to deal exhaustively with this subject. The main facts can alone be referred to, and larger textbooks of operative surgery or surgical anatomy consulted for further details.

The *Fissure of Rolando* may be found topographically by the following method: The upper extremity of the fissure corresponds to a point half an inch behind the centre of the line extending from the glabella to the external occipital protuberance. The direction of the sulcus is downwards and forwards at an angle of about 67° to the middle line. This may be indicated by laying a half-sheet of letter-paper over the skull, the long side corresponding to the middle line, and with its centre over the upper limit of the fissure, the anterior half is now folded over obliquely from this point, leaving an angle of 45° between the front of the paper and the middle line of the skull, and then the same process is again repeated, bisecting the angle and leaving one of about 67°, so that the anterior limit of the folded paper corresponds to the line of the fissure, which is about $3\frac{3}{8}$ inches in length. A 'Rolandometer,' consisting of two strips of flexible metal united at the appropriate angle, is now sold by many instrument-makers. As a general rule this 'Rolandic line' crosses

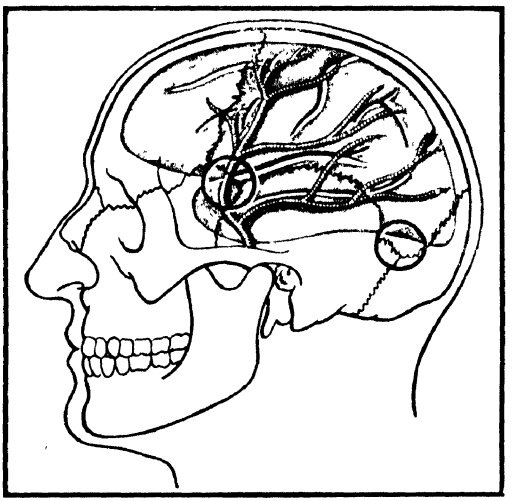

FIG. 515. DIAGRAM SHOWING THE IMPORTANT FISSURES IN THE BRAIN AND THE BRANCHES OF THE MIDDLE MENINGEAL ARTERY.

The anterior circle is for exposure of the anterior branch of the artery, the posterior one is for exposure of the lateral sinus.

the fissure about its centre, being in front of the fissure above and a little behind it below; but it is sufficiently accurate for practical purposes. The centre of the line between the 'mid-point' and the external occipital protuberance marks the position of the parieto-occipital fissure, and a line drawn from this point to the external angular process of the frontal bone corresponds in its anterior portion to the horizontal limb of the Sylvian fissure (Fig. 515).

Methods of Opening the Cranium.

In the old days but one instrument was employed for this purpose, *viz.* the trephine; but our increasing knowledge of cerebral lesions and the security given by aseptic methods have necessitated a considerable elaboration in the methods of operating on the cranium

1. Simple *trephining* is still employed in dealing with lesions where an extensive exposure of the brain is not required. The modern trephine (Fig. 516) is often fitted with a solid metal handle to render sterilization easy, and the crown is usually bevelled and not straight, so as to check the liability to slip inwards and wound the dura. The scalp is incised and turned aside by raising a flap which has its base downwards, so as to ensure its vitality. Bleeding is abundant, but is controlled by special scalp forceps, which grasp the galea and are turned backwards out of the way.

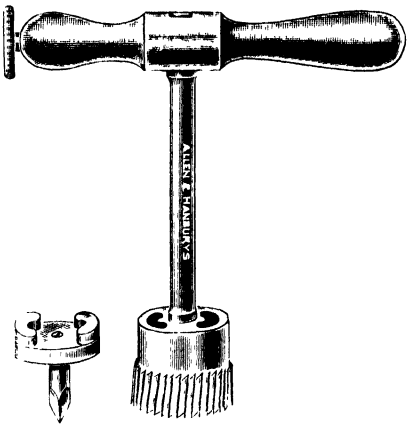

FIG. 516.—A MODERN TREPHINE

The pericranium is stripped from the bone, and the trephine applied with the centre-pin projecting. As soon as a well-marked groove has been made, the centre-pin is withdrawn or removed, and the instrument carried through the cranium. An increased flow of blood will often indicate when the diploë is reached, and care must be taken not to injure the dura. To this end the groove in the bone is carefully examined from time to time by a flattened probe or the blunt end of a needle, and the more so when the operation is undertaken in a region where the bone is known to be of irregular thickness, or if a venous sinus lies beneath it. The disc is removed by an elevator. Considerable bleeding sometimes takes place from the section of the bone, but can usually be controlled by crushing the spot with powerful forceps, or by rubbing in Horsley's wax (carbolic acid, 1 part, oil, 2 parts; wax, 7 parts). If the opening is not sufficiently large, it may be increased by skull forceps. The use of the trephine may be avoided by employing an electrically-

driven perforator or burr, which penetrates the skull, but does not injure the dura mater

2 In many cases of cerebral abscess the trephine is unnecessary, as the causative focus (*e.g* mastoid disease or frontal sinus empyema) is first opened up, and the cranial cavity reached by removing portions

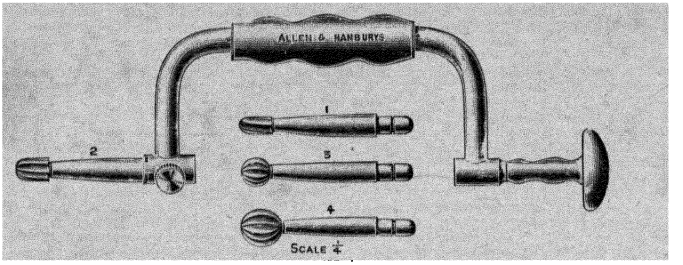

FIG. 517.—HUDSON'S BRACE WITH CYLINDRO-SPHERICAL AND SPHERICAL BURRS

of bone with a gouge. The same thing occurs in many depressed fractures.

3. In a decompression operation or for the removal of a cerebral tumour, where a considerable opening has to be made, various plans are adopted.

(*a*) Some surgeons utilize a large 2-inch trephine, but this is obviously undesirable owing to the irregular thickness of the skull, and the difficulty which attends the equal deepening of the groove in all directions over such a large circumference.

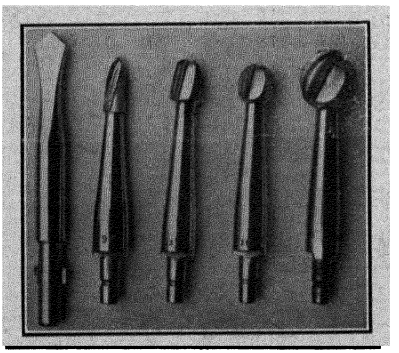

FIG. 518.—A STARTING BIT AND SERIES OF BURRS FOR TREPHINING THE SKULL

(*b*) When it is undesirable to replace the bones, a small trephine hole and enlargement by skull forceps should be adopted.

(*c*) Of late, however, some form of Wagner's osteoplastic method (Fig. 522) has been chiefly used. In this a large flap of scalp tissues is turned down together with the underlying bone, laying bare the dura mater. Probably the simplest way of dividing the bone is to make four small burr openings at the corners of the flap with a Hudson's brace (Figs. 517 and 518), and connect these by the use of a Gigli saw, *i.e.* a piano-wire with a screw-thread turned on it, and with handles attached at each end, passed by means of a probe under the bone from one opening to another (Figs. 519-521); or by the use

of a de Vilbiss' rongeur on two sides, whilst the upper end is sawn through by a Hey's saw set on the slant, so that the incision is bevelled, thereby preventing the bone from slipping in when replaced, and the base is divided by a Gigli saw or broken across This procedure is a serious one, attended by considerable shock and hæmorrhage, and



FIG 519.—A MODIFIED GIGLI GUIDE, SHOWING THE METHOD IN WHICH THE SAW IS ATTACHED TO IT

therefore may be undertaken as a preliminary measure a week or ten days before the lesion in the brain is attacked

Cranioplasty.—Loss of substance of the cranium arises from many different causes, and varies both in extent and effect. Operation may have to be undertaken for one of two reasons: either to protect

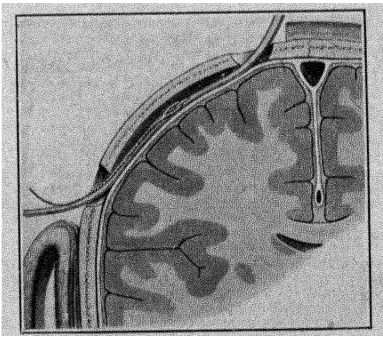

FIG 520.—METHOD OF INSERTING A GIGLI SAW BY MEANS OF A GUIDE, WHICH ALSO ACTS AS A PROTECTOR

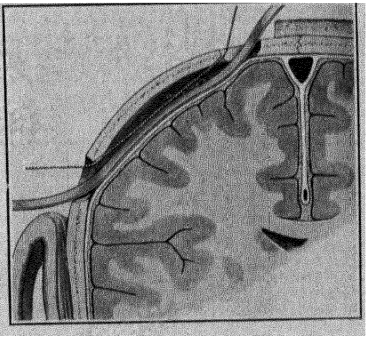

FIG 521

The skull is cut with the saw, the underlying dura mater and brain are protected by a metal guide

the patient from the mechanical risks arising from the presence of the defective area, or to attempt to remedy the effects of intracranial adhesions, etc., in the direction of persistent headache, epilepsy, etc. In the latter case it may be necessary to include the brain itself in the scope of the operation; this feature is referred to elsewhere (p. 938).

(*a*) Some degree of protection may be ensured by wearing a metal

plate over the cranial defect secured in position over the scalp by elastic straps, but this is unsightly and unworthy of modern surgery.

(*b*) A bone graft is used. It is desirable in all these cases to detach the dura from the edges of the defect and for a distance of a centimetre or more beyond. The operation consists in turning up or down a flap of scalp so as to expose the defect, care must be taken in dividing the scar tissue which may be present between the dura and the scalp. The dura is then carefully freed from the margins of the opening by a raspatory, and the closeness of this connection is very marked, as soon as the detachment is effected, the dura drops back somewhat, and the cerebral pulsations become evident

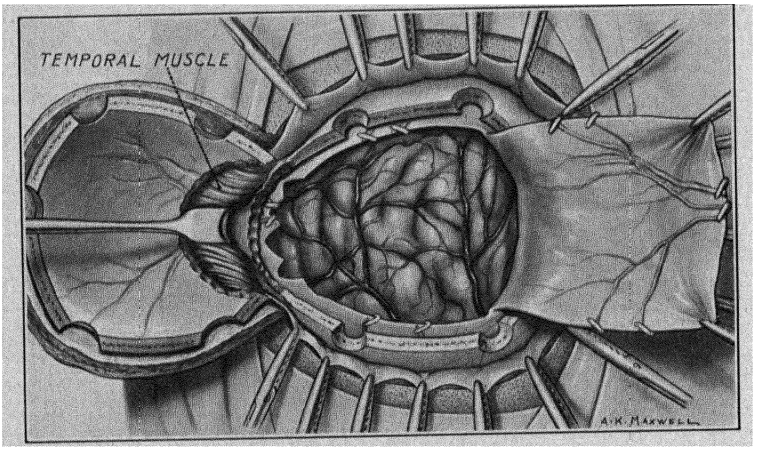

FIG. 522.—OSTEOPLASTIC METHOD OF OPENING CRANIUM

It will be noticed that the flap of skin and bone is larger above than below, thereby facilitating division of the base; openings have been made by a small burr, and the base divided, the dura mater has been turned up and the meningeal vessels controlled with silver clips

The treatment of the dura and brain is mentioned elsewhere (p. 938). Three chief plans of dealing with the opening may be mentioned. (*a*) A flap of pericranium and outer table is fashioned so as to fit accurately over the opening. A couple of small drill holes at each end of the defect through the cranial margins and bone flap permits of the introduction of a mattress suture to fix the flap *in situ*. The scalp is replaced and secured by sutures without drainage. (*b*) Instead of a bone graft from the neighbourhood, one can be obtained quite well from the tibial subcutaneous surface, or from the outer wall of the ilium including the periosteum (Figs. 523 and 524). It is fixed by a large number of small sutures between the pericranium and the periosteum of the flap. In either case it is wise to freshen up and bevel the margins of the cranial defect by the use of a burr. Excellent

results have often followed these proceedings, a good solid skull resulting, and the headache and pain being completely relieved.

(*c*) A simpler proceeding, and one requiring less technical skill, consists in filling up the opening with flaps cut from a costal cartilage. The dura mater is freed from the bone as described above. The surgeon then exposes the seventh and eighth costal cartilages through a suitable incision, and cuts from it a strip of cartilage a little larger than the hole in the skull, sometimes for a large defect two or three such strips are required, they vary in thickness up to one-eighth of an inch. These are slipped into the opening so as to occupy the space between the dura and the bone, and are fixed by overlapping the opening on the inner side. The cartilage is believed to remain as such, and protects the dura from re-attaching itself to the skull. Admirable results follow, at any rate for a time, the late cerebral

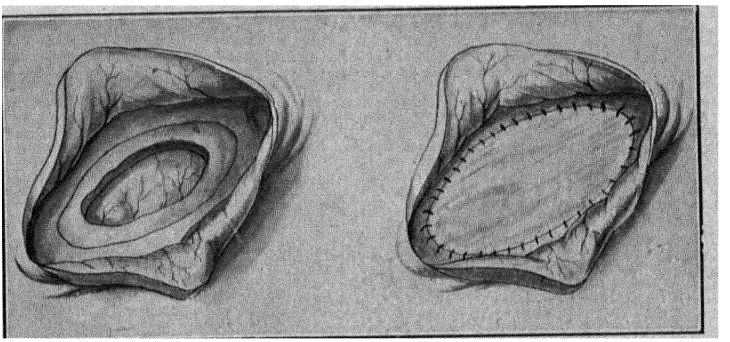

FIGS. 523 AND 524.—CRANIOPLASTY BY FIXATION OF A BONY FLAP INCLUDING THE PERIOSTEUM OVER DEFECT IN THE SKULL BY MULTIPLE SUTURES.

symptoms are relieved, although there is but little added cranial protection. Celluloid plates have been used in exactly the same manner, but the late results are often far from satisfactory, and the plates often have to be removed.

The Cerebro-Spinal Fluid.

Normal cerebro-spinal fluid is slightly alkaline and as clear as water, with a specific gravity of 1006 to 1008, it contains traces of globulin (not more than 0·025 per cent.), and of a copper-reducing substance, and perhaps a few lymphocytes. It is calculated that from 100 to 130 c.c. are present in the normal adult, but this amount is readily increased if there is a free exit, as in some fractures of the base, or if the escape is blocked, and the fluid is present under tension.

It is mainly derived from the choroid plexuses of the lateral ventricles, but receives additions from similar structures in the third and fourth ventricles. It appears to be a true secretion, inasmuch as

pigments, such as bile, which stain practically all structures in the body, do not pass into it, and various drugs, such as salvarsan, are also held back. The fluid has a definite circulation within the cerebro-spinal space. Starting from the lateral ventricle on either side, it passes down through the Y-shaped foramen of Monro into the third ventricle, and thence by way of the iter into the fourth. Escaping from here through the foramina of Magendie and Luschka, it collects in the cisterna magna, and thence spreads downwards along and around the spinal cord, and forwards along the base of the skull, to occupy the various spaces left between the various elements of the base of the brain. Thence it passes up in the pia-arachnal sheath over the convolutions, dipping with the vessels into the sulci, and giving sheaths along the various nerves as they emerge from the brain and engage the different foramina; it also communicates with the fluid in the internal ear. Finally, it is absorbed into the venous sinuses of the skull through the arachnoid villi (Fig. 525), which communicate in large numbers with the interior of the sinuses; some of the spinal fluid escapes into the lymphatics of the nerve-roots (Figs. 526 and 527). It must be remembered that there are no lymphatics in the brain, and that the extensions of the pia arachnoid along the cerebral vessels serve to remove or supply fluid to it, and a very efficient mechanism for this purpose it is.

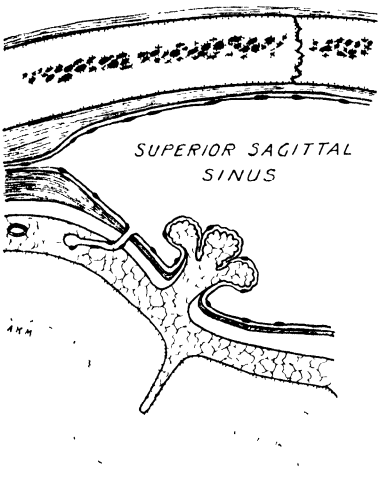

FIG 525.—DRAWING SHOWING THE RELATIONS OF THE ARACHNOID VILLI TO THE LONGITUDINAL SINUS

The removal of cerebro-spinal fluid has been much employed since Quincke originally recommended it in 1891, and is of the greatest value both diagnostically and therapeutically. Formerly lumbar puncture was the only method adopted, but now other situations may be utilized for this purpose.

1. **Ventricular Puncture** is one for which considerable skill and special knowledge must be available. The main cavity of the lateral ventricle is situated close to the median line and about 4 or 5 cm. in front of the upper end of the Rolandic fissure.

The technique of ventriculography consists in making two small incisions in the scalp, about one inch on either side of the mid-line, and about two inches above the lambdoid suture. Local anæsthesia with ½ per cent. novocaine is quite sufficient for this operation. The lips of the incision are retracted and small burr-holes are made. The dura mater when exposed is carefully nicked with a small crucial incision. The patient is usually placed in a sitting or semi-recumbent

position, and it is important that the head should be securely fixed. A ventricular needle is introduced through the burr-hole and passed downwards, forwards, and inwards, in such a way that the lateral ventricle is entered at the junction of the body with the occipital horn (Fig. 528). A known quantity of cerebro-spinal fluid is withdrawn and a smaller known quantity of air injected. It is advisable to inject air into one side only, as by so doing the potency of the foramen of Monro can be determined by the passage of air from one ventricle to the other. If no fluid can be obtained from one ventricle, the needle must be inserted into the ventricle on the opposite side.

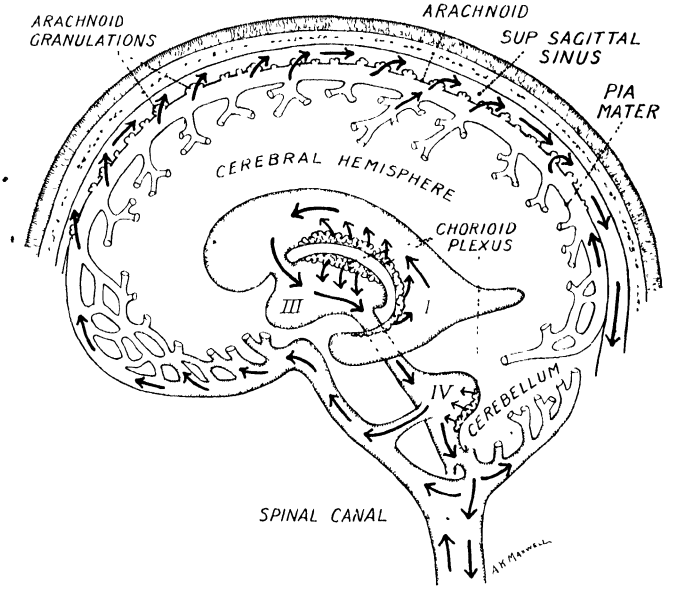

FIG 526.—DIAGRAM SHOWING THE COURSE OF CEREBRO-SPINAL FLUID FROM THE CHOROID PLEXUSES IN THE LATERAL VENTRICLES TO THE ARACHNOIDAL VILLI IN THE SUPERIOR LONGITUDINAL SINUS

As much cerebro-spinal fluid as possible is withdrawn, and is replaced by a somewhat smaller volume of air, except in cases of marked internal hydrocephalus. The average amount of air to be injected is between 50 and 120 c.c.

When the air has been injected the wounds are closed and the patient is transferred to the X-ray department. Lateral and antero-posterior skiagrams are taken. The lateral skiagrams (Fig. 529) may show deformity of the anterior or posterior horns by tumours situated in the frontal or occipital regions. The antero-posterior skiagrams (Fig. 530) may show a deflection of the ventricles from the mid-line or a filling defect of the third ventricle (Fig. 531).

Frontal Puncture for Ventriculography is advocated by quite a

number of neurological surgeons at the present time because there is little variation in the anatomy of the ventricular system at the point where the cannula enters it, in contradistinction to the great variation found in the size of the posterior horns. There is also better outlining of the entire ventricular system. The puncture is performed with the patient in the prone position with the head extended. A small incision is made about 10 cm. above the supra-orbital ridge and 2 cm. lateral to the mid-line. The scalp is retracted and a burr opening made in the skull. The dura mater is incised and a cannula inserted perpendicular to the surface of the skull and the ventricle tapped

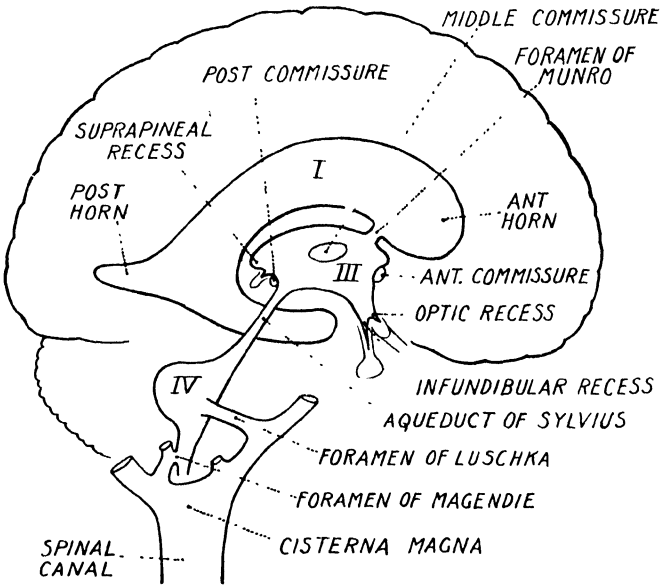

FIG. 527.—DIAGRAM OF THE VENTRICULAR SYSTEM OF THE BRAIN AND ITS CONNECTIONS

(Fig. 527). The needle is below the foramen of Munro, in contrast to the posterior ventricular puncture, when it is at the level of the foramen of Munro.

Ventricular estimation is a much simpler and safer procedure than ventriculography, and consists of tapping both lateral ventricles and not injecting air. Asymmetry of the lateral ventricles is in itself strong evidence of a cerebral tumour on the side of the smaller ventricle; further, a symmetrical hydrocephalus usually indicates a cerebellar tumour.

2. **Cisternal Puncture** (Figs. 533 and 534) has already been alluded to in connection with the diagnosis of tumours of the spine and spinal cord (p. 834). It is also employed for drainage purposes in connection with basal meningitis and may be of assistance when lumbar puncture

fails. A similar procedure has been utilized in some cases of meningitis arising in connection with mastoid suppuration; a radical operation is undertaken and the meninges opened, and it is then possible in some cases to wash the meningeal cavity out from this spot with the assistance of a lumbar puncture, and some excellent results have been obtained.

3. **Lumbar Puncture** is the method of withdrawal of cerebro-spinal fluid most commonly employed. The technique is quite simple: A stout antitoxin or exploring needle should be selected and sterilized by boiling, and the skin in the region of the third and fourth lumbar interspaces (the spinous process of the fourth vertebra is on a line joining the iliac crests) is to be carefully purified. The patient sits or lies with the body well flexed. The needle is then inserted in the fourth interspace, either in the middle line, or a third of an inch from it; it must be pointed forwards, with a very slight inclination upwards In most cases the needle will go straight into the spinal canal below the termination of the cord, and the fluid will escape. If bone is encountered, it is advisable to withdraw the needle and re-insert it at a slightly different angle In cases of repeated failure the third interspace may be tried. Under ordinary circumstances the fluid escapes quietly, drop by drop; but in cases of increased tension it may gush out freely. The pressure of the fluid can easily be measured by a manometer.

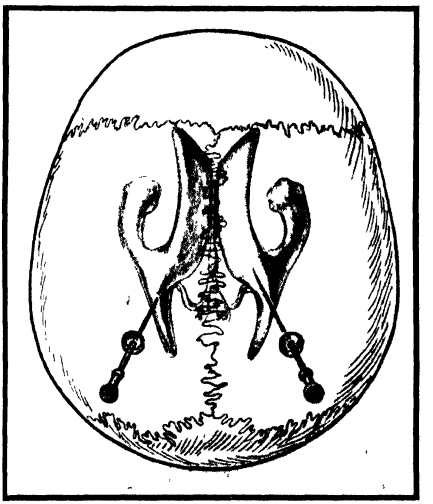

FIG 528.—DIAGRAM SHOWING THE VENTRICULAR SYSTEM OF THE BRAIN FROM ABOVE

It shows the position of the ventricular puncture.

The best manometer is that devised by Greenfield; it is convenient and easy to work (Fig. 535).

The characters of the cerebro-spinal fluid vary much in different conditions, both as to quantity and quality, and the study of these is of the greatest help in **diagnosis.** In *acute meningitis*, due to organisms other than the tubercle bacillus, the fluid is under pressure and turbid, containing much albumen. Many cells are present, mainly polymorphonuclear leucocytes, and the causative bacteria may be detected by suitable means. In *tuberculous meningitis* the fluid is almost clear and contains a slight excess of albumen and lymphocytes, but tubercle bacilli are rarely found. The fluid is, of course, under pressure and escapes from the needle in a brisk



FIG. 529.—LATERAL SKIAGRAM SHOWING ENLARGED LATERAL VENTRICLE DUE TO CEREBELLAR TUMOUR

stream. In *fracture of the base of the skull or of the spinal cord* in *injuries to the surface of the brain* and in *cerebral hæmorrhage*, blood usually appears around the lower end of the spinal cord within a few hours of the injury, and is intimately mixed with it. For its characters in *spinal cord tumours* see p. 834; in *anterior poliomyelitis*, p. 527, in *cerebral tumours*, p. 906 in *cerebral abscess* and *lateral sinus thrombosis* the fluid is normal but may be under excessive tension.

The **therapeutic** value of this procedure has perhaps scarcely been so fully recognized as its use in diagnosis. In many cases of meningitis the coma is due mainly to excessive cerebro-spinal fluid, and if the amount of this can be diminished the symptoms often abate. The value of lumbar puncture will, therefore, depend on whether or not it is possible to influence the intracranial tension thereby, and that, in turn, is dependent on the situation and character of the adhesions present. The puncture must, therefore, be obviously experimental, as one can never be certain as to the adhesions; but it is a simple proceeding, and may well be employed in all cases of meningitis, in the hope that some good may follow. In traumatic conditions it may be useful when the lesion is not very serious, and the pressure on the brain not hopelessly exaggerated. In cerebral tumours it must be employed with caution, as fatal results have followed the removal of a compara-



FIG. 530.—ANTERO-POSTERIOR VENTRICULOGRAM, SHOWING DILATED VENTRICLE DUE TO CEREBELLAR TUMOUR

tively small amount of fluid owing to undue pressure on the base thereby induced.

It is also possible to introduce drugs within the spinal theca after lumbar puncture, *e.g.* stovain or novocaine, for analgesic purposes (see Chapter XLVI.), anti-tetanic serum or a solution of magnesium sulphate in tetanus, or sodium bromide in delirium tremens. Attempts have also been made to influence by this route para-syphilitic nervous affections where the cerebro-spinal fluid remains positive to the Wassermann reaction in spite of general medication; thus salvarsanized serum, or autogenous blood-serum after the use of salvarsan, or a solution of corrosive sublimate, has been injected after puncturing the meninges, but no great success has followed this procedure

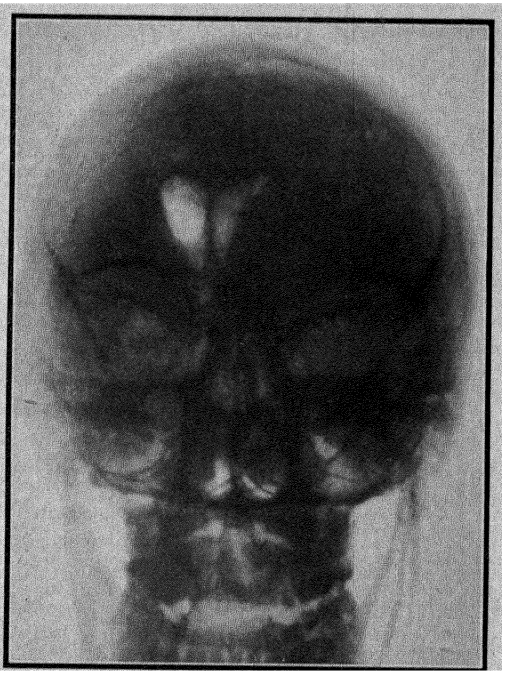

FIG. 531.—ANTERO-POSTERIOR VENTRICULOGRAM, SHOWING DISPLACEMENT OF THE VENTRICLES TO THE RIGHT DUE TO A LEFT OCCIPITAL TUMOUR

General Conditions of the Brain after Head Injuries.

Concussion of the Brain, or stunning, is a clinical condition, characterized by a more or less complete suspension of its functions as a result of injury to the head, which leads to some commotion of the cerebral substance, and may or may not be associated with hæmorrhage. It varies with the severity of the cause from a slight momentary giddiness and confusion of thought to the most complete insensibility, and is closely allied to shock, from which it is often distinguished with difficulty.

In fatal cases, one finds on post-mortem examination merely the same conditions as obtain in shock, *viz.* engorgement of the lungs, viscera, and the right side of the heart, whilst the brain presents some lesion of varying severity, from mere punctiform ecchymoses to actual disintegration and disorganization. The symptoms can scarcely be attributed to the injury itself or to a reflex stimulation of the vagus, as they often bear so little proportion to the degree of mischief.

Many theories of concussion have been formulated, but that of

Trotter seems to answer best most of the difficult questions that arise. He attributes the condition to 'hyperacute general compression of the brain.' When a severe blow is applied to the skull, this necessarily

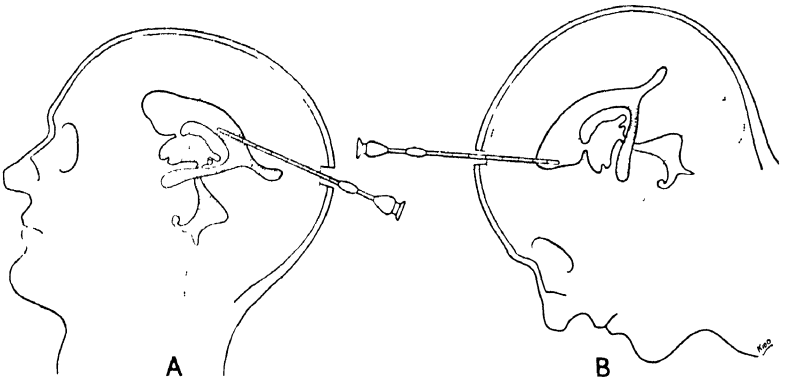

FIG. 532.—VENTRICULAR PUNCTURE.
A, Posterior method. B, Anterior or frontal method.

entails a diminution of the cranial capacity, which takes place at the expense of the fluid contents. The whole brain at the moment of contact becomes squeezed like a sponge, and owing to the severity of the blow the resistance offered by veins, capillaries, and arteries is practically the same, the result is a widespread anæmia, and this produces, as has been shown by Cushing, paralysis. The state of severe concussion is understandable if it is considered as an anæmia of the brain of very short duration, with immediate widespread paralysis, which has a tendency to pass off spontaneously.

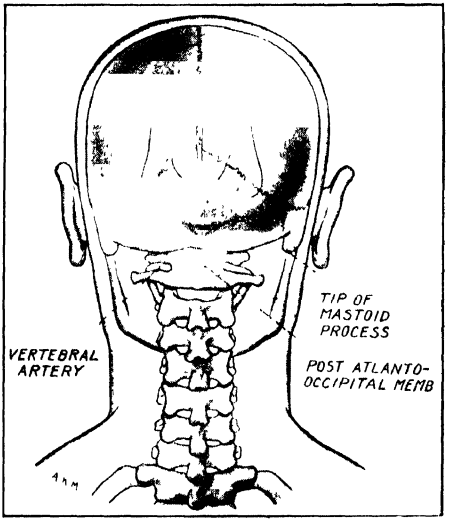

FIG. 533.—THE SITE FOR CISTERNAL PUNCTURE.
A line joining the tips of the mastoid processes passes through the centre of the posterior atlanto-occipital membrane.

The **Symptoms** vary considerably in degree, but in a well-marked case the stage of concussion is evidenced by unconsciousness, more or less complete, although the patient can sometimes be roused by shouting; he lies on his back, with the muscles relaxed and flaccid; the eyelids are closed, and the

conjunctivæ may be insensitive; the pupils vary, but are equal and often contracted, usually reacting to light; but in bad cases they are dilated, and do not contract when light is admitted. The surface of the body is pale, cold, and clammy. The respirations are slow, shallow, and sighing, whilst the pulse is rapid, weak, fluttering, and scarcely sensible to the fingers; the temperature is at first subnormal, the sphincters are relaxed, with perhaps unconscious evacuations from both bladder and bowel. The reflexes are present in the milder cases, though sluggish; in the more severe they may be entirely absent.

This condition may last for a considerable time, and then pass slowly into more profound unconsciousness and death, or be followed by the phenomena of inflammation, compression, or cerebral irritation. In the simpler cases, however, *reaction* soon begins to manifest itself. The patient is presumably put to bed, and warmth carefully applied to the extremities. The first sign of reaction is probably a slightly increased rate of both breathing and pulse, and he may be able to tell his name and address; sometimes he turns on his side, and pulls the bedclothes up to his face, since he feels cold and chilly as a result of the cutaneous anæmia. Gradually he becomes more and more rational, and the functions of both mind and body are restored, reaction being fully established by the occurrence of vomiting, due to a condition of cerebral hyperæmia following the anæmia. Probably he suffers from headache for some days, and a slight amount of fever will follow; but this passes off, and leaves the patient either quite well, or with a somewhat irritable brain requiring prolonged rest. Subsequent events may, however, prove that more mischief has been done than appears at first. Thus, some special function of the brain may be permanently lost or impaired, such as memory, hearing, or vision; a patient may forget the names of places or persons, or may lose all memory of time; speech may become defective or stammering, or a certain amount of asthenopia (weakness of vision) may supervene. Such individuals are very liable to develop signs of mental instability, and even delusional insanity or melancholia, if placed in positions of

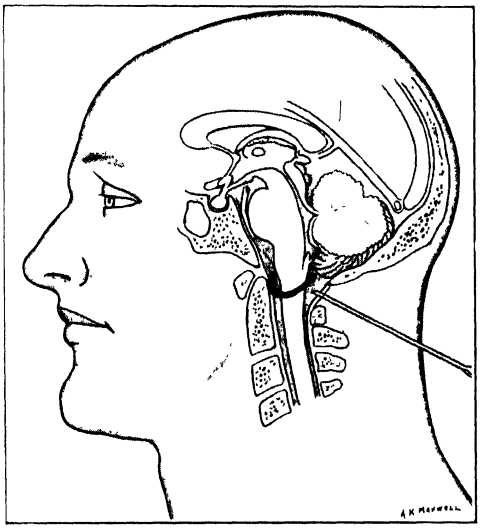

FIG. 534.—CISTERNAL PUNCTURE.
The dark ring is the outline of the mastoid process

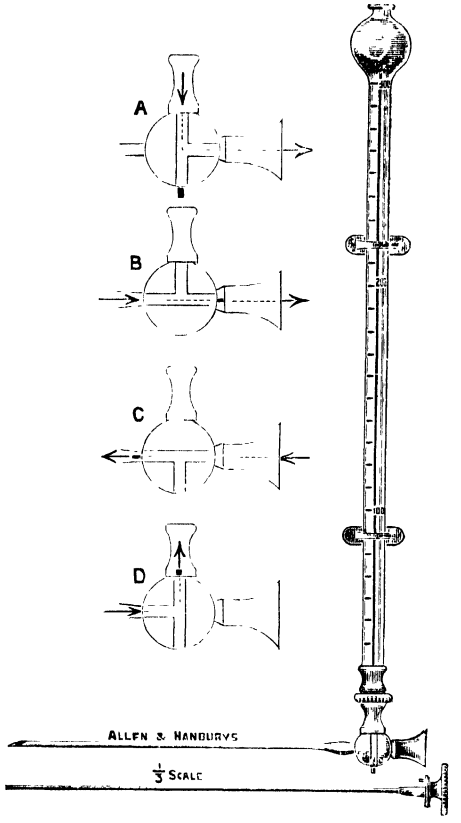

FIG 535 — GREENFIELD'S CEREBRO-SPINAL MANOMETER FOR MEASURING THE PRESSURE OF THE CEREBRO-SPINAL FLUID.

The manometer is attached by rubber tubing to the lumbar puncture needle as soon as it is felt to have entered the spinal column Then, while one hand holds the needle in place, the other simply removes the stilette, and turns the stopcock through a quarter of a circle in the direction of the manometer tube (D) When the pressure and pulsation of the fluid have been noted, a turn of the tap towards the handle of the needle (B) allows the fluid to run out of the manometer into a collecting tube and also allows further flow of fluid from the spinal canal When the tap is turned away from the manometer (A), the manometer empties itself, but the spinal canal is shut off If it is desired to inject anything into the spinal canal, the tap may be turned towards the point of the needle, so that the manometer is shut off (C).

responsibility or strain. Others seem to suffer from a general loss of nerve-tone (neurasthenia), rendering them incapable of fulfilling their ordinary duties in life. In all the more severe cases there is a complete lapse of memory as to the accident, and even as to the events which preceded and followed it, extending sometimes to a fortnight or more, and perhaps including a period during which the patient was apparently quite rational. Not a few of the post-concussion phenomena, however, are functional in origin, and can be treated by suggestion.

The **Treatment** of concussion very closely resembles that of shock, *viz* the patient is at once put to bed with the head low. If conscious, he may be given a drink of hot tea, but needless stimulation must be avoided, for fear of exciting hæmorrhage; an enema of hot coffee may be administered, or, if *in extremis*, brandy, or a hypodermic injection of strychnine. A good purge, such as 5 grains of calomel, or a drop or two of croton oil on sugar, should be administered after reaction in the milder cases, but while still unconscious in the graver forms. It is most important that the patient be kept quietly in bed for at least ten days or a fortnight after a moderately bad concussion, and free from all sources of worry and irritation, even though he feels quite well.

The diet must be restricted, and the bowels kept open. 'Make haste slowly' is here a golden rule.

When the unconsciousness is prolonged, and no signs of fracture of the cranium exist, lumbar puncture should be employed, and may be most beneficial. Dehydration has become a very useful form of treatment in the last decade; intravenous hypertonic saline solution is used in varying strengths up to 25 per cent., or 50 c.c. of 50 per cent. glucose. Should these forms of treatment fail, the head should be shaved, and an icebag applied; the bowels are opened regularly, and the state of the bladder attended to; the room must be kept dark and quiet, the attendants making as little noise as possible in walking and talking, etc.; sufficient nourishment must be given either by a spoon if the patient can thus take it, or by nutrient enemata or a nasal tube.

Cerebral Irritation.—By cerebral irritation is meant a clinical condition which sometimes follows concussion, characterized by great irritability of both mind and body. It usually results from blows or falls on the temple, forehead, or occiput, and is probably due to a superficial laceration of the brain, possibly in the frontal region, and to the hyperæmia caused by its subsequent repair.

The **Symptoms** are very characteristic, and usually manifest themselves two or three days after the injury, though sometimes earlier. The patient lies on his side in a condition of general flexion, the back arched, the legs drawn up to his abdomen with the knees bent, and the hands and arms drawn in. He is restless, and may toss about, but never extends himself fully or lies supine. The eyes are closely shut, and he resists all attempts to open them; the pupils are contracted; the temperature is usually a little raised, but the surface of the body and head are both cool; the pulse is quiet, but weak; the sphincters are usually in a normal condition, and the excreta are often passed in the bed, but the bladder may occasionally need to be emptied by catheter. In some mild instances the patient may get up to empty his bladder and then return to bed. He is by no means unconscious, but takes no heed of what is passing around, and is intensely and morbidly irritable. When disturbed, he will gnash his teeth, frown, swear, and resent the intrusion in the most expressive manner. At the end of a few days, or perhaps after a week or two, a marked alteration in the condition of the patient usually shows itself. He is less irritable, begins to stretch himself out, and with this is conjoined an improvement in both pulse and temperature. Sometimes he becomes childish, and needs to be taught the names of persons and things; at other times he is garrulous, perhaps giving a fresh story of his accident every day, but generally there is an absolute lapse of memory in this direction. Usually the brain recovers in time, but serious after-effects in the direction of chronic meningitis or mental aberration are likely to ensue.

Treatment.—The patient is kept quiet and free from noise and excitement; his diet must be light and nourishing. The head should not be too low, and an icebag may be used if the patient will permit it. The bowels are kept well open, and this is best done by saline

purges on account of their dehydrating action, which helps to reduce the œdema of the brain; sedatives such as bromide may be useful. Intravenous hypertonic saline should be tried. When the irritable stage is prolonged, subtemporal decompression should be performed. This frequently affords relief to the œdematous brain, with restoration of the normal circulation.

Compression of the Brain.—Compression is the term given to a clinical condition due to some abnormal and excessive intracranial pressure which disturbs the functions of the brain. In the earlier stages the blood in the veins and venous sinuses, with the cerebro-spinal fluid, are forced out of the cranial cavity, and a position of equilibrium may be reached; but as the pressure increases, venous stasis first develops, causing cyanosis of the brain with its accompanying irritative symptoms, and later anæmia ensues with its paralytic symptoms.

When of traumatic origin, it may arise from the following causes: (*a*) Depressed bone or the presence of a foreign body, in which case the symptoms of concussion merge directly into those of compression, and usually without any interval of consciousness. It is probable, however, that in these cases the symptoms are due more to the associated hæmorrhage than to the actual cranial lesion. (*b*) Extravasation of blood within the cranium, either outside the membranes, or on the surface of the brain, or within its substance. If the bleeding is extradural, there will probably be a short interval of consciousness between the concussion and the compression; if the bleeding is cerebral, the symptoms of compression may manifest themselves at once without any interval being noticed. (*c*) It may be due to an acute spreading œdema, the explanation of which is subsequently given. (*d*) It may arise from the pressure of inflammatory exudation or pus, in which case the symptoms are preceded by those of inflammation, and at the earliest will not manifest themselves before the third day, but they may be deferred for a week or two.

Compression also arises as a result of idiopathic hæmorrhage, tumours, gummata, or abscesses, *e.g.* of middle-ear origin.

The **Symptoms** of compression are essentially those of *coma*. When the condition is well established, the patient lies on his back absolutely unconscious, and cannot be roused either by shouting or shaking. His *breathing* is slow, laboured, and stertorous, the lips and cheeks being puffed in and out. The stertor arises from paralysis of the soft palate, and the puffing of the cheeks from paralysis of the facial muscles. In the later stages the respirations become irregular, and take on the Cheyne-Stokes type. Gradually breathing becomes more shallow and difficult, and death finally arises from cessation of the respiratory act. The *pulse* is full and slow at first from irritation of the vagus and vasomotor centres, but later on becomes rapid and irregular, owing to increased pressure upon and exhaustion of these medullary centres. The *surface* of the body may either be cool, hot, or perspiring; the *temperature* similarly varies, often being low in the early stages and higher at a later date. Not unfrequently the fatal end is associated with marked hyperpyrexia. In some cases where

the compressing force is unilateral, there may be some difference of temperature on the two sides of the body. The *pupils* vary according to the degree of compression and the situation of the compressing agent. If the cerebral pressure is equally diffused, both pupils first contract, and then gradually dilate and become reactionless; but if one hemisphere is affected more than the other, the pupil on that side passes rapidly through these changes, whilst on the opposite side they are not developed until later. Thus, it is a common thing to find the pupils unequal in size, and reacting differently to light. The whole body in the later stages is in a condition of *motor paralysis*, but at an earlier period of the case there may be some difference on the two sides if the lesion is unilateral; thus, if the left side of the brain is primarily affected, a right-sided hemiplegia is likely to be present at a time when the muscles on the left side can still respond to cerebral stimuli. A localized compression involving the motor area may lead to convulsions in the corresponding group of muscles. The voluntary control over the bladder is lost, and hence retention ensues, the sphincter ani is often relaxed, and fæces pass involuntarily, although marked constipation is usually present.

The symptoms in some cases are ushered in by severe pain or headache, which is partly due to pressure upon and tearing of the dura mater, and partly to the altered vascular conditions of the brain; the brain substance itself is not sensitive, and hence the pain is not directly referable to any lesion of or pressure upon it. Naturally, the clinical picture is modified according to the cause of the compression, even as the course of the case varies widely according to whether or not the compressing agent can be removed by the surgeon, or absorbed by natural processes.

The **Diagnosis** of coma from compression, when a complete history of the case can be obtained, is often easy, and, indeed, the whole clinical aspect may be so typical that no question as to the cause of unconsciousness can be raised. But when a person is found in the streets unconscious, and no history either of the patient or of an accident is obtainable, and no serious lesion of the skull is present, the diagnosis is often extremely obscure, since coma may be due to many other causes, *e.g.* (*a*) Cerebral lesions, such as apoplexy, whether the result of hæmorrhage, embolus, or thrombosis, or it may be the consequence of a preceding epileptic fit, or due to a rapidly spreading œdema in cases of cerebral tumour or abscess. (*b*) Various toxic agents may induce coma; they may be introduced into the system from without, as in the case of alcohol, opium, or other narcotics, or may be developed within the body, as in uræmia or diabetic coma. (*c*) Heatstroke or exposure to cold may also lead to unconsciousness. In the latter case there can be but little doubt as to the cause, since the patient is cold, pale, and in a state of severe prostration; in the former the diagnosis may for a time be doubtful. (*d*) Lastly, it must not be forgotten that two or more of these conditions may co-exist. Thus a drunken man may fall and break his skull, and then the smell of liquor in his breath may lead to an erroneous diagnosis.

It is therefore evident that a very thorough examination is required before any conclusion can be arrived at as to the cause of the coma, and it is often impossible to make an immediate diagnosis. In such cases the patient should be carefully tended and watched, and not shut up in a police-cell without attendance.

The following points should always be observed in the examination: (1) A rapid note should be made as to the surroundings of the patient —whether there is blood or vomit near him, how the body is lying, and the nature of the ground. (2) The depth of the coma should be tested, and, if possible, the man should be roused, and asked to give an account of himself. (3) A most thorough and complete investigation should be made as to his condition. The skull is first examined, to settle if possible whether a fracture is present; the surface temperature is noted, as also the character of the pulse and respirations. The tongue should be looked at, as it is often bitten in an epileptic fit. The smell of alcohol in the breath is not sufficient warrant in itself to diagnose merely drunkenness, as the alcohol may have been given after the accident. The condition of the pupils may throw some light on the case: in opium-poisoning they are small and equal, a condition also seen in hæmorrhage into the pons, in alcoholism they are often dilated and fixed, but vary considerably. The amount of power and the state of the reflexes are then observed, any inequality probably indicating a unilateral lesion in the brain. The urine must be drawn off, and examined for albumen and sugar. (4) In dubious cases, and especially where there is any suspicion of drunkenness or poison, the stomach should be washed out. (5) Finally, if the cause is still uncertain, the patient should be put to bed and carefully watched.

The **Treatment** of compression must be, where possible, directed to removing the cause. When it is due to depressed bone or a foreign body, immediate operation is required; collections of pus should be opened, and blood-clots removed. Failing such measures, and if lumbar puncture gives no relief, the treatment of the condition resolves itself into keeping the patient quiet, with the head low and cool, the room dark and noiseless, the bowels open (using croton oil on sugar, or enemata, for this purpose), and the bladder empty. The patient may be fed by rectum, and if the breathing or pulse is very laboured, and cyanosis begins to show itself, venesection may be advisable. Considerable interference with the respiration arises from falling back of the tongue, as often occurs in profound anæsthesia during operation, and if due to this cause the head may be rolled over to one side, or the tongue pulled forwards.

Laceration of the Brain.—Injuries to the brain and its membranes are frequent complications of head injuries, and all the most serious results of these accidents arise from this source. They are produced in many different ways, and cause varied symptoms; but the most important distinction to draw is between those wounds which communicate with the exterior and those which do not.

I. **Non-penetrating Wounds of the Brain** result from blows and falls, which may or may not produce simple fissured or depressed

fractures of the skull, but not unfrequently the most serious cerebral symptoms follow injuries in which the bones do not participate. In depressed fractures the brain is usually most contused or torn immediately below the injured spot; but in cases where there is no depression, the greatest mischief is frequently found at a point exactly opposite to that struck (point of *contrecoup*), whilst the local bruise may be much slighter. Thus, in the case of one of our students who in an epileptic fit fell, striking the left occipital region on a stone pavement, we found *post mortem* a fissured fracture at the spot struck and a bruise on the left occipital convolution, whilst the anterior portion of the right frontal lobe was severely contused, and, indeed, disintegrated. The explanation of this fact is that the force of the injury is transmitted to the brain substance in a wave which concentrates its violence against the opposite side of the skull. In very sharp sudden localized blows, as from a spent bullet, local bruising of the subjacent brain may be alone produced.

Pathological Anatomy.—The *immediate* effects of such an injury vary considerably. There may be a mere bruise, evidenced by a few points of extravasation, on the surface or in the grey matter; or the more superficial parts of the brain may be totally disintegrated and mixed with clots; or, if laceration has occurred, clots may be found adhering to the injured spot, or extending from it widely into the subarachnoid space, or even, under rare circumstances, into the lateral ventricle. The *later* effects in cases where the wound does not communicate with the exterior are mainly those of inflammation or degeneration. Soon after the accident considerable exudation follows, causing the ecchymosed brain substance to swell and become œdematous; this may speedily subside, but in the more serious cases a *spreading œdema* may be caused, owing to the pressure of the swollen tissues upon the superficial veins in the pia mater; the circulation in these is hindered, and increased exudation follows, leading to general cerebral pressure and even death, a consequence hastened by the excess of cerebro-spinal fluid usually induced by the process. Under such circumstances the greater part of the brain is œdematous and glistening, the injured area being yellowish-red in colour, with evident points of extravasation scattered through it. Still later, degeneration of the brain substance may follow owing to the disturbance of its circulation, and is indicated by the presence of a pulpy yellowish mass, soft enough to be washed away by a stream of water, and containing fat globules and granular cells, with débris of nerve fibres (*yellow softening*). If the area involved is small and unimportant, the patient may recover, the softened tissue being absorbed and replaced by a scar; if large or implicating important centres, death or paralysis must ensue. In cases of laceration of the brain which recover, a tough depressed cicatrix is formed, usually adherent to the membranes, and containing hæmatoidin crystals, whilst extravasated blood may be organized into a dirty brownish lamina, adherent to the pia mater, or into an arachnoid cyst.

Clinical History.—The symptoms necessarily differ with the severity and locality of the lesion.

Whenever concussion occurs after a head injury, and the patient recovers slowly from it, the surgeon will rightly suspect contusion or laceration of the brain. In the slighter cases recovery is often inaugurated by an attack of vomiting, and this is followed by a rise of temperature to about 100° F. for a few days, whilst the patient complains of fixed pain and headache, which under suitable treatment may entirely disappear. Some impairment of sense or of function, however, may persist.

More serious lesions give rise to various symptoms resulting from hæmorrhagic effusion, and these develop either at once or within twenty-four or forty-eight hours of the injury. Thus, if the phenomena of compression supervene at once, without any interval of consciousness, a diagnosis of depressed bone or a serious hæmorrhage into the cerebral substance may be safely made. If, on the other hand, the patient rallies for a time before becoming comatose, an extradural hæmorrhage from the meningeal vessels or venous sinuses may be suspected. Moreover, the possibility of a rapidly spreading œdema ought not to be forgotten.

Hæmorrhage into the cortex is characterized by irritative or paralytic phenomena, which vary with the cortical area involved. The degree of unconsciousness depends on the amount of the hæmorrhagic effusion.

In the *Upper and Middle Frontal Convolutions* neither motor nor sensory symptoms are noted, but cerebral irritation and subsequent weak-mindedness are likely to follow, especially if the left side is involved; lesions to the right frontal lobe do but little harm to a right-handed individual. Apparently, the intellectual faculties, as well as speech, are limited to one side of the brain.

Wounds of the *Third Left Frontal Convolution* lead to motor aphasia, *i.e.* the inability to produce or articulate words, in right-handed individuals; in left-handed people wounds of the right side have a similar result. Injury to the opposite convolution has no effect. If only one side is damaged, the other can sometimes be educated so as to take on its function.

Hæmorrhage into the *Motor Area* results in localized convulsions or paralysis, according to the degree of mischief. If the bleeding is progressive, a regular extension of the convulsions may be witnessed, the movements commencing, perhaps, in some region which is at the same time incapable of voluntary movement, and spreading to other parts of the body. Thus, if bleeding is occurring into the cortical centres for the face on the left side of the brain, paralysis of the right side of the face may be present, and it is here that the convulsions will start, spreading regularly to the right side of the neck, arm, and leg, and then involving the left leg, arm, and side of the head in order, finally becoming general, as in an epileptic fit. After each convulsion the paralysis is found to have spread.

It is sometimes very difficult to diagnose between a true cortical hæmorrhage and one which extends diffusely over the cortex in the subarachnoid space from the rupture of a vein in the pia mater. In the latter, however, the symptoms develop earlier, the paralysis is

less marked, and the convulsions are less regular, though perhaps more generalized.

An irritative lesion of the motor area for the head and eyes causes a conjugate deviation of the eyes towards the other side; a destructive lesion causes both eyes to be deflected towards the injured side. The posterior wall of the fissure of Rolando is concerned with cutaneous, muscle and joint sensibility.

Wounds of one *Occipital Lobe* may cause a temporary homonymous hemiopia, but no persistent loss of vision, unless the angular gyrus

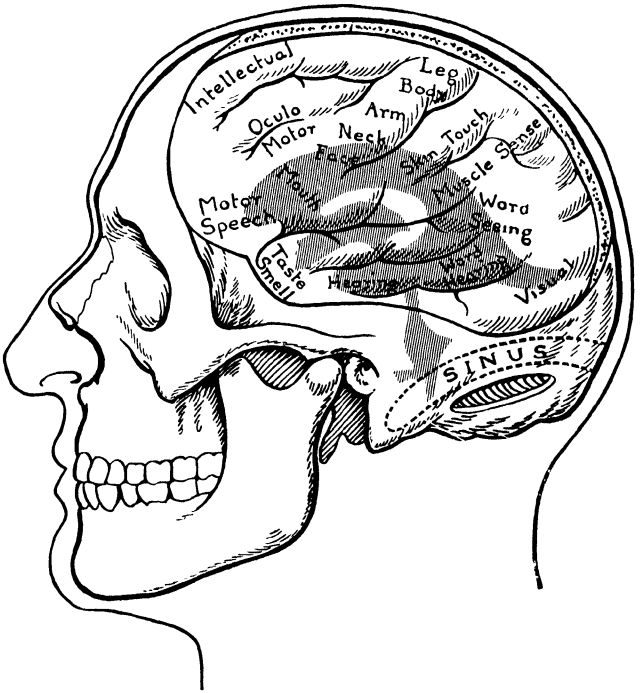

FIG 536.—DIAGRAM REPRESENTING THE FUNCTIONS OF THE CEREBRAL CORTEX
The outline of the ventricular system is shown in its relation to the skull.

is also destroyed. Lesions of the latter region are always associated with permanent disturbances of vision (Figs. 536 and 537).

The *Upper Temporo-sphenoidal Lobe* contains the cortical auditory centre, and lesions in this region cause deafness. The sense of smell is located in the anterior portion of the lower temporo-sphenoidal lobe which constitutes the uncinate process.

Injury to the *Corona Radiata* leads to paralysis of the regions represented by the overlying cortex, but without convulsions or other irritative phenomena. If the corpus striatum or internal capsule is

torn or involved in a hæmorrhage, coma rapidly supervenes, accompanied by hemiplegia and perhaps hemianæsthesia. Occasionally the effused blood bursts *into the lateral ventricle*, and causes a rapid rise of temperature, increasing until the patient's death, together with a very rapid weak pulse and increased respiratory rate (40 to 60 per minute).

Wounds of the *Cerebellum* cause giddiness, vertigo, ataxy and nystagmus, the patient reeling about, in characteristic cases, as if drunk, and, if the lesion is unilateral, falls to the side of the injury.

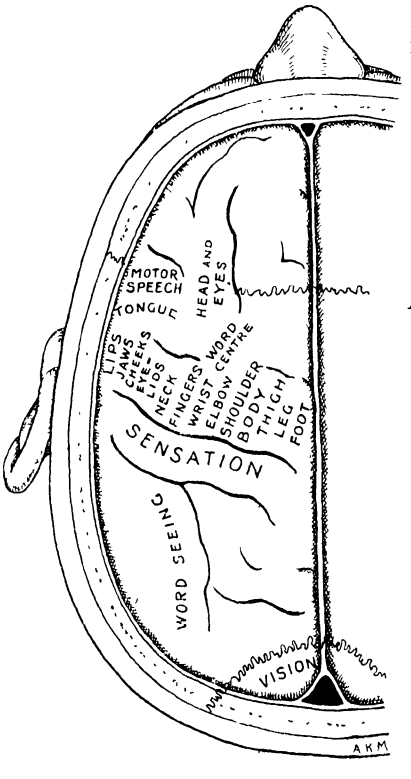

FIG 537.—DIAGRAM SHOWING THE RELATION OF MOTOR AREA IN THE CORTEX.

A wound of the *Crus Cerebri* occasions more or less complete hemiplegia of the opposite side of the body, associated with some amount of hemianæsthesia, and total paralysis of the 3rd (oculomotor) nerve on the side of the injury.

Laceration or contusion of the *Pons Varolii*, if not immediately fatal, may lead to paralysis of the opposite side of the body, together with paralysis of the 5th, 6th, 7th, or 9th nerves, on the same side as the lesion, constituting the so-called 'crossed paralysis.' Marked contraction of the pupils (myosis) may also be present.

Wounds of the *Medulla* are usually fatal. If, however, the patient should escape, he is liable to suffer from disturbed functions of the circulatory and respiratory centres, with perhaps Cheyne-Stokes respiration and glycosuria.

Pyramidal Signs.—Motor impulses are conducted from the cortical motor areas to the muscles chiefly by the pyramidal tract. From the motor cells in the cortex the fibres converge through the corona radiata into the internal capsule, thence after passing through the pons and medulla cross to the other side of the body and terminate in the anterior horn cells. Lesions of the cerebral portion of this tract produce a certain degree of hemiplegia, varying from slight paresis to complete paralysis. At the commencement there is usually flaccidity of the affected side, which in a week or ten days is succeeded by hypertonicity with a tendency to flexion of the upper limb and to extension of the lower. Clawing of the hand, which gives the sensa-

tion of elastic resistance, becomes progressive from the onset of the hypertonicity. The platysma may be observed to contract more energetically on the sound than on the paralyzed side, and the tongue deviates slightly to the side of the paralysis. The deep reflexes are usually more active on the paralyzed side. The alterations in the cutaneous reflexes are particularly significant. The plantar reflex gives an extensor response (Babinski sign), and the abdominal reflexes on the paralyzed side may be either diminished or absent. Other signs of less importance may be found in textbooks dealing with the subject.

The **later results** of a cerebral laceration vary much. The patient may recover perfectly after a more or less prolonged period of unconsciousness, but not unfrequently some loss of power persists, which will seriously impair the patient's subsequent usefulness.

The febrile phenomena already mentioned as characteristic of the first few days of convalescence after an attack of concussion may pass into a condition of subacute or chronic localized inflammation of the injured area, as indicated by pain and headache. In such cases the inflammatory effusion may be so abundant as to determine the onset of unconsciousness in four or five days. Occasionally an abscess forms deeply in the white substance, and this will be indicated by the usual phenomena of such a condition, coming on ten or fourteen days after the injury.

The formation of cicatrices between the brain and membranes may determine the development of traumatic epilepsy or insanity at a later period (p. 938).

The **Treatment** of these cases is always an exceedingly anxious matter for the surgeon. In the majority of instances it is merely symptomatic, following the usual course adopted in concussion, compression, cerebral irritation, etc., as indicated elsewhere. Depressed bone, if present, will, of course, be dealt with by operation. Early convulsions and paralysis are carefully watched to see if any indication as to the site of the bleeding can be obtained, since it is possible that trephining over the injured spot and removing blood-clots or securing bleeding-points might be advisable; but the clinical records of such treatment are not very encouraging. Late convulsions and paralysis due to inflammation are best treated by shaving the head and applying an ice-cap, and by lumbar puncture. If the pulse is full and hard, and the patient otherwise young and healthy, general venesection may be adopted; the bowels must be moved by a smart purgative, such as croton oil, whilst bromide in full doses may be administered. If the convulsions continue in spite of such treatment, and become more severe and extensive, the patient will almost certainly die of coma; trephining over the injured area is then distinctly indicated, the surgeon hoping to find and remove some clot, or, at any rate, to relieve tension by decompression, care being taken in all cases, where the intracranial pressure is high, to reduce this before opening the dura mater by tapping the ventricle.

In quite a number of these cases a *subtemporal decompression* is indicated. The patient has recovered from his concussion, but

remains in an irritable, semi-conscious condition, noisy and restless at times, and at other times more or less comatose; his mental condition is bad, and the bodily functions irregular. Lumbar puncture is sometimes useful, but the patient is so restless that it is dangerous to do it apart from a general anæsthetic, and repeated administrations are undesirable. When no localizing symptoms are present (and this is often the case), the skull may be advantageously opened beneath the temporal muscle, which is turned down for the purpose; a free removal of bone follows, extending antero-posteriorly rather than transversely; and the dura mater is opened. In this type of case the brain pulsations cannot usually be felt before incising the dura; a free flow of cerebro-spinal fluid follows the incision in most cases, and the brain pulsations are then at once re-established. The dura is turned back in flaps and stitched aside, and the temporal muscle laid down again in place and fixed by sutures. The skin incision is closed without drainage. The effect of this procedure is to provide a permanent relief of tension to the intracranial space in a comparatively safe position. In some cases of this type definite fulness in the temporal fossa is noticed for a time. The patient in favourable cases loses his headache, and becomes quiet and rational in a short time. In one instance the patient expressed himself as more capable of mental concentration after this operation than he ever had been before his accident (air-crash).

It may, however, be desirable in supposed cases of cerebral œdema to employ the intravenous injection of a hypertonic saline solution prior to operation. The cerebral tissue is one of the most sponge-like structures in the body, readily absorbing and quickly giving up fluid to the pia-arachnal prolongations which accompany the vessels in their distribution. The call to dilute the hypertonic solution injected into the blood-stream will first be answered by the loose fluid contained in the cerebral substance, and may remedy the coma induced thereby.

II. **Penetrating Wounds of the Brain** result from blows or falls, as in compound depressed fractures; or from the entrance of foreign bodies, such as bullets, shrapnel or shell fragments, or from stabs or punctures, which most commonly occur in the weaker parts of the cranium, *e.g.* the temple or upper wall of the orbit; or from sabre-cuts or axe-wounds, in which an oblique or almost valvular incision is made through the scalp and cranium, laying bare and wounding the brain and its membranes.

In some cases where the skull has sustained a considerable degree of injury, and a large opening results, the general disturbance is often slight, compared with the extent of the local injury, so that, although brain substance may protrude from the wound, there is sometimes but little concussion. The chief dangers arise when the opening is but small. Any of the conditions due to hæmorrhage detailed below may follow, but they may be slight if the blood can escape from the wound. The inflammatory phenomena due to *infection* of the wound may be localized or diffuse. In the latter instance general meningo-encephalitis manifests itself in the course

prevent the extension of the trouble beyond the neighbourhood of the wound. Hernia cerebri is very likely to follow, and possibly a deep cerebral abscess may complicate matters at a later date. In cases that have been successfully rendered *aseptic*, the course is similar to that run by a non-penetrating wound, except that, if anything, the immediate prognosis is better, since the opening in the skull diminishes the likelihood of compression from simple or spreading œdema. Where the lesion has involved the motor area, permanent monoplegia may persist, and later symptoms are always liable to arise owing to the formation of cortical adhesions.

Treatment.—In all cases of punctured or compound depressed fracture, a thorough exploration of the wound should be made, and all depressed or injured bone removed. Foreign bodies should be taken away, if found close to the wound, and often the mere removal of a superficial blood-clot from the mouth of the track will permit the brain to 'vomit' out deeper clots and even fragments of bone, or small foreign bodies. The method of sucking up broken-down and disintegrated brain tissue by a catheter and ball syringe has already been alluded to (p. 861). Bullets or large shell fragments, or foreign bodies, ought to be removed if within 2 inches of the surface (P. Sargent); but if deeper, they should be left alone, unless there is a definite and easily followed track leading to them Protruding brain tissue is washed with hot normal saline solution and left *in situ* Bleeding-points in the brain are controlled by pressure over small flaps of muscle or fascia; but the application of a swab wrung out of hot saline solution should be first tried. The dura mater should, if possible, be drawn together by one or two sutures, and the scalp-wound is closed, if possible completely, so as to avoid the use of drainage on account of the risk of infection entering through the drain opening, if employed, the gauze or tube should be removed, when all is going well, in about two days' time. If the temperature rises as a result of infection, the wound must be reopened, and every effort made to relieve tension, and thus localize the mischief. Lumbar puncture should be frequently undertaken, and the fluid examined for organisms; an autogenous vaccine has been found useful in some cases. Should diffusion occur, as indicated by an increasing severity of the symptoms, the patient must be treated in accordance with the general principles laid down for dealing with acute meningitis.

It is imperative that from the earliest possible moment the patient should be placed under the influence of bromides in order to quiet him and protect him from the risks of epilepsy.

In this description of lacerations of the brain the fact that symptoms may arise from inflammatory conditions affecting the bones (p. 848) has been purposely omitted. In actual practice the course of events is often considerably modified by such complications.

Later Management of Head Cases.—All injuries involving the skull and associated with cerebral symptoms must be regarded as of a serious nature, and the patients before being discharged from medical supervision should be warned as to the course of life that is desirable, and the restrictions that should be observed; these naturally are more

urgent in the more serious cases. Thus after a penetrating lesion of the brain, such as occurs in gunshot wounds, and in particular if there is a marked cranial defect, or if the patient has recovered from a hernia cerebri, he should be advised to live as quiet and regular a life as possible; the country is to be preferred, so as to avoid the hurry and bustle of town life; alcohol is absolutely forbidden; sexual excitement must be avoided; the diet should be simple and unstimulating; the bowels must be kept regularly open. Light work may perhaps be undertaken which does not involve hanging the head downwards, or overstrain, mental or physical. Fatigue and exhaustion are to be avoided, and the patient must indulge in plenty of sleep. Hot and badly ventilated rooms are undesirable, and places of public recreation are best avoided. Cinema shows are extremely bad, the vibratory movements of the pictures disturbing the patient's sense of equilibrium. The head should be well protected in hot weather, and these patients should not be sent abroad to hot climates. In fact, the patient after a bad head injury must develop a 'vegetable' type of life for a while, and nothing can be much better than light work on a farm for a year or two. Gradually as the brain recovers tone, the ordinary stress and strain of life may once again be taken up.

In spite of such care, or more frequently owing to the want of it, many patients who have sustained penetrating wounds of the brain from which they have recovered as a result of an effective decompression, begin to experience after a while symptoms, partly due to the injury, partly to the after-results of the operative treatment. They complain of headache more or less constantly, varying in degree with the amount of excitement and noise around them; they also suffer from anorexia and constipation, and perhaps from vomiting. They are unable to concentrate their attention on reading or games, and become morose and irritable. Possibly epilepsy supervenes, and if the motor area is involved this may be of the Jacksonian type. Vision is often defective owing to paresis of accommodation, and they may complain of giddiness and noises in the head. Some of these symptoms are undoubtedly functional, but others are very genuine results of the local lesion. Occasional exacerbations occur if the patient is exposed to cold and fatigue; he may even become unconscious and die.

The head wound is usually found to be tense, and no cerebral pulsations can be felt; the opening in the skull is closed by a firm scar which is attached to the margins of the cranial defect; it may even bulge outwardly during the more severe attacks.

These cases may be improved by keeping the patient quiet and giving him bromides; attention to the bowels is also desirable. Few of them will improve permanently unless the dura is freed from the cranial attachments, and some form of cranioplasty is almost always necessary. If no operation has been undertaken at the time of the injury, a number of these cases are greatly improved by subtemporal decompression.

Injuries to the Intercranial Blood-vessels.

1. **Wounds of the Venous Sinuses** are by no means uncommon, being torn across in fractures, or punctured either by some sharp instrument or by spicules of bone. The superior longitudinal, petrosal, lateral, and cavernous sinuses are those most frequently involved, especially the first, because it is more intimately connected with the bones than any of the others. Not unfrequently a depressed fragment of bone is driven into a sinus, and no bleeding occurs until the fragment is displaced with a view to elevating it, when a serious gush of dark venous blood will follow. When there is no external wound, and the outer wall of the sinus has been torn, the hæmorrhage may strip up the dura mater and compress the brain, producing effects resembling those due to a wound of a meningeal artery; but generally the bleeding is not great, since comparatively little pressure suffices to arrest it by determining thrombosis. If, however, the inner wall of the sinus is torn across, the blood finds its way between the meninges, and gives rise to the symptoms of diffuse intrameningeal hæmorrhage. When an external wound exists, there is the usual evidence of venous bleeding, but it is readily checked and rarely fatal. Infective thrombosis and pyæmia are the chief dangers, but entrance of air has also led to a fatal issue in a few cases. **Treatment,** when practicable, consists in plugging the sinus with aseptic gauze, and applying an antiseptic compress, possibly removing fragments of bone in order to expose it. Where the outer wall alone has been torn, it may be possible to suture it without interfering with its continuity, but, failing this, a flap of fascia should be cut and applied to its outer surface; in a minute or two gentle pressure has caused it to adhere like a postage-stamp, and the bleeding ceases. For symptoms and treatment of infective thrombosis, see p. 899.

2. **Wounds of the Middle Meningeal Artery.**—This vessel enters the skull at the foramen spinosum, and subsequently divides into two branches which ramify between the skull and the dura mater. The anterior branch is most frequently torn as it crosses the antero-inferior angle of the parietal bone, as the result of any type of fracture in that locality. The artery is, however, sometimes ruptured by a blow on the side of the head, sufficiently severe to detach the dura mater, but without causing any injury to the bone; this membrane always carries the vessel with it, and if it emerges from a bony canal just at that spot, as so often happens, the artery is torn across by the projecting inner lip of the canal. Whether or not the dura is primarily detached, the blood soon collects between it and the bone, pressing the brain inwards, and burrowing down towards the base of the skull (Fig. 538). This is due mainly to the force-pump-like action of the arterial pressure, for when fluid is driven into a closed cavity, the power of the jet is multiplied by the area occupied. The clot rarely measures more than 4 inches in diameter. The posterior division is only wounded in about 5 to 10 per cent. of the cases.

The **Symptoms** are, unfortunately, often obscured by some co-existent cerebral lesion or complication; but in a typical case three

stages should be present, *viz.*: (*a*) A primary concussion, as the result of the blow; (*b*) a temporary return to consciousness, the so-called 'lucid interval'; and (*c*) cerebral compression causing a gradual supervention of coma within twenty-four hours, and that usually without any considerable rise of temperature, though it may be associated with severe pain in the head and vomiting. The interval of consciousness varies widely, but it is not often longer than an hour or two, whilst in many cases it is scarcely recognizable. On the other hand, cases are known where symptoms were delayed for days or even weeks after an injury. As accessory signs, the following may be mentioned: (1) Since the blood-clot is situated close to the motor area of the cortex, and especially over the centres of the head and arm, twitching of these parts, followed perhaps by flaccidity and paralysis, may be a well-marked feature, and usually supervenes before the onset of coma. (2) When the clot extends to the base of the skull, it presses on the cavernous sinus, and may induce passive congestion of the eyeball, paresis of some of the ocular muscles, and proptosis. (3) The pupils may often give valuable information. That on the injured side will be contracted at first, owing to the irritation of the third nerve, as the pressure rises the third nerve becomes paralyzed and dilatation of the pupil takes place owing to the unrestrained action of the cervical sympathetic. If the pressure is maintained, its effect is transmitted across the mid-line, with the result that the third nerve is irritated, and contraction of the opposite pupil ensues. This in turn will be followed by dilatation of the pupil, as the third nerve becomes paralyzed. If operation is not performed to relieve the condition, death ensues, both pupils being dilated and fixed, owing to the fact that both the third nerves are paralyzed. The **Prognosis** is extremely unfavourable.

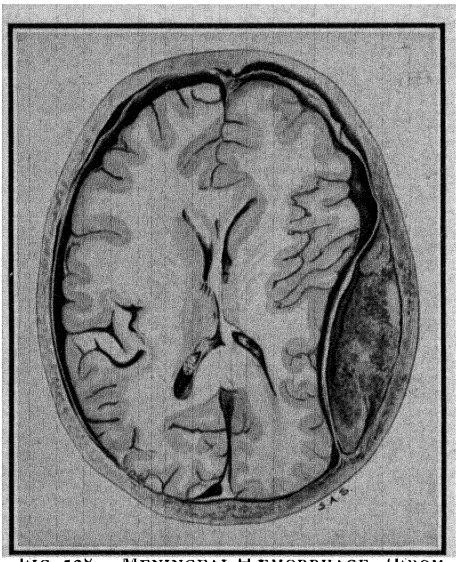

FIG 538.—MENINGEAL HÆMORRHAGE (FROM SPECIMEN IN COLLEGE OF SURGEONS MUSEUM)

The **Diagnosis** of extra-dural as distinct from intra-dural hæmorrhage is by no means simple. The latter is usually more rapid in its onset, and if involving the motor area may be associated with definite cortical phenomena; it is likely to be associated with blood-staining of the cerebro-spinal fluid; unfortunately, the two conditions not unfrequently co-exist.

The **Treatment** consists in opening the skull in order to remove the blood-clot and secure the artery, if still bleeding. The spot selected for dealing with the anterior division of the artery is 1½ inches behind the external angular process of the frontal bone, and 1½ inches above the zygoma. The scalp is shaved and thoroughly purified, and a vertical incision is made which includes everything as far as the pericranium (Fig. 539). A crucial incision is then made over the selected spot, and the pericranium reflected sufficiently to allow a 1-inch trephine or burr to be applied (Fig. 540). On removing the disc of bone a mass of blood-clot presents, which should be broken up with the finger and washed or scraped away. If the artery is seen bleeding on the dura mater, it may be possible to pick it up, and tie or twist it, or a fine curved needle threaded with catgut may be passed under it, and thus a ligature applied. If, however, the blood comes from a canal in the bone, the outer table must be clipped away sufficiently to enable the canal to be seen and plugged by a small piece of aseptic wax, sponge, or gauze, which may be left without danger. The incision is then closed; drainage is not usually necessary, and should be avoided owing to the risk of infection.

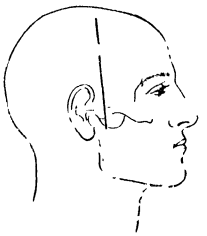

FIG 539.—INCISION FOR EXPOSING THE MIDDLE MENINGEAL ARTERY

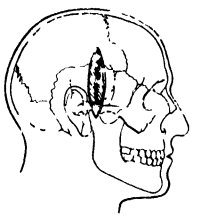

FIG 540.—THE AREA OF BONE REMOVED IN CASES OF MIDDLE MENINGEAL HÆMORRHAGE.

Should the meningeal vessels be intact the opposite side should be explored. When there is bleeding under the dura, there is no pulsation of the dura at that point. Sometimes there is a bluish discoloration. A small incision in the dura clinches the diagnosis, for if blood is present it spurts out, and with it bits of clot.

The posterior branch of the artery can be reached by trephining immediately below the parietal eminence at the same level as for the anterior branch.

3. **Wounds of the Internal Carotid Artery,** in its intracranial portion, are rare, but if complete are necessarily fatal. They usually result from penetrating wounds of the orbit, or from a gunshot wound, or the vessel may be torn by a splinter of bone in a fracture of the base of the skull. Mere fissures through the carotid canal do little harm, since there is plenty of room within it around the artery. Occasionally, however, the artery is slightly torn, and an aneurismal varix develops between it and the cavernous sinus. **Treatment.**—The injury is fatal in the majority of cases before help can be ob-

tained; if not, compression of the carotid trunk or ligature of the internal carotid in the neck is the only hope. See also on orbital aneurism (p. 337).

4. **Intrameningeal Hæmorrhage** arises from wounds of the cerebral

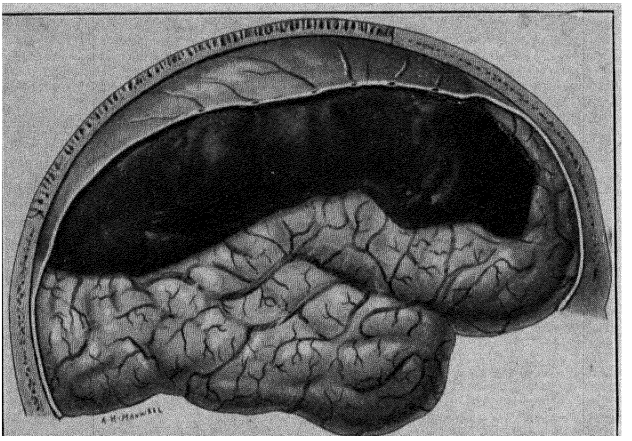

FIG 541.—SPECIMEN SHOWING LARGE SUBDURAL HÆMATOMA

cortex or membranes in cases of fractured skull, or from concussion without fracture. The blood may be derived from the veins and

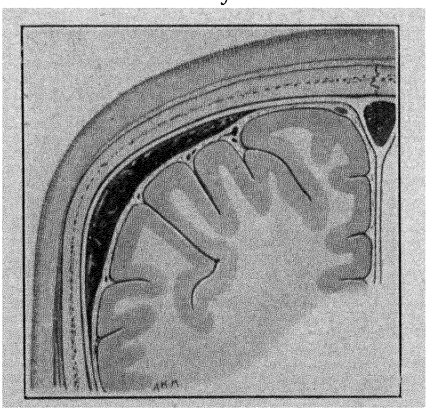

FIG 542.—SECTION OF BRAIN SHOWING CHRONIC SUBDURAL HÆMATOMA

capillaries so abundantly present in the pia mater, or from lesions of the inner wall of venous sinuses.

Chronic subdural hæmorrhage often arises from trivial head injuries in adults over the age of forty years, and quite frequently gives rise to a *subdural hæmatoma* (Figs. 541 and 542). There is often an interval

of several days to several weeks after the injury before symptoms develop, the patient merely complaining of headache and perhaps photophobia. About a month after the injury hemiplegia and drowsiness may appear, and on examination papilloedema may be discovered if the fundi are examined. A ventriculography may be of great value in demonstrating the side of the lesion.

The **Treatment** consists of exploration of the brain through multiple burr holes on the suspected side and the blood-clot is washed out or sucked out (Fig. 543). In quite a number of cases the hæmatoma is bilateral, and therefore, if there is the slightest doubt, burr holes should be made on both sides.

At times the collection of blood may have formed a definite cyst, and it is then called a *subdural hæmorrhagic cyst* or *arachnoid cyst.* If the condition is found, an osteoplastic flap should be turned down and the cyst completely removed. Such an operation simply means joining the burr holes with a Gigli saw, the bone flap being returned after the removal of the cyst.

5. **Cerebral Hæmorrhage** occurs more frequently from idiopathic causes than from trauma, except in the case of severe lacerations. In the more aggravated forms, death is practically certain to result in a short time from increased intracranial tension.

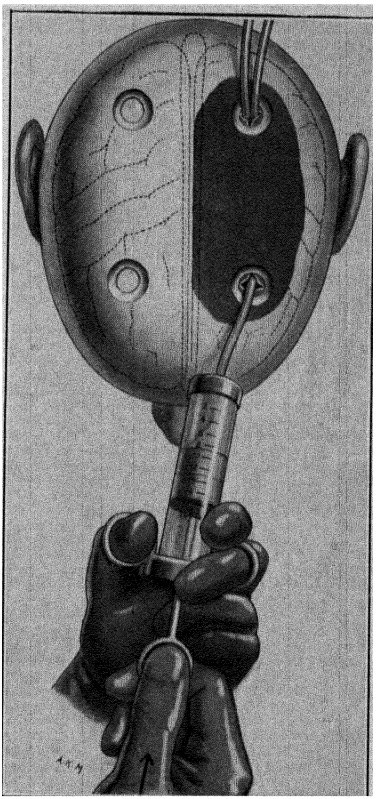

FIG. 543.—METHOD OF REMOVING A SUBDURAL HÆMATOMA.

A catheter is attached to a 20 c.c. syringe and the contents are aspirated or washed out. An extra catheter is placed in the exit burr hole, as it facilitates the removal of the clot.

Intracranial Inflammation.

Inflammation of the cranial contents is almost always bacterial in origin, and may follow a great variety of lesions, *e.g.*: (1) Injuries of all types, but especially compound or punctured fractures. (2) Middle-ear disease is perhaps the most frequent origin of these affections, the infection reaching the brain through an opening in the tegmen tympani, or spreading from the mastoid process along the sigmoid groove in which lies the lateral sinus. (3) It may extend inwards from scalp, face, nose, or neck by ways of the emissary

veins, or even along the sheaths of nerves. (4) It may accompany simple contusion of the cranial bones (p. 849) as a result of an auto-infective inflammation in these structures. (5) It may develop as a complication of pyæmia, septicæmia, pneumonia, scarlet fever, small-pox, and other general infective diseases. The causative bacteria in the preceding groups are generally staphylococci or streptococci, when the inflammation is due to traumatism; but the pneumococcus is usually present, when the mischief extends from the middle ear or accessory nasal sinuses. (6) It may constitute the chief manifestation of a general infective fever, spreading from the nasal fossæ, and known as *Cerebro-spinal Fever*. This affection is due to a specific organism, the *Diplococcus intracellularis* or *Meningococcus*, and is extremely infectious. Certain individuals have been proved to be 'carriers' of this organism in their nasal fossæ, and infection may be spread by them by coughing and sneezing. Medical textbooks must be consulted for a description of this disease. (7) Chronic inflammatory trouble may arise from tubercle and syphilis.

It must be remembered that in actual practice the different forms of inflammation described below run into one another, and that the resulting symptoms are often a complex mixture of several types. For descriptive purposes the following groups may be differentiated:

(i.) **Subcranial Inflammation** (**Pachymeningitis**) manifests itself either as a simple thickening of the dura, or as an effusion of pus between the dura and the bone (subcranial abscess).

Simple Pachymeningitis results either from a slight simple depressed fracture, or from a contusion with or without a fissured fracture, or from the gradual spread of a mild infective inflammation from the overlying bone. The process is really protective in character, the dura becoming thickened. It may extend to the under surface of the dura, and lead to a localized lepto-meningitis characterized by adhesions between the cortex and the dura. If the process extends no further, the clinical manifestations are slight, consisting merely of pain and localized headache. For treatment, see chronic meningitis (p. 898).

Subcranial (or **Extradural**) **Abscess** results from either a compound depressed or a punctured fracture, in which the dura mater is only separated from the bone and not lacerated, especially when the external wound is small and efficient drainage is not obtained. It also occurs by auto-infection in consequence of a simple contusion or fracture of the skull, leading to a detachment of the membranes and a collection of blood in the cavity thus produced. Any form of osteomyelitis of the cranial bones may determine its onset, as also the lodgment of a pyæmic embolus; but apart from injury, its most common cause is, without doubt, extension of inflammation from the middle ear.

A perforation of the tegmen tympani (Fig. 546, 2) allows of the invasion of the cranial cavity, and an abscess forms above the attic, which perhaps discharges through the ear; in other cases the suppuration extends along the groove for the lateral sinus. In the former instance, a localized subdural abscess may subsequently develop,

limited by meningeal adhesions, and the intervening dura mater may slough; in the latter, thrombosis of the lateral sinus may follow.

The **Symptoms** produced are (1) those generally characteristic of suppuration, *viz.* a high temperature, with perhaps rigors. (2) The signs of intracranial pressure in the form of fixed headache followed by coma are also present, if the abscess is large, or if it affects the cerebral membranes sufficiently to cause a serous meningeal effusion. (3) If there is no open wound, an œdematous swelling of the scalp, known as *Pott's puffy tumour*, may develop over the site of the abscess (Fig. 544). When there is a compound fracture of the skull, the margins of the wound look unhealthy, and at its base may be seen

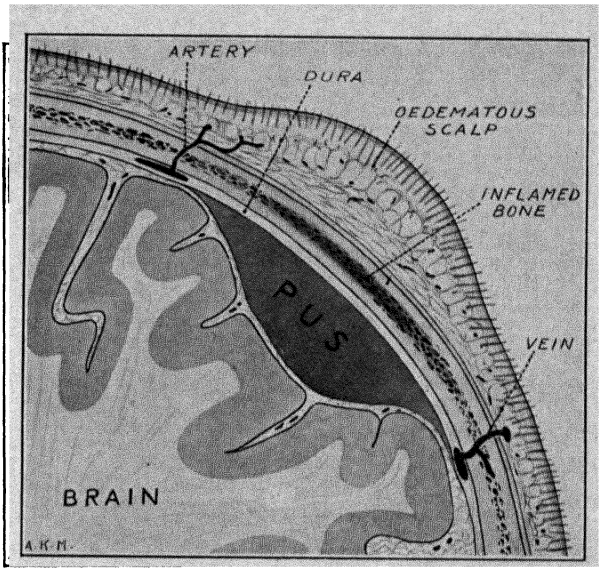

FIG 544.—SUBCRANIAL SUPPURATION INVOLVING, OVERLYING BONE AND CAUSING AN ŒDEMATOUS CONDITION OF THE SCALP (POTT'S PUFFY SWELLING) (SEMI-DIAGRAMMATIC).

bare bone, yellow and dry, from which the pericranium has separated, perhaps with pus oozing out between the fragments. If the pus burrows towards the base of the skull, optic neuritis may develop. (4) Focal symptoms of spasm or paralysis may complicate the case if the dura over the motor area is involved. The **Treatment** of such a condition consists in evacuating the abscess cavity through a sufficient opening made by trephining, or by removing loose or diseased portions of bone, and providing for drainage. Sometimes more than one opening is required for this purpose.

When the affection follows otorrhœa, the mastoid antrum is usually opened up, as also the attic, and sufficient bone gouged or cut away from the roof to give effective drainage.

Occasionally the condition is of a diffuse subacute character, spreading widely over the surface of the dura mater and causing extensive mischief. In one case observed it followed a carbuncle on the back of the neck, and in another it was due to syphilitic disease of the cranial bones with septic complications. Pus spreads along the dura, the outer surface of which is thickened by granulation tissue, and the membrane itself becoming gradually softened allows the surface of the brain to become involved. The bones become carious with a certain amount of necrosis of the inner table. Pus finds its way to the surface through the bone, possibly through the foramina for emissary veins, and abscesses form beneath the scalp, which early becomes œdematous. The cerebral symptoms may be comparatively slight, headache and vomiting being the chief phenomena. The only treatment practicable is an extensive decompression which lays bare the dura mater and removes the sequestra. In the cases mentioned above nearly half the cranium had to be removed in order to get clear of the trouble. The former case improved for a time, but died of acute mania; the latter case did very well, and fresh bone was formed over most of the denuded area.

(ii.) **Acute Diffuse Meningitis (lepto-meningitis)** is always infective in nature. The symptoms vary considerably in their intensity according to the site and method of inoculation and the activity of the organisms, but the whole pia-arachnal space is quickly involved. The superficial part of the brain is also invaded in the inflammation as well as the meninges, and the term 'meningo-encephalitis' would perhaps be the better appellation.

The **Symptoms** appear about forty-eight hours after an injury, although sometimes infection may be delayed beyond this period. In the early stages the patient complains of severe, constant, and increasing headache, associated with heat of head, a forcible pulsation of the carotids, a quick pulse, and general irritability of the brain, as indicated by vomiting, intolerance of light and sound, delirium, and perhaps convulsive twitchings of the muscles, not only of the head and back, but also of the extremities. The vomiting is of the usual cerebral type, *i.e.* it occurs without nausea, and has no relation to the ingestion of food. High fever is generally present, and possibly a rigor may occur at the onset. As the disease progresses the patient gradually becomes comatose, the pulse is slow and full, the respirations are laboured, and death usually ensues in three or four days.

According to the site of infection, the inflammatory phenomena may manifest themselves more acutely over one part than another, and for descriptive purposes two chief varieties have been distinguished, *viz.* meningitis of the convexity and meningitis of the base. The general symptoms are alike in both forms, but when the convexity is involved, convulsions are a more prominent feature in the case, and may at first be limited to localized groups of muscles; in basal meningitis the temperature usually runs higher, the head and neck are more retracted, optic neuritis is more frequent, and some form of squint is not uncommonly observed.

On *post-mortem* examination the skull-cap is separated from the

meninges with some difficulty; the dura mater is thick and congested, and the subjacent veins are manifestly distended; the cerebro-spinal fluid is increased in amount, and turbid from admixture with lymph or pus; the arachnoid is thick and opaque; the surface of the convolutions is flattened and œdematous, and lymph occupies all the sulci, matting them together; the cortical grey matter is usually red and congested; the underlying white substance of the centrum ovale is injected; the ventricles are distended with cerebro-spinal fluid, and the choroid plexuses are engorged with blood.

The **Treatment** consists in shaving the head and applying cold by means of an icebag, care being taken that the application is continuous, and not intermittent. In the robust general venesection is useful, but in weaker individuals purging and a low diet must be relied on. The patient should be kept absolutely quiet in a darkened room, and every source of irritation and excitement removed. Even if recovery ensues, it is often delayed, and for a while incomplete, especially as regards the mental powers, and precautions as to quiet and freedom from worry and strain must be maintained for a long time. An abundance of sleep in restful surroundings is essential.

If the condition is due to a localized infective lesion, this must, of course, be dealt with by suitable means; *e.g.* the middle ear is opened up and diseased bone removed, depressed fractures are operated on, and localized drainage effected, etc. Apart from this, attempts have been frequently made to relieve the symptoms and determine a cure by means of operative measures, directed towards reducing the intracranial tension; the subarachnoid space has been opened below the tentorium, whilst others have employed cisternal or lumbar puncture, repeating it frequently. When one considers the intricate character of the space to be drained, the fact that it is sure to be subdivided into separate cavities by deposits of lymph, and especially when it is remembered that the brain substance is itself swollen, and that the important fourth ventricle has only a small communication with the subarachnoid space—all these considerations suggest that it is unlikely that much success will follow such treatment.

Acute Meningo-encephalitis is sometimes *limited* in character. It can only occur in the absence of tension, diffusion along the meninges being prevented by the formation of adhesions. It usually results from a localized inflammation of bone (Fig. 545), due to a contusion, a penetrating wound, or possibly to middle-ear mischief. The process ends in the formation of adhesions between the brain and its membranes, preceded or not by suppuration. Of course, where pus forms, a cure can only be established by operation.

(iii.) A **Subacute** form of meningitis is occasionally met with, coming on at a somewhat later date. The patient may have apparently recovered from his injury, with the exception of a fixed pain in the head. The onset of the symptoms is often due to some indiscretion, and may be gradual or sudden. In all probability this affection is also microbic in origin, and the delay in its appearance depends either on the small number of bacteria present, or on their being in a low state of virulence; or possibly they have been latent for a time, and are

aroused into activity by secondary causes; or, again, they may have worked their way gradually inwards along lymphatics or vessels from the periphery to the meninges. The symptoms are similar in character to those of acute meningitis, though somewhat less severe; but a fatal result is very apt to follow. In the *treatment* of this form, no active antiphlogistic measures should be adopted, since the patient's condition is somewhat asthenic. Absolute rest and quiet are essential; counter-irritation should be applied to the scalp and neck, and possibly mercury administered, or some absorbent organic salt of iodine. Lumbar puncture may be useful, or a decompression may be desirable, if there be a local lesion, the

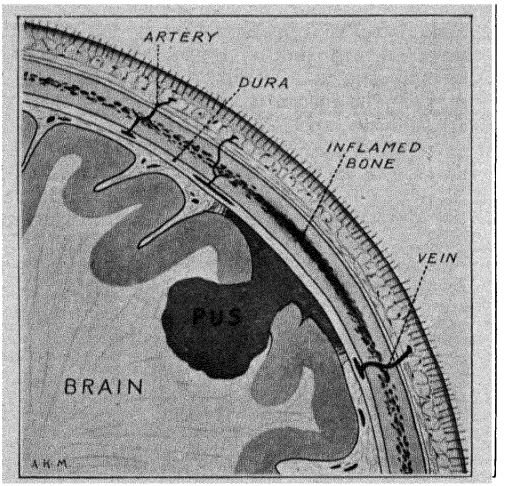

FIG 545.—SUPERFICIAL ABSCESS OF BRAIN SPREADING FROM SUBDURAL SPACE (SEMI-DIAGRAMMATIC)

site of injury may be selected, but apart from this an exploratory subtemporal decompression can be undertaken.

(iv.) **Chronic Lepto-meningitis** arises from very similar causes to the pachymeningitis already described (p. 894), but in addition may be associated with deep lesions, and may serve to limit the spread of infection; it is usually of a protective character. Syphilitic patients are perhaps more liable to its development than others. It is evidenced by infiltration and thickening of the membranes, which are usually adherent to one another and to the cerebral cortex It gives rise to a localized headache, which is constant, and increased on excitement or the injudicious use of stimulants, whilst tenderness is often noted on deep pressure, and traumatic epilepsy may ensue. The *treatment* consists in attention to the general health, free action of the bowels, abstinence from excitement and stimulants, the local

application of counter-irritants, and the administration of mercury. For the question of operating for traumatic epilepsy, see p. 938.

(v.) **Tuberculous Meningitis** is a condition usually seen in children, due to an invasion of the meninges with tubercle. The pial vessels are chiefly affected, and the base of the brain is mainly involved. Inflammatory adhesions follow, and the free circulation of the cerebro-spinal fluid is checked by the blocking of the foramina of Magendie and Luschka, so that the ventricles are often distended. For symptoms and clinical history medical textbooks must be consulted.

(vi.) **Infective Thrombosis of the Sinuses,** though occasionally seen after injuries, is more commonly associated with suppurative diseases of the bone apart from trauma, and one variety, *viz.* that affecting the lateral sinus, is almost exclusively caused by disease of the middle ear. It is also induced by extension from scalp injuries as a complication of subaponeurotic cellulitis, or may spread inwards from erysipelatous or pyogenic lesions of the face, or suppurative conditions of the nose. Putting aside the results of chronic otorrhœa, the cavernous sinus is much more frequently involved than any other, and this affection is often secondary to suppuration in the sphenoidal or ethmoidal sinuses.

Pathologically, the same manifestations are observed as in any case of infective phlebitis. The sinus becomes impervious owing to thrombosis, which may develop slowly or suddenly; the clot becoming disintegrated gives rise to multiple emboli, whilst various inflammatory conditions of the surrounding tissues necessarily result, *e.g.* necrosis or caries of bones; subcranial abscess, meningitis, simple and localized, or infective and diffuse; or even cerebral or cerebellar abscess.

The *symptoms* are mainly of a pyæmic nature. The temperature is high, but with remissions, and often with repeated rigors; fixed headache and early and continuous vomiting are also marked features of the case. With these may be associated evidences of meningeal mischief, or of pulmonary trouble in the shape of dyspnœa, but sometimes diarrhœa and septicæmic manifestations may be the more prominent.

If the cavernous sinus is involved, marked exophthalmos, with congestion of the orbit, and even of the eyelids and face, may result, and ptosis or squint may also be set up by implication of the nerves which lie in the walls of the sinus.

During the late war many cases of thrombosis of the superior longitudinal sinus were observed, resulting from wounds by a bullet or shrapnel fragment. The symptoms included bilateral loss of power of the lower limbs, more marked distally; loss of cortical sensation; and such pyramidal symptoms as an extensor plantar response (Babinski), ankle clonus, etc. In addition there may be turgescence of the veins of the scalp and forehead, together with tenderness along the line of the sinus and epistaxis.

For local results and treatment of thrombosis of the lateral sinus, see Chapter XLVII.

Treatment, except for the lateral sinus, is but rarely possible, and hence the importance of preventing this disease by a most careful

attention to asepsis in the surgery of the face and of the nasal cavity. For the lateral sinus much can be done, but for the other sinuses all that is feasible is attention to general measures

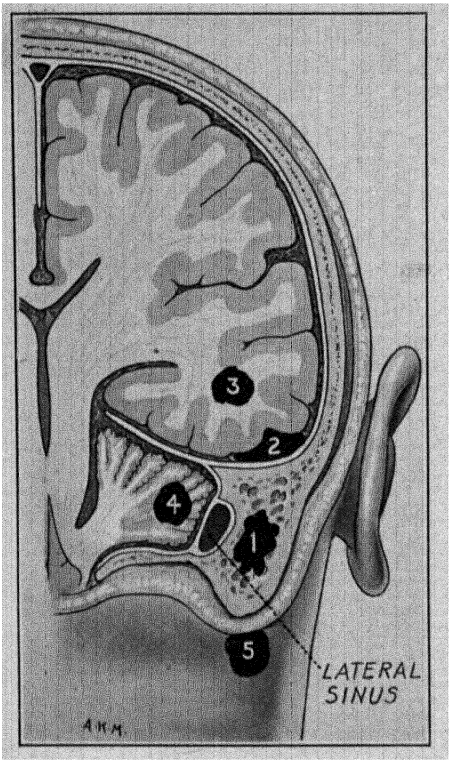

FIG 546.—DIAGRAM TO REPRESENT THE COURSE OF INFLAMMATORY TROUBLE FROM SUPPURATIVE DISEASE OF THE MIDDLE EAR

1, Dilated and infected mastoid antrum 2 subdural (intradural) abscess from infection through the roof of middle ear or mastoid 3 abscess in temporo-sphenoidal lobe 4 cerebellar abscess, 5, Bezold's abscess through perforation of tip of mastoid process

Brain Abscess.

Causes.—Pyogenic infection is, of course, the ultimate cause of all cerebral suppuration, but the manner in which the organisms find their way to the brain varies considerably.

(i.) The commonest source of cerebral abscess is suppuration in the middle ear (Fig. 546), and the cerebellum is nearly as frequently involved as the cerebrum In the former the abscess is usually in the anterior portion of the lateral lobe (Fig. 546, 4), close to the back of the petrous bone, whilst in the latter the posterior portion of the temporo-sphenoidal lobe is most frequently affected The inflammation may spread directly from the tympanic cavity, or inner aspect of the mastoid process, through the bone to the membranes, which become adherent to the brain, and then into the cerebral substance. Occasionally a subcranial abscess is first developed (Fig. 546, 2), and the cerebral affection follows; sometimes a direct opening has been found through the tegmen tympani into an abscess cavity, and the abscess has even discharged itself and been drained in this direction. More commonly a layer of brain tissue intervenes between the membranes and the pus, and then infection must have been carried along the vessels and their sheaths. **Chronic otorrhœa** accounts for 60 per cent of brain abscesses

Brain abscesses of a similar type occur in connection with suppuration

PLATE XI

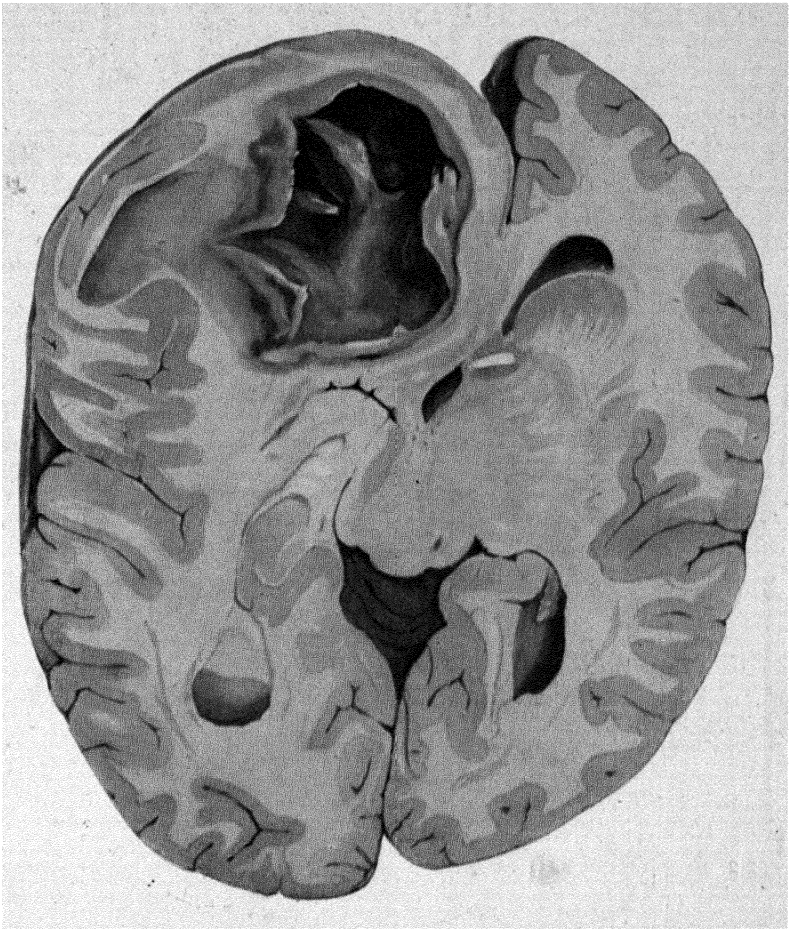

Large Frontal Abscess of the Brain, secondary to Suppuration in the Frontal Sinus

(Mr. E. D. D. Davis' Case)

in the frontal and accessory nasal sinuses and amount to 10 per cent. of all cases. Such abscesses are usually acute and secondary to a frontal osteomyelitis, and occupy the anterior part of the frontal lobe (see Plate XI.).

(ii.) Blood-stream infection accounts for some 25 per cent. of brain abscesses, intrathoracic suppuration (bronchiectasis and empyema) being the commonest cause. Various forms of pyæmia, especially if of staphylococcal origin, may give rise to abscess formation in the brain. Cerebral abscess is also known to follow some of the exanthemata, such as scarlatina, typhoid, etc.

(iii.) Trauma is another but less common cause of abscess of the brain. Such an abscess may occur either in the early or late stages of head injuries. In the **early** stages it is usually superficial, and connected with some infective lesion of the scalp, cranium, or membranes, with or without a penetrating wound. In the late stages the pus forms deeply in the white substance. It may be due to a penetrating wound, whether a foreign body is present or not, the microbes finding their way into the interior of the brain, either through the track of the missile, or along blood-vessels or their pia-arachnal sheaths. Sometimes it occurs apart from penetration, and then is due to auto-infection of a contused or lacerated area. Chronic abscess of this type is most frequently seen on the same side of the brain as the lesion, and the parietal and frontal lobes are most affected; occasionally, however, it may occur on the opposite side in the same way as a contusion.

A cerebral abscess is usually single; occasionally more than one is present, *e.g.* a cerebral and cerebellar may coexist in connection with suppuration in the middle ear. The course taken by the case is usually chronic, and then the pus is encapsuled; in acute cases there is usually no limiting membrane.

The **Symptoms** vary somewhat with the method of onset and the characters of the abscess. If traumatic and due to infection from without, the case runs an acute course, associated with intense pain in the head, recurrent rigors, and rapid development of coma. Diffuse meningitis is often present, and the two conditions can scarcely be distinguished. In not a few of the cases of chronic abscess, all that the patient complains of is headache, until suddenly the temperature rises with a bound; he becomes unconscious and dies within a day or two. Such a course of events is probably due to the bursting of the abscess into the lateral ventricle or meningeal cavity, or to the onset of an acute spreading œdema. The symptoms of all cerebral abscesses may be said to fall into three groups: toxic symptoms, symptoms of increased intracranial pressure, and symptoms resulting from local damage to the brain.

In a typical case there are three well-marked stages. (i.) In the *Initiatory Stage,* which lasts from twelve hours to two or three days, the patient is suddenly seized with severe pain in the region of the ear, radiating perhaps throughout the head, and accompanied by a rigor of some severity. The temperature and pulse are both raised, and vomiting of a cerebral type is present; the tongue is foul.

whilst anorexia and constipation are well marked. During this period the otorrhœa diminishes, or ceases entirely.

(ii.) In the *Fully-developed Stage* the patient lies quietly in bed in a dull, apathetic condition, able to answer questions but slowly, and with his brain evidently in a torpid state. The headache has to a great extent ceased, but tenderness over the temporo-mastoid region still remains. The temperature falls gradually and becomes subnormal; the pulse is slow and full; and respiration is usually slow. The vomiting and constipation continue, and the patient's mouth and breath become very offensive. Loss of muscular power scarcely amounting to paralysis occurs in many cases where the motor track is involved, and the order in which this paresis appears is of localizing value. Thus, if a temporo-sphenoidal abscess is not far from the cortex, the face is first affected, then the arm, and finally the leg; but if the abscess is deeper and presses on the motor fibres in the internal capsule, the order in which these parts are involved is reversed. Motor asphasia is sometimes well marked when the abscess is on the left side. If the abscess is placed posteriorly, it may press on the cerebellum through the tentorium, and cause symptoms of a cerebellar type. Papillœdema (p. 923) is a somewhat unreliable sign, but if present is more marked on the affected side, whilst the corresponding pupil is dilated and fixed.

(iii.) The *Terminal Stage* is marked by a gradually increasing unconsciousness and death; or the abscess may burst into the lateral ventricle, causing sudden coma, a rapid rise of temperature and pulse, irregular respirations (often of a Cheyne-Stokes type), and death; or it may burst into the subarachnoid space, and then death is preceded by symptoms of diffuse lepto-meningitis.

The signs connected with a small **Cerebellar Abscess** (Fig. 546, 4) are often very indefinite and vague, but as the abscess increases in size the symptoms may become very characteristic. The patient complains of bouts of occipito-frontal headache, giddiness, and vomiting. On the whole, vomiting is more marked in abscesses below the tentorium than those which occur above it. Papillœdema is also a more constant feature. Nystagmus is a constant sign, and is usually coarser and slower on deviation of the eyeballs to the side of the abscess. The patient complains of vertigo and staggers when attempting to walk, falling towards the affected side. The head and neck are retracted, respiration is irregular and shallow, the pulse is slow and weak, paralysis may be noted on one or both sides of the body and may affect only the upper extremity. There may be attacks of unconsciousness, dysarthria, and dysphagia.

Prognosis.—Leptomeningitis is the most frequent cause of death in brain abscesses. The abscess may rupture into one of the ventricles of the brain or into the subarachnoid space. The results of operation are better for cerebral than for cerebellar abscess, but the mortality rate on the whole still continues to be on a high level.

Differential Diagnosis.—From *meningitis*, a cerebral abscess is usually recognized by the fact that in the former condition irritative phenomena, such as acute and active delirium, contraction of the pupil,

photophobia, rigidity and spasm of muscles, especially in the back of the neck, and severe pain, are more evident and are produced earlier. The temperature is usually high, and mental dulness comes on within three or four days of an injury, whereas an abscess rarely forms before the end of the first week. *Extradural abscess* (subcranial) is associated with a high temperature, earlier onset after an injury in traumatic cases, and more rapid compression symptoms; optic neuritis is unusual, and the vomiting is less troublesome. Localized œdema of the scalp may be present, or tenderness on deep pressure. In *thrombosis of the lateral sinus* the temperature is high and oscillating, papillœdema may be absent, and there may be tenderness in the neck along the course of the internal jugular; in abscess, symptoms of compression are associated with a low temperature and marked optic neuritis. It must not be forgotten that the two conditions may coexist. It is often impossible to diagnose between a chronic abscess and a *tumour of the brain*; the symptoms in the latter usually come on more slowly than in the former, but the progress is steady and unrelenting; the temperature remains near the normal, and there is less gastric disturbance. The history of the case and white blood-count may throw some light upon its nature, since in cases of cerebral abscess there is generally some causative focus of infection. Tumour is more common in the frontal and parietal regions, abscess in the temporo-sphenoidal lobe. Papillœdema is more marked and more common in tumour than in abscess. Ventriculography and exploratory puncture may help in the differential diagnosis.

Diagnosis.—The blood-count in cerebral abscess is rarely of any value as a guide to diagnosis. The examination of the cerebro-spinal fluid, on the other hand, often provides conclusive information. It must be realized that lumbar puncture is not without danger in cases of abscess formation with increased intracranial pressure because of the possibility of sudden increase on the medulla. Therefore, if lumbar puncture is contemplated the patient must be transferred to a nursing-home or hospital, so that, if necessary, an immediate operation may be performed following the withdrawal of the cerebro-spinal fluid. As a rule the withdrawal of 3 c.c. of fluid should be sufficient for pathological examination. The pressure of the fluid may be raised or be within normal limits. There is usually a rise in the protein content from the normal 0·03 per cent. to anything up to 0·01 per cent.

Exploratory puncture should be performed when the diagnosis of an abscess appears probable and its position is reasonably certain. A burr hole is made in the skull and the brain explored by a hollow, blunt needle.

Ventriculography may give valuable information as to the position of an abscess, and is probably not used as much as it should be. It is not a dangerous procedure in the hands of a surgeon accustomed to deal with brain conditions.

Treatment will depend according to the age of the abscess, whether it be acute or chronic. In the acute cases a very definite localization should be obtained by ventriculography, if necessary. If possible,

the patient should be tided over the acute stage, and any attempt at surgical interference should be delayed until the abscess has become chronic and encapsulated. When, however, the condition of the patient will not warrant this, the technique advocated by Clovis Vincent should be undertaken. A large osteoplastic flap is reflected over the site of the abscess. A nick is made in the dura mater, the abscess is aspirated by a needle, and the osteoplastic flap is replaced. After an interval another aspiration may be carried out, if necessary through one of the burr holes The abscess will probably become encapsulated and can be exposed and dissected out after an interval of a month or more. If the abscess is of the chronic variety and is encapsulated, then it can be exposed through a burr hole in the skull, the dura mater is opened with a diathermy cautery which causes the

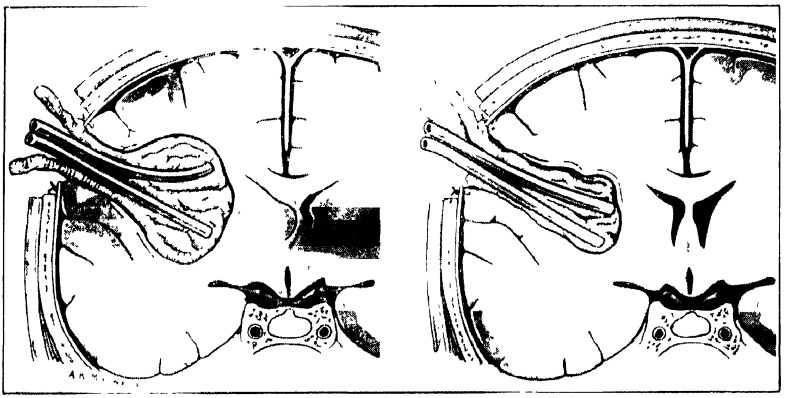

FIG 547.—CHRONIC ABSCESS OF THE BRAIN, SHOWING HOW THE CAVITY CAN BE DRAINED BY A TUBE PACKED ROUND WITH GAUZE

FIG. 548.—CONTRACTION OF A BRAIN ABSCESS AFTER DRAINAGE

(Notice how the ventricle almost becomes normal in outline following drainage)

membrane to adhere to the cortex. Free drainage is established and the cavity packed with gauze around a drainage tube or tubes (Figs. 547 and 548). The gauze is gradually removed, allowing the cavity to heal up from the bottom.

Another method which has given good results consists in making a large burr hole in the skull over the abscess and enlarging the opening with rongeur forceps The dura mater is incised in a cruciate manner, the triangular flaps retracted, and the subdural space surrounding the opening packed with gauze soaked in a weak solution of iodine (Fig. 549). The decompression allows the abscess to extrude itself towards the opening in the skull (Fig. 550). After an interval of a week or ten days the abscess can be explored and drained (Fig. 551).

In middle-ear disease the diagnosis, both as to the presence of an abscess and its situation, is often doubtful. In such cases the antrum

and attic are then opened and explored thoroughly, and according to whether the disease is more marked in the former or latter, the

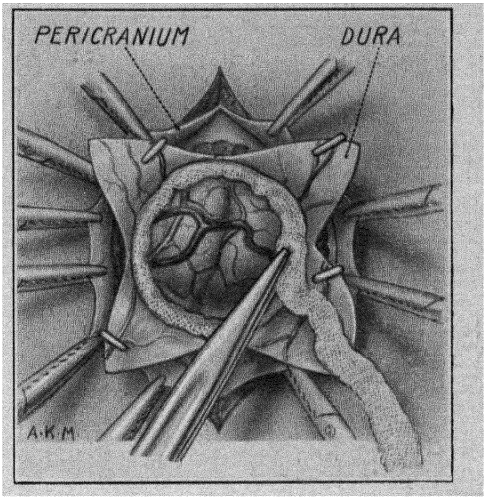

FIG. 549.—THE EXPOSURE OF THE BRAIN OVER AN ABSCESS.
(The subdural space is packed with gauze to facilitate adhesions.)

further steps of the operation are directed towards the cerebellum or cerebrum. By removing carefully the bone behind and above

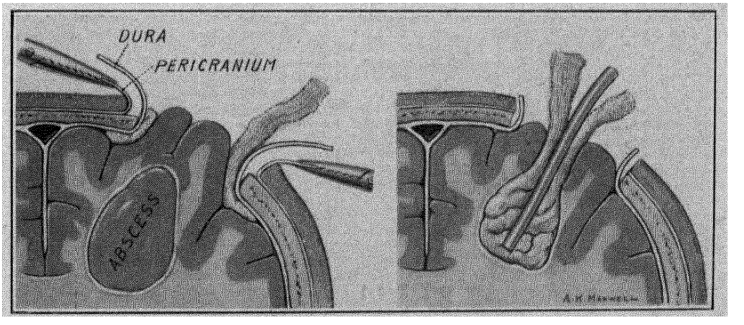

FIG. 550.—THE ABSCESS CAVITY AS FOUND AT SECOND OPERATION.
(Partial herniation has taken place.)

FIG. 551.—DRAINAGE OF ABSCESS WITH TUBE AND GAUZE.

the antrum, the lateral sinus is exposed, and by working above or below it, the cerebrum or cerebellum can be examined and, if need be, incised.

Intracranial Tumours.

Broadly speaking, intracranial tumours may be divided into those which are benign and those which are malignant.

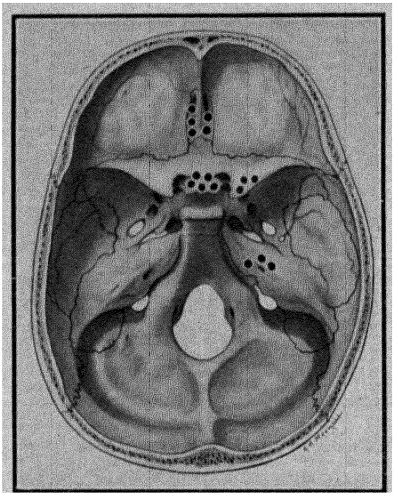

SHOWING THE COMMON SITES FOR MENINGIOMAS

The chief varieties of the non-malignant tumours are as follows.

(1) **Meningiomata** (*syn.:* dural endothelioma, meningeal fibroblastoma) are tumours characteristic of adult life, occurring most commonly in the para-sagittal central region. Their other common sites are near the cribriform plate of the ethmoid, near the basisphenoid and in the temporal fossa (Fig. 552). They account for about 14 per cent. of all cerebral tumours. These tumours are now known to arise on the arachnoid granulations, and hence their common occurrence in the para-sagittal region by the venous lamina (see Fig. 553). The tumour is usually a rounded mass sharply defined, and firmly attached to the dura mater (Fig. forms a thin layer on the inner surface of the dura ('meningioma-en-plaque'). The cerebral tissue is not invaded, but is compressed by the growing tumour. Large vessels enter and leave the tumour from the pial circulation. On section the tumour is seen to be composed of a firm whitish consistence (Fig. 554). Histologically these tumours are characterized by the whorl formation of their cells, which are often elongated with scanty cytoplasm and a vesicular nucleus (Fig. 555). When calcium is deposited in the centre of the whorls a typical picture of psammoma bodies is produced.

The meningiomata commonly invade the cranial

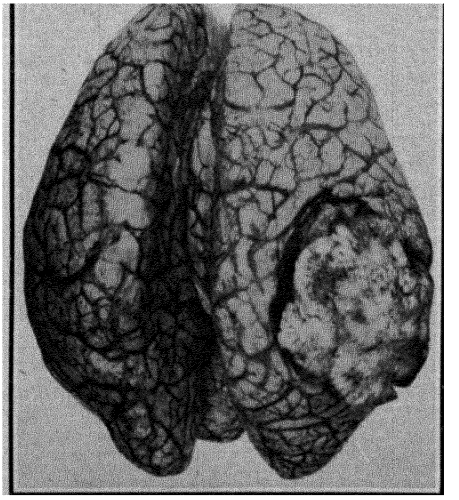

FIG. 553.—PHOTOGRAPH OF BRAIN, SHOWING A LARGE MENINGIOMA IN THE RIGHT PARIETAL REGION

bones (Fig. 556). Growth is slow but late in appearing. Attacks of twitchings, paresis, or loss of sensation may be the first sign, commonly in the foot and lower limbs, and subsequently spreading up one side of the body. Changes in the cranial vault may be palpable, there may be local erosion and hyperostosis, a bruit may be heard, and the tumours are frequently highly vascular (Fig. 556). When a rise of intracranial tension is found the tumour is usually large. These tumours are essentially benign, they grow locally, and they invade only the skull bones by pressure. They do not metastasize, and when completely removed they do not recur. They compress the cerebral tissue in their vicinity, but when this compression is removed the cerebral tissue resumes function in a dramatic way.



FIG. 554.—LARGE PARA-SAGITTAL MENINGIOMA REMOVED FROM A MAN AGED FORTY-EIGHT YEARS. The tumour has been cut into two pieces.

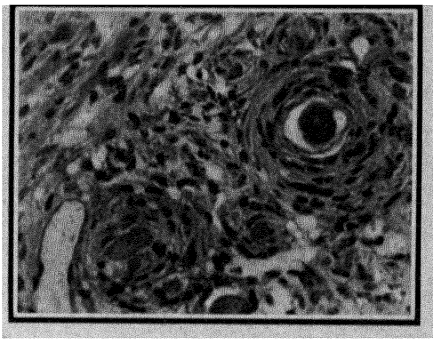

FIG. 555.—MICROPHOTOGRAPH OF MENINGIOMA, SHOWING PSAMMOMA FORMATION.

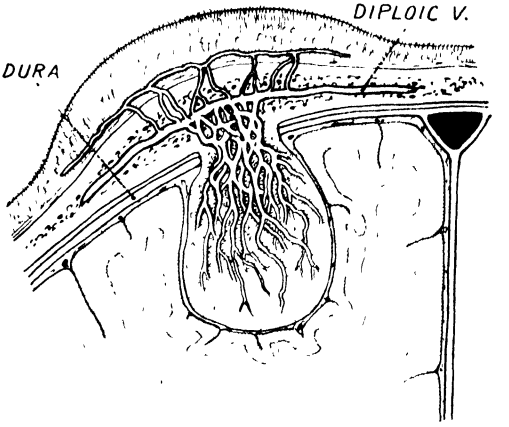

FIG. 556.—DRAWING DEMONSTRATING THE INCREASED VASCULARITY IN THE DIPLOIC VEINS IN THE REGION OF A MENINGIOMA.

The treatment of

these tumours is removal. This may, however, be difficult owing to two reasons

(*a*) Vascularity of the tumour The control of its blood-supply may tax the surgeon's ingenuity to the utmost. Multiple-stage operations may be necessary. Recourse may be had to silver clips (Fig 557), muscle grafts, and electro-coagulation (p. 298).

(*b*) Inaccessibility of the tumour. This also presents a stumbling-block, and special operative methods may have to be devised. The tumour may be in the region of the olfactory groove, the cavernous sinus, or behind the entrance of the superior cerebral veins (which should not be ligatured for fear of paraplegia) (Fig. 558).

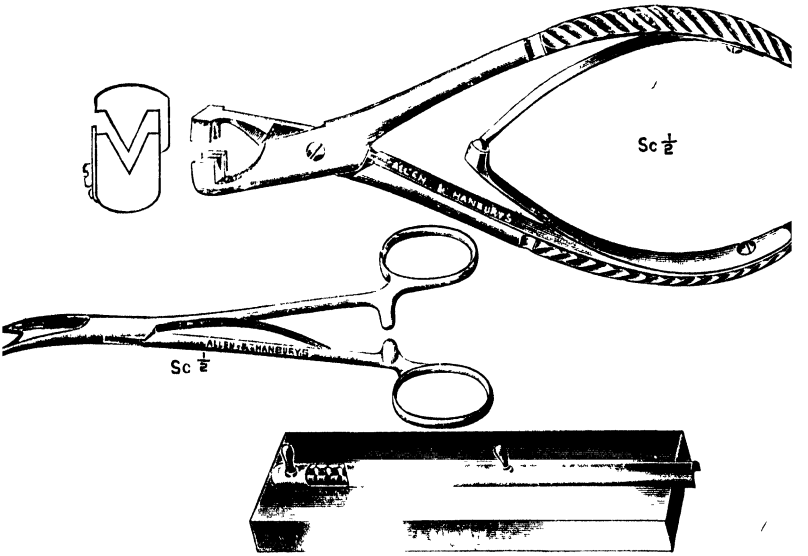

FIG. 55 WIRE SUTURE SET CONSISTING OF FORCEPS FOR SHAPING AND CUTTING THE CLIP FORCEPS FOR HOLDING AND APPLYING THE CLIPS, AND A CARRIER WITH SLIDING COVER AND HEAVY BASE FOR HOLDING CLIPS.

Successful removal is, however, most gratifying The patient is completely cured, and has been rescued from a progressive loss of cerebral function which would end in death

(2) **Cholesteatomata** (syn dermoid epidermoid, pearly tumour) are rare tumours of the diploe, they may be found at all ages, though more common in the earlier decades Epidermoids differ from dermoids in their structural layers, also in the fact that the latter contain hair. Cholesteatomata appear as yellowish-white cystic tumours, with smooth, glistening surfaces exhibiting a peculiar sheen resembling 'mother-of-pearl' They are avascular, consequently the contents are dead. They give rise to symptoms, owing to the fact that they cause obstruction to the circulation of the cerebro-spinal fluid

Treatment consists in the removal of the cystic tumour.

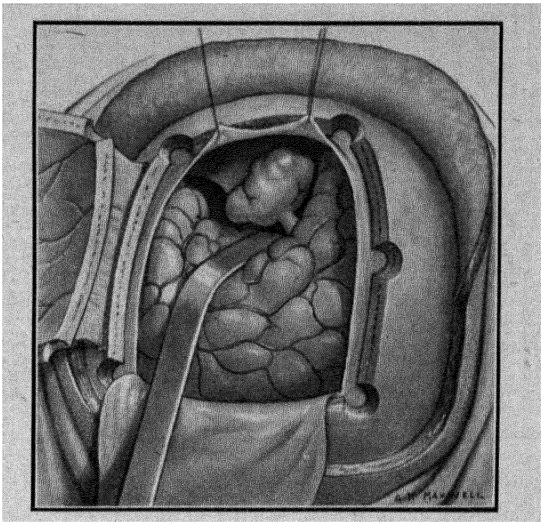

FIG 558.—MENINGIOMA OF LEFT SPHENOIDAL RIDGE
Drawing made at time of operation

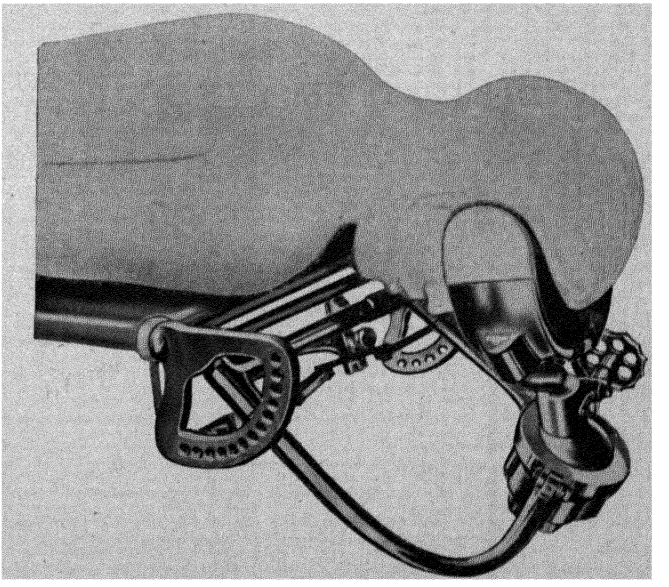

FIG 559.—DIAGRAM SHOWING SPECIAL HEAD CLAMP AND PATIENT IN POSITION FOR A CEREBELLAR EXPOSURE.

(3) **Acoustic Nerve Tumours** are neuro-fibromas or neurinomas, which grow from the sheath of the auditory nerve in the region of the cerebello-pontine angle, and press against the internal auditory meatus. They constitute about 10 per cent. of primary intracranial tumours. They are small at first and quite localized, but cause grave symptoms out of all proportion to their size. Deafness, tinnitus, and vertigo are early signs, which are followed by facial spasm, irritation, and weakness. There may be diplopia and paræsthesia of the fifth nerve. As the tumour grows it gradually excavates the bone forming the internal auditory meatus, and this can often be demonstrated radiographically in good skiagrams. In generalized neuro-fibromatosis acoustic nerve tumours may be found, and are not unfrequently bilateral.

Microscopically they are composed of interlacing bundles of long spindle cells which sometimes show regimentation of their nuclei.

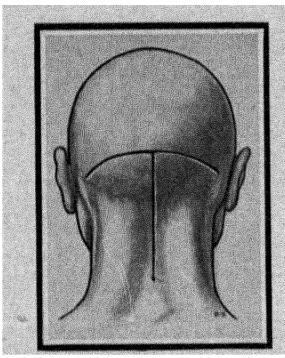

FIG 560 - CROSS BOW INCISION FOR CEREBELLAR EXPOSURE

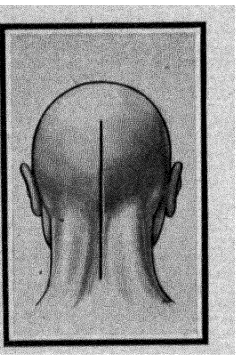

FIG 561 —VERTICAL INCISION WHICH GIVES GOOD ACCESS IN CEREBELLAR OPERATIONS

Whorls are often present, but are less definite than in the meningiomas. These tumours should be explored by the suboccipital route. The patient is placed face downwards on the operation table and the head firmly grasped in a head-piece which is lined with sorbo rubber (Fig. 559). Avertin anæsthesia should be employed, followed by intratracheal gas and oxygen, the scalp being anæsthetized with ½ per cent. novocaine. The cerebellar fossæ are exposed by means of either a 'cross-bow' incision (Fig. 560) or a median vertical one (Fig. 561). If there is much increase in the intracranial tension it is a wise precaution to tap the lateral ventricles (Fig. 562) before the dura mater is incised. When the dura mater is opened (Fig. 563) the cerebellar hemisphere is gently retracted, or, if necessary, a portion of it is amputated and the cerebello-pontine angle exposed. The tumour is pinkish-grey in colour, and lies closely applied to the petrous portion of the temporal bone. An arachnoid cyst is frequently found in front of the tumour, and the surgeon must traverse this to

expose the tumour. Numerous vessels run over the surface of the tumour and blend with the capsule. The fifth, seventh, ninth, tenth, and eleventh cranial nerves are stretched out by the tumour and may also blend with the capsule. It is for this reason that complete removal of the tumour is impossible. The present-day procedure is to incise the capsule, and with a curette remove the contents, which are usually very soft and easily removed. This allows the capsule to collapse with complete relief of pressure symptoms. The acoustic nerve, however, usually remains paralyzed.

(4) **Pituitary Adenomas** are dealt with on p. 929.

(5) **Hypophyseal Duct Tumours,** also known as cranio-pharyngiomas or Rathke's pouch tumours, are of congenital origin and account for

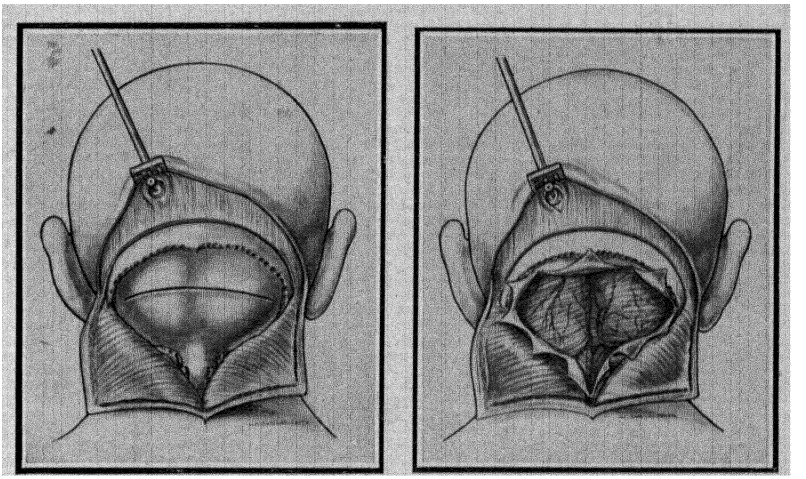

THROUGH A CROSS-BOW INCISION

The lateral ventricle has been tapped The line of incision through the bulging dura mater can be seen.

The dura mater has been incised exposing the cerebellar hemispheres.

4 per cent. of all intracranial tumours. They are situated above or within the sella turcica or in the floor of the third ventricle. Although they grow to a large size, they remain benign encapsuled tumours which are usually cystic, and calcification is common, so that diagnosis is facilitated by X-ray examination. These tumours occur most frequently in children and are derived from developmental cell rests. They should be exposed through a transfrontal approach (see p. 933). The cystic tumour should be punctured and its contents aspirated, and then an attempt should be made to remove the cyst wall piecemeal. If the cyst is very large, puncture and sudden decompression may cause very unpleasant symptoms from subthalamic interference hyperthermia, coma, etc.

Histologically these cysts are lined with a squamous epithelium resting upon a layer of dense collagen. In many of these tumours the cells adjacent to the supporting collagen are of the columnar basal type, giving an appearance which has led to the misapplication of the term 'adamantinoma' to such tumours.

(6) **Blood-vessel Tumours** account for 2 per cent. of intracranial tumours, and they fall into two main types: (*a*) Angiomatous malformations, due to abnormal development of the cerebral vessels.

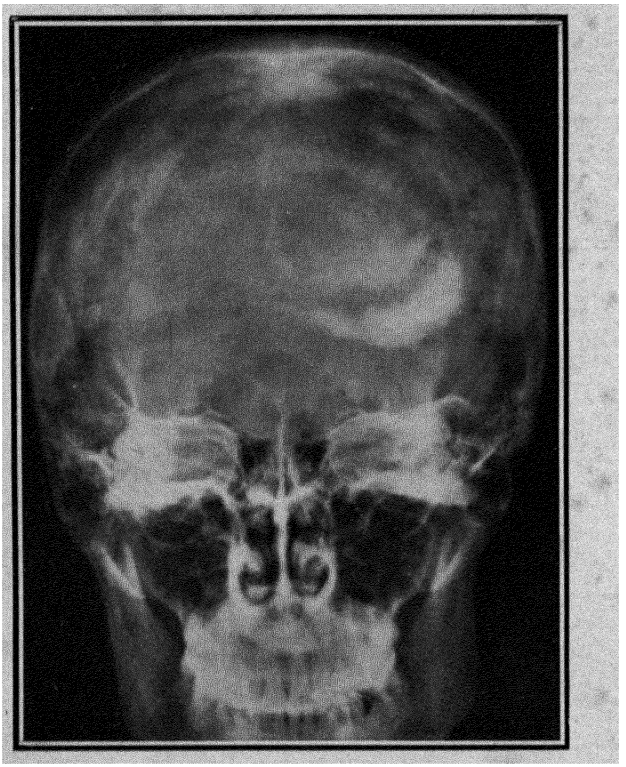

FIG. 564.—ANTERO-POSTERIOR SKIAGRAM OF SKULL SHOWING LARGE ANGIOMA OF THE OCCIPITAL CORTEX ON THE LEFT SIDE.

These may be chiefly capillary (cerebral telangiectases), venous, or arterio-venous. These tumours are not unfrequently associated with facial cutaneous nævi. The arterio-venous tumours may cause a bruit which is audible both to patient and surgeon. Unilateral exophthalmos and papilloedema may be associated (Fig. 564).

(*b*) The other type of tumour is known as the angioblastoma. These tumours are often cystic; they are found almost invariably in the cerebellum at the posterior end of the roof of the fourth ventricle.

PLATE XII

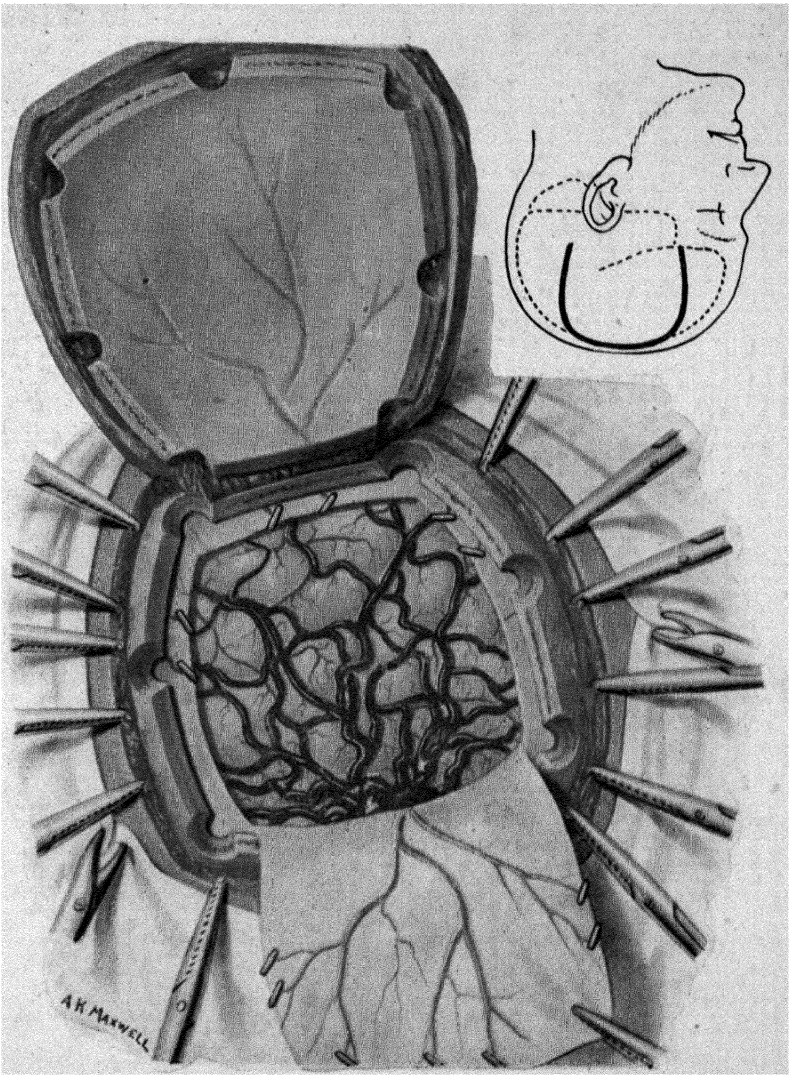

Vascular Tumour of the Brain

(The small drawing shows the extent of the incision)

These are the tumours which may be associated with angiomatosis of the retina (Lindau's disease).

The first type of tumour should be treated by a surgical exploration, and perhaps cautery or occlusion with clips of any main vessels, followed by irradiation (see Plate XII). It is impossible to remove the tumour completely. The hæmangioblastomas, on the other hand, may be extirpated surgically, though bleeding may be troublesome

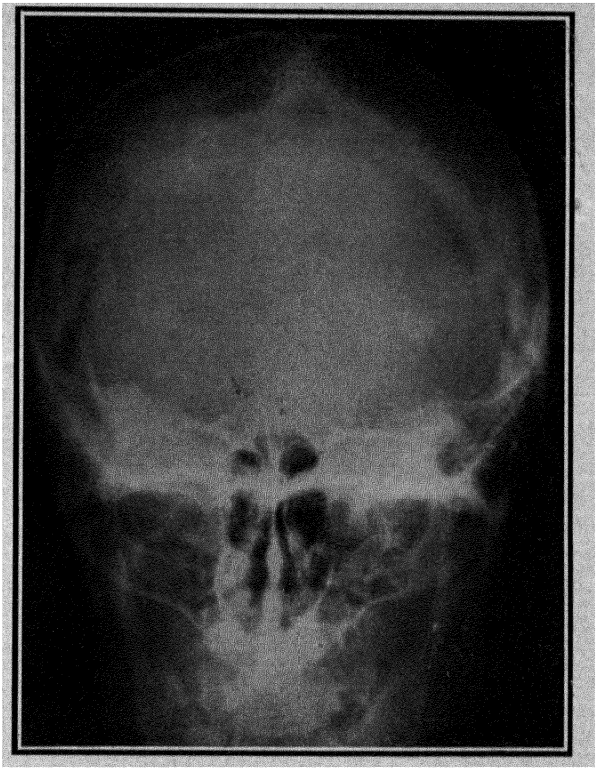

FIG 565.—ANTERIOR POSTERIOR SKIAGRAM OF THE SKULL, SHOWING CALCIFICATION IN THE CHOROID PLEXUS.

during removal. The usual suboccipital exposure of the cerebellum is used.

(7) **Non-malignant Gliomas** form a small group, probably not more than 5 per cent. of the large groups of gliomas. Cerebellar astrocytoma may be classed under this heading; it is usually cystic and of slow growth, occurring more often in the vermis of the cerebellum than in the lateral lobe.

The ependymoma of the fourth ventricle is another benign glioma.

(8) **Other Non-malignant Tumours** are chordomas and papillomas

of the choroid plexus. The papillomas of the choroid plexus may give rise to calcification in the plexus itself (Fig. 565), which can be seen in X-ray films.

(9) **Granulomata** are included under the heading of tumours, because, clinically, they give rise to symptoms which cannot be differentiated from true tumour formation.

Tuberculomata.—The incidence of tuberculoma of the brain varies enormously according to the observer and the locality in which the figures are made up. Cushing gives the incidence of tuberculoma of the brain as 2·8 per cent. of cases of cerebral tumour. Garland and Armitage found that in 13,000 necropsies performed at Leeds from 1910 to 1931, 264 were cases of cerebral tumour. Of these, no fewer than

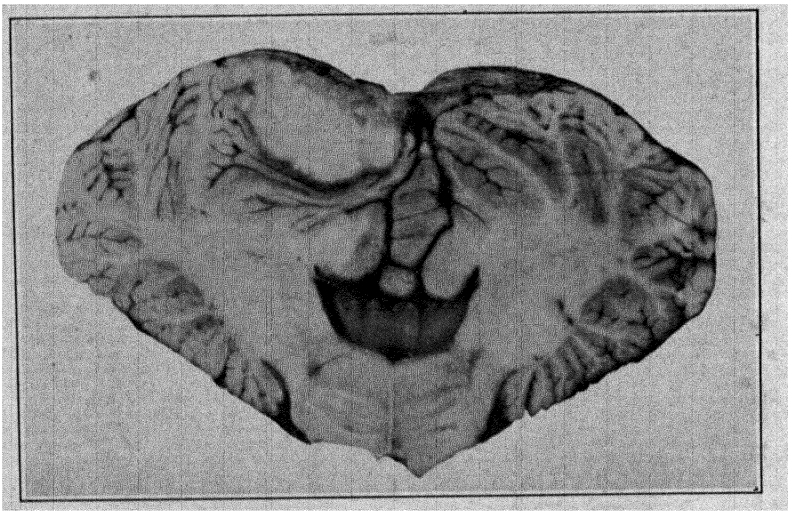

FIG 566.—CIRCUMSCRIBED TUBERCULOMA OF THE BRAIN IN A CHILD AGED SIX
The child suffered from pulmonary tuberculosis and renal tuberculosis

89, or 33·8 per cent., were tuberculomata, so that it is not easy to give a figure as to the actual incidence.

Tuberculomas are far commoner in childhood than in adult life, in a ratio of about 4 to 1. Below twenty-three years of age, approximately 60 per cent. of cerebral tumours diagnosed were found to be tuberculomas. The lesion is of two types:

1. The circumscribed tuberculoma.
2. The tuberculoma 'en plaque,' which affects the meninges.

1. The *circumscribed tuberculoma* may occur anywhere in the brain tissue. It is much commoner, however, in the cerebellum than in the cerebrum (Fig. 566). The tumour may be single or loculated, showing one large cyst and several adjacent smaller cysts.

Occasionally they are disseminated throughout the brain substance, and may occasionally be found in the cord.

The lesion is typical of any tuberculous lesion. Depending on the rate of growth and the resistance of the patient, the tuberculoma may emerge into the surrounding brain substance, or show a definite capsule. The more slow-growing the lesion the thicker the capsule.

The size varies from that of a millet seed to a hen's egg. They are often very firm, and at operation closely resemble a cerebral tumour (Fig. 567). On section there is a zone of necrosis in the centre associated with caseation. The centre is dry and yellowish with a tendency to crumble. Occasionally, if more active, the centre is diffluent, with a greyish-red peripheral growing zone.

Microscopic section shows three layers: (1) central area of necrosis, (2) a zone with giant-cells, lymphocytes, plasma cells, leucocytes and an increase in glial tissue, in which tubercle bacilli may rarely be

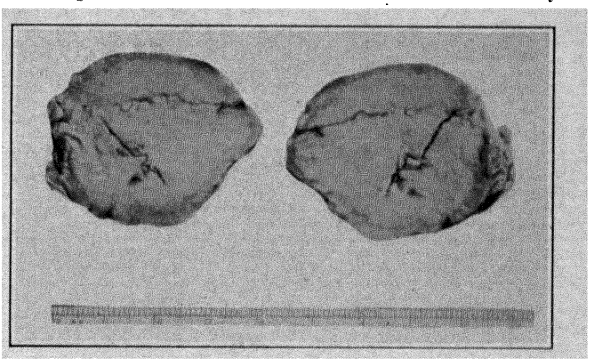

FIG 567.—TUBERCULOMA REMOVED FROM LEFT LOBE OF CEREBELLUM
Its size can be seen in comparison with the rule below

demonstrated; (3) a zone in the surrounding brain tissue showing degenerated nerve cells and nerve fibres. The small blood-vessels are thrombosed and show a lymphocytic cuffing. Fat-laden microglia may be found in large numbers in this layer and hypertrophied astrocytes. Daughter tubercles often surround the main mass.

The meninges are also involved in the neighbourhood of the region affected. To the naked eye there is reddening of the meninges, and actual tubercles may be seen. Microscopic section may show a picture typical of tuberculous meningitis.

It has been stated that tuberculomas of the brain give rise to symptoms only when meningitis has supervened. This, however, is open to grave doubt, as deep-seated lesions occur in which both macroscopic and microscopic investigation of the meninges fail to show any tuberculous reaction.

Tuberculous meningitis occurs in 75 per cent. of cases according to some observers, but in a large series only 16 per cent. of cases of tuberculous meningitis were associated with tuberculoma of the brain.

Changes in the cerebro-spinal fluid are common if the lesion is adjacent to the meninges. The cerebro-spinal fluid is under pressure, the protein is increased, and there may be a pleocytosis. The cells are predominantly lymphocytes.

Secondary changes are produced inside the skull as a result of the presence of a tuberculoma, especially with those arising in the posterior fossa. There are the changes of hydrocephalus. There is a blocking of the ventricular system from pressure on the aqueduct or on the roof of the fourth ventricle. Dilatation of the lateral and third ventricles results. The lesion itself is destructive rather than expanding, and hence large tuberculomata above the tentorium may give rise to only slight signs of raised intracranial pressure.

There is very commonly evidence of tuberculosis elsewhere. The lungs may be affected, the spine, the reproductive organs, and the suprarenals. Fever is common, ranging from 99° to 101°, usually a slight evening rise. The actual tuberculoma may be secondary to a tuberculous lesion in the cervical spine or in the middle ear or sinuses.

2. *Tuberculoma 'en plaque'* is a very rare condition. The meninges are the seat of a chronic tuberculous infection. It is usually extensive, covering one or more hemispheres. The lesion is caseous in nature, with the usual microscopical appearances. Headache is very marked, and fits of a Jacksonian type extremely common.

The prognosis is very grave and no operative treatment is of any avail.

Symptoms.—The symptoms occasioned by a tuberculoma of the brain are very varied and depend on the site of the lesion. The signs produced may be divided into focal, local, and general.

The *Focal Signs* are produced by the lesion itself. The tuberculoma is commonly situated in the cerebellum, and gives rise to cerebellar signs which consist of a combination of the following:

Nystagmus is common. It is usually present on lateral movement of the eyes. The nystagmus is slow to the side of the lesion and rapid to the opposite side.

The head is held with the occiput towards the shoulder of the affected side, the eyes looking away from the side of the lesion.

Tremor is common. It is of two types—a constant static tremor which occurs apart from movement, and an intention tremor which, as its name suggests, increases as the finger approaches the object which it is attempting to touch.

If the hands are held in front of the patient with the eyes shut, the hand on the affected side tends to fall away.

Barany's past-pointing test may be positive. There is lack of tone, generalized, but specially marked on the side of the lesion. The deep reflexes are diminished. There is difficulty in the performance of fine movements, either in rotation of the hands or in manipulation of the fingers, termed 'adiadochokinesia.'

There is unsteadiness in the gait, with a tendency to swerve and fall to the side of the lesion. If the lesion is in the mid-line of the cerebellum, then the patient tends to fall forward or backward—commonly backward.

Speech is also affected, being staccato in type.

With a supratentorial lesion the signs correspond with the site of the lesion, thus a tuberculoma in the parietal region will give rise to loss of sensation, astereognosis and, occasionally, fits on the opposite side of the body.

The Local Signs are the signs due to raised intracranial pressure. Headache is a common feature, and vomiting also. The tumour is destructive rather than expanding, but with subtentorial lesions the aqueduct is readily pressed upon and internal hydrocephalus results. In these cases the headache and vomiting are severe, and associated eye palsies may occur. The discs are choked and show the changes of papilloedema. In a child the sutures of the skull tend to separate, and fontanelles may bulge.

The General Signs.—There is commonly fever of a mild degree, a temperature of 100·5° in the evenings, sweating may be profuse, and loss of weight may occur.

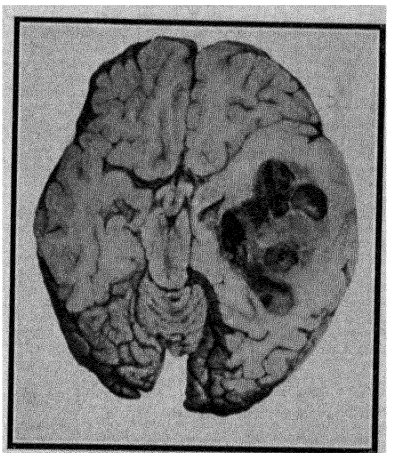

FIG 568.—SPONGIOBLASTOMA MULTIFORME.

There are usually the signs of tuberculosis elsewhere, commonly in the lungs, but also surgical tuberculosis may be seen, for example in the bones, joints, reproductive organs. In any case the lungs should be X-rayed.

Treatment.—The treatment of tuberculomas of the brain should be conservative, and although in a few cases the granuloma may be removed entirely, yet in the majority of cases tuberculous meningitis occurs as a complication and ends the scene. In those cases where a successful removal is accomplished, it too often happens that the patient dies at a later date from tuberculosis elsewhere, or from miliary tuberculosis. It is because of this fact that surgical treatment should consist of a simple decompression followed at a later date by heliotherapy. Several children with obvious tuberculomas of the cerebellum have recovered remarkably after such treatment.

Surgical treatment is indicated only where signs of intracranial pressure are present and it is essential to save the eyesight of the patient by a decompression.

Gummata of the Brain usually spring from the meninges, and are more irregular in shape than tuberculous masses. They are frequently multiple, and are seldom seen in children. Like the tuberculomas, they are getting rarer, and since the intravenous arsenical preparations have been used in the treatment of syphilis their occurrence is almost unknown in the brain.

The **Malignant Tumours** consist for the most part of the gliomas, which constitute fully 50 per cent. of all intracranial tumours. The gliomas have been divided into numerous sub-classes, especially by American writers, chiefly according to the predominating cell type. It must be remembered, however, that these are not all pure cell

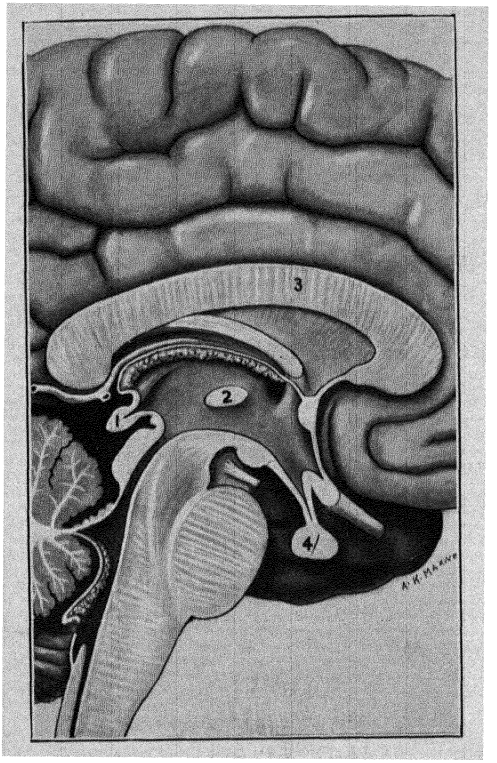

FIG. 566. ANATOMICAL RELATIONS OF PINEAL GLAND

1, Pineal gland, 2, interthalamic connection, 3, corpus callosum, 4, pituitary gland (hypophysis cerebri)

tumours, many varieties of cells being found in each tumour. Several definite sub-classes, however, are commonly recognized:

(*a*) **Spongioblastoma Multiforme** is the commonest variety of the glioma group. The tumour is of rapid growth and is confined almost exclusively to the cerebral hemispheres. The tumour may grow to a large size and may contain areas of necrosis and multiple cysts (Fig. 568). These tumours are found only in adults and are radio-resistant.

Microscopically there is a great variation in the appearances both in different tumours and in the different parts of the same tumour. The spongioblasts may form pseudo-rosettes around vessels and palisades around the borders of necrotic foci. Mitoses are usually numerous.

(*b*) **Medulloblastoma** is an uncommon tumour which occurs in children. The common site is the vermis of the cerebellum. The tumour is very invasive and tends to spread in the arachnoid and pia

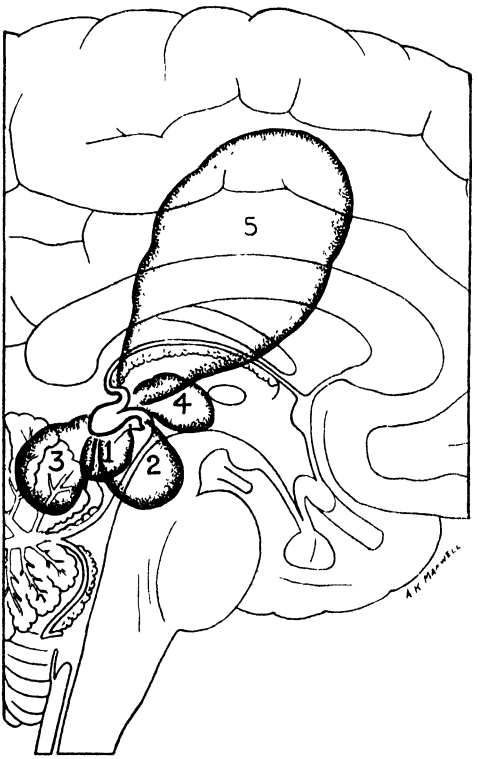

FIG 570.—SCHEMATIC REPRESENTATION OF THE VARIOUS WAYS IN WHICH A PINEAL TUMOUR MAY EXTEND AND CAUSE PRESSURE.

1, On the corpora quadrigemina; 2, on the aqueduct of Sylvius, 3, downwards on the cerebellum, causing cerebellar symptoms; 4, on the midbrain; and 5, on the cerebral hemisphere

mater. It may thus spread over the whole cerebellum and down the spinal cord, nodules being found even in the cauda equina roots. These tumours are the most rapidly growing of all the glioma group.

Histologically this tumour is composed of small, closely packed cells, with relatively large nuclei, containing a dense net of chromatin and inconspicuous nucleoli. Multinuclear giant-cells are occasionally seen, and mitoses are usually abundant.

(*c*) **Astrocytoma** is the most indolent of the glioma group, and therefore carries the best prognosis. The tumour is of slow growth and is relatively non-vascular; it has a tendency to cystic formation and at times calcification.

(*d*) Other gliomas are uncommon, but astroblastomas and oligodendrogliomas may be met with in the cerebral hemispheres.

(*e*) **Pineal Tumours** are not so uncommon as they are supposed, and they account for about 3 per cent. of intracranial neoplasms. Owing to their proximity to the corpora quadrigemina (Fig. 569), these tumours give rise to a definite pineal syndrome which is associated with impairment of the upward gaze, or with skew deviation of the eyes. This is due to pressure on the anterior corpora quadrigemina. As the pineal tumour increases in size the aqueduct is pressed upon, and an internal hydrocephalus is produced. The nuclei of the third

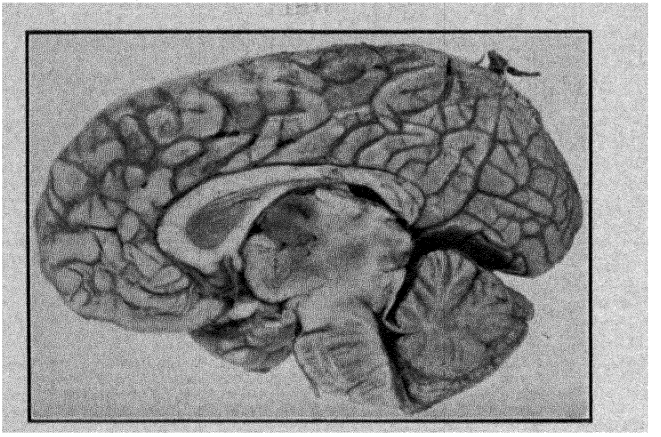

FIG 571.—PHOTOGRAPH OF BRAIN, SHOWING PINEALOMA

nerves which are situated in the periaqueductal region become pressed upon, and this produces disturbances in the intrinsic and extrinsic musculature of the eyes (Fig. 570). Pineal tumours may be divided into two classes: the pinealomas and the pineal teratomas. The pinealomas, or 'pineoblastomas' as they have often been called, are large tumours (Fig. 571), and they have a characteristic microscopical appearance (Figs. 572 and 573). There are large masses of spherical epithelioid cells, of quite considerable size, and these are separated by a fine network of reticular connective tissue in which there are lymphoid cells. The large cells are often called 'pineal parenchyma' cells.

The pineal teratomas are more rare, and are also more or less typical in their histological appearance. Sections reveal multiple cysts or tumours, consisting of a variety of cells, and often containing cholesterol crystals.

Tumours of the Optic Nerves and Chiasma.

Although these are uncommon, they are more frequent than is usually thought. They are slowly-growing gliomas which often cause an enlargement of the optic foramina (Fig. 574) which may be diagnosed

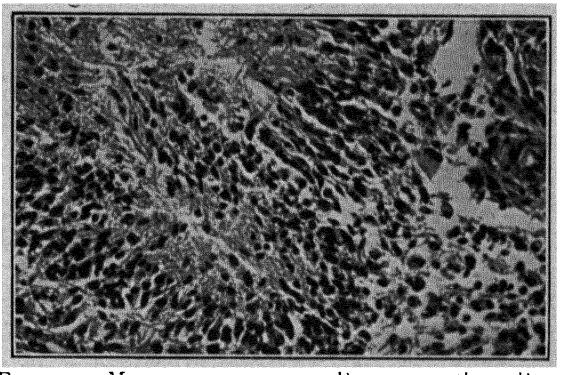

FIG 572.—MICROPHOTOGRAPH OF PINEALOMA (LOW POWER)

by modern skiagrams. There is usually optic atrophy and a ventriculogram may show a deformity of the anterior portion of the third ventricle (Fig. 575).

Metastatic Tumours are more common than is generally supposed,

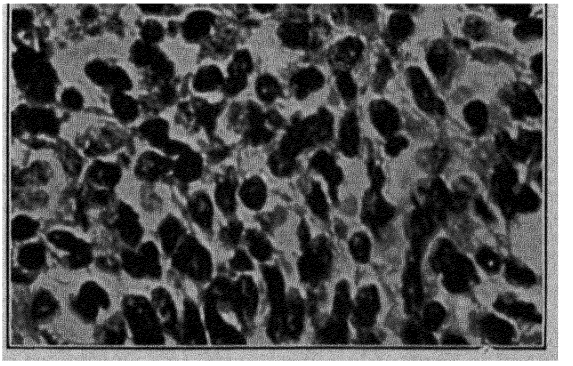

FIG 573.—MICROPHOTOGRAPH OF PINEALOMA (HIGH POWER).

and form about 10 per cent. of all intracranial new growths, they may be carcinomas, sarcomas, or hypernephromas. The commonest by far are the secondary growths resulting from a primary carcinoma in the bronchus. The possibility of a secondary deposit in the brain

must always be considered when a patient develops cerebral symptoms after an operation for primary carcinoma, especially when the primary focus is in the thyroid or the breast.

It is a curious fact that secondary growths of the pituitary gland, whether invasive or metastatic, are remarkable in their predilection for the posterior lobe, and this lobe may be completely destroyed without the development of diabetes insipidus.

The **Symptoms** of a cerebral tumour in the early stages are comparatively seldom brought under the notice of the surgeon, but it is of the greatest importance that their significance should be recognized by the general practitioner, who ought, in case of doubt, at once to obtain the assistance of a skilled neurologist, as it is only through improved and earlier diagnosis that we may hope for better surgical results. It is quite possible for a tumour to attain con-

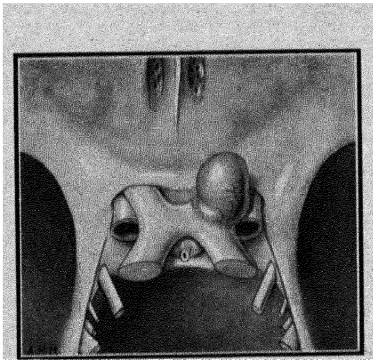

FIG. 574.—GLIOMA OF RIGHT OPTIC NERVE.

Drawing made at time of operation

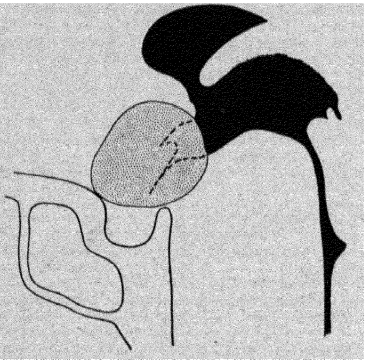

FIG. 575.—DRAWING FROM VENTRICULOGRAM

The dotted area shows the obliteration of the third ventricle by an optic nerve glioma

siderable dimensions before causing serious symptoms; the brain can accommodate itself to increased pressure in an astonishing fashion so long as the circulation is not unduly disturbed. Supratentorial tumours usually conform to this requirement, and hence may already be of large size when the patient comes under observation, or before they cause serious pressure. Subtentorial tumours, on the other hand, are likely early to encroach on the fourth ventricle or aqueduct of Sylvius, thereby causing back-pressure within the lateral ventricles, and bringing about the grave terminal phenomena. When these have appeared, the time has usually passed for successful interference, except in a few cases of subtentorial origin.

The **early** symptoms consist in some localized modification of the cerebral function, probably combined with headache and perhaps vomiting. The character of the *localizing phenomena* varies, of course, with the part of the brain involved, thus, if the cortex

of the motor area is affected, Jacksonian epilepsy is likely to result, in which a definite aura associated with a particular movement precedes the fit, which develops in an orderly fashion; in the later stages the fits are replaced by paralysis, and a localized monoplegia may be an important sign of a cerebral tumour. A subcortical lesion produces localized paralysis without convulsions. Motor aphasia would suggest an affection of Broca's lobe; word-deafness, an implication of the hinder end of the temporal lobe; and homonymous hemianopsia, a lesion of the occipital region. Interference with co-ordination, vertigo, and nystagmus point to mischief in the cerebellum, and the association of these phenomena with localized lesions of cranial nerves, especially of the seventh or eighth, points to the cerebello-pontine angle. The *headache* varies much in character, but is usually localized, occurs in paroxysmal attacks, and may be associated with local tenderness on deep pressure, if syphilitic in origin. It is increased by anything that causes passive congestion of the brain, such as coughing, and the sites of maximum pain and of the tumour often correspond. *Vomiting*, if present, is of the usual cerebral type, *i.e.* it bears no relation to the ingestion of food, and is not preceded by nausea.

The **later** phenomena are purely those due to intracranial tension, which may aggravate or to some extent mask the localizing signs. Headache becomes more severe and persistent; vomiting and constipation are well marked; the patient becomes drowsy and apathetic, wasting rapidly, and the temperature is subnormal. Papillœdema is generally present, and at first more marked on the side of the tumour. It is due to increased tension of cerebro-spinal fluid, which is thereby forced into the sheath of the optic nerve, and produces a condition of œdema, which extends to the lamina cribrosa and causes serious interference with the return of blood and lymph from the retina. There is in reality no inflammatory element about it. In the earlier stages the margins of the disc become blurred and indistinct, and the retinal veins congested and tortuous; the neighbouring retina is œdematous, and the vessels are only seen at intervals; linear ecchymoses may also occur. The vision may at first be but little affected; but if the case persists, atrophy of the disc and blindness follow, even in cases of gummata which have been cured by medicine, if that cure has not been attained quickly.

The **terminal** phenomena of a cerebral tumour are gradually increasing coma, and the supervention of symptoms similar to those of compression (p. 878), whilst the temperature may be subnormal or occasionally very high. Sudden death is not unfrequent.

Treatment.—In every case the possibility of the symptoms being due to gummatous disease must not be forgotten, and a test for the Wassermann reaction should always be undertaken; if positive, an intravenous injection of salvarsan may be given, or large and increasing doses of iodide of potassium (even up to 40 or 60 grains three or four times a day) should be administered before undertaking operative proceedings. But time must not be lost; if the patient's condition does not rapidly improve, then operation should be performed. Symptoms of gastric irritation must be prevented by giving some alkaline carbonate

especially the ammonium or soda salts), whilst the dose should be freely diluted with water.

Operation should be undertaken as early as possible, since even if no tumour is discovered the patient runs but little risk, whilst delay may render it irremovable. For details larger textbooks must be consulted, but a few general points may be noted. Infiltration anæsthesia should be induced by the use of 1 per cent. novocain and adrenalin. If a general anæsthetic has to be employed, intratracheal gas and oxygen should be given. The skull is opened by turning down a large osteoplastic flap (Fig. 576), and with local anæsthesia the loss of blood is so much diminished that there is often no need to delay till a later date the subsequent steps. The dura is incised and the brain exposed. It is gently explored by a grooved needle, each stab being made exactly at right angles to the surface. If, however, a cortical neoplasm is found, it is isolated from the surrounding brain substance by a dissector, all bleeding being controlled by the coagulating electrode of an electro-surgical unit. The dura mater is then loosely approximated and the wound closed without drainage. After the operation, the patient must be kept absolutely quiet, with the head slightly raised. The drainage-tube is removed in twenty-four or forty-eight hours, and the scalp wound is usually healed in six or seven days.



FIG. 576.—EXTENT OF INCISION IN A CASE OF LARGE PRE-ROLANDIC GLIOMA

When the tumour is inaccessible or irremovable, or its situation doubtful, temporary benefit often results from *decompression*. The decompression is best undertaken over the supposed site of the tumour, but has sometimes been subtentorial, with a view to influencing beneficially the vital centres. An intensive course of X-ray treatments is then given over the decompression area. A considerable measure of benefit follows such operations, as evidenced by an improved mental condition, loss of pain, retrogression of the papilloedema and the preservation of sight. Of course, sooner or later the continued growth of the tumour results in the patient's death.

Lobectomy may be performed in those cases where the tumour is situated in the frontal, temporal, parietal, or occipital lobes.

If the tumour is situated in the temporal pole, which is a silent area of the brain, relatively large portions of the brain can be removed without causing serious post-operative disability. The best form of anæsthesia is avertin, followed by intratracheal gas and oxygen.

Local infiltration of the scalp is undertaken, using ½ per cent. novocain, to which has been added some adrenalin solution.

A large horseshoe-shaped osteoplastic flap is turned down and the dura mater exposed. If the intracranial pressure is much increased, an attempt is made to tap the lateral ventricle. Should this fail, owing to the fact that the ventricle is compressed by the pressure exerted by the tumour, then the opposite ventricle is tapped. The dura mater is opened as a flap and the brain exposed. If the tumour is situated in the temporal pole, a lobectomy is carried out. The cerebral vessels are coagulated with the diathermy coagulating current (Fig. 577).

The area to be removed is decided upon, and the cutting diathermy point is used to divide the brain substance, any big vessels encountered being coagulated *en route*. The brain substance is separated by thin

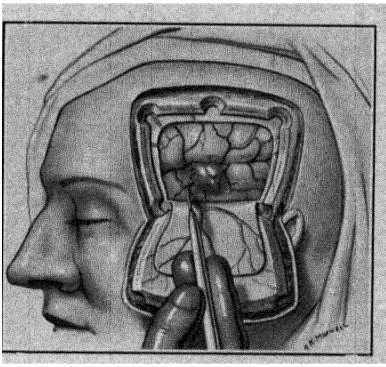

FIG. 577.—REMOVAL OF A TUMOUR OF THE TEMPORAL POLE OF THE BRAIN

The cortical veins in the region of the tumour are coagulated with the diathermy cautery.

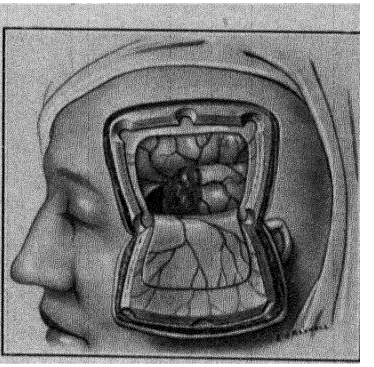

FIG. 578.—APPEARANCE OF THE BRAIN AFTER LOBECTOMY OF THE TEMPORAL POLE FOR TUMOUR

malleable retractors. The surgeon proceeds very slowly and carefully until the whole of the temporal pole in which the tumour is contained is removed. The cut surface of the brain is examined to see that no sign of any tumour tissue remains and that all bleeding points have been effectively coagulated (Fig. 578). The dura mater is replaced and the osteoplastic flap returned and sutured in two definite layers. No drainage is necessary as a rule. The patient is returned to bed, and, if necessary, a small blood transfusion is given. As soon as consciousness is recovered he is nursed in the sitting position. Fluids are given liberally, and solid food is taken about the third day. The patient is able to leave hospital within three weeks.

In those cases where the tumour is large and is situated in the substance of the temporal lobe, the best results are obtained by performing a palliative decompression, followed by a course of deep X-ray therapy. Better results have been obtained by this procedure

than by partially removing the tumour and then giving X-ra treatment.

In dealing with cerebellar tumours, or those in the neighbourhoo either by removal or decompression, Cushing's cross-bow incision ma be employed. It consists of a curved incision, with its concavit downwards, passing along the superior curved line of the occipit bone, and from its centre passes down a vertical incision as far as i necessary in order to reflect the muscles from the posterior aspect of th atlas. Removal of fibromata from the cerebello-pontine angle shoul be undertaken very slowly by *morcellement* and suction owing to th proximity of vital centres.

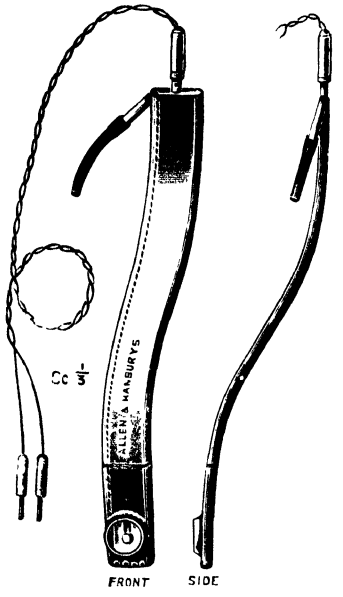

FIG 570 THE WAKELEY RAWLING ILLUMINATED RETRACTOR AND SUCKER

Meningiomas require adequate expo sure, and because of their vascularity is necessary to be prepared to give blood transfusion at any time during o after the operation. If the tumour very large, it is often a good plan t gouge out its interior with an electro surgical loop. As the result of suc treatment the tumour shrinks up an its complete removal presents littl difficulty. If the tumour is situate on both sides of the longitudinal sinu and is anterior to the lateral con municating veins, the whole tumou with the falx and the sinus may b resected without producing motor o sensory paralysis. If, however, th tumour is placed posteriorly to th lateral communicating veins, remov of the longitudinal sinus will result i paralysis, and, therefore, this struc ture should be carefully preserve although complete removal of the tu mour may thereby be rendered impo sible. In such cases post-operativ radiation therapy should be given wit the object of completely destroying any tumour cells. In cases whe a large hypertrophied osteoma of the skull overlies a para-sagitt meningioma, the surgeon can trim off the hypertrophied bone, bo the newly-fashioned bone-flap for half an hour, and then replace it.

At times meningiomas may arise on the tentorium, in which cas they must be resected with that structure. If bleeding cannot b stopped with ordinary methods, a muscle flap from the gluteal regio can be cut and applied to the cavity from which the tumour has bee removed.

There are two methods of approach to **pineal tumours,** and bot demand a large right occipito-parietal osteoplastic flap. Dandy approach is the operation of choice. The dura mater is opened widel as a flap, and turned downwards. After the cerebral veins have bee

divided, the whole of the posterior extremity of the hemisphere is retracted to such an extent as to expose the falx cerebri. A useful brain retractor, which also combines suction and illumination in one, is seen in Fig. 579. Continued retraction will bring the inferior longitudinal sinus into view, and beneath it the corpus callosum. In order to obtain adequate retraction without damaging the cortex of the hemisphere, it is always necessary to tap the lateral ventricle. To obtain an adequate exposure of the splenium of the corpus callosum, it is often advisable to divide the inferior longitudinal sinus

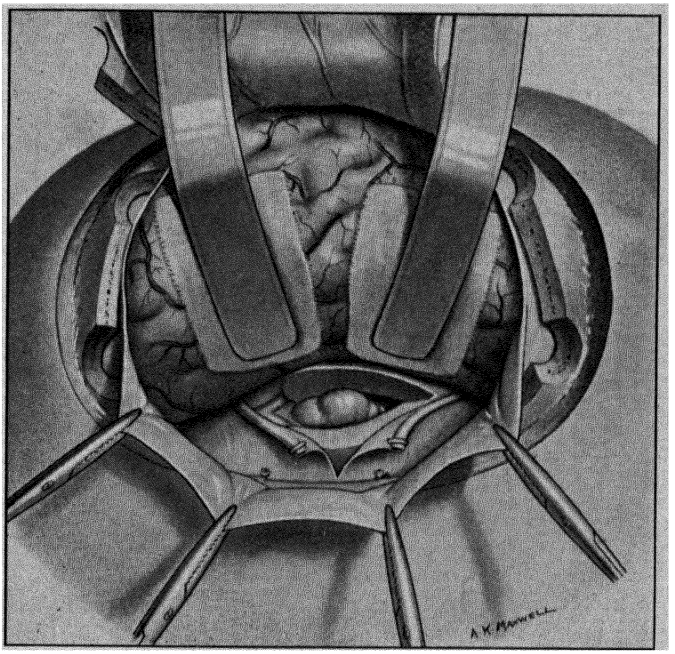

FIG 580.—EXPOSURE OF A PINEAL TUMOUR

The inferior surface of the falx has been divided, together with the inferior sagittal sinus. The posterior end of the corpus callosum has been divided, exposing the pineal tumour.

between silver clips, and then slit up the lower border of the falx for half an inch or more. The splenium of the corpus callosum is then incised in the mid-line and the tumour exposed (Fig. 580). The most important structure in relation to the tumour is the great vein of Galen, which lies under the fornix. This vein and its tributaries should be carefully preserved. The tumour must be carefully dissected out. In this procedure the third ventricle is sometimes opened. All bleeding is controlled by the application of silver clips or the use of the diathermy point. The posterior part of the cerebral hemisphere is allowed to

fall back into place, and the dura mater sutured with one or two tethering sutures. Drainage for a day or so is often necessary. The osteoplastic flap is replaced and the scalp sutured.

The second method of surgical removal of a pineal tumour is that devised by Van Wagenen, in which the tumour is attacked through the dilated lateral ventricle. This is an easier method, because as soon as the ventricle is opened the tumour can be seen bulging through the median wall of the ventricle (Fig. 581). The disadvantage of this method is that it usually leaves some permanent disturbance of function in the form of hemiplegia and homonomous hemianopia.

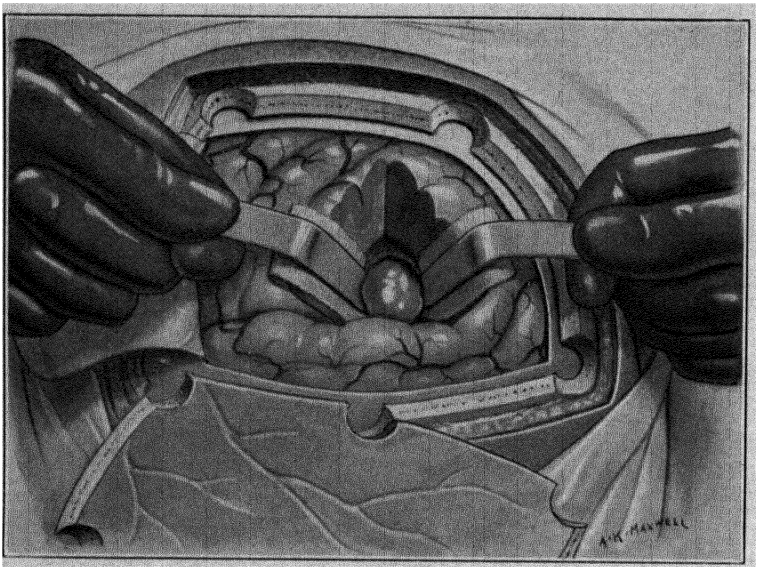

FIG. 581.—ACTUAL EXPOSURE OF A PINEAL TUMOUR THROUGH THE LATERAL VENTRICLE.

Tumours of the Pituitary Gland, or Hypophysis Cerebri.

The pituitary is a peculiar ductless gland in many respects. The anterior and posterior portions are developed in different ways and have a particular histology, each producing a distinct hormone.

The anterior lobe is derived from an outgrowth, or diverticulum (pouch of Rathke) of the primitive pharynx, and its secretion is discharged into the blood-stream; an increase of this secretion produces gigantism if it occurs before the epiphyses have joined, and acromegaly if full growth has been reached. If there is hypopituitarism, sexual desire and potency are lost, and an early sign of the disease in females is amenorrhœa. Metabolism is also affected, showing a close connection with the thyroid gland; in hypopituitarism it is diminished, and in hyperpituitarism it is increased.

The posterior lobe is developed as a funnel-shaped sac from the floor of the third ventricle of the brain, and consists of a mixture of epithelial and nervous elements. There is some evidence that the secretion of this portion is discharged into the cerebro-spinal fluid. Post-pituitary extracts, if injected into mammals, produce three important groups of actions—namely, the pressor (cardiovascular) action, the oxytocic (uterine) action, and the antidiuretic (renal) action. Experimentally the removal of the posterior lobe leads to increased sugar tolerance, adiposity, and polyuria.

Tumours of the pituitary gland consist of adenomata and cystic tumours of Rathke's pouch. The commonest tumour of the pituitary is the adenoma, which arises in the anterior lobe and is named according to the type of cell which it resembles.

Primary tumours of the posterior lobe are virtually unknown.

(*a*) Chromophobe adenoma is the commonest type of pituitary tumour, and it gives rise to hypopituitarism. It is composed of masses of non-granular cells showing no specific staining properties (Fig. 582). Probably the cells are an embryonic type of the chromophobe cells which occur in the normal gland. There are no eosinophile cells and the tumour does not furnish any endocrine secretion.

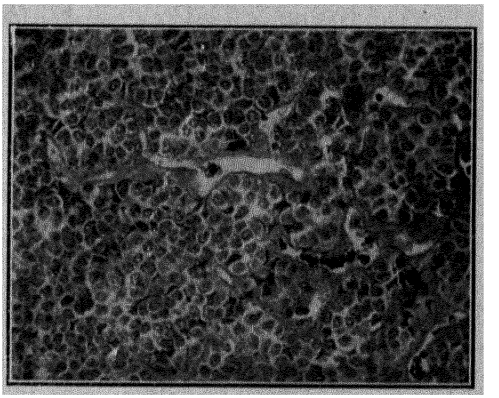

FIG 582.—MICROPHOTOGRAPH OF CHROMOPHOBE ADENOMA OF THE PITUITARY (HIGH POWER)

(*b*) Chromophile or eosinophilic adenoma is made up of granular eosinophile cells that resemble the normal epithelium of the anterior lobe. The cells vary in size and shape, and there are generally a few chromophobe cells present as well. This type of tumour produces symptoms of hyperpituitarism.

(*c*) Mixed adenomata resemble the general chromophobe tumour with some eosinophile cells scattered through it. These tumours give rise to 'dyspituitary' or mixed syndromes, owing to the blending of the hypo- and hyperpituitary features.

Hyperpituitarism is always associated with the anterior lobe, and shows itself either as gigantism in children or acromegaly in adults (Fig. 583), the former being a relative increase of all parts of the body, while in the latter the chief changes are in the skull, spine, and distal portions of the extremities. In hypopituitarism the effects also differ as they occur in childhood or adult life. When developed in childhood, two types are noted, one in which the child is infantile in character, with small bones, and fine, hairless skin (Lorain's disease), the other in which there is great and generalized deposition of subcutaneous fat, with

sex infantilism and metero[illegible] tolerance, without any arrest in growth (Frohlich's syndrome).

Rathke's pouch, or [illegible] tumours are wholly or partially cystic tumours arising in the pituitary stalk, and are, therefore, supra-pituitary in position. These neoplasms are very similar in microscopical appearance to fibrocystic disease of the jaw. It is for this reason that they have been named adamantinomas. One of the commonest characteristic features of these supra-pituitary tumours



FIG. 583.—SKIAGRAM OF SKULL OF ADVANCED ACROMEGALIC
(An enormous sella turcica [illegible] and a very large frontal sinus)

is their tendency to undergo calcification, which usually can easily be seen in skiagrams.

In all forms of pituitary enlargement, signs of pressure may occur either early or late, and the surgeon is then anxious to know whether the tumour is in the pituitary itself or is suprasellar in origin. If it is an adenoma of the pituitary, the sella turcica enlarges in size downwards and forwards (Fig. 585), eventually depressing the sphenoidal air sinus; suprasellar tumours usually erode the clinoid processes, and there is flattening of the sella turcica. Varying disturbances of vision result from this, the [illegible]mmon being a bilateral hemianopia

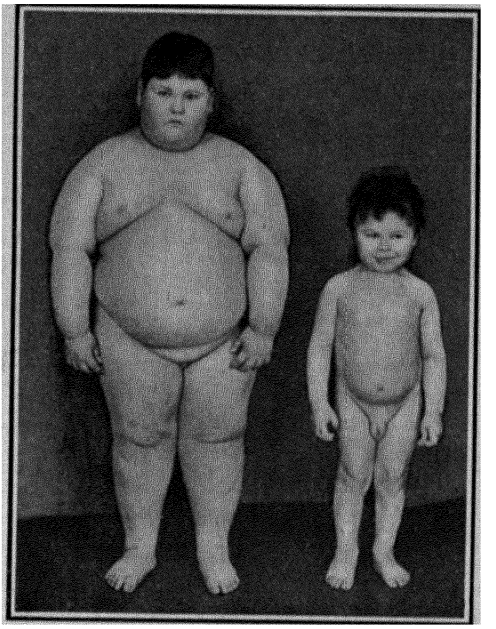

FIG 584.—THE TWO TYPES OF HYPOPITUITARISM IN CHILDREN

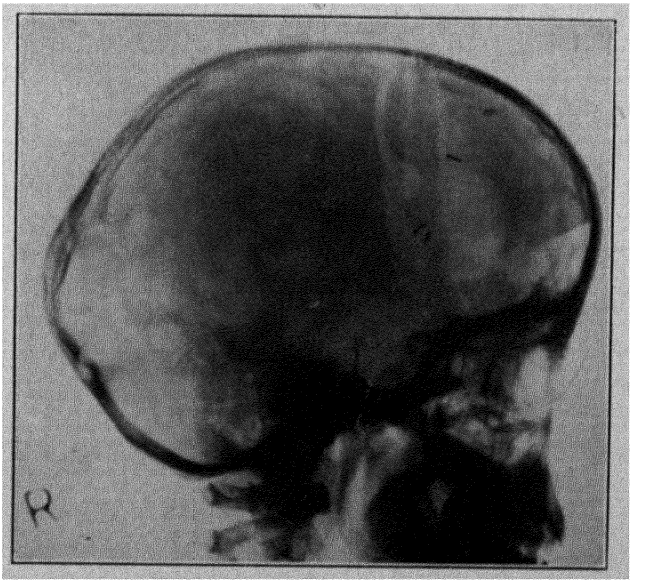

FIG. 585.—SKIAGRAM OF SE[illegible] TO AN ADENOMA O[illegible]

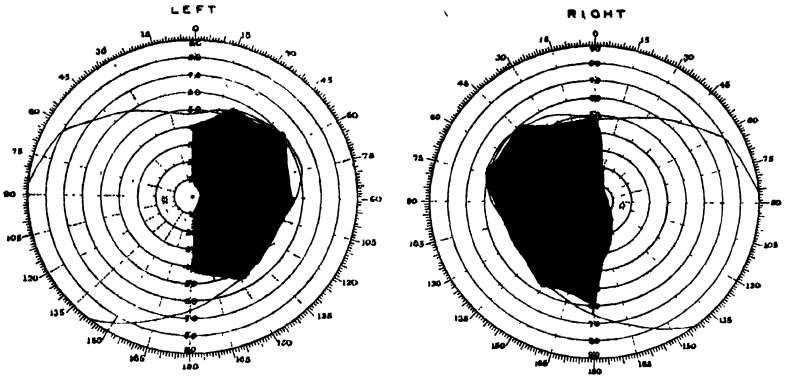

FIG. 586.—VISUAL FIELDS FROM A CASE OF PITUITARY ADENOMA
Right temporal hemianopia, with a quadrantic defect in the left temporal field

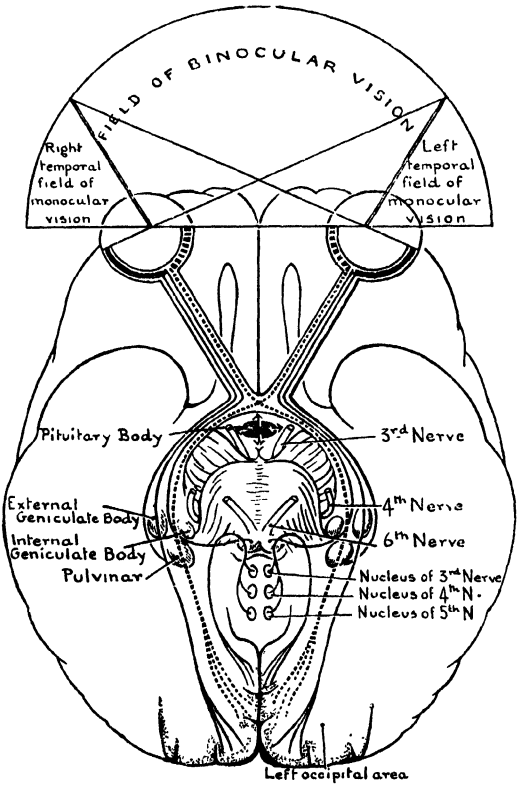

FIG 587.—DIAGRAM SHOWING THE CONNECTIONS OF THE OPTIC NERVES TO THE OCCIPITAL CORTEX.
The close connection of the pituitary and the optic chiasma can be seen

(Fig. 586), followed in time by optic atrophy with complete blindness (Fig. 587). Intracranial pressure is not markedly increased, but headache is often complained of, usually without vomiting, and the sensation of the face may be impaired, together with modifications of taste and smell.

In some retrochiasmal tumours a scotoma may occur instead of a hemianopic field defect—more especially in hypophyseal duct tumours. As the majority of pituitary tumours arise below and rather in front of the chiasma, they cannot cause a scotoma unless the chiasma occupies a prefixed position (Fig. 588), which it does in about 5 per cent. of cases. When, however, the chiasma is prefixed, a pituitary adenoma usually extends upwards behind it and commonly produces central scotomata.

It is only when pressure symptoms have arisen that operative treatment is indicated. There are two chief routes for exposing the



FIG. 588.—RELATION OF OPTIC CHIASMA TO THE PITUITARY FOSSA.

pituitary gland: (1) transfrontal and (2) trans-sphenoidal. The former is the one most usually adopted by neurological surgeons of this country.

Transfrontal Exposure of Pituitary Tumours.

The transfrontal approach should be used for all suprapituitary tumours.

The patient should be placed in the supine position with the head slightly extended over a sandbag. An ear-to-ear incision is made, starting about 2 cm. above and in front of the ear and passing transversely across the head to the other side (Fig. 589). The scalp is turned forwards over the face, the supra-orbital vessels and nerves being preserved. An osteoplastic flap is elevated outwards, the temporal muscle acting as a hinge (Fig. 589). The next step is to elevate the dura mater from the orbital roof and keep it retracted by means of a retractor. The dura mater is gradually and very carefully separated by means of small rolls of cotton-wool, until the ridge of the lesser wing of the sphenoid is reached. On the medial side the separation is limited by the olfactory groove. The dura mater is incised at the limit of separation, and the cerebro-spinal fluid allowed to escape. An illuminated retractor is now inserted through the opening in the dura mater and beneath the frontal lobe of the brain, and is then carefully and slowly retracted, when the right optic nerve will gradually come into view. As a result of the pressure of

the tumour, the optic nerve may be flattened. The pituitary tumour will be seen to the inner side of the optic nerve, and the internal carotid artery may sometimes be seen lying to the outer side of the optic nerve.

The capsule of the tumour is incised with the diathermy needle, and the interior of the tumour is aspirated or removed by means of

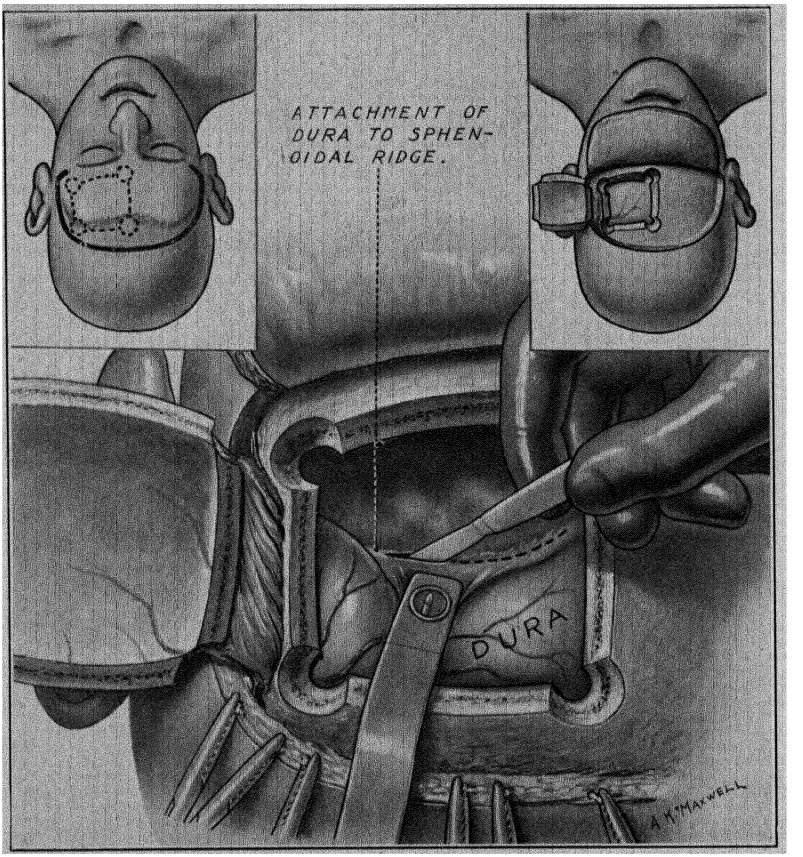

FIG 589.—TRANSFRONTAL APPROACH TO A PITUITARY TUMOUR
(The insets show the method of forming the osteoplastic flap.)

a small metal loop (Fig. 590). The capsule is then gradually removed by careful traction. Hæmorrhage may be controlled by means of small rolls of cotton-wool and a gentle stream of hot saline solution. To be certain that all the tumour capsule is removed is wellnigh impossible in every case, and for this reason it is advisable to give a course of X-ray therapy after the operation.

Cystic stalk tumours are exposed in a similar way. The cyst is punctured, the fluid withdrawn, and the capsule removed by firm traction. The closure of the wound after a transfrontal operation is quite simple. The bone flap is replaced, the periosteum sutured, and the scalp returned and sutured with interrupted silkworm gut sutures.

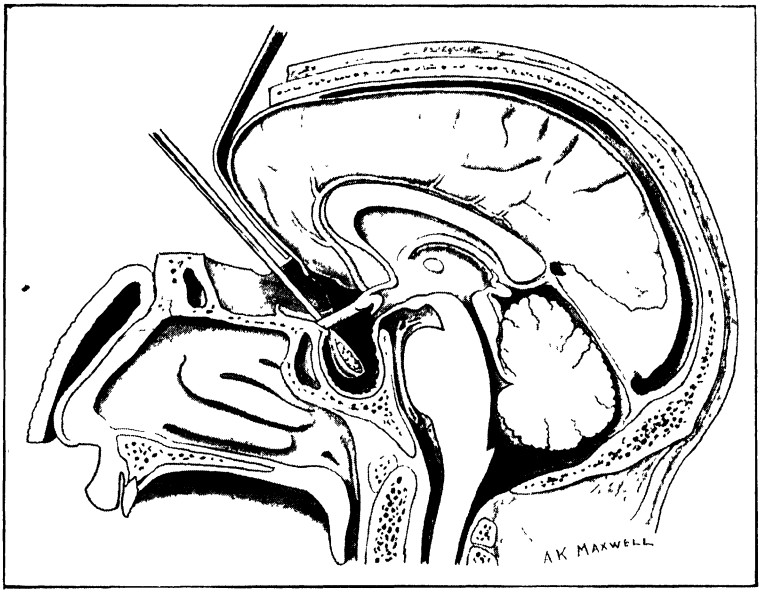

FIG. 590.—REMOVAL OF THE CONTENTS OF A PITUITARY ADENOMA BY MEANS OF A SMALL LOOP CURETTE

(A transfrontal approach is used.)

Trans-sphenoidal Exposure of Pituitary Tumours.

This operation is seldom performed to-day; its only indication is a case of acromegaly.

Intratracheal anæsthesia is essential in this operation, and the patient should be in the supine position with the head well extended. The frenum of the upper lip is incised and the lip retracted upwards with a periosteal elevator; the muco-periosteum is then displaced upwards until the anterior edges of the nasal septum are exposed. A submucous resection of the nasal septum is now performed, and the sphenoidal attachment of the vomer exposed and removed. By means of a lighted speculum the anterior walls of the sphenoidal sinuses can be seen, and the thin bone which constitutes these walls, together with the thin vertical septum separating the two sinuses, can then be removed by long, thin alligator forceps,

thus exposing fully the cavity of the sphenoidal sinuses (Fig. 591). The bulging floor of the sella turcica, which forms the roof of the sphenoidal sinuses, can now be seen, and this is broken through, exposing the dura mater covering the tumour. The dura mater is incised with a long, thin, hooked knife, and the tumour contents can be seen discharging into the cavity of the sphenoidal sinuses. As much as possible of the softish tumour substance is removed by suction.

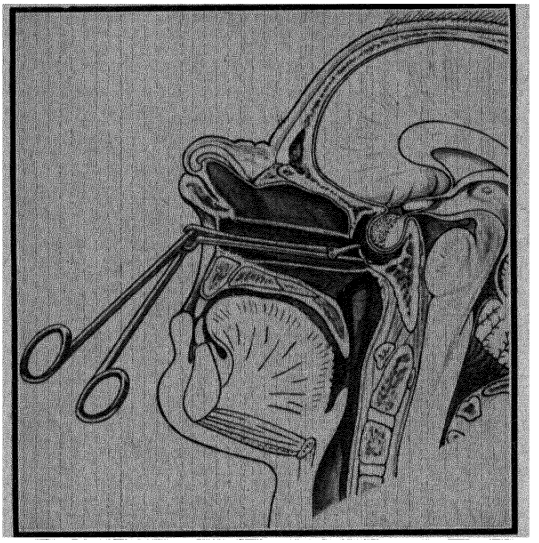

FIG 591.—TRANS-SPHENOIDAL EXPOSURE OF PITUITARY TUMOURS

Drainage is carried out by inserting a thin strip of rubber into the sella turcica and allowing it to lie between the muco-periosteal layers of the nasal septum and fixing it to the frenum of the lip. The rubber strip should be removed after an interval of thirty-six hours. The nasal cavities are plugged with gauze soaked in vaseline, which should be removed twenty-four hours after operation. The patient is nursed in the Fowler position.

The surgical treatment of pituitary tumours gives excellent results.

X-ray treatment of pituitary tumours should always follow surgical removal, so that there is no fear of any recurrence. But X-ray treatment should never be given by itself in the absence of

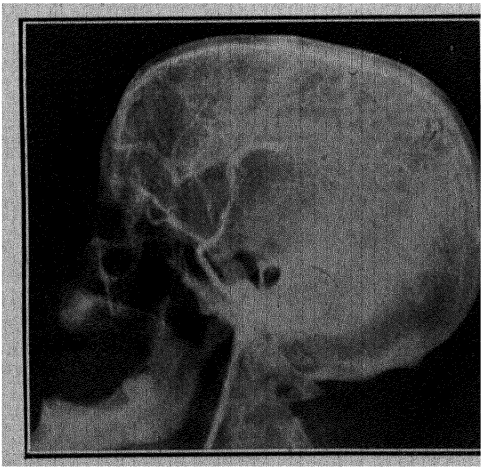

FIG 592.—ARTERIOGRAM IN A CASE OF PARIETO-TEMPORAL GLIOMA.

The cerebral vessels are pushed up by the tumour.

operation, where there are signs of increased intracranial pressure, because there is a great tendency for the pressure to be raised still further, owing to the œdema of the brain caused by the treatment. We have seen two fatal results follow such treatment and several cases of retinal hæmorrhage.

Arteriography may be of use in some cases where the diagnosis of the cerebral tumour is difficult; 10 to 20 c.c. of thorotrast are injected into the internal carotid artery and an X-ray exposure made. The outline of the cerebral vessels is clearly demonstrated (Figs. 592 and 593). If a tumour is pressing on the brain, that area will not appear to have any blood-vessels passing to it. Arteriograms may also be useful in the diagnosis of congenital intracranial aneurisms and angiomata. The vascular pattern in an arteriogram illustrates the size of the tumour as well as its vascularity. Also, there are occasions when the differentiation of an aneurism from a meningioma is all-important (Figs. 133 and 134, p. 336), and an injection of thorotrast may save opening the skull.

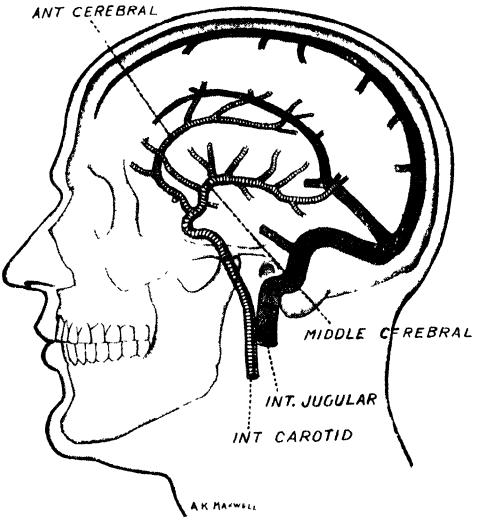

FIG 593.—ANATOMY OF THE INTERNAL CAROTID ARTERY, AND VENOUS DRAINAGE FROM THE BRAIN

The Surgical Treatment of Epilepsy.

The only operative treatment for this condition now seriously considered is directed to the cerebral cortex, a proceeding dependent on the supposition that the epileptic convulsion results from an irritable condition of the cortex, which may be excited into convulsive activity by various stimuli, originating either in the brain or elsewhere.

When due to **tumours, abscess,** etc., epilepsy is accompanied by other manifestations, which should guide the surgeon to a correct opinion as to the nature of the case and the operative outlook.

Epilepsy due to Cysticercosis is quite common in India. The intermediate stage of *Tænia solium* develops readily in man, and the embryos have a predilection for the brain, especially for the grey matter. Epilepsy is far the commonest of the nervous manifestations of cysticercosis. The usual treatment of epilepsy must be carried out; surgery is not indicated, owing to the large number of parasites found in the brain and their wide distribution.

Traumatic Epilepsy is the term applied to an epileptic condition resulting from injuries. It may arise from any of the following conditions: (1) A neuralgic cicatrix in the scalp; (2) a slight unrelieved depression of the skull; (3) excessive formation of callus after a fissured fracture, or chronic thickening of the bone from osteitis after a contusion, whereby the dura mater is pressed upon and irritated; (4) chronic meningitis, usually associated with an adherent cicatrix in the brain, and particularly liable to occur in syphilitic patients; (5) a single depressed spicule of bone projecting into the cerebral substance; and (6) as a result of penetrating wounds of the brain which have been treated by decompression.

The **Symptoms** produced are epileptic seizures of the Jacksonian type, the exact manifestations varying with the portion of cerebral cortex which is involved. Localization of the lesion depends partly on the character of the aura, partly on the associated symptoms, such as a fixed headache or the presence of a cicatrix. The convulsions are localized to begin with, but often become general.

Operative Treatment is only applicable in those cases in which the convulsions remain localized; general convulsions place the patient in the category of idiopathic epileptics with a focal onset. The skull is opened over the site of the supposed injury, and it may be that some depressed fragment or spicule of bone is found; it will, of course, be removed. Occasionally a cyst may be found, due to the presence of a hæmatoma at the site of an old injury. If, however, nothing is found but an adherent cicatrix between the membranes and the underlying brain, it is still an open question as to whether the surgeon should proceed further. In a considerable number of cases the cicatrix and underlying brain substance have been removed; the fits ceased for a time, but in most instances recurrence followed sooner or later from the formation of a fresh adherent cicatrix.

Focal Epilepsy and Athetosis.

Although Horsley in 1909 first described a method of excision of an area of motor cortex for relief of violent athetoid and convulsive movements of an upper extremity, it is due to the work of Sachs and Furlow, of St. Louis, that this method has now become an established one. The operation should, if possible, be performed under local anæsthesia. An osteoplastic flap is raised over the motor cortex, a dural flap turned down, and a careful examination is made of the exposed brain. Stimulation of the cortex is performed with a unipolar galvanic electrode, so that the area of exposed cortex when stimulated will reproduce the focal convulsive movements or sensory seizure. Having determined the area exactly, a nick is made in the pia mater in the centre of the convolution, a small elevator is then inserted (Fig. 594) and the membrane incised with a knife. The pia mater is gently rolled back to the edges of the sulcus; this can conveniently be performed with pledgets of cotton-wool soaked in saline (Fig. 595, A). The requisite amount of convolution is now removed with a brain spoon, the surgeon keeping inside the pia mater

(Fig. 595, B). This operation on the cerebral cortex is quite bloodless, and the dura mater is replaced and the osteoplastic flap sutured in position.

Hernia Cerebri.

By hernia cerebri is meant a protrusion of the brain substance through an *acquired* opening in the skull. It thus differs from an

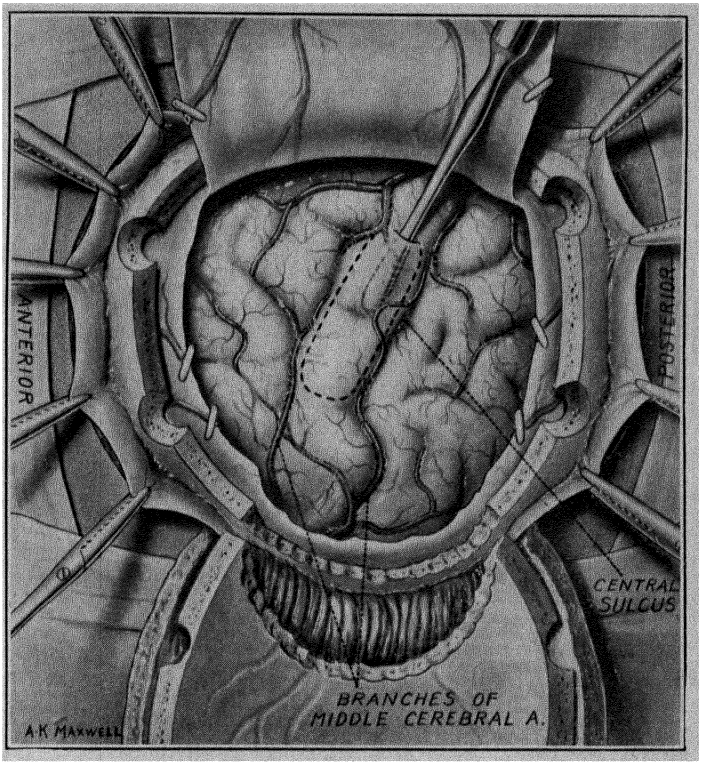

FIG. 594.—OPERATION FOR FOCAL EPILEPSY.

(The exact portion of the convolution is determined and the pia mater is raised on an elevator.)

encephalocele, which consists in the protrusion of brain substance through some *congenital* defect.

It is always an evidence of increased intracranial pressure, and may be looked upon as Nature's safety-valve for the relief of compression. It is met with in two distinct forms:

1. When a decompression operation has been performed for a cerebral tumour. The brain substance protrudes through the opening under the scalp, and by this means a temporary relief of intracranial

tension is brought about, the patient's life prolonged, and possibly consciousness restored for a time. The tumour, however, continues growing, and sooner or later the patient dies comatose, unless the tumour is inflammatory and disappears.

Hernia of the brain due to decompression for removal of a cerebral tumour is rarely seen to-day, owing to the fact that deep X-ray therapy after operation prevents its occurrence.

2. The other variety, due to a compound depressed or punctured fracture, is the result of infection in the underlying brain substance, and the increased pressure within the skull thereby induced leads to a protrusion of inflamed and œdematous cerebral tissue through the wound in the dura, which is usually of small size. The tumour is soft and dusky in colour, and pulsates synchronously with the heart, the pulsations being often evident to the naked eye, and it usually increases

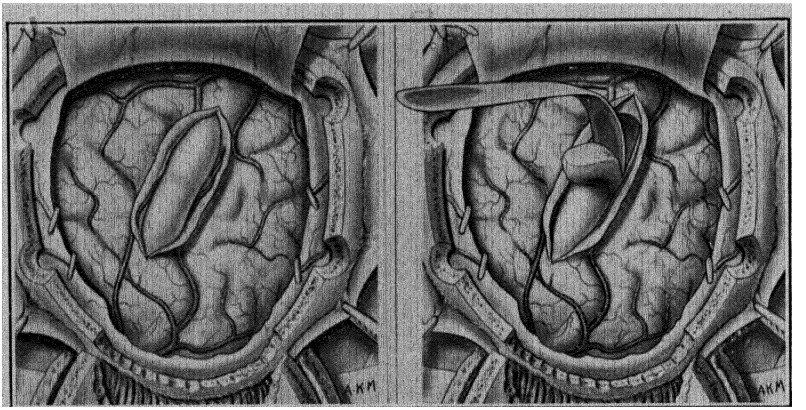

FIG. 595.—OPERATION FOR FOCAL EPILEPSY

A, The convolution is denuded of pia mater; B, the convolution is removed with a small brain spoon

in size somewhat rapidly. At first the mental condition of the patient is unimpaired, but sooner or later coma follows, if the hernia progresses, ending in the patient's death. To begin with, the mass consists mainly of œdematous granulation tissue covered by blood-clot, without much brain substance, but later on cerebral tissue itself may protrude. The condition is usually recovered from with care, but the patient has an adherent cicatrix, and is always liable to develop evidences of cerebral instability, epilepsy or insanity. In spite of this he may remain fairly well, if the original hernia did not involve the lateral ventricle, if this cavity or any of its prolongations is laid open and invaded by sepsis, inflammatory troubles are certain to supervene without much delay in spite of temporary healing. Within two years all such patients are likely to die of septic encephalitis.

Treatment.—Prevention of this affection must always be aimed at by endeavouring to render any wound involving the meninges aseptic

and providing for relief of tension. Punctured wounds and depressed fractures of the skull, even when giving rise to no urgent symptoms, should always be operated upon, since freedom from tension may prevent the formation of a hernia cerebri, even should absolute asepsis not be attained. If, however, a hernia has developed, treatment consists in the application of wet gauze packs soaked in hypertonic saline solution, or in glycerine and formalin (2 per cent.), with the object of providing an escape for the fluid from the œdematous hernia; dry dressings are always undesirable. Gentle pressure is useful, and lumbar puncture is sometimes helpful. Under no circumstances should any attempt be made to slice away the mass. After a time, and sometimes quite suddenly, the condition begins to improve; the hernia diminishes in size, and the wound granulates over and heals, leaving, however, an adherent cicatrix.

CHAPTER XXVIII.

AFFECTIONS OF THE LIPS AND JAWS.

Affections of the Lips.

Hare-Lip.—By hare-lip is meant a congenital fissure of the upper lip, which may extend for a variable distance through the soft tissues



FIG 596.—SINGLE HARE-LIP WITH BUT LITTLE INVOLVEMENT OF THE ALVEOLUS, AND HENCE SLIGHT DEFORMITY OF NOSE



FIG 597.—SINGLE HARE-LIP AND COMPLETE CLEFT OF ALVEOLUS AND PALATE WITH GREAT NASAL DEFORMITY.

alone, or may also implicate the bony alveolus and the floor of the nose, and extend backwards through the palate. The name is not



A B

FIG. 598.—DOUBLE COMPLETE HARE-LIP, WITH DISPLACEMENT FORWARDS OF THE CENTRAL PORTION OF THE INTERMAXILLA (OS INCISIVUM).

A, Front view; B, seen in profile.

a good one, since a hare's lip is cleft in a Y-shaped manner, the fissure being central below, and bifurcating above into each nostril.

Varieties.—A hare-lip is *complete* or *incomplete*, according to whether or not it extends into the nostril. It is termed *simple* (Fig. 596) if limited to the soft parts; *alveolar*, if the bony alveolus is also involved, *complicated*, if associated with a cleft palate (Fig. 597). The defect may exist on one or both sides of the middle line; if *unilateral* or single, it is most common on the left side, in the proportion of two to one; if double or *bilateral*, it is usually, but not invariably, alveolar, and accompanied by a complete cleft of the palate. The central portions of the lip and alveolus (os incisivum) may retain either their normal position, or, as is more frequently the case in the bilateral type, project

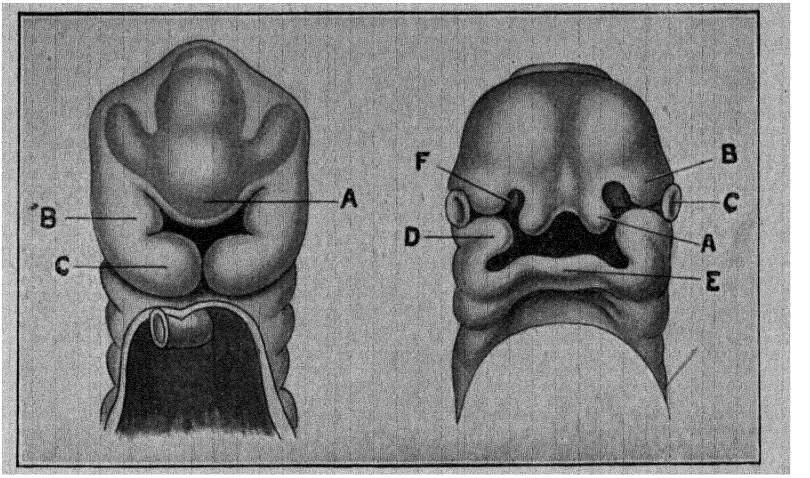

FIG. 599.—HEAD OF FŒTUS OF ABOUT FIVE WEEKS, FROM VENTRAL ASPECT (AFTER HIS), SHOWING THE PRIMITIVE STOMODÆUM BOUNDED ABOVE BY (A) THE UNDIVIDED FRONTO-NASAL PROCESS, LATERALLY BY (B) THE MAXILLARY, AND BELOW BY (C) THE STILL SEPARATE MANDIBULAR PROCESSES

The quinque-radiate appearance is well represented.

FIG. 600.—HEAD OF FŒTUS OF SIX TO SEVEN WEEKS, FROM THE VENTRAL ASPECT. (AFTER HIS)

The mandibular processes (E) have now united; the ocular vesicle (C) is seen on either side towards the upper end of the orbito-nasal fissure, and the fronto-nasal process has developed (A) internal and (B) external nasal processes on either side of (F) the still unclosed anterior nares; (D) maxillary process.

forwards at the end of the nose, forming a proboscis-like appendage (Fig. 598, A and B); its base of support is often thin and elongated, so that lateral mobility may be obtained. Even in simple cases the nose is deformed, being broad and flattened, a condition which becomes much more marked when the alveolus and floor of the nose are widely fissured. Hare-lip is not uncommonly associated with other deformities, *e.g.* spina bifida and talipes, and it is frequently transmitted from one generation to another. Occasionally a thin red line, as of a cicatrix, is seen occupying the position of a hare-lip cleft, and is probably due to a persistence of the raphe of union of the labial segments, a slight

groove in the alveolus may also be observed at a corresponding point.

Development.—The bony and fleshy parts of the face originate from the outgrowth of processes around the cavity formed by the bending forward of the primitive cerebral vesicle over the end of the notochord. At about five weeks after conception the primitive buccal cavity or stomodæum has a quinque-radiate appearance, due to the manner in which these processes are formed (Fig. 599). A broad median lappet (fronto-nasal process, A) descends from above; this is separated by a fissure on each side from the symmetrically placed maxillary processes (B), and these again below from the more prominent mandibular processes (C), which early unite across the middle line, to form the lower jaw. The fronto-nasal process soon, however, changes. On either side of a slight depression in the median line is placed the internal nasal process or globular process (Fig. 600, A), from which are produced superficially the central portion of the upper lip, and from its deeper aspect the intermaxilla, which divides into the two incisive segments, each carrying the germ of an incisor tooth. Separated from this by a hollow (F), which subsequently forms the anterior nares, is the rounded external nasal process (B), from which develop the side of the cheek and the ala nasi. External to this a fissure (naso-orbital) runs up to, and even beyond, the primitive eye (C), and this is later on closed by amalgamation of the internal and external nasal processes on the inner side with the adjacent maxillary process on the outer (D), except in the deepest part, which constitutes the nasal duct. The integrity of the upper lip is obtained by the union of the lower parts of the internal nasal and maxillary processes, which thus exclude the external nasal from participation in its free border. It is doubtless owing to this arrangement that the sulcus or depression around the ala nasi constitutes such a distinct and characteristic feature of the face. At the same time the deeper parts of these nasal processes are uniting with one another and with the palatal plates, which grow horizontally inwards from the under side of the maxillary processes, uniting in a Y-shaped suture, the point of junction of the limbs being situated at the anterior palatine canal. The union of all these elements is taking place from the sixth to the tenth week, and by that date even the uvula, the last part to unite, should be complete.

Ordinary hare-lip is due to a failure of union of the internal nasal process with the structures in external relation with it; if limited to the soft parts (simple hare-lip), the cleft runs between the internal nasal and maxillary processes; if complete or alveolar, between the same two below and superficially, but in addition between the internal and external nasal processes above and on the deep side. The cleft in the alveolus passes between the intermaxilla and the maxilla (Fig. 601). The relation of the cleft to the teeth varies somewhat, since the germ of the lateral incisor may be developed on one or other side of the suture between the maxilla and intermaxilla, or may even lie between the segments. Hence the lateral incisor is sometimes found on the outer side of the cleft, sometimes on the inner; moreover, an accessory incisor is occasionally developed on the inner side of the cleft.

The os incisivum, or projecting portion of the intermaxilla, usually consists of two segments of bone, united in the median line, and in a child most frequently contains only the two milk central incisors and the rudiments of the two permanent ones; occasionally, as we have just stated, there may be an extra tooth developed on one or both sides of the process.

A simple hare-lip does not interfere seriously with the infant's nutrition, but when double, and especially if associated with a cleft palate, considerable trouble may arise, thus necessitating surgical treatment as a life-saving measure at a very early date. It must also be remembered that all movements of the face, *e.g.* in crying or laughing, exaggerate the deformity from the unbalanced action of the divided orbicularis oris and other muscles.

The period at which to operate is open to discussion; as a rule, especially in unilateral cases, it is best to wait until the third month. The parts are larger and the operation easier, and the infant more adjusted to a separate existence, with a consequent decrease in mortality from post-operative infections to which all infants are liable. In bilateral cases, if the infant cannot suckle, the operation can be carried out during the first week of life.

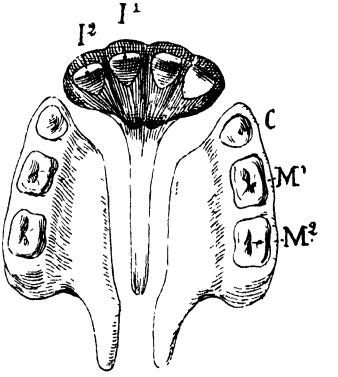

FIG. 601.—DIAGRAM TO REPRESENT THE SITUATION OF THE CLEFT IN ALVEOLAR HARE-LIP

I¹, I², Incisors; C, canine tooth; M¹, M², first and second molars

Operation for Single Hare-Lip.—The child should be laid on an operating-table with its arms bound to the body. The surgeon stands behind it, the anæsthetist and assistant one on each side. The operation may be described in three stages:

1. The *lip* is thoroughly *dissected up from the maxillæ* and alveoli by cutting through the reflections of mucous membrane and the attachment of the muscles and other soft parts. This is mainly needed on the outer side, and where there is much flattening of the nose the ala nasi will also require to be separated. This may cause some amount of bleeding, but sponge pressure easily controls it.

2. The *edges of the cleft* are then *pared*. The object to be attained is the union of the cleft lip by means of a cicatrix, which shall be as unobtrusive as possible, whilst the red margin must be continuous, and the section such that the raw surfaces are larger than are absolutely necessary, so as to allow for subsequent cicatricial contraction without the development of a notch. Two of the best methods are as follows:

(*a*) The incision extends from the apex of the cleft, or from within the nostril, in a crescentic manner (Fig. 602) on each side, and where the nose is much flattened more tissue is removed on the outer than

on the inner, so that when the parts are sutured together the nostrils become as nearly as possible symmetrical. By this means the depth of the lip is increased to allow of subsequent contraction, whilst the red margin can be made continuous.

(*b*) *Mirault's Operation* (Fig. 603).—The inner margin and apex of the cleft are pared, so as to leave a raw surface; a flap of red marginal tissue, as thick as possible, is then cut from the outer side, and implanted

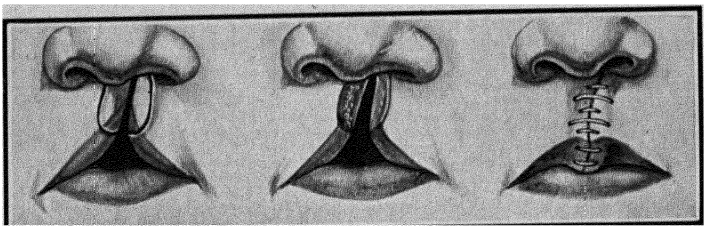

FIG 602.—ROSE'S OPERATION FOR SINGLE HARE-LIP

On the left side the semilunar incisions are seen extending as far as the free borders of the lip. The right-hand figure shows the parts drawn into position, the cross-lines represent the catgut or horsehair stitches

on the bevelled raw surface of the red margin on the inner side, the upper portions of the cleft being also apposed.

3. *Sutures* are now inserted to maintain the lip in the position into which it can be drawn by the fingers without tension. Two deep silver-wire sutures should be introduced, one just above the red margin, and one close to the nose, to draw into position and steady the nostril,

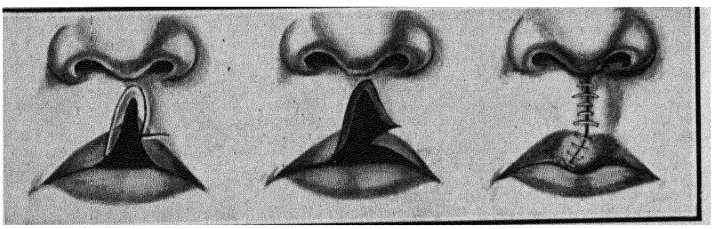

FIG 603.—MIRAULT'S OPERATION FOR HARE-LIP

The formation of the prolabial flap is shown ready to be implanted on the prepared inner side

which should be left smaller than that on the other side, so as to allow for subsequent dilatation, which is certain to occur. Horsehair or catgut stitches are used to bring the exact margins together, the continuity of the muco-cutaneous line being accurately preserved, and the cut edges of the mucous membrane upon the deeper aspect being sutured, each stitch, after it is tightened, being used to elevate and evert the lip, and thus assist the insertion of the next. The wound

is dressed with a small piece of gauze, and secured by another dry piece cut in the shape of a butterfly, so that the narrow body shall fit over the lip, and the wings spread over the cheeks; this is fixed by collodion, and maintained for some days after the stitches are removed, the deep ones on the fourth day and the superficial ones about the eighth or tenth. Careful feeding by spoon is necessary, the mother's milk being drawn off and given in this way if possible. In simple cases the child may be returned to the breast about the fifth day. In order to prevent the child from picking at the lip or disturbing the dressing, it is well to put a splint on the flexor side of each arm to control the elbow-joint.

The **Treatment of Double Hare-lip** may be discussed under two headings, *viz.* the treatment of the os incisivum, and that of the soft parts.

The os incisivum need not be touched if it retains its normal position and the labial clefts are then alone dealt with, but if it projects forwards, as is often the case, it must be either removed, replaced, or reduced in



FIG. 604.—ROSE'S OPERATION FOR DOUBLE HARE-LIP

The central tubercle is pared in a V-shaped manner, and the lateral segments by curved incisions, extending to the red margin, and then inwards. Only the apex of the central portion is included in the completed lip.

size. (*a*) In bad cases where there is much projection the process must be removed. The central portion of the upper lip is freed from it by dissection, and the base of the process divided with cutting-pliers; a small artery in the bone will spurt vigorously, and may need an application of the cautery to stop it. The operation on the lip is deferred till ten days later. A certain amount of deformity from dropping back of the upper lip is certain to result, but can be in measure obviated by adding a projecting cheek-plate to that which carries the artificial incisors. (*b*) Reposition may be effected by several methods, the best of which is Bardeleben's, who incises the lower border of the septum, strips off the muco-periosteum from either side, and then bends or breaks the bone back into position, fixing it by silver wires, and uniting the lip at once to form a splint to maintain it *in situ*. The advantages claimed for reposition are that the patient retains his own central incisor teeth, and that the normal contour of the jaw and face is not interfered with. Against this plan, however, must be placed the facts that the bone rarely becomes firmly united, that the teeth are

stunted and erupt obliquely backwards from rotation of the process, and that its presence prevents the maxillæ from falling together and increases the difficulties of subsequently closing the palatal cleft. By dividing the septum parallel to the plane of the palate, the process can be slid back, and its rotation is thereby avoided. (*c*) Where, however, the projection is not great, the size of the os incisivum can be lessened by gouging out the teeth contained within it, so that the lip can be closed over it.

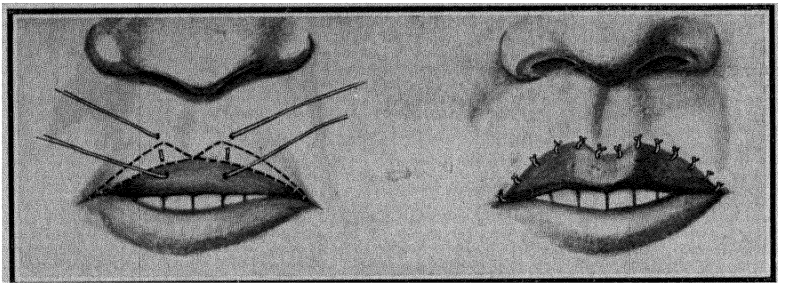

FIG. 605.—GILLIES' OPERATION FOR THE FORMATION OF CUPID'S BOW

The soft parts of the lip are dealt with in much the same way as in single hare-lip. They are freely detached from the maxillæ, and the edges pared, as shown in Fig. 604, the central portion being cut into a **V**, and no attempt made to incorporate it into the free margin for fear of depressing the tip of the nose, whilst the lateral segments are pared as in the single operation. These latter are now drawn together and united in the middle line below the central portion, so that a **Y**-shaped cicatrix results. One of the stitches should fix the apex of the **V**; the other should be inserted just above the red margin. The dressing and after-treatment are as in the single operation. For a time the child may have difficulty in breathing owing to the diminution in the size of the oral aperture, but this is obviated by the nurse drawing down the lower lip with the fingers.



FIG. 606.—MEDIAN HARE-LIP

Although this operation gives excellent results, the upper lip is often straight with very little mucous membrane showing. In these cases the Cupid's bow operation devised by Gillies gives excellent results, as can be seen in Fig. 605. This operation is performed some ten years or more after the original one.

Median Hare-lip may occur in one of two forms: either a simple cleft exists in the middle line (Fig. 606), or there may be an absence of the intermaxilla and nasal septum, causing flattening of the bridge of the nose, and a broad median defect, flanked by the maxillary portions of the lip.

Oblique Facial Cleft is an uncommon deformity, characterized by a

cleft or sulcus in the face, starting from the usual situation of a hare-lip below, but running up outside the nostril to the inner side of the lower lid (Fig. 607). Coloboma of the iris or choroid is sometimes associated with this rare defect. The deformity is due to non-closure of the naso-orbital fissure, and runs along the line of the nasal duct. It may be limited to the soft parts, or may involve the bones, even laying open the antrum.

Macrostoma (Fig. 608) is characterized by an abnormal width of the mouth, and is due to non-union of the maxillary and mandibular processes. It may be uni- or bi-lateral, and is usually associated with anomalies of development of the ear, accessory auricles being often present. As a rule, a small papilla on the upper and lower margins



FIG. 607.—OBLIQUE FACIAL CLEFT, OR, RATHER, CICATRICIAL DEFORMITY ALONG THE LINE USUALLY TRAVERSED BY SUCH A CLEFT.



FIG. 608.—MACROSTOMA WITH AURICULAR APPENDAGES.

points of attachment of the orbicularis. The existence of these is of great importance as indicating the extent to which the cleft must be pared in order to restore the mouth to its normal size.

Mandibular Clefts are exceedingly rare. They are due to non-union of the mandibular processes in the middle line, and involve either the soft tissues of the lower lip alone, or may extend to the bone, and even the tongue. Treatment is as for ordinary hare-lip.

Microstoma is the term applied to a condition in which the fusion of the parts entering into the formation of the lips progresses to a greater extent than usual, so that the oral orifice is contracted. It may be associated with defective development of the lower jaw. In the more severe cases, where the mouth is extremely narrowed, a transverse cut should be made outwards on each side, and the mucous membrane stitched to the skin.

Macrocheilia, or hypertrophy of the lip, occurs in three forms: (1) The congenital variety, a condition analogous to macroglossia, and due to a congenital distension of the lymphatic spaces, or chronic lymphangiectasis accompanied by overgrowth of the connective tissue. The lower lip is most often involved, and is firm, thickened, and everted, causing considerable deformity. The treatment consists in the removal of a V-shaped portion from the centre. (2) An acquired form occurs in children and young people with a tuberculous inheritance, constituting the so-called 'strumous lip.' Either lip may be affected, but perhaps more frequently the upper; the thickening is due to a chronic lymphangitis, resulting from the absorption of toxic material from persistent cracks and fissures. If these can be healed, and the general health improved, diminution in the size of the lip soon follows. (3) In adults, macrocheilia is in almost all cases due to tertiary syphilis.



FIG. 609.- CHANCRE OF UPPER LIP.
The enlargement of the submaxillary lymphatic glands is very evident.



FIG. 610.—CHANCRE OF LOWER LIP.
The submaxillary lymph glands are enlarged.

The lower lip is most often enlarged, and becomes thick and hard. It is due to the diffuse sclerosis characteristic of tertiary mischief. General treatment, and not local, is needed.

Syphilitic Affections of the lip are not uncommon. A *primary* chancre may be caused by kissing, or by smoking an infected pipe, or drinking from a glass with an infected rim. It usually presents a smooth ulcerated surface, discharging a small amount of sero-pus, resting on a mass of infiltrated tissue which may extend over the whole lip (Fig. 609). The induration is not so great as in chancres upon the genital organs, but the infiltration is much more extensive. Enlargement of the submaxillary lymphatic glands occurs very early, and the disease usually runs an active course. A labial chancre may closely resemble epithelioma, but is distinguished from it by its rapid development up to a certain point, by the early implication of the glands,

which soon become very large, by the positive Wassermann reaction, by the age of the patient, and the course taken by the case, as well as by the local appearances (Fig. 610). The surface is usually flattened, and less warty and irregular than in epithelioma, whilst the skin is more involved than the mucous membrane. Moreover, it is more common on the upper lip, whilst epithelioma is usually seen on the lower (compare Figs. 612 and 613). In the *secondary* stage mucous tubercles are frequently met with, involving the inner side of the lip and the angle of the mouth. In the *tertiary* period serpiginous ulceration and gummata may occur, or the diffuse induration described above. In *inherited* syphilis, cracks and mucous tubercles are constantly present, and may be so extensive as to leave cicatrices radiating from the mouth, which are very characteristic (Fig. 52, p. 165).

Cracked Lips (or, as they are often called, *chapped lips*) are usually the result of cold weather, a central crack or fissure forming which is extremely painful, and liable to bleed very readily on everting or stretching the part. The lower lip is that generally affected. In tuberculous children more than one may occur, and by their persistence they give rise to a considerable degree of induration and infiltration, and perhaps lead to glandular trouble. All that is needed in the shape of *treatment* is the application of a little lanoline or cold cream, but if they persist, it may be advisable to touch them with nitrate of silver.

Herpes Labialis is a condition usually associated with catarrh, and not unfrequently with pneumonia or other fevers. Either lip may be affected, and the herpetic eruption is quite limited in extent. It consists of a number of little vesicles situated on a hyperæmic and painful base; after a few days the vesicles become transformed into pustules, and these in turn burst and dry up, the whole affection lasting perhaps a week or ten days. No special treatment is required. If the inner aspect of the lip is affected, the epithelium early becomes sodden and is shed, so that the vesicular stage is much shorter.

Mucous Cysts occur on the inner side of the lip in the form of small rounded swellings, which are translucent and contain a glairy fluid. They are often due to trauma, whereby the opening of a mucous gland is blocked. The whole cyst wall should be dissected out, and the wound closed by stitches.

Nævi are frequently met with in the lip. If confined to the inner aspect they may be dissected out, but when large and involving the whole thickness, they should be dealt with by electrolysis.

Warty Growths are often seen on the lower lip, especially near the angle, and may then simulate epithelioma. They are distinguished, however, by the fact that ulceration is not often present, that the lymphatic glands are not involved, and that there is but little infiltration of the base (Fig. 611). They should, however, be removed as early as possible, since malignant disease often starts from them.

Epithelioma of the lip usually occurs in men of the working classes, and is commonly due to the irritation produced by smoking a short clay pipe, which is allowed to rest on one or the other side near the

angle. A semicircular notch will frequently be noticed in the teeth of the upper and lower jaw, corresponding to the situation of the growth on the lip, and caused by the constant friction of the pipe-stem. It may also start opposite the site of some projecting rough or carious tooth. It is but rarely met with in women, occurring in England in not more than 5 to 6 per cent. of the cases, and probably most of these are clay-pipe smokers. It is certainly more common amongst country folk, who use the short clay pipe, than amongst the cigarette and cigar smokers in towns.



FIG 611.—PAPILLOMA OF UPPER LIP.

The disease may start as an induration around a crack or fissure, which gradually extends, forming a typical malignant ulcer; or as a wart-like growth, which fungates and ulcerates; or as a chronic infiltration leading to an irregular nodulated thickening of the lip, which sometimes looks shrunken and feels sclerosed (Fig. 612). Occasionally it develops at the angle of the mouth, and then involves both lips (Fig. 613).

Unchecked by treatment, the disease steadily progresses, forming an ulcerated mass of greater or less size, and even involves the jaw. The submental and submaxillary glands are early implicated, as also the glands which accompany the carotid vessels. Beyond this, however, the disease rarely extends, visceral complications being uncommon. Death is generally caused by the secondary growths in the neck, which attain considerable dimensions and then ulcerate, this stage being possibly preceded by one of cystic degeneration. From these ulcerating surfaces a quantity of discharge escapes, the amount varying with the septicity

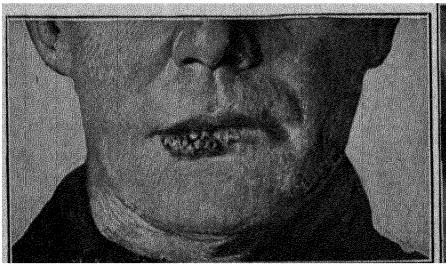

FIG. 612.—CHRONIC EPITHELIOMA OF LOWER LIP.



FIG. 613.—EPITHELIOMA OF ANGLE OF MOUTH INVOLVING BOTH LIPS

or not of the wounds. Intense pain is caused by implication of nerves, and hæmorrhage from the vessels in the neck is likely to follow.

The **Diagnosis** of epithelioma is rarely doubtful, but occasionally warty growths, or even a primary chancre, may be mistaken for it. The clinical history generally suffices to determine the nature of the mass,

as also the character of the base and the appearance of the parts; but in uncertain cases the removal of a small portion of the edge under local anæsthesia, and its microscopic examination, are required to set doubts at rest.

Treatment.—The treatment of epithelioma of the lip may be by excision or by radium. Radium is the method of choice and will be described first. Interstitial radium should be used; a palisade of needles should be placed deep in the growth and left in position for several days, the dosage in milligramme hours depending on the size of the lesion. As in carcinoma of the tongue, all metal fillings in the teeth and any bridgework must first be removed and oral sepsis treated prior to radiation. Where possible the needles should be prevented from coming into contact with the jaw for fear of necrosis, with subsequent sequestrum formation; in advanced cases this is a counsel of perfection, as the jaw may be extensively involved.

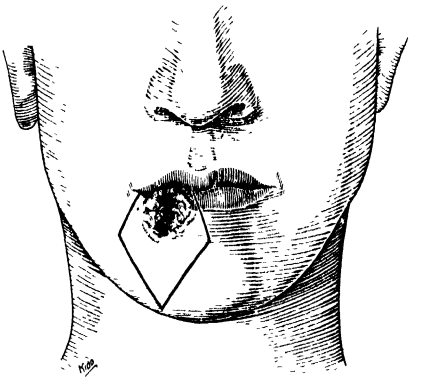

FIG. 614.—INCISIONS FOR REMOVAL OF EPITHELIOMA OF LIP.

The results with radium are excellent, small ulcers healing up completely, and even in the late case, with extensive destruction, a degree of healing is achieved that at first sight might seem impossible. Treatment of the glandular area in the neck may be by X-ray therapy or by radium with a Sorbo or Columbia paste collar, similar to the method employed in carcinoma of the tongue. Glandular spread in carcinoma of the lip is much less frequent than in carcinoma of the tongue, and in early cases it may be justifiable to keep the patient under observation only following treatment of the primary growth if there are no palpable glands, and give treatment later if need arises. All cases with palpable secondaries should have radiation. Distant metastases are extremely rare.

Surgical treatment consists in the removal of the primary growth with the submental submaxillary and deep cervical glands where there is any evidence of secondary lymphatic involvement. As already explained, it is justifiable where there are no palpable glands to adopt an expectant attitude to them. The primary growth must be excised widely (Fig. 614); this may be done either with the scalpel or the diathermy knife. The operations, such as Syme's for the removal of the whole lower lip, are no longer performed. The deformity following excision is much greater than that produced with radium and the result no better.

Affections of the Teeth.

Dental Sepsis.—Allusion has already been made (p. 57) to the important part played by this condition in the production of many forms of general poisoning of the system of the so-called rheumatic type, and in the genesis of various inflammatory conditions of the intestinal track and its adnexa. Streptococci are normal inhabitants of the mouth, and these, together with various diphtheroids, are probably responsible for most of these lesions; staphylococci are not often present. Doctors and dentists must co-operate in dealing with these affections, which play such an important part in the health of the community.

There are two main sources of absorption in connection with the teeth, *viz.* the apices and the gums.

1. **Peri-apical infections** occur in about half the cases. The sequence of events is usually as follows: The pulp cavity of the tooth becomes infected as a result of the extension of dental caries from the surface; acute inflammatory phenomena of a purulent type, accompanied by severe toothache, end in necrossi of the pulp, and when effective drainage is not provided, in escape of bacteria through the apical foramen. Inflammation is hereby caused, and may result in the formation of a gumboil (Fig. 616), with relief to the pain and tension. If no gumboil forms, the process may quiet down, but an encapsuled focus remains at the apex of the tooth. If the peri-apical trouble is chronic from the first, a granulomatous nodule forms, or a small cavity lined with granulation tissue results, or the bone itself is invaded, and possibly a localized necrosis follows. From any of these local lesions general absorption may occur. The affected tooth may or may not be tender on pressure; the pulp cavity may have been filled, and yet mischief may be present, as some tiny septic focus near the apex may have been overlooked, and thus the filling may have done harm rather than good.

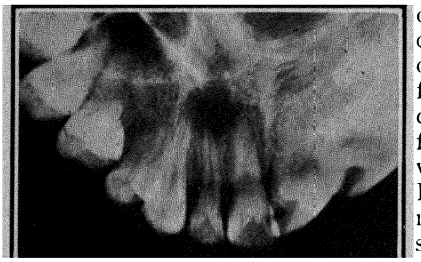

FIG. 615.—SKIAGRAM SHOWING APICAL ABSCESSES IN CONNECTION WITH TEETH.

X-ray examination in all such cases is an essential element in diagnosis, and the interpretation of such radiographs by an expert is very necessary, since many pitfalls exist for the inexperienced (Fig. 615). A definite cavity or focus of necrosis around the apex of a tooth is fairly easy to recognize; but the mere existence of alveolar absorption around teeth, especially in those past middle life, must not be looked on as necessarily dangerous or requiring extraction.

The wholesale removal of teeth for chronic rheumatism in the hope of thereby eliminating some undiscovered focus of septic absorption is wholly unjustified, and has been carried to such length as to be a disgrace to the profession. Each tooth should be separately

studied, and only condemned to removal if definite disease can be detected, or if a tooth has been under suspicion for some time and the patient's condition has not improved in the interval in spite of approved curative treatment. The question of removing all diseased teeth at a sitting, or only a few at a time, must be decided by the patient's age and general condition. The recuperative power of those over fifty years of age is not so good as in younger subjects, and it is wise to go cautiously with them, taking out only a few teeth at a sitting. When the general condition is decidedly bad, it is wise to examine the blood before operating, as, if a leucopenia exists, removal of even only a few teeth may be dangerous; possibly they would then have to be dealt with one by one.

2. **Gingivitis,** more or less generalized, and of a suppurative or ulcerative type, is another common source of streptococcal infection. The process often starts as a result of defective cleanliness, leading to the retention of food débris between the gums and the teeth, or in the interdental spaces. Decomposition ensues, especially during the night, and inflammation is caused. The gum margin becomes hyperæmic and swollen, bleeding easily on pressure, and ulceration may occur on the inner or dental aspect, and from these denuded surfaces absorption can take place. Diseases such as scurvy, or the injudicious administration of mercury, may assist in the development of this process. The teeth become loosened, and the infection may spread along the periodontal membrane until possibly the teeth fall out; necrosis of the alveolar margins may ensue, or the suppurative process may pocket around the teeth, and finally constitute a condition of pyorrhœa alveolaris (p. 959).

It is obviously most important that all children should be carefully instructed in the correct use of tooth-brushes, as well as in the hygiene of the mouth. Cleansing the mouth and teeth after meals, and especially at night, should constitute part of the routine life of children, and by the observation of a few simple rules such as this much sickness could be prevented.

Alveolar Abscess (Fig. 616) is almost always associated with suppuration around the fang of a carious tooth, the bacteria finding their way out of the pulp chamber through the apical foramen. The alveolar walls become expanded, and the pus either finds its way over the edge of the bone, or even through the osseous tissue under the external periosteum. If limited in extent, it perforates the gum directly, and is then known as a *gumboil*; but occasionally it burrows beneath the periosteum, which is stripped from the bone, and may thus lead to an abscess of larger size, possibly resulting in necrosis of the jaw. The formation of an alveolar abscess is almost always associated with considerable œdema of the face, and pain of a serious character, and when extensive may give rise to marked constitutional disturbance. Sometimes graver complications ensue; thus, in the upper jaw the antrum may be opened, and suppuration in this cavity follow, whilst in the lower the abscess may travel downwards and burst externally, either close to the lower margin of the bone or in the neck. A troublesome sinus results, which can only be cured by the removal of the tooth,

and even then a depressed and adherent cicatrix ensues, which is very unsightly. The most essential point in the *treatment* necessarily consists in the removal of the offending tooth. Often this is quite sufficient, and possibly the tooth may come away with an abscess cavity attached to one of the fangs. When suppuration occurs beneath the periosteum, the pain can at first be relieved in measure by fomentations, but as soon as fluctuation is detected a free incision should be made, if possible, through the gum, and the cavity emptied. Possibly it may be wise to keep a small piece of rubber glove in for a few hours, but if a large enough opening has been made, all that is subsequently needed is repeated and frequent irrigation, preferably with peroxide of hydrogen. When the skin is thinned and the cheek red, an external incision is usually required, and sometimes this may have to be undertaken as a preliminary, the extraction of the tooth being left until the swelling has somewhat subsided. If a sinus persists after removal of the tooth, it must be opened up, and any carious or necrosed bone taken away. Not unfrequently the masseter becomes infiltrated and sclerosed when the lower jaw is affected, and difficulty in opening the mouth may result.

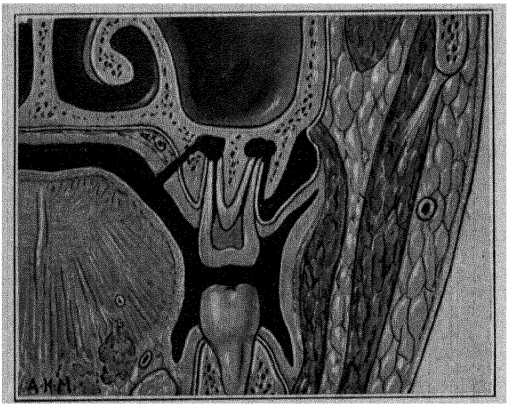

FIG. 616.—DIAGRAM OF ALVEOLAR ABSCESS RESULTING FROM DISEASE OF MOLAR TOOTH.

The spread of septic material in two directions is here shown. In one the swelling forms beneath the gum from the offending tooth. In the other the spread has been medial and has burst through the palate.

Dental Cysts are by no means uncommon, resulting from the irritative effects of dental caries; hence they follow the distribution of that affection, and are most frequently seen in connection with the upper first molars and bicuspids (Fig. 617). They develop at the roots of the teeth, causing a painless regular expansion of the bone, free from inflammatory phenomena, unless infected secondarily with bacteria. After a time the centre of the swelling softens, and, as the bony wall is absorbed, parchment-like crackling can be felt; finally, the condition presents as a rounded, tense, elastic swelling, around the margins of which the remains of the expanded bone can be detected. In the upper jaw they often encroach on and project into the bony antral cavity, pushing the mucous membrane in front of it. The tooth which is the cause of the trouble is always dead, and frequently merely a septic root is present.

The *cause* of these cysts is probably the proliferation of certain embryonic remains of the enamel organ, brought about by the irrita-

tion of toxic matter which has escaped from the pulp cavity. These fœtal residues are lighted up into activity, developing into masses or columns of epithelial tissue, which undergo cystic degeneration. Their pathogenesis is practically identical with that of the epithelial odontome (p. 198), but merely one cyst develops here instead of many. The fluid contained therein is thick and mucoid in character, and broken-down epithelial cells and cholesterine are seen in it on microscopical examination.

Treatment.—The cyst must be laid freely open into the mouth, the septic tooth or stump removed, and the anterior wall of its alveolus cut away. The alveolus and cyst thus laid into one cavity are scraped so as to remove all the epithelial lining, and packed with gauze so as to ensure healing by granulation In the upper jaw the utmost gentleness is required in dealing with the deeper wall of the cyst, as the septum between it and the antral cavity may be extremely thin and entirely devoid of bony tissue.

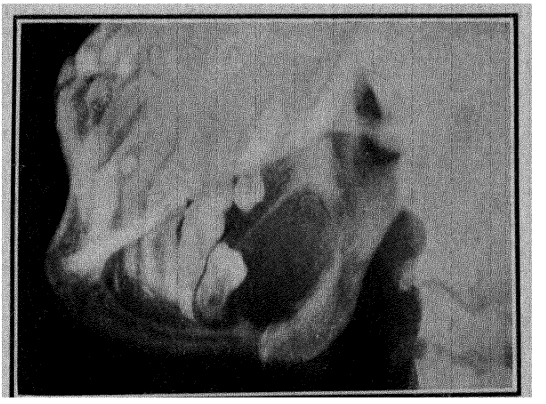

FIG. 617.—LARGE DENTAL CYST IN LOWER JAW.

Odontomata or tumours connected with the teeth are described elsewhere (p. 198).

The Extraction of Teeth.—Although this operation is usually undertaken by dentists, yet surgeons and medical practitioners have not unfrequently to perform it, and not a little skill and judgment are sometimes needed in its execution. An anæsthetic may or may not be employed. If merely one or two teeth are to be drawn, gas or chloride of ethyl will suffice; but when a large number require extraction at one sitting, it is better to give ether or the C.E. mixture; chloroform should never be administered when the patient is in the sitting position. The posterior teeth are, of course, dealt with first, and subsequently those in front. Suitable forceps are required for the various teeth, and the number of fangs belonging to each must be kept in mind. Incisor and canine teeth are removed by a combination of traction and rotation; the bicuspids and molars by traction combined with lateral movement, especially inwards. The forceps, after being sterilized, should be pushed well up under the gum, and no traction made until a firm grasp has been taken of the neck of the tooth, and the tooth itself loosened by lateral swaying.

Accidents of various types happen from time to time. The crown may break away, leaving the fangs *in situ*, and then each of these must be sought with root forceps and accounted for. In dealing with the first or second upper molar, it is quite possible to drive a fang upwards

into the antral cavity, setting up thereby acute suppuration within the cavity. Laceration of the gum is often unavoidable, and injury to the alveolar margin may follow; but such accidents as fracture or dislocation of the lower jaw are certainly avoidable. The use of an elevator is sometimes desirable in order to remove old roots, but it is an instrument that must be used with great care.

After extraction the mouth is washed out with sterilized or carbolized water, and the bleeding usually ceases without delay. If the gum has been much torn, it should be pressed back into position by the fingers, and when the mouth is dirty it may be desirable to touch the socket over with tincture of iodine. A mouth-wash of boric acid or sanitas is subsequently employed.

Should the *hæmorrhage* continue, as in patients suffering from purpura, scurvy, and hæmophilia, the socket must be carefully plugged with a strip of gauze soaked in a styptic such as adrenalin or hæmoplastin; the use of perchloride of iron in this connection is undesirable. Plugging is frequently a difficult and unsatisfactory method; as an alternative the walls of the socket may be approximated with a catgut suture, which effectively prevents further bleeding. This method is obviously not applied where an abscess is draining through the socket. Occasionally the bleeding restarts after two or three days as a result of infection of the socket; it is then necessary to open up the cavity freely from the outer side, cutting away gum, and, if need be, bone, so as to allow free exit to discharges and a more ready access for strips of gauze soaked in styptics or antiseptics.

Wisdom Teeth are not an uncommon source of trouble, mainly by their abnormal eruption, both as to date and manner, and this chiefly owing to the reduction in the size of the jaws brought about by civilization. The most common condition is for the wisdom tooth to be wedged against the second molar in such a position that its eruption is impossible. Inflammatory phenomena usually follow, or trismus, and it becomes essential to relieve the condition. The offending tooth is generally so deeply buried that even under a general anæsthetic it is almost impossible to reach it, and the better treatment is to remove the second molar, when normal eruption may quickly follow, and the wisdom may be able to take on the work of the second molar. In the hands of a trained expert, however, it is usually possible to remove the offending third molar, leaving the second molar intact, an obvious advantage, as the more misplaced the wisdom tooth the less likely is it to benefit by the removal of the tooth in front. If it should come to the surface sufficiently to cause an opening in the gum, infection may occur and the removal of the offending tooth becomes essential. This may be very difficult, as it is often buried deeply and in part covered by the gum tissues. A sufficient opening in the gum must then be made, if necessary by cutting it away, so that the crown can be clearly seen. If forceps or elevator fail to effect its removal (and it is often very firmly fixed in the bone), it may be desirable to burr away the surrounding bone so as to set the tooth free. The greatest care must be taken to prevent infection of the surrounding tissues, or serious consequences may follow.

Affections of the Gums and Alveolar Processes.

Spongy or Inflamed Gums (gingivitis) are not unfrequently caused by a dirty and uncared-for condition of the teeth, the administration of mercury, or scurvy. A similar condition of the gums, especially in children, is found in acute leukæmia.

Pyorrhœa Alveolaris (or **Riggs' Disease**) consists in an inflammatory condition of the margins of the gums, accompanied by a purulent discharge, which arises from pockets or pouches which may extend a greater or less distance along the roots of the teeth. In the worst cases the gums are swollen and œdematous to such an extent that they often hide or partially cover the stumps of decayed teeth, and they bleed readily. The tongue is coated, and the breath exceedingly offensive. In less severe cases and in the later stages the tissues of the gums shrink, and, together with the alveolar border, become atrophic; the fangs are thereby uncovered and the teeth loosened, so that after a while a natural cure may be established by the patient becoming edentulous. The process is limited to a few teeth, or may involve many. It is generally preceded by an excessive deposit of tartar, beneath which bacterial infection occurs, the inflammation spreading down along the periodontal membrane, and perhaps extending to surrounding parts, *e.g.* the maxillary antrum. In most cases, on making pressure along the alveolar margins, a greater or less quantity of pus can be squeezed out. For the constitutional results of this *oral sepsis*, see p. 58.

Treatment must, in the first place, be directed to the teeth, and consists in the removal of tartar and the application of astringents and antiseptics, preferably peroxide of hydrogen, not only to the exposed mucous membrane, but also into the pouches and pockets where pus collects. In some cases it is wise to destroy the granulation tissue forming the outer wall of these pouches by means of the electric cautery, or even to remove the teeth. Too much must not be done at a time, as the general symptoms may be aggravated by an increased absorption of toxins, and the reparative activities of the patient may be very deficient. In resistant cases vaccine treatment may be desirable.

Hypertrophy of the Gums is met with in the form of a sessile overgrowth, sometimes almost cauliflower-like, around and between the teeth, which are usually carious; it occurs most frequently in children. In slight cases the overgrowth may be destroyed by the application of a crystal of trichloracetic acid; but in the more exaggerated types excision is required.

Epulis.—By this term is meant a tumour growing from the alveolar periosteum. Two varieties are described, *viz.* the simple and the myeloid.

A **Simple Epulis** is usually of a fibromatous nature, and may grow from either jaw, though more commonly from the lower. It is generally due to the irritation of diseased teeth, and although most marked on the outer aspect, it burrows between the teeth, and is also found on the inner side. It appears as a red fleshy mass, smooth or perhaps

lobulated (Fig. 618), of an elastic consistency, and possibly associated with a little superficial ulceration. It is covered with mucous membrane, and may contain a few spicules of bone. The *treatment* consists in removing the growth, together with the teeth or stumps with which it is connected. If small, it will suffice to cut away and scrape the bone from which it arises; but if large, or if it recurs after such treatment, the portion of the alveolus from which it springs must also be excised. This is best accomplished by extracting a tooth on either side of the tumour, and cutting vertically through each socket with a saw, the two incisions being united below by a chisel, so as to remove a quadrangular portion of bone without interfering with the continuity of the jaw.

Giant-Celled Epulis.—This title is applied to an osteoclastoma developing from the interior of the alveolar process. It presents an identical pathology with osteoclastomata elsewhere. Where the tumour remains entirely encapsulated it presents the usual signs of this tumour—a smooth regular swelling, with eggshell crackling on palpation in some cases. It forms a soft, rapidly increasing mass of a dusky purple colour, which runs on to ulceration or fungation; the deeper portions may contain an ossific deposit. *Treatment* consists in free removal of the tumour and of the portion of alveolus from which it arises. In the upper jaw this sometimes necessitates excision of the complete palatal segment of the maxilla, but in the lower jaw it is generally possible to maintain the continuity of the mandible by removing merely a quadrilateral portion in the same way as for a simple epulis. Operation should always be followed by irradiation.

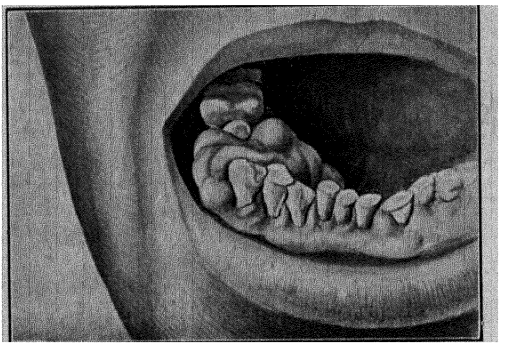

FIG. 618.—SIMPLE EPULIS.

Epithelioma and **Sarcoma** (**round** or **spindle-celled**), arising from the gum, are both met with. Epithelioma in this situation occasionally fungates, but more often invades the bony tissues, and in the upper jaw extends upwards to the antrum; hence it is sometimes termed a 'creeping or burrowing epithelioma.' The ordinary signs of this disease become evident, lymphatic glands are enlarged, and typical ulceration of the gum follows. The only possible *treatment* consists in free excision of the growth, together with the portion of bone affected and the lymphatic area involved.

Necrosis of the Jaw.—Causes: (1) Subperiosteal alveolar abscess, connected with dental caries. (2) Traumatism, such as blows on the jaw, with or without fracture, in the latter instance being due to infective osteitis. The use of dirty forceps or elevators in extracting

a tooth may similarly light up an infective inflammation, resulting in necrosis. (3) It may follow one of the exanthemata or any condition of malnutrition, arising as an infective idiopathic or embolic osteomyelitis, and then probably affecting a considerable extent of bony tissue, possibly the whole mandible. (4) It results from mercurial poisoning, but rarely at the present day. (5) Phosphorus necrosis is met with amongst those who work in lucifer-match factories, but only when ordinary phosphorus is used; the amorphous form is harmless. The fumes are supposed to gain access to the jaws through carious teeth, giving rise to a somewhat acute inflammation, which terminates in necrosis. A considerable amount of new bone forms beneath the periosteum, and the sequestrum, which is curiously grey and porous, like pumice-stone, is always slow in separating. Either jaw may be affected, but the lower a little more commonly than the upper. (6) Tubercle and actinomycosis are occasionally responsible for this condition, and in tertiary syphilis it is observed, usually affecting the alveolar borders of the palate.

The **Clinical Phenomena** associated with necrosis of the jaw are necessarily much the same whatever the cause. The acute form commences with severe pain in and around the jaw, followed by great swelling of the face and difficulty in opening the mouth or taking food. The temperature is raised, and even rigors may be present; the breath is usually foul. Sooner or later an abscess forms, which may point either in the mouth or on the face, or the pus may burrow downwards for some distance into the neck.

Treatment.—In the early stage the cheek should be fomented, but as soon as there is any suspicion of pus a free incision is made down to the bone inside the mouth and along the line of reflection of the mucous membrane. When necrosis is present, it must be treated in the ordinary way, the sinuses being flushed out with an antiseptic solution three or four times a day until the sequestrum is loose; it is then removed, if possible from within the mouth. Drainage by means of an external opening is often absolutely necessary.

Tumours of the Upper Jaw.

Many of the **Simple Tumours** springing from the upper jaw have been already described amongst those involving the alveolar border and antrum. Only a few remain to be dealt with.

Osteoma occurs either in the form of a tumour composed of compact tissue, then usually growing within the antrum; or occasionally as a diffuse symmetrical overgrowth, constituting the condition known as *leontiasis ossea*. A few cases of **Chondroma** have also been reported.

Leontiasis ossea is a disease, fortunately very rare, which, commencing in young adult life, progresses slowly, but relentlessly, and may at length destroy the patient after causing a great amount of suffering. Nothing is known as to its origin, except that it may commence in the ethmoidal sinuses as an inflammatory process of feeble virulence, and spread as a creeping periostitis. It affects either

the cranial or facial bones, or both, and consists in a development therefrom of nodular masses of soft spongy bone, embedded in which are areas of fibrous tissue. When affecting the facial bones, the projections may become very marked, and give the patient a hideously repulsive appearance, with a more or less leonine aspect (Fig. 619). As growth progresses, the new bone encroaches on the cavities of the skull, the antrum, the orbits, or even the cranial cavity, and thus exophthalmos, neuralgia, and finally coma may be produced. No satisfactory treatment is known, although attempts to chisel away the masses have been made.

Malignant Disease of the Upper Jaw occurs in the form of sarcoma or cancer. *Sarcoma* is perhaps the more common, and originates either from the anterior wall, from the cavity of the antrum, from the spheno-maxillary fossa behind the bone, or may extend into the maxilla from the naso-pharynx. Not unfrequently these growths have a considerable ossific basis, and this is sometimes so extensive as to obliterate the antral cavity, and convert the bone into a solid mass (Fig. 620). *Carcinoma* develops in the form of a squamous burrowing epithelioma, springing from the mucous membrane of the anterior ethmoidal region, or commencing in the mucous glands of the lining membrane of the maxillary sinus (Fig. 621).

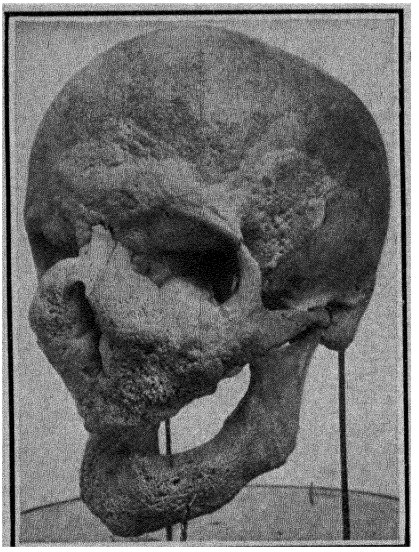

FIG 619 — LEONTIASIS OSSEA (ROYAL COLLEGE OF SURGEONS)

The **Clinical Features** of both forms of malignant disease are practically identical.

If arising *from the anterior aspect* of the bone, a tumour is produced which projects under the cheek, the tissues of which are invaded, it extends down towards the mouth, and is readily detected through the mucous membrane. It may, however, spread deeply and involve the cavity of the antrum. It causes no obstruction to nasal respiration, and no epiphora except in the later stages.

If it originates *within the antrum*, or, as is more common, from the antro-ethmoidal region, the usual signs of distension of that cavity are produced, associated with a foul, and often blood-stained, discharge from the nose, within which the ulcerated surface of the growth may be seen. Epiphora is caused by pressure on the nasal duct, whilst the growth has been known to burrow upwards along this passage and project near the inner canthus. The passage of air through the nose on that side is impeded, and the palate may be de-

pressed. The growth may also extend up the infundibulum to the ethmoidal cells and frontal sinus, or it may erode the antral roof and invade the orbit.

If the growth commences *behind the maxilla*, it usually springs from one of the walls of the spheno-maxillary fossa, or from the base of the skull, and is then characterized by a great tendency to spread in all directions. It may push the whole bone bodily forwards without encroaching upon the antrum; sometimes it finds its way outwards to the pterygoid fossa through the pterygo-maxillary fissure, or inwards to the nose through the spheno-palatine foramen, or even up into the orbit; whilst more rarely it spreads down along the posterior palatine



FIG. 620.—SARCOMA OF UPPER JAW.



FIG 621.—MALIGNANT DISEASE OF UPPER JAW.

the later stages the antral cavity is also involved, and even the base of the skull eroded.

The **General Signs** of a malignant tumour of the superior maxilla consist in the appearance of a growth which, in its earlier stages, may produce various effects, but finally destroys the bone and occupies the whole maxillary region (Fig. 621). It is often associated with nasal obstruction, epiphora, and a discharge of blood or pus from the nares. Severe pain sometimes accompanies the process, usually affecting the second division of the trigeminal. Neighbouring lymphatic glands are enlarged very late in the disease; those in the submaxillary region are first involved, and afterwards those in the anterior triangle; secondary deposits in the viscera may also occur somewhat later. The tumour

minimum mutilation through the hard palate. This is removed on the affected side, care being taken to leave the soft palate and its attachment intact. The antrum is then widely exposed, the growth removed with diathermy, and subsequently radium applied to the cavity on the upper surface of an obturator which is fitted by a dentist. After radiation is completed the cavity is closed by an obturator. This method has the advantage of leaving the cavity so that it may be regularly inspected for any sign of early recurrence.

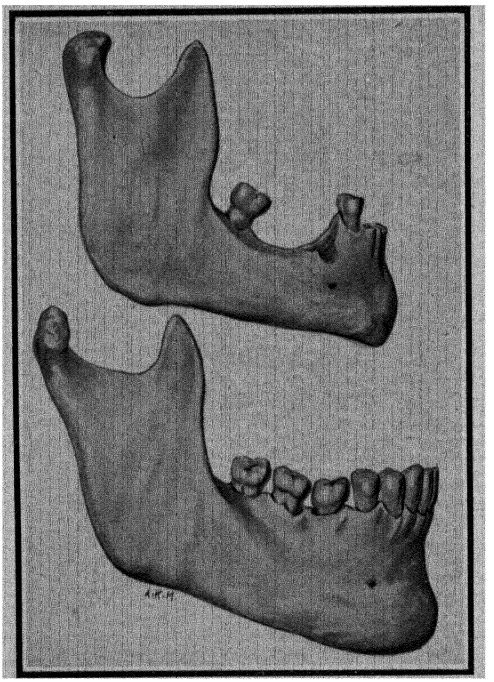

FIG 624.— TWO JAWS FROM PEOPLE OF THE SAME AGE.

The upper one shows how the alveolar margin atrophies on removal of the teeth

Recurrence in these cases is high—a 20 per cent. survival rate at the end of the third year.

Excision of the Upper Jaw *en masse* is now seldom employed except to satisfy the enquiries of examiners.

The Lower Jaw.

The mandible may be considered as a mixed bone, because it is formed chiefly from membrane, but also from cartilage. At birth it consists of two halves, connected at the symphysis menti by fibrous tissue. The rami are short, so that each condyle is nearly on a level with the upper border of the symphysis. During the first year osseous union takes place. As adult life is reached, the body of the mandible increases in depth, the rami lengthen, and the angle decreases, while the mental foramen gradually assumes a position midway between the superior and inferior borders. In old age, if the bone becomes edentulous, the whole of the alveolar border undergoes absorption. If teeth are extracted in adult life, the alveolar margin becomes absorbed, as can be seen in Fig. 624.

Infections of the Jaw.—Septic infections of the mandible are quite common, and it is curious that they are not more so, considering the very septic state in which the mouth is often found to be.

Osteomyelitis of the Lower Jaw.—Two distinct varieties may be recognized:

(1) Extensive acute involvement, which simulates acute osteomyelitis of the long bones.

(2) Localized necrosis, due to local infection.

The acute form is very severe and is often fatal, but, fortunately, is rarely seen. The infection may be blood-borne, or it may reach the bone from an adjacent infection in the teeth. As the lower jaw obtains its blood-supply internally from the inferior dental artery, and externally from vessels supplying the periosteum, it can be imagined that various forms of disease exist according to the source of the infection. The whole of the narrow cavity is supplied by the inferior dental artery, which is enclosed in a dense canal, and if this artery is occluded by septic thrombosis, there is destruction of a large part of the lower jaw. As a rule the whole of the alveolar process, carrying with it the teeth, may necrose and become separated. Sometimes, a week or so after one side of the jaw becomes infected, the other side follows suit. There is a general constitutional reaction with high temperature, and at times rigors; the disease, if not fatal, follows the course of osteomyelitis of the long bones.



FIG 625.—SKIAGRAM OF CASE OF OSTEOMYELITIS OF LOWER JAW, SHOWING SEQUESTRUM

In those cases where the disease is caused by extension of infection from the mouth, either from an infected tooth or from an injury, there may be a much more severe reaction owing to the fact that the infection is not due solely to the *Staphylococcus pyogenes aureus*, but to a mixed infection in which a variety of organism takes part. In such cases extensive suppuration of the soft tissues of the neck may supervene, and there may be extension down the fascial planes of the neck into the mediastinum, a fatal mediastinitis resulting.

Treatment should be conservative on the whole. It may be necessary to incise the periosteum and drill the bone. Owing to the density of the osseus tissue of the lower jaw, it takes a long while for the necrotic bone to become extruded—much longer, in fact, than in the long bones. It may take several months, or even years, before all the sequestra finally become separated. The sequestra can be easily demonstrated by the use of X-rays (Fig. 625), and in removal the surgeon should be careful not to fracture the jaw, as this can quite easily be done owing to the weakness of the surrounding involucrum.

Local Necrosis.—This condition is quite common, and usually is the result of infection from the teeth. The third molars appear to be the chief offenders, no doubt because they are most commonly misplaced and unerupted. Trismus is often a sign which requires to be

minimum mutilation through the hard palate. This is removed on the affected side, care being taken to leave the soft palate and its attachment intact. The antrum is then widely exposed, the growth removed with diathermy, and subsequently radium applied to the cavity on the upper surface of an obturator which is fitted by a dentist. After radiation is completed the cavity is closed by an obturator. This method has the advantage of leaving the cavity so that it may be regularly inspected for any sign of early recurrence.

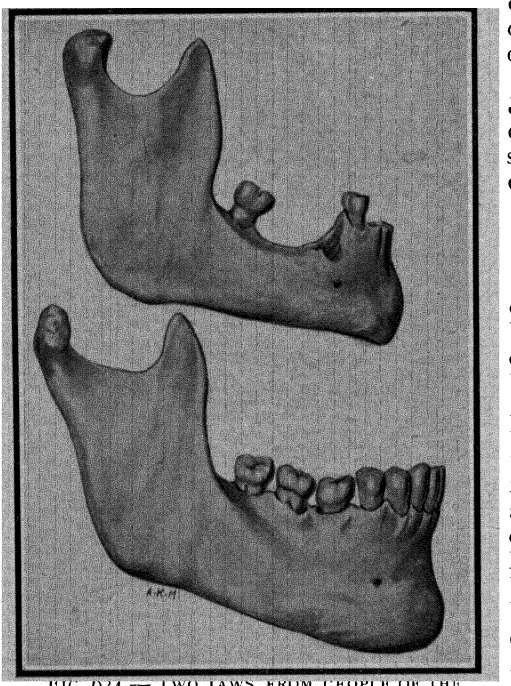

FIG. 624.— TWO JAWS FROM PEOPLE OF THE SAME AGE.

The upper one shows how the alveolar margin atrophies on removal of the teeth

Recurrence in these cases is high—a 20 per cent. survival rate at the end of the third year.

Excision of the Upper Jaw *en masse* is now seldom employed except to satisfy the enquiries of examiners.

The Lower Jaw.

The mandible may be considered as a mixed bone, because it is formed chiefly from membrane, but also from cartilage. At birth it consists of two halves, connected at the symphysis menti by fibrous tissue. The rami are short, so that each condyle is nearly on a level with the upper border of the symphysis. During the first year osseous union takes place. As adult life is reached, the body of the mandible increases in depth, the rami lengthen, and the angle decreases, while the mental foramen gradually assumes a position midway between the superior and inferior borders. In old age, if the bone becomes edentulous, the whole of the alveolar border undergoes absorption. If teeth are extracted in adult life, the alveolar margin becomes absorbed, as can be seen in Fig. 624.

Infections of the Jaw.—Septic infections of the mandible are quite common, and it is curious that they are not more so, considering the very septic state in which the mouth is often found to be.

Osteomyelitis of the Lower Jaw.—Two distinct varieties may be recognized:

(1) Extensive acute involvement, which simulates acute osteomyelitis of the long bones.

(2) Localized necrosis, due to local infection

The acute form is very severe and is often fatal, but, fortunately, is rarely seen. The infection may be blood-borne, or it may reach the bone from an adjacent infection in the teeth. As the lower jaw obtains its blood-supply internally from the inferior dental artery, and externally from vessels supplying the periosteum, it can be imagined that various forms of disease exist according to the source of the infection. The whole of the narrow cavity is supplied by the inferior dental artery, which is enclosed in a dense canal, and if this artery is occluded by septic thrombosis, there is destruction of a large part of the lower jaw. As a rule the whole of the alveolar process, carrying with it the teeth, may necrose and become separated. Sometimes, a week or so after one side of the jaw becomes infected, the other side follows suit. There is a general constitutional reaction with high temperature, and at times rigors; the disease, if not fatal, follows the course of osteomyelitis of the long bones.

In those cases where the disease is caused by extension of infection from the mouth, either from an infected tooth or from an injury, there may be a much more severe reaction owing to the fact that the infection is not due solely to the *Staphylococcus pyogenes aureus*, but to a mixed infection in which a variety of organism takes part. In such cases extensive suppuration of the soft tissues of the neck may supervene, and there may be extension down the fascial planes of the neck into the mediastinum, a fatal mediastinitis resulting.



FIG. 625.—SKIAGRAM OF CASE OF OSTEOMYELITIS OF LOWER JAW, SHOWING SEQUESTRUM.

Treatment should be conservative on the whole. It may be necessary to incise the periosteum and drill the bone. Owing to the density of the osseus tissue of the lower jaw, it takes a long while for the necrotic bone to become extruded—much longer, in fact, than in the long bones. It may take several months, or even years, before all the sequestra finally become separated. The sequestra can be easily demonstrated by the use of X-rays (Fig. 625), and in removal the surgeon should be careful not to fracture the jaw, as this can quite easily be done owing to the weakness of the surrounding involucrum.

Local Necrosis.—This condition is quite common, and usually is the result of infection from the teeth The third molars appear to be the chief offenders, no doubt because they are most commonly misplaced and unerupted. Trismus is often a sign which requires to be

fully interpreted, and here an X-ray will often clinch the diagnosis. The treatment should be carried out essentially by a dental surgeon.

Infections of the lower jaw occasionally follow the use of certain drugs, especially if there is some oral sepsis present at the same time. The drugs which may cause necrosis are mercury, arsenic, and antimony. Some patients are very susceptible to these drugs, and even the local use of arsenic in the preparation for filling a cavity in a tooth may lead to quite extensive destruction of the portions of the jaw.

In cases of syphilis where there is extensive dental caries, the use of mercury and arsenic in the treatment of the disease must be carefully watched, otherwise extensive necrosis or complete destruction of the alveolar process may take place. It is in the treatment of such cases that the co-operation of surgeon and dental surgeon is so essential. The principles of treatment, which is essentially conservative, are as follows. Drainage must be established with the least amount of trauma; this may be intra-oral, or, more frequently in the lower jaw, an extra-oral incision will be needed over the swelling. Once provided, drainage must be maintained and ample time allowed for the virulence to subside and sequestra to form. Skiagrams will show when the process is completed. When formed, sequestra must be removed without disturbing the bed of granulation tissue beneath.

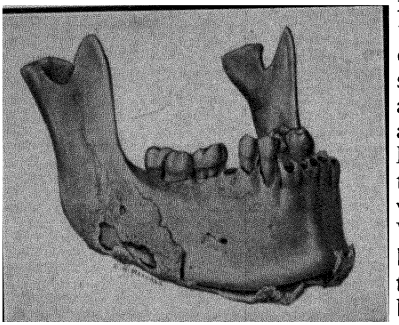

FIG. 626.—SPECIMEN OF LOWER JAW SHOWING PHOSPHORUS NECROSIS, FROM A MAN, ÆT. 35, WHO HAD BEEN ENGAGED IN LUCIFER-MATCH MAKING FOR MANY YEARS. (R.C.S. MUSEUM.)

Necrosis may be seen at times during the course of one of the exanthemata, especially in young children, when it may be a fatal condition. Measles, scarlet fever, typhoid, chicken-pox, and small-pox have all been known to be the causative agent in necrosis of the jaw. In these cases an attitude of conservatism should be always adopted.

Phosphorus Necrosis is rarely met with at the present day owing to the fact that amorphous phosphorus is now used instead of yellow phosphorus in the manufacture of matches. Many museums in the country, however, possess excellent specimens illustrating this condition (Fig. 626). The lower jaw is affected equally with the upper, and it was quite a common observation that both were affected at one and the same time. The fumes given off from the yellow phosphorus gain access to the jaw, generally through carious teeth, and set up an inflammatory reaction. Salivation and swelling of the gums and bone take place, and this is followed in quick succession by necrosis of the bone. The teeth become loosened, and finally drop out, and there is an exudation of pus from the empty sockets. The patient's health

deteriorates rapidly owing to septic absorption, anæmia, and exhaustion due to anorexia; death may even take place from these complications. Sequestra, both large and small, are gradually formed, but take a long time to become sufficiently loose to be exfoliated. When a sequestrum separates or is removed, however, it is found to be of a curious yet characteristic appearance; it is bossy and porous, and may be likened to coarse pumice-stone. As a rule a considerable involucrum forms, and the lower jaw may be reconstituted again after separation of all the sequestra. Even after the separation of what appears to be the whole of the lower jaw in the form of a sequestrum, the jaw is remarkably re-formed, and a denture can be worn at a later date.

Treatment should be conservative, with the removal of loose sequestra where necessary, the great essential being to build up the general health of the patient.

Radium Necrosis.—This is a form of necrosis which has appeared with the advent of radium treatment for cases of carcinoma of the tongue. It is probably the most chronic and most painful form of necrosis which affects the lower jaw. It is preventable to a large extent, for the radium should be protected in a lead screen. Cases do arise, however, where every precaution has been taken, and the necrosis, which is heralded by chronic burning pain, often for a month or more, becomes manifest firstly by X-rays before any clinical signs are forthcoming. Months pass before any clinical evidence of necrosis is to be seen, and sequestra slowly form and take a very long time to separate. Two or three years is often the actual time period for the separation of minute sequestra. In this condition, again, conservatism is the treatment, any active interference causing a mixed infection and an osteomyelitis of the mandible.

Actinomycosis of the Jaw.—The lower jaw is quite commonly infected with the ray fungus, the infection commencing in a carious tooth, or an abrasion of the mucous membrane by a tooth plate or a hard particle of food. There is some swelling of the bone which eventually leads to necrosis. Multiple abscesses form which in turn form sinuses, and these discharge sticky exudate containing the well-known 'granules.' Excessive fibrosis takes place about the sinuses, and the tissues appear to be markedly indurated. If the disease is not treated, slow extension takes place into the muscles in the neighbourhood, and the jaw may become fixed, causing difficulty in swallowing and breathing. The veins may be compressed, or, occasionally, erosion takes place with generalized metastatic deposits of the disease which kill the patient.

The **Prognosis** is far from hopeless, and is quite good if the condition is still localized to the lower jaw.

Treatment must be local and general. Excision of all necrotic tissue is essential, and the area should be packed with gauze soaked in tincture of iodine. These packs should be changed daily. Indurated masses and sinuses should be incised and packed with iodine gauze.

The general treatment consists in giving large doses of potassium iodide up to 1,000 grains per diem. If the patient develops signs of

iodism the dose should be doubled, not halved. The treatment should extend over six weeks or two months. X-ray treatment has given good results in some cases.

Vaccine treatment may be tried as an adjuvant method of treatment, but is not so satisfactory as intensive potassium iodide treatment.

During the treatment it is essential that the general health of the patient should be maintained by the use of a suitable nourishing diet, and a tonic if necessary.

Tumours of the Lower Jaw.—Innocent tumours are rare; they consist of osteoma, chondroma, myxoma, lipoma, and fibroma.

Osteomata may be ivory or cancellous. The ivory osteomata occur in the region of the neck and condyle of the mandible. The tumour is usually single and is found as a smooth, hard mass covered with periosteum. Growth is slow, but such tumours may cause limitation of movement at the temporo-mandibular joint. Excision is difficult, and fracture of the neck of the mandible may result if precautions are not taken to prevent this. **Cancellous osteomata** are more common than the ivory, and may be met with near the symphysis or in the region of the lingula. Their removal may be difficult owing to the fact that they may be growing from the inner side of the mandible. **Chondromata** are occasionally seen; they arise most commonly in the region of the condyle or the symphysis, and may be mistaken, clinically, for osteomata. **Myxomata** are very rare tumours in relation to the mandible, and it is quite possible that they may be due to degenerative changes occurring in fibromata, chondromata or lipomata. **Lipomata,** when present, are often subperiosteal in situation, and are rarely diagnosed correctly. The tumour is often very hard, and is mistaken for an osteoma, but X-ray examination does not reveal a bony tumour. The correct diagnosis is only made on exploration, when the tumour can be completely removed and the diagnosis confirmed by the microscope. **Fibromata** may occur in any part of the mandible; they grow from the periosteum and form hard tumours, which may become pedunculated if growing from the inside of the jaw, as they then come into contact with the tongue, which soon exerts a suction traction action on the tumour. Excision is a simple matter; if left alone they slowly increase in size, and later may become sarcomatous.

Osteoclastomata may occur as endosteal growths which slowly expand the body of the jaw. They generally present but slight evidences of malignancy, and may be treated in the first place by opening the outer shell of bone through the mouth, scraping away the soft dusky purple contents, and plugging the cavity with gauze, after having swabbed it out with pure carbolic or tincture of iodine. If the case is a late one and the jaw much expanded, the cavity may be filled with bone chips to help the consolidation of the bone. If recurrence takes place, the cavity should be scraped out once more and some radium needles be inserted after the cavity has been filled with bone wax. The needles are left in for six or seven days; they are then removed with the wax and the wound allowed to granulate.

Sarcomata form the commonest malignant tumours of the mandible, and every type of osteogenic sarcoma may occur. The periosteal variety is very malignant, and shows an excessive amount of new bone laid down in radiating lamellæ; on the other hand, it may simply show a large gap in the bone (Fig. 627). The best form of treatment is deep X-ray therapy, but some cases treated with the radium bomb have shown good results (Figs. 628 and 629). Excision of half the mandible may be undertaken if suitable X-ray or radium therapy is not available (Figs. 633-635). Small doses of radium or X-rays only aggravate the condition.

Endosteal Sarcoma often arises in the horizontal ramus, and the condition may be mistaken for chronic osteomyelitis, especially if too much stress is placed on the X-ray appearance. In cases of doubt, a



FIG. 627.—SKIAGRAM OF SARCOMA OF THE LOWER JAW

biopsy should always be obtained to confirm the diagnosis. Excision of half the mandible may be undertaken, or the case may be treated by deep X-ray therapy. Secondary sarcomatous deposits may rarely be seen in the lower jaw. They appear as hard masses which, on X-ray examination, often appear to be cystic. Such deposits are seen only in the advanced stages of sarcomatosis where secondary deposits are to be found all over the body. **Malignant Melanoma** may be seen occasionally growing from the lower jaw. Some thirty cases are reported in the literature. The growth forms a bluish-black lump growing from the inner or outer surface of the horizontal ramus. Histologically, the tumour is very cellular, of sarcomatous structure, the spindle cell predominating. Excision of half the jaw should be undertaken. **Carcinoma** may invade the jaw from the tongue or the

floor of the mouth, and is of the squamous-celled type (Fig. 630) Wide excision of the bone, together with the primary disease, is always required, unless it has extended so far as to render extirpation impracticable; in such cases radium treatment should be undertaken. **Columnar-celled Carcinoma** is rare; it commences in epithelial rests in the peri-odontal membrane, and spreads into the jaw. The treatment is similar to that outlined above. **Secondary Carcinoma** may occasionally be seen in the jaw in advanced cases of carcinomatosis, the primary disease being in the breast, prostate, thyroid or kidney. The X-ray appearances are characteristic of secondary carcinoma in the long bones. **Endothelioma** may rarely be seen in the lower jaw. It arises in connection with the blood-vessels, and is found growing

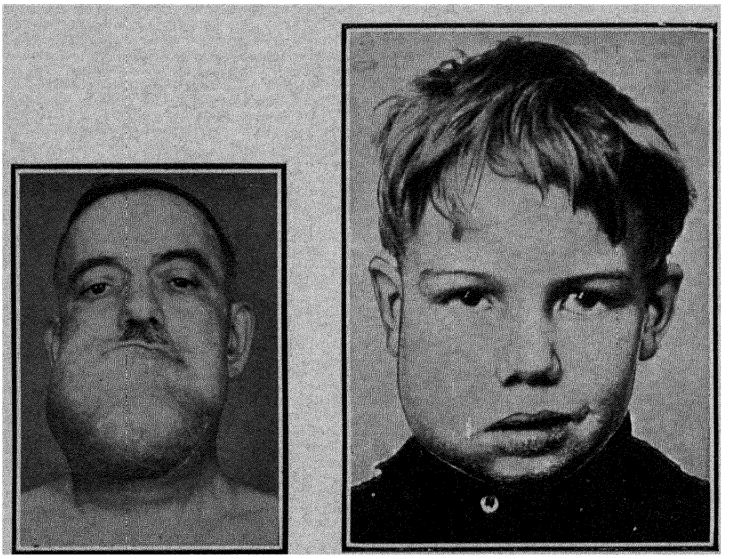

FIG 628.—OSTEOGENIC SARCOMA OF THE LOWER JAW

FIG. 629.—SARCOMA OF THE LOWER JAW IN A CHILD.

from the alveolar process. Diagnosis is often difficult, even when a piece has been removed for histological examination. Treatment should consist of local excision of the jaw in the region of the tumour.

Fibrocystic Disease of the Lower Jaw (Adamantinoma, Epithelial Odontoma).—This is a rare disease, but one which is well known. It forms a hard swelling, attached to and continuous with the jaw. In some cases the tumour undergoes some calcareous degeneration, which may readily be seen in the X-ray photograph. In other cases the whole of the lower jaw may be converted into definite cystic masses (Figs. 631 and 632). In others multiple sinuses develop, both inside and outside the mouth; these are very suggestive of the disease. Histologically

the tumour consists of a mass of epithelial lined spaces surrounded by dense fibrous tissue, this appearance having led to the term fibrocystic disease. It is a different pathology from fibrocystic disease elsewhere, and hence the name is a bad one. It is not necessary in all cases to remove half the lower jaw, but the tumour should be removed as completely as possible.

Excision of the Lower Jaw.—This is an operation which is rarely performed at the present day. Partial removal may be necessary in the removal of epulides; this consists generally of the removal of a portion of the alveolar border together with the growth.

Resection of the median portion of the lower jaw is undertaken for those cases where there has been an extension from a carcinoma of

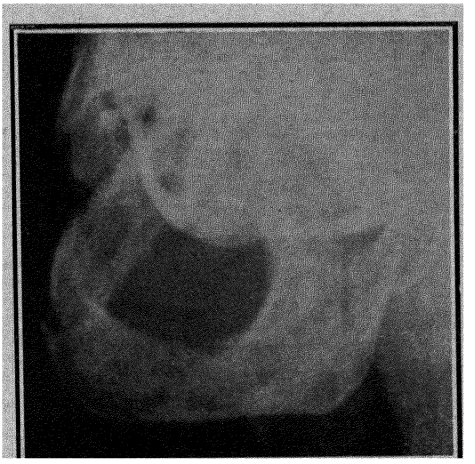

The disease has spread from the floor of the mouth

the under surface of the anterior part of the tongue, from a carcinoma of the floor of the mouth, or even from a carcinoma of the lip. Before undertaking such an operation it is very important that all septic foci in the mouth should be removed. Intratracheal gas and oxygen is the best form of anæsthesia, and allows the pharynx to be plugged with gauze, so that no blood or saliva can enter the air passages during the operation. The diseased area is enclosed by two incisions which converge in the mid-line just above the hyoid bone. The divided vessels are secured and the lower jaw is divided by a saw and removed. The two halves of the jaw are then united by means of a piece of stout catgut or kangaroo tendon, which is passed through two drill holes on either side. The skin flaps are undermined and brought together; it may be necessary to relieve the tension of the flaps by some lateral incisions. It is essential to suture the lip carefully so that the

red margin on one side coincides exactly with that of the other. Drainage is essential, the tube being placed in the lower part of the incision

Excision of Half of the Lower Jaw.—This operation is performed for cases of malignant disease. Intratracheal gas and oxygen anæsthesia and plugging of the pharynx with gauze is imperative. With the head turned to the opposite side, an incision is made commencing in the centre of the lower lip and passing downwards to a point immediately below the symphysis (Fig 633). It is then carried along the under surface of the body of the mandible and as far as the angle. The incision is then prolonged upwards along the posterior border of the vertical ramus as far as the lobule of the ear, but no further, because of the danger of cutting the facial nerve.

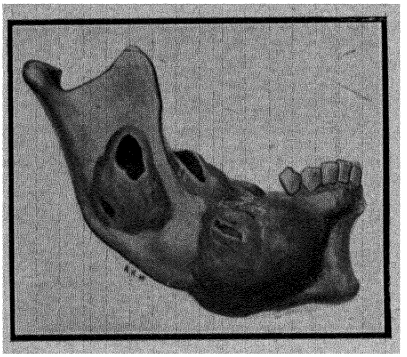

ODONTOME OF THE LOWER JAW (R.C.S. MUSEUM)

While making the incision over the posterior part of the body of the mandible the fascial vessels are encountered and secured between ligatures. The large flap is turned upwards, and the muscles attached to the jaw, which are not involved or in contact with the tumour, are elevated by a periosteal elevator (Fig 634). The muscles on the inner side of the jaw are dealt with in a similar manner, care being taken that the mucous membrane of the mouth is kept intact. The central incisor tooth is extracted, and the jaw divided through the empty socket with a small saw and cutting pliers, a little to one side of the middle line. By this means the genial tubercles and their attached muscles are not damaged, and so the movements of the tongue are unimpaired. The bone is now pulled outwards and its internal attachments are brought into view and divided, care being taken to secure the inferior dental vessels just before they enter the canal in the bone. By depressing the jaw

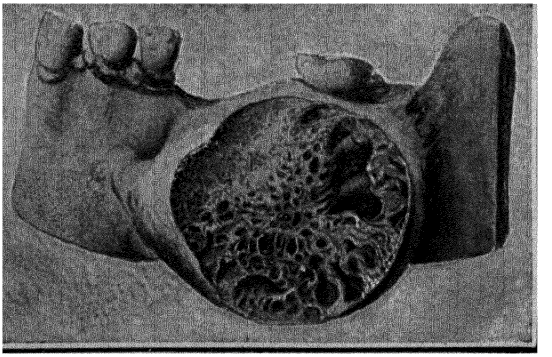

FIG 632.—EPITHELIAL ODONTOME OF THE LOWER JAW (R.C.S. MUSEUM)

the tendon of the temporal muscle is exposed and its attachment to the coronoid process can be severed by a few touches with the knife. Lastly, the condyle of the jaw is freed after cutting through the tendon of the external pterygoid muscle and the capsule of the temporo-mandibular joint (Fig. 635). Care should be taken not to divide the internal maxillary artery, which is in close proximity to the inner surface of the neck of the mandible. As a rule hæmorrhage is quite easily controlled, and the wound can be stitched together with interrupted silkworm-gut sutures, a drainage-tube being inserted at the posterior end. Care should be taken in approximation of the lip so that the red margin is continuous on both sides of the incision. The wound is dressed with gauze in which one or two marine sponges are incorporated to give firm pressure and prevent the occurrence of a hæmatoma. The drainage-tube should not be removed until all oozing has stopped, which is generally about the third or fourth day after the operation. The wound heals well, and there is little post-operative pain. The patient can be allowed out of bed on the second day, and

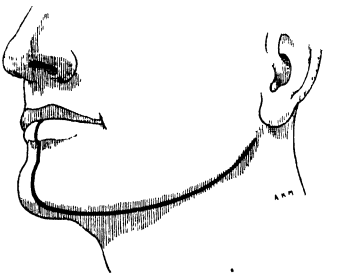

FIG 633.—THE INCISION FOR REMOVAL OF HALF THE LOWER JAW

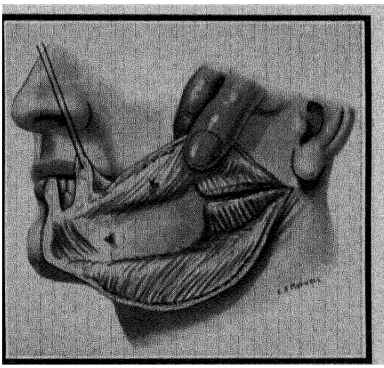

FIG 634 OPERATION FOR REMOVAL OF HALF THE LOWER JAW

The skin flap is raised and the masseter muscle cut through

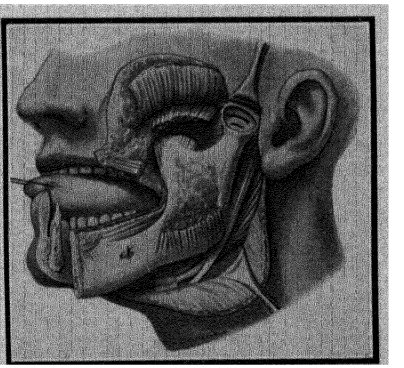

FIG 635.—EXCISION OF HALF THE LOWER JAW

The bone has been divided in the middle line and its final muscular attachments are severed

can generally leave hospital about the tenth day. Considerable deformity usually results from this operation, owing to the remaining half of the bone being drawn across the middle line, but, if necessary, this often can be overcome by a plastic operation at a later date. The co-operation of a dental surgeon will often help in obtaining a

good result by the use of a suitable denture. Although excision of half the lower jaw appears to be quite a simple operation, there are a number of pitfalls which the surgeon should endeavour to avoid. First and foremost, gentleness is all-important, as a fracture may result at or near the site of the tumour. The pharynx may be opened if the knife is not kept close to the bone while separating the soft parts from the region of the angle of the jaw. The internal maxillary vessels may be wounded and give rise to troublesome hæmorrhage which is difficult to locate and control.

Leontiasis Ossea.—The lower jaw is frequently involved in this uncommon disease; in fact, in some cases it appears to be the first bone of the face to become affected. The bone is enlarged, sclerosed, and pitted as if a creeping periostitis had taken place. The jaw



FIG. 636.—LEONTIASIS OSSEA AFFECTING THE LOWER JAW OF WOMAN AGED 31

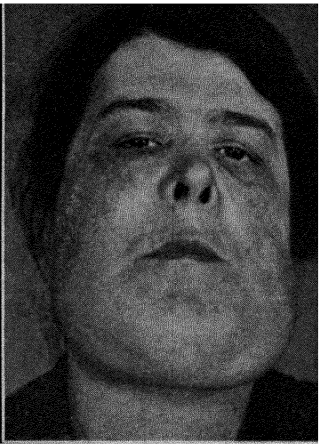

FIG. 637.—FULL-FACE PHOTOGRAPH OF THE SAME PATIENT

appears enlarged in every direction, and the patient is often very conscious of this fact. There is no known treatment for the condition, but small abscesses may form around some septic teeth, which are often embedded in a very dense mass of sclerosed bone (Figs. 636-638). Extraction of the teeth may entail a very difficult surgical operation, the only method by which the teeth can be removed being by an electrically-driven burr or chisel.

Osteitis Deformans (Paget's Disease).—Although the bones of the cranium are commonly affected in this disease, the facial bones and lower jaw only show slight involvement. In a few recorded cases the lower jaw has been markedly affected and enlarged. On X-ray examination the jaw appears to have cystic spaces connected by multiple trabeculæ throughout its entire length. The dried bone is quite porous.

Osteo-Arthritis is by no means rare in this joint, although it is quite often overlooked as a cause of pain in the joint. With modern methods of radiology the condition can be seen quite easily on a skiagram. The condition may be symmetrical, and is characterized by considerable enlargement of the condyle of the jaw, which causes it to bulge laterally, so that it can be felt in front of the tragus of the ear. Movements of the joint are painful and limited, and crepitus can nearly always be elicited. If the condition is bilateral, the lower jaw appears to be pushed forwards, rendering the chin quite prominent. If, however, the condition is unilateral, the jaw becomes deflected to the sound side. Loose bodies may form in some cases, and may cause ' locking ' of the joint, while in others there is extensive lipping of the periphery of the condylar cartilage, proliferation of the synovial villi, and ' lipoma arborescens ' may be in evidence. As the disease progresses the interarticular cartilage may disappear completely, and the glenoid cavity, as it enlarges, may assume a flattened outline, so that a partial dislocation may even occur. If pain and limitation of movement are complained of, the only satisfactory treatment is excision of the condyle, as all other forms of treatment are useless and a waste of time.

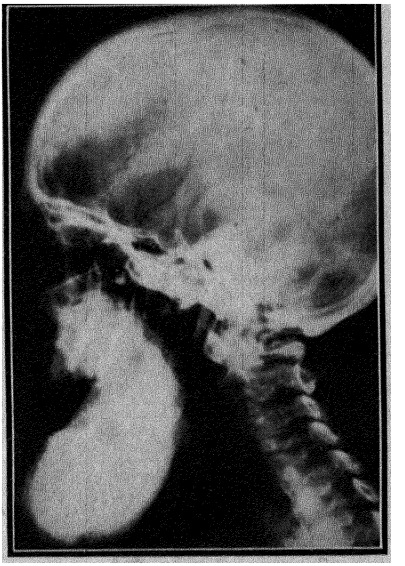

FIG. 638.—SKIAGRAM OF PATIENT WITH LEONTIASIS OSSEA FROM WOMAN SEEN IN FIGS. 636 AND 637

The operation of excision of the condyle of the jaw is carried out through a curvilinear incision, commencing over the middle of the zygoma, and passing downwards in front of the tragus. In this operation the surgeon is working in a somewhat cramped space with the zygoma above, the facial nerve below, the parotid glands in front, and the external ear behind. After the skin and subcutaneous tissues have been incised, the small flap is turned upwards. A transverse incision is now made at the posterior end of the zygoma, opening up the capsule of the joint and the synovial membrane. The neck of the mandible is exposed, and a fine Gigli saw is passed round this with a small aneurism needle. The neck of the bone is cut through with this saw and the condyle removed. Sometimes the neck of bone may be divided with a small pair of cutting pliers. Any bleeding from the cut surface of the bone can be controlled by the firm application of some bone wax to the raw area. A small piece of celluloid can be placed over the cut surface of the bone and retained with a

stitch. This prevents any chance of ankylosis of the joint. A piece of fascia may perform the same purpose, while some surgeons advocate the use of a portion of the tunica vaginalis testis. The wound is closed with two or three interrupted sutures, no drainage being employed. The patient is encouraged to move the joint at an early date. The results of such an operation as this are really gratifying, and patients are quite pleased.

Tuberculous Arthritis.—It is often difficult to be certain whether tuberculous disease in this joint has arisen in the bone or in the synovial membrane. The affection itself is rare, and is only seen when the disease is fairly well advanced. It runs the usual course of any tuberculous joint affection, and ends in caries of the condyle. Secondary infection may occur, leading to ankylosis. The condition is

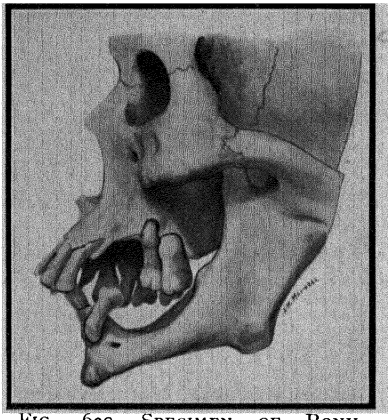

FIG 639.—SPECIMEN OF BONY ANKYLOSIS OF THE JAW OF MANY YEARS' STANDING. (R C S. MUSEUM)

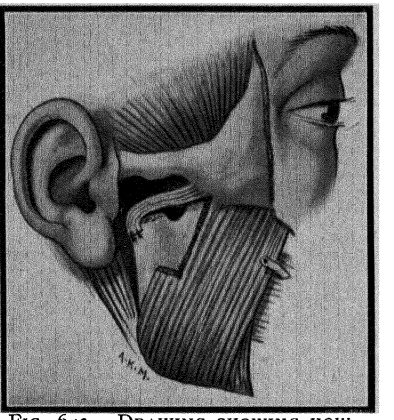

FIG 640.—DRAWING SHOWING HOW A STRIP OF THE MASSETER MUSCLE MAY BE USED TO ENSURE A FALSE JOINT AFTER EXCISION OF THE CONDYLE.

very chronic, and has been mistaken for osteo-arthritis on more than one occasion, the true diagnosis only being made when excision of the condyle was performed and the bone subjected to microscopical examination. Excision of the condyle and thorough cleansing of the cavity of the joint, followed by the application of bipp, is the treatment for this condition.

Neuropathic arthritis of this joint is a very rare entity; a hypertrophic Charcot's arthritis has been reported in the literature.

Treatment for the different varieties of fixation of this joint will of necessity vary according to the causative conditions.

Fibrous ankylosis can be dealt with by excision of the condyle of the jaw described above.

Bony ankylosis (Fig. 639) often presents a difficult problem, owing to the fact that the surgeon is working in a limited space, and any

attempt to remove the neck or head of the condyle by means of a chisel or osteotome may result in a fracture into the middle ear or injury to the facial nerve. A fine pair of nibbling forceps may be used, and the bone in the region of the neck of the mandible be carefully removed, piece by piece, until the bone is completely divided. It is important to remove a considerable portion of bone so as to leave quite ½ inch between the two surfaces. A piece of fascia lata, celluoid, or muscle graft should be inserted between the bony surfaces so as to ensure a false joint and prevent any bony union (Fig. 640). It is often possible to turn in a flap of the temporal muscle without extending the incision and without interfering in any way with the action of the muscle itself. In bilateral cases, after the stitches are removed, it may be necessary to move the jaw repeatedly under gas anæsthesia to ensure free movement. The end results in these cases depend to a large extent on the patients themselves; the persevering ones get excellent results, while the nervous patients, who will not try to move their jaws, often complain that the operation has been a failure and that they are little benefited by the surgical intervention. The surgeon should try to assess each patient before undertaking the operation, when he will be able to gauge the probable reaction in each case. Some patients should never be operated upon, as failure is assured by their behaviour prior to operation.

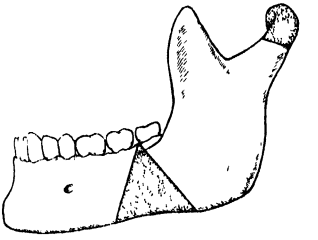

FIG. 641.—DRAWING SHOWING THE EXTENT OF BONE REMOVED IN EXCISION OF THE CONDYLE AND IN ESMARCH'S OPERATION

The most difficult cases to relieve or cure are those in which there is much cicatricial contraction round about the joint. Division or excision of the adhesions is useless, as, during healing, fresh adhesions form and the condition is unrelieved. In these cases, therefore, Esmarch's operation often gives good results (Fig. 641). This operation consists of the removal of a wedge of bone, with its apex towards the alveolar border, from the neighbourhood of the angle of the mandible. A portion of the detached masseter muscle is turned in between the two bony surfaces so that an artificial joint is formed. The incision should be made below and behind the angle of the jaw; this gives good exposure and allows the muscles to be separated from the outer and inner surfaces of the mandible. The bone can most conveniently be divided by the use of a Gigli saw. An alternative method is to remove the vertical ramus of the jaw down to the level of the alveolus, but this method does not give so satisfactory a result as Esmarch's operation.

Diseases of the Temporo-Maxillary Articulation.

Acute Synovitis may supervene in the course of an attack of rheumatic fever, and is evidenced by pain on movement of the jaw, and by

tenderness and swelling immediately beneath the root of the zygoma, due to effusion into and around the joint. Resolution generally follows, but fibroid thickening of the ligaments and impairment of movement may result.

Acute Arthritis arises from pyæmic infection after the exanthemata, or from gonorrhœa, but may be caused in children by direct extension of inflammation through the tympanic plate from the middle ear, as in scarlatina. It is characterized by the usual signs of a severe localized inflammation, with the formation of abscesses, and results commonly in ankylosis. Fomentations and the opening of abscesses constitute the only early treatment, whilst excision of the condyle is sometimes required later.

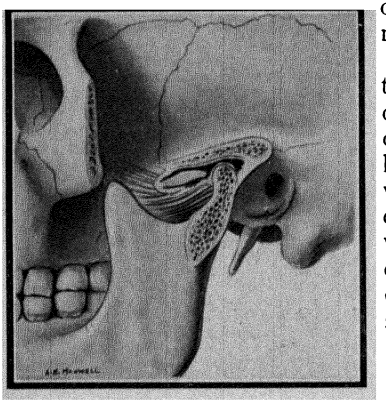

FIG 642.—DISPLACEMENT OF THE MANDIBULAR CARTILAGE

Internal Derangement of the temporo-maxillary joint (locking or clicking jaw) is not a very uncommon affection, resulting from laxity of the interarticular cartilage, which gets caught between the condyle and the eminentia articularis when the mouth is opened. The effect is a temporary painful fixation or locking of the jaw, which is usually set free by lateral movements. At other times there is marked clicking or creaking of the jaw when the mouth is opened. The actual displacement of the mandibular cartilage is probably due mainly to the shape and attachment of this meniscus. The fibro-cartilage is a dome-like structure very closely applied to the conyexity of the mandibular condyle. As far as thickness is concerned it is irregular, being very much thicker in its centre and anteriorly, between these two thickenings there is a distinct depression. The posterior part of the cartilage is very thin, and passes well down over the posterior surface of the condyle and fuses behind with the capsule. Rarely the posterior part of the mandibular cartilage actually becomes detached and is pulled forwards (Fig. 642). In bad cases *treatment* consists in excising the loose cartilage through a T-shaped incision; in the milder cases nothing can be done except to assist in the removal of the synovial effusion by blistering.

CHAPTER XXIX.

AFFECTIONS OF THE MOUTH, SALIVARY GLANDS, AND PALATE.

Stomatitis, or inflammation of the mucous membrane of the mouth, is by no means uncommon, especially in children.

1. **Catarrhal Stomatitis** results from mechanical irritants, such as roughened teeth, from irritating chemicals, or from septic inflammation following operations which involve the mouth, and is undoubtedly increased, if not initiated, by excessive smoking. It also arises in the course of fevers, and in conditions of debility such as follow measles and other exanthemata in children; or is associated with disturbances in the alimentary canal, as from improper feeding, dyspepsia, etc. The mucous membrane becomes hyperæmic and swollen, usually in small localized patches, which may gradually spread and become confluent, involving nearly the whole of the oral cavity. The exudation of mucus is increased, and becomes viscid and turbid, whilst the epithelium, at first white and sodden, is after a while rubbed off, leaving superficial erosions or distinct ulcers, which are very painful. The *treatment* consists in the removal of all sources of irritation, and the administration of drugs to correct intestinal derangements. Antiseptic mouth-washes should also be employed, such as sanitas (1 in 20), boro-glyceride (1 in 20), chlorate of potash, Condy's fluid, peroxide of hydrogen, or dettol.

2. **Aphthous Stomatitis** occurs in badly-fed children in the form of small whitish spots on a hyperæmic base, which run together and produce ulceration. Attention must be directed to the general condition, and a little borax and honey or a solution of boro-glyceride (1 in 20) applied locally. **Thrush** is due to the presence of a parasitic fungus, the *Oidium albicans*, and occurs in patches somewhat resembling curdled milk in appearance. In history and treatment it resembles the aphthous variety. In both types there is often some enlargement of the lymphatic glands, which, however, frequently subsides without suppuration.

3. **Gangrenous Stomatitis,** or cancrum oris, has been already described (p. 116). A similar condition occurs in elderly debilitated people especially if suffering from albuminuria or diabetes, and the possessors of foul teeth.

4. **Mercurial Stomatitis** is now rarely seen, except in persons who are unduly sensitive to the action of mercury. It is aggravated by dirty teeth, or if the patient smokes to excess. The gums are swollen and tender, bleed on pressure, and are very painful, especially when biting, or drinking hot fluids. The teeth may become loose and fall out, whilst the alveolar borders may be laid bare and necrose. The

tongue is sometimes swollen and inflamed; salivation is a marked symptom, and the breath becomes very offensive. *Treatment.*—Leave off the mercury, or at any rate reduce the dose considerably, and administer saline purgatives. Chlorate of potash combined with alum, dilute hydrochloric acid, or tincture of myrrh, may be useful locally.

5. For **Syphilitic Stomatitis,** see p. 153.

The buccal mucous membrane is also involved in the course of other diseases, *e.g.*, diphtheria, scarlet fever, and erysipelas, but special descriptions are not needed here.

Affections of the Tongue.

Congenital Abnormalities.—(*a*) The tongue has been completely or partially absent. (*b*) One half of the tongue is defective in size (*hemiatrophy*). (*c*) *Tongue-tie* is said to be present when the frænum is shorter than usual, causing the tip to be depressed and fixed in the floor of the mouth so that it cannot be protruded. Sucking becomes difficult in such a condition, and when it is allowed to persist there is often a lisp in the speech. Treatment is only needed in the severer forms, and consists in raising the tongue with the index and middle fingers placed one on either side, and snipping the frænum, thus put on the stretch, across its centre with a pair of blunt-pointed scissors directed downwards. (*d*) The tongue may be adherent to the floor of the mouth, being *bound down* by folds of mucous membrane (*ankyloglossia*). This may also exist as an acquired condition due to cicatricial contraction after ulceration. In congenital cases the adhesions are but slight, and the organ can be readily freed; in the acquired condition this cannot always be accomplished. (*e*) The frænum and tongue are occasionally too long, allowing of increased mobility, and even fatal results have occurred from the organ rolling backwards and impeding respiration. (*f*) The tongue may be *cleft*, presenting a bifid appearance, this may be complete or partial, and is usually associated with a congenital fissure through the lower lip and mandible. (*g*) *Macroglossia* (or large tongue), although sometimes acquired, is usually a congenital deformity. The organ is enlarged in all directions, and protrudes from the mouth, so that the teeth indent it, and cause ulceration and considerable interference with the venous return. It thus becomes purplish and dry from exposure, the mucous membrane looking almost like skin, although saliva dribbles freely from beneath it. In old-standing cases the teeth are displaced outwards and the jaws deformed, so that, even if the tongue is reduced to its normal size by treatment, it may be impossible to close the mouth. Pathologically, it is to be looked on as lymphangiectasis (p. 371) of congenital origin, and associated with diffuse overgrowth of the connective tissue. Recurrent attacks of lymphangitis add to the trouble, the tongue gradually increasing in size, and the disease has been known to terminate in the development of lympho-sarcoma. The *treatment* consists in excision of a V-shaped portion, suturing the raw surfaces subsequently with catgut. In some cases macroglossia

is an evidence of hypothyroidism, and some striking cures have been reported after the use of thyroid extract.

Wounds of the tongue are usually caused by the teeth, especially in children, either during an epileptic fit or as a result of falls. There is often brisk hæmorrhage for a few moments, but the blood may be extravasated into its substance, and causes considerable swelling. In simple cases the wound should be purified, and the mouth constantly cleansed; a few points of suture may be inserted if necessary, but the wound must not be entirely closed, or tension from infection will result. When smart arterial bleeding is present, the wounded vessel must be sought for and tied.

Acute Superficial Glossitis occurs as part of a general stomatitis, and needs no special notice.

Acute Parenchymatous Glossitis, or acute inflammation of the tongue, may arise from penetrating and infected wounds, or from the bites or stings of insects, or may be associated with acute stomatitis in the course of fevers, or with the injudicious administration of mercury. The condition may be limited to one half of the organ, but when arising from general causes is bilateral. The tongue becomes painful, swells up rapidly so as to fill the mouth, and even protrudes beyond the teeth, the pressure of which leads to superficial ulceration. The salivary glands are enlarged and painful, and salivation is a marked feature in the case. Speech, swallowing, and even respiration are much interfered with, and there may be considerable febrile disturbance. The case, if treated with care, usually ends in resolution; but diffuse or localized suppuration may ensue, as well as the most urgent dyspnœa, arising either from œdema glottidis or from the pressure of the enlarged organ. *Treatment* consists in stopping the mercury, or removing any evident cause, and in the administration of saline purgatives with chlorate of potash. Ice should be sucked, and an ice poultice applied to the submaxillary region. In bad cases free incisions into the dorsum should be made on either side of the median line to give exit to the effused fluids and blood. If asphyxia is threatening, high tracheotomy or laryngotomy is required.

Abscess of the tongue may result from the acute process described above, but is more usually of a chronic nature, and situated at the anterior part of the organ. It is generally due to the admission of micro-organisms through some superficial lesion which has quickly healed. It presents as a tense swelling, fluctuation in which may be marked by the amount of inflammatory thickening which surrounds it. A free incision both settles the diagnosis and cures the case.

Sublingual Abscess, when acute, is due to infection of the submucous tissue, as by puncture with a fish-bone, or starts in a follicle of the sublingual or in a submucous gland. A puffy swelling forms beneath the tongue, which, if not opened early, may lead to an extension downwards of the mischief into the submental region. The tongue becomes swollen and turgid from pressure upon the veins, whilst œdematous laryngitis may also be induced. Considerable constitutional disturbance generally accompanies this process. A median incision through the mucous membrane, and the insertion and opening of a

pair of dressing forceps, is the safest and best method of treatment the cavity being subsequently washed out and drained. The more diffused form of sublingual abscess is usually associated with submaxillary cellulitis (p 62).

Chronic Streptococcal Glossitis.—This condition is of fairly common occurrence, and must be distinguished from a similar disease caused by syphilis. Adults are the chief sufferers, generally females, but children may be affected. The condition is caused by subepithelial activity of streptococci, and by suitable measures it is possible to obtain cultures of the organisms from the submucous layer. The inflammatory signs may be more or less limited to the surface, and appear as localized patches of hyperæmia and overgrowth of papillæ, together with superficial heaping up of sodden epithelial squames in neighbouring regions; by desquamation of these cells certain parts of the tongue become denuded and of a smooth appearance, while in other places infolding of the superficial layers gives rise to apparent fissuring. *Treatment* is as for chronic superficial glossitis.

Chronic Superficial Glossitis is an interesting and important disease, which may be associated with a similar condition of the mucous membrane lining the interior of the cheeks and lips. It is most commonly due to tertiary syphilis, but may arise from excessive smoking, ragged and rough teeth, or spirit-drinking, chronic dyspepsia, perhaps of a gouty nature, being also present in many cases. It is very liable to be followed by epithelioma (25 per cent. of the cases).

For purposes of description it is useful to divide the disease into the following five stages, although it must be clearly understood that they are artificial, and several of them may be present in different parts of the same tongue: (i.) The papillæ become enlarged and swollen, leading to the appearance of red hyperæmic patches, which cannot be recognized for certain unless the tongue is thoroughly dried with a handkerchief, towel, or piece of clean blotting-paper, which must not be carelessly dabbed over the organ, but should be firmly pressed down so as to absorb all the moisture. (ii.) Overgrowth of epithelium follows, and as it increases in thickness it becomes opaque and horny, so that the red patches are replaced by white ones, leading to the appearance which has been designated *Leucoplakia*. Sometimes the papillæ become much enlarged, and stand out definitely and separately from the organ; or the whole surface may be covered with dense white patches. To this condition the term *Ichthyosis* has been applied. (iii.) Later on the excess of epithelium is shed, leaving red smooth patches in which the papillæ are atrophied, or have entirely disappeared. If this occurs over the greater part of the organ, the *glazed red tongue* so characteristic of tertiary syphilis is produced. If, however, this process only occurs in smaller areas intermixed with portions covered with white epithelium, a patchy appearance of the tongue results, wrongly termed *Psoriasis linguæ*. (iv.) At varying periods of the disease, sometimes earlier, sometimes later, the organ becomes ulcerated, *cracked*, or *fissured* in a somewhat characteristic manner. A median fissure is usually seen running down the middle, and from

this furrows extend transversely, dividing the surface into rectangular compartments. These fissures are not always due to the cicatrization of cracks, as when opened out healthy papillæ are seen at the base, and no sign of superficial scarring. They are, then, evidently the result of the contraction of deep sclerosed tissue in the substance of the organ. Superficial ulceration often occurs, owing to some local irritation, or to smoking; the atrophic condition of the mucous membrane explains the great liability to this occurrence. (v.) Still later, epithelioma may develop, and usually in connection with one of the cracks, or of the cicatrices arising therefrom. It is often somewhat slow in its progress, owing to the amount of sclerosis induced by the preceding inflammation.

The typical *smoker's patch* is a red irritable area on the front of the tongue, from which papillæ are often absent, and perhaps covered with a yellowish-white crust. Sometimes the epithelium is heaped up here into a well-marked leucoplakic spot.

The disease is always accompanied with much discomfort, the tongue being sometimes so tender that the patient cannot drink hot fluids or take condiments or stimulants without pain. The speech becomes thick and indistinct. The affection may settle down after a time, and remain quiescent, so long as the patient conforms to the restrictions as to diet, etc., which are essential. If, however, he is careless or refuses to obey orders, the trouble may progress, and epithelioma develops.

Treatment.—All sources of irritation are excluded from the mouth as a first precaution. Thus, smoking or chewing tobacco must be rigidly prohibited. Alcohol is forbidden, but if essential whisky well diluted is permitted. Condiments, such as mustard, spices, curry, and cheese, are excluded from the dietary, and only simple unirritating ingesta allowed. The mouth is washed out frequently with an alkaline lotion, *e.g.* bicarbonate of soda (20 grains to 1 ounce), or borax (10 grains to 1 ounce), especially after meals, so as to exclude all risk of acid fermentation in the débris of food. The teeth must be brushed night and morning, and all stumps and rough excrescences removed; definite pyorrhœa must be carefully treated. Gaps between the teeth should be filled by artificial teeth fitted to a smooth plate. Cracks and sores may be treated by painting the surface with a solution of chromic acid (grs. v. ad ℥i.) or of perchloride of mercury (grs. ii. ad ℥i.), but it is better to excise them completely, as also any wart-like formation. Solid nitrate of silver should particularly be avoided, as its use is likely to predispose to epithelioma.

Careful attention is given to the digestion, and general antisyphilitic remedies are employed where necessary, even including salvarsan, but mercury must be used with discretion.

On the appearance of definite epithelioma suitable operative measures must be instituted, as radium therapy does not give good results in these cases.

Ulceration of the tongue arises from a variety of causes, and occurs in many different forms. Thus, **dental** or **traumatic** ulcers, due to the irritation of rough and carious teeth, are generally seen at the margins

of the organ. **Dyspeptic** ulcers are associated with gastric disturbances; they are usually located on the middle of the dorsum, and are often very painful. **Tuberculous** ulcers are not common, and are nearly always secondary to pulmonary or laryngeal phthisis. They commence in the form of a submucous abscess, which bursts and leaves a small painful sore, usually situated at the sides or on the dorsum near the tip. Secondary abscesses form around and coalesce with the original ulcer. *Treatment* is chiefly needed on account of the pain and discomfort, and consists in complete excision, or in cocainizing and scraping the sores, touching the base with pure carbolic acid, and dressing with iodoform. Applications of cocaine may also be made before meals, as a palliative measure, when radical treatment is contraindicated because of the extent of the pulmonary mischief. Occasionally tuberculous disease appears in the form of a painful fissure, which on being opened up reveals a mass of pulpy granulations, and possibly caseating nodules, lying in a cavity of some size; the margins of the fissure are sometimes the seat of overhanging papillary growths (**tuberculous papilloma**). Excision is essential in these cases. All tuberculous lesions are naturally liable to become infected by the mouth bacteria, and many diverse appearances result from this cause; apart from this, all tuberculous ulcers are free from induration. **Lupus** also attacks the tongue, but is very uncommon, and almost invariably secondary to a similar affection of the skin of the face. In a case under our care it appeared in the form of an irregular granulating surface surrounded by nodulated cicatricial tissue of an exceedingly dense character. The progress was very slow, owing to the amount of sclerosis present. *Treatment* consists in the application of the X-rays or of radium.

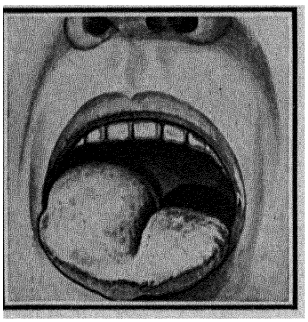

FIG. 643.—GUMMA OF RIGHT SIDE OF TONGUE. (FROM WAX MODEL IN COLLEGE OF SURGEONS MUSEUM.)

Syphilitic Disease of the tongue occurs in a variety of different forms. A *primary* sore presents a characteristic indolent and inactive surface, usually near the tip, with subjacent infiltration, and much chronic enlargement of the submental lymphatic glands, which, however, do not generally suppurate. In the *secondary* stage mucous tubercles, fissures, and ulcers form, and usually on the sides or near the tip. Occasionally a broad wart-like condyloma develops on the dorsum, which may be associated with longitudinal fissures; it is sometimes termed ' Hutchinson's wart.' In the *tertiary* period chronic superficial glossitis occurs, as also diffuse infiltration or gummata.

Gumma of the tongue is not uncommon, occurring usually in patients under forty years of age, as a late tertiary phenomenon. It starts as a localized submucous or intramuscular infiltration near the median line, and generally towards the middle or posterior part (Fig. 643). The swelling is at first hard and firm, but later on becomes soft and

fluctuating, and in time the overlying mucous membrane, which was unaffected, yields, and gives exit to the characteristic contents. The ulcer thus produced is oval or round in shape, and deeply excavated, the base being constituted by a slough. There is but little induration either of the base or edges, and neither the floor of the mouth nor the base of the tongue is involved, so that the organ can be freely protruded, whilst deglutition and articulation are scarcely interfered with. The patient complains of little pain, and the neighbouring lymphatic glands are seldom affected. The progress is slow, and the effect of antisyphilitic treatment very decided, the gumma being absorbed, or the ulcer, if present, healing readily, but leaving a localized area of sclerosis or a deep cicatrix, from which malignant disease may subsequently originate. In some cases a diffuse infiltration of the organ occurs, leading to a generalized sclerosis rather than to a localized gumma. The *treatment* consists in the administration of iodides with or without mercury, and the mouth is kept clean with a simple mouth wash.

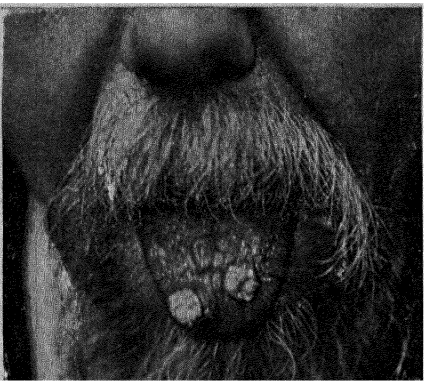

FIG 644 — PAPILLOMATA OF TONGUE, SECONDARY TO CHRONIC SUPERFICIAL GLOSSITIS

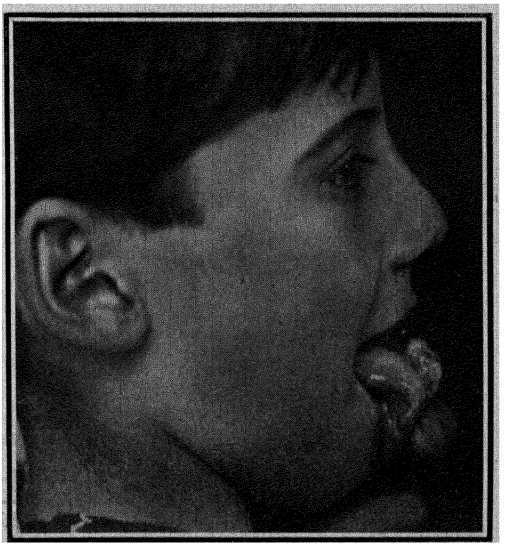

FIG 645 —PAPILLOMA OF THE TONGUE IN A BOY ÆT 8

Innocent Tumours are not frequent in the tongue, cysts, lipoma, and nævi being the chief varieties, and requiring no special description.

Dermoid Cysts also form within or under the tongue, occupying the middle line, projecting either into the floor of the mouth or beneath the chin. They are due to non-obliteration of the upper end of the thyroglossal duct. The contents are of the usual sebaceous type.

Such tumours should rarely be dealt with from the mouth, as they extend deeply, and need to be carefully dissected out. A free incision should be made beneath the chin, and the whole cyst removed unopened.

Papilloma of the tongue (Fig. 644) is not uncommon in young subjects (Fig. 645), and may precede an outbreak of cancer. It may develop in a tongue, or may follow chronic superficial glossitis in adults. So long as the base is free from infiltration, it may be looked on as innocent; but it is always to be considered as a pre-cancerous condition, and must be removed with the knife.

Cancer of the Tongue is both a frequent and a very fatal variety of this disease. It is usually met with in men, and may arise as a result

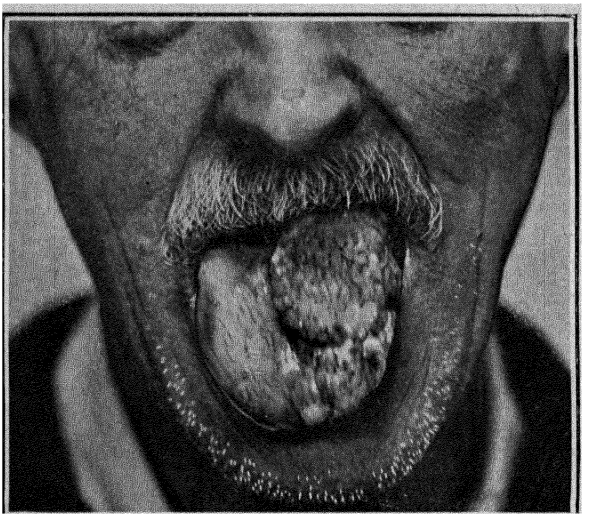

FIG. 646.—EPITHELIOMA OF THE TONGUE

In this case the patient presented himself with a large growth on the left side with leucoplakic patches on the right side. Glands were enlarged. The left half of the tongue was removed, and subsequently the glandular area dissected out. Nine years later he was again admitted for similar disease on the other side.

of the irritation caused by excessive smoking, especially when neglected, rough, and carious teeth are present. An underlying strain of syphilis is also frequently present in these cases.

Its mode of onset varies somewhat according to the situation: (*a*) It arises most commonly as an ulcer at the margin of the organ, towards the junction of the middle and posterior thirds, and is then generally due to the irritation caused by ragged and irregular bicuspid or molar teeth; (*b*) it may start in a crack, fissure, or cicatrix on the dorsum, as a result of chronic superficial glossitis, or of a preceding gumma; (*c*) it may commence as a wart-like growth, the base of which becomes infiltrated, the tumour invading the muscular

substance, and spreading to the root of the tongue, (*d*) it may originate as a submucous infiltration, starting as an ingrowth from the mucous membrane, without much external manifestation of its presence, (*e*) it may first be noticed as an irregular ulcer in the floor of the mouth, or (*f*) it may spread into the tongue from surrounding parts, such as the tonsil or larynx.

The type of disease varies also with the site. The anterior two-thirds of the tongue differs structurally and functionally from the posterior one-third. The former is covered with papillæ, the superficial end organs of taste; the latter has no papillæ, but contains much lymphoid tissue, the so-called lingual tonsil.



FIG 647.—LARGE CARCINOMATOUS ULCER AT THE SIDE OF THE TONGUE

In the anterior two-thirds the neoplasm is a squamous-celled carcinoma with typical cell nests and infiltrating columns of epithelial cells. The posterior third gives rise to an anaplastic form of growth with no cell nests, a tendency to metastasize early, the secondaries sometimes being found before the primary, and a high degree of malignancy. It is, however, radio-sensitive. The typical features are as follows: *viz.* a new growth is noticed (Fig. 646), hard in consistence, indefinite in its extent, which may or may not be painful from the first, and which ulcerates superficially, with a grey, sloughy, foul surface, readily bleeding when touched, and discharging a foul secretion, which causes extreme fœtor of the breath. Sometimes an excavated ulcer develops, surrounded by an indurated mass, which gradually shelves off into the neighbouring healthy structures, or may be abruptly limited (Fig. 647). Profuse salivation is produced, and all movements of the tongue are painful and limited on account of the infiltration of the base, so that both swallowing and speech are difficult, the patient often allowing the saliva to dribble out of his mouth. The pain is usually severe, and extends along many of the branches of the fifth nerve, especially to the ear.

In a number of cases, however, where the disease starts deeply in a fissure, or in the submucous variety, ulceration may be a late symptom, the disease infiltrating widely before an ulcer develops.

The lymphatic drainage of the tongue is important. The tip drains via the submental glands to the upper deep cervical lymph glands. The

margin and dorsum of the tongue drain via the sublingual and submaxillary gland to the upper deep cervical group. The posterior third drains by lymphatics through the pharyngeal wall to the jugulo-digastric group and thence to the upper deep cervical group of glands. Those at the tip drain impartially to the glands of both sides of the neck. The margin and dorsum, although there is a communication between the lymphatics of both sides of the tongue, clinically usually involve the gland only of the same side, unless the growth extends very near to or across the mid-line, when both sides of the neck may be involved (Fig. 648). Ultimately the disease spreads to the deep glands lying along the main vessels, a gland lying over the bifurcation of the common carotid artery being early enlarged. These glands, if not removed, soon attain considerable dimensions, and become stony hard and fixed to surrounding structures, especially the carotid sheath. These secondary growths not uncommonly become cystic in character, from the degeneration of the masses of epithelium formed within them; after a time they approach the surface and burst, leaving ragged malignant ulcers in the neck. The lower jaw itself is often invaded in the later stages of the disease. The occurrence of the typical cachexia is determined not only by the pain and consequent sleeplessness, but also by the inability to take sufficient nourishment, the absorption of products of putrefaction swallowed with the saliva, the excessive salivation, the occasional hæmorrhages, and the extent of the secondary growths. The patient rarely lives, apart from treatment, for more than twelve months after the disease has been first noticed. Death is due to exhaustion, hæmorrhage, or septic pneumonia.

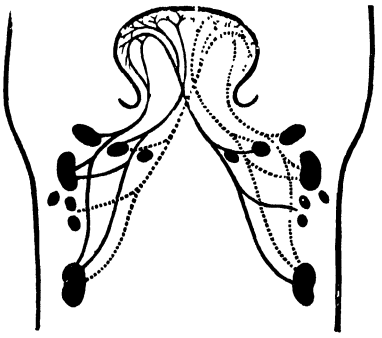

FIG. 648.—DIAGRAM SHOWING THE LYMPHATIC DRAINAGE OF THE TONGUE.

Diagnosis.—When a case is met with where the ulcer is situated at the side or base of the tongue in a patient over forty-five years of age, with the typical enlargement of the glands, profuse salivation, and impaired movements, there can be little doubt as to the diagnosis. But when it is seen in the early stage as an infiltration of a syphilitic fissure or cicatrix, or as a small wart, it may be difficult to determine whether or not malignant disease is present. The early enlargement of the glands, the amount and character of the pain, the fixity of the organ, and the infiltration of the base of the ulcer are important guiding marks; but in doubtful cases a small portion of the edge of the growth and of the adjacent parts should be excised under cocaine, and subjected to careful microscopic examination, and thus its nature ascertained. Moreover, the fact of improvement after the administration of steadily increasing doses of

iodide of potassium does not exclude the presence of cancer, as the two conditions so often co-exist.

Treatment of cancer of the tongue includes treatment of the tongue and of the glands of the neck. There are two methods of treatment, **Excision** and **Radiation.**

Treatment by excision consists in thorough and early removal of the growth, which it should be remembered has probably extended much further than one expects. The excision must include not only the tumour, but also a wide area of tissue around it, so as to get well beyond the zone of infiltration; not only the lymphatic glands, which are obviously enlarged, but also the whole lymphatic area, extending practically from the base of the skull to the episternal notch. It is obviously desirable to undertake such extensive operative proceedings in two stages, if possible, dealing first with the tumour in the mouth, and subsequently with the glands. The fact that recurrence is rarely noted in the portion of the organ that intervenes between the two operative areas indicates that such a practice, though not ideal, is justifiable.

In all cases great care must be taken in the preparation of the patient so as to minimize the risk of infective mischief, whether treatment by radiation or excision is intended. Before radiation all metal fillings and bridgework must be removed, as these cause secondary radiation with risk of necrosis. Suitable antiseptic mouth-washes are employed for some days; dirty roots and stumps are removed, the remaining teeth carefully scaled, and tartar removed, and the mouth given time to heal. Possibly, if time permit, a culture might be made of the chief organisms in the mouth, and a vaccine procured which may help to guard the patient from post-operative infection. It is also wise to keep him indoors for a few days beforehand, so as to protect him from risks of cold and bronchitis, and to stop all smoking. He should also practise feeding himself with a cup to which is attached a rigid tube, so that he will be accustomed to this after the operation.

The actual operative details differ somewhat according to the extent and situation of the disease, but most of the operations for removing the growth are a modification of the intrabuccal method suggested by Whitehead.

If the *tip* only is involved, it can be removed by a V-shaped incision, made after steadying the tongue with a deep suture. The small ranine artery will spurt on each side, but is easily secured, and the gap is then closed by sutures.

When the disease involves one side of the tongue and is not very extensive, and does not spread deeply into the base, it will suffice to remove the *anterior half* or two-thirds of the affected side as a first stage without touching the glands. The patient having been anæsthetized, the mouth is opened with an efficient gag, and anæsthesia is maintained by intratracheal insufflation, with a laryngeal pack to prevent any access of blood to the trachea. A coarse silk thread is passed through each half of the tongue to draw it forwards and steady it. The tongue, being drawn out of the mouth by these loops of silk,

is carefully divided by blunt-ended straight scissors down the middle line into two segments, which are readily separated from one another by the finger, the scissors merely dividing the mucous membrane. The base of the organ is freed by cutting through the mucous membrane close to the alveolus, and then along the middle line of the floor of the mouth, so that the sublingual salivary gland can be also taken away—a most necessary step. The blunt end of a curved pair of scissors is then pushed down behind the symphysis, and the attachment of the genio-hyoglossus to the bone divided, thereby enabling the tongue to be drawn out much more effectively. The mucous lining of the dorsum is now divided transversely behind the growth, and the muscular structure of the organ slowly nipped through with scissors. During this process, by the aid of the finger or a director, the vessels can be seen and secured before division. Removal of the diseased half with the sublingual gland is thus easily accomplished by making the incisions meet, and dividing the intervening tissues. Bleeding-points are picked up and secured as they appear. It is always advisable to expedite healing by closing the wound in the tongue partially or entirely, either by stitching the mucous membrane of the dorsum to that of the base, or by twisting the half-tongue on itself and stitching the tip to the back of the organ. The patient will probably be sufficiently recovered from this operation to enable the surgeon to deal with the glands in a week or ten days.

If both sides of the tongue are involved, but the disease has not extended deeply into the base, it is not difficult to effect removal by a modification of the same procedure. The mouth is gagged open, and two silk slings are inserted, one through the anterior portion and the other just in front of the epiglottis. The mucous membrane of the floor of the mouth is then incised on either side, and the muscles attached to the genial tubercles divided. By this means the tongue is considerably loosened and can be drawn well up out of the mouth, so as to enable the section to be made across it with scissors at the desired level. The main vessels can generally be seen and secured before division, and the amount of bleeding is not excessive. It is often possible to draw forward the stump of the tongue and secure the mucous membrane anteriorly, so as to diminish the size of the raw area in the mouth.

The **After-Treatment** is much the same in all cases. The raw surface may be painted with Whitehead's varnish (which consists of friar's balsam, but with the rectified spirit replaced by a saturated solution of iodoform in ether); the all-essential thing, however, is to keep the cavity well irrigated with antiseptic lotions, such as weak solutions of boric acid, boroglyceride (1 in 20), sanitas or lysoform. The patient must be closely watched for the first forty-eight hours, to see that his respiration is not obstructed by the stump of the tongue falling backwards; but at the end of that time this danger will be at an end. It is not desirable to keep him in bed more than two or three days. The patient is fed *per rectum* for twenty-four hours, but afterwards a tube attached to the spout of a feeder is introduced into the pharynx or œsophagus. In the simpler cases he is able to swallow freely and

without difficulty in the course of a day or two, and even in the worst cases he can feed himself with a long tube passed into the pharynx in five or six days. The chief dangers of the operation arise from septic contamination, resulting in secondary hæmorrhage or septic pneumonia; and these are best avoided by careful and thorough preparation of the patient.

The removal of a part of the tongue is not such a mutilation physiologically as one might expect at first. Deglutition is interfered with for a time, but the power is soon regained, and even articulation may be in great measure restored.

The glandular field may alone be treated either by excision or by radium. A block dissection of the glands should be undertaken only where these are clinically palpable yet operable, and when the primary has been completely removed. In those cases where no glands are palpable, or when they are so fixed as to be inoperable, then radiation is the method of choice. No mistake must be made here in the case where the glands are impalpable. Treatment is still essential or secondaries will develop, but radiation rather than surgery is the method of choice.

It is a wise precaution in those cases where clinically one side presents palpable glands, and dissection is undertaken, to irradiate the other side. It will be remembered the lymphatics of the tongue cross freely.

The operation for **removing the glandular area** in connection with cancer of the tongue is a serious proceeding, as its scope should extend from the mastoid process to the episternal notch. If the disease has involved both sides of the tongue, both sides of the neck must be cleared, and even when the disease has only apparently affected one side of the tongue, the glands on both sides of the neck may be involved. The incision extends along the anterior border of the sterno-mastoid throughout its whole length, and a second incision meets it, reaching from the chin to just below the great cornu of the hyoid bone. The flaps thus marked out are dissected up and turned forwards, the platysma being included in them. The cellular tissue of the submental and submaxillary regions, together with all lymphatic glands and the submaxillary salivary gland (except the deep process and duct), is dissected up from before backwards and turned back towards the main vessels. The internal jugular vein is then laid bare, and all the lymphatic glands lying upon it are dissected upwards from below or downwards from above. All the cellular tissue of the anterior triangle is cleared away in one piece with the glands, extending from that which lies under cover of the omo-hyoid below to those which are placed beneath the posterior belly of the digastric and lower edge of the parotid above. The facial and lingual arteries will have to be secured back and front; the external jugular vein is sacrificed, and if need be the internal should also be taken away; but the facial and spinal accessory nerves must be spared. Careful deep suturing will minimize the deformity, but it will be necessary to drain the lower part of the wound.

Treatment by Radiation.—Treatment by radiation in cancer of the tongue is now the method of choice. The insertion of needles

is not a formidable proceeding; the tumour frequently shrinks up and may completely disappear in some cases, the mobility and full function of the tongue returning. Further, in advanced cases where only palliation is possible, much may be done to alleviate the patient without subjecting him to the mutilating operations previously practised.

It is just as necessary in treating a case of carcinoma of the tongue with radium to eliminate oral sepsis by a scrupulous toilet of the mouth

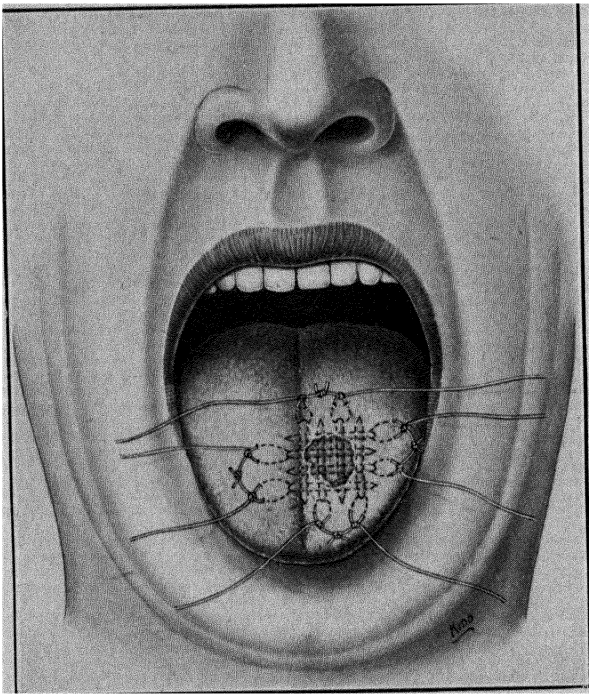

FIG. 649.—RADIUM NEEDLES INSERTED AROUND A GROWTH IN THE TONGUE

as suggested above. Local anæsthesia can be used, but it is considered inadvisable, as it increases the amount of fluid in the tongue, and radium does not react so well in œdematous tissues. For this reason intratracheal ether should be administered in these cases. When the patient is under the anæsthetic, the surface of the tongue should be dried and the extent of the growth ascertained as accurately as possible.

In lesions of the anterior two-thirds, the method of choice is by interstitial radium. The needles, which contain 1 or 2 mg. of radium, are inserted deep into the growth, forming a palisade (Figs. 649 and 650). The needles must be parallel and not radially inserted. Radial insertion results in an overdose in the centre where the needles are close

together and inadequate dosage at the periphery. This results in a sloughing ulcer with a neoplastic edge that continues to infiltrate the tongue. The radium should be left in position for seven to nine days, the dosage varying from 1,500 to 2,500 mg. hours. A larger dose may be needed in extensive lesions.

The needles are secured, each with a double thread, one end of which is passed through the substance of the tongue, and back of the thread of the other needles, thereby preventing them from shifting.

The posterior third of the tongue presents a special problem; radium needles are difficult to insert and to keep in position in this inaccessible area. Accordingly, where available, treatment with a *radium bomb* is the ideal method; failing that by deep X-rays.

If interstitial radiation is used, the threads may be secured by passing them through the nose and strapping them to the cheek.

Mention must be made of a new line of treatment recently introduced for squamous-celled carcinoma by Professor Chaoul. Low-voltage X-rays are applied in repeated small doses, and the results to date have been reported to be satisfactory.

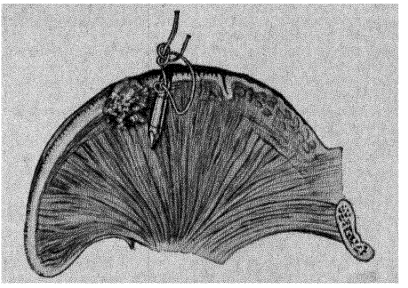

FIG. 650.—METHOD OF INSERTING AND RETAINING A RADIUM NEEDLE IN THE TONGUE.

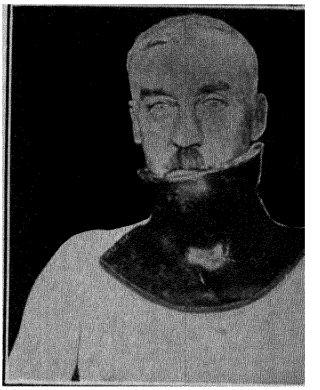

COLLAR APPLIED TO THE NECK.

Whatever method is applied to the primary growth, the glandular fields need equal attention. The indications for excision have already been given.

Where radium is to be used it is best applied by means of a Columbia paste* (Fig. 651) or Sorbo rubber collar, 3 to 4 cm. thick, to the outer aspect of which 2 to 3 mg. radium needles are applied by means of adhesive strapping. The total post-operative dose should be in the region of 10,000 mg. hours. This necessitates wearing a collar about sixteen hours a day for two weeks.

Deep X-ray therapy may be employed instead of radium, with similar results.

In some cases deep X-rays or a radium collar may be used following a block dissection as an additional safeguard.

* Columbia paste = a wax consisting of beeswax, paraffin, and sawdust.

Affections of Salivary Glands.

Inflammation of the Parotid Gland is met with in several different forms.

1. **Epidemic Parotitis (Mumps)** is a highly infectious acute specific disease usually seen in children. The period of incubation is about three weeks, and the attack itself consists in a slight febrile disturbance, associated with swelling of one or both parotid glands; one gland is attacked first, becoming enlarged and tender, whilst the other side is similarly affected in a day or two. Mastication becomes difficult, owing to the tension of the parts. The swelling usually persists for about a week and then gradually subsides; it extends below and in front of the ear, and the socia parotidis can be felt lying over the masseter; the submaxillary, sublingual, and neighbouring lymphatic glands are sometimes enlarged. Suppuration is rare, but in adults metastatic inflammation of the testis, mamma, or ovary is not uncommon. This complication is generally unilateral, and thus, although atrophy of the testis commonly follows orchitis, sterility is not produced. *Treatment.*—Keep the patient warm and quiet, and administer salines. In the later stages friction with stimulating liniments will hasten resolution. After an acute attack, the gland may remain enlarged for some time.

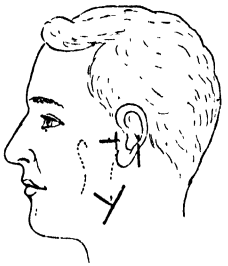

FIG. 652.—INCISIONS USED IN OPERATING UPON CASES OF SUPPURATIVE PAROTITIS.

2. A **Simple Parotitis** occasionally results from exposure to cold or from injury, whilst the presence of a calculus in the duct leads to a chronic sclerosing inflammation. The symptoms consist of pain and swelling, together with a certain amount of constitutional disturbance. Occasionally unilateral or bilateral parotitis may result from irritation of the gums and obstruction of the orifice of Stenson's duct by a large upper denture, especially if the latter is rough and covered with débris, due to lack of cleaning. **Post-operative Parotitis** was a fairly common complication of abdominal operations before it became known that the infection was a buccal one and reached the gland by the parotid duct. Today it is very rare, since oral sepsis is always treated before any abdominal operation is contemplated. *Treatment* should be prompt, incision and drainage being required. Incision should not be delayed until fluctuation can be elicited. It is only in the later stages that fluctuation can be made out, and this is due to the fact that the parotid is encased in a very firm capsule derived from the cervical fascia, and the texture of the gland is very firm. A ⊥-shaped incision should be made and the skin and parotid capsule incised; the gland should then be explored with a pair of sinus forceps or a probe. A single ⊥-shaped incision is often sufficient, but at times multiple incisions are necessary (Fig. 652).

3. **Suppurative Parotitis** is a much more serious condition. It may extend from the mouth along Stenson's duct, or supervene in the course of pyæmia, or as a sequela of some of the exanthemata, *e.g.*

scarlet or typhoid fevers. The gland becomes enlarged, with congestion and œdema of the overlying skin, and, owing to the tension of the fascia, exceedingly painful. *Treatment.*—If early incisions are not made into the gland, the pus finds its way to the surface by bursting into the external auditory meatus at the junction of the osseous and cartilaginous portions. The gland itself undergoes necrosis and large sloughs are formed. The incisions illustrated in Fig. 652 will be found very useful. Early free incisions are imperative; mere puncture of the gland or probing it with sinus forceps is useless.

Inflammation of the submaxillary and sublingual glands may arise in an exactly similar way, but no special description is called for. Occasionally, however, the process extends beyond the submaxillary glands to the neighbouring tissues, giving rise to what has already been described as submaxillary cellulitis, or Ludwig's angina.

Ranula is a cystic swelling of the floor of the mouth, containing a glairy mucoid fluid which is not saliva. There has been much con-



FIG 653.—CALCULUS REMOVED FROM DUCT OF SUBMAXILLARY GLAND (ACTUAL SIZE).



FIG 654.—CALCULUS REMOVED FROM DUCT OF SUBMAXILLARY GLAND.

troversy as to its origin, and the matter is as yet unsettled. It has been attributed to obstruction to Wharton's duct or to blocking of one of the sublingual ducts (ducts of Rivini); but neither suggestion corresponds with observed facts. The most likely explanation is that it is due to distension of a displaced portion of a lateral dermoid of the neck; the cervical sinus remains unobliterated, and is carried forwards by the extensive migration of the muscles that enter into the tongue. The tumour is usually unilateral, and may become as large as a pigeon's egg.

Treatment consists in complete extirpation, if possible, a careful search being made for any outlying projections or communicating tracks. Too often the cyst bursts during this procedure, and its limits being then lost, all the surgeon can do is to remove as much of it as possible by torsion or dissection, and to pack the cavity and allow it to heal by granulation.

Obstruction to the Flow of Saliva results from various causes, such as cicatricial contraction in the neighbourhood of the entrance of the

duct into the mouth, or from the presence in the duct of a **salivary calculus,** consisting of phosphate and carbonate of lime, and usually fusiform in shape (Figs. 653-655). Calculus formation more frequently occurs in connection with the submaxillary and sublingual glands, since the saliva secreted by them is thick and mucoid, whereas parotid saliva is limpid in character. The majority of salivary calculi are opaque to the X-rays (Fig. 656).



FIG. 655.—SUBMAXILLARY GLAND WITH A CALCULUS IMBEDDED IN IT.

The chief *Symptom* is a painful enlargement of the gland during and after meals, gradually disappearing as the saliva finds its way past the block; in old-standing cases the gland becomes chronically enlarged, and its interstitial tissue increased in bulk, whilst a certain amount of periadenitis also follows. When a calculus is present, there is usually a considerable discharge of offensive mucopus into the mouth. Where the obstruction is complete a cyst may form, and if this is opened, or finds its way to the exterior and bursts, a salivary fistula results.

Sialography.—Mention must be made here of the radiographic demonstration of the ramifications of the duct of the parotid gland by means of the injection of a radio-opaque substance down the duct, followed by an X-ray photograph. This method may be used to localize a calculus, to show the presence of cavities in a chronically infected gland, and to define the course of a fistula (Fig. 656). Lipiodol is the substance usually used; it has the advantage of being antiseptic as well as radio-opaque. The total amount required should not exceed 1 c.c., and should be at body temperature.

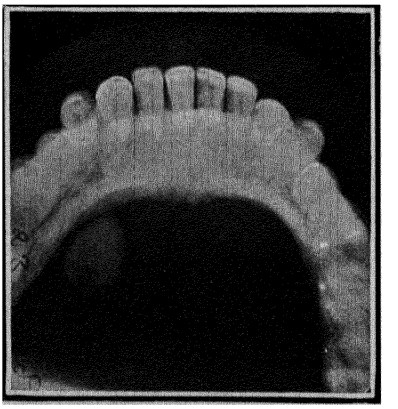

FIG. 656.—SKIAGRAM SHOWING CALCULUS IN DUCT OF SUBMAXILLARY GLAND.

Treatment.—In cases of simple obstruction an attempt must be made

to restore the natural exit, or to make an artificial one. A calculus can usually be seen or felt at intervals projecting from the entrance of the duct, which must then be incised from the mouth, and the

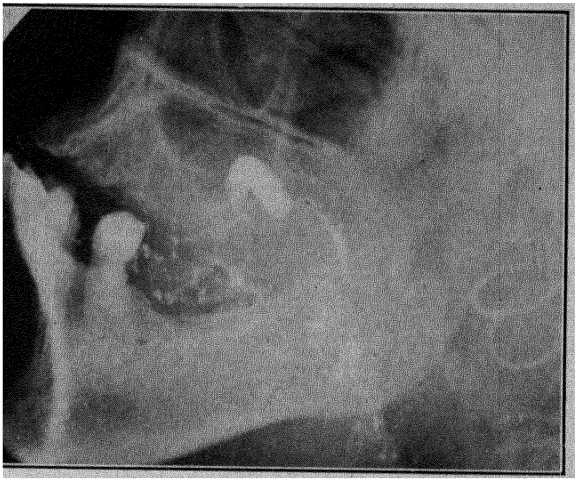

FIG. 657.—SIALOGRAM SHOWING A STRICTURE OF THE PAROTID DUCT FOLLOWING THE IMPACTION OF A STONE.

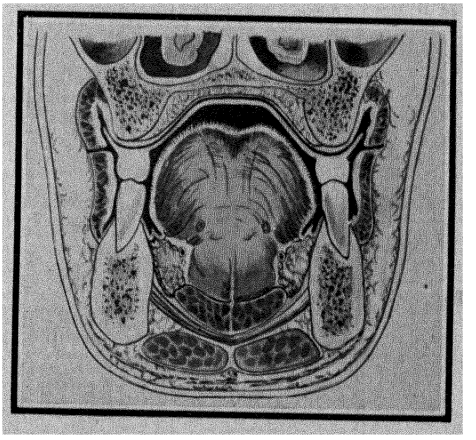

FIG. 658.—DIAGRAMMATIC DRAWING THROUGH THE MOUTH, SHOWING THE RELATION OF AN UPPER DENTURE TO THE ORIFICES OF STENSEN'S DUCTS.

stone removed. If placed deeply in the substance of the submaxillary, total removal of the gland should be performed (Fig. 655).

Chronic Parotitis may follow irritation of the opening of the duct in the mouth by badly fitting dentures (Fig. 658). Acute emphysema of the gland can occur in glass-blowers, wind instrument-players, etc.,

and it has also been produced artificially by malingerers in war-time. The emphysematous appearance may be alarming, but it rapidly subsides in the course of a day.

Salivary Fistulæ.—Fistulæ of the submaxillary gland are uncommon and usually heal of their own accord; the rare cases which do not are easily treated by excision of the gland. Parotid fistulæ are not very rare, and may be divided into two groups, according to whether they involve the duct or the gland.

Fistulæ of the parotid *gland* and duct are most frequently caused by injury or by suppuration around a calculus. In operations for

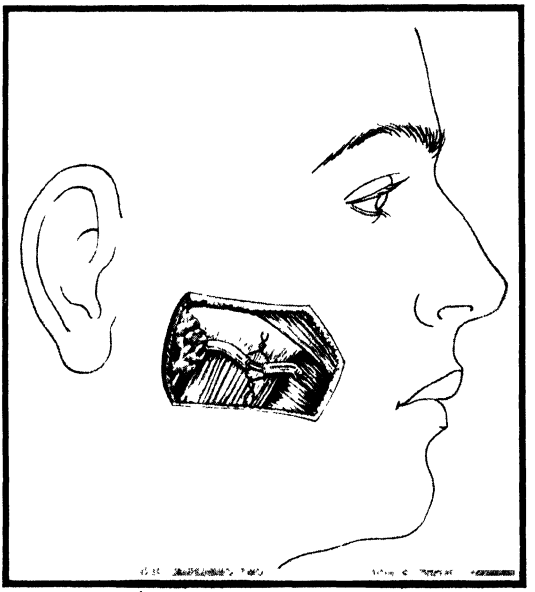

FIG. 659.—METHOD OF SUTURING THE PAROTID DUCT OVER A PIECE OF SILKWORM GUT.

removal of glands from the upper part of the neck, the lower part of the parotid may be wounded, and a small fistula will result which generally heals almost at once, unless the wound becomes infected, when a permanent fistula invariably results. When the duct is involved, the nearer the lesion is to the gland, the more difficult it is to cure. Spontaneous healing is unknown, and the portion of the duct in front of the fistula frequently becomes stenosed and sometimes obliterated. Should the fistula be situated in front of the masseter, operation will often cure. In recent cases, such as a stab injury, the wound should be opened up and the two ends of the duct isolated. A piece of stout silkworm gut is passed from the mouth through the orifice of Stensen's duct and out on to the face; it is then passed into the proximal portion

of the duct and thus acts as a dowel (Fig. 659). The wall of the duct is sutured over the piece of silkworm gut, and the skin wound closed. In order to prevent a clot forming in the duct at the line of suture, the silkworm gut is retained *in situ* until the patient recovers from the anæsthetic. This method is only of use when the wound is recent. If in a recent case there is difficulty in getting apposition of the divided ends of the duct the proximal portion should be ligatured; in the absence of sepsis this will cause atrophy of the parotid. If, however, infection is present, septic parotitis will follow.

In old-standing cases of pre-masseteric fistula the following procedure will sometimes suffice: A straight needle threaded with silk is passed through the fistula into the mouth; the needle is then unthreaded, and the piece of silk outside the mouth is threaded on to it. The needle is then inserted through the fistula into the mouth a second time. The two ends of the silk are then tied in a knot. The included piece of tissue which is strangulated by the suture dies and sloughs, and by this means an opening is made into the mouth. As the parotid secretion has now a free vent into the mouth the fistula heals (Fig. 660).

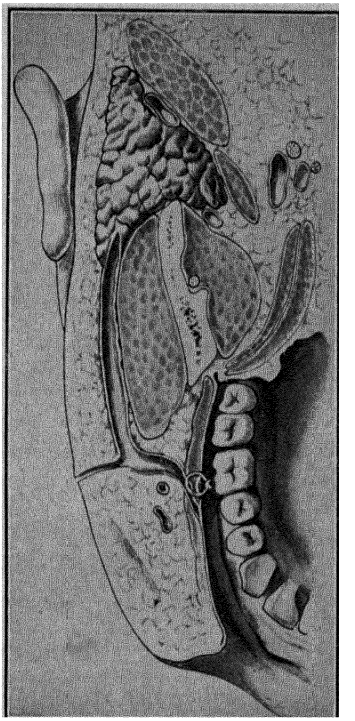

FIG. 660.—METHOD OF FORMING A NEW OPENING INTO THE MOUTH BY MEANS OF A SUTURE THROUGH THE BUCCAL MUCOUS MEMBRANE

Fistulæ of the proximal portion of the parotid duct, *viz.* over the masseter muscle, are, as may be imagined, very difficult to cure, and nearly thirty different operations have been devised. There is, however, only one justifiable procedure, an old one, which has been much neglected. By means of a small fine malleable probe, which is passed from the mouth along the duct and out of the fistula on to the face, a piece of silk is attached and drawn out on the face. To the end of the silk is attached a fine piece of drainage tubing, and this is drawn out of the fistula, leaving one end in the mouth, while the other is projecting on the face. Saliva may find its way along the side of the drainage-tube into the mouth. After a few days the drainage-tube is drawn so far into the mouth that it no longer projects from the fistula. Finally, after a week it is withdrawn altogether. In some cases the result of this method is admirable, and the fistula remains completely closed; should infection of the duct be present, however, the rubber tube may cause parotitis.

There is only one certain method of closing a fistula of Stensen's duct when sepsis is present, or when the operation has failed, and that is by *avulsion of the auriculo-temporal nerve.* This method was first advocated by Leriche some years ago. A vertical incision is made in front of the external auditory meatus, when the nerve is seen lying just beneath the superficial temporal artery. The nerve is divided with a knife, the proximal portion grasped with a pair of Spencer-Wells' forceps, and as much of it as possible avulsed by firm traction. The fistula is generally healed at the end of a week.

Fistulæ of the parotid gland, as already mentioned, usually heal of their own accord. For those which do not, two methods of treatment are available:

(1) Radiotherapy; and
(2) Avulsion of the auriculo-temporal nerve.

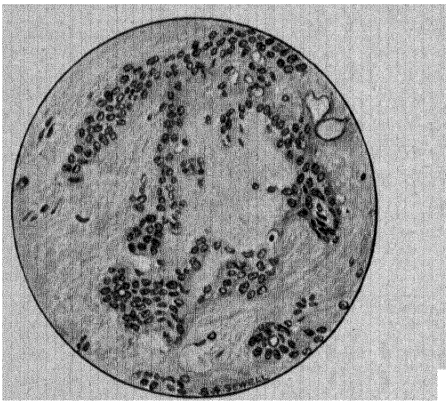

FIG. 661.—LOW-POWER VIEW OF SECTION OF MIXED PAROTID TUMOUR, SHOWING AREA RESEMBLING CARTILAGE.



FIG. 662.—HIGH-POWER VIEW OF MIXED TUMOUR OF THE PAROTID, SHOWING THE EPITHELIAL CELLS

which is 0·5 mm. The torpedo itself is encased in another platinum tube, 0·5 mm. in thickness, in order that the β-radiations may be cut off. The platinum tube is then placed in a rubber tube to facilitate its application. The fistula and its surrounding parts are covered with lint, in order to cut off any secondary radiations from the metal filters. A four-hour application is usually sufficient, but should the skin be somewhat thickened and indurated from the constant discharge of saliva, a six-hour application is advisable. Whatever length of application is used, it is advisable to give a hypodermic injection of atropine (gr. $\frac{1}{75}$) half an hour beforehand. This lessens the secretion of the gland during the time the radium is being applied.

X-rays have been used in the treatment of parotid fistulæ, but are not so constant in their action. Three pastille doses, with a weekly

interval between each, should be given through a filter of 3 mm. aluminium. Here again the atropine should be administered prior to treatment.

Tumours of the Parotid Glands are of considerable interest, and may be simple or malignant.

The commonest **Simple** parotid tumour is the so-called *mixed tumour*, which is characterized by the presence of spaces containing material resembling cartilage. There has been, and still is, an active controversy as to the nature of these mixed tumours. They were at first thought to be purely epithelial in origin, but Virchow suggested that the so-called cartilage was formed by a process of metaplasia from connective tissue, whilst Cohnheim stated that it was a remnant of the branchial arches which became displaced during fœtal life.



FIG. 663 —SIMPLE PAROTID TUMOUR

An endothelial origin was proposed by Wartmann, who considered that the polyhedral cells were derived from lining cells of the lymphatic vessels; but

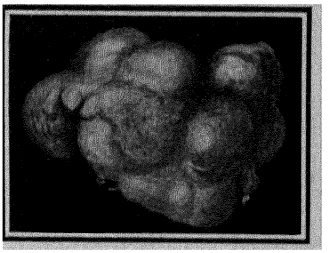

FIG 664 —SIMPLE TUMOUR OF THE PAROTID GLAND (OPERATION SPECIMEN $\times \frac{1}{2}$.)

it has now been demonstrated that the cells show no definite endothelial characters under the higher powers of the microscope and more modern and delicate contrast staining. Recently attention has been drawn to the fact that appearances produced by the mucoid change in the stroma of basal cell carcinomas resemble the mucoid change in the stroma of mixed parotid tumours, and an attempt has been made to classify them under that heading At the present time, however, the consensus of opinion is that the vast majority of so-called mixed tumours are entirely epithelial in nature. They are derived most frequently from the ducts of the glands, but in a few cases from the secreting cells. The mucinous material, which is such a prominent feature of most of these tumours, is a true secretion of mucin from the tumour cells, and is only an exaggeration of a normal function of the gland cells. In the substance which has been described as cartilage, the matrix is formed by a change in the mucin of the tumour, where it loses its fibrillar appearance

and its power of staining deeply with special dyes (Figs. 661 and 662).

Clinical Features.—Mixed tumours are equally common to either sex, and know no age incidence; they may occur in children or old people. They are usually situated in the superficial portion of the gland substance, are coarsely nodular, and vary in consistency in different parts (Fig. 663). They may also less commonly occur in other situations such as the roof of the mouth, the gums, or the cheek. The facial nerve in its course through the gland is deeply placed, and hence is not pressed on by these tumours unless they undergo malignant change. They have a definite capsule, and outside this

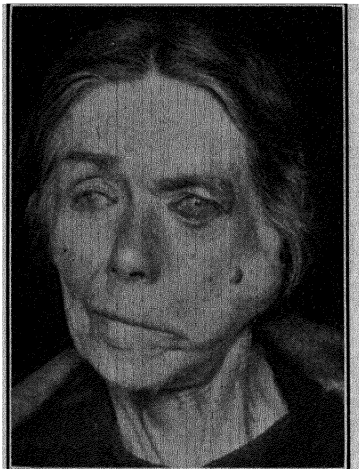

FIG. 665.—MALIGNANT TUMOUR OF THE PAROTID.

The drooping of the eyelid and general asymmetry of the face are indicative of the facial paralysis caused by the growth.

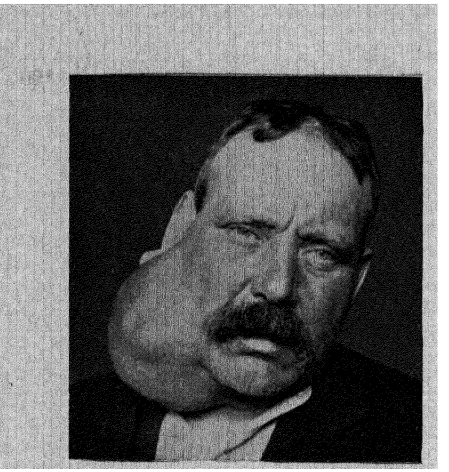

FIG. 666.—MIXED TUMOUR OF THE SUBMAXILLARY GLAND.

The patient had noticed the tumour for eight years

the gland tissue is somewhat compressed to form an extra pseudo-capsule (Fig. 664). This fact is important from the point of view of treatment, for it permits of ready enucleation, and fistula rarely results owing to the compressed gland substance around the tumour preventing any escape of secretion.

These tumours show a definite tendency to recur even after a long interval, and therefore are considered by many surgeons to be potentially malignant.

Malignant tumours of the parotid (Fig. 665) occur in the form of sarcoma, or carcinoma, and are sometimes secondary to a simple tumour, the change of type being marked by increased rapidity of growth and greater pain. The mass becomes more fixed, and signs of

pressure upon the vessels and nerves develop; the facial nerve is very likely to be implicated, leading to paralysis of the face. Moreover, the skin becomes hyperæmic and often adherent to the tumour, and finally ulceration and even fungation may obtain. Secondary deposits occur in the neighbouring lymphatic glands or in the viscera, and the patient soon passes into a state of malignant cachexia. Carcinomatous tumours are less common than the sarcomata, but run a similar course. The growth is an adenoid cancer, not unfrequently of the soft or encephaloid type, and neighbouring lymphatic glands are early invaded.

The **Diagnosis** of simple parotid tumours from malignant growths is a matter of the greatest importance from a prognostic point of view, since simple tumours are usually encapsuled, and their removal, except when large or deeply placed, is not a matter of special difficulty; malignant disease is more diffuse, rendering extirpation of the mass almost impracticable. The distinction between the two forms is made by a consideration of the signs and symptoms considered above, attention being directed to the rate of growth, the condition of the skin and surrounding parts, the mobility or not of the neoplasm, and the general aspect of the patient, whilst associated paralysis of the facial nerve is almost always characteristic of malignancy.

Treatment.—*Simple* parotid tumours are dealt with by turning forwards or upwards a flap of skin and subcutaneous tissue, so as to expose completely the capsule and enable the dissection of the growth to be made with as little danger to the facial nerve as possible. It is generally placed beneath the growth, but occasionally runs superficial to it, or in its substance. The tumour is often enucleated without much difficulty, but the surgeon must make certain that no deeper processes are left, or recurrence will inevitably follow. The hæmorrhage from the transverse facial and other arteries is free, but easily restrained. There is no need to remove redundant skin in these cases, as it quickly contracts.

Malignant tumours are amenable to surgical removal only in the early cases; as there is frequently a facial paralysis due to malignant involvement this need not be spared.

In the late cases treatment may be either by surface application of radium by means of a plaque or else by deep X-rays. Unfortunately, the tumours are usually not very radio-sensitive.

Tumours of the Submaxillary Gland are very similar in nature to those of the parotid. Simple tumours are represented by adenomata and mixed tumours (Fig. 666). Sarcoma and carcinoma are also met with; if seen in the early stages, they are easily removed.

Affections of the Palate.

Cleft Palate.—By cleft palate is meant a congenital defect of the roof of the mouth, whereby the structures entering into its formation do not unite in the middle line, thus allowing an abnormal communication to exist between the nose and mouth. The term does not include losses of substance resulting from injury, syphilis, or lupus. The mildest cases consist merely of a bifid uvula, perhaps not involving

the palate at all; the next degree of severity affects the velum alone (Fig. 667); more or less of the hard palate may also be implicated, the cleft reaching as far forwards as the site of the anterior palatine canal (Fig. 668), whilst the severest type of the deformity extends in addition through the alveolus and upper lip on one or both sides, the os incisivum being in the latter case displaced forwards, perhaps on the tip of the nose (Fig. 669). The union of the palatal segments takes place from before backwards, so that it is very unusual to find the alveolar portion of the palate affected apart from the rest.

On looking carefully at a cleft palate, the defect usually appears to be mesial, but occasionally it seems as if a unilateral or bilateral fissure existed. To understand such an occurrence it must be remembered that three anatomical elements unite in the middle line of the roof of

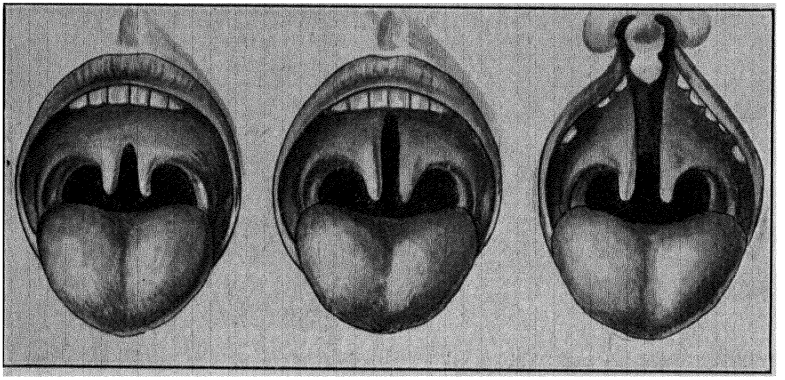

FIG 667. FIG. 668. FIG 669

VARIOUS FORMS OF CLEFT PALATE: FIG. 667 INVOLVING MERELY THE VELUM; FIG. 668 TRAVERSING THE HARD PALATE AS FAR FORWARDS AS THE ANTERIOR PALATINE CANAL; AND FIG 669 BEING COMPLICATED WITH A DOUBLE HARE-LIP.

the mouth, *viz.* the two palatal processes growing in horizontally from the maxillæ, one on each side, and the ethmo-vomerine septum projecting vertically downwards from under the surface of the fronto-nasal process and base of the skull. All these should join together about the ninth or tenth week of intra-uterine life. If, however, the palatal processes fail to reach the middle line, a median defect appears (Fig. 670, A), unless the ethmo-vomerine septum is so hypertrophied as to project between them, when the appearance of a double cleft is produced (B). When only one division of the palate unites with the septum, an apparently unilateral cleft results; most commonly the defect is on the left side, the vomer being attached to the right free edge, a left-sided alveolar hare-lip also complicating the case (C). In these cases the septum often slopes off so as to appear to be continuous with the palatal segment.

The *width* of the cleft and the slope of the segments vary greatly in

different cases. The wider the cleft, the more unfavourable it is for treatment by operative means; and this is one of the arguments used in favour of the removal of the intermaxilla in cases of double hare-lip, so as to allow of the approximation of the two maxillæ. As to the *slope* of the segments, the more vertical they are, the more favourable for operation, since the flaps of muco-periosteum easily meet in the middle line. When the palate is more horizontal, and like a Norman rather than a Gothic arch, the flaps are shorter, and greater lateral displacement is necessary to bring their edges into apposition; this involves much more traction on the stitches, and hence less satisfactory results.

The *effect* of this deformity upon the infant, from a physiological point of view, is very serious. The process of *nutrition* is considerably impaired, owing to the fact that the power of suction is lost, and fluids taken into the mouth are apt to escape through the nostrils instead of being swallowed. Consequently these children must be carefully spoon-fed, with the head thrown well back. *Articulation* becomes very indistinct, so that it is often impossible to understand



FIG. 670.—DIAGRAM TO SHOW THE MODIFICATIONS OF CLEFT PALATE

what is said, the voice having a peculiar and characteristic intonation. All the letters known as explosives, whether dentals, labials, or gutturals, requiring a certain amount of air pressure within the mouth for their due pronunciation, are difficult to produce, particularly *b*, *d*, *p*, *t*, *g*, *f*, etc. Moreover, the exposure of the nasal mucous membrane to the air is so much greater than usual that it is liable to chronic rhinitis sicca (p. 1023). Both taste and smell are much diminished, partly from the unhealthy state of the mucous membrane and also from the absence of an opposing surface against which the food can be triturated by the tongue.

Treatment.—The chief objects to be aimed at by the surgeon are: (1) To provide a roof to the mouth, thereby protecting the nasal cavity from the presence of food and fluids; (2) to provide a movable velum so that the naso-pharynx may be cut off from the oro-pharynx during articulation and deglutition; and (3) to secure these aims without disturbance of the mutual relations of the teeth of the two jaws, thereby protecting the patient from external deformity.

It is the second of these desiderata that until recently had so often been disappointing. Cases in which a good anatomical result was obtained often gave poor functional results: a nasal voice and re-

gurgitation of food into the nose, due to an immobile fibrosed soft palate.

Recently pharyngoplasty, to narrow the naso-pharyngeal valve, has been introduced to assist in obviating this difficulty, and will be described below. The older and classic operation will be described first.

Langenbeck's operation aims at closing the whole cleft from front to back by raising flaps of muco-periosteum on either side, and drawing them together by sutures in the middle line. That it is capable of securing a satisfactory closure of most clefts of the palate, even when they are very extensive, cannot be doubted, but at the same time the fact must be admitted that what is gained in transverse section is lost in antero-posterior, and that the functional activity of the velum is in all serious cases very greatly limited. Moreover, success in closing the gap in the hard palate introduces a fibro-cicatricial element into it which must result later on in drawing together the divided halves of the maxilla, and thereby endangering the perfect occlusion of the teeth. The chances of physiological failure are here manifest.

The operation should be undertaken when the child is two or three years old. In younger children the parts are very small, and the tissues very delicate and friable; the operation is therefore increasingly difficult, and the child is incapable of standing much shock or loss of blood. At the age named the patient is more readily controlled, and bad habits of speech have not been formed. It is most important that the general health be good, and the mouth and throat free from local disease or inflammation; enlarged tonsils are usually removed previously. To guard against accidents, it is well to keep the child indoors under observation for a few days previously, and the spring and summer are the best time for the operation.

The closure of lesser defects of the palate may be carried out by Langenbeck's operation of *staphylorrhaphy* as follows:

Anæsthesia is induced by gas, oxygen and ether, the greatest care being taken to prevent the tissues being damaged by it. The child lies on its back and the mouth is effectively gagged open. Incisions are made on either side reaching from the back of the hard palate to just in front of the cleft (Fig. 671). Through these suitable raspatories are introduced, and the palatal muco-periosteum detached from the bone, so that the front of the cleft is quite loose; it is also detached completely from the posterior border of the hard palate. The margins are then carefully but completely pared, and it is easy to introduce stitches through the edges so as to bring them into accurate apposition (Fig. 672). If there be any tension on the stitches, the lateral openings are slightly and carefully enlarged backwards so as partly to divide the insertions of the levatores palati muscles.

Gillies' operation is more suitable in complete clefts of the palate. The most suitable age for this operation is about six years; it was designed to provide a better functional result, a mobile velum being aimed at, and the hard palate not touched, but treated only by the insertion of an obturator. For details we must refer to larger textbooks, but the essential elements are indicated in the accom-

panying diagrams (Figs. 673 and 674). The first step is to raise two short flaps of mucous membrane from the posterior end of the hard palate, corresponding to its whole breadth, and remaining attached to the velum. Next, the velum is carefully but completely detached from the back of the hard palate on either side so as to

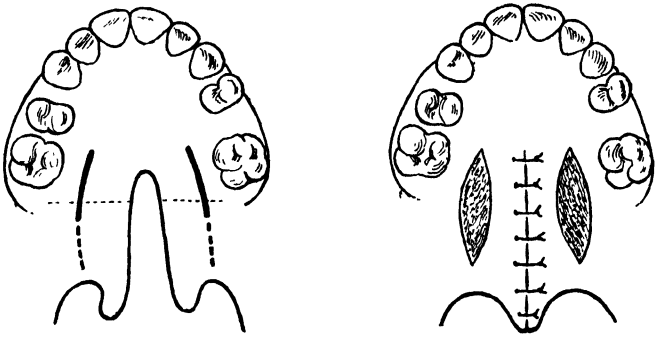

FIGS. 671 AND 672.—STAPHYLORRHAPHY (LANGENBECK'S METHOD).

hang free. The short flap of mucous membrane is now rolled over the free border of the palatal segment and stitched in position, so as to prevent subsequent cicatricial contraction. The mucous membrane on the inner borders of the velum is then split longitudinally so as to free the upper and lower surfaces, and without loss of tissue to provide

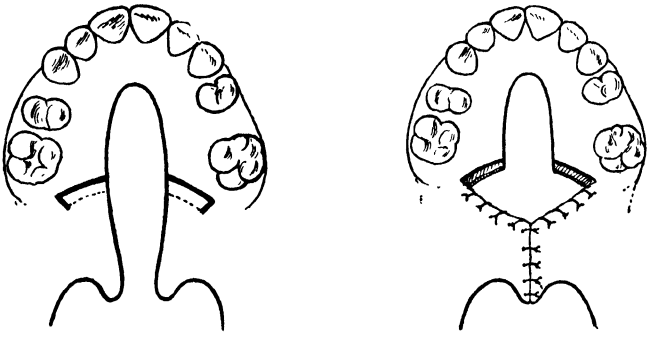

FIGS. 673 AND 674.—GILLIES' OPERATION FOR COMPLETE CLEFT PALATE

In the former, the necessary incisions are indicated; in the latter, the method of bringing the flaps together is shown, so as to provide an effective velum; the opening in front is covered over by an artificial obturator.

raw edges for suturing together. Fine catgut stitches secure the palatal segments in position, and thus a complete soft palate has been formed without attempting to deal with the hard. When healing is complete and the tissues have hardened sufficiently, an obturator is provided by a dentist, and the patient is later handed over to a voice-trainer.

After the operation the child should be put to bed with the head low, so that any accumulation of blood or mucus may gravitate easily into the pharynx. The mouth can be washed out with a weak solution of sanitas, or sprayed with a solution of dichloramine-T in chlorinated eucalyptol. No nourishment should be given for the first four or five hours, and but very sparingly for the first twenty-four. Milk and water, given by a spoon or from a feeder, will form the staple article of diet. By about the fifth day soft food, such as soaked bread and custard pudding, may be safely permitted. The patients are generally allowed up on the sixth day. The silver stitches may be left in for ten days or a fortnight without doing any harm. Should any signs of inflammation occur, the palate should be sprayed over with a solution of peroxide of hydrogen.

It is possible that in most cases articulation will be, if anything, impaired as the immediate result of the operation, since the mechanism which the patient ordinarily employs is thrown out of gear; subsequent education at the hands of a voice-trainer is absolutely essential in order to correct this; even then the unpleasant articulation occasionally persists.

Wardill's Operation.—Mention has previously been made to pharyngoplasty. Wardill pointed out that closure of the naso-pharyngeal valve, which is essential for normal phonation, is dependent not only on a freely mobile soft palate, which can be approximated to the posterior pharyngeal wall, but also to a pharyngeal element. This is the contraction of some of the fibres of the superior constrictor which produce a distinct ridge which, in conjunction with the palate, completely shuts off the naso-pharynx. In cleft palate the naso-pharynx is sometimes unduly deep and wide, and this may be still further widened by fibrosis produced in the velum following plastic operations, with the poor functional result already mentioned.

Pharyngoplasty consists in decreasing the cleft and width of the naso-pharynx to assist in functional recovery. The operation is performed under intratracheal anæsthesia with the head thrown back. An incision one inch long is then made transversely over the site of the ridge. This is deepened through the muscle into the cellular tissue. The constrictor muscle is then widely separated and freed, and thus the operator is enabled to sew up the muscle vertically, so narrowing the naso-pharyngeal opening. This is combined with repair of the soft palate. Gillies' method may be used, but recently an operation has been devised to move the soft tissues of the entire palate backwards, allowing the exposed hard palate to granulate, but enabling the soft palate to be approximated to the posterior pharyngeal wall (Figs. 675 and 676). The cleft in the soft palate, still untouched in Fig. 677, is then pared and sutured. Only the broad principles are presented here, and Figs. 675 to 677 are self-explanatory. Mention must be made that when the incision has been performed the soft tissues are separated with an elevator. It is necessary to fracture the hamulus of the palate bone to free the tendons of the tensor palati muscles; this enables the flap to swing freely. Exposed areas will be left over the hard palate and at the posterior ends of the

lateral incisions, as no lateral tension must be exerted on the newly repaired soft palate. These areas are packed with iodoform gauze and allowed to granulate.

Ulceration of the Palate occurs in a variety of forms, *e.g.* (*a*) *simple*,

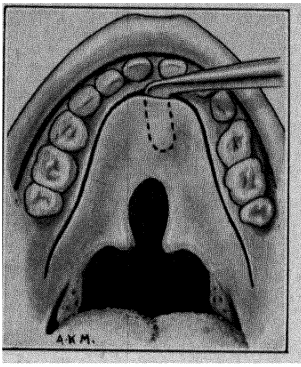

FIG. 675.—PHARYNGOPLASTY. INCISION IN THE MUCOPERIOSTEUM

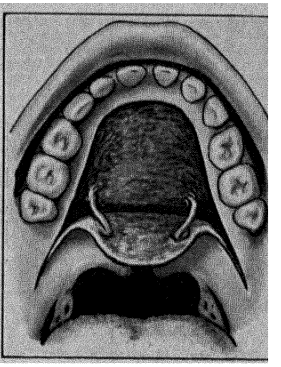

FIG. 676.—DETACHMENT OF THE MUCOPERIOSTEUM WITH ITS BLOOD SUPPLY

as an accompaniment of general stomatitis; (*b*) *syphilitic*, which may involve either the hard or soft palate; if superficial, it is usually a late secondary phenomenon; if deep, it involves the bones, and often leads to necrosis, and is then due to tertiary mischief; (*c*) *lupoid*, a somewhat uncommon condition, which may result in great destruction of tissue; it is usually seen in children, and often associated with a similar disease of the nose, from which, indeed, it may have spread; (*d*) *tuberculous*, due to the breaking down of a tuberculous abscess under the periosteum, and then complicated with caries of the bony palate; (*e*) *malignant*, usually resulting from the growth of epithelioma, either starting primarily in the palatal mucous membrane, or extending to it from the tongue, tonsil, or upper jaw.

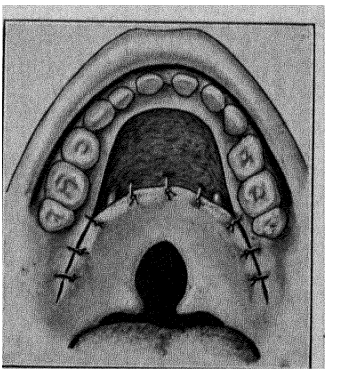

FIG. 677.—THE WHOLE SOFT PALATE IS DISPLACED BACKWARDS.

Acquired Perforations of the Palate, though occasionally caused by traumatism or lupus, are in almost all case due to tertiary syphilis. The ethmo-vomerine septum is often involved in the destructive process, giving rise to a most offensive discharge from the nose. If the soft palate is alone affected, the velum may become fixed by cicatricial adhesions to the back of the pharynx, and pharyngeal stenosis, or considerable loss

of substance of the velum, results. A nasal intonation of the voice is always caused by any condition which interferes with the closure of the naso-pharynx by the velum during articulation. The *treatment* of these conditions should follow the usual antisyphilitic course. Perforations are best remedied by the use of plate obturators. We have seen out-patients make efficient obturators out of a piece of sheet indiarubber maintained *in situ* by suction, or of two pieces stitched together in the middle, one piece passing above and the other below the opening. Occasionally when the aperture is small, the local disease soundly cured, and the general health good, an attempt may be made to close it by stripping up muco-periosteal flaps, paring the edges and suturing them together. The results are, however, seldom satisfactory.

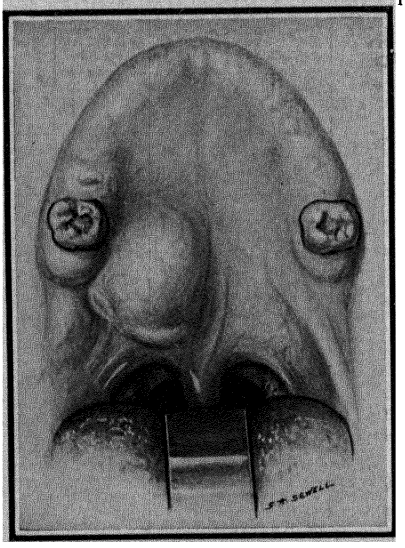

FIG. 678.—ADENOMA OF THE PALATE.

Any of the ordinary forms of inflammation of bone may be met with in the hard palate. **Necrosis** is usually due to tertiary syphilis,

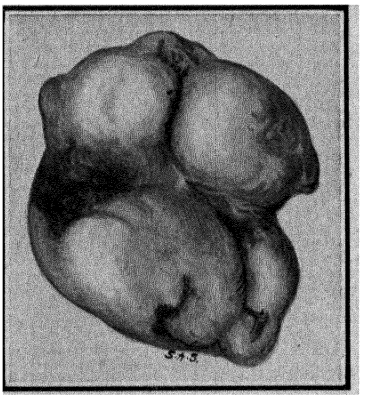

FIG. 679.—SPECIMEN OF ADENOMA OF PALATE AFTER REMOVAL (NATURAL SIZE).

or may accompany acute subperiosteal suppuration, extending from an alveolar abscess. In either case the surgeon must wait till the sequestrum is loose, and then it may be removed. **Caries** is generally due to syphilis or tubercle.

The following **tumours** occur on the *hard* palate. Simple *epulis* may extend from the alveolus, or an identical condition may start in the middle line. An *adenoma* (Figs. 678 and 679) of the palatal glands is occasionally met with. This resembles the mixed salivary tumour. It presents as a smooth or papillated tumour, somewhat resembling epithelioma, but distinguished from it by its slower rate of growth, and the absence of ulceration, pain, or glandular enlargement. An operation limited to the soft parts is probably all that is necessary. *Sarcoma* may be primary, and is then often

myxo-sarcomatous in type, or secondary. In the former case it simulates rather closely a diffuse alveolar abscess, but is recognized by its slower growth, less pain, absence of inflammation, and, if need be, by the results of an exploratory puncture. *Epithelioma* also occurs, but is uncommon. Treatment for the two latter conditions, if limited to the palate, would consist in local removal, with a later operation on the glands, if necessary. Sarcomatous growths would be better treated by radium.

Elongation of the Uvula is frequently the result of a chronic relaxed throat. At first it merely lasts for a time, and by the use of astringents disappears; but later on the elongation becomes chronic, and causes great irritation of the back of the tongue and fauces, resulting in a troublesome throat cough and even vomiting. Under exceptional circumstances it should be removed. After well cocainizing the part it is grasped by a pair of hook forceps, which seize not only the mucous membrane, but also the muscular structures beneath, and a sufficient amount is then removed by snipping it across near the base with a pair of blunt-ended scissors, leaving about a third of an inch of the organ behind.

CHAPTER XXX.

AFFECTIONS OF THE NOSE AND NASO-PHARYNX.

By V. E. NEGUS, M.S., F.R.C.S.

Examination of the Nose and Naso-Pharynx.—In order to understand fully the diseases of the nose, it is essential that the organ be efficiently examined, and to do this six chief methods are employed:

1. **External Examination.**—The nose is first examined externally for signs of displacement or deformity of the bony framework, due to previous injury or inflammatory changes. It must also be noted whether redness or swelling is present and whether the skin is affected by ulcerative or neoplastic diseases.

2. *Anterior rhinoscopy* consists in inspection of the front of the nasal cavity through the anterior nares. A good light is required, either reflected from a frontal mirror or derived from an electric head-lamp, and some form of nasal speculum. Thudichum's speculum is satisfactory; it consists of two unfenestrated blades, connected by a U-shaped spring. The ring and index fingers are placed one on each limb, so as to regulate the amount of tension, and prevent painful overstretching. The blades are inserted into the nostril, the nasal vibrissæ being thus held aside. By this means one is enabled to examine the nasal fossæ, including the inferior turbinals. The amount of distension of the latter limits the view of other structures; if greatly swollen, it feels soft and even fluctuating, but collapses on the application of a 2½ per cent. solution of cocaine, allowing the free convex border of the middle turbinal to come into view, as also the cleft or olfactory fissure between it and the septum. The septum can also be examined, frequently showing deviations from the middle line, and thickenings or spurs of bone or cartilage which run in an antero-posterior or vertical direction.

The introduction of a sterilized probe under the guidance of the eye is of value in examining the nose.

3. By *posterior rhinoscopy* is meant an examination of the posterior nares by a mirror placed behind the uvula and soft palate. It is by no means easy to accomplish, and requires some dexterity and practice. The tongue should be depressed, and a small mirror, the glass surface of which is previously warmed to prevent condensation of moisture, is then passed behind the uvula, without touching it or the posterior wall of the pharynx, and by shifting its angle and position a view should be obtained of the structures in the naso-pharynx and posterior choanæ. If not successful, and if it is absolutely necessary to obtain a view, the fauces should be cocainized and the velum held up by some form of palate retractor, such as White's. The posterior nares (or choanæ)

are seen, separated by the posterior free margin of the septum, and within each cavity the rounded ends of the turbinals. Of the inferior turbinal only a portion can be seen owing to the prominence of the velum palati, but the middle turbinal body can be examined in greater detail at its posterior end. Lateral to the choanæ are seen the openings of the Eustachian tubes, and above and between them Luschka's tonsil, a collection of lymphoid tissue in the roof of the naso-pharynx which forms adenoids when enlarged.

4. *Palpation of the Posterior Nares* with the index finger, previously disinfected, is rarely necessary. Standing behind, with the head held firmly, the left cheek is pushed in between the molar teeth with the left forefinger, to save biting; the index finger of the right hand is passed behind the uvula and velum, and the nares can be explored, and the existence of adenoids or other growths determined.

5. A *bacteriological* examination of the discharge from the nose is often of value, especially when a recurring nasal catarrh is present. Swabs from the nasal fossæ are usually sterile, and it may be necessary, therefore, to take them from the naso-pharynx. Various forms of bacteria are found, and a vaccine will sometimes protect the patient for a considerable time. The meningococcus may effect a lodgment in the nasal fossæ without the patient experiencing any ill-effect, as also the *B. diphtheriæ*, and carriers of these organisms may scatter infection widely.

6. Finally, *transillumination* and a radiographic examination of the paranasal sinuses may be of considerable service.

Alteration in the Shape of the Nose may be caused by traumatism, such as a fracture or displacement of the nasal bones (p. 565), or may follow defective growth of the ethmo-vomerine septum, due to disease of syphilitic or tuberculous origin early in life, or may result from tertiary syphilis. A common cause in childhood is abscess of the septum due to injury, leading to necrosis of the septal cartilage and subsequent falling in of the bridge. In adults, a falling in at the tip of the nose may be caused by too extensive removal of the front portion of the septal cartilage during the operation of submucous resection for septal deviations.

Treatment of Fractures and Displacements.—Displacements or fractures of the nasal bones should be reset soon after the injury unless much swelling is present, in which case it may be advisable to wait for three or four days before making finer adjustments.

For the re-establishment of normal conditions manipulation is required, with special forceps; after obtaining good position, a splint of Stent's material, or one moulded from strips of ribbon gauze soaked in collodion, is applied. It is inadvisable to postpone replacement of the bones for more than ten or fourteen days after the injury, as fixation will occur.

When there is no prospect of mobilization by manipulation, it is necessary to saw through the ascending processes of the superior maxillæ, by introducing a saw through an incision within the nasal vestibule.

If there is depression of the bridge or cartilaginous portion of the

nose, good results may be obtained by the introduction of a cartilage or bone graft obtained from a costal cartilage or a rib.

Expansion of the Nose is always the outcome of some long-continued intranasal pressure, especially from new growths. It follows the development of mucous polypi, when they are very large and chronic. The bridge is flattened and bulged out on either side, giving the face an appearance justifying the name 'frog-nose' (Fig. 680) which has been applied to it.

Partial or Total Destruction of the nose may result from disease or trauma, or may be the necessary end-result of the eradication of the former. Lupus, tertiary syphilis, epithelioma (Fig. 681), and rodent ulcer amongst diseases, and gunshot wounds and motoring accidents



FIG 680.—EXPANSION OF BRIDGE OF NOSE (FROG-NOSE) RESULTING FROM THE PRESENCE OF MUCOUS POLYPI.

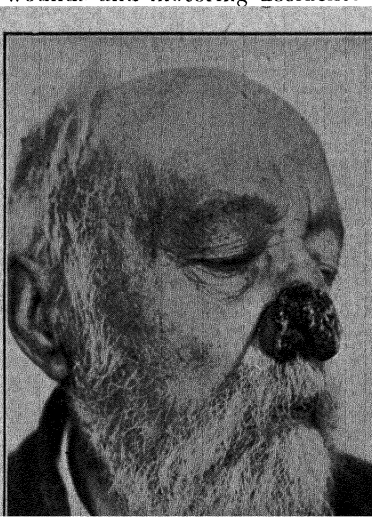

FIG. 681.—EPITHELIOMA OF NOSE.

amongst traumata, are the most common causes. Many methods of **Rhinoplasty** have been devised, but only one will be described.

The so-called *Indian Method* employs for the reconstruction of the nose a flap of skin from the forehead, and is, for most cases, the method of choice. The flap is more or less pyriform, and has its pedicle based on the supra-orbital vessels. Occasionally the pedicle is so arranged as to contain the superficial temporal vessels. The construction of a nose calls for the supply of lining and framework in addition to covering skin.

If skin is not available in this region, hinged flaps may be obtained from the skin of the cheeks bordering on the lateral margins of the defect. Nowadays the provision of support is usually left for a final stage in the reconstruction, and a hinged cartilage graft inserted

through one of the scar lines already present, after suitable undermining of the covering skin, gives good definition to the bridge line and satisfactory protrusion to the tip.

Sutures should be removed as early as possible if stitch marks are to be avoided, and all should be out by the fifth day after operation. Drainage tubes may be inserted in the nostrils to preserve their shape and prevent hæmatoma formation between the covering and lining skin, but it should be realized that such measures are useless for preventing the contraction of insufficiently skin-lined openings.

The pedicle of the forehead flap is divided and replaced in ten to fourteen days. Delay in carrying out this stage has no adverse effect on the cosmetic result, but renders the opening out and spreading of the pedicle on the forehead a much more troublesome procedure.

The raw surface which remains may be covered immediately by a Thiersch graft, or may be left for a further week or so until the pedicle has settled in, to be covered by a free full-thickness graft which provides skin of better texture and appearance.

Although, when circumstances dictate it, very unobtrusive prosthetic appliances of suitably coloured metal or other material can be made and held in position by adhesives or by a spectacle frame, a nose which is essentially part of the patient's own body is infinitely preferable and more satisfactory in every way.



HAMMER-NOSE

The **skin of the nose** may be the site of acne or sebaceous cysts. In the most exaggerated stage the sebaceous glands become overgrown and form large protuberant nodular masses projecting from the end of the nose, and covered with red greasy skin, in which the dilated orifices of the glands are very evident, and with dilated capillaries coursing freely over them. This condition is generally known as *lipoma nasi*, *rhinophyma*. or *hammer-nose* (Fig. 682).

Rhinophyma may be checked in its incipient stages by the judicious use of X-rays; when fully developed, operative treatment is required. The best procedure is to shave away the exuberant masses with a razor or scalpel. The islands of epithelium left at the extremities of the sebaceous pits rapidly spread over the raw surface. Great care must be taken to avoid opening into the nasal cavity, and a finger in the nostril is probably the best precautionary measure to use as a guide during the shaving process. Hæmorrhage is free, but is readily checked by iced saline compresses and pressure dressings. Diathermy coagulation is useful for persistently bleeding points. Only occasionally is it necessary to skin graft the raw surface left by the shaving process.

Affections of the Nasal Septum.—By the term *spur* is meant a localized cartilaginous or bony ridge or thickening of the septum.

which runs in a more or less oblique direction, along the upper border of the vomer. A *deviation* is a bending of the septum from the middle line, causing inequality of the nasal fossæ; the cartilaginous septum is mainly involved, and the condition is sometimes of traumatic origin. The two conditions are usually combined, and may be associated with a high-arched palate. Deviation of the septum, when severe, may give rise to nasal obstruction and may predispose to chronic rhinitis, or to obstruction of the ostia of the nasal sinuses, with resultant headache or inflammation of hyperplastic or suppurative type. Nasal asymmetry may be present in cases of deviated septum due to injury. To correct deviations, with or without spurs or ridges, **submucous resection** of the septum is performed under a local or general anæsthetic, and the results are excellent. The muco-perichondrium and muco-periosteum are stripped up on the convex side, and the whole thickness of the cartilage and bone is removed; the two layers are then placed in contact, and by their union constitute a median septum.

Foreign Bodies are sometimes impacted in the nasal passages of children. Unilateral purulent discharge from a child's nose should suggest the likelihood of such an occurrence; peas, beads, or buttons are the substances usually introduced. A certain amount of unilateral obstruction to nasal respirations is caused thereby, followed by a catarrhal or suppurative rhinitis, and in old-standing cases a rhinolith or nasal calculus may be formed by the deposit of inspissated mucus upon the outer surface of a foreign body. Removal is best effected in adults by thoroughly cocainizing the affected side so as to reduce the congestion and swelling of the mucous membrane, and then seizing the foreign body by suitable forceps, a hook, or a snare. For children a general anæsthetic is required. Removal should never be attempted without the assistance of satisfactory illumination and a nasal speculum. Necessarily, all instruments used for this purpose should be thoroughly sterilized. The old-fashioned plan of attempting removal by syringing is most unsatisfactory, and, indeed, dangerous, and should be totally discarded.

Epistaxis, or bleeding from the nose, may arise from a variety of causes, including traumatism, directed either to the mucous membranes or the bones, or from the presence of ulceration or tumours. Some of these local causes are very evident, if they are carefully looked for with a speculum and frontal mirror. The site of bleeding is almost invariably an area on the anterior part of the septum, where an anastomosis is formed between the septal branch of the spheno-palatine artery and branches from the anterior ethmoidal and coronary vessels. One of the commonest lesions is a small abrasion or ulcer of the septum, due to detachment by the finger of a scab or dried crust of mucus which causes irritation within the nostril; each time the nose is 'picked' in this way, bleeding recurs. Another frequent source of epistaxis is the rupture of a varicose vein in the mucous membrane of the septum; varix occurs not unusually in plethoric individuals, and sneezing or blowing the nose violently may lead to an attack (Fig. 683). Foreign bodies may cause hæmorrhage, as also

ulceration of an angioma on the septum. It frequently occurs in young people about puberty in consequence of local disturbance in the vascular arrangement of the parts; again, cerebral congestion may induce it, owing to the communication by means of emissary veins between the interior of the skull and the venous plexuses in the nose; excessive changes in the atmospheric pressure, as in mountaineering, may lead to epistaxis, whilst in abnormal states of the blood it may be associated with hæmorrhage elsewhere, as in hæmophilia, purpura, and scurvy. It is sometimes an evidence of chronic Bright's disease, and may be one of the first symptoms to call attention to the existence of this disease; it may follow cardiac or pulmonary disease, resulting in cerebral congestion, and may be a prominent symptom in enteric fever. One or both nostrils may be the seat of the bleeding, and it may be so excessive as even to threaten life.

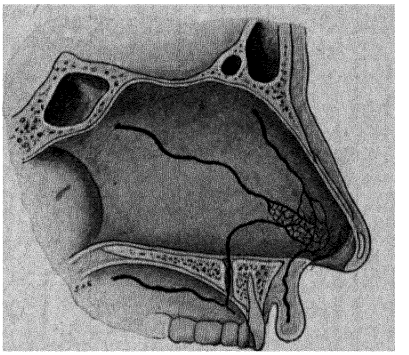

FIG. 683.—BLOOD-SUPPLY OF THE NASAL SEPTUM TO SHOW THE ANASTOMOSIS IN AN AREA CLOSE BEHIND THE NASAL VESTIBULE, THE 'BLEEDING AREA.'

Treatment.—It must not be forgotten that, in the majority of cases, there is some local cause of epistaxis which can be found and treated directly. The bleeding is generally unilateral, and in nine out of ten cases the source is within easy reach of the anterior nares, being placed on the septum just behind the vestibule of the nose; by grasping the nostrils firmly, so that the ala is pressed against the bleeding-point for ten minutes, the hæmorrhage is controlled, and an opportunity given for clotting. At the same time the patient should sit up, and cold be applied to the root of the nose or to the nape of the neck. If on examination the bleeding-point is detected, whether it be a varicose vein or an ulcerated surface, the hæmorrhage can almost at once be stayed by applying a galvano-cautery, or by sealing the spot with a probe tipped with fused chromic acid. Failing these measures, the nostrils may need to be plugged, but such a proceeding is seldom required. It may suffice merely to pack the anterior nares with ribbon gauze soaked in iodoform and soft paraffin, or a sterilized rubber finger-stall may be introduced and filled with gauze. If this does not suffice, the posterior nares must also be plugged. For this purpose Bellocq's sound is usually employed in order to pass a thread round the base of the palate, and out of both nose and mouth; but where it is not obtainable, a rubber catheter may be used instead. To the lower end of this thread or catheter a pledget of sterilized gauze soaked in iodoform, about 1½ inches by 1 inch in size, is attached, and this, guided by the finger round the soft palate, is drawn tightly forwards into the posterior nares. It is a good plan to have two threads coming forwards out of the nose, and these may be tied firmly

around a pad of lint placed over the side of the nostril, thereby occluding the anterior nares and completely blocking the nasal cavity, back and front. The loose end of the thread emerging from the mouth is fixed to the cheek by a strip of adhesive plaster. The plug is retained for twelve or even twenty-four hours, and then removed, being replaced if necessary.

Severe cases of epistaxis may require one or more blood transfusions.

Inflammatory Diseases.

Acute Rhinitis.—This condition is extremely common, constituting what is popularly known as a 'cold in the head.' It is not only due to exposure to cold, but may be caused by irritating gases or dust, and may be one of the prodromal symptoms of influenza, scarlet fever, measles, whooping-cough, or glanders. Not only is the nasal mucosa involved, but the inflammation often extends to the frontal or maxillary sinuses, causing brow-ache and face-ache, whilst if it spreads to the mucous lining of the Eustachian tube, temporary deafness may ensue. Anosmia and partial loss of taste may be present. In infants dyspnœa may result owing to obstruction of the nasal passages, and this may be so marked as to interfere for a time with breast-feeding; the infant attempts to breathe through the nose, since the mouth-breathing is an acquired habit. Apart from the usual remedies directed to increasing the action of the bowels, kidneys, and skin, considerable relief can be obtained by steam inhalations containing friar's balsam, menthol, and eucalyptus oil every three or four hours.

A suppurative form of rhinitis is associated with acute suppuration in one or more accessory sinuses, and then treatment must be directed mainly to the sinus. The discharge is abundant, and causes much obstruction to nasal respiration because of marked swelling of the mucous membrane. The nasal passages must be cleared with steam inhalations, but nasal douches must never be used, because of the danger of infecting the middle ear. A solution of ephedrine may give relief if used as drops in liquid paraffin containing 1 per cent., or in a spray of saline solution to which ½ per cent. has been added.

Chronic Rhinitis occurs in many distinct types, of which we can merely give a bare outline.

1. **Simple Chronic Rhinitis** occurs most often in those working in a dusty atmosphere, and is often associated with inequality of the two nasal fossæ due to deviation of the nasal septum; it may appear after the subsidence of an acute attack. The mucous membrane is seen to be redder than usual, and is slightly thickened, thus giving rise to nasal obstruction. Search must be made for a cause in any of the nasal sinuses or in the naso-pharynx, where adenoids may be present. Locally, sprays of menthol in oil or of chloretone and glycerine in cinnamon water are useful; the most important point, however, is to discover and remove the cause.

2. **Hypertrophic Rhinitis,** one of the most common forms, is characterised by engorgement of the erectile tissue covering the inferior or

middle turbinated bones, causing obstruction to nasal respiration and an abundant discharge of muco-pus. The entire nasal mucosa, septal as well as turbinal, may be involved. It is more common in male patients with prominent noses, where the passages are narrow; it may run in families, and is often present in Jews; it occurs with marked septal deviations on the concave side, closing up a roomy nostril, and may be lighted up by some slight local irritation such as a sudden change of temperature. It is frequently associated with and aggravated by infection of one or more of the paranasal air sinuses, careful examination and treatment of which must be carried out. The inferior turbinal is chiefly involved; it is swollen, red, and rounded, the mucous covering being infiltrated. The local application of a 2½ per cent. solution of cocaine causes its complete, though temporary, collapse in a few moments. If allowed to persist, hyperplasia of the mucous membrane follows, and in the most marked types a projecting papillomatous-like mass appears at the posterior extremity; this condition is often termed *moriform enlargement* from its likeness to a mulberry. The mucous covering of the middle turbinal may participate in the same process, but in this region the thickening of the mucosa is pale and of a more œdematous type. A certain amount of pharyngitis or laryngo-tracheitis may also be present. *Treatment.*—In the early stage all that is required is the use of steam inhalations of menthol and benzoin, or a spray containing menthol in oil, or chloretone and glycerine in cinnamon water. In extreme cases a galvanocautery at a red heat may be run along the length of the inferior turbinal bone.

In certain cases hyperplasia of parts of the nasal mucous membrane takes place and leads to the formation of polypi, with great obstruction to respiration. Any infection of the sinuses must be dealt with.

Straightening of the nasal septum, or removal of part of the middle turbinal body, may be necessary. The posterior end of the inferior turbinal may be snared, but the main part of this structure must not be removed.

Nasal Polypi are inflammatory formations resulting from long-standing rhinitis of hyperplastic type, or may be the result of allergic swelling of the mucosa; they are soft gelatinous masses, which on microscopic examination much resemble myxomatous tissue, covered by ciliated columnar epithelium. They are usually associated with a secondary chronic osteitis of the underlying bone. They are often dependent on suppuration of the adjacent sinuses, especially the ethmoidal, but the pus production may be secondary and not causative. Polypi are usually situated above or below the middle turbinal, arising from the lower border of the middle turbinal, or from the ethmoidal cells. They start occasionally in the maxillary, frontal, or sphenoidal sinuses; they do not involve the septum or inferior turbinal. Polypi are generally multiple (Fig. 684), a large one projecting downwards and forwards towards the anterior nares, and covering or hiding a series of smaller ones, which readily spring into prominence when that in front is removed. They are usually attached by a small pedicle, and when developing in the nasal fossa are pyriform and laterally

compressed. When of large size, they may cause expansion of the bridge of the nose (Fig. 680), and even reach the nostrils, when the epithelium covering the anterior portion becomes squamous, and the mass firmer in texture and papillomatous in appearance. An *antro-choanal polyp* is one, usually single and of large size when recognized, which springs from inside the maxillary antrum, passes through the antral opening, and travels backwards into the posterior choana and naso-pharynx.

The main **Symptom** arising from nasal polypi is obstruction to the passage of air along one or both sides of the nose. This is of gradual onset, and invariably worse in wet weather, on account of the hygroscopic property of mucoid tissue. There is often a thin, watery discharge from the nose. The patient is unable to blow the nose, and his articulation becomes nasal in quality. Ill-defined headache is common, and due to obstruction of the nasal openings of the frontal sinuses. On rhinoscopic examination one finds a greyish, semi-translucent, glistening mass occupying the nasal fossæ. The pedunculated nature of a polypus can be easily demonstrated by passing a probe around it.

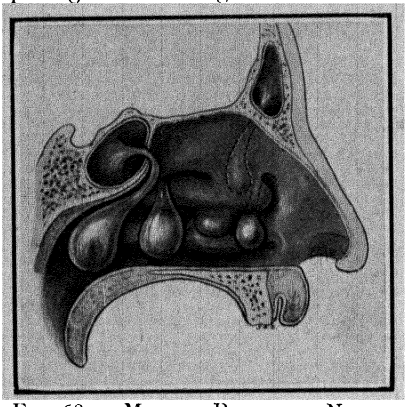

FIG. 684.—MUCOUS POLYPI OF NOSE (DIAGRAMMATIC).

Translucent, smooth, pale nasal polypi are seen hanging in the nasal fossa. One originates in the frontal sinus and lies under cover of the middle turbinal body, in close proximity to one arising from an anterior ethmoidal cell. Posteriorly one has escaped from the sphenoid sinus, and another from a posterior ethmoidal cell. There is also commencement of polypus formation on the lower border of the middle turbinal.

The **Diagnosis** should present no difficulty to one who knows how to employ the nasal speculum. Abscess, a spur, or a deviation of the septum, though causing unilateral obstruction, can be recognized by careful examination. Œdematous masses of granulation tissue, associated with tuberculous or syphilitic disease of the bones, are recognized by their colour, by the involvement of the septum as well as the turbinals, by the absence of superficial epithelium, and by not being distinctly pedunculated; carious bone can often be felt by a probe through the granulation tissue. Polypi differ from hypertrophy of the mucous membrane over the inferior turbinated bone; they do not spring from this region, whilst the latter condition is sessile and red, and shrinks considerably on the application of cocaine. They are distinguished from malignant new growths by their pale colour, smooth surface, and avascularity.

The **Treatment** of polypi consists in their removal by the snare or forceps.

The *snare* is specially indicated if there is a single polypus hanging

down the naso-pharynx, or if the polypi are few in number. The patient is seated in a chair, and the surgeon sits or stands in front. The nasal cavities are anæsthetized with a solution of equal parts of cocaine (10 per cent.) and adrenalin, and the situation of the pedicle ascertained, if possible, by inspection and by the use of a probe. The snare is then introduced, and the loop passed round the base of the pedicle and gradually tightened. The polyp is then torn away, and often brings with it the area of carious bone which lies beneath it. The same process is repeated to the smaller masses until the nose is clear. The cavity does not require to be tightly plugged afterwards for hæmorrhage, unless the latter is very severe; if packing be inserted it must not be tight, or too highly placed, for fear that meningitis may arise from infection through the cribriform plate.

If recurrence has occurred after the removal by the snare, the nostril must not only be effectively cleared, but the underlying bone must be removed for the cure of the ethmoiditis. Radical ethmoidectomy is often desirable in the first place. Antrostomy also may be required.

3. **Rhinitis Sicca** is a condition characterized by loss of vascularity and deficiency of secretion from the glands of the nasal mucous membrane. It is found in those who work in hot and dry rooms, and is treated by the application of oily solutions or of a stimulating paint, such as that of Mandl (iodine and potassium iodide).

4. **Atrophic Rhinitis** generally commences in childhood and usually in an underfed child, who may be debilitated by tuberculosis or may be the subject of congenital syphilis. It is a condition due to deficiency of blood-supply, and to alterations in the supply of and viscosity in the quality of the nasal mucus. It may follow in the train of hypertrophic rhinitis, because of contraction in the chronically inflamed submucous tissues. When severe it is characterized by an exceedingly evil smell, due to saprophytic decomposition of crusts; when this occurs the condition is known as ozæna. Some cases are caused by infection of the maxillary sinuses, a thorough examination of which must be made. It must be carefully distinguished from the offensive condition due to tuberculous or syphilitic disease, the impaction of foreign bodies, or the ulceration of malignant growths.

The erectile tissue is collapsed, and the ciliated epithelium may be lost in places, or may be replaced by stratified epithelium. What secretion there is dries on the surface of the mucous membrane, and gives to it a glazed appearance. The nasal fossæ are roomy because of shrinking of the mucosa and atrophy of the nasal turbinate bodies. Usually both sides are involved, but occasionally one nasal fossa only is affected if the septum is markedly deflected; it is on the roomy side that the changes are first seen, while on the narrow side there may be hypertrophy or hyperplasia.

The pharyngeal wall is often dry and crusted, and the larynx and trachea may present the same appearances.

Treatment.—The first essential is to keep the nose clean and free from putrefying masses of dried secretion. A spray of glucose and glycerine may suffice, but sometimes this must be accomplished by

irrigating the cavity once or twice daily with a warm solution of sodium chloride, sodium bicarbonate and phenol. Every portion of scab ought to be removed daily, and the surface lubricated with some such application as a spray of menthol and paroleine (2½ grains to 1 ounce).

Various means of narrowing the nose have been devised, with success in some cases. Operative measures, however, are seldom required, except for the treatment of an infected maxillary sinus.

5. **Diphtheria** occurs in the nasal fossæ, usually as a complication of the same disease elsewhere, and requiring a similar form of treatment (p. 122). It may also occur as a local and non-systemic condition, rendering the subject a carrier.

6. **Syphilitic Disease** of the nasal fossæ is generally tertiary in type, and consists in a diffuse gummatous affection of the nasal bones, septum and turbinals, with resultant suppuration and either caries or necrosis. The condition is usually a very offensive one; the accessory sinuses are not specially liable to involvement. *Treatment* is of the usual antisyphilitic type, including the injection of arsenic or bismuth preparations, and perhaps the use of iodides and mercury. Locally, the nose must be kept clean by irrigation and removal of diseased bone. If the septum is seriously affected, the bridge of the nose will become depressed. In cases of congenital type the disease may start in infancy, causing the condition known as snuffles; considerable deformity results from destruction of the nasal bones.

7. **Tuberculosis of the Nose** takes the form of lupus, commencing typically at the junction of skin and mucous membrane in the vestibule. Jelly-like nodules appear, which ulcerate and coalesce, leading to destruction of the nasal septum with the formation of a perforation. The disease spreads both along the cartilages and also outwards to the skin of the face, with signs of healing in places and contraction; loss of tissue and contraction produce deformity and falling-in of the tip of the nose. Secondary deposits may appear in the palate, fauces or larynx. A more active form of tuberculosis sometimes occurs with destruction of parts of the bony septum, but never with perforation of the hard palate as in syphilis.

Treatment is directed to the removal of the focus by excision or diathermy. General treatment is given to improve the health, preferably in a sanatorium; ultra-violet radiation gives good results in some cases.

In the frontal sinuses osteomata may arise, while in the maxillary sinuses odontomata of various types may appear.

Affections of the Para-Nasal Sinuses.

Disease of the Accessory Sinuses of the Nose is a frequent accompaniment of either the acute or chronic nasal affections just passed under review, or it may arise from more localized lesions, *e.g.* antral trouble from affections of the teeth, or frontal sinus infection from external injury. Perhaps the most common cause is a sharp influenza attack, which may lead to an involvement of the nasal fossæ and al

the sinuses (pan-sinusitis); this is amenable to treatment in the early stages, but if neglected may become chronic and give rise to serious trouble. There is then persistent discharge of purulent material from the nose, which, when arising from a maxillary antrum infected by a septic tooth-root, is often offensive; to this may be added special features according to the particular sinuses which are affected.

It must be remembered that the outlet of some of the sinuses (Fig. 685) is badly placed for drainage purposes, especially that of the maxillary antrum, the opening of which is nearer the roof than the floor, drainage being maintained by ciliary action. Even in the case of the frontal

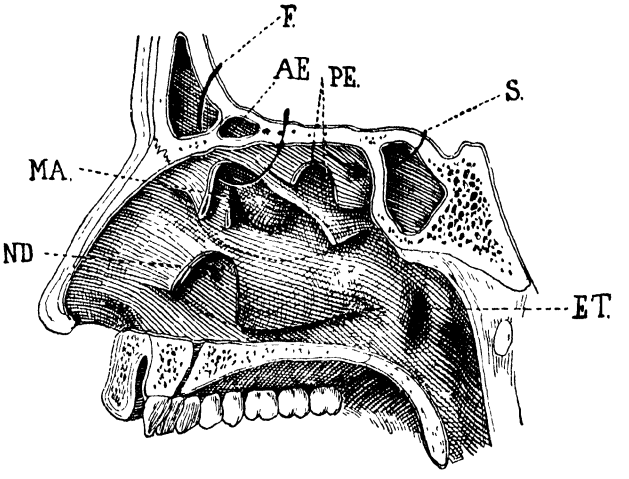

FIG. 685.—OUTER WALL OF NASAL FOSSA, INDICATING THE POSITION OF THE ACCESSORY SINUSES AND OF THEIR ORIFICES.

F, Probe passed from frontal sinus down the infundibulum to middle meatus; AE, anterior ethmoidal cells, PE, orifices of posterior ethmoidal in superior meatus, shown by removal of a portion of the superior turbinal; S, sphenoidal sinus with probe in its orifice; MA, orifice of maxillary antrum shown by cutting away part of the middle turbinal; ND, orifice of naso-lacrymal duct under cover of the inferior turbinal, part of which has been removed; ET, pharyngeal opening of Eustachian tube.

sinus, the outlet, which is well situated for drainage, is a long, narrow passage easily blocked by œdematous swelling of the mucous lining. When once suppuration has commenced in the sinuses, it may spread from one to another owing to the close proximity of the various orifices. The maxillary sinus is most frequently infected, with the ethmoidal cells next in order. Infection of the frontal sinus is more rare and is almost invariably secondary to infection of the maxillary sinus.

In the *acute* cases which follow influenza or cold, the antrum is most frequently involved. Readers are referred back to what has already been written on these subjects (p. 1020), with the emphatic reminder that careful treatment during the early stages may prevent

the affection becoming chronic, and save the patient from much suffering and danger. In the early *acute* stages, irrigation of the nasal fossæ should never be ordered, but medication by means of steam inhalations; the antrum may need washing out after cocainizing the inferior meatus and puncturing the wall with trocar and cannula, daily if necessary. Any more extensive operation is extremely dangerous in the acute stage, and should be avoided for at least ten days from the commencement of the disease, except in rare cases (see p. 1029).

In *chronic* cases there is discharge from one or both sides of the nose, and the patient complains of feeling stuffed up; breathing will be mainly oral. On examining the interior of the nose, even after cleansing it, the cavity is not found to be patent, but may be blocked up by swollen turbinals or by polypoid masses, which project from the middle meatus. Pus may be seen lying in this region, and comes from either frontal sinus, maxillary antrum, or anterior ethmoid cells.

In such a case the antrum should be punctured and thoroughly washed out; if afterwards more pus appears on hanging down the head, it must come from the frontal sinus or ethmoidal cells. Pus lying above the middle turbinal comes from the posterior ethmoidal cells or the sphenoidal sinus.

Affections of the Maxillary Sinus.

The antrum of Highmore or maxillary sinus is a cavity lying within the superior maxilla; it is roughly pyramidal in form and triangular on section. The bony walls vary much in thickness, but the orbital, nasal, and facial aspects are thin. Below, the roots of the upper molar teeth and sometimes the bicuspids are separated from it merely by a thin plate of bone; above, the infra-orbital nerve and vessels are imbedded in the superior wall. It is lined by an extension of the mucous membrane of the nasal cavity; the ostium is on the mesial wall, being badly placed for drainage purposes, nearly an inch from the floor, so that any escape of secretion—if abundant and not removed by ciliary action—is by overflow. This opening, moreover, is under cover of the middle turbinal, not far from the lower end of the fronto-nasal duct and the exit of the anterior ethmoidal cells, so that when infection has attacked one cavity it is likely to spread to others.

Distension of the antrum may arise from new growth or dental cyst formation, and may be manifested in any of four directions: (*a*) inwards, causing obstruction to nasal respiration, and possibly epiphora, from compression of the naso-lacrymal duct; (*b*) upwards, leading to protrusion of the eyeball, or exophthalmos; (*c*) downwards, resulting in depression of one side of the palate, and possibly irregularity in the line of teeth; and (*d*) outwards, giving rise to a somewhat characteristic projection of the cheek beneath the malar eminence. Under these circumstances, a finger inserted into the mouth, between the cheek and the bone, will detect fulness and possibly a loss of resistance in the anterior wall of the antrum, or the whole anterior wall may be absorbed and an elastic swelling take its place. Infra-

orbital neuralgia is a marked feature in such of these cases as are of rapid progress.

Suppuration within the Antrum (*empyema of maxillary sinus*) may arise from disease connected with the roots of the first or second molar or first bicuspid teeth; it more commonly results from an acute inflammation of the nasal cavities due to infection by *B. influenzæ*, pneumococcus or streptococcus, and may be associated with inflammation in the other accessory nasal sinuses. It is occasionally lighted up by injury, as in boxing, football, or fighting; or the cavity may be infected by bathing in the sea, stagnant ponds, or swimming baths.

The **Symptoms** produced are often equivocal, and the condition may be present for some time without being recognized.

In *chronic* forms all that is noticed may be an intermittent discharge of pus from one side of the nose, associated with nasal obstruction, a chronic cough and an irritable throat. The pus varies considerably in amount and character, being sometimes extremely offensive. On holding the head forwards, there may be an overflow of pus into the nostril, and sometimes when the patient reclines it flows back into the pharynx. Cacosmia (a bad smell *perceived by the patient*) is almost always diagnostic of dental-root infection of the antrum with mouth organisms. Should the opening into the nose become blocked, all the symptoms are aggravated, possibly with pain and swelling.

In *acute* cases all the above phenomena may be present, accompanied by severe tensive pain and some amount of febrile disturbance. Toothache in one or more teeth of the affected side is often due to neuritis of one or more branches of the superior dental nerve. Osteomyelitis of the bony walls may also be induced in children, since the mucous membrane is closely adherent to the periosteum. This complication, however, usually results from primary infection in a tooth socket.

The **Diagnosis** of suppuration within the antrum is not always easy. The discharge of pus from the nose is suggestive, as also the presence of a dead or painful molar or bicuspid tooth. If a flow of pus can be induced by change of position of the head, it is pathognomonic of suppuration within one of the accessory sinuses connected with the nose, probably of the antrum. If, after the nose has been cleared and the head hung down, pus is seen welling up from under the middle turbinal, the diagnosis is almost certain. *Transillumination of the antrum* helps to confirm this opinion. A suitable electric lamp is placed within the mouth in a dark room, or the examination is made under a photographer's cloth; if the antra are normal, the cheeks, lips, and lower margins of the orbits become of a rosy-red colour. On pulling down the lower lid, the sclerotic is seen illuminated in its lower part; and the pupil shows up as a red area, the light having passed through the antrum into the globe of the eye. If, however, the cavities are occupied by pus, blood, a growth or polypi, or if the mucous lining or bony walls are thickened, the parts remain dark. Transillumination is not accurately diagnostic in every individual, and hence the value of the test is diminished. The presence of illumination generally

excludes intra-antral growths or abscess, but its absence, unless unilateral, is not of much significance. Differences of illumination on the two sides are, however, of considerable diagnostic significance.

Radiographic Examination is of considerable value, the films being exposed through the occipito-mental plane. A fluid level may be visible if there is retained secretion; in hyperplastic cases thickening of the lining membrane or polypus formation may be revealed.

Finally, the antrum may be punctured with trocar and cannula through the inferior nasal meatus, and an absolute diagnosis obtained by washing it out (Fig. 686).

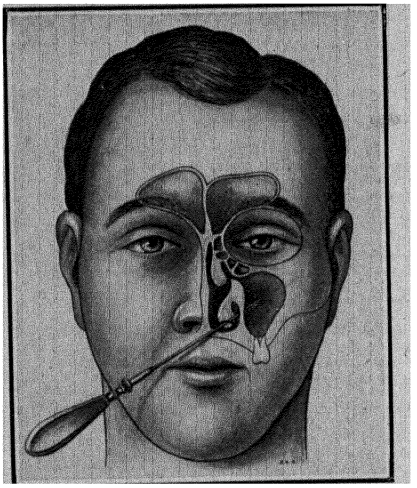

FIG 686.—THE FRONTAL, ETHMOIDAL AND MAXILLARY SINUSES SHOWN DIAGRAMMATICALLY.

The figure illustrates the good drainage of the frontal sinus as compared with that of the antrum of Highmore, in which the ostium is placed high up, thus favouring stagnation of secretions. A trocar and cannula are in position for lavage of the maxillary sinus, the instrument pierces the naso-antral wall below the inferior turbinal body

The **Treatment** varies with the type of the disease. It must always be remembered that the orifice of the antrum into the middle meatus is an inch above the antral floor, and hence the natural drainage is defective, being merely of an *overflow* type when the patient is erect if ciliary action is ineffective or has been paralyzed.

In acute cases the cavity should be washed out from the nose, the inner wall being punctured through the inferior meatus after efficient cocainization; warm sterilized salt solution is employed. This lavage may be required at first on alternate days, but afterwards less frequently, and in the intervals the patient is guarded from cold. Steam inhalations* of friar's balsam, menthol, and eucalyptus oil every three or four hours are very helpful and comforting.

It is important to make certain that the point of the cannula is actually within the antral cavity before commencing lavage, as it is possible that it is still in the nasal cavity, or has crossed the antral cavity, and may be (*a*) in the orbital cavity, or (*b*) under the cheek in the canine fossa, or (*c*) in the pterygoid

* For steam inhalations 1 pint of water at 180° F. should be placed in a jug, and the solution added. A towel is rolled up and placed around the mouth of the jug; the nose and mouth are held over the jug, the eyes remaining outside, away from the steam The patient breathes through the nose, and closes one nostril at a time; he should expire mainly through the mouth, continuing the inhalation for five to ten minutes. He must remain in an even temperature for half an hour after the inhalation. A simple prescription is:

℞ Menthol .. .. gr. iii.
Tinct. benzoin co. .. .. ʒi.
Sig. i. in O.i. aq.

region. The syringe should always be filled with lotion before commencing the lavage, as there is danger of air-embolism if this precaution be overlooked. The face must be watched when the syringe is first squeezed to detect any swelling due to mal-placement of the needle.

In chronic cases, intranasal operation will usually suffice; to be effective, the anterior part of the inner (nasal) wall of the antrum under cover of the inferior turbinal must be removed to allow of dependent drainage and lavage of the antrum. Sometimes there is a large accumulation of polypoid tissue within the antrum. To remove it the surgeon must make an opening for inspection by incising the mucous membrane and periosteum over the canine fossa, after retracting the upper lip. He then makes an opening through the anterior bony wall (*Caldwell-Luc operation*). Effective removal of hyperplastic mucosa can then be performed under direct vision, but this buccal opening is allowed to close at the end of the operation. The lining membrane should not be completely removed, except in very rare cases. An opening into the nasal fossa is then made through the inferior meatus, as in intranasal antrostomy.

Drainage of the antrum through a tooth socket was formerly in vogue, but is now seldom used, because of the disadvantage of constant re-infection of the cavity from the mouth.

The **Ethmoidal Cells** lie along the inner wall of the orbit, and should the orbital ethmoidal plate be perforated or necrosed, as a result of acute or chronic ethmoiditis, one or more cells may burst into and infect the orbital cavity, leading to orbital cellulitis, which is usually of nasal origin. Hyperplastic ethmoidal disease leads to excessive polypoid formation, and caries of bone takes place beneath the diseased mucous membrane from which the polypi are derived.

The **Sphenoidal Sinus** lies at the back of the nose, and drainage thereof, in diseased conditions, is partly of the overflow type (Fig. 685, S); the discharge escapes downwards into the naso-pharynx, and often leads to crust formation around the posterior nares. Suppuration therein may cause deep-seated pain in the back of the orbit and nose, and over the occiput; thrombosis of the cavernous sinus, retrobulbar neuritis, involvement of orbital nerves, or even basal meningitis are possible complications.

Treatment, except in the simpler cases, should always be handed over to a rhinological expert, as operative measures, often of a serious character, may have to be undertaken. The essential element is drainage of the affected cavities, together with removal of the polypi and diseased bone which hinder the exit of the discharge. In acute cases it is desirable for a few days to treat the patient merely by medicated steam inhalations, and possibly by lavage of the maxillary sinuses, but further and more effective treatment is usually required in chronic cases. In many patients the lining membranes of these cavities will be thickened and transformed into polypoid masses. The operative procedures mentioned are likely to be required for the associated disease of the antrum. For disease of the ethmoid cells, it may be necessary, after removal of the middle turbinal, to break through by means of Grunwald's forceps, and to remove the entire

inner ethmoid wall, as well as the partitions between the various cells and all polypi. For disease of the *sphenoidal* sinus the anterior wall must be removed by a special punch forceps down to the floor. In mild cases of sphenoidal infection catheterization and lavage with saline solution may effect a cure. In severe cases, where all the sinuses are infected, it may be necessary to work through an external incision.

Frontal Sinuses.

These sinuses are cavities in the frontal bones lined with a mucous membrane continuous with that of the nose. They are seldom large before the age of puberty. In adults they vary much in size and shape, and are often asymmetrical or single; the prominence of the superciliary ridges is no guide to their extent. Information as to these points may be gained by radiography, the rays being directed from behind and the plates placed in front. The presence of pus and of tumours may be determined in this way. Transillumination is seldom useful.

Fracture of the anterior wall is not uncommon as the result of a direct blow, depression of the fragments being produced, but without cerebral complications. If the mucous membrane is torn, surgical emphysema of the scalp and face may follow, and is naturally increased on blowing the nose. In open fractures, suppuration may occur, leading to septic osteitis and necrosis of the frontal bone, and, if the posterior wall is involved, to an extradural or even a cerebral abscess. When the anterior wall only has been destroyed, a localized collection of air may form under the skin, and remain as a permanent tumour, known as a *pneumatocele capitis*; it rises and falls with forced respirations.

Inflammation of the frontal sinus is caused by extension from the nose; generally it follows or accompanies empyema of the maxillary sinus and seldom arises as a primary condition, except in rare cases of penetrating wounds or fracture. It produces headache, localized to the region of the sinus, with pain or tenderness on pressure. Fever and a feeling of mental dulness are present. As mentioned above, no operation should be performed on the frontal sinus during the acute stage, except under necessity, when an abscess has broken through its walls, or when spreading osteomyelitis is present. Lavage of the maxillary sinus is required in the majority of cases. This treatment is combined with steam inhalations and the encouragement of drainage from the fronto-nasal duct by the application to the region of the middle turbinal body of small pledgets of wool soaked in 10 per cent. protargol or, in resistant cases, 2½ per cent. cocaine solution. Blockage of the fronto-nasal duct without infection of the cavity can lead to mucocele. The floor of the sinus at the inner angle of the orbit is expanded. External operation may be required.

In the treatment of chronic infection of the frontal sinus external operation is avoided if possible. Any infection of the maxillary sinus must be cured; pathological enlargement of the middle turbinal is rectified by operation, any polypi obstructing the fronto-nasal duct are

removed, infected anterior ethmoidal cells are drained, and any marked deviation of the nasal septum is corrected. If the condition is not cured or markedly ameliorated thereby external operation is performed. An incision is made just below the eyebrow, internal to the supra-orbital nerve and curving round the inner margin of the orbit. Part of the floor of the frontal sinus is removed, but the anterior wall is left intact, except in rare cases of osteomyelitis.

A free communication is made between the sinus and the nose by removal of parts of the nasal, lachrymal, ethmoidal and superior maxillary bones. It is of great advantage and, in our opinion, essential to apply a skin graft to the newly formed opening.

Intracranial Complications of sinusitis may cause extradural abscess, localized or diffuse meningitis, or frontal lobe abscess. These rare complications are seldom spontaneous, but more often appear after operations. The infection arises from the frontal, ethmoidal, or sphenoidal sinuses, and passes in by direct continuity after fracture or caries of bone, or enters through venous channels. Opening of the anterior fossa of the skull is carried out through the posterior wall of the frontal sinus if indicated. Meningitis of nasal sinus origin is almost invariably fatal.

Acute Osteomyelitis is a dangerous complication of acute frontal sinusitis. It is occasionally primary, but is more often the result of surgical interference in acute cases.

In the spontaneous type the patient has a chance of recovery, but the prognosis is very bad in post-operative cases. An afebrile and slowly progressive type may be also seen, arising as a secondary complication of an operation on the ethmoidal cells or on the frontal sinus itself. It is necessary, in such cases, to carry out drastic operative treatment. An incision is made from ear to ear over the vertex and a wide area of bone is removed, sometimes including the greater part of the frontal bone.

Neoplasms of the Nose and Sinuses.

Simple New Growths occur in the nasal fossæ in the form of papilloma, fibroma, angioma, osteoma, and chondroma. They may be removed, if small, through the nostril, but, if large, Moure's lateral rhinotomy or Rouge's or Denker's operations may be necessary (see p. 964).

Hydrops Antri is the term applied to a chronic distension of the antrum with a glairy mucoid fluid, somewhat similar in character to that contained in a ranula; it is due to the formation of a dental cyst which has encroached on the antral cavity; rarely it is due to the presence of a dentigerous cyst. The *treatment* required is to open the cyst thoroughly through the canine fossa. An opening is made into the inferior meatus of the nose to drain both antrum and cyst.

Malignant Disease of the Nose may originate in various parts of the nasal fossæ or sinuses. **Squamous-celled carcinoma** occurs most frequently; the symptoms consist of blood-stained discharge and respiratory obstruction, associated later with pain and cachexia. The disease

commences either in the ethmoidal cells or in the mucous glands of the antrum of Highmore. In the former case the symptoms are referred mainly to the nose, but swelling usually appears during the progress of the condition at the inner angle of the orbit, the eyeball sometimes being displaced outwards, possibly with ophthalmoplegia or defective vision due to pressure on the optic nerve. If the growth starts in the antrum, the first external sign is swelling of the cheek, caused by forward displacement of the antral wall; extension leads to involvement of the hard palate or alveolar margin, or to bulging inwards of the lateral nasal wall. Breaking through into the nasal fossa causes a blood-stained discharge, and sinuses may appear in the skin of the cheek. The course of the disease is rapid, owing to the great vascularity of the part, but lymphatic glands are not involved until very late when the skin is infiltrated. It is possible to deal with these patients by operative measures, which must be varied according to the requirements of the case. Radium may be of service after removal of the growth by excision and diathermy. External irradiation treatment by deep X-ray therapy or teleradium may be used instead of, or in addition to, operative removal. We, however, recommend surgical removal, combined with diathermy, for the majority of cases.

Sarcoma also may commence in the nose itself. It gives rise to the usual signs of an intranasal growth, and may sometimes be dealt with in a satisfactory manner by surgical removal and the application of diathermy, followed by radium. A few cases are on record in which such treatment has proved efficacious in curing the disease.

The **operations** which have been devised *for dealing with malignant disease of the nose and naso-pharynx* are numerous.

(*a*) In some cases of intranasal disease *Rouge's operation* has been recommended, but is now seldom used. It consists in the detachment of the mask of the face from the maxilla by everting the upper lip and incising the mucous membrane and subjacent tissues until the nasal cavities are opened. The septum nasi is divided by cutting-pliers, and the nasal cartilages are completely separated. The soft tissues of the face can then be retracted upwards, and the nasal fossæ fully exposed. The bleeding is always considerable, and the space gained in children is but slight. When the operation is completed, the mask of the face is allowed to fall back again into position, union occurring without difficulty.

(*b*) When the upper and anterior portion of the nasal cavity is to be dealt with, *lateral rhinotomy*, as described above (p. 964), or some modification of it, may be employed with advantage. Any area of skin infiltrated by growth must, of course, be removed. The same operation gives excellent access to the naso-pharynx.

(*c*) When the disease is located further back, originating rather in the naso-pharynx than in the nose itself, the *palatine route* may be used. Perhaps the best of the several suggested operations is that of *Nélaton*. This consists in a median section of the velum and of the mucous membrane covering the posterior half of the hard palate, most of which is cut away, as also the back of the vomer, if necessary. The naso-pharynx is thus opened sufficiently to allow of the removal of the

growth. The reflected segments of the palate are subsequently sutured together. This operation is now seldom undertaken owing to the possibility of non-union of the palatal flaps and the greater advantages of the lateral nasal route.

(*d*) By elevating the upper lip and opening the antrum through the canine fossa and then removing the lateral wall of the nose, as in Denker's operation, extensive growths can be removed, provided they do not involve the higher regions overmuch, and particularly the frontal sinus. Part of the upper alveolus is taken away and, after clearance of the growth by surgical excision and diathermy, a large opening is left, through which the cavity may be irradiated with needles carried in an obturato and may be inspected for possible recurrence. The deficiency is rectified by the provision of an obturator attached to a denture, with no disfigurement. In our opinion this operation is to be preferred for almost all malignant growths of the nose, sinuses, and naso-pharynx.

Naso-Pharynx.

Adenoids.—The naso-pharynx is the seat of a large amount of lymphoid tissue, similar to that met with in the tonsil, situated on the roof and known as the pharyngeal or Luschka's tonsil. Adenoids consist in hypertrophy of this tissue, exactly analogous to the chronic hypertrophic form of tonsillitis, with which, indeed, it is often associated. They occur in the form of broad, cushion-like masses in the vault. The formations are soft and vascular, bleeding very readily. The surface is plicated, and in the recesses or folds between the different portions of the mass bacteria lodge and give rise to various inflammatory troubles locally, and occasionally in neighbouring lymphatic glands. Not uncommonly isolated masses similar in structure to the above are to be seen on the posterior wall of the pharynx, and a certain amount of chronic rhinitis and laryngitis may be associated. The condition is rarely seen in others than children, and especially those living in the smoky atmosphere of large towns. If untreated, adenoids usually disappear by the age of twenty, but not before much harm has been done to the individual.

The **Symptoms** are mainly due to obstruction to nasal respiration. The mouth is generally held half open, to allow the child to breathe through it, thereby exposing the upper central incisors (Fig. 687); from a similar cause he snores during sleep, and usually wakes with the mouth and tongue dry. The nostrils are drawn in, and the nose is thin and pinched, the whole facies being characteristic; the children often look sleepy and half silly, and, indeed, may be very backward in their studies. Not uncommonly there is a certain amount of semi-purulent discharge from the nose, or it may be hawked up from the pharynx, perhaps mixed with blood. Deafness is caused if the tympanic membranes are indrawn because of obstruction of the Eustachian tube. Catarrhal otitis media may result from extension of the catarrhal condition of the mucous lining of the Eustachian tubes, and deafness may be induced thereby. The presence of adenoids increases the chances of acute inflammation of the ear during attacks

of acute rhinitis or naso-pharyngitis and also interferes with recovery. Both taste and smell are sometimes impaired as a result of hypertrophic rhinitis. The ethmoid and maxillary sinuses may become infected. The palate becomes high and arched, owing to the altered intranasal air pressure, and as the patient grows up the incisor teeth may project forwards, giving a curious rabbit-like expression to the face. The cervical glands become infected from the tonsils and are enlarged, and are often the seat of tuberculous disease. In bad cases which have been allowed to persist throughout adolescence the thorax becomes flattened, the ribs are drawn in, and the spine is kyphotic (Fig. 688).

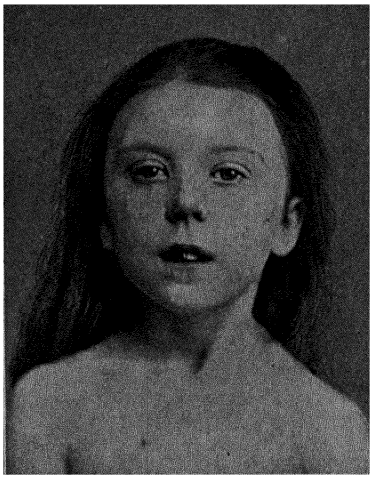

FIG. 687.—ADENOID FACIES. (FROM A PHOTOGRAPH KINDLY LENT BY SIR ST. CLAIR THOMSON.)

This illustration shows well the sleepy look, the pinched nostrils, the open mouth, and projecting upper central incisors, so characteristic of this condition.

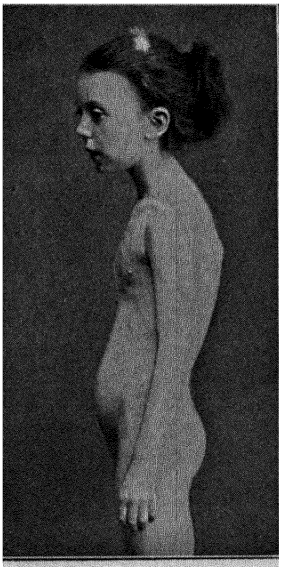

FIG 688.—LATERAL VIEW OF A CHILD WITH NEGLECTED ADENOIDS (FROM A PHOTOGRAPH LENT BY SIR ST. CLAIR THOMSON.)

This is the same child whose face appears in Fig 687 It will be seen that the chest is shallow and retracted, and the spine kyphotic. The arms are small, but the legs are well developed.

Physical Examination consists in posterior rhinoscopy, by means of which the adenoids can be seen, or in palpation of the posterior nares, a process to be avoided but occasionally necessary in children, if they have not sufficient control to permit of the former. On passing the finger behind the velum, the naso-pharynx is found to be occupied by a soft mass of tissue which readily bleeds, and more or less obstructs the openings of the posterior nares.

Circumstantial evidence is derived from the symptoms, from the presence of enlarged and unhealthy tonsils, and from the retraction

of the tympanic membranes; a diagnosis of adenoids should thereby be made without the necessity or desirability of the unpleasant post-nasal palpation.

Treatment consists in removal of the adenoids by operation if marked symptoms and signs are present. In mild cases improvement may be obtained by reduction of carbohydrates and increase of fats in the diet, by giving vitamin-containing oil of cod liver or halibut and by the use of nasal drops of argyrol, 5 per cent. In young adults arsenic in small doses (liquor arsenicalis, ♏ ii. b. or t.d.s.) may be of value after operation. Nasal douches must never be used, for fear of setting up infection in the sinuses or ears. The only effective way of dealing with the condition is by surgical removal, whatever the age of the child.

Operation.—The child, lying on its back, flat or with a pillow under the shoulders, is anæsthetized with ethyl chloride, either alone or preferably followed by ether. Premedication with nembutal, given by mouth, or paraldehyde administered rectally, is strongly recommended. If enlarged tonsils co-exist, these should be dealt with in the first place. Gottstein's curette, or some modification of it, is then introduced behind the soft palate. It is pressed upwards so that its free convex edge impinges on the upper part of the posterior border of the nasal septum. It is then swept backwards and downwards over the pharyngeal wall, so as to shave away the chief portion of the projecting mass of adenoids. Possibly the application of a second curette may be required to deal with outlying lateral portions; any remaining tags are removed by the use of Luc's or any other suitable forceps. La Force's adenotome (Fig. 689) is a most useful instrument, and is preferred by many to a curette. By its use the whole mass of adenoids can be removed cleanly, with no possibility of damaging the pharyngeal aponeurosis or constrictor muscle. There is considerable bleeding, but this quickly stops of itself, except in rare cases which require plugging of the naso-pharynx. The blood is removed by a suction pump, but, if one is not available, the child should be turned over and held face downwards immediately after the operation, so as to allow the blood to run out of the mouth and nose, whilst the face and forehead are sponged with ice-cold water to check the hæmorrhage. Many surgeons prefer to perform the operation with the child lying on his side. The patient is kept indoors for a few days, and only fluid food allowed. The most likely complication is acute otitis media, indicated by earache and rise of temperature. No local after-treatment is required as a rule, but the throat may be gargled with a mild antiseptic. Nose-breathing exercises should subsequently be instituted, and in many bad cases are as important as the operation.



FIG. 689.—LA FORCE'S ADENOTOME.

Neoplasm of the Naso-Pharynx. **Naso-Pharyngeal Fibroma** is the

term applied to a neoplasm which springs from the base of the skull, either from the basi-sphenoid or basi-occipital. It is firm, smooth, and fleshy in character; when of large size, it may be lobulated. The early symptoms are almost limited to those of obstruction to nasal respiration, but to this is not unfrequently added severe epistaxis owing to the vascularity of the capsule and of the overlying mucous membrane. As it increases in size, ulceration occurs, leading to a fœtid sanious discharge, and the growth rarely remains limited to the naso-pharynx. If pushing forwards, it may lead to expansion of the bridge of the nose and separation of the eyes, which may even be made to diverge; but if backwards, it may depress the velum and hang downwards. In other cases it may burrow into the orbit or any of the other surrounding cavities, or may even erode the base of the skull or encroach upon the cranium. It is rare for any of these latter manifestations to occur until after the tumour has become sarcomatous, a change which sometimes occurs.

The disease attacks young people, and mainly those in the second decade of life. It progresses with increased rapidity if malignant changes take place; a fatal issue may be due to hæmorrhage, asphyxia, or cerebral complications.

Malignant Neoplasms.—In rather older subjects a sarcoma may appear in the naso-pharynx as a primary growth, with symptoms similar to those already described; the course is rapid.

Primary carcinoma also occurs, and may spread down the naso-pharyngeal wall to appear below the soft palate; the Eustachian tubes are obstructed by the growth, with symptoms of deafness at an early stage.

Treatment.—The aim in simple cases, whether the tumour is small or large, is to remove it completely, together with the underlying periosteum from which it arises. Nélaton's operation will in some cases assist the surgeon to reach the base of the skull and deal with the tumour. Lateral rhinotomy is sometimes more satisfactory. In the more severe cases, where the growth has become diffuse, it is very doubtful whether any good can be done by operation, since the base of the skull is certain to be gravely affected. Radium may then be of real use, leading to marked shrinkage and fibrosis of the tumour, as also to the destruction of any small portions remaining after operation.

Malignant growths respond well to deep X-ray therapy, and therefore this is recommended as the method of choice, whether the growth be carcinomatous or sarcomatous. The treatment must be prolonged and thorough and involves considerable discomfort to the patient.

CHAPTER XXXI.

AFFECTIONS OF THE TONSILS AND PHARYNX.

By V. E. NEGUS, M.S., F.R.C.S.

Acute Tonsillitis results from bacterial infection, sometimes of a semi-epidemic type. The palate, fauces, and pharyngeal walls generally participate in the inflammatory process; among the organisms present are staphylococci, pneumococci, and streptococci, often one type in almost pure culture, but sometimes as a mixed infection. Two varieties of acute tonsillitis are described, but there is no sharp line of demarcation:

(*a*) Acute parenchymatous tonsillitis causes general enlargement of the organ, which is dusky red in colour, and painful, causing obstruction to swallowing and sometimes to breathing also in those cases in which the tonsils almost meet in the middle line. The temperature is high; the glands below the angle of the jaw become enlarged and tender; the tongue is covered with a thick, whitish fur; and the bowels are confined. The local condition may be associated with septicæmia in severe cases.

(*b*) Acute follicular tonsillitis differs only from the description just given by marked involvement of the tonsillar crypts, from which a yellow exudate discharges itself, coagulating on the surface to form a false membrane, unlike that of diphtheria, however, in that it does not cause bleeding when detached.

This type of inflammation affects more often tonsils of the buried variety, while the parenchymatous enlargement is associated with prominent tonsils.

Peritonsillar abscess, or *quinsy*, is a complication of acute inflammation of the tonsil, with suppuration around it. The usual site of the abscess is just outside the capsule, at the upper pole; infection extends outwards through the superior tonsillar fossa. Occasionally an abscess forms in the tonsil itself. Both sides are inflamed, but the suppuration is often unilateral, or, if bilateral, one tonsil is affected before the other; pus usually takes three to seven days to form. The swelling is great, so that breathing and swallowing are alike difficult; the temperature is high, pain is severe, and the cervical glands are considerably enlarged. Œdema of the glottis may result. Other symptoms are much the same as in those described above. Left to itself, the abscess sooner or later points and bursts, usually in the soft palate above and to the outer side of the tonsils, and this gives the patient immediate relief.

The **Diagnosis** from *scarlet fever* must be made by the absence of the characteristic rash and red tongue of the latter condition, and by the redness being more dusky and less diffuse in tonsillitis. From

erysipelas of the fauces, it is known by the redness being more concentrated, the œdema less marked and more limited, by the glands at the angle of the jaw being less enlarged, and by the absence of any external manifestation of the disease. From *diphtheria* the follicular variety is recognized by the want of adhesion of the false membrane to the subjacent parts and by the absence of the Klebs-Loffler bacillus on cultivation. In acute tonsillitis the temperature tends to reach a higher level.

Treatment should always be commenced by a good calomel purge, which may be followed by the administration either of salicylate of soda (10 grains, thrice daily), or of chlorate of potash. The patient will experience much relief by inhaling the steam from hot water (180° F.) in which a little friar's balsam (3i.) and menthol (gr. iii.) is dissolved, or the tonsils may be painted with a 10 per cent. solution of protargol or 5 per cent. solution of guaiacol in glycerine several times a day, the latter paint acting both as an antiseptic and as a local anæsthetic. Pus is evacuated as early as possible: this should be effected by the use of sinus forceps after incision of the superficial layers with a guarded scalpel. The surface may be anæsthetized with equal parts of cocaine solution (10 per cent.) and adrenalin, applied on a wool swab. Fig. 690 indicates the point of election at which to open a peritonsillar abscess, *viz.* a little internal to a point midway between the base of the uvula and the last upper molar tooth (Sir St. Clair Thomson). The opening is suitably enlarged downwards and towards the middle line. It is essential not to go too deep or too far outwards, so as not to injure the superior constrictor or to open through the deep fascia. Both before and after opening the abscess, hot flannels or fomentations may be applied to the neck and throat, and plenty of fluid nourishment administered when the patient can swallow comfortably. This is followed as soon as possible by tonics. The fact that quinsy is very liable to recur suggests that during the quiescent interval after an attack the tonsils should be removed.

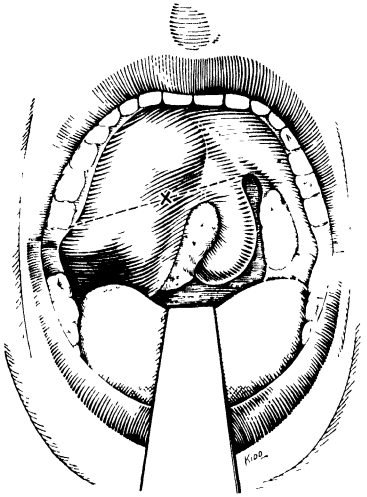

FIG 690.—DIAGRAM TO INDICATE THE SITUATION TO OPEN A PERITONSILLAR ABSCESS, VIZ. ON A LINE DRAWN FROM THE BASE OF THE UVULA TO THE LAST MOLAR TOOTH, BUT NEARER THE UVULA.

Chronic Tonsillitis frequently follows an acute attack, but may commence as a primary condition. The tonsil is more or less enlarged and of a redder colour than normal; secretion is contained in the crypts, particularly when the tonsils are of the buried variety. The condition

is seen usually in children, who suffer in addition from adenoids; the tonsils may be the seat of tubercles. Glands in the neck are liable to infection and then become enlarged, and may be the site of abscess formation, often tuberculous, but sometimes of simple inflammatory nature.

Enlarged Tonsils and Adenoids are usually seen in children of the poorer classes who live in small homes in a large city. They are often associated with enlargement of the cervical lymphatic glands, and running noses due to constant repeated colds which result in excoriation of the nostrils. These children live in unhygienic surroundings, and are fed generally on carbohydrate diet. The condition is less frequently found in the well-cared-for children of the better classes, and adenoids are less common in dry, warm climates. The pharyngeal troubles associated with scarlet fever, measles, and other infective diseases often precede the development of these conditions. In consequence of the nasal obstruction, children become mouth breathers, and sometimes speak thickly. They snore during sleep, and the inflammatory trouble is liable to extend to the mucous lining of the Eustachian tube, giving rise to Eustachian obstruction or to middle-ear complications.

As a secondary result tuberculous disease of the cervical lymphatic glands is likely to occur, probably due to infection with the bovine type of tuberculosis; the glands behind the angle of the jaw (tonsillar glands) are the first to be involved. The tonsil in such cases is frequently found to contain typical tuberculous giant-cell systems. Removal of the offending tonsils usually cures the glandular trouble. Defective teeth may have some causative influence in aggravating tonsillar affections, and it is always wise before operating on tonsils and adenoids to have the mouth put in good order; in a few cases this may obviate the necessity for operation. Recurring attacks of acute inflammation of the tonsils are often seen, and it is never wise to operate for the removal of these structures during the acute stage.

A careful examination should also be made of the nose before removing tonsils and adenoids, so as to make sure that the mouth-breathing is not due to some obstruction, such as a spur or deviation of the septum. It is important, also, to exclude sinusitis as a causative or complicating factor.

The **Treatment** of mild cases consists in first attending to constitutional weakness by removal of the patient to fresh or seaside air, and by the administration of iron and cod-liver oil; at the same time the throat, when practicable, should be painted with some antiseptic or astringent application. Small doses of liquor arsenicalis are often of value in these cases.

In cases of chronically enlarged tonsils and adenoids, associated with marked symptoms or secondary pathological signs in neighbouring or distant organs, the tonsils should be removed by enucleation. The old-fashioned method of removing a portion of the tonsil by bistoury or guillotine should never be performed. **Complete Tonsillectomy** or enucleation may be carried out in two ways:

1. *Enucleation by the Guillotine.*—The patient, usually a child, is admitted to hospital on the previous day so as to permit a careful examination of heart, lungs, and urine; instructions should have been given to the mother to administer a suitable aperient on the evening before admission. Operations on out-patients are most undesirable, though sometimes performed, from lack of beds. The child is anæsthetized with ethyl chloride, preferably followed by ether; premedication with nembutal by mouth or paraldehyde given rectally is desirable. He is then placed on the operating-table, lying on the back, with a pillow under the shoulders. The surgeon stands on the right of the patient. The mouth is opened by means of a Doyen's gag lying on the left cheek.

The instrument of choice is Heath's reinforced guillotine, fairly blunt. Holding it in the right hand, the ring of the instrument is first carried round the lower pole of the right tonsil, and by a rotating and forward movement the tonsil is lifted forwards and upwards out of its bed. The tip of the index finger of the other hand is then placed on the outer attached part of the anterior pillar of the fauces, and by pressure against the ring of the instrument the tonsil is gradually everted and pushed completely through the ring. The blade is then slowly closed down by pressure of the thumb of the right hand, great care being taken not to encroach on the anterior pillar, as it may easily be introduced along with the everted tonsil if the digital pressure has been too vigorous. Final removal is completed by a levering movement of the hand.

The tonsil is then completely removed, the blade making its way between the capsule and the layer of fibrous tissue lining the tonsillar bed. Hæmorrhage is free at first, but pressure with sponges held in forceps easily controls it. Any large bleeding vessels can be picked up later by suitable forceps and ligatured.

The guillotine being now taken in the left hand, the left tonsil is removed in a similar manner, the actions of the right and left hands being reversed. It is a great advantage if the surgeon is ambidextrous; if he can only use the right hand, it is necessary for him to stand behind the patient's head on starting the removal of the left tonsil.

The operation is completed by the removal of adenoids, and the child is rapidly turned into the prone position to allow of the escape of blood from the mouth and nose. Put to bed on the side with his face more or less downwards, he soon recovers consciousness, and is encouraged to cleanse his mouth. He is advisably kept in bed for a day or two, and should wash out the mouth and throat with some weak antiseptic lotion; soft food is, of course, all that is permissible.

2. *Enucleation by Dissection.*—Various methods are in vogue when it is found undesirable to use the guillotine. The essential points are first to lift the tonsil out of its bed by means of a suitable pair of vulsellum forceps; the mucous membrane is then divided between the anterior faucial pillar and the free surface of the tonsil, thereby exposing its capsule. The tonsil is gradually freed from its bed and removed by blunt dissection, the mucosa everywhere being divided as near the free surface of the tonsil as possible. Division of the

junction between palatine and lingual tonsil is effected by the use of a snare. Bleeding vessels are then ligatured if necessary.

In either operation serious hæmorrhage may occur, either at the time of operation or later (reactionary or secondary). It can usually be controlled by direct pressure applied to the raw surface by means of a pad or plug of gauze, and held by suitable forceps; counter-pressure of a finger from the neck may be of assistance. Morphia to keep the patient quiet, and ice to the neck, may be used in post-operative cases before suturing. Hæmoplastin given by injection or applied locally to the tonsil fossa may stop the hæmorrhage. If bleeding is excessive, search must be made for bleeding vessels, general anæsthesia being used if necessary. Ligatures are applied where required; suture of the pillars of the fauces over a small roll of gauze soaked in iodoform is occasionally called for. In adults an alkaline mixture may be given before the operation, for three or four days, sufficient to render the urine alkaline.

Syphilitic Disease of the tonsil is met with in various stages. The primary chancre is seen occasionally. The glandular enlargement in the neck is very marked in such cases, and the course of the disease as a rule severe. Secondary ulcers of the 'snail-track' type (*plaques muqueuses*) are common in this region, being usually symmetrical. In the tertiary period a diffuse gummatous infiltration occurs, involving also the palate and fauces, and leading to pharyngeal stenosis.

Tumours of the Tonsil are almost always malignant in type, but are not very common. *Epithelioma* occurs as a firm indurated infiltration, rapidly spreading to adjacent parts, with early involvement of the lymphatic glands. It starts either in the tonsil itself, near the root of the tongue or in the pillars of the fauces, and presents a ragged, nodular surface with a hard margin and with an area of ulceration if advanced. It is not always painful, and notice may first be called to it by the enlargement of the glands in the neck. It runs a rapidly fatal course if left to itself. *Lympho-sarcoma* of the tonsil arises in the organ itself; it presents a smooth, dusky red appearance, the mucous membrane being stretched over it, and feels soft and almost fluctuating. In the early stages it may be freely movable, but before long it infiltrates surrounding structures, and affects the neighbouring lymphatic glands. *Round-celled sarcoma* also attacks the tonsil as a primary growth, and is less limited and defined than the former. In all these varieties the growth extends into the pharynx, impeding deglutition and respiration, and ulceration with or without serious hæmorrhage may ensue; indeed, the latter complication is a frequent cause of the fatal result.

Extirpation of Malignant Tumours of the tonsil is sometimes impracticable from the extent of the disease and the early implication of the surrounding structures, although it has now been shown that they are more amenable to treatment than was formerly thought to be the case. As will be mentioned later, it is preferable to treat cases by external radiation therapy if suitable technique is available. The disease may be dealt with by operation in two ways: (*a*) *From the mouth* in the case of the loosely encapsuled and freely movable lympho-sarcomata. The capsule is divided, preferably by a diathermic cautery, and the

growth shelled out, sometimes with the utmost ease, and with very little hæmorrhage. Removal should be followed by radio-therapy, but recurrence in the lymphatic glands is almost certain to follow. (*b*) From the mouth in cases of epithelioma, diathermy being used to coagulate the growth, which is then removed piecemeal. Preliminary ligature of the external carotid artery is advisable, combined at the same time with block dissection of glands in the neck, if there is any suspicion of their infection. (*c*) *From the neck.* This plan is the method to be used in dealing with an epithelioma if operation is decided upon. A vertical incision is made along the anterior border of the sterno-mastoid with a second horizontal arm, and a careful dissection conducted down to the pharyngeal wall, removing all lymphatic glands, and securing the external carotid or its anterior branches. The mass is then isolated from the surrounding structures and removed, after dividing the mandible to give free approach; part of the lower jaw bone is removed, together with the growth.

New growths of the tonsil respond well to radiation therapy. The best method is to commence with teleradium or deep X-ray therapy, and to follow this by needles inserted through the mouth, arranged so as to irradiate the whole of the growth, or applied to the surface in the form of a plaque. Small residual areas may, alternatively, be destroyed by diathermy.

Affections of the Pharynx.

Acute Pharyngitis is usually associated with a similar inflammatory condition of the velum palati, nasal mucous membrane, and tonsils, and results from exposure to cold, from inhalation of septic organisms, and from general diseases of the exanthematous type, *e.g.* scarlet fever and diphtheria. It is characterized by redness, pain and swelling of the mucous membrane, which becomes covered with mucus or muco-pus. An irritable cough, perhaps with sneezing, interference with nasal respiration, and great pain on swallowing, is produced by this condition, and if it spreads to the Eustachian tube temporary deafness is induced. Ulceration of the velum and fauces occasionally follows.

The **Treatment** consists in attending to the general condition, especially if of exanthematous origin, and in administering remedies, *e.g.* purgatives and diuretics, and soothing local applications, *e.g.* lozenges of phenol (gr. ½), ice to suck, chlorate of potash or phenol gargle, etc. Great relief is often given by inhaling steam from water at 180° F., to which a drachm of friar's balsam and 3 grains of menthol have been added. A spray of protargol (2 per cent.) or a paint (10 per cent.) is useful.

Chronic Pharyngitis is commonly met with in clergymen and public speakers who are called upon to exert their voices for any length of time, in costers and street-hawkers who shout their wares, and in drinkers and smokers. In the majority of cases it is secondary to some form of rhinitis or sinusitis, or to nasal obstruction. It may commence as a chronic inflammation, or may follow an acute attack.

membrane, especially in the neighbourhood of the fauces and soft palate, which rapidly runs on to ulceration, and may impede both respiration and deglutition. The administration of salvarsan, or of mercury and iodide of potassium, should cause rapid improvement, but the subsequent cicatrization may bind down the velum, and lead to pharyngeal stenosis of such a character as to constitute a fibro-cicatricial septum, with an opening through it perhaps only large enough to allow a small bougie to pass. For such a condition much may be done; the opening may be dilated by careful division of some of the bands and the passage of bougies. Of course, there is a great tendency for the opening to contract again, and treatment by bougies or a soft rubber tube must be maintained, while in resistant cases skin grafts must be applied to raw or divided surfaces.

A *localized gumma* may form in the submucous tissue, not unfrequently involving the posterior pharyngeal wall, and running its ordinary course with or without ulceration.

Retro-pharyngeal Abscess is acute or chronic in its course. The *acute* form results occasionally from infection through the mucous membrane, as by fish-bones, etc.; usually it arises from an imflammation of the lymphatic glands, which are found in this situation in children, and derive their lymph from the interior of the nose and naso-pharynx. The pus is situated between the pharyngeal wall and the prevertebral fascia, and is therefore near the surface and limited to one side. The *chronic* variety generally follows tuberculous caries of the spine, or disease of the bones at the base of the skull, and the pus is placed behind the prevertebral fascia, spreading across the mid-line. Whether acute or chronic, the abscess forms a tense elastic swelling, situated behind the posterior pharyngeal wall; in the former case it is associated with high fever, and locally much redness and inflammatory œdema, which may even extend to the glottis and cause dyspnœa; in the latter, where the affection is chronic, there is less local inflammatory reaction, but signs of cervical caries may be present. The abscess may burst into the pharynx, or may burrow outwards on either side, being guided by the prevertebral fascia, and point either in front of or behind the sterno-mastoid.

Treatment should never be delayed, from fear of the supervention of œdema of the glottis. The *chronic* abscess should always be opened from the neck, as then an aseptic course can be maintained; aspiration is dangerous on account of the important structures lying in front of the abscess. If pointing in front of the sterno-mastoid, the abscess is opened in that situation; but otherwise an incision should be made along the posterior border of the muscle, which must be drawn forwards, and the transverse processes of the cervical vertebræ defined. Possibly the abscess will be opened by the necessary manipulation of the wound; if not, a pair of sinus forceps is thrust into it in front of the vertebræ. The cavity is opened sufficiently to permit of careful curetting; it is then ' bipped,' and the wound closed completely without drainage.

The great majority of cases of *acute* abscesses, however, may be opened from the mouth. The child is placed on its back with its

PLATE XIII

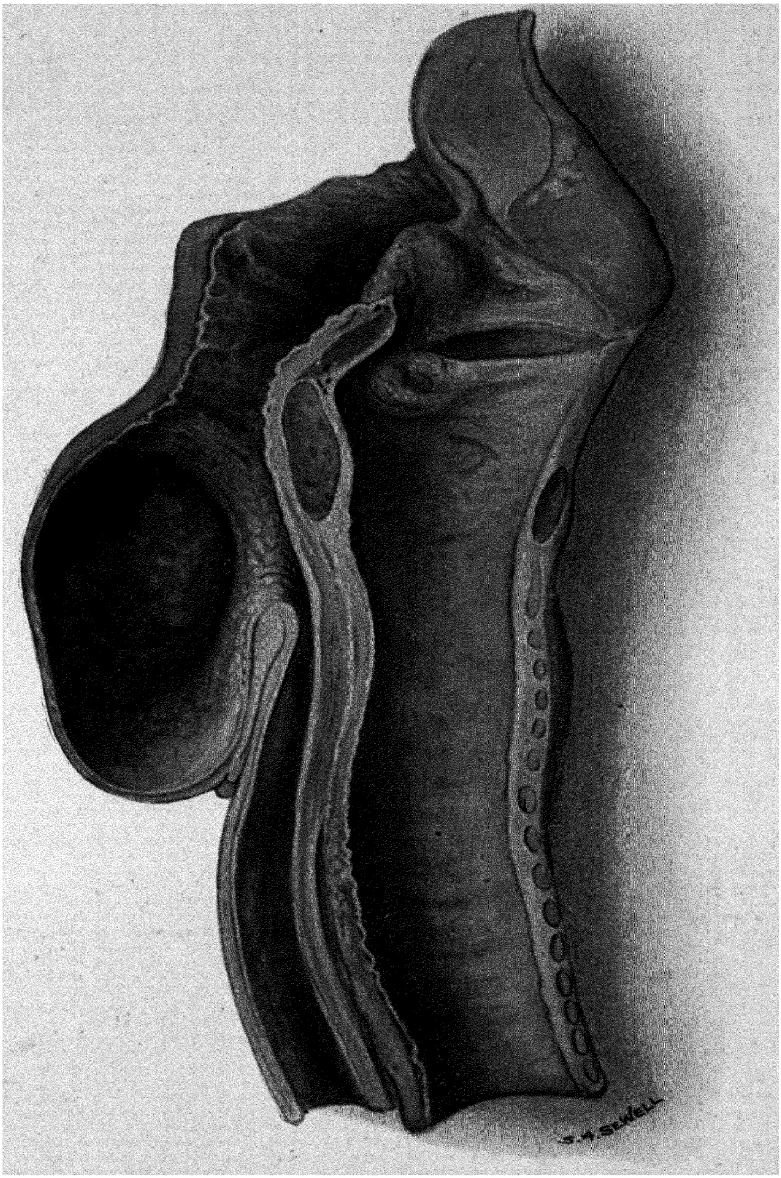

Diverticulum of the Pharynx

(*Museum, Royal College of Surgeons*)

head hanging far back; a gag is introduced, and a guarded knife inserted through the mucous membrane into the swelling at its most prominent point. Careful swabbing or suction should avoid any danger of aspiration of pus liable to cause pulmonary trouble.

Pharyngeal Diverticulum.—This complaint occurs in middle-aged or elderly individuals. The pouch springs from the posterior wall of the pharynx just above its junction with the œsophagus, and hangs downwards alongside the gullet in the lower part of the neck (Fig. 691 and Plate XIII.). It may be so large as to reach well into the mediastinum. The *symptoms* are due to distension of the cavity with food, which stagnates, forming a swelling in the neck which can be emptied by pressure; loss of weight from want of food may result, because of pressure of the sac on the œsophagus, down which food is thus prevented from passing. The administration of a small barium meal and subsequent radiography will make clear the diagnosis, which should be confirmed by œsophagoscopy. *Treatment* in mild cases consists in washing out the sac and dilating the cricopharyngeal sphincter under direct vision. In severe cases it necessitates exposing the diverticulum in the neck, through a lateral incision in front of the sterno-mastoid, removing it, and stitching up the opening in the pharyngeal wall. The operation may be carried out in either one or two stages.

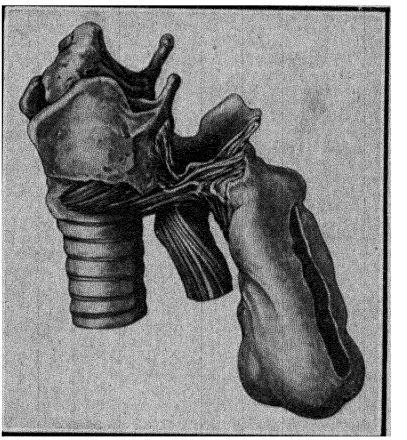

FIG 691.—LARGE DIVERTICULUM OF ŒSOPHAGUS (ROYAL COLLEGE OF SURGEONS MUSEUM.)

Epithelioma either involves the pharynx primarily, or spreads to it from adjacent parts, such as the tongue or tonsil. The most common positions for a growth are in connection with the tonsil, in the pyriform fossa, at the base of the tongue, and in relation with the epiglottis or aryepiglottic fold. The usual type of tumour develops with some amount of ulceration; lymphatic glands later become secondarily affected, and the tumour gradually invades surrounding tissues, although it is interesting to note that for some time it is limited to the mucous membrane, extending superficially over it, but not involving the underlying pharyngeal muscles. Death results from general exhaustion, from hæmorrhage due to ulceration into large vessels, from interference with swallowing or breathing, from lung infections, from pressure on important nerves, or from general dissemination.

Treatment.—Growths in the tonsil have been considered above. For those on the lateral pharyngeal wall, in the pyriform fossa, or on the aryepiglottic fold, operation is undertaken by Trotter's method of lateral pharyngotomy. An incision is made along the anterior

border of the sterno-mastoid; glands are removed by partial or complete block dissection, together with the internal jugular vein. The sterno-mastoid muscle is then sewn over the carotid sheath to the prevertebral muscles, and the lateral wall of the pharynx is freed. Part of the hyoid bone may require removal, but if the growth is low in the pharynx approach is obtained by removal of the greater part of the thyroid ala. The growth is dissected away with a sufficient margin of surrounding healthy tissue; the pharynx is closed, if possible at the time, but occasionally a subsequent plastic operation is necessary. If the growth is near the larynx, tracheotomy is desirable. Radiation therapy has been used in some cases with success; needles may be carefully arranged outside the growth after sufficient exposure by external operation, but a preferable method is by distance radiation with deep X-rays or massive units of radium.

CHAPTER XXXII.

AFFECTIONS OF THE ŒSOPHAGUS.

Anatomical Considerations.—The œsophagus reaches from the lower extremity of the pharynx to the cardiac orifice of the stomach, a distance of about 25 cm., or 10 inches. It commences at the level of the crico-pharyngeal sphincter, the muscle fibres of which arise from the cricoid cartilage, while its lower limit is approximately the lower end of the sternum. The distance from the central incisor teeth to the diaphragm is about 16 inches, or 40 cm. The tube is not quite in the middle line, but inclines to the left as it passes through the posterior mediastinum. The pericardium is in relationship with the œsophagus in front, and the pleura on each side. Its narrowest portions are its upper end, which is kept closed by the crico-pharyngeus muscle, in the centre at about 23 cm. from the upper teeth, where the aorta presses against its left lateral wall, at about 25 to 27 cm., where the left bronchus crosses it, and at the diaphragmatic hiatus. The pneumogastric nerves are also in immediate relationship with it.

The **Methods of Examination** of the œsophagus are four:

1. Palpation may reveal broadening at the level of the larynx, due to infiltrating with growth; or secondary glands in the supraclavicular fossa. Surgical emphysema or para-œsophageal abscess may be detected in cases of perforation.

2. Examination with a laryngeal mirror may reveal the upper border of a neoplasm, or may show the presence of froth in the pyriform fossa due to œsophageal obstruction lower down, or paralysis of a vocal cord caused by involvement of the recurrent laryngeal nerve in a carcinomatous growth.

3. *Radiography* is of assistance in the examination of the œsophagus. Metallic foreign bodies can be seen and accurately located; and by the use of swallowed barium it is possible to determine the situation of a stricture, and the amount of dilatation of the œsophagus above it (Plate XIV.).

4. The use of the *œsophagoscope* has transformed the surgery of this organ. If local anæsthesia with cocaine is used, it is advisable to administer a preliminary injection of morphia and scopolamine to dull the patient's sensitiveness, and also to check the salivary secretion. General anæsthesia may be employed, and is to be preferred in most cases. With the patient lying on his back, it is possible to introduce the instrument and gently to insinuate it down the gullet (Figs. 692 and 693). By this means foreign bodies, growths, strictures, etc., can be seen, and direct treatment, controlled by vision, can then be adopted. The blind use of rigid bougies is to be avoided, except in rare circumstances.

As most cases of œsophageal disease are associated with difficulty in swallowing, it is appropriate to make some general observations on the subject of dysphagia

By the term **Dysphagia** is meant a condition in which swallowing is painful or difficult. The **Causes** are very numerous, and may be arranged as follows:

1. *Buccal and Pharyngeal, e.g.* acute or chronic inflammation, whether simple, scarlatinal, diphtheritic, etc.; ulceration of syphilitic or malignant origin: stenosis as a result of ulceration; paralysis, *e.g.* labio-glossolaryngeal or bulbar, or spasm; impaction of foreign bodies; retropharyngeal abscess; tumour, etc.

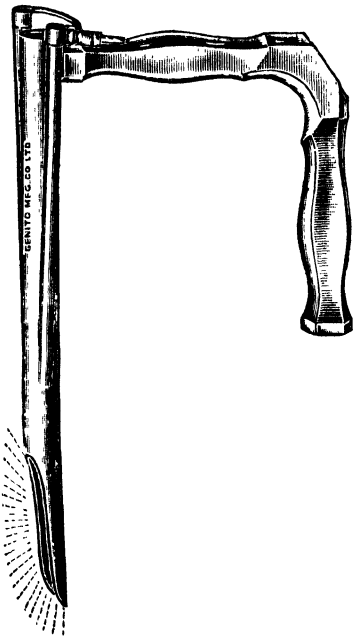

FIG. 692.—ŒSOPHAGEAL SPECULUM FOR EXAMINATION OF THE HYPOPHARYNX AND UPPER END OF ŒSOPHAGUS.

The instrument is of Chevalier Jackson's type in shape, but is fitted with twin obliquely-set lens-fronted lamps, designed to throw a light well forward.

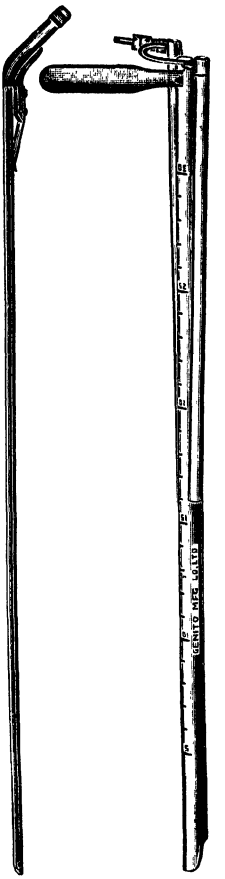

FIG. 693.—ŒSOPHAGOSCOPE, SIZE SUITABLE FOR CHILDREN, FITTED WITH TWIN OBLIQUE LIGHTING AND DETACHABLE SUCTION TUBE FOR REMOVING SECRETIONS AND FOOD DÉBRIS.

2. *Laryngeal, e.g.* acute or chronic laryngitis; tuberculous, syphilitic, or malignant disease.

3. *Œsophageal, e.g.* congenital malformations, acute or chronic inflammation, impaction of foreign bodies, the presence of diverticula, œsophagectasia, and simple or malignant stricture.

4. *Extrinsic.*—In the *neck*: goitre, enlarged glands of malignant or simple type, aneurisms, etc., tumours growing from the vertebral bodies. In the *thorax*: mediastinal growths or glands, aneurisms of the aorta and large vessels.

To *investigate a case of dysphagia*, note: (1) The method of onset, whether acute or chronic—if the former, it is probably due to a foreign body; (2) the condition of the pharynx as seen from the mouth; (3) the condition of the neck as seen and felt from without, whether or not a tumour is to be felt behind the cricoid, or whether a goitre or aneurism exists; (4) the character of the voice, as indicative or not of laryngeal disease; a laryngoscopic examination should be made; (5) the chest must be carefully examined for aneurisms, etc.; (6) the œsophagus is examined by X-rays and the œsophagoscope. If the obstruction is in the œsophagus, the patient's age and general condition will give *prima facie* evidence as to whether or not it is due to malignant disease; but it must not be forgotten that the stenosis *per se* causes loss of flesh and weight.

Malformations of the œsophagus are congenital or acquired.

A **Congenital** communication may exist between the œsophagus and trachea, or the upper end of the œsophagus may end blindly, whilst the lower end opens into the trachea near its bifurcation. A very small fistula may produce no symptoms, but in most cases life is impossible under such conditions, and the children die shortly after birth.

Congenital Webs are occasionally seen, either at the level of the crico-pharyngeal fold or in the middle or lower thirds of the œsophagus. Symptoms of dysphagia can be relieved by dilatation.

Congenital Shortening.—In this abnormality the gullet terminates at about the level of the seventh thoracic vertebra; below this level the food channel consists of stomach extending up through the diaphragmatic orifice. At the junction of œsophagus and intrathoracic stomach a stricture may be present, leading to difficulty in swallowing.

Dilatation is required, but periodical repetition is necessary, owing to a tendency to recontraction from inflammatory changes in the walls of the stricture. The epithelial covering is sometimes deficient, from developmental defect.

Symptoms of distension may be produced if the intrathoracic portion of the stomach is enlarged to an advanced degree; there may be attacks resembling angina pectoris, from pressure on the pericardium.

Acquired malformations take the form of *Diverticula.* Two types have been described: (*a*) *Pressure Diverticula* may be found near the mouth of the œsophagus or at the lower end. Those causing symptoms referred to the upper end are in truth diseases of the pharynx, and are described on p. 1045 (see Fig. 691 and Plate XIII.).

(*b*) *Traction Diverticula* are rare; they occur on the anterior wall,

near the bifurcation of the trachea, and are due to cicatricial traction from without, by adhesion of an inflamed bronchial gland to both œsophagus and trachea. They are always of small size, and cause no symptoms. They are seldom recognized *ante mortem*, except, perhaps, by direct œsophagoscopy.

Foreign Bodies frequently lodge in the œsophagus, especially in children. The usual site of impaction is at the crico-pharyngeal fold or at the level of the thoracic inlet. Portions of food, coins, bones, pins, dentures, etc., are the objects usually met with. The patient complains of pain in the gullet, whilst swallowing is painful or impossible. Large bodies may be impacted against the aperture of the larynx, and may then cause sudden death from dyspnœa; if the obstruction is not so great and remains unrelieved, œdema of the glottis may supervene. Impaction of sharp objects may be followed by ulceration, perforation, and death, either from hæmorrhage, owing to one of the large vessels being opened, or from suppurative mediastinitis. In the case of an opaque body, diagnosis, both as to its presence and situation, can be made by radiography.

The **Treatment** necessitates the use of the œsophagoscope. Removal should never be attempted blindly by forceps or a coin-catcher, as in earlier days. The cases are therefore handed over to the laryngologist in hospitals. In the absence of such assistance the medical attendant is not justified in dealing with the case by blind methods. The patient can be transferred to a surgeon provided with the necessary equipment. Unskilled attempts at removal, particularly if performed blindly, will only add danger, and must not be undertaken. Secretions are removed by suction until a clear view is obtained. The foreign body is then grasped with suitable forceps and, after careful disimpaction of any embedded points, it is removed together with the œsophagoscope.

If perforation has taken place, with infection of the tissues outside the upper end of the œsophagus—leading to the formation of an abscess—an incision, 4 inches long, is made along the anterior border of the sterno-mastoid, preferably on the left side, because the œsophagus naturally curves in that direction. The surgeon carefully finds his way between the carotid sheath on the outer side and the larynx and trachea on the inner, avoiding the thyroid vessels and nerves. The external wound is packed with gauze soaked in flavine, and left to be closed at a later date. External operation is not indicated except when perforation has occurred.

If a foreign body passes the upper narrow parts of the œsophagus, it will almost invariably slip through into the stomach, and will pass along the intestinal tract in most cases, without causing trouble. In rare cases perforation occurs in the thoracic portion of the œsophagus, with resulting para-œsophageal abscess or mediastinitis. Drainage should be established into the œsophagus, an incision being made under direct vision through an œsophagoscope.

When once the foreign body has passed into the stomach, purgatives and emetics should be avoided, and if not of large size and sharp or irregular shape, the case is left to nature, the treatment being merely

expectant. The patient is kept quiet, and fed on soft food—such as brown bread, porridge, etc.—and the onward passage of the foreign body watched by radiography. Should it be large and its course arrested, and especially if inflammatory symptoms occur, laparotomy for its removal must be undertaken promptly.

Inflammation of the œsophagus, with or without ulceration, is caused by swallowing corrosives or irritants, and, in a more localized form, by the impaction of foreign bodies. The symptoms are pain and difficulty on swallowing, and the treatment consists in giving antidotes and olive oil, in the restriction of the diet to liquids, whilst in bad cases rectal feeding or gastrostomy may be necessary.

Chronic Inflammation of the Mouth of the Œsophagus occurs in middle-aged women, and may be followed by malignant changes. The symptom is dysphagia. Some cases are associated with chronic superficial glossitis and secondary anæmia. The treatment consists in dilatation of the crico-pharyngeal sphincter, together with the administration of large doses of iron and extract of liver or hog's stomach if anæmia is present.

Simple Stricture of the œsophagus is located either near its commencement, just behind the cricoid cartilage, or more often at the level of the left bronchus, and is most frequently the result of swallowing corrosives with subsequent cicatrization of the wounds caused thereby. In most cases more than one constriction is present. At the cardiac orifice a stricture may arise from the healing and contraction of a peptic ulcer. The main *symptom* is gradually increasing difficulty in swallowing solids, and later fluids. If the obstruction is placed at the upper end of the tube, food is returned immediately; but if lower down, the œsophagus may become moderately dilated, and the food collects for a time and then returns unchanged. There is no pain in this form of stricture, although the patient is usually able to indicate the level of the obstruction. As the case progresses, he becomes steadily emaciated from sheer starvation and may even die from this cause. Radiographic examination, after the swallowing of barium, enables the outline of the stricture to be seen. The smoothness of the walls and the tapering appearance, together with the history of the case, allow a correct diagnosis to be made in almost all cases.

Treatment.—(*a*) Dilatation of the stricture by means of graduated bougies or a dilatable bag under direct vision through an œsophagoscope. An interval of some days should elapse between the attempts at dilatation. (*b*) Dilatation by perforated bougies attached to a whalebone staff and guided through the stricture along a previously swallowed thread, according to the method of Plummer, is efficient in some cases. (*c*) Gastrostomy is necessary in severe cases with emaciation. A swallowed thread may subsequently be drawn out through the gastrostomy opening, and an endless thread created by uniting the two ends. A flexible bougie is attached to the lower end of this thread, and is drawn up through the strictures (retrograde dilatation, Tucker's method). Graduated metallic olivary bougies may, alternatively, be used. At each treatment the smaller sizes

are followed by bigger bougies, until sufficient dilatation has been attained.

Varix of the veins in the lower portion of the œsophagus is occasionally met with as the result of pressure on the portal vein, or from cirrhosis of the liver. This is due to the fact that these branches open into the gastric division of the portal system, passing through the œsophageal opening into the diaphragm. Hæmatemesis may result, and has even proved fatal.

Neurological Disorders.

Spasm of the Œsophagus.—Lack of relaxation of the crico-pharyngeal sphincter and sometimes actual spasm of the muscle give rise to dysphagia referred to the level of the cricoid cartilage and to a feeling of something being stuck in the throat.

There is usually some reflex cause, such as an impacted foreign body, a malignant new growth, or chronic inflammation of the mouth of the œsophagus.

The condition may be purely neurotic, and is then associated with the sensation of a lump which moves; this is known as globus hystericus.

Treatment in cases of reflex type must be directed to the cause, while functional cases require general medical treatment and possibly dilatation of the crico-pharyngeal sphincter under direct vision.

Œsophagectasia (cardiospasm, achalasia, phrenospasm) is a term applied to a condition in which food will not pass from the thoracic œsophagus through the diaphragm, except when sufficient has collected for its weight to carry it through by gravity. There is not necessarily any spasmodic contraction of muscle fibres at the lower end of the œsophagus, as various mechanical factors are involved. Local œsophagitis is caused in many of these cases by stagnation of food, resulting in organic fibrous stricture. The disease makes itself evident most often in middle-aged women, and is of very gradual onset. There may be occasional difficulty in completing the act of deglutition, and possibly choking attacks occur during meals; but more often patients complain of a sensation of weight and discomfort in the lower part of the chest. There is sometimes vomiting of decomposed food material in large quantities. The œsophagus is markedly dilated, as revealed by radiography (Fig. 694). Examination with the œsophagoscope confirms the diagnosis. *Treatment* consists in dilating the cardiac orifice with bougies, first through an œsophagoscope, and afterwards by means of Hurst's mercury-loaded bougies.

Stretching the diaphragmatic hiatus with the fingers after laparotomy is called for in some cases. In others, with marked lengthening and kinking of the œsophagus, the gullet may be mobilized and its lower end pulled down into the abdomen (œsophagolysis). An anastomosis has been established between the dilated œsophagus and the stomach by some surgeons, but the operation is not recommended by us.

Malignant Disease of the œsophagus occurs in subjects over forty years of age, and is much more common in men than in women,

either at the junction of the pharynx and œsophagus, *i.e.* behind the cricoid cartilage; the usual situation is in the middle of the tube, where it is crossed by the left bronchus (Fig. 695), or near the diaphragmatic hiatus; the growth is usually of squamous-celled type, but in the latter site columnar carcinoma may be found, having spread up

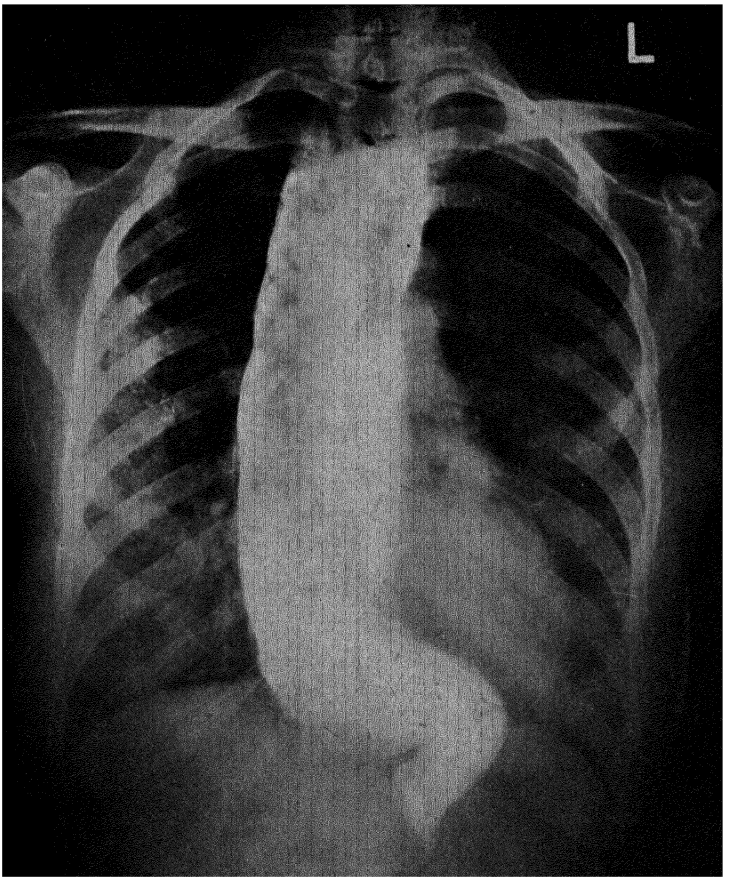

FIG. 694.—CARDIOSPASM.

Note the smooth, conical outline of the constriction, and also the dilatation and tortuosity of the œsophagus above it, in contrast to the normal calibre of the œsophagus in Fig. 696.

from the stomach. In men the middle portion of the œsophagus is mainly affected; in women the disease is almost limited to the upper end. The growth may eventually involve the whole circumference of the tube, and sooner or later ulcerates; direct outward spread leads to perforation of the trachea, pleural cavity, or rarely one of the large

vessels. Involvement of a recurrent laryngeal nerve in growth causes one-sided paralysis of the larynx, with changes in the voice; the left side is more often affected than the right. Secondary deposits appear in lymphatic glands, and sometimes in the liver. The *symptoms* consist of gradually increasing difficulty in swallowing, first for solids only, and later for liquids as well. There is often a feeling of obstruction, and occasionally regurgitation of food is complained of.

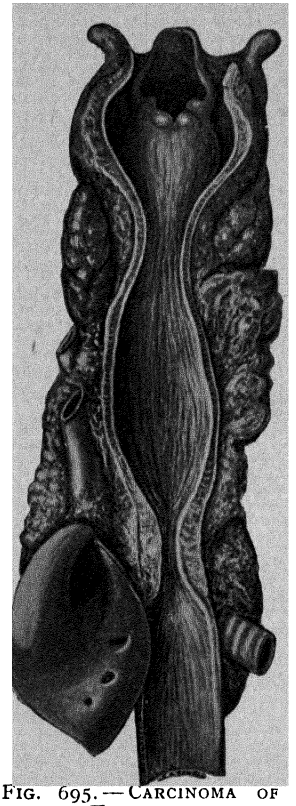

FIG. 695.—CARCINOMA OF THE ŒSOPHAGUS IN A TYPICAL POSITION.

Pain is uncommon except with post-cricoid growths, when it may appear early and be of severe type, referred to the ear, along the course of Jacobsen's nerve. Collection of frothy saliva in the pharynx worries the patient, particularly as there is often overflow into the larynx, with resulting cough; this symptom is most troublesome in cases where one recurrent laryngeal nerve is paralyzed, because of inefficiency in lateral protection of the laryngeal aperture by the aryepiglottic fold. Should the growth be at the upper end of the tube, pain may be referred to the ear, and a tumour may be distinctly felt, placed deeply in the neck and probably more marked on the left side; in the earlier stages nothing can be felt externally, although the side-to-side movements of the larynx may be impeded (Plate XIV.).

The *Diagnosis* of œsophageal stricture can be made by the history of the case, the general condition of the patient, and by administration of barium and radiography, followed by œsophagoscopy. The X-ray picture of a malignant stricture (Fig. 696) is very typical, the barium being held up in the dilated portion above it. On screen examination the upper level is seen to rise and fall. A broken, thin, irregular stream is seen gradually passing through the stricture, but when once below it rapidly passes into the stomach. In cancer the œsophagus is never greatly dilated as in cardiospasm. An œsophageal bougie must not be passed blindly in any case of suspected malignant disease; if dilatation is attempted, it must invariably be done *under vision*, for in most cases the lumen of the œsophagus is well away to one side of the growth. It is by no means difficult to perforate the walls of a diseased œsophagus and open up the mediastinal tissues, causing thereby a fatal cellulitis. The use of the œsophagoscope enables the upper part of the stricture to be seen and a piece to be taken for microscopical examination if desired; an absolute diagnosis can thus be made.

PLATE XIV

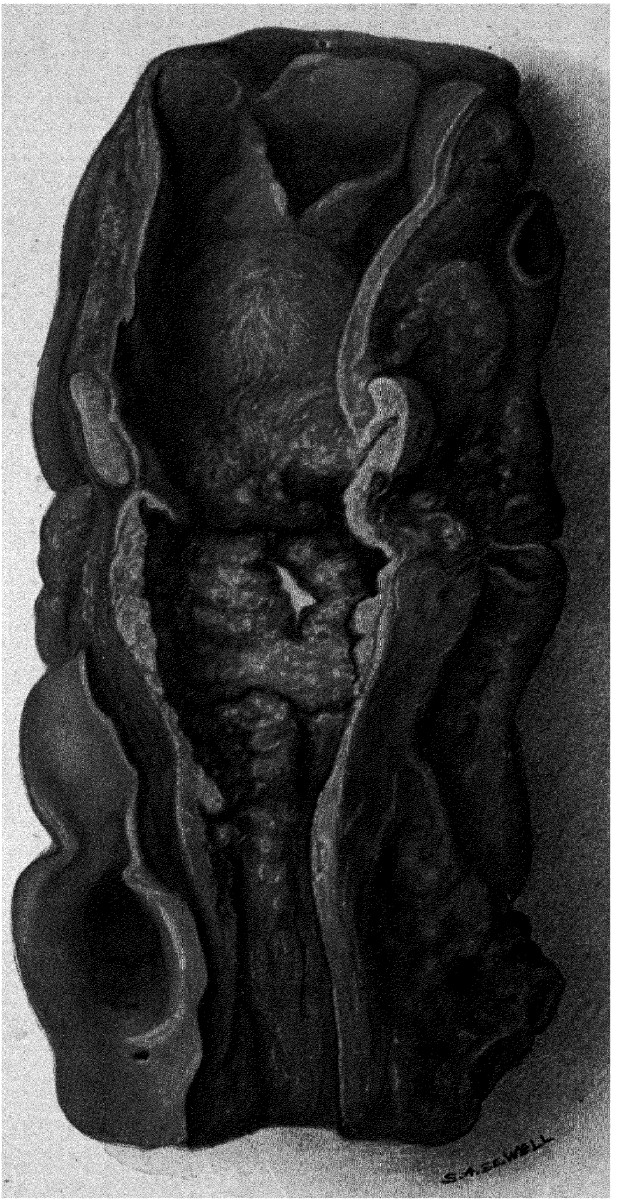

Carcinoma of the Oesophagus showing a perforation
(*Museum, Royal College of Surgeons*)

Treatment of Cancer of the Œsophagus.—The treatment of *post-cricoid growths*, if not too advanced, consists of excision of the upper segment of the œsophagus and reconstruction of the gullet by a skin tube, according to Trotter's method. Attempts to remove a growth from the middle of the œsophagus have been made on quite a number of occasions, either by a combined abdominal and cervical operation,

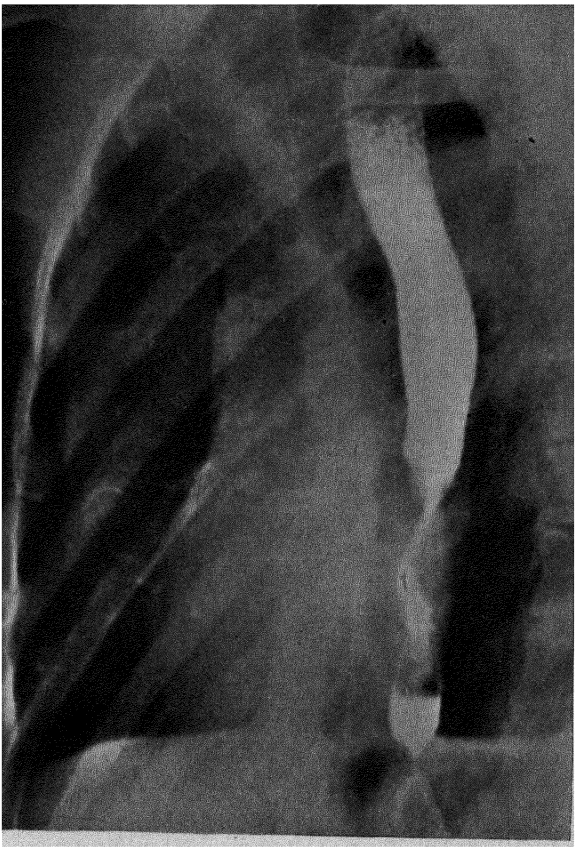

FIG. 696.—CARCINOMA OF ŒSOPHAGUS

Note the filling defect and the holding up of the barium column, but there is no appreciable dilatation.

or by the trans-thoracic route, but the results are almost always unsatisfactory, except in very rare instances. It is necessary to remove the whole œsophagus, or to bring the lower cut end out on to the surface of the thorax. Treatment by irradiation is decidedly disappointing, but with new methods of technique it is hoped that better results will be obtained.

Dilatation can be carried out by means of bougies, or, better still, by dilatable bags under direct vision through an œsophagoscope. Repeated dilatation will in some cases allow the patient to swallow with comparative ease; it can sometimes be carried out by Plummer's method, in which a thread is swallowed by the patient in order to act as a guide along which a perforated bougie on a flexible stilette is passed.

Intubation of a growth at the middle of the gullet is of decided value in enabling the patient to be fed for some considerable time by the natural channel. H. S. Souttar has introduced a tube (Fig. 697), similar in principle to that advocated by Charters Symonds, that acts beneficially. It is made of gilded German silver wire, wound in a spiral, and twisted to prevent its regurgitation, and with the upper end expanded in the form of a funnel; the lumen is large enough to permit the patient to take not only liquid nourishment, but also finely divided solids. Cases are reported in which the patient was able to retain the tube for over a year with comfort, swallowing with ease during the whole period. Before this tube is inserted the stricture must be dilated through an œsophagoscope up to 11 mm.



FIG. 697.—SOUTTAR'S INTUBATION TUBE.

Radium in small quantities has been employed over prolonged periods by means of Souttar's tubes; the radium needles are fixed in position by means of a rubber covering slipped over the flexible metal tube, which is then inserted into the stricture along a guide and withdrawn by an attached thread after one or two weeks (A. J. M. Wright).

The most successful method at present appears to be the implantation of radon seeds into the growth, all parts being irradiated. To ensure even distribution, four or five seeds may be coupled together to form a chain. Three or four such columns are required to irradiate an average growth. The method is best suited for neoplasms of the middle third, but may also be used for some at the upper and lower ends. Swallowing, almost of normal character, may return after the radiations have caused shrinkage of the carcinoma; life may be made tolerable until extension of the growth perforates the trachea or left bronchus and causes death from septic pneumonia within a few days.

It is desirable to make an attempt to restore the power of swallowing through the natural channels, but in some cases gastrostomy is called for, especially with growths at the lower end of the œsophagus.

CHAPTER XXXIII.

SURGERY OF THE AIR-PASSAGES.

By V. E. NEGUS, M.S., F.R.C.S.

Examination of the Air-Passages.—1. Before the student can diagnose affections of the upper air-passages, it is essential for him to master the use of the *laryngeal mirror*. This consists of a circular mirror set at an angle on the end of a metal stem; it is inserted into the patient's widely-opened mouth in such a way that it rests against, and slightly elevates, the soft palate. A beam of light is thrown on to the mirror, either from an electric head-lamp on the surgeon's forehead, or by reflection from a frontal mirror. The patient's tongue, held with a small cloth, is drawn well forwards so as to enable the light to reach the larynx, the image of which is seen in the mirror. Considerable practice is needed to attain any facility in the use of this instrument, and to recognize normal from abnormal structures. The use of cocaine to anæsthetize the fauces is in many cases indispensable. It must be remembered that the image is inverted, so that the anterior portion of the larynx appears behind, but there is no reversal of the sides.

2. It is now possible to see the interior of the air-passages by the use of the *bronchoscope* (Fig. 698). This consists of a straight tube, which can be introduced through the upper air-passages under general anæsthesia or after cocainization; it can then be carried down to the bifurcation of the trachea and into one or other bronchus. By this means foreign bodies can be extracted from the trachea or bronchi. Bronchoscopes with distal lighting of Chevalier Jackson's type are preferred by many, while others use proximal lighting, a mirror reflecting the light from a small electric bulb.

3. *Radiography* plays a considerable part in the diagnosis of affections of these regions. The presence and position of a foreign body is determined by this agency; the existence of abscess, bronchiectasis, or a growth in the lung can be ascertained. The movements of the diaphragm can be followed, and the condition of the chest-wall established. Pulmonary tuberculosis can be recognized at an early stage, and the condition of the bronchial lymphatic glands noted. Radiography also enables the physician or surgeon to follow the effects of such proceedings as the establishment of an artificial pneumothorax or phrenic avulsion.

Lastly, it is of use in the diagnosis of pulmonary cavities, tuberculous or simple, after the intratracheal injection of *lipiodol* (p. 1086); 10 to 20 c.c. of this material in adults (a correspondingly diminished amount in children) may be introduced into the air-passages either through the glottis or by puncturing the crico-thyroid membrane. In either

case the trachea must be previously anæsthetized by cocaine (5 per cent.) or percaine (2 per cent.). The lipiodol must be well warmed, as also the syringe; and the patient must lean towards the side which is to be investigated. Radiography should be undertaken at once. The patient must be warned against swallowing any of the material expectorated after the injection. Excellent and helpful results have followed this procedure. The solution may be introduced through a bronchoscope if desired.

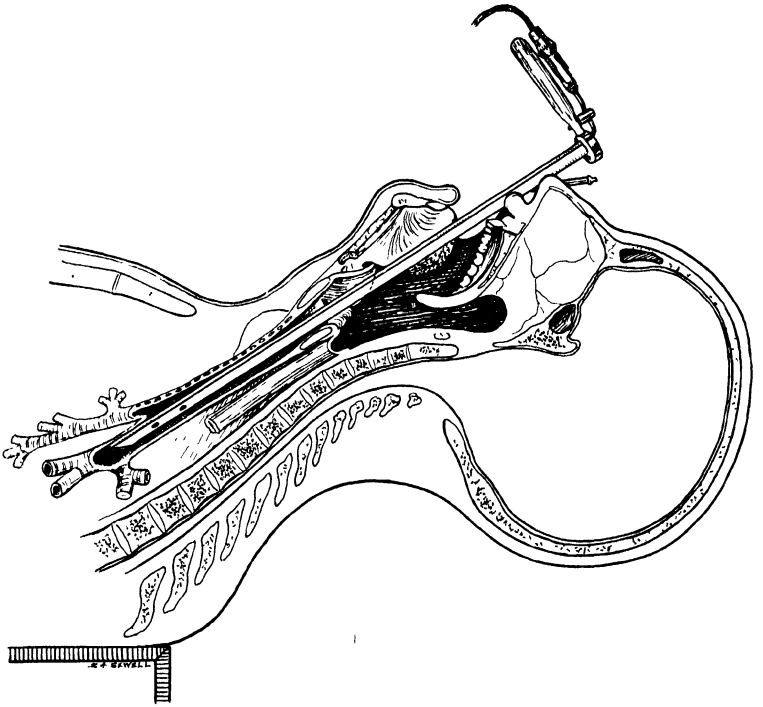

FIG. 698.—CHEVALIER JACKSON'S BRONCHOSCOPE IN POSITION

The head of the patient is raised so as to bring the occiput to a position 10 cm. above the level of the table. Half the scapula is off the table in Boyce's position, as recommended by Chevalier Jackson.

Injuries of the Larynx.—Several conditions arising from traumatism of the upper air-passages are described elsewhere, *e.g.* fracture of the hyoid bone (p. 571), and incised wounds, as in cut throat (p. 1109).

Occasionally the thyroid or cricoid cartilages may be injured or fractured by direct violence, as in garrotting, with resultant local pain and hæmorrhage, and possibly some obstruction to respiration. As a rule, no treatment is required beyond keeping the patient quiet, but should symptoms of dyspnœa arise, intubation or tracheotomy must be undertaken. The injury may be self-inflicted, as with a razor.

Inflammatory Diseases of the Larynx.

Simple Acute and Chronic Laryngitis are generally associated with affections of the nasal passages, nasal sinuses, or pharynx. They are seldom of primary origin. The acute affection is caused by bacterial infection, and is characterized by aphonia (loss of voice) and cough. Locally, the vocal cords are seen to be hyperæmic and swollen. The *Treatment* is rather medical than surgical.

Acute Œdematous Laryngitis, or œdema of the glottis, is a condition of considerable importance. *Causes.*—(*a*) It is secondary either to some other laryngeal affection, such as acute catarrhal laryngitis or acute perichondritis, or more rarely to some chronic affection, such as tubercle, syphilis, or carcinoma; or (*b*) it may extend from inflammatory conditions of neighbouring tissues, such as the root of the tongue or the submaxillary region, *e.g.* in cellulitis or Ludwig's angina; or it may be secondary to a retropharyngeal abscess. (*c*) It is also not unfrequently seen in children from drinking scalding water, as from the spout of a kettle, or sometimes in adults from swallowing corrosives. (*d*) It may result from the presence of a foreign body. (*e*) It has also been known to occur as part of the general anasarca of chronic Bright's disease. *Characters.*—The folds of mucous membrane extending on either side of the epiglottis both to the root of the tongue and backwards to the arytenoid cartilages become swollen and œdematous from a serous effusion into the submucous tissue (Fig. 699). The same condition involves the false vocal cords (superior thyro-arytenoid folds), extending down as far as the true cords. The process is checked at this level owing to the absence of submucous tissue, the vocal cords consisting of elastic fibres covered merely by a layer of squamous epithelium. The epiglottis becomes folded laterally upon itself as a leaf, leaving only a valve-like chink, which permits of expiration, although considerably checking inspiration. The *Main Symptom* produced by this condition is dyspnœa, not unfrequently aggravated by spasm of the glottis, and this is sometimes of sufficient

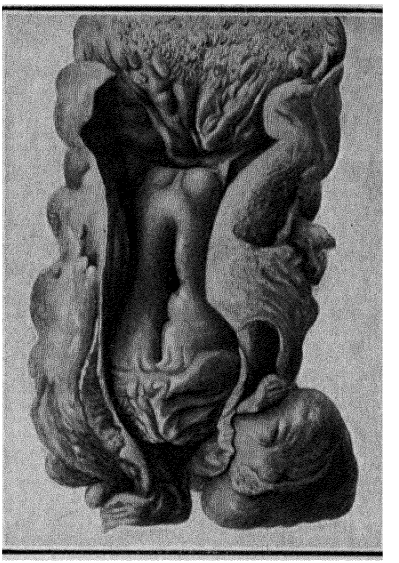

FIG 699.—ŒDEMA OF LARYNX SEEN FROM BEHIND (R C S MUSEUM)

The base of the tongue is seen to be enlarged and swollen, and the arytenoepiglottidean folds are œdematous, so that the entrance to the larynx is represented by a mere chink.

intensity to destroy the patient's life. There may be some difficulty in swallowing, owing to associated œdema of the pharynx and œsophagus, and also some degree of febrile disturbance. The diagnosis is made by laryngoscopic examination, when the slit-like opening of the glottis, bounded below and behind by thickened œdematous folds of mucous membrane, can be seen. *Treatment.*—Relief may be gained by inhaling steaming water, to which some tinct. benzoini co. has been added. Fomentations or ice compresses applied externally are also useful, especially the latter. In very severe cases, particularly in children, tracheotomy may be necessary.

Diphtheritic Inflammation (p. 122) is usually met with as an extension of a similar affection of the fauces. It gives rise to severe dyspnœa from obstruction, and, if the condition does not yield to the injection of the diphtheritic antitoxin, will require intubation, tracheotomy, or treatment through a direct laryngoscope.

Syphilitic Diseases of the Larynx.—In the *secondary* stage, mucous tubercles or superficial ulcers occasionally form in the neighbourhood of the vocal cords. No special local treatment is required. In the *tertiary* period, diffuse gummatous infiltration or localized gummata may develop, giving rise to destructive ulceration, which especially affects the epiglottis and aryteno-epiglottidean folds, and may spread and involve the boundaries of the glottis. Inflammation of the perichondrium is likely to follow, leading to necrosis of the cartilages. Hoarseness and dyspnœa are the chief symptoms, whilst considerable obstruction may be caused subsequently by laryngeal stenosis, due to cicatrization. *Treatment* consists in the cautious administration of iodide of potassium and mercury, together with injections of salvarsan or one of its later substitutes. The drugs may at first increase the swelling and thus lead to severe dyspnœa. Should urgent dyspnœa arise, tracheotomy must be undertaken. Tertiary syphilis of the larynx is at the present time very rare, owing to early and improved methods of treatment.

Tuberculous Laryngitis (Plate XV., Figs. 1 and 2) is almost always secondary to phthisis; if no focus is present in the lungs, deposits of lupus will be found in the nose or on the face. The disease commences at the posterior part of the larynx in the neighbourhood of the arytenoid cartilages as a submucous infiltration, which later breaks down, and leads to typical tuberculous ulcers similar to those occurring in other regions (p. 169). Considerable destruction of tissue ensues in advanced cases, involving the posterior region of the larynx, and even leading to perichondritis and necrosis of the cartilages. Hoarseness, cough, pain on swallowing, and perhaps a certain amount of dyspnœa, are the chief symptoms arising from this affection, the prognosis of which is always of a serious nature. *Treatment.*—As for other tuberculous affections, constitutional treatment is now mainly relied on, and for choice in a sanatorium, whilst absolute silence is insisted on. Occasionally local treatment is undertaken by the laryngologist in the form of applications of the galvano-cautery. The earlier recognition of pulmonary tuberculosis and its more effective treatment is, however, reducing the number of cases of the laryngeal affection.

PLATE XV

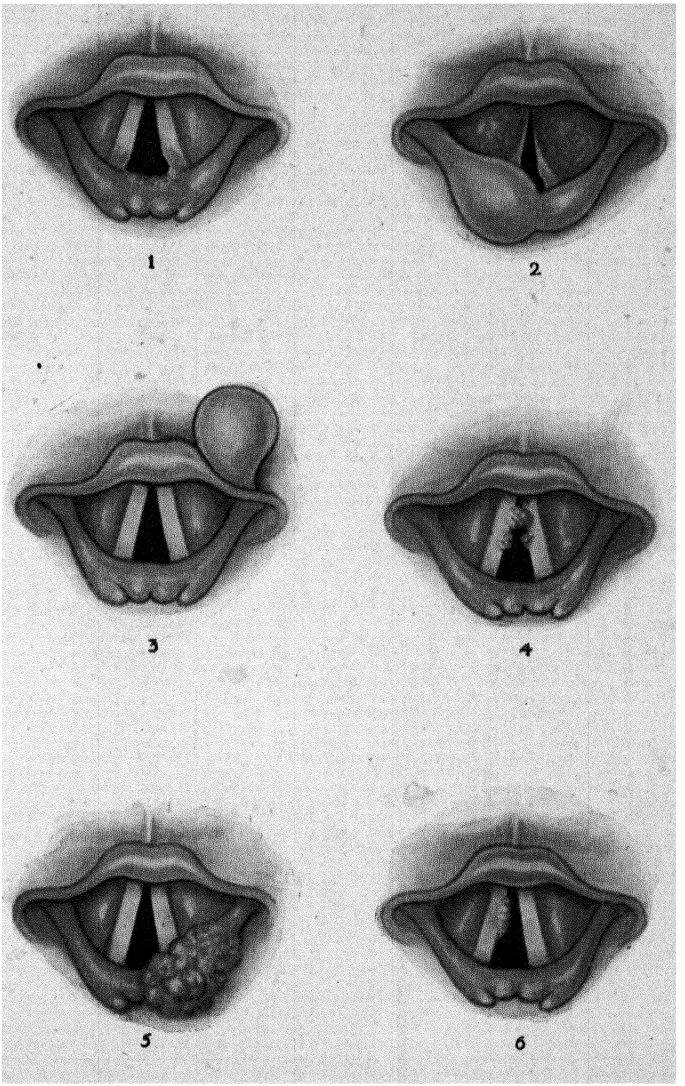

Diseases of the Larynx

1. Tuberculosis involving posterior extremities of vocal cords and inter-arytenoid region.
2. Advanced tuberculosis with ulceration of vocal cord and swelling of aryteno-epiglottic fold.
3. Mucous cyst in vallecula.
4. Simple papillomata.
5. Extrinsic carcinoma on aryteno-epiglottic fold.
6. Intrinsic carcinoma on vocal cord.

Acute and Chronic Perichondritis usually end in the formation of an abscess and in necrosis of the cartilage involved. The *acute* variety is pyogenic, and due to traumatism—sometimes as the result of high tracheotomy—or to auto-infection following acute fevers, such as typhoid. The patient complains of severe pain and tenderness over the larynx, with fever, dysphagia, and hoarseness. Dyspnœa results from swelling of the mucous membrane, and œdema of the glottis may follow. An abscess may point internally or externally, and on opening it the cartilage will usually be felt bare and perhaps necrosed. *Treatment* in the early stages is symptomatic; but when the affection is producing dyspnœa, and an external swelling is present, it is well to cut down on the cartilages from outside. Should this fail to relieve the dyspnœa, tracheotomy will be required. The *chronic* variety is more often due to tubercle, syphilis, or carcinoma; in it an abscess forms more slowly and with less constitutional disturbance, but necrosis ensues none the less. When the abscess points externally, it should be opened. When a well-marked sequestrum is present, it must be removed by an external incision, and if need be thyrotomy must be undertaken. Distortion or stenosis of the larynx is a probable sequela, possibly necessitating the perpetual use of a tracheotomy tube.

Paralysis of the Larynx may follow injury of the recurrent laryngeal nerve in the removal of a goitre, or may be due to the pressure of an aneurism of the innominate artery or aorta, a tumour in the mediastinum, or cancer of the œsophagus. Paralysis from the above causes is generally unilateral. The effect of complete paralysis of one recurrent laryngeal nerve is to produce immobility on the affected side of the vocal cord, which lies in what is known as the 'cadaveric position,' *i.e.* midway between that in which it is placed during phonation and during inspiration. When due to pressure on, and not section of, the nerve, the abductor fibres are involved first, leading to unopposed action of the adductor muscles, with serious dyspnœa in bilateral cases. The *Symptoms* arising from unilateral recurrent paralysis are slight, the voice, after a time, being but little modified, as the healthy cord is capable of passing across the middle line. If both sides are paralyzed, the voice may be slightly changed in character, but severe dyspnœa is present, and this may prove fatal, unless tracheotomy is promptly performed.

Simple Tumours.

Papillomata of the Larynx (Plate XV., Fig. 4) occur more often in children than in adults; they appear as wart-like masses, growing from the vocal cords, and give rise to hoarseness and later to dyspnœa. They are recognized on indirect laryngoscopic examination, and in adults may be successfully removed by laryngeal forceps after the parts have been efficiently cocainized. It is better, however, to employ the direct laryngoscope, as with special tubes and forceps it is possible to obtain a clear view of the parts and to remove the growths with precision and accuracy. In children direct laryngoscopy is the only possible method. **Fibroma, Chondroma, Angioma,** and **Mucous Cysts** occasionally affect the larynx, but all are uncommon.

Malignant Tumours.

Epithelioma of the Larynx occurs in elderly patients, and is more frequent in the male sex; it appears most commonly as a nodular overgrowth on the anterior third of one vocal cord (Plate XV., Fig. 6) (intrinsic type). The tumour gradually spreads, both superficially and deeply, and may eventually invade the cartilages, giving rise to necrosis. The growth in early intrinsic cases is unilateral, causing hoarseness. As it extends, the growth gives rise to dyspnœa; pain is an unusual symptom. As long as the disease is strictly limited to the interior of the larynx (intrinsic cancer), there is but little tendency to affection of lymphatic glands. Cancer of the larynx may also commence on the epiglottis, aryepiglottic fold, or on the posterior surface of the cricoid cartilage (extrinsic type). When the growth affects the exterior of the larynx or surrounding structures (Plate XV., Fig. 5), lymphatic enlargement may follow, and the disease runs a more rapid course, and may destroy life by dyspnœa, pneumonia, or exhaustion from lack of nourishment. The symptoms consist of a feeling of discomfort or of pain radiating to the ear, together with pain or difficulty in swallowing and an increase in salivation. Persistent pain in the ear in patients over forty-five years of age always demands a most thorough examination of the throat. *Treatment.*—In the early *intrinsic* stages thyrotomy (laryngo-fissure, p. 1063) and complete and wide removal of the affected area will give a good prospect of cure. An isolated growth of a low degree of malignancy on the anterior region of one cord, not extending across the anterior commissure, nor involving the arytenoid cartilage, with fairly good or unaffected movement of the cord, gives a good prospect of cure if a sufficient margin of surrounding healthy tissue be removed. In selecting cases for this operation particular attention is paid to the situation of the growth, to the degree of mobility of the affected cord, and in cases of doubt to the type of growth. An epithelioma which has not extended beyond the anterior commissure gives a better prognosis than one which spreads on to the other cord, although in the latter case it is possible to remove part of the second cord with success, either by simple laryngo-fissure or by excision of the anterior portion of the larynx in one piece. If the arytenoid cartilage is involved, and particularly if the posterior commissure has been reached, partial removal of one cord is not likely to be effective, and total laryngectomy or radiation treatment is required. Backward spread is likely to be accompanied by great loss of movement of a cord, and is generally a contra-indication to laryngo-fissure. The type of growth observed in sections of a small fragment bitten out clearly with special forceps—without injuring healthy tissues—often gives valuable information. If the malignant cells are well differentiated, the rate of growth is usually slow, and prognosis is good. This is known as Broder's Group I., and is associated with few mitotic changes in the cells. If, on the other hand, the malignant cells are embryonic in type, without much differentiation, growth is usually rapid and the prognosis bad, as any operative procedure, even by total laryngectomy,

is liable to be followed by early recurrence. This type of growth is known as Group IV., and in it mitotic changes in the cells are marked. It is sensitive to irradiation. Intermediate appearances are grouped as Classes II. and III., with prognosis midway between the two extremes. In cases of doubt microscopic examination may be necessary before the correct procedure is decided on. In extensive unilateral cases radium may be used. The ala of the thyroid cartilage is removed and a palisade of six to eight needles, each of 1 to 2 milligrammes, is placed in position and left for about seven to eleven days. External irradiation by deep therapy or teleradium may, alternatively, be used. In *extrinsic* cases removal of part or the whole of the larynx by lateral pharyngotomy, median pharyngotomy, total laryngectomy, or pharyngo-laryngectomy, together with the affected glands, may be required, and the operation may include part of the tongue and pharyngeal wall. Radiation treatment may be preferable in certain cases. Where, however, the disease has spread extensively, with involvement of numerous glands, its total extirpation may not be practicable, and the prospect of cure by irradiation may be so poor that all that can be done is to treat symptoms as they arise, tracheotomy being required in certain cases. The treatment of post-cricoid growths is referred to on p. 1053.

Operations upon the Air-Passages.

1. **Subhyoid Pharyngotomy** can be employed to provide access to the upper parts of the larynx. A transverse incision is made through the thyro-hyoid space, the pharynx is opened, and the epiglottis detached from the base of the tongue (Fig. 700). It is a proceeding that is seldom undertaken, but may be necessary for the removal of certain neoplasms.

In **Transhyoid Pharyngotomy** the hyoid bone is divided in the middle line through a vertical incision extending from the symphysis menti to the thyroid cartilage. The pharynx can then be opened either above or below the level of the hyoid bone and the back of the tongue, the posterior wall of the pharynx, or the upper part of the larynx exposed. A preliminary tracheotomy is, of course, necessary.

Neither of these proceedings is very satisfactory in that they provide very little room, unless the lower jaw and tongue are divided in the midline (median translingual pharyngotomy). In **Lateral Transthyroid Pharyngotomy** the ala of the thyroid cartilage is removed after making a lateral incision along the anterior border of the sterno-mastoid; this enables the surgeon to define the limits of the disease, and by opening the pharynx he can remove a growth on the aryepiglottic fold or lateral border of the epiglottis, after clearing the lymphatic area involved. Preliminary tracheotomy is necessary, and various remedial operations to make good the defects caused by the removal of the pharyngeal wall may be called for. The details of operation and after-treatment are too lengthy to be described here.

2. **Thyrotomy (Laryngo-Fissure)** consists in dividing the thyroid cartilage vertically in the midline (Fig. 700). This route may be used for the removal of tumours of an innocent nature, or of a localized

intrinsic carcinoma of the vocal cord. An incision is made in the middle line from the upper border of the thyroid cartilage to the suprasternal notch. Tracheotomy is performed, either below or at the level of the isthmus of the thyroid gland; in the latter case the isthmus is divided. The thyroid cartilage is stripped bare of its perichondrium on the side of the growth, and then by means of special saw and shears is cut through from below upwards. The outer blade of the shears is made to cut the cartilage a little to the unaffected side to give good clearance; the inner blade is passed through the crico-thyroid membrane and enters the glottis from below; if kept rigidly in the middle line, it neither injures the growth nor damages the vocal cord and other tissues on the sound side. The larynx is held open with retractors, and the trachea is plugged above the tracheotomy tube; the vocal cord and ventricular band, with the underlying muscles and perichondrium, are then stripped off the thyroid ala as far as necessary, even on to the cricoid ring. The ala thus separated is then removed to give easier access to the interior of the larynx. Using specially curved scissors, three cuts are needed to remove the tumour: one through the aryepiglottic fold; a second below the vocal cord; and the third behind the growth, taking away a small portion of the vocal process of the arytenoid. The growth is thus removed completely with a sufficient area of healthy tissue around it. Any bleeding is controlled; the tracheal plug is removed; the tissues are accurately sutured together, and a dressing applied. The tracheotomy tube is removed after eight to twenty-four hours.

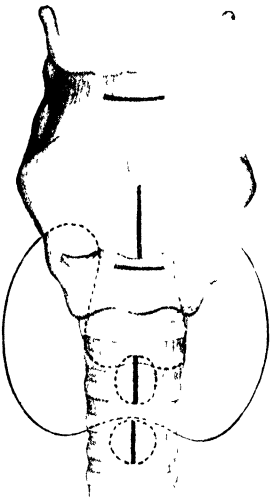

FIG. 700

The hyoid bone is seen above, with the thyro-hyoid membrane extending from it to the thyroid cartilage, a transverse incision is shown in the membrane as for subhyoid pharyngotomy. A vertical incision in the centre of the thyroid cartilage represents the position of laryngo-fissure Through the crico-thyroid membrane a transverse incision indicates where laryngotomy is performed. The trachea with its rings is shown partly covered by the isthmus of the thyroid gland; the positions of tracheotomy openings through the second and third and fourth and fifth rings are shown by vertical lines, dotted circles representing the disc removed before insertion of the cannula.

This method of treating intrinsic cancer of the larynx has been brought into great prominence and favour by the work of Sir StClair Thomson, and the after-results have proved most successful, the patient being able to speak clearly.

3. **Extirpation of the Larynx (Total Laryngectomy)** is never undertaken except for malignant disease, and then as a rule only when it

involves both sides. So long as the growth is intrinsic there is hope of a good result; but when it has spread beyond the laryngeal limits, the prognosis is much worse. In favourable cases, although the patient loses all power of normal phonation, yet he can speak with his œsophagus, or can cause a reed to vibrate while articulating with the mouth and lips. Improved diagnosis on the part of practitioners is bringing patients for operation at an earlier date, and laryngofissure is much more frequently employed than formerly, so that the performance of total laryngectomy has decreased in frequency. Into the details of the operation it is unnecessary to enter here. It must suffice to state that a skin flap with its base above is turned up and the larynx freed in front and laterally. The thyro-hyoid membrane is cut through and the larynx is removed from above downwards, being cleared from its attachments to the constrictors. The trachea is cut across below the first ring on the slant so as to enable its margins to be stitched to the edges of the skin, thus establishing a permanent opening. The rent in the mucous membrane of the pharynx is closed by sutures, the divided muscles are drawn together, and the skin incision closed, with provision for free drainage. It is possible, in many cases, to secure healing by first intention. If the disease has spread beyond the laryngeal limits, the operation must be suitably modified, and becomes increasingly difficult and dangerous. When a growth involves both larynx and pharynx, entensive removal is necessary, with subsequent operation for the repair of defects in the food passage (pharyngo-laryngectomy).

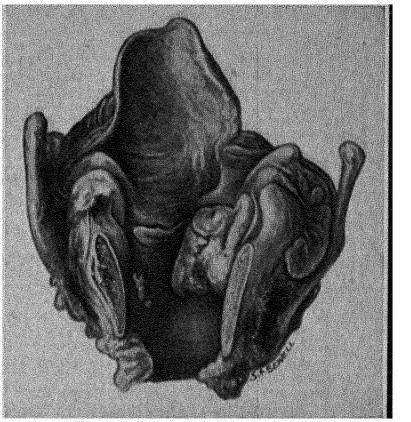

FIG 701 LARYNX OF AN ELDERLY MAN WITH AN EXTENSIVE CARCINOMA ON THE RIGHT SIDE AND A SMALL NODULE ON THE LEFT

The patient suffered from glycosuria, but survived the operation of complete laryngectomy Several months later recurrence took place in glands in one side of the neck; these were removed by block dissection Three years later the patient was quite well

4. **Laryngotomy** is rarely undertaken except for the relief of dyspnœa arising from some sudden obstruction to the respiration, and is thus to be looked on as *an operation of urgency*. It is a rare alternative for tracheotomy in cases where the entrance to the larynx is obstructed by a foreign body, for spasm of the glottis, or for accumulations of blood in the neighbourhood of the larynx during an operation. It is readily performed by making an incision over the situation of the cricothyroid membrane, which is then divided transversely along the upper border of the cricoid cartilage, the sterno-hyoid muscles being, if

necessary, drawn aside and a tube inserted. Whenever there is time to operate deliberately, tracheotomy is the better practice, since a tube inserted through the crico-thyroid space gives rise to considerable irritation, and the voice or breathing may be interfered with by the contraction of the cicatrix. A special tube is required, the lumen of which is not circular, but oval and flattened from above downwards.

5. **Tracheotomy.**—The trachea consists of from sixteen to twenty rings, of which six or seven are above the level of the sternum. The isthmus of the thyroid body generally covers the third and fourth rings; the trachea may be opened either above, below, or behind the isthmus, which is, if necessary, divided, or pushed up or down. Tracheotomy is required in any condition of serious obstruction to the respiration, occasionally for œdema of the larynx, and often for diphtheria; for stenosis, tumours, and some forms of paralysis of the larynx; occasionally before or after the removal of foreign bodies; or for compression of the larynx or trachea by external tumours, such as a malignant thyroid gland. It is also undertaken as a preliminary measure in operations on the pharynx or larynx, in which there is any likelihood of asphyxia or secondary septic pneumonia, owing to the entrance of blood or septic discharges into the air-passages. If tracheotomy is performed too near the larynx, there is great danger of perichondritis, followed by death, or of subsequent laryngeal stenosis, due to obstruction or to fixation of the arytenoid cartilages because of arthritis, with consequent loss of movement of the vocal cords; in such a case the tracheal cannula must be worn permanently. Therefore, the opening should never be so high as to injure the cricoid cartilage, nor to divide the first ring of the trachea; it should be at the level of the third or fourth, and occasionally the fifth rings of the trachea. The former distinction between high tracheotomy above the isthmus and low tracheotomy below it loses meaning, as the arbitrary boundary fixed by the gland can be ignored. A patient should never be allowed to die of asphyxia because the operator finds difficulty in opening the trachea low down; air should be let into the wind-pipe at all costs, but if the first tracheal ring or cricoid cartilage has been damaged it is important that, as soon as tranquil respiration is established, a second opening should be made well away from the larynx and the cannula transferred.

The operation is performed as follows: The patient is placed on the back, with a sandbag or pillow beneath the neck, so as to throw the head backwards and put the structures on the stretch, and with the shoulders somewhat raised. No anæsthesia may be required if the patient is partially asphyxiated, but usually it is advisable to employ local infiltration with novocain. General anæsthesia should be avoided if possible, because of the danger of increased dyspnœa at the time of operation and also for fear of post-operative lung complications. The head is held exactly in the middle line, and the surgeon feels for, and identifies, the cricoid cartilage. The incision extends from the top of the cricoid cartilage to the top of the sternum. The superficial fascia is divided, and the interval between the sterno-

hyoid and sterno-thyroid muscles made out, so as to enable them to be separated one from the other. The edges of the wound are drawn aside by blunt hooks, which should both be held by one assistant, so as to ensure equable traction.

The isthmus of the thyroid gland should be pushed either up or down, after the fascia along its lower or upper border has been transversely incised; if this is inconvenient, it is divided and ligated. The trachea is thus clearly exposed, and should be fixed and steadied by inserting a sharp hook into the lower border of a tracheal ring. The wound is freed from blood, and after the injection of about 5 minims of 2½ per cent. cocaine—except in very urgent cases—the trachea is opened by cutting through one of the rings from below upwards, a complete disc being removed, sufficiently large to admit of the introduction of the cannula, unless the urgency of the case prevents this refinement. A deep inspiration is usually taken at once, with or without coughing, and if the operation is undertaken for diphtheria the surgeon must be careful not to let any membrane which may then be expelled enter his eyes, nose, or mouth. The insertion of the tube is in many cases easy—particularly if a disc has been removed; in others it is a matter of some difficulty. Anything which suffices to separate the lips of the tracheal incision, *e.g.* the handle of a scalpel introduced and turned, a couple of hooks, or dressing forceps, will form an efficient guide for this purpose. The breathing soon becomes quiet and regular, and the tube is adjusted and fixed in position by tapes passed through lateral openings in the face-plate, and tied round the neck. The wound is dressed with a few layers of gauze beneath the plate.

When very *low* tracheotomy is performed, the inferior thyroid veins come into view, and may cause trouble if they are distended with blood, as is so frequently the case in patients suffering from dyspnœa. They must be held aside by hooks, or divided between ligatures, and the deep layer of fascia behind them incised so as to expose the trachea, which is cleared, fixed, and opened in the same way as described above; the left innominate vein may be in danger, and occasionally the innominate artery also may be near the zone of operation.

Many different forms of *tracheotomy tube* have been used from time to time, but the essential elements are a double cannula, the inner portion of which can be readily removed and cleansed: it should always be longer than the outer, in order to prevent any plug of mucus being left within the outer tube on removal of the inner. A face-plate (E) is attached to the outer cannula (A), in order to fix and steady it. One of the best is that known as *Durham's tube*, as it is adjustable (Fig. 702); it is set at right angles, and has a lobster-tailed inner tube; its removal and replacement require a little skill. A cannula made in the form of the arc of a circle is very satisfactory, if its length and curvature are correctly designed. Whatever variety of tube is preferred by the surgeon, it is essential to have several sizes to hand, as the calibre of the trachea and the depth at which it lies vary much in different patients.

Difficulties and Dangers of the Operation.—Although the above description might lead the student to suppose that tracheotomy is an easy operation, this is by no means the case, partly owing to the fact that it frequently has to be undertaken in a hurry, with perhaps inefficient assistance and in a bad light, and also because of the intense vascular engorgement of the structures. A cool head and a steady hand are in such cases of infinitely greater value to the operator than the most perfect anatomical knowledge. The following are the chief mistakes and accidents:

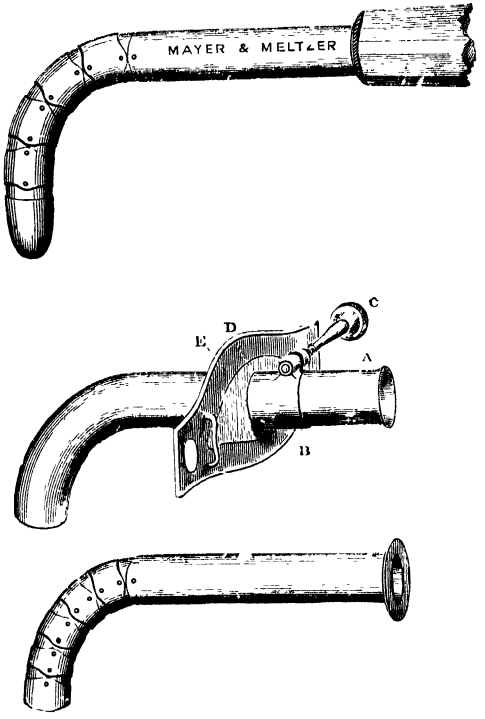

FIG. 702.—DURHAM'S LOBSTER-TAILED TRACHEOTOMY TUBE WITH INTRODUCER ABOVE AND INNER TUBE BELOW.

(1) It is *not always easy to find the trachea*, especially in the necks of fat children, or where there is an unduly large thyroid isthmus, or possibly a projection of the thymus gland into the neck. It is here most essential to keep in the middle line, although occasionally the trachea may be displaced from its normal position by some external growth, and can then be found only by careful exploration with the finger.

(2) *Hæmorrhage* is generally troublesome It is usually venous in character, arising either from the anterior jugular vein or from the inferior thyroid plexus. If possible, it should be controlled by pressure forceps before opening the trachea; but this is not always practicable in urgent cases, and luckily it usually ceases as soon as easy respiration through the tube has been established. The presence of the left innominate vein in front of the trachea must not be forgotten, although it but rarely reaches above the sternum. In about 8 per cent. of all subjects an arterial twig (the *thyroidea ima*) courses upwards from the innominate artery along the trachea, to reach the isthmus of the thyroid body; if divided, it must be secured and tied. Should much blood be inspired, it may determine the occurrence of septic pneumonia at a later date. The use of a suction pump during the operation is of great assistance.

(3) The possibility of the *entrance of air into veins* must not be overlooked, although it is an uncommon accident, since the intravenous pressure is usually increased.

(4) Not unfrequently considerable mischief has been done by *incautious use of the knife*, especially if the operator forgets to fix the trachea with a sharp hook before opening it. The knife should always be entered with its back towards the episternal notch, and the incision made from below upwards. In a child the trachea is small; and if it is moving rapidly up and down, as happens in urgent dyspnœa, or if the child is restless, the difficulty is manifestly increased. Many accidents have happened from this cause, *e.g.* wounds of the large veins or arteries of the neck, or even of the œsophagus or bodies of the vertebræ.

(5) As soon as the trachea is opened or an attempt made to introduce the tube, a severe fit of *coughing* is induced which is sometimes so prolonged as to interfere with the introduction of the tube. This can be almost entirely overcome by introducing with a hypodermic syringe a few drops of a 2½ per cent. solution of cocaine into the trachea before it is incised.

(6) The *introduction of the tube* is a matter of no difficulty if the surgeon takes the precaution of not removing the hook until this is satisfactorily accomplished. Many mistakes have followed the non-observance of this rule; thus, the tube has missed the trachea altogether, and passed into the fascial interspace in front, as also to one or other side; the outer portion of a bivalve tube has often been passed with one limb within the trachea and the other outside. A very dense diphtheritic membrane has also been a cause of difficulty, in that, although the tube has been really passed into the trachea, it has not penetrated the membrane, and thus has hindered rather than helped the breathing. In all cases of diphtheria the interior of the trachea should be examined carefully by separating the lips of the incision before attempting to insert the tube.

After-Treatment.—The patient is placed in bed, in a room kept at a uniformly warm temperature (75° F.). Draughts are excluded by curtains, and nothing, except a thin veil of gauze, should be placed over the entrance to the tube, so that respiration may not be hindered, nor the expectoration of mucus, false membrane, etc., prevented. One of the most frequent sources of extension of diphtheria to the lungs, or of septic pneumonia, is the re-inspiration of material which has been coughed out upon a portion of muslin or gauze placed with excellent intentions over the mouth of the tube. A nurse should be in constant attendance on the patient, in order to wipe away all such material *as it is expelled*. If a suction pump is available, it will be found most useful for removing secretions.

The inner portion of the tube is removed by the nurse, and cleaned frequently, any inspissated mucus upon it being readily removed by the use of a solution of bicarbonate of soda (20 grains to 1 ounce). The outer tube is also removed for cleansing purposes, but only by the medical attendant; it does not require changing sooner than fourteen days after insertion. Should the respiration become

impeded by a collection of mucus in the trachea, a rubber catheter connected to a suction pump will be of great assistance in clearing the passages.

The period for which the tube is kept in position varies, but its removal should always be undertaken at as early a date as possible, for fear of leading to impairment of the voice, or normal respiration. Before removal of the cannula the inner tube should be closed with a cork, at first partially and then completely, to accustom the patient to breathe once more through the larynx. Specially made holes in the outer cannula and inner tube of some types enable normal respiration to be performed with ease.

After-Complications of Tracheotomy.—(*a*) The tube may give rise to ulceration of the trachea if it is not correctly shaped. Thus, if too much curved, it irritates the anterior wall, and may cause death by perforation of the left innominate vein. If insufficiently curved, the posterior wall may become ulcerated, and the œsophagus laid open. In cases where a tracheotomy tube has to be worn for long, it should be made of silver.

(*b*) Septic troubles may arise in the wound, leading to cellulitis and even secondary hæmorrhage; they are especially dangerous in the low operation, since they may extend to the mediastinal tissues. If the skin incision is long and has been left open, this complication should never arise. In cases of diphtheria the wound may also become affected with the disease.

(*c*) Inflammation of the trachea, bronchi, and lungs may result either from the entrance of cold or unmoistened air, or from the inspiration of septic or diphtheritic material.

(*d*) Difficulty is sometimes experienced in leaving off the tube, owing to the presence of granulations obstructing the lumen of the trachea, or to stenosis of the trachea or larynx, or even to paralysis of the abductor muscles, especially in diphtheritic cases. The usual cause is too high a tracheotomy, causing perichondritis, arthritis of the cricoarytenoid joints, and fixation of the vocal cords. The trachea may also be distorted, and its calibre thus diminished, by cicatricial union of the skin and mucous membrane. The diagnosis of the cause at work in any particular case can be made only by laryngoscopy, and careful examination of the wound and upper portion of the trachea. Granulations round the mouth of the cannula may be scraped away or destroyed by caustics; stenosis of the larynx must be dealt with as described above; stenosis of the trachea may require plastic reconstruction. It is important to diminish the risk of these difficulties by avoiding high tracheotomy; or, if this is not feasible during the time of urgency, by replacing a high-placed cannula by one lower in the trachea within a few hours.

(*e*) Finally, it should be remembered that if a patient is condemned to the perpetual use of a tracheotomy tube, he must be warned of the possibility of water getting into the trachea during bathing and of his being drowned thereby.

6. **Intubation of the Larynx** consists in the passage through the mouth of a suitably curved tube, carried on a specially contrived

introducer. The best patterns to employ for the purpose are those known as O'Dwyer's tubes. The lower end of the cannula is oval and not circular, and passes between the vocal cords into the trachea whilst the upper enlarged end lies in the laryngeal aperture; it requires changing frequently in order to prevent erosion of the mucous membrane. It has been used with considerable success in cases of œdema of the glottis and laryngeal stenosis, but is not to be recommended for diphtheria, owing to the risk of carrying the false membrane down with it. Tracheotomy is to be preferred in cases of laryngeal obstruction.

Foreign Bodies in the Air-Passages.—Any part of the respiratory tract may be partially or completely obstructed by the presence of a foreign body, the effect of which may be of greater or less gravity according to its situation, character, and size.

1. **In the Nasal Passages** (see p. 1018).

2. Obstruction occurring **at the entrance to the larynx** may be due to attempts to bolt large masses of food, which, becoming impacted may cause immediate death. A person, eating a meal voraciously turns black in the face and falls off his chair dead. A similar result has followed such a foolish act as attempting to swallow a billiard ball. If the obstruction is not complete, as when a large denture becomes impacted, dyspnœa is caused, the symptoms rapidly increasing owing to œdema of the submucous tissue of the glottis. Accidents of a similar nature may occur during anæsthesia, an epileptic fit, or drunkenness, substances such as a denture or a mass of vomited food blocking the entrance to the larynx. The **Treatment** must be prompt since there is no time to lose. The mouth should be forced open by the handle of a fork, or anything suitable that happens to be near and the finger swept round the pharynx so as to dislodge the foreign body. Care must be taken not to push the object still further into the laryngeal aperture. Failing removal, laryngotomy or tracheotomy must be performed, and artificial respiration, if necessary, instituted. In less urgent cases there is time to remove the substance from the mouth by direct laryngoscopy.

3. **In the Larynx.**—A foreign body enters the larynx by inhalation during a deep respiratory effort, when the glottis is widely open. Anything large is likely to be stopped above the larynx, while smaller objects usually pass into the trachea or bronchi. Small coins, buttons, nutshells, or pins may, however, be arrested in this region. Total obstruction may cause immediate death, or the object may enter one of the ventricles, and produce only partial obstruction, as evidenced by a sudden sense of suffocation, urgent dyspnœa, and a violent attack of coughing, attended, perhaps, by vomiting, such as occurs when anything is said to have 'gone down the wrong way.' After a preliminary bout of coughing little is felt, and symptoms may be almost completely absent. Laryngoscopic examination should reveal the situation of the intruding body. The **Treatment** consists in removal through the mouth with grasping forceps, passed through a direct laryngoscope, the head of the patient being lowered to prevent the foreign body falling into the trachea if dislodged when not firmly grasped.

4. **In the Trachea.**—To lodge in this situation a foreign body must be small enough to pass through the rima glottidis, and not too heavy, otherwise it will drop into one of the bronchi; it may become impacted, if it has jagged edges, but more often remains free.

The **Symptoms** are obstruction, irritation, and inflammation, dependent on the size and nature of the object. At the moment of arrival of the foreign body the patient will suffer from a severe attack of spasmodic dyspnœa and coughing of temporary duration. Later on similar attacks may be induced if the foreign body moves, particularly if it is light or of a vegetable nature; it can be coughed up against the lower aspect of the vocal cords, and death has even resulted from its impaction in the larynx in this way. The irritation of a vegetable type of foreign body in the trachea produces acute tracheo-bronchitis, with frothy expectoration and spasmodic cough. **Treatment** consists in the introduction of a bronchoscope, so that the foreign body may be seen, and by suitable forceps secured and removed. If such appliances are not available, a low tracheotomy must be performed if dyspnœa is severe, particularly if the object is of vegetable nature. As soon as practicable the patient is conveyed to some centre where the foreign body can be removed by bronchoscopy.

5. To become impacted in a **Bronchus** the foreign body must be sufficiently small to pass through the rima glottidis, and heavy and smooth enough to drop down the trachea; the most common *non-vegetable* articles are buttons, pebbles, slate pencils, pins, an O'Dwyer's tube, or beads, teeth, or part of the inner cannula of a tracheotomy tube. The right bronchus is more often obstructed, as it is more in a direct line with the trachea, and is the larger. Symptoms similar to those already described manifest themselves, *viz.* obstruction, irritation, and inflammation. The obstruction is twofold: immediate, as a result of the passage of the intruder through the glottis, a condition due more to spasm than to mechanical causes; and late, as a sequence of its lodgment in the bronchus. *Vegetable substances* like orange-pips and melon-seeds, or pieces of nut, may lodge in a main bronchus or one of the branches; in such a case irritative tracheo-bronchitis arises in addition to the signs of obstruction of part of the lung. The obstruction is at first partial, and more or less valvular in character, allowing entrance of air during inspiration, but preventing its exit. Obstructive emphysema of a lobe or a whole lung is thus produced. The swelling of the mucous membrane later makes it complete. Subsequent collapse of that portion of the lung supplied by the affected bronchus is induced, as indicated by dulness and the absence of breath-sounds. Vegetable substances produce such acute tracheo-bronchitis that they soon kill the patient if not removed; non-vegetable objects, on the other hand, may lie in the lung for months or years without producing symptoms, but lung abscess or bronchiectasis, with purulent sputum, will appear eventually. Sometimes the abscess may extend through the lung substance to the pleura, setting up a localized empyema. In other cases multiple bronchiectases appear, and the patient finally dies of exhaustion.

Treatment.—It has now been demonstrated conclusively that except

in cases where a foreign body lodges on the top of the larynx and causes immediate suffocation, it is possible to permit the patient to travel to some centre where expert help is available. After the first spasms of coughing the patient who has inhaled a foreign body of non-vegetable type is more or less comfortable, and no immediate ill-results arise; in the case of vegetable objects, however, œdema of the glottis may necessitate urgent tracheotomy. The foreign body is then carefully localized by examination of the lungs and X-rays, and it is wise (as advised by Chevalier Jackson) to practise removal of a replica of the foreign body through the bronchoscope before dealing with the case by removal under direct vision, or, on rare occasions, under fluoroscopic guidance. Cases of deeply lodged foreign bodies, with considerable disorganization of the lung, may call for lobectomy.

CHAPTER XXXIV.

SURGICAL AFFECTIONS OF THE LUNGS, PLEURAL CAVITIES AND MEDIASTINUM.

Pleural Effusion is the commonest surgical manifestation of a diseased pleura, and may be either serous, sero-fibrinous, or suppurative. A *chronic* serous effusion is nearly always due to tuberculous disease of the lung, or to mediastinal conditions causing pressure, such as aneurism or new growth; *acute* serious effusions almost always go on to a suppuration, giving rise to an empyema. Where there is a new growth of the lung involving the pleura, or where the pleuræ are studded with small secondary growths, an effusion occurs which is blood-stained, and from which cells from the growth can frequently be obtained.

Treatment.—When the effusion is tuberculous in origin and not producing marked pressure symptoms, it is probably best to leave it alone, but if the lung is completely collapsed and the mediastinum displaced to such a degree as to embarrass the heart's action, then aspiration, repeated if necessary with air replacement, should be undertaken.

In cases when the diagnosis of the type of effusion is doubtful, an exploratory aspiration should be undertaken over the point of maximum dulness, and where breath sounds are most completely absent. If a purulent fluid is found, only sufficient for diagnostic purposes should be withdrawn.

When purulent fluid is found, either free in the pleural cavity or encysted, the condition is known as **empyema.** Such a collection of pus may be due to underlying disease of the lung, the commonest causes being pneumonia, either of the lobar or broncho-pneumonic type; or it may be due to the spread of infection from the mediastinum, or through the diaphragm from abdominal suppuration, such as a subphrenic abscess. Infection is also said to occur through the blood-stream, but in all probability these cases have some small lesion of the lung from which the disease has extended. Infection may also be carried directly to the pleural cavity through an external wound. In phthisis a tuberculous empyema may be found. An empyema can occur at any age, but at the extremes of life the condition is much more serious, and especially in infancy.

A description of the physical signs and symptoms belongs to the physician rather than to the surgeon. It will suffice to mention here that in a total empyema the affected side of the chest does not move on respiration, whilst the intercostal spaces may bulge; on percussion the side is dull, except perhaps immediately below the clavicle, where tympanitic resonance (skodaic) may be elicited. On auscultation

breath sounds are absent, except in the vertebral groove, where bronchial breathing may be heard. The loss of vocal fremitus is also an important sign. A certain amount of fever and dyspnœa is usually present, the latter being dependent to a large extent on the rapidity with which the empyema has formed; leucocytosis is well marked, and the heart and other viscera may be displaced. Left to itself a large empyema may find its way to the surface, usually through the second interspace in front along the large perforating vessels (*empyema necessitatis*), and if situated on the left side may have transmitted to it pulsations from the heart and great vessels (*pulsating empyema*). In the case of a smaller empyema the pus may burrow through the lung, open into a bronchus and be coughed up, a natural cure resulting. When the pus is limited to certain areas, special names are given to the empyema,

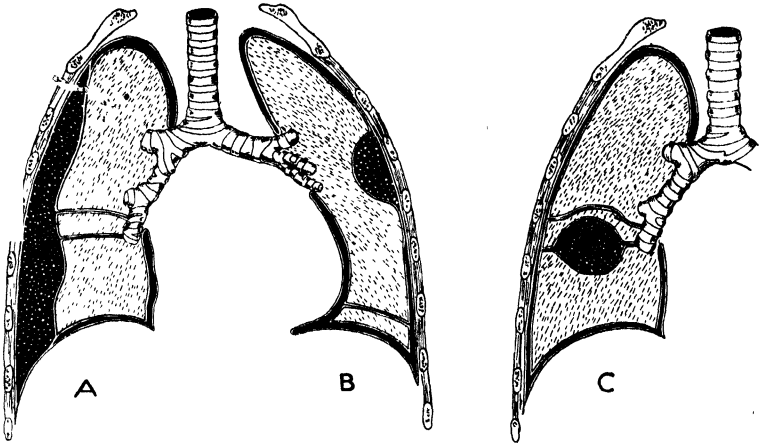

FIG. 703.

A, Large empyema. B, Small localized empyema C, Interlobar empyema.

such as apical when localized at the apex, and interlobar when occurring between two lobes (Fig. 703).

In the early stages of the disease the pleura is but little altered in structure, although a certain amount of lymph may be deposited on it; as the disease progresses, this layer of lymph is increased, and more especially so in the type due to the pneumococcus. Organization takes place in the deeper layers, and at the same time fibrosis occurs in the periphery of the affected portion of the lung, while occasionally an area of softening or an abscess cavity can be seen in the superficial lung substance. In old-standing chronic cases the pleura becomes dense and firm owing to the development of fibrocicatricial tissue, whilst the surface is converted into a layer of granulation tissue similar to that found in all chronic abscesses. As the fluid increases in the pleural cavity, the lung collapses before it; at first its alveolar texture remains unaltered, and with removal of the fluid re-expansion takes place. In chronic cases, however, this re-expansion

is hindered by the thickening and density of the visceral pleura, which resists the atmospheric pressure, and the fibrotic changes already mentioned which take place in the lung itself.

Under these circumstances, when the exudate is drained away the lung remains collapsed (*chronic empyema*), and nature then attempts in several ways to remedy the defect and obliterate the cavity. (*a*) Emphysematous changes take place in the other lung, and the mediastinum is displaced to the affected side. (*b*) The chest wall becomes flattened, and there is a compensatory scoliosis. (*c*) The diaphragm tends to be pushed up by the abdominal viscera, and (*d*) there is an exuberant growth of granulation tissue from the surface of the empyema cavity.

In a certain proportion of cases the cavity, although reduced in size, still remains, lined with a thickened pyogenic membrane, and discharging pus. Under these circumstances, evidences of chronic septic absorption manifest themselves, including clubbed fingers, hypertrophic osteo-arthropathy, secondary anæmia, etc., and extensive operative interference is then necessary to remedy the condition.

The **Diagnosis** of empyema is usually readily made by attention to the history and physical signs, confirmation of such an opinion being obtained by puncture with a sterilized exploring syringe under local anæsthesia. If pus is found, only sufficient for diagnostic purposes should be withdrawn. A medium-sized needle should always be employed for this purpose, and it is well to insert it along the top of a rib after drawing the skin up or down, so that on removal a valvular puncture results. The character of the pus will be a valuable guide to the treatment to be employed. If the pus is thin and runs readily, or if offensive in odour, the likelihood is that the infection is a mixed one, and the empyema under these circumstances is not limited by adhesions (*pyothorax*); if, on the other hand, difficulty is found in aspiration and the pus thick and flaky, the probability is that a pneumococcal infection is present and that it is localized. The previous clinical course of the case will also help in the diagnosis between a pneumococcal and streptococcal infection. A bacteriological examination should be made to confirm these facts.

Prognosis depends much on this point. Thus an empyema due to pneumococci usually runs a mild course, and is sometimes cured in the early stage by aspiration alone; one due to the ordinary pyogenic cocci is more acute, especially in the presence of a hæmolyzing streptococcus. The presence of tubercle bacilli renders the outlook more doubtful, whilst a mixed infection is always a serious complication.

Treatment.—If a *streptococcal* or *mixed* infection is found, aspiration of the pus should be undertaken at intervals, until such time as the pus thickens in character, when open drainage can be performed. It is found that this form of treatment of pyothorax gives greatly improved results, since it allows time for the formation of adhesions, fixation of the mediastinum, and the localization of the pus, whilst the patient is relieved of large quantities of toxin, and the embarrassment of the heart from pressure effects is remedied. During this period the patient is given a course of M. and B. 693. If a *pneumococcal* infection is present, aspiration alone is satisfactory if it can be carried out;

usually, however, it fails from the fact that the needle becomes rapidly blocked with lymph, and then the pleural cavity must be freely opened. Where a double empyema is present, an open operation should be performed on the worst side, and aspiration on the other, until such time as the patient's condition also allows open drainage to be effected on this side.

The operation of opening the pleural cavity is best done under local anæsthesia, or gas and oxygen. It is usually necessary to resect a portion of rib subperiosteally, though some surgeons prefer an intercostal drainage. The site chosen should correspond to the lowest level of the pus, or be so placed as to secure the best drainage; usually in a complete empyema the eighth rib is the most suitable for excision, and this should be done in the posterior axillary line. It should be remembered that an adequate opening is essential in order to allow the surgeon to view the cavity and clear out the large fibrinous masses that are so frequently present. In a certain number of early pneumococcal cases, after evacuating the pus and cleansing the cavity, the incision may be closed without drainage; should a rise of temperature from re-accumulation occur later, aspiration will probably suffice.

In a large number of pneumococcal and in all mixed infections *Drainage* must be undertaken, and this is best effected by introducing three short portions of tube side by side, which only just enter the cavity. Such adequate drainage will in the pneumococcal cases allow the removal of the tubes in four to five days, but in the mixed infection cases the time will be longer. Some surgeons maintain that the drainage of the pleural cavity should be by the 'closed' method. This is effected by a single flanged tube (Tudor Edwards) introduced into the cavity and led off to a bottle by the side of the bed; the end of the tube is below the level of an antiseptic solution, and some degree of negative pressure is thus produced, helping to re-expand the lung.

If operation is performed early and is adequate, re-expansion of the lung will always occur. It should be assisted by breathing exercises undertaken by the patient, such as blowing bubbles or water from one Wolfe's bottle to another, or forced expiration with the glottis closed, such as occurs while straining at stool. In a certain number of cases the lung will fail to expand, and while the soft parts heal an intrapleural cavity is left (*chronic empyema*) with a chronic discharging sinus. The causes are to be found in delayed treatment of the empyema, inadequate drainage, or sometimes too long a period of drainage, whilst occasionally tubes, safety-pins, and pieces of gauze are lost in the cavity during some period of the treatment. The presence of a small bronchial fistula may also keep a chronic infection, while in a certain proportion a sinus is present due to necrosis of the divided rib. In such cases an X-ray examination should be made after the cavity has been filled with lipiodol; its extent can then be determined, and the necessary procedure adopted.

If the cavity is small, the sinus should be opened up and the overlying ribs removed to a sufficient extent to allow complete exposure of the interior. Two drainage tubes are introduced, and round them are packed gauze soaked in some antiseptic. Dressings are renewed daily,

and the wound allowed to heal from the bottom by granulation. The cavity is thus obliterated by three factors: the local falling-in of the chest wall, its replacement by granulation and fibro-cicatricial tissue, and to a certain extent by expansion of the lung. In the case of large cavities, this procedure is not only too severe, but is inadequate. Where the cavity is very large and the lung shows no signs of expansion, a paravertebral thoracoplasty should be undertaken. This in the majority of cases is highly successful, and even when a cavity still persists, it is usually so reduced that a local operation such as is described above may be performed at a later date. Roberts has recently introduced an operation for the large empyema cavities where the ribs over the cavity are removed, and the thickened parietal pleura is divided posteriorly. The flap thus formed is hinged anteriorly, and is kept in close apposition with the visceral pleura by means of outside packing, thus obliterating the cavity. Where the X-ray picture shows a bronchial fistula this should *first be closed*, before any other operative procedure is attempted. The fistula in the lung is exposed by following the sinus and removing portions of the ribs in its neighbourhood; this allows mobilization of the affected area of lung. A collar of the thickened visceral pleura is then cut round the sinus and the edges sutured with catgut, a further row of sutures being inserted in order to bury the first row; drainage should be maintained by a tube through a separate stab wound and the original wound sutured. *Decortication* of the thickened visceral pleura has been advocated in these cases; this consists in exposing the cavity and stripping the thickened visceral pleura from the lung, a severe procedure associated with considerable shock to the patient, and oozing from the stripped surface with added danger of fresh sepsis from the injured lung. A less severe operation consists in making incisions in the thickened visceral pleura in a cross-hatch manner; this allows the lung to expand by stretching the cut pleura. These methods do not give such good results as the procedures already advocated.

Tumours of the Pleura are rare, apart from the multiple malignant nodules secondary to primary growths elsewhere. Endotheliomata occur, but are seldom correctly diagnosed. When arising from the parietal pleura, they compress the lung, but do not invade it, in the same manner as endothelioma of the dura mater pushes into the brain. If not too extensive, they can be removed together with the overlying ribs.

Hydatid Cysts of the pleura also occur, but call for no special mention.

Surgical Affections of the Lungs.

Non-penetrating Wounds of the Lungs result from violence applied to the chest, with or without fractures of the ribs, and consist either of laceration or contusion.

Contusion of the Lung often follows an injury which is not sufficiently serious to break the ribs. The symptoms produced are severe pain in the side, with slight shock and hæmoptysis. Some traumatic inflammation follows, both of the lung and of the pleura, as indicated by loss of resonance and possibly friction sounds. The **Treatment** consists

in keeping the patient quiet in a warm room, and regulating the bodily functions. Pain is often relieved by strapping the side of the chest.

Laceration of the Lung is usually due to fracture of the ribs by direct violence. The severity of the symptoms necessarily varies with the character and extent of the injury. In bad cases the patient suffers from marked shock, pain, and dyspnœa. Evidences of hæmorrhage soon follow, either in the form of hæmoptysis or hæmothorax. If the wound is small, the patient complains of an irritating cough, and brings up a good deal of blood-stained frothy mucus; but if the laceration is extensive, involving the larger vessels, a quantity of pure blood may be ejected, even leading to death from syncope, or from asphyxia, owing to the blood filling the larger bronchial tubes. **Hæmothorax** may also be well marked; it results in a gradually increasing area of dulness extending from below upwards, together with loss of breath sounds, and vocal fremitus, coming on soon after the injury without signs of inflammation. Left to natural processes, the blood will be gradually absorbed, but it is likely to cause many adhesions and much impairment of respiration. Infection may occur secondarily, either from the blood itself or from infected foci in the lung.

Owing to the laceration of the pulmonary vesicles, air may escape either into the pleural cavity, giving rise to the condition known as pneumothorax, or into the cellular tissue of the body, constituting surgical emphysema. **Pneumothorax** is always associated with more or less collapse of the lung, and, if complete or produced suddenly, is almost certain to lead to considerable interference with respiration, and possibly to severe dyspnœa or even orthopnœa. A slight degree of pneumothorax, or a complete one, if produced slowly, has but little functional result if the other lung is healthy and no strain is thrown upon it. The air which finds its way into the pleura in connection with a ruptured lung, having filtered through the pulmonary alveoli, is free from organisms, and hence does not cause suppuration or putrefaction of the blood-clot present, unless bronchitis or some other suppurative condition has existed previously. The physical signs of pneumothorax consist in a high-pitched tympanitic note on percussion, and on auscultation amphoric breathing and possibly metallic tinkling. As soon as the wound in the lung commences to heal, the amphoric sounds disappear, the effused air is absorbed, and the lung gradually expands, a process which may take four or five days. If blood is present in the thorax, a condition of *hæmo-pneumothorax* is produced, recognized by a splashing or succussion sound heard on shaking the patient. **Surgical Emphysema** indicates a wound of both pulmonary and parietal layers of the pleura, which are slightly separated by air, constituting a localized pneumothorax. At each inspiration a fresh amount of air enters this cavity, and is expelled into the areolar tissues through the parietal wound at each expiration, being forced perhaps to a considerable distance from the spot where it commences, or even spreading over the whole body. It is of no serious significance unless extensive, disappearing rapidly after the wound in the lung has commenced to heal, thus occluding the opened pulmonary alveoli. It is recognized by the parts becoming swollen and puffy and giving a sensation of fine crackling

crepitus when the hand is pressed over them. Occasionally emphysema may arise as an *interstitial* condition, when the parietal pleura has not been injured, the air escaping from the alveoli along the interalveolar connective tissue into the root of the lung, and then appearing first at the lower part of the neck.

Such are the ordinary phenomena observed in the early stages of a lacerated lung. The effects subsequently produced consist in a localized traumatic pleuro-pneumonia, associated with slight elevation of the temperature, possibly rusty sputum, and often severe dyspnœa. In the worst cases death may result from asphyxia.

Penetrating Wounds of the Chest, due to direct injury and often associated with fracture of the ribs, are followed by very similar effects. The story is modified, however, by the fact that the external wound in the chest wall allows of the exit of blood, arising either from an intercostal artery, the internal mammary, or from the wounded lung, and this, combined with shock, may prove fatal. The recognition of the source of the bleeding is not always easy, but it is probably of parietal origin: (*a*) if it is unaccompanied by hæmoptysis; (*b*) if it increases obviously at each systole; and (*c*) if it can be controlled by digital compression. The treatment of bleeding from the intercostal and internal mammary vessels has already been indicated.

Moreover, the open wound is often associated with the entrance of bacteria into the pleural cavity, as also of infected foreign bodies and portions of the clothing, and this may change the resulting pleuro-pneumonia from a simple to an infective inflammation. Empyema is consequently a frequent sequela, whilst the inflammation of the lung may terminate in suppuration or gangrene, though this is uncommon. Surgical emphysema is also induced by air being sucked into the cavity during inspiration, and failing to escape during expiration, owing to the lips of the wound falling together; it may ensue even when the lung itself has not been damaged. When a large wound is present, the lung flaps up and down in the opened pleural cavity, and this is undoubtedly an important element in the production of the great shock induced by these injuries. When the lower part of the chest is injured, there is always the likelihood that the pericardium, or even the heart itself, may be involved, especially in gunshot wounds; the diaphragm also is frequently torn or perforated, and the abdominal viscera may be implicated. A torn diaphragm admits of the hernial protrusion of the abdominal contents, and strangulation may follow.

Treatment.—When the injury is **non-penetrating,** the patient should be kept quiet in a warm room, and the side strapped. This compression of the chest wall must be generally omitted in patients where the irregular ends of fractured ribs, broken by direct violence, are driven inwards, for fear of increasing the mischief in the lung.

Persistent hæmoptysis should be treated by keeping the patient absolutely quiet in the horizontal position and applying cold to the side. Morphia is especially needed when great restlessness and irritability are present. Lactate of calcium may also be given by the rectum. Stimulants are necessarily contra-indicated for fear of increasing or restarting the hæmorrhage. The effect of such expectant

treatment will be to cause the blood in the pleural cavity to clot, and this acts as a tampon to the affected viscus. In bad cases, under such conditions, bleeding may only cease when the patient is in a condition of profound collapse; blood transfusion or intravenous saline solution may then suffice to tide over the period of danger and lead to a successful result.

The treatment of hæmothorax is governed by the recognition of the fact that the blood when effused in the pleural cavity does not, as a rule, clot *en bloc*, but that the fibrin is deposited as a layer over the parietal and visceral pleura, as a result of the churning movements of respiration. Organization of this fibrinous layer commences early, and the lung is soon bound down by it, so that even though the fluid is absorbed or removed at a later date, the lung does not fully re-expand and defective respiratory movements ensue. A small hæmothorax, *i.e.* one about a hand-breadth in depth, may usually be left to the natural powers of absorption; if it does not quickly decrease, however, aspiration may be employed. A large hæmothorax with fluid blood present should always be aspirated early, and if need be the aspiration must be repeated more than once and the removed fluid replaced by air. The exudate should be examined bacteriologically, and when pus is present, open operation, with a view to emptying the cavity completely, should be undertaken. The presence of a large hæmothorax with clotted blood which cannot be withdrawn through an aspirator is also an indication for opening the chest.

In the early cases the scope of a thoracotomy should not be limited merely to the introduction of a drainage-tube, but should consist in removing four inches of a rib suitably situated, so as to permit the introduction of a retractor or rib-spreader. A bleeding intercostal artery can then be secured, the whole of the clot cleared out, and injuries to the lung dealt with. The operation and its after-treatment are similar to those for a penetrating wound (*vide infra*).

Simple pneumothorax seldom requires surgical treatment, since the imprisoned air is quickly absorbed, and the lung re-expands; should this not occur, and if severe dyspnœa is present, it may be advisable to remove the air by aspiration. This may sometimes fail, or the air may re-collect, and then the chest wall must be opened so as to permit of its escape. It is impossible for the lung to re-expand against the pressure of air confined in the chest; when an opening is made, the air can be driven out by a vigorous expiratory movement, such as coughing, which also forces air from the healthy lung into the wounded one when the glottis is closed.

Temporary dyspnœa may be overcome by the inhalation of oxygen; but when of a more decided character, and not due to any condition which can be removed, it is essential to diminish the blood-pressure, and thus decrease the amount of blood carried to the uninjured lung, so as to enable it to cope with the work of blood-aeration. In urgent cases, where the patient is becoming cyanosed, and life is threatened by asphyxia, venesection must be adopted. The blood is withdrawn from the arm rapidly and freely, and as it flows the dyspnœa ceases. This may be repeated once or twice before the full effect is obtained and respiration becomes unembarrassed.

The treatment of **Penetrating Wounds of the Thorax** involving the lung is always a matter of considerable difficulty. When the wound is of large size, air is sucked in and out of the chest freely, and the lung collapses, immediately followed by mediastinal flapping, causing respiratory distress and shock. First-aid treatment consists in rapidly cleansing the wound and surrounding skin, and then in closing the chest, if possible, by sutures through the soft parts, or by effective packing. As soon as this is accomplished the respiratory distress diminishes, and the blood collecting in the pleural cavity exercises pressure and helps to check further loss. In gunshot wounds, radiographic examination is important to determine the presence or not of metallic fragments or of detached spicules of broken ribs; screening is often more effective than photography, owing to the rapid movements of the chest.

If further operation is required, local infiltration analgesia will often suffice, or gas and oxygen may be administered. The condition of shock, which is often extreme, should be treated by warmth and blood transfusion. The ragged margins of the wounds are carefully excised, and fragments of broken ribs removed. The thorax is freely opened, clots are turned out, foreign bodies removed (care being taken to explore between the diaphragm and chest wall posteriorly, where heavy bodies may gravitate), and the lung itself is drawn up and examined. Torn fragments may be removed, the base being ligatured or sutured; a superficial penetration may be made good by suturing with or without excision; a deep penetration is cleansed by strips of gauze; but in all cases it is essential that the lung should be completely closed if practicable. The lung is so vascular that as a rule it can take care of itself as regards infection. Surrounding parts, *e.g.* the pericardium and diaphragm, are then gently explored, and wounds are suitably treated. Finally, the chest wall is completely closed, a muscular flap being turned in to make good irreparable gaps in the pleura. No drainage is provided. The air in the pleural cavity is removed by aspiration, and a recurrent effusion is similarly treated. If infection occurs, drainage can always be established at a later date.

Of course, it may not always be possible for a surgeon single-handed to undertake such extensive proceedings, but at least an effort must be made to excise the wound margins and to remove fragments of broken rib and damaged muscle. The opening in the chest wall ought to be closed effectively in all cases, and hæmothorax or infection is treated at a later date by aspiration or open drainage.

Hernia of the Lung, or pneumocele, is a rare condition in which a portion of the lung protrudes through an opening in the thoracic parietes beneath the uninjured skin. It may occur suddenly, as the immediate consequence of a laceration of the intercostal muscles and pleura, or more gradually, being then due to the yielding of a cicatrix. It is most usually seen about the fifth intercostal space, but has been known to develop in the root of the neck from a lesion in the dome of the pleura. It appears as a rounded swelling, increasing in size on coughing or making expiratory efforts, and possibly disappearing entirely on holding the breath. It imparts a crepitant feeling to the

fingers when compressed, and on auscultation a loud vesicular murmur is heard. As a rule, no treatment is necessary beyond the application of a pad or truss; but if it causes much trouble, the part should be exposed by a suitable incision, the lung freed from its adhesions and replaced in the chest cavity, and the defect in the wall made good by implanting a flap of fascia lata covered by a pedunculated flap of muscle from the neighbourhood.

A similar condition, arising as a complication of an open wound, is termed a **prolapse** of the lung. An attempt should always be made to return the protruded viscus, and to prevent its recurrence by suturing the aperture through which it has escaped. If left unreduced, it is very likely to become gangrenous from strangulation, and should then be removed by the application of a ligature, the wound being subsequently closed.

Abscess of the Lung is a commoner condition than is usually recognized. It may arise from the aspiration of foreign material, such as septic blood-clots after the removal of tonsils or teeth, from erosion round a foreign body impacted in a bronchus, and from an unresolved patch of pneumonia either of the broncho-pneumonic or of the lobar type. It may occur from a septic infarct, and in cases of septicæmia and pyæmia these may be multiple. It is usually unrecognized in the early stages, the patient often being treated for a purulent bronchitis. As the condition advances, the sputum becomes more copious and frequently offensive; the amount coughed up in twenty-four hours cannot be taken as an indication of the size of the lesion. With the increased sputum, the patient begins to waste rapidly, and develops a secondary anæmia and sweats. The pulse is rapid and the temperature swinging. An examination of the lung usually reveals an area of dulness, with diminished or absent breath sounds, and there may be signs of cavitation. In the more chronic cases, clubbing of the fingers is seen. An examination of the sputum may show lung tissue or elastic tissue; this indicates that the abscess is communicating with a bronchus, and that partial drainage is taking place. The X-ray picture varies considerably; it may show a dense shadow with an irregular diffuse edge situated in the substance of the lung, usually towards the periphery; or the shadow may be less dense with a fluid level in the centre. This latter picture is quite characteristic, and indicates that the abscess communicates with a bronchus, and an attempt at evacuation is taking place. The introduction of lipiodol is not usually helpful, as the cavity is either closed or the opening is set obliquely and does not allow the oil to run into it. Various views should be taken to localize, as far as possible, the position of the abscess, and the exact site where it approaches nearest to the chest wall (Plate XVI., Fig. 1).

The **Treatment** of pulmonary abscess depends on its size and age, the former being gauged by the radiographic appearances and the latter by the history. There can be little doubt that a large number of cases are cured without surgical intervention, and particularly so when small post-operative abscesses arise, as septic infarcts or from aspiration. Such an abscess usually shows itself about fourteen days after

operation in the manner above described, and is diagnosed by a radiogram, and frequently shows a fluid level. The patients should be kept in a sitting posture, whatever the position of the abscess, as this allows them to cough up the pus more efficiently and with greater ease. The value of bronchoscopy in this condition is referred to at p. 1057. In the more chronic cases, other steps will have to be taken. Aspiration of the abscess through the chest wall, either for diagnosis or treatment, is to be condemned owing to the risk of setting up an empyema. The production of a pneumothorax in order to collapse the lung around the abscess has been advocated, but in our opinion is only suitable for very early cases without much surrounding consolidation, as there is a risk of collapsing the healthy lung round the diseased area, and preventing what drainage may be available through the bronchial tubes. The best method is drainage by an open operation. The incision should be placed over the area where the abscess, as seen by X-rays, approaches nearest to the chest wall. A large portion of rib is excised and the pleura opened; if adhesions are present between the visceral and parietal pleuræ, these should be reinforced with a few stitches. An exploring needle is passed into the lung until pus is found. The lung is then incised, either with a knife or by diathermy passed along the needle, and the pus evacuated; necrosed lung and lymph should be removed gently with the finger, and the opening into the cavity enlarged to allow of adequate drainage. At the same time an estimate should be formed of the wall of the abscess; this may be either soft and collapsible, or, in old chronic cases, very hard and epithelialized; this latter type will usually require a further collapsing operation at a later date, and may even require lobectomy. A tube is introduced into the cavity and packed round with gauze. If on opening the pleura no adhesions are found, palpation of the lung should be undertaken to estimate the size and position of the abscess; this is readily determined by the presence of an indurated mass in the substance of the lung. In such a case the lung should be brought up to the parietal pleura and stitched to it, or if this is not feasible, the wound should be packed with gauze in order to promote adhesions, and the abscess opened four to five days later. It has been observed that in cases where there is a free pleural space packing to produce adhesions has sufficiently collapsed the abscess to bring about a cure of the condition without external drainage. This method of packing has been advocated to be used extra-pleurally to produce collapse, but its value is doubtful. The drainage-tube should be left in position until the discharge is no longer offensive and then gradually withdrawn. If the abscess cavity does not close, some form of local collapsing operation will be subsequently required.

The causation of **Gangrene** of the lung is similar to that of lung abscess. The infection, however, is usually more virulent, and the patient's resistance less. This results in a larger area of the lung being involved with no well-marked limitation of the disease. The portion of lung affected is airless, and on handling has the appearance of a large slough; no adhesions are found between this mass and the parietal pleura—in fact, the pleura may also become gangrenous.

The progress of the disease varies considerably, some cases dying within a few days, others lasting for some months. The *Treatment* is surgical; a wide exposure of the diseased area is made, and the sloughs separated, if necessary by ligature, and the wound lightly packed with gauze soaked in some form of antiseptic. The prognosis is bad, as these patients are exhausted by coughing and the severity of the septic process.

Bronchiectasis is a condition characterized by dilatations of the bronchial tubes, either single or multiple. The cavities are usually situated in the lower lobe, and are frequently bilateral; the left lower lobe is the commonest site, if the disease is unilateral. It may be caused by the presence of a foreign body which partially blocks a bronchus and prevents the distal tubes from being properly emptied; secondary infection causes softening of the tubes with consequent dilation, or a localized softening may take place round the foreign body, giving rise to a single bronchiectatic abscess. Fibrosis following a pneumonia or other lung and pleural infections may distort the affected bronchi, and produce dilatations which are increased in size by the weakening of the walls due to retained secretion, and the condition can frequently be traced consequent to the exanthemata and pertussis. It is also said to occur following a collapse or atelectasis of a portion of the lung, thus accounting for the frequency with which it is found in the left lower lobe. In the same way a congenital cystic lung may account for those cases where the dilatations are found in all lobes of one lung, the other lung being unaffected. As the disease advances, there is marked fibrosis of the lung round the affected areas, with distortion of the mediastinum.

Symptoms and Signs.—These are by no means typical. The patient may only complain of recurrent attacks of 'bronchitis,' or fevers and chills from time to time, with occasional sweating. The cough may be persistent and hacking, and of such an intractable character as to be unrelieved by heroin and other remedies. The sputum varies in amount and in its character; in its mildest form it may be slight in amount and of frothy type, while in advanced cases it may amount to over a pint a day of the very foulest expectoration. In milder cases the patient expectorates a large quantity of sputum in the morning, and for the rest of the day is relatively free from cough. Owing to the inflamed condition of the affected tubes hæmoptysis from granulation tissue is common.

The signs of bronchiectasis are varied; the presence of basal collapse and cavitation with alteration in the breath sounds are suspicious in cases with a clear history, especially if these signs alter with postural treatment; the certainty of the diagnosis is usually completed by the presence of clubbing of the fingers and other signs of hypertrophic pulmonary osteo-arthropathy. The diagnosis is confirmed by the introduction of lipiodol into the bronchial tree, either by injection through the crico-thyroid membrane, or by nasal catheter; the degree of dilatation and its extent can thus be estimated.

The **Treatment** of the condition is in the first place medical; but

scopy should always be undertaken, as it may permit the removal of a foreign body, or by treatment of granulation tissue allow improved drainage and so prevent the extension of the disease.

In cases where the disease is unilateral and confined to one lobe, obectomy should be considered (Fig. 704). This is most successful

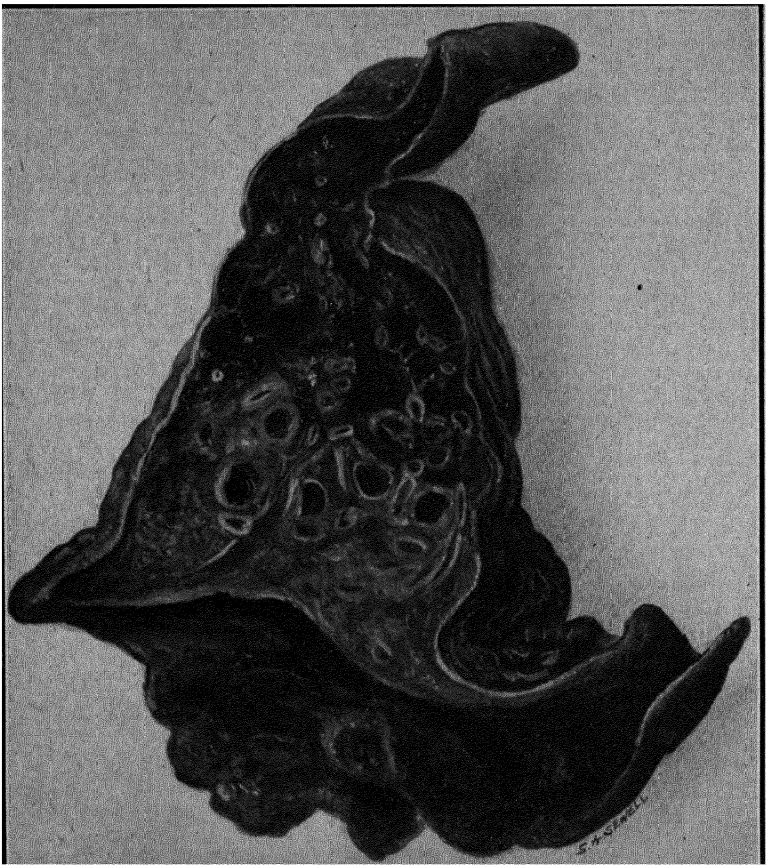

FIG. 704.—BRONCHIECTASIS (LOBECTOMY SPECIMEN).

in children and young adults, and should not be performed in elderly patients. In this country the operation performed is one-stage lobectomy; this is most successful, and has a mortality of less than 20 per cent., a figure which is high but will improve with increasing familiarity with the post-operative complications. Other surgical procedures are lobectomy in two stages, the first stage being an attempt to cause adhesions between the upper lobe and the parietal pleura, so that the

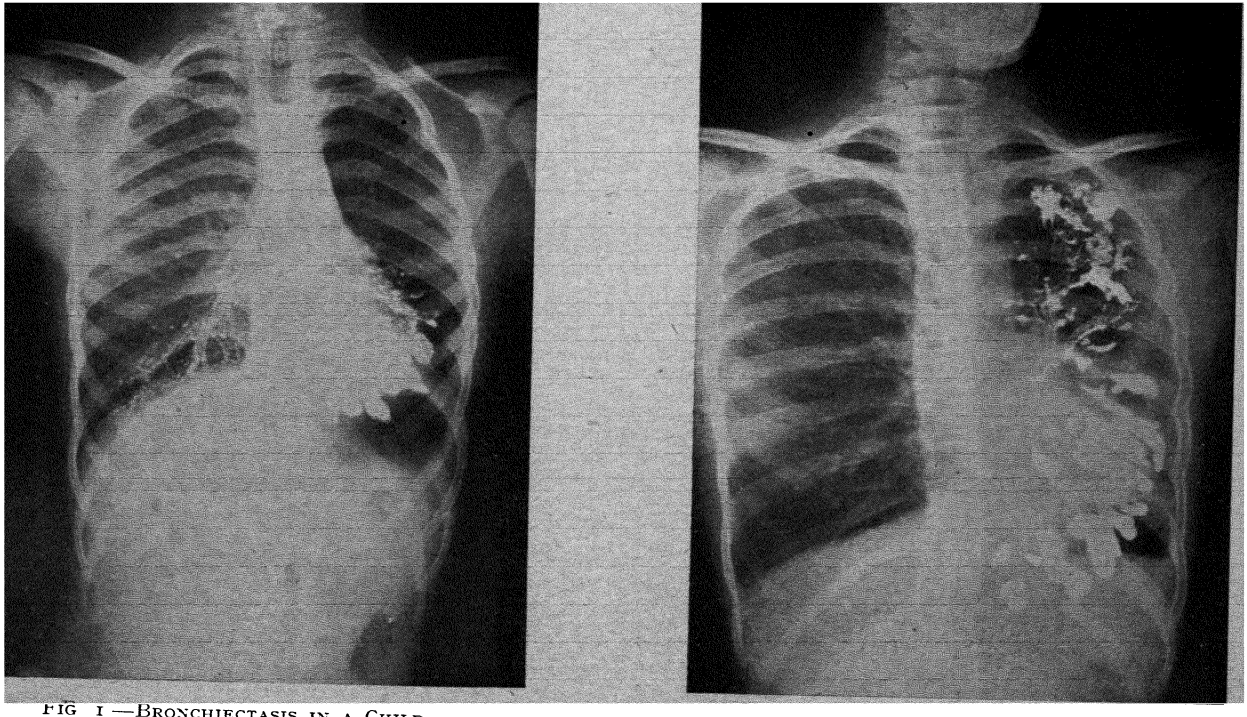

FIG 1 —BRONCHIECTASIS IN A CHILD

The dilated cavities can be seen filled with lipiodol, while the normal bronchial tree can be seen on the right side Some lipiodol can be seen in the stomach, and the gas bubble in

FIG 2 —BRONCHIECTASIS IN A YOUNG ADULT.

This is the unilateral type The dilated tubes are seen filled with lipiodol, and extend throughout the left lung The

diseased lobe is removed from a closed pleura, in contradistinction to an open pleural space as in the one-stage lobectomy. The disadvantage of this method is that the lobes, or lobe, left behind cannot so freely expand to fill that side of the chest owing to their preformed adhesions.

A third method of dealing with the diseased lobe is by cautery pneumectomy, in which the lobe is removed piecemeal by several cautery excisions, an operation that has little to recommend it.

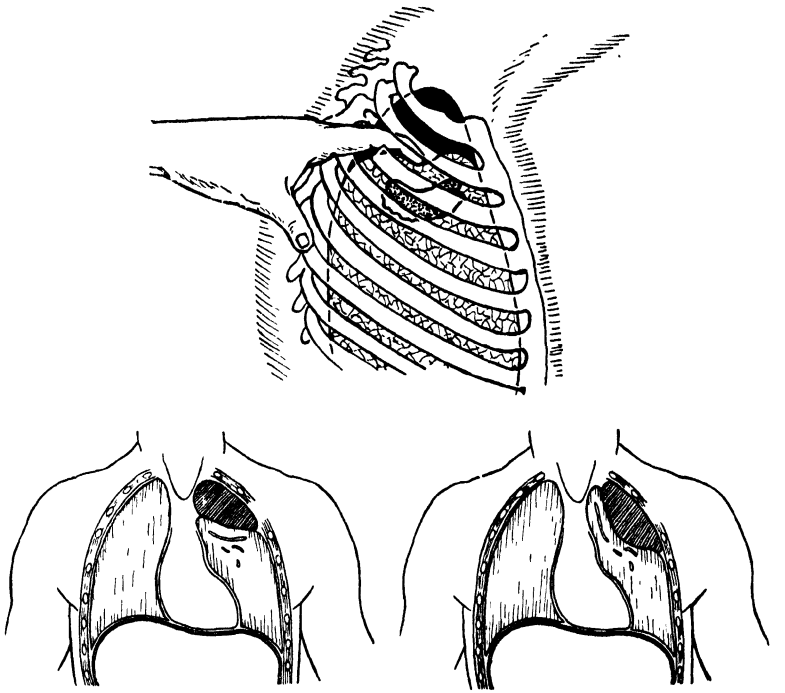

FIG. 705.—DIAGRAMMATIC ILLUSTRATION OF EXTRAPLEURAL PNEUMOTHORAX AND WAX PLOMBAGE.

The small portion of the third rib posteriorly that has been removed is obscured by the finger. The relaxation of the lung produced is shown in the second and third diagrams.

Massive plombage in those cases which are not fit for lobectomy has been done, and seems to hold out a reasonable hope for such cases (Fig. 705).

Lobectomy.—In the one-stage operation great care should be taken in the preliminary treatment. The patient should be given postural treatment in a Nelson bed for a period which varies with the amount of sputum, and at the same time a vaccine should be given. Particular care should be given to the diet, and the patient should be

encouraged to take a full diet rich in proteins, as their protein loss in the sputum they produce is very considerable.

Several days before operation an artificial pneumothorax should be produced. The quantity of air introduced need not be large, and it is a disadvantage to keep it up too long, as this is liable to delay re-expansion of the lobe, or lobes, left behind. Owing to the complications of atelectasis of the remaining lobe, or lobes, some surgeons advocate the fixing of the healthy lobe. This is done by the introduction of iodized talc into the pleural cavity. This causes the formation of adhesions sufficient to prevent collapse of the healthy lobe when the thorax is opened.

At the operation the patient is placed on the non-affected side, and a pillow or sandbag placed under the ribs in order to open up the intercostal spaces. The anæsthetic should be avertin and gas and oxygen, or cyclopropane, and an increasing number of cases are being done under spinal. An incision is made in the seventh interspace from the nipple line in front to the erector spinæ behind. The incision is deepened to the intercostal muscles and then through these to the pleura, which is opened. This opening is carried throughout the length of the wound, keeping close to the upper border of the rib. A small portion of rib behind the angle is then removed and the intercostal bundle divided and ligatured. The rib spreaders are introduced and opened. The affected lobe is seized with lung-holding forceps and all adhesions divided with scissors. The pulmonary ligament is also secured and divided up to the hilum. A tourniquet is then placed round the separated lobe as close to the mediastinum as possible (Fig. 706). The pleural space is packed off with flavine gauze and the lobe removed. The stump is then sutured with mattress catgut sutures and the bronchi touched with carbolic or flavine (Fig. 707), the tourniquet is released and the stump allowed to fall back. When complete hæmostasis has been secured, the spreaders are removed and the ribs approximated with sutures with the help of a rib approximator. The wound is then sutured. A large trocar and cannula are introduced into the eighth interspace and a suitable self-retaining catheter left *in situ*; the large pneumothorax is decreased in size, either through this catheter or with a syringe and needle. The complications of the operation are those of sepsis and atelectasis of the remaining lobes. The catheter which is left in the space is connected with a closed drainage system which helps to expand the remaining lobe and also drain the cavity. This in the majority of cases is sufficient, but in some cases a rib resection has to be performed about the tenth day to drain an empyema. Pericarditis and cerebral abscess may lead to a fatal termination.

In certain cases where bronchiectasis is unilateral, but more than one lobe is affected, total pneumectomy may be advised. This is naturally a very much more serious procedure, but is justified when the ultimate conclusion of the disease is taken into consideration.

Lipiodol injections, as has been already stated, help very considerably in the diagnosis of surgical affections of the lungs. One method is by the crico-thyroid route: the patient lies on the back with the head

extended, a small area of skin over the crico-thyroid membrane is injected with novocain after purification. The needle of a syringe is then inserted into the trachea, and about 5 to 10 minims of 10 per cent. cocaine injected, the patient is instructed to cough, which sprays the trachea and under-surface of the glottis, and produces sufficient anæsthesia for the injection of the oil. A small trocar and cannula or a wide-bored needle is then inserted through the crico-thyroid mem-

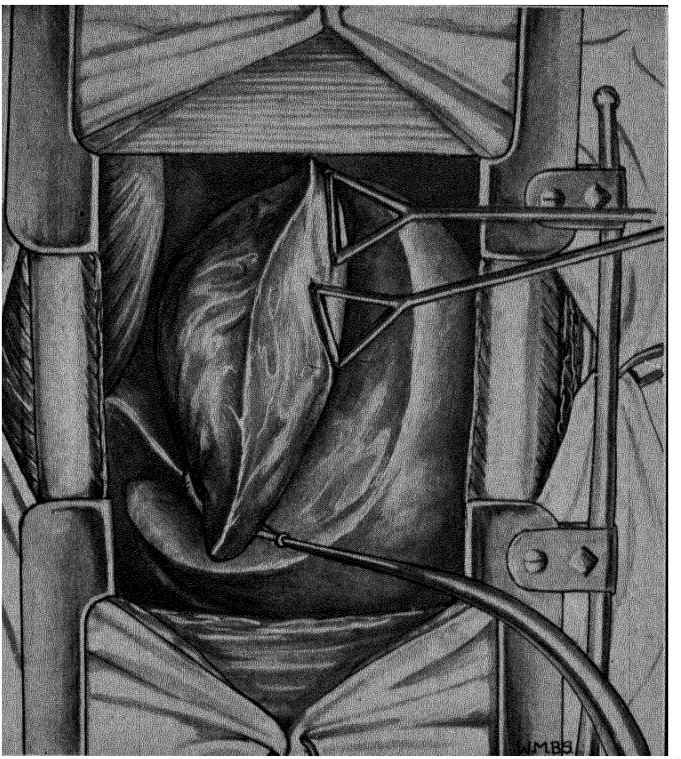

FIG. 706.—LOBECTOMY. THE LOWER LOBE WITH THE TOURNIQUET IN PLACE.

brane, and about 20 c.c. of warmed lipiodol slowly injected, the patient being turned to the affected side while the oil is running in. If a picture of the upper lobe is desired, the operating table is fixed in a moderate Trendelenburg position for a few minutes after the oil has been injected; this allows the oil to run into the upper bronchial tree on the affected side. Another is by the introduction of a catheter through the nose after cocainization, the catheter, striking the posterior pharyngeal wall, is automatically directed forward and passes through the glottis.

Pulmonary Tuberculosis in its chronic form is a disease that can be dealt with by surgical measures. Like tuberculosis elsewhere in the body, rest to the diseased tissues is the chief means of curing the disease, and in the lung this is best attained by collapsing the affected organ. This can only be employed, however, in the absence of disease in the other lung, or with the other lung only slightly involved. The ideal method of collapse is by means of an artificial pneumothorax, which is

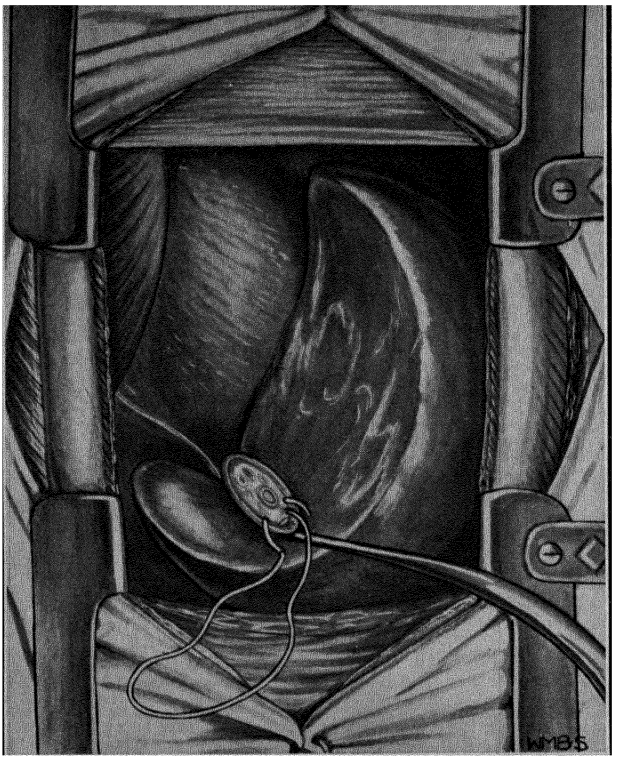

FIG. 707.—LOBECTOMY. THE LOBE REMOVED, SHOWING SUTURES BEING PLACED IN THE STUMP

produced and maintained by the introduction of air into the pleural cavity, and in some cases of oil (oleothorax), the details of the technique are to be found in the special literature of the subject. Complete collapse of a lung may fail owing to the presence of adhesions between the visceral and parietal pleuræ; these adhesions may be local or general. If local, they can be divided intrapleurally; this is undertaken by means of a thoracoscope, an instrument like a cystoscope, which is introduced through a cannula into the pneumo-

thorax cavity under local anæsthesia, and the adhesions examined and divided by a cautery through a separate cannula, or attached to the main instrument. The division of these adhesions should not be done by diathermy, as there is considerable risk of later sloughing extending into the pulmonary end of the adhesions with subsequent infection of the free pleural space; for the same reason the adhesions should be divided as close as possible to the parietal pleura to avoid injury to pulmonary tissues (Fig. 708). After the division of the adhesions, the artificial pneumothorax is completed at a later date. If the adhesions are general or cannot be divided, other steps to collapse the lung have to be undertaken.

Local collapsing operations are beneficial in a certain number of cases. This chiefly applies to **phrenic avulsion,** which paralyzes the diaphragm, and allows collapse to take place at the base of the lung as the diaphragm rises in the chest, and also permits shrinking of the lung from the fibrosis which is part of the disease. The phrenic nerve is exposed in the neck under local anæsthesia. A small transverse incision is made in the skin and platysma muscle over the lower end of the sterno-mastoid. The external fibres of the muscle are split, the posterior sheath incised, and by blunt dissection the scalenus anticus muscle exposed. The phrenic nerve is identified running in the sheath in a longitudinal direction; it is anæsthetized with novocain, separated and divided; a small length of the nerve is pulled up and about three inches removed. In certain cases a temporary phrenic paralysis is desirable, and in such cases, after exposing the nerve, it is crushed with Spencer-Wells forceps; when this is done a search must be made at the outer border of the scalenus muscle for an accessory phrenic, and if one is present it should be divided.

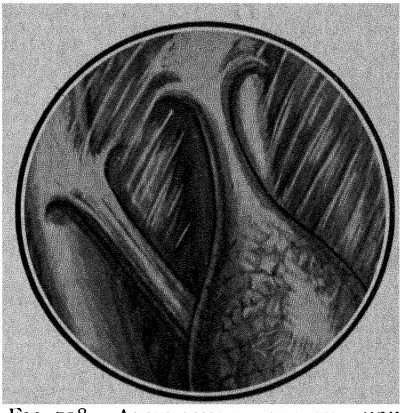

FIG 708.—ADHESIONS AS SEEN THROUGH A THORACOSCOPE

The ribs and intercostal muscles shining through the parietal pleura can be identified, with two adhesions, one fibrous and one fleshy.

Paralysis of the diaphragm as a routine procedure should not be performed. It is of considerable value in cases of hæmoptysis, severe unilateral fibroid phthisis, and in certain cases of infiltration without cavitation; it should not be undertaken as a single procedure in apical cavitation.

Where cavitation is present every endeavour must be made to allow the cavities to close. Although this closure may occasionally occur spontaneously, it is so rare that surgical intervention is nearly always required. The procedures adopted are either the removal of portions of the ribs, or the relaxation of the lung by stripping the parietal pleura

from the chest wall, and preventing re-expansion by the introduction of muscle, fat, or paraffin wax (plombage) (Fig. 705). This procedure is not free from complications. The wax may be extruded, it may ulcerate through into the cavity and be coughed up, or it may travel down and lie above the diaphragm. It is therefore better to use this method in cases in which rib collapsing operations have not completely closed the cavity, or where the patient's age contra-indicates partial thoracoplasty.

An improvement on plombage with its attendant risks is the performance of extrapleural pneumothorax. This can be done either as a single procedure or in combination with an artificial pneumothorax. In cases where a pneumothorax has produced a non-selective collapse the cavity is held out by adhesions usually to the apex, and this can be freed by extrapleural stripping. A portion of the third rib is removed posteriorly and the parietal pleura carefully stripped from the chest wall by finger and small gauze swabs. The whole apex is thus freed by direct vision, with special attention to hæmostasis, as far down as the hilum on the mediastinal surface and a corresponding distance all round. Where it is desired to combine it with an artificial pneumothorax the pleura is then widely opened the whole way round the thorax. After-treatment consists in keeping up the pneumothorax and if necessary aspirating fluid from the base. The combined method has the great advantage of allowing the refills to be performed in the usual manner without the attendant difficulties and dangers that may occur with an extrapleural pneumothorax alone.

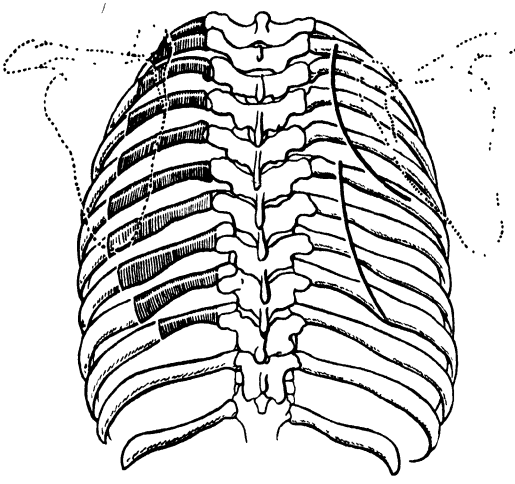

FIG 709.—DIAGRAM TO ILLUSTRATE THE INCISIONS IN TWO-STAGE THORACOPLASTY.

The shaded portions of the ribs represent parts removed.

Where cavitation is present there is little doubt that some form of rib resection should be undertaken. This consists of the removal of portions of the ribs posteriorly, **paravertebral thoracoplasty.** The operation in its fullest extent consists in the removal of portions of the first and the tenth ribs posteriorly from the tips of the transverse processes laterally, an amount varying from 2 to 7 inches being removed, and the whole operation being extra-pleural (Fig. 709).

Variations of this extensive operation are used depending on the

individual requirements, in some cases removal of portions of the upper three ribs is sufficient, in others eight, and in some a complete procedure (Fig. 710). It may be said that where a partial thoracoplasty is done, the amount of rib removal is larger than in the complete operation. Some surgeons advocate the removal of the transverse processes as well, and others, when a local apical thoracoplasty is performed, also strip the apical parietal pleura to produce increased collapse by mobilizing the apex and mediastinal pleura.

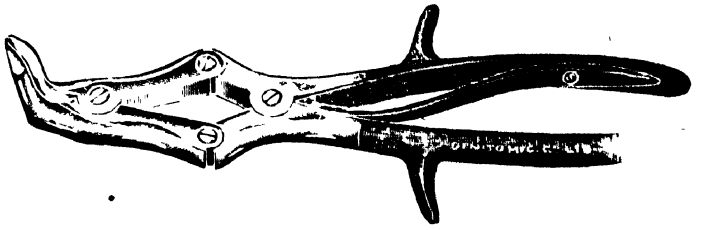

FIG. 710.—PRICE THOMAS'S RIB SHEARS.

These operations are performed usually in stages depending on the patient's condition and the degree of collapse required. Post-operative complications are relatively few, and the degree of shock is not so severe as might be expected with such an extensive operation.

The collapse obtained is very striking, especially at the apex, and is increased by weights being applied during convalescence, the degree of deformity is scarcely noticeable with the patient clothed, as the shoulder is maintained by the clavicle (Fig. 711).

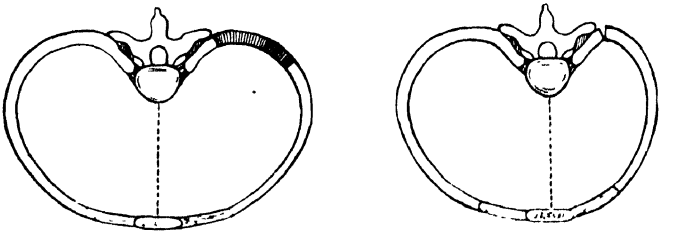

FIG. 711.—DIAGRAMS TO ILLUSTRATE THE COLLAPSE THAT OCCUR AFTER THORACOPLASTY.

New Growths of the Lung are either primary or secondary. The former are carcinomas, and most commonly arise from the hilum and spread into the lung, they may, however, rise at the periphery. This latter type can occasionally be dealt with surgically, the affected lobe being removed. In certain cases it may be possible to do a pneumectomy with individual ligature of the vessels and bronchus, and subsequent X-ray treatment of the posterior mediastinum. These tumours are squamous-celled and frequently of a basal-celled type,

arising in the pulmonary alveoli, of epithelium of the smaller bronchi (Plate XVII., Fig. 2).

Secondary carcinomas are multiple, and, of course, do not lend themselves to surgical interference.

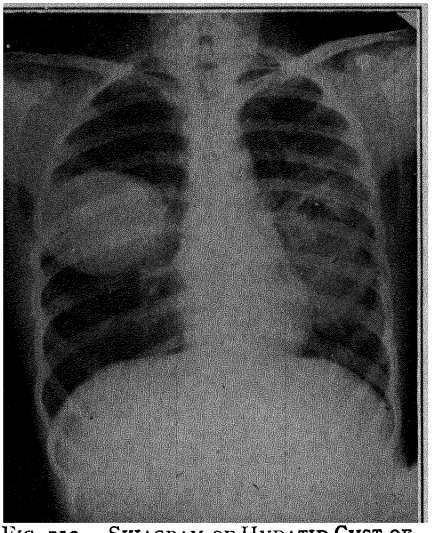

FIG 712.—SKIAGRAM OF HYDATID CYST OF THE LUNG (DR COPPLESTON'S CASE)

Hydatid Cysts of the lung are occasionally seen in this country, but are common in Australia. They may attain a large size and may be full of daughter cysts, or contain only fluid. They may rupture into a bronchus with a natural cure, or they may suppurate, being then indistinguishable from an abscess. The symptoms are a slight cough, night sweats, and hæmoptysis; if close to the surface, there may be local pain and friction. An area of dulness is present on examination, with diminished breath sound. The diagnosis is made by radiography, the cyst showing with a clear outline, unlike an abscess (Figs. 712 and 713). When not suppurating, the endocyst is readily removed after thoracotomy, the cavity being drained for a few days.

Bronchoscopy in Lung Diseases.

Not only is the bronchoscope used for the removal of foreign bodies from the air-passages, but use is made of it also for the diagnosis and treatment of various neoplastic and inflammatory diseases.

Non-malignant New Growths in numerous instances have been removed through a bronchoscope. In our own experience, a patient with recurrent hæmoptysis, lasting for several months and suspected as being of tuberculous origin, was found, after the injection of lipiodol, to have a filling defect at the commencement of the left lower lobe bronchus. Bronchoscopic examination showed the presence of a smooth neoplasm

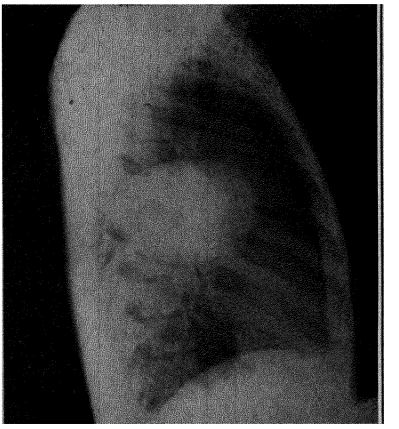

FIG 713.—LATERAL X-RAY OF SAME CASE AS FIG. 712

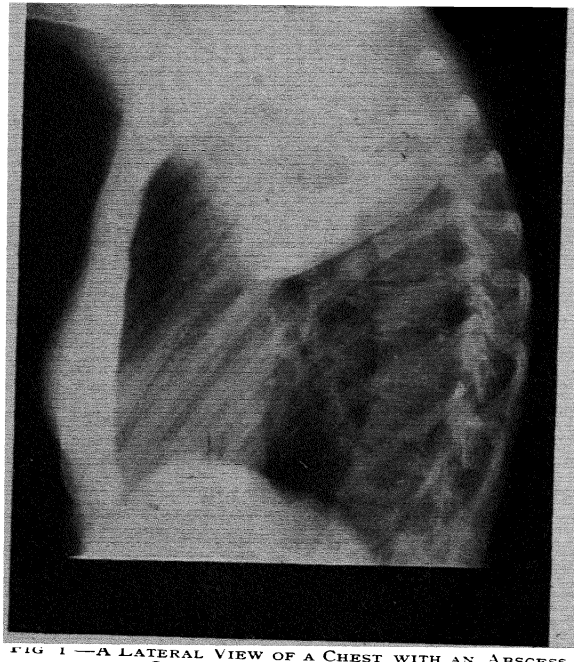

FIG 1 —A LATERAL VIEW OF A CHEST WITH AN ABSCESS CAVITY IN THE UPPER LOBE

The diffuse shadow of the abscess is shown, a well-marked fluid level can be seen in the centre, with an air space above indicating that the abscess communicates with a bronchus, and that partial drainage is taking place

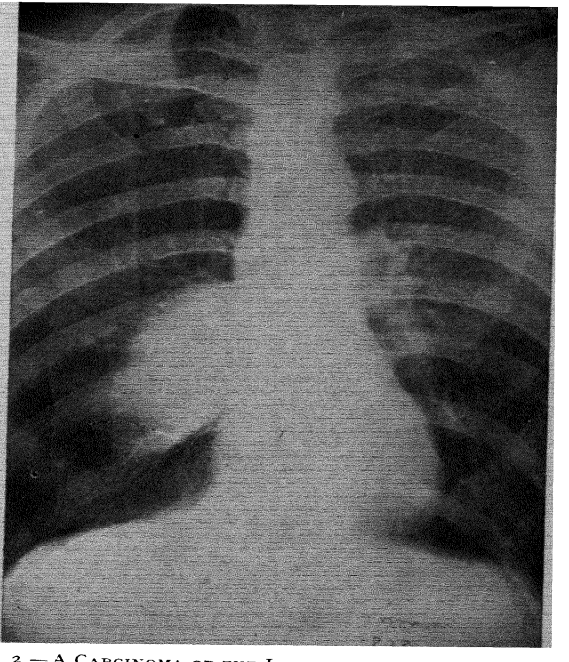

FIG 2 — A CARCINOMA OF THE LUNG IS SEEN ON THE RIGHT SIDE

The shadow is dense, diffuse at the edges, and continuous with the hilum A partial pneumothorax has been produced for diagnostic purposes, and the edge of the lung can be seen some distance from the chest wall The tumour, which is situated in the lower part of the upper lobe, has fallen to a lower level on collapse of the lung

from which a piece was taken for microscopic examination; the section showed a fibroma, which was nibbled away on a subsequent occasion, with apparent cure.

Malignant New Growths.—As the majority of the carcinomata in the lung either commence in a bronchus or invade the lumen at an early date, examination with a bronchoscope will in all probability establish a diagnosis. The friable and free bleeding growth can be seen and a piece taken for microscopic examination; clearance of the lumen of the affected bronchus will allow air to enter the lung and relieve the patient to some extent of the distress associated with suppuration in the obstructed area. An intubation tube containing radon seeds, as designed by Tudor Edwards, may be inserted into the affected bronchus and left in position for seven days, sometimes with a good result.

In one case dealt with, a small pedunculated alveolar carcinoma was removed complete from the right main bronchus, with disappearance of symptoms for several years, and with free air entry into a previously airless lung.

Lung Abscesses, if treated within a few weeks of inception, respond well to bronchoscopic treatment. The abscess results in the majority of cases from inspiration of infected clot during or soon after operations in the mouth or pharynx, particularly after extraction of teeth or removal of tonsils. Infective material carried down causes partial or complete blockage of a bronchus with suppuration in the lumen of the tube. Removal of the plug cures the condition in most cases; it is attained by aspiration with a Chevalier Jackson's bronchoscope fitted with a suction tube, and by swabbing the inflamed walls of the bronchus and any granulation tissue with 10 per cent. silver nitrate.

In many cases an abscess forms outside the bronchial wall in the parenchyma of the lung, owing to spread of infection through the bronchial epithelium, or as a result of blood-borne infection. If this abscess bursts into the bronchus—as usually occurs—aspiration will afford a good chance of recovery, as not only is the pus removed, but free drainage is established by dilatation of the inflamed and partially obstructed bronchus, together with reduction of swelling by local applications of silver nitrate.

Bronchiectatic Abscess.—If an abscess in the parenchyma of the lung drains for a considerable time into a bronchus, or if a local inflammatory condition commences in the bronchus itself, either because of the presence of a clot or of a foreign body of a solid nature, the bronchial walls become inflamed and weakened, and are finally distended. A cavity of large size may be produced, and it is then difficult to say how much is made up of the original lung abscess and how much is true dilatation of the bronchus. Whatever be the formation of the walls, bronchoscopic treatment should be tried, and may give good results; if a foreign body is found and removed, the condition will in all probability be cured. In one case the removal of a complete vertebra of a rabbit, which had been in the right lower lobe bronchus for sixteen months, and had produced a bronchiectatic abscess from which copious pus was coughed up daily, cured the patient.

Many other cases of this type—that is to say, those in which a single

cavity is present, usually in one or other lower lobe—have responded well to bronchoscopic treatment, carried out under local anæsthesia with little discomfort to the patient, who is not necessarily confined to bed. If the treatment fails, some form of external operation may be necessary; bronchoscopy should, however, be performed first, as it is frequently efficacious, and is always harmless if performed with local anæsthesia.

Multiple Bronchiectasis.—Numerous small dilatations on the finer air-tubes secreting pus are not so favourable as single cavities, but it is possible even then to improve the general condition of the patient and to add to his comfort by the removal of stagnant secretions and the reduction of obstructive swelling of the larger bronchi, which prevents the expulsion of sputum when the patient attempts to empty his lungs by coughing. If the general and local conditions do not improve after a few treatments by bronchoscopy, some more radical procedure will be called for, such as division of the phrenic nerve or thoracoplasty.

Surgical Diseases of the Heart and Pericardium.

Wounds of the Heart are of two classes, the non-penetrating and the penetrating. The former are due to injuries of a crushing nature, and as the heart is injured by the fragments of overlying bones it is unusual for surgical treatment to be practicable in such cases; the latter are the commoner form of injury, and in certain instances the wound in the heart can be sutured or foreign bodies removed. The right ventricle is most frequently injured, the left auricle least frequently. Owing to the thin wall of the auricles, injury to them is more dangerous than to the ventricles; the thick muscular wall of the latter may suffice to check the hæmorrhage. The patient may die from the immediate cessation of the heart's action, or from intrapericardial pressure of blood, or from internal or external hæmorrhage.

If the patient does not die at once, he suffers from intense shock and prostration combined with a weak and turbulent action of the heart, great pain in the chest, and dyspnœa, whilst the pulse is scarcely perceptible. The area of cardiac dulness may be greatly increased. In over 70 per cent. of cases the pleura will also be wounded, so that blood escaping externally will be frothy. Purulent pericarditis is likely to ensue.

Treatment.—The patient must be kept absolutely quiet and with the head low until it is decided whether or not operative interference is justifiable. If the case is to be left, the external wound is purified, and no attempt made to explore it with the finger or probe for fear of dislodging clots. If operation is attempted, an anæsthetic is given, a trap-door incision consisting of the fourth and fifth costal cartilages is turned up, the pericardium freely incised; this allows blood-clot to escape, and with the decompression of the heart its action becomes stronger; the wound in the heart is gently explored and closed with deep sutures inserted through the muscular substance. A certain number of cases are on record where a wound of the heart has healed spontaneously even with a bullet in its substance, and the patient survived for years.

Cardiac Massage has been performed with success in cases where the patient has had a syncopal attack during the administration of an anæsthetic. An opening is made into the peritoneal cavity, a hand introduced, and the heart massaged through the diaphragm.

Pericardial Effusion, whether serous or purulent, may require surgical treatment in order to relieve symptoms of cardiac failure, due to the pressure of the exudate. The sac, when distended, pushes aside the pleuræ and lungs, and also is enlarged upwards, carrying up the base of the heart and rotating the apex forwards to a slight degree. The bare interpleural area of the pericardium is therefore increased, and the cavity may be tapped by trocar and cannula, or by aspirator, either close to the left border of the sternum in the fifth interspace, or one and a half inches from the sternal edge of that bone, so as to avoid the internal mammary trunk which courses down about half an inch from the border.

For suppurative pericarditis incision and drainage are necessary. This may be readily accomplished by removing the fifth costal cartilage and dividing the underlying perichondrium and triangularis sterni, together with section between ligature of the internal mammary vessels. This exposes the pericardium, which is opened and washed out, and a drainage-tube inserted. The prognosis is not good, as the patient's condition is bad.

Cardiolysis is an operation for the removal of a portion of the chest wall, lying in front of the heart, with the object of replacing the comparatively unyielding thoracic wall by a soft, pliable covering. It has been performed in cases of valvular disease with great hypertrophy, and also for cases of adherent mediastino-pericarditis to relieve the fixation of the heart to the chest wall, with its consequent mechanical disadvantage.

The parts usually removed have been the third, fourth, and fifth left costal cartilages, with or without a piece of the sternum, and the ends of the corresponding ribs. It is desirable to remove the perichondrium, but in cases of adhesive inflammation this may be almost impossible without wounding the underlying structures. In cases of Pick's disease, where there are dense pericardial adhesions obstructing the large venous channels, the parietal pericardium which is usually calcified should be gently stripped off the heart and removed piecemeal, the most extensive removal being on the diaphragmatic surface in order to free the inferior vena cava, though the benefit from this operation is probably produced by decompression of the ventricles, thus allowing better filling and prevention of back pressure effects in the auricles and large veins. Attempts have been made recently to deal surgically with anginal conditions. The relief of pain is attempted by interference with the sympathetic thyroid circle, either by sympathectomy, or by total removal of the thyroid gland. A more radical procedure is by supplying the sclerosed heart with a fresh blood-supply. This is done by grafting a portion of the pectoralis major on to the heart, or by drawing up an omental graft through the diaphragm, and fixing this to the ventricle.

Both in Pick's disease and in grafting operations the approach to the heart is an important feature of the procedure. This can be done by splitting the sternum or using an osteoplastic flap. In the latter case small portions of the costal cartilages of the third, fourth, fifth, and sixth ribs on the left side are removed, the sternum is split from the xiphisternum to opposite the second interspace and then divided to the left. This allows half the sternum to be turned to the left as a flap giving free access to the pericardium. On completion of the operation the flap is turned back and fixed by a large number of small sutures through the periosteum. In the case of an omental graft a small opening can be made through the pericardium and peritoneum into the abdominal cavity, through which the omentum can be drawn and fixed to the ventricle.

Operations on the Great Bloodvessels have been performed. Trendelenburg's operation is an attempt to remove an embolus from the pulmonary artery. The suitable cases are few, owing to the fact that death is in most cases instantaneous, and because the plugging of the vessel is frequently thrombotic rather than embolic. One or other main branches of the pulmonary artery has been ligatured in a few cases to check severe hæmoptysis, and in bronchiectasis; owing to the blood-supply of the lung being derived from the bronchial arteries, gangrene does not follow this procedure.

The affections of the **mediastinum** are most commonly infective (*mediastinitis*), and are seen in cases of cellulitis of the neck which spreads under the deep fascia. It may also follow operations on the neck when the pharynx or larynx has been opened. The commonest cause is from lesions in the œsophagus, either ulceration from growths or following the impaction of foreign bodies. Abscess formation is rare, the condition nearly always being fatal before a sufficient local resistance is set up. The patients complain of pain under the sternum and in the back, with high fever and rigors; there is dyspnœa and irregularity of the heart's action. **Treatment** is usually of no avail, but if the disease appears to be confined to the anterior mediastinum, drainage may be effected by splitting the sternum. A chronic tubercular abscess may be located in the mediastinum, secondary to spinal caries. This calls for no operative interference unless paraplegic signs are present, when a costo-transversectomy may be performed.

Tumours of the mediastinum are not uncommon if we include true retro-sternal goitres. Other forms are due to enlargement of glands, as in lymphadenoma, sarcoma of the thymus, teratomata, and dermoid cysts; these latter usually push outwards into one or other pleural cavity, and are frequently mistaken for tumours of the lung; an attempt to remove them should always be made. These tumours and cysts are always in the upper part of the mediastinum.

Asphyxia or **apnœa** is the term applied to indicate the condition arising from interference with or stoppage of the respiratory act. If this has not proceeded to any great extent it is termed **dyspnœa;** when, however, the obstruction is so marked that the patient is obliged to maintain the upright sitting position, the term **orthopnœa** is applied to it.

The **Causes** of asphyxia may be classified as follows:

1. Conditions arising from the presence of abnormal contents within the air-passages, *e.g.* foreign bodies; blood-clot or pus from the bursting of an aneurism or abscess; serum, as in œdema of the lung; mucus or muco-pus, as in suffocation. Death by drowning usually arises from a similar cause, *viz.* the replacement of air by water in the respiratory passages.

2. Causes arising in the walls of the air-passages, such as diminution of their lumen from inflammatory congestion, as in œdema of the glottis; cicatricial stenosis; the presence of new growths, or the displacement of parts, as in cut throat; or the falling back of the root of the tongue after partial excision.

3. Extrinsic causes, or those arising outside the air-passages, *e.g.* in the *neck*, strangling, hanging, garrotting, etc.; the presence of tumours such as goitres or aneurisms; a retropharyngeal abscess or tumour, or displacement backwards of the sternal end of the clavicle. Within the *thorax* obstruction to the respiration may be caused by the presence of tumours, aneurisms, or effusion into the pericardium or pleura.

4. Nervous causes, *e.g.* paralysis or spasm of the larynx, and paralysis of the diaphragm, either from peripheral lesions, such as the pressure of aneurisms or tumours on the nerve trunks, or from central causes such as a lesion in the upper part of the spinal cord or medulla.

5. In many forms of cardiac disease the lungs may become engorged with stagnant blood, leading gradually to dyspnœa, orthopnœa, and asphyxia, owing to increasing difficulty in eliminating carbonic acid.

The **Treatment** of asphyxia varies much under different circumstances. A rapid examination is at once made to ascertain, if possible, the cause of the mischief, and whether its onset has been gradual or sudden. If it has been gradually developing, it is not uncommonly due to some thoracic condition which cannot be immediately relieved; if, however, its onset has been sudden, and not the result of any evident lesion, the neck and chest should be bared, and examined for signs of traumatism, the mouth opened, the tongue drawn forwards, and the glottis examined with the finger to see that the passages are clear. The patient should, if necessary, be removed into fresh air, and artificial respiration at once commenced. Obstruction above or within the larynx needs tracheotomy or intubation, as also conditions associated with pressure on the trachea.

Artificial Respiration is required in a variety of surgical conditions, and can be undertaken by what is known as Sylvester's method. In this the patient lies on his back, with a pillow beneath the shoulders, the mouth opened, and the tongue drawn forwards. The arms are then grasped just above the elbows and drawn upwards above the patient's head, so as to expand the chest through the action of the great pectoral muscles. This position is maintained for about two seconds, and then the arms are lowered to the side and pressed firmly against the ribs, so as to determine a forcible respiratory act. At the end of about two seconds more the arms are again elevated and the

same cycle passed through. This should be repeated about fifteen times a minute, and the operator must be careful not to use too great violence, or to hurry over it unnecessarily, as harm rather than good results thereby.

Another less satisfactory method consists in alternately compressing the lower part of the thorax and abdomen with the hands, so as to drive out a certain amount of air, and then by suddenly relieving the pressure the elastic expansion of the chest wall draws in a fresh supply

CHAPTER XXXV.

SURGERY OF THE NECK.

In the second or third week of intra-uterine life a series of branchial arches form in the human embryo as in other mammalia, constituting the foundation from which the future structures of the neck are developed. In the majority of mammals five such post-oral arches occur, separated from one another by the so-called **branchial clefts**; but in man the fourth and fifth are amalgamated. They project from the side of the primitive spinal column, and consist of mesoblast lined on either side by epithelium. They unite across the median line at an early date, and also one with another, thereby leading to a large extent to the obliteration of the clefts. Occasionally, however, this union is imperfect, and sundry malformations result.

From the first arch there arise the mandible, the muscles of mastication, and the processus gracilis of the malleus. Its nerve supply is derived from the mandibular branch of the trigeminal nerve. The Eustachian tube, the tympanic cavity, the external auditory meatus, and the Glaserian fissure represent the unobliterated portion of the first cleft. From the second arch there arise the stapes, the styloid process, the stylo-hyoid ligament, and the lesser cornu of the hyoid bone. The nerve supply to this arch is derived from the seventh nerve. The second cleft is rudimentary, being represented by the fossa of Rosenmuller and the sinus pyriformis. The tonsil is developed in this cleft. The third arch gives rise to the greater cornu of the hyoid bone and is supplied by the ninth nerve. The fourth and fifth arches give rise to the thyroid cartilage and are supplied by the superior and inferior laryngeal branches of the vagus nerve. The third and fourth clefts are normally obliterated in man, but their occasional persistence gives rise to one form of branchial fistula.

Branchial Fistulæ are due to imperfect closure of the branchial clefts or to non-obliteration of the **cervical sinus.** This latter structure is developed as a result of the more rapid growth of the first and second arches, causing them to overlap the third and fourth and giving rise to a canal which may persist. The sinus runs upwards from a small opening situated over the lower end of the sterno-mastoid muscle near its inner border, passes between the internal and external carotid arteries, and ends in the supra-tonsillar fossa. In most cases branchial fistulæ are incomplete and possess only one opening, either internally or externally, the common type being a short tract running inwards for an inch or so. They are lined with columnar epithelium and secrete a glairy fluid. They are not uncommonly associated with other abnormalities, such as macrostoma, absence of the pinna, or accessory auricles situated either near the orifice of the fistula or close

to the ear. In the majority of cases they may be disregarded, but if troublesome should be laid open and the lining membrane either dissected away or destroyed with the galvano-cautery. It is advisable to inject the tract with methylene blue before attempting excision, so as to render it visible, as there is a great liability for a small portion to get left behind.

Branchial Cysts arise from incomplete closure of a branchial cleft, the unobliterated portion becoming distended with secretion. They usually appear in adolescents, often between the ages of ten and twenty, and are frequently attributed to a blow, which, it may be presumed, brings into activity structures which would otherwise have remained passive. They grow slowly and painlessly, forming rounded swellings, often rather soft, with more or less distinct fluctuation, according to the depth at which they are situated; their contents, if near the cutaneous end of the cleft, are sebaceous in character, similar to, but more fluid than, that found in dermoid cysts, *viz.* flattened epithelial cells, cholesterine plates, and fatty granules. If placed nearer to the pharynx, they are occupied by a glairy mucoid fluid. They are usually lined with squamous epithelium, but a few cases have been recorded in which the cells were columnar, and even ciliated, in character. The most common situation is in the third cleft, the cyst then lying between the thyroid cartilage and the anterior border of the sterno-mastoid, in relation with the great wing of the hyoid bone; when of large size, it may extend beneath that muscle, displacing it outwards (Fig. 714). More rarely a cyst arises from the second cleft, being then located in the upper third of the neck, and spreading up towards the styloid process; it may even reach from the mastoid process to the hyoid bone, running parallel to the inferior border of the jaw, and fluctuation may be detected through the mouth. *Treatment* consists in extirpation when the condition has attained sufficient size to be troublesome.

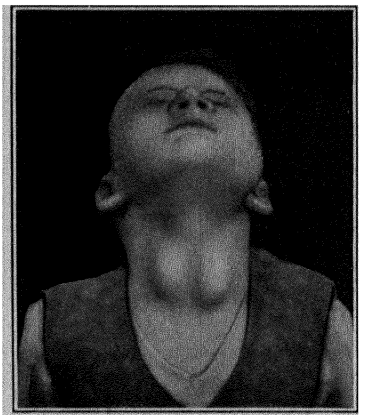

FIG. 714.—BILATERAL BRANCHIAL CYSTS IN A BOY, CURED BY EXCISION. (MR TWISTINGTON HIGGINS'S CASE)

Branchial Carcinoma may similarly originate in some unobliterated fragment of branchial epithelium, and takes the form of squamous epithelioma; it may be primarily cystic or solid, in either case running the ordinary course of the disease, infecting lymphatic glands secondarily and destroying life by cachexia or hæmorrhage. It is usually seen in men of middle age, and may have been preceded by a small swelling which was probably noted earlier in life. The usual site is in the upper part of the neck (second visceral cleft), constituting a tumour deeply placed beneath the sterno-mastoid about the level of the hyoid

bone, it is ill-defined in outline and spreads rapidly forwards beneath the jaw in the submaxillary region. Neighbouring muscles are infiltrated, but involvement of the pharynx, œsophagus, or larynx is unusual. There is considerable pain from nerve involvement spreading round to the back of the neck and head. The diagnosis can only be made by excluding all sources of primary infection elsewhere, and treatment is rarely practicable owing to the deep connections of the growth.

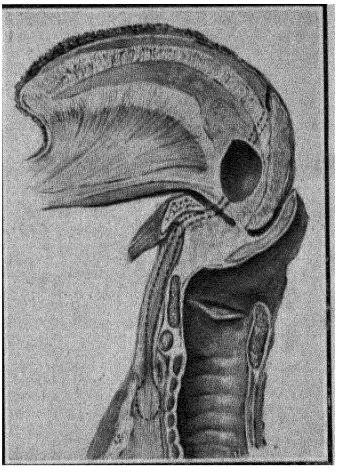

FIG. 715.—MEDIAN SECTION OF TONGUE, LARYNX, AND TRACHEA, SHOWING THYRO-GLOSSAL DUCT EXTENDING FROM THE FORAMEN CÆCUM OF THE TONGUE DOWNWARDS BEHIND THE HYOID BONE AND IN FRONT OF THE TRACHEA TO THE ISTHMUS OF THE THYROID BODY. (SEMI-DIAGRAMMATIC. FROM COLLEGE OF SURGEONS MUSEUM.)

A small dermoid cyst in the centre of the tongue is also represented.

Various other congenital conditions may be met with in the neck. **Congenital induration of the sterno-mastoid** in all probability arises from injury during parturition, and usually occurs in head presentations, probably from bruising of the side of the neck against the under surface of the symphysis, it is said to be more common on the left side than on the right. In cases that have been examined microscopically, the indurated mass has been found to consist of fibrous tissue. It disappears spontaneously after a time, but may result in torticollis.

Congenital Cysts of the Neck.—(*a*) *Dermoids* occur here as in any other region where congenital remains are found. As already mentioned, they may develop laterally from the branchial clefts, but may also be found in the middle line, or in connection with the thyro-glossal duct. (*b*) The *thyro-glossal duct* (Fig. 715) consists of a tubular outgrowth from the embryonic pharynx passing downwards behind the body of the hyoid bone in front of the larynx and trachea as far as the isthmus of the thyroid gland, which is subsequently developed from it, and unites with the lateral lobes, which in turn spring from the deeper parts of the branchial arches. The upper end of this duct is situated at the foramen cæcum of the tongue, and thence traverses the substance of that organ between the genio-hyo-glossi muscles to reach the hyoid bone; the lower end is represented by the pyramid of the thyroid isthmus. The whole of this tube disappears under ordinary circumstances, if, however, the upper part remains unobliterated, a dermoid cyst may originate from it, placed either in the substance of the tongue or immediately below it. If the lower portion remains patent, a cyst develops containing mucoid or glairy fluid, which, however,

is not present at birth. If it bursts spontaneously, or is opened, a so-called *median cervical fistula* results. Accessory thyroid growths of an adenomatous nature may develop from any part of the duct, but especially from the lower end; they are quite innocent in nature, and unless troublesome may be left alone. (*c*) *Cystic hygroma* is sometimes congenital, but may also be acquired. It consists of a multilocular swelling, the spaces composing it being due to dilatation of lymphatic spaces, and filled with lymph. The tumour is often of considerable size, and forms a soft, lobulated swelling, often with deeply placed intermuscular prolongations. It may produce great deformity and marked pressure effects. The skin over it may be occupied by dilated capillaries or lymphatics. Unless extending to inaccessible parts, such as the superior mediastinum, it should be dealt with by excision. Alternatively, sclerosing solutions (*e.g.* sodium morrhuate) or some form of radiotherapy may be tried.

Acquired Cysts of the Neck are of the following types: (*a*) *Sebaceous cysts* develop in the skin as elsewhere, but need no separate notice. (*b*) *Bursal cysts* are stated to occur in connection with the larynx and hyoid bone. There is usually a bursa over a prominent pomum Adami, and this may become enlarged and distended with fluid. Another bursa, the sub-hyoid bursa, also exists between the back of the hyoid bone and the thyro-hyoid ligament and may be mistaken for a thyroglossal cyst. Its long axis, however, lies transversely, and it is incorporated in the soft tissues beneath the hyoid bone, moving on respiration. In doubtful cases a microscopical examination of the lining wall will quickly settle the diagnosis, since if it is bursal in origin it is lined with endothelium, whilst if it is thyro-glossal it is lined with epithelium. In the former case incision and drainage usually suffice to bring about a cure, although excision is preferable; in the latter case the lining wall must be entirely removed. (*c*) *Unilocular serous cysts* are sometimes met with in the lower part of the posterior triangle. They contain serous fluid, with perhaps an admixture of blood. Their origin has not been defined with any certainty, but they are probably due to a dilatation of the lymph spaces, and are best treated by excision. (*d*) *True hydatid cysts* also occur in this region. (*e*) *Blood cysts* have been found in close connection with the large vessels of the neck. They are possibly due to the dilatation of a vein, and may communicate or not with some vascular channel, such as the jugular, being then partly emptied on pressure. Where no communication with a venous trunk exists, the lining membrane is intensely vascular. If their vascular origin is recognized, they should be left alone unless causing urgent symptoms. If, however, a blood cyst is opened by mistake, the supplying vessels must be secured, if possible, and, failing that, the cavity must be packed with gauze soaked in adrenalin. (*f*) Cysts are also occasionally met with in connection with the *salivary* glands and the *thyroid* body. (*g*) *Malignant cysts* arise, as already mentioned, from the remains of the branchial clefts, or from a degeneration of epitheliomatous lymphatic glands. They are often of large size, and their removal is impracticable owing to the adhesions which they contract to the deeper structures.

Cut Throat.—Injuries of the neck are commonly met with in cases of attempted homicide or suicide, and vary much in severity according to the extent and position of the wound. A right-handed suicide usually cuts his throat from left to right, and therefore the incision is bold and clean on the left side, tailing off towards the right; in a left-handed suicide the incision runs in the opposite direction. A homicidal cut throat varies in its direction according to whether it is done from behind or in front, and also with the hand employed. If the front of the neck is mainly involved, the air-passages are laid open, and the patient's life, though much endangered, is not necessarily destroyed. If, however, the wound chiefly affects the side, the great vessels and nerves may be divided, and death from hæmorrhage is very liable to ensue. The course and treatment of the latter class of case require no particular notice, since the general principles relating to all wounds must be adhered to. Where, however, the air-passages have been opened, special complications arise, requiring suitably modified treatment.

Wounds involving the Air-passages, the result of cut throat, may be situated at four different levels: (*a*) above the hyoid bone, encroaching on the base of the tongue; (*b*) through the thyro-hyoid space, the most common situation; (*c*) in the larynx; and (*d*) opening or dividing the trachea.

The **immediate effects** of such lesions are due to shock, hæmorrhage, asphyxia, or the entrance of air into veins. *When above the hyoid bone,* the root of the tongue and submaxillary region are involved, and hæmorrhage from the lingual or facial arteries or their branches follows; if the wound extends far enough, the main vessels are divided, and death results. In the less severe cases the patient runs considerable risk of being suffocated by the epiglottis and base of the tongue falling back over the larynx. Much difficulty will be subsequently experienced in feeding the patient, owing to impairment of the movements of the tongue. When the *thyro-hyoid* space is opened, the facial and lingual arteries are again in danger, as also the upper part of the superior thyroid. The base of the epiglottis is divided, and portions of mucous membrane around the entrance of the larynx may be detached, and cause obstruction to respiration. Blood may also trickle down the larynx into the trachea, and lead to asphyxia. In both this and the preceding variety, much pain and difficulty on swallowing will be experienced. Wounds of the *larynx* are usually transverse, and not very extensive owing to the resistance offered to the knife by the cartilage. The thyroid body may be wounded and bleed freely, otherwise there is but little hæmorrhage. Blood may find its way into the trachea or lungs, and asphyxiate the patient. When the *trachea* is involved, the common carotid and inferior thyroid vessels are very liable to be wounded, giving rise to severe, if not fatal, hæmorrhage. Asphyxia may be brought about by displacement of the severed portions of the tube, or from the entrance of blood into the air-passages, whilst air may also be sucked into opened veins. The recurrent laryngeal nerve may also be divided.

The **secondary effects** following cut throat are mainly inflammatory in origin. (*a*) The wound is likely to become *infected,* giving rise to

a cellulitis which may spread down to the mediastinum, or to œdema of the glottis. Secondary hæmorrhage also arises from this cause, and even general pyæmia. (*b*) *Inflammation of the air-passages*, tracheitis, bronchitis, or broncho-pneumonia frequently follows, partly as a result of the entrance of cold air, and partly from the admission of septic material, such as food, decomposing blood-clot, or discharges. The patient may become cyanosed from these causes, and in consequence of the partial asphyxia the sensibility of the mucous membrane of the glottis is diminished, allowing of the passage into it of food which appears at the mouth of the wound; in some cases this may have arisen from division of the superior laryngeal nerve, but the depth at which this structure is situated in the neck makes it difficult to conceive how it could be divided without injury to the main vessels. (*c*) *Surgical emphysema*, or the entrance of atmospheric air into the cellular tissue, may also follow a wound of the air-passages. It is not limited to the neck, but extends to the trunk, being recognized by the puffy distension of the part, and by a soft crackling crepitus elicited on pressure. It is of no great consequence, and usually disappears in a few days.

The **Treatment** consists in securing all bleeding-points, if possible, but occasionally they are placed so deeply that it is necessary to tie the external carotid; general oozing from the surface must be attended to, for fear of blood being sucked into the air-passages. Every effort should be made to render the wound aseptic; damaged portions of skin are excised, as also hopelessly injured muscle; if there is a reasonable prospect that asepsis has been attained, the wound may be closed by sutures in the ordinary way. Where, however, asepsis is doubtful, the wound should be packed with gauze soaked in flavine, and suture deferred for a few days,

The treatment of the air-passages varies with the site of the lesion. If the trachea has been roughly divided, the portions should be steadied by a stitch on either side, and a tracheotomy tube inserted—at any rate, for a few days; when cleanly cut, total closure without the use of a tube can be safely permitted. When the wound involves the larynx, it is desirable to close the opening at once, since the larynx does not readily tolerate the presence of a tube; if necessary, it is better to perform a high tracheotomy. When the wound involves the thyro-hyoid space, or is situated above the hyoid bone, it is quite safe in many cases to close the wound layer by layer after carefully disinfecting it. The mucous membrane is first dealt with by stitches which do not penetrate its whole thickness, and then a more thorough purification can be undertaken; if the epiglottis is divided, it must be accurately sutured. If there is any doubt as to the advisability of this proceeding, a high tracheotomy is first performed, and then the wound closed as far as possible.

In every instance the head should be flexed on the chest, and in suicidal cases a careful watch maintained to prevent the patient tearing the wound open. Loss of blood is dealt with by the infusion of saline solution or blood transfusion, and the patient's general condition attended to. Feeding should always be undertaken through a nasa

tube passed into the œsophagus, whether that structure is wounded or not, and this should be continued until the patient's natural powers of swallowing are restored.

The following **Sequelæ** occasionally result from a cut throat: (*a*) An *aerial fistula* is a persistent abnormal communication between the air-passages and the external air, and occurs most often in the thyro-hyoid space, the skin and mucous membrane becoming continuous one with the other around the margins of the opening. In some cases it may be closed; but if laryngeal stenosis or adhesions are present, it must be left alone for a time until these conditions have been treated. The operation consists in separating the skin from the mucous membrane, and in order to accomplish this, the external wound must be enlarged vertically. The edges of the mucous membrane are then pared, and stitched together horizontally. The external wound is either closed vertically, or left partially open and packed. (*b*) *Laryngeal or tracheal stenosis*, due to the cicatrization of wounds in these regions, may necessitate the constant use of a tracheotomy tube. (*c*) *Aphonia* may arise from division of the recurrent laryngeal nerve, and is then usually persistent. (*d*) *Œsophageal or pharyngeal fistulæ* may also in rare instances complicate the healing of an extensive wound in the throat, but tend to close of themselves, and require no special treatment.

Diseases of the Thyroid Body.

The thyroid body is a ductless secretory gland which lies beneath the fasciæ of the lower part of the front of the neck in close relation with the larynx and trachea. It consists of two lateral lobes, joined by an isthmus which lies across the second, third, and fourth rings of the trachea, and from which a slight upward projection is sometimes noted, the pyramid, which represents the original connection with the buccal cavity. The gland itself has a well-defined fascial sheath and a fibrous capsule, which dips in between the constituent acini to form the stroma; between the two the vessels enter, and many large veins are to be found. The blood-supply of the gland is very free, being derived from the four thyroid arteries which enter at the four corners, and possibly from the thyroidea ima artery, which runs up the front of the trachea to the lower border of the isthmus.

The glandular acini are lined with cuboidal epithelium, and secrete a colloidal material which normally contains an albuminous preparation of iodine, thyroxin. There is a very close connection between the acini and the surrounding lymphatics and venules. The secretory activity of the gland undoubtedly plays a very important part in the economy of the body, but at present the whole subject of the internal secretions (hormones or endocrines) is not perfectly understood; a certain number of facts emerge clearly into the light of day, but a fairly dense fog lies between them, especially as regards the interaction between the varying secretions.

Accessory Thyroids sometimes develop above or below the isthmus. They may be connected with it, moving up and down with it on deglu-

tition; or they may be independent, occurring in any part of the thyroglossal duct, and even in the base of the tongue, in that situation resembling a dermoid cyst. If troublesome, they should be removed and subjected to microscopic examination, as their structure varies, and there is a possibility of recurrence.

A classification may be given of the diseases of the thyroid body:

Inflammatory Diseases:

Acute thyroiditis.

Chronic thyroiditis:

(*a*) Non-specific.
1. Ligneous thyroiditis (Riedel's disease, woody thyroid).
2. Lymphadenoid goitre (Hashimoto's disease).

(*b*) Specific.
1. Tuberculous.
2. Syphilitic.
3. Actinomycosis, hydatid disease.

Non-Inflammatory Diseases:

(*a*) Adolescent goitre (physiological, puberty goitre).

(*b*) Colloid goitre.
1. Diffuse (simple, parenchymatous, Derbyshire neck).
2. Nodular (adenomatous).

(*c*) Toxic goitre.
1. Diffuse (exophthalmic goitre, Graves' disease, primary thyrotoxicosis).
2. Nodular (toxic adenoma, Plummer's disease, secondary thyrotoxicosis).

(*d*) Deficiency diseases.
1. Cretinism.
2. Myxœdema.

Tumours:

(*a*) Simple, *e.g.* 'fœtal adenoma,' fibroma, hæmangioma, and papilloma.

(*b*) Malignant.
1. Carcinoma—the scirrhus, the papilliferous, adenocarcinoma, and the malignant adenoma.
2. Sarcoma.

Acute Thyroiditis.—The thyroid gland may be the seat of acute inflammatory disease by pyogenic organisms, arising from local lesions such as cellulitis of the neck, infection of a cyst or impaction of a foreign body in the œsophagus; but more commonly it is a blood-borne infection and occurs in the course of certain infectious diseases such as typhoid fever, pneumonia, and mumps. One lobe or the whole gland is involved, and becomes enlarged, tender, and hot. Dyspnœa and dysphagia may be present, with general constitutional disturbance. If pus forms, rigors may occur, and should the infection spread outside

the capsule, cellulitis of the neck may follow. The presence of pus is not always easy to detect.

Treatment.—The patient is kept quiet in bed on a restricted diet, and his bowels and skin are made to act. Fomentations are applied to the part, or an ice compress; and under such a régime resolution may occur. If signs of suppuration supervene, as frequently happens, free incisions must be made.

Chronic Thyroiditis is rare, but may occur as one of several varieties. In certain instances the causative agent has not been defined, and Riedel's disease and lymphadenoid goitre both fall within this category. In all other varieties the pathological processes do not differ materially from those seen in other parts of the body when due to the same cause.

Riedel's Disease (ligneous thyroiditis, woody thyroid) is a slowly spreading, sclerosing type of inflammatory change which results in the gland becoming large and hard. The main pathological feature appears to be a dense fibrosis which invades the tissues of the gland, surrounding the alveoli and leading to an ischæmic degeneration of the alveolar cells. The condition is progressive and leads ultimately to a fibrous replacement of practically the whole gland. In spite of this fact, however, myxœdema is a rare sequela. The sclerosing process also spreads outside the confines of the gland, embracing the carotid sheath on both sides, and in this way has been known to reach the base of the skull. The œsophagus and trachea may become compressed, leading to dysphagia and stridor; the latter may also be partly due to pressure on the recurrent laryngeal nerve. Relief is usually obtained by a relatively limited resection of the gland or merely by simple division of the isthmus.

Lymphadenoid Goitre (Hashimoto's disease) is an inflammatory condition of the thyroid which results in a uniform enlargement, but does not possess the invasive characters of the Riedel's disease. The main pathological feature is a diffuse permeation of the whole gland with lymphocytes and which leads to a gradual destruction of the alveolar structure by its invasive properties. It is for this reason that myxœdema is a common accompaniment of this type of disorder. The disease seldom leads to pressure symptoms and thus does not require operative treatment; but the size of the swelling can be reduced by radiotherapy if thought desirable.

Tuberculosis is a very rare disease of the thyroid gland, and may develop in the course of a miliary infection or appear as a localized fibrocaseous affection, usually in association with the disease elsewhere in the body. A nodular condition of the gland is produced, and in the early stages, on account of the associated features of wasting, nervousness, flushing of the skin, and slight anæmia, may be mistaken for thyrotoxicosis. The condition should be treated on the usual lines.

Syphilis may occur as a gummatous affection, as either a congenital or a tertiary lesion. The process is usually localized, but may be diffuse in the inherited type. The swelling is painless and rarely gives rise to symptoms. It usually responds quite favourably to medical treatment.

Actinomycosis and **Hydatid Disease** are rare affections of the thyroid gland, but occur only as an incident in the course of infection elsewhere in the body. The lesions should be dealt with on the appropriate lines.

Goitre.—This term is applied to any non-inflammatory enlargement of the thyroid body; it does not indicate any special lesion, but a general or local physiological or pathological enlargement of the gland. Many theories as to the cause of goitre have been propounded, but none are fully satisfactory.

The thyroid gland being an important ductless gland, its function with reference to the general metabolism of the body must be considered, as well as the local manifestations. When the function of the gland is suppressed either by surgical removal or disease, a condition of hypothyroidism arises. In adults this results in **myxœdema,** which is characterized by a deposit of a mucinoid substance in the subcutaneous tissues; the face becomes puffy, waxy white, and expressionless, with, perhaps, a hectic flush over the malar eminences; the tongue is enlarged; the limbs become thickened and clumsy by an increase in bulk of the soft tissues; a puffy mass often occupies the supraclavicular fossa, which, however, does not pit on pressure. The hair falls out, the pulse is slow, the temperature and basal metabolic rate become subnormal, and the mental faculties are dulled. Without treatment, death will result sooner or later from asthenia. In young children absence or destructive disease of the gland produces **cretinism.** The children are of stunted growth, with pale, flabby faces, dirty habits, and with intellects so dulled as to be classified as idiots. In both these conditions the administration of thyroid extract (2 to 5 grain tablets once a day) produces great improvement.

The secretion from the thyroid gland is constantly being poured into the blood-stream, varying in amount according to the need of the body, and there can be little doubt that it has an important influence on the function of all the other ductless glands. Its increased activity at times is so marked as to produce a visible enlargement in the gland. Puberty, especially in girls, is such a period, as are also pregnancy, fear, and sexual excitement. Enlargements occurring from these causes are sometimes spoken of as *physiological,* and may disappear spontaneously or with the administration of thyroid extract or iodine.

A similar condition can be produced experimentally in dogs (Marine) by removing a portion of the gland, when hyperplasia of the remainder takes place, with disappearance of the colloid, this later being used up by the increased demands of the body, while the overgrowth of glandular tissue is needed in order to keep up the supply of thyroxin. Reinhoff has shown that this so-called involution process takes place in Graves' disease after the administration of iodine in the form of Lugol's solution. If a patient or an experimental animal with hyperplasia is given an excess of iodine, or if the demands of the body for thyroxin should be lessened, involution usually takes place in the gland, as occurs in 'physiological' goitre. The acini are no longer filled with proliferating epithelium, the colloid re-accumulates in the acini, the vascularity decreases, the epithelium lining the acini becomes

flattened, and there is a great increase in the fibrous stroma of the gland.

The thyroid gland is constantly being acted on by chemical, bacterial, and psychic stimuli which produce hyperplasia, and as the stimulus ceases involution follows. Reinhoff has shown that this process of involution is not equally distributed throughout the gland, some areas undergoing involution to an extreme degree (hyperinvolution), and others withstanding the process, each lobule apparently acting on its own. In the hyperinvolution process, many lobules may coalesce owing to their walls thinning out and giving way from the pressure of the colloid, the epithelium being so flattened that the nuclei stand out 'like the beads on a necklace' (Boyd). Owing to this unequal process of involution, some one area may be shut off from the rest of the gland by an increase in the fibrous stroma, containing chiefly colloid, and a few cellular elements. Such an area has hitherto been called a colloid adenoma, and more than one of these may be present. Other areas that do not undergo involution of necessity remain small, but can be found scattered throughout the gland, and may be present in sufficient numbers to cause toxic symptoms. Adenomas of the thyroid are therefore not new growths, but result from a process of hyperplasia involution.

Adolescent Goitre is the term applied to the enlargement of the gland which occurs about the time of puberty. It is probably a compensatory response to the demands of the body for increased thyroid secretion, and is brought about in the first instance by a hyperplasia of the cellular elements. This is followed later by involution, which in most cases restores the gland to normality; but in a certain number this physiological reduction in activity is incomplete, and a swelling persists which resembles the colloid type of goitre in its early stages, but differs from it by containing small scattered areas of hyperplasia.

Colloid Goitre is widely distributed geographically. In this country the favourite seats are Derbyshire and Gloucestershire, but it also occurs not unfrequently in and around London. It is exceedingly common in Switzerland and the valleys of Northern Italy, and it is also to be found in parts of the Pyrenees, Himalayas, and Andes. In North America it is widely distributed, but perhaps more commonly near the Great Lakes. These facts apply chiefly to the colloid goitre, but wherever this is found, other types of enlargement of the thyroid occur. Two chief theories as to the causation hold the ground: (1) That it is due to a deficiency of iodine in the diet, chiefly through the water-supply; this is to a certain extent proved to be the case by the diminution of the number of cases of goitre, and the improvement which follows when the water-supply of the district is medicated with small quantities of iodine, or the use of iodized table salt is made compulsory. The improvement of drinking-water in goitrous districts has, however, also proved beneficial, without the addition of iodine. (2) M'Carrison holds the view that an organism, not yet identified, is introduced into the intestinal tract through an impure water-supply, and that toxæmia caused by the organism produces hyperplasia of the gland. He has been able to produce a goitre by feeding the filtrate of water from

a goitrous district, not only to animals, but to healthy human subjects, while the filtrated water has produced no effect. Gaylord, working with fish, has produced evidence to support this theory.

Colloid goitre may occur clinically as one of two types, the diffuse and the nodular variety.

Diffuse Colloid Goitre (simple or parenchymatous goitre, Derbyshire neck) is the commonest variety seen in early adult life. It consists of a diffuse enlargement of the thyroid gland, the parts retaining to a great extent their general proportions, although one lobe is often greater than the other. The most notable feature is the great increase of colloid material within the vesicles, which produces an enormous distension of the alveoli and flattening of the lining epithelium. At



FIG. 716. FRONT AND LATERAL VIEW OF A COLLOID GOITRE.

the same time the fibrous stroma is increased and helps to give rise to the slight lobulation of the gland which is so often a feature (Fig. 716). The swelling is soft and inelastic to the touch and quite painless, and there may be some lobulation. The amount of colloid accumulation may be so large as to give a cystic feeling, while, if the stroma of the gland is greatly in excess, the tumour feels harder and there is more lobulation; in some cases the increase of the stroma may be so excessive that insufficient gland substance is available for the needs of the body, leading to myxœdema. It produces no symptoms other than those associated with pressure from its increasing size (Fig. 718).

Nodular Goitre (adenomatous goitre, Fig. 719). The pathogenesis of this type of goitre has already been referred to, and the pathology

is similar to the diffuse type The difference lies in the fact that the hyperplasia-involution cycle has probably existed for a much longer period of time and that the fibrous development is more extensively developed, so that a grossly nodular appearance is imparted to the gland. One other distinction is the frequency of the presence of various types of degeneration, as cystic, hyaline, fibrous, and calcareous, in this variety of goitre. Malignant change also is by no means rare Clinically, it consists in the presence of one or more encapsuled nodules in the substance of the thyroid body, which is itself often concurrently enlarged. The nodules may occupy one or other lobe, or when multiple may be scattered through the substance of the organ, occasionally they develop in the isthmus alone. If situated near the surface their limitation and free mobility in the gland can be easily detected but when placed deeply their special feature cannot be recognized The majority of these nodules are due to the hyperplasia - involution cycle, and consist of thyroid tissue which has undergone hyperinvolution, and has been shut off by the increase of the stroma from the rest of the gland. A small number of nodules may be of the fœtal type These latter are nearly always single, and retain their characteristic

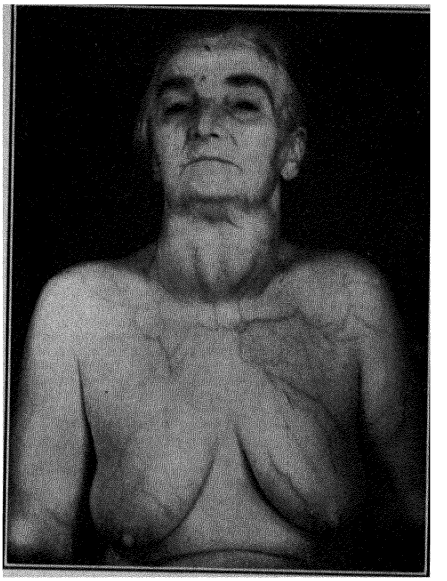

FIG. 717.—INJECTED PHOTOGRAPH OF A LARGE RETROSTERNAL GOITRE IN A WOMAN ÆT 68

The enlargement of the subcutaneous venous plexus is well seen



FIG. 718.—MICROPHOTOGRAPH OF COLLOID GOITRE

independently of their age, the former type of nodule may undergo changes. The whole internal stroma may disappear owing to pressure, and the nodule consist only of colloid. Hæmorrhage may take place into a nodule, and then it increases rapidly in size, or it may become secondarily infected through the blood-stream. In old-standing cases, when calcification has occurred, the nodules assume a stony hardness which may be mistaken for a carcinoma. In these cases the long-standing history is usually sufficient to differentiate, but in doubtful issues a skiagram may be of service.

Clinical Features.—In all varieties of goitre the thyroid body is the site of a swelling involving its whole substance, or one or other of its lobes, or possibly the isthmus alone. Its consistence varies with the nature of the growth, but it always moves with the larynx on

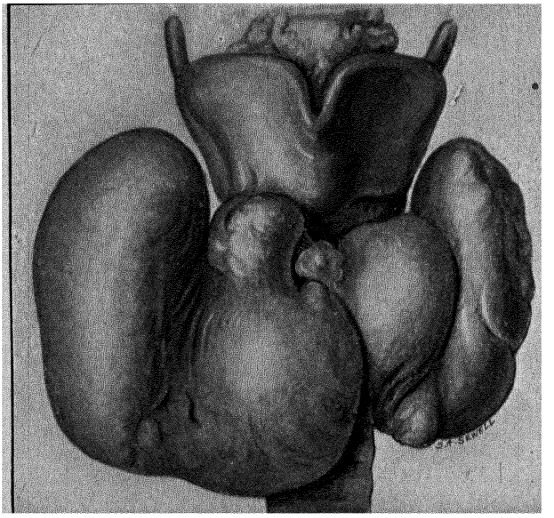

FIG. 719.—NODULAR GOITRE. (KING'S COLLEGE HOSPITAL MUSEUM.)

swallowing. The local effects are produced from the anatomical position of the swelling. Pressure on surrounding structures leads to dyspnœa or dysphagia, while the carotid sheath and its contents are displaced outwards, accounting for the attacks of giddiness and fainting which sometimes occur. The trachea is especially liable to changes of situation and shape, from the enlargement of the gland; it is usually flattened from side to side (*scabbard trachea*), and often displaced an inch or more from the middle line, the greatest displacement and most urgent dyspnœa being produced by the localized swellings of the gland. This is seen particularly in localized swellings which have enlarged downwards into the upper opening of the thorax (*retrosternal* or *intrathoracic* goitre) (Fig. 717). The degree of displacement of the trachea can be noted best by radiography, the air in

he trachea showing as a shadow, it may be so marked as to produce tridor, but never aphonia, which is found only in cases where the ecurrent laryngeal nerve is involved, an occurrence rarely seen except n carcinoma of the gland The ordinary type of goitre is much more ommon in women than in men; it does not appear to be hereditary, nd is not influenced by marriage.

The **Treatment** of the colloid and nodular varieties of goitre may be onsidered together, as they are different in nature from those which ollow. In the early stages palliative measures can be employed, onsisting in the improvement of the general health, correction of rrors in the personal and sanitary hygiene, and the administration f small quantities of iodine.

In cases where, in spite of such treatment, the growth persists, ncreases in size, or gives rise to pressure symptoms, operative treat-

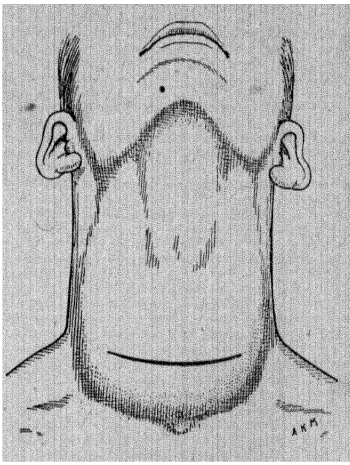

IG. 720.—POSITION AND SIZE OF COLLAR INCISION

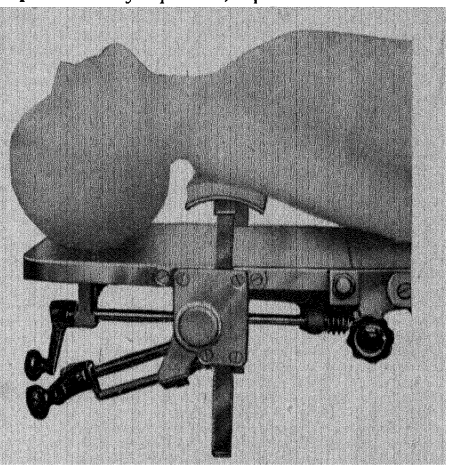

FIG 721 —THE DUNHILL REST, WHICH KEEPS THE NECK IN A CONVENIENT STABLE WAY

nent should be undertaken in order to remove the localized swelling r a part of the gland. Total extirpation, as already mentioned, esults in myxœdema; but so long as a sufficient portion of the secret- ng substance is left, whether it is derived from the isthmus or from ne of the lobes, no such sequela need be feared. In fact, goitres hould be treated much in the same way as new growths, *viz.* by emoval when small; there is still unfortunately a considerable ten- lency amongst practitioners and patients to leave them untouched until hey are of large size, thus greatly increasing the risk of the operation.

Partial Thyroidectomy is conducted as follows: Under avertin and as and oxygen anæsthesia with local infiltration of the skin with per cent. novocain, a collar incision is made transversely across he neck 4 to 6 inches in length (Fig. 720). To steady the neck Dunhill neck-rest is useful (Fig. 721). The platysma and layers

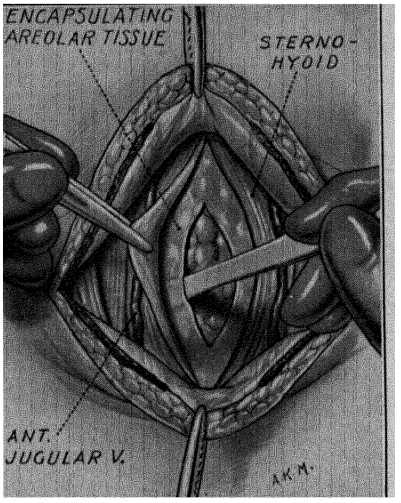

FIG 722.—EXPOSURE OF THYROID GLAND.

(The infra-hyoid muscles have been retracted and the capsule of the gland incised.)

of deep fascia are divided, and the sterno-mastoid, sterno-hyoid, and sterno-thyroid drawn aside, or, if need be, divided. The lobe to be removed is thus exposed within its capsule, which should then be opened (Fig. 722). The upper and lower poles are defined by blunt dissection. The superior thyroid vessels are secured by double ligatures (Fig. 723) and divided; the middle thyroid vein is ligatured at the outer border of the gland, and the inferior thyroid vessels are dealt with below, special care being taken to avoid the recurrent laryngeal nerve by tying the vessels close to the gland. The lobe is now delivered into the neck by blunt dissection, and the isthmus freed from the trachea. In detaching the latter the surgeon must not forget

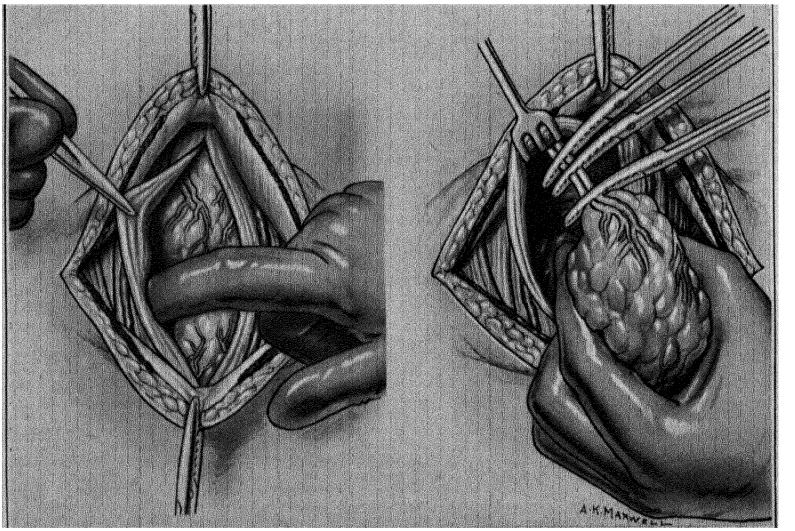

FIG. 723.—METHOD OF DELIVERING THE UPPER POLE OF THE THYROID GLAND AND LIGATURE OF THE SUPERIOR THYROID VESSELS

that the cartilaginous rings may have been softened or absorbed by pressure, and that the walls of the trachea are easily wounded. The isthmus is divided, and any bleeding vessels secured. The wound is closed with catgut sutures for the muscles and fascia, and the skin sutured. A drain is introduced for twenty-four hours, as it is difficult to employ pressure on the neck. Healing by first intention should be the invariable result, and the scar almost invisible.

The question of anæsthesia in these operations has been much discussed. Some surgeons advise that local infiltration anæsthesia should always be employed; many others reserve that procedure for the worst cases, and trust to a skilled anæsthetist to administer gas and oxygen after the administration of avertin to the majority of the patients. With this latter view we personally concur. In cases where there is marked pressure on the trachea, as in intrathoracic goitre, the intratracheal administration of gas and oxygen may be preferred.

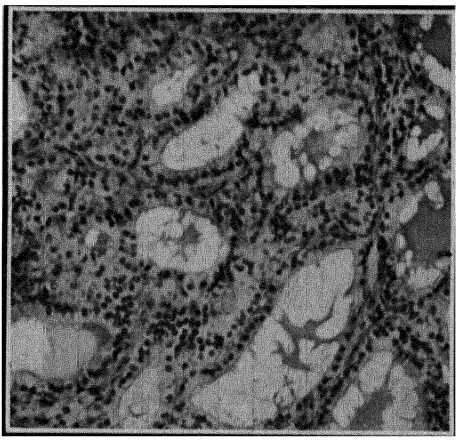

FIG 724.—MICROPHOTOGRAPH OF EXOPHTHALMIC GOITRE.

In nodular goitre, where the nodules are multiple or incompletely differentiated, the affected lobe should be removed, but if the nodule is single, or a fœtal adenoma is present, it may be enucleated by dividing the skin and muscles as before, incising the gland substance and capsule down to the swelling, which is readily shelled out.

Toxic Goitre.—This condition can be subdivided into two clinical varieties. **Diffuse toxic goitre** (also called **Graves' disease, exophthalmic goitre, primary toxic goitre,** or **primary thyrotoxicosis**) is the term applied to the disease when it occurs in a gland clinically free of nodules; while **nodular toxic goitre** (also called **toxic adenoma, Plummer's disease, secondary toxic goitre,** or **secondary thyrotoxicosis**) is the term applied to the nodular goitre which is associated with signs of toxicity.

In either case the gland is the seat of hyperplastic changes of a marked degree. In the primary form these changes are so prominent as to give a characteristic appearance to the cut surface of the gland, which is fleshy-looking with no obvious colloid, in marked contrast to the translucent appearance of the colloid gland, and with a fine network of interstitial tissue. Microscopically, the alveoli are small and crowded together with a small quantity of poorly staining colloid; papillary proliferation of the columnar epithelium is present, and there is marked increase in the vascularity of the gland (Fig. 724). This

characteristic appearance is lost when the patient has been given Lugol's iodine, the gland undergoing an involution process in varying degree, with increase in the colloid and fibrous tissue, and a flattening of the papillary proliferations of the epithelium of the acini. In the secondary type the changes are not usually evident to the naked eye, but microscopically similar changes are noted. In the diffuse type, more especially in the severe cases, there is usually some degree of enlargement of the thymus gland, the significance of which is not understood.

The **Cause** of the symptoms found in toxic goitre is not established. There can be no doubt that the marked hyperplasia found in the gland is responsible for the greater part of the symptomatology, although it is not certain whether the secretion produced is of normal character. The clinical features of Graves' disease are characterized by a diffuse enlargement of the thyroid gland, which often pulsates forcibly owing to a greatly increased vascularity, marked palpitation and tachycardia, a fine tremor of the hands, and protrusion of the eyeballs. In addition to these fairly constant features there are numerous others, of which the most important include a raised basal metabolic rate, loss of weight, thirst, and disturbed menstrual function, usually amenorrhœa. The symptomatology would appear to depend upon the presence of excessive thyroid secretion and overaction of the sympathetic nervous system, and the clinical picture depends upon the degree of admixture of these two components. The protrusion of the eyeball is a remarkable feature which is fairly constant (Fig. 725). Its mechanism has been thought by Mulvany to be due to the contraction of the unstriped musculature situated in the front half of the orbit and the lids in conjunction with a diminution in muscle tone (thyrotoxic myasthenia) of the voluntary ocular muscles. By this means the eye is gradually pulled forward into a position of exophthalmos. Its non-disappearance in certain cases after operation is due to a permanent shortening of the soft tissues between the lids and the globe, to a lengthening of the ocular muscles, and to a retrobulbar deposition of fat. A fine fibrillary tremor of the extremities and tongue is commonly observed in these cases. The patient is always extremely nervous, with a moist skin and a high pulse-rate, and frequently a high blood pressure; any exertion or excitement increases the irritability of the heart action, and may induce considerable respiratory distress. In advanced cases the diseased heart may go on to fibrillation, the

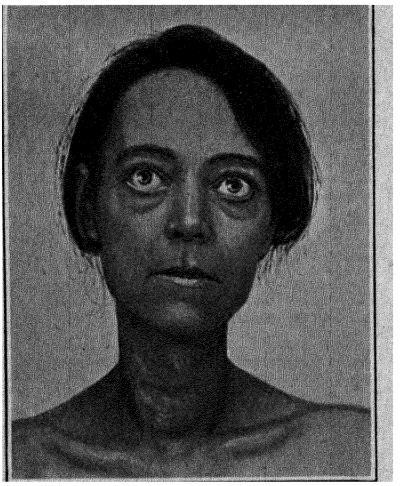

FIG. 725.—EXOPHTHALMIC GOITRE

nervous symptoms progress to mania, while the patient may die from exhaustion following on severe attacks of diarrhœa and vomiting. The disease has definite remissions, and may become completely cured during such a period with little treatment other than rest. On the other hand, the exacerbations usually leave the patient worse than before, with impaired general health and a weakened heart.

This exhaustion is to be accounted for by the fact that with the increased or vitiated secretion of the thyroid the metabolism of the whole body is enormously increased, and the disease acts like a blast on a furnace, leading to greatly increased consumption of fuel. In such cases, by measuring the basal metabolic rate we can estimate the severity of the disease. Mild cases show an increase of 20 to 40 per cent., while in severe cases the rate rises to 60 to 100 per cent. This metabolic rate gives an indication as to the progress or remission of the disease. Its use, however, should be restricted, as the frequent estimation of the rate worries the patient and increases the symptoms.

Nodular toxic goitre is usually less severe than the diffuse type, because the gland is much less active and is often the seat of various degenerative changes. For this reason the symptoms of toxicity such as loss of weight, raised metabolic rate, the presence of exophthalmos, are slight in comparison with the anxiety features, such as tremor, sweats, palpitation, and headaches, which are marked. One other feature is the much greater tendency for cardiac disturbance to develop, although the degree of tachycardia preceding its appearance may have been only slight. This is due to the fact that the disease occurs at a later period of life.

Treatment of Toxic Goitre consists in freeing the patient, if possible, from all sources of irritation and worry by absolute rest in bed. Attention should at the same time be paid to sources of infection which are frequently to be found in the tonsils or mouth. A most powerful form of medication has been reintroduced by Plummer for the treatment of these cases, *viz.* by Lugol's iodine (5 per cent. iodine in a 10 per cent. aqueous solution of potassium iodide). This solution given in small quantities daily (mv.-vii. t.d.s.) usually produces a marked lowering of the pulse-rate, a decrease in the basal metabolic rate, and a diminution of the nervous symptoms. In some of the worst cases Lugol's solution may be given intravenously; it may safely be administered in any dilution up to fifteen drops to a pint, and can be given in glucose or saline solutions. Sometimes large doses of Lugol's solution will quickly perform what small doses, although long continued, have not been able to accomplish.

Unfortunately this improvement is not always maintained, and the maximum benefit is seen after about eight to ten days, although in some cases it only appears after two or three weeks. If continued after this period, the drug appears to lose its effect, and a second course rarely produces as much benefit as the former. After a short course the patient reaches a condition in which operative measures can be undertaken with a greatly decreased mortality rate.

When medical treatment has not been effective, or if there is an exacerbation of symptoms, *operative treatment* must be considered.

The mere suggestion of surgical measures to these patients usually produces a rise in the pulse-rate and a great increase in the nervousness, and the advantage of a course of Lugol's iodine as a preliminary is at once obvious. As already mentioned, the exhibition of iodine in these cases produces a marked effect on the thyroid, which becomes firmer and very slightly nodular on its surface, and on section has no longer the beefy look of an untreated gland. The operative procedure required is the removal of about seven-eighths of the gland; if less is removed, the symptoms are likely to recur and a further operation is necessitated (Fig. 726).

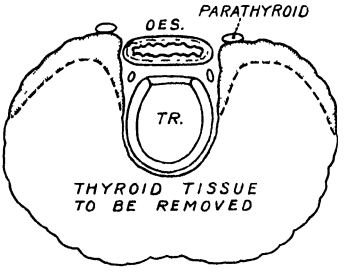

FIG. 726.—THE AMOUNT OF THYROID REMOVED IN SUBTOTAL THYROIDECTOMY

The gland is exposed as described previously, and the upper pole on the right side divided between double ligatures, thus securing the superior thyroid artery and vein. The lobe is thus freed, and a series of artery forceps are applied to the postero-lateral aspect of the lobe, and the lobe sliced across towards the trachea, thus leaving a small portion of the gland between the trachea and the œsophagus. The isthmus is then freed, and the removal of a portion of the lobe on the opposite side by a similar method completes the operation. Bleeding points are secured and tied; the muscles and skin are sutured, and a drain introduced for twenty-four hours. A further course of Lugol's iodine is subsequently administered.

The choice of an anæsthetic in these cases is of great importance. Chloroform should never be given. Avertin, gas and oxygen, with local infiltration of the skin, is most satisfactory, some surgeons preferring local anæsthesia with scopolamine and omnopon. Both these types of anæsthesia are suitable for those cases where the heart is fibrillating, the latter a type of case that appears desperate, but in which brilliant results can be obtained.

Dunhill in a verbal communication states that out of 278 cases, 227 (81·6 per cent.) have regained normal rhythm, with a 6·1 per cent. mortality, and the remaining cases not being traced.

With modern pre-operative treatment, acute hyperthyroidism as a post-operative complication is rarely seen. A small percentage of the patients do not respond to Lugol's iodine, and then it may be advisable to ligature the superior thyroid arteries, and only after some improvement has occurred to remove a portion of the gland. When the patient stands operation badly it is always advisable to effect the needful removal of the gland in stages until a sufficiency has been taken away. A reappearance of toxic symptoms after the first operation usually indicates that an insufficient amount of gland has been removed. A period of six months at least is necessary before the full benefit of an operation is seen.

Radio-therapy in the treatment of toxic goitre is sometimes bene-

ficial; some cases are improved, but in the majority operative treatment holds out a better hope of curing the disease.

Tumours of the Thyroid Gland.—These may be simple or malignant. The most notable **simple** tumour is what has been termed **fœtal adenoma** on account of the resemblance which it bears to fœtal thyroid tissue. This swelling usually occurs as a small, firm, encapsulated tumour of fleshy appearance, situated in one or other pole of the thyroid body. On section it is seen to consist of small, rounded, solid alveoli containing no colloidal matter or other evidence of secretory activity. The growth of this tumour is slow, and it does not attain any great proportions nor appear to be disposed to malignant change. Other simple swellings have been described, but are

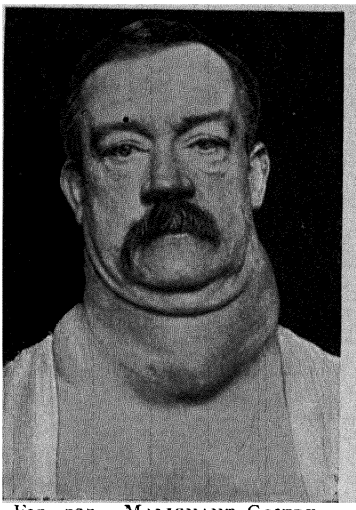

FIG. 727.—MALIGNANT GOITRE.

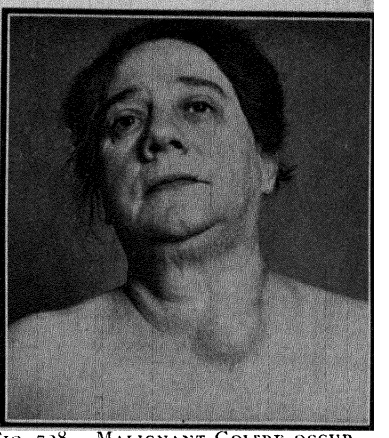

FIG 728.—MALIGNANT GOITRE OCCURRING IN A WOMAN WHO WAS KNOWN TO HAVE A NODULAR GOITRE FOR TWENTY YEARS

rare. The hæmangioma, fibroma, and papilloma are the most common varieties, but the diagnosis is seldom made apart from operation.

Malignant Disease of the thyroid gland (Fig 727) may arise in an apparently healthy gland or in one which is already the seat of nodular change (Fig. 728). It is thought by some observers that a definite association exists between the presence of nodules in the gland and the onset of malignant change.

Pathology.—The vast majority of malignant growths of the thyroid gland are of the nature of carcinomata, of which there are three main varieties. The commonest, **carcinoma simplex,** is of the usual scirrhus variety, similar to that which is seen elsewhere in the body (Fig 729). It possesses locally invasive qualities and spreads by means of the lymphatic system, but distant metastases also occur as in the case

of breast and other similar types of cancers. Locally, it infiltrates the surrounding tissues, and may compress the trachea and œsophagus, giving rise to serious and often quickly fatal complications.

The **Papilliferous Adeno-carcinoma** is a more benign and less common type of cancer. It grows slowly and spreads to the neighbouring lymphatic glands, but it is much less invasive than the scirrhus variety and may run a course of several years. The glands which are involved lend themselves to local excision, but tend to recur after a varying interval, which may be long. Lastly, there is the **malignant adenoma of Langhans,** the structure of which sometimes cannot be distinguished from that of normal thyroid tissue. The primary tumour is usually small and may be pulsating; but metastases are early and numerous and have a special predilection for the bones, in particular the skull and the vertebræ. These metastases, like the primary, are often pulsating, and the author is familiar with one case in which an early deposit in the sternum was thought to be an aneurism.

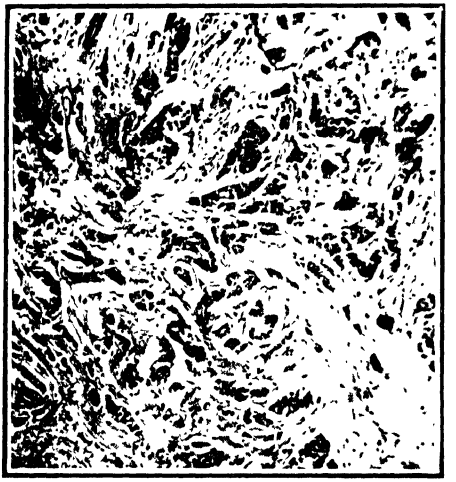

FIG. 729.—MICROPHOTOGRAPH OF CARCINOMA SIMPLEX OF THYROID (×82)

Sarcoma is rare, and its existence doubted by some authorities. Possibly the commonest variety is the lympho-sarcoma, which may arise in the lymphoid tissue normally present in the gland. One other unusual and peculiar type of tumour, which is possibly a sarcoma, is what has been termed a **carcinoma sarcomatoides.** This is a rapidly spreading and growing neoplasm which presents the unusual feature of a mixture of epithelial and connective tissue elements. It is most probable, however, that this tumour is an atypical form of carcinoma.

Clinical Features.—The onset of malignant disease is suggested by the presence of a swelling which is from the first hard and without a clear definition. Pain, particularly that which is referred to the ear, is an early and fairly constant feature, but local pain is usually a later phenomenon. Pressure features are often early, and the trachea and œsophagus become compressed, the former sometimes becoming perforated. Hoarseness and dyspnœa develop rapidly and may be aided by involvement of the recurrent laryngeal nerve. The main vessels of the neck are frequently surrounded and compressed, leading in the first instance to venous engorgement of the head and neck (Plate XVIII.). Death may occur from asphyxia, serious hæmorrhage into the trachea or œsophagus, or from broncho-pneumonia. When



Carcinoma of the Thyroid

(Museum, Royal College of Surgeons)

the neoplasm occurs in association with a pre-existing goitre, the change in type is indicated by a rapid increase in size, by a change in the consistence of the mass, which becomes harder and more nodular than previously, and fixed, and by the onset of pain. Otherwise the clinical progress of the disease may be insidious and very misleading.

Treatment by extirpation should always be attempted in the early stages, and in all cases before the gland becomes definitely fixed. In those which are inoperable, radiotherapy should be employed and may sometimes effect a cure. In any case, relief not uncommonly follows, and pressure symptoms may be avoided or reduced by its judicious use.

The **Parathyroid Glands** are small ovoid bodies, usually four in number, situated behind the thyroid gland, and generally near the termination of the inferior thyroid artery. Microscopically they consist of columns of epithelial cells with large nuclei embedded in a rich capillary stroma. Spaces are often found in them containing a colloid material, which is not considered identical with that found in the thyroid vesicles. Their function is not definitely known, but their complete removal in animals causes acute convulsive attacks, together with the condition known as tetany, and death in a few days from coma. The tetany formerly ascribed to removal of the thyroid body is in reality due to disease, absence, or removal of the parathyroids. They also have considerable influence upon the calcium metabolism of the body. Post-operative tetany due to injury or removal of the parathyroid in operations upon the thyroid gland can be treated by giving parathormone and calcium. Tumours of the glands are associated with cystic disease of bones.

The **Thymus Gland** is an occasional source of trouble in that it persists and becomes enlarged instead of disappearing. Normally it reaches its greatest dimensions about the age of two years, and then gradually wastes, so that by puberty it is represented by a mass of fatty tissue, with perhaps a few remnants of the original organ. Its persistence, and still more its enlargement, is indicated by fulness of the root of the neck, dulness over the sternum, perhaps by evidences of mediastinal pressure on the large veins, and certainly by increasing dyspnœa. A skiagram is always necessary for the ultimate diagnosis and is often conclusive. A *thymic asthma*, partaking of the nature of laryngismus stridulus, has been described; but more important is the association of an enlarged thymus with generalized lymphatic hyperplasia, and a large spleen in the condition known as *status lymphaticus*, which may be a cause of sudden death under anæsthetics. The thymus is generally enlarged in cases of Graves' disease that come to the post-mortem table. Tracheotomy is useless in the treatment of the somewhat severe dyspnœa sometimes present, and operative interference for the removal of the enlarged gland has been undertaken with success in some cases. Lymphadenoma and lympho-sarcoma have also been known to affect this organ.

CHAPTER XXXVI.

DISEASES OF THE BREAST.

Congenital Malformations of the breast are much more common than is generally supposed. One or more accessory breasts (*polymasia*) or nipples are found either below the normal one or just above it; sometimes they have been found in the axilla, on the outer side of the thigh, or other unusual situations. They are often of a most rudimentary nature, but in a few cases have secreted milk (Fig. 730). Very rarely the breasts are entirely absent (*amazia*) (Fig. 731). Occasionally the

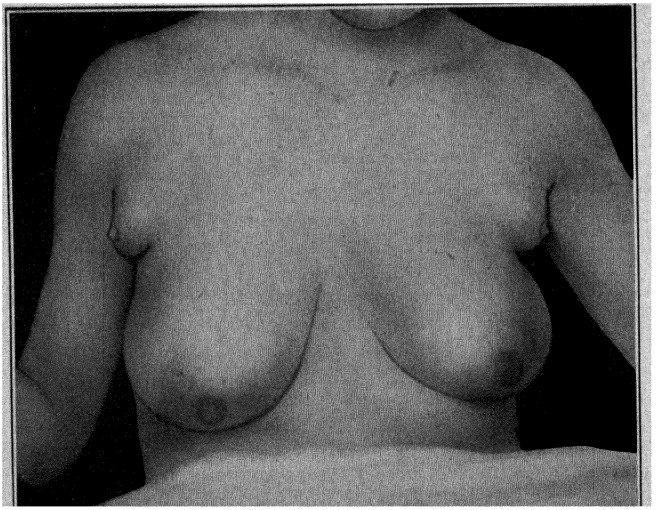

FIG. 730.—AXILLARY BREASTS WHICH WERE QUITE FUNCTIONAL (DR M CHRISTIE'S CASE)

male breast becomes enlarged to the ordinary size of a virgin's breast (*gynecomastia*), the organ is usually functionless, since the overgrowth mainly affects the stroma, although lactation has been known to occur. The condition may be associated with imperfect or irregular development of the sexual organs

Diffuse Hypertrophy of the breast (Fig. 732) consists of a general enlargement of the organ due to a diffuse overgrowth, chiefly of fibrous stroma and fatty tissue. The breast usually remains firm and elastic,

but may reach enormous dimensions, occasionally to the extent of resting on the knees when the patient is sitting. The condition comes on about puberty and is generally bilateral. The breasts are usually painless, although sometimes neuralgia is noticed. Functionally they are useless, as even if the patient becomes pregnant secretion of milk but rarely occurs. No cause can be assigned for the overgrowth.

The **Treatment** of diffuse hypertrophy must vary from amputation to some form of mammaplasty. X-ray treatment and hormone therapy are useless and are apt to make the patient melancholic.

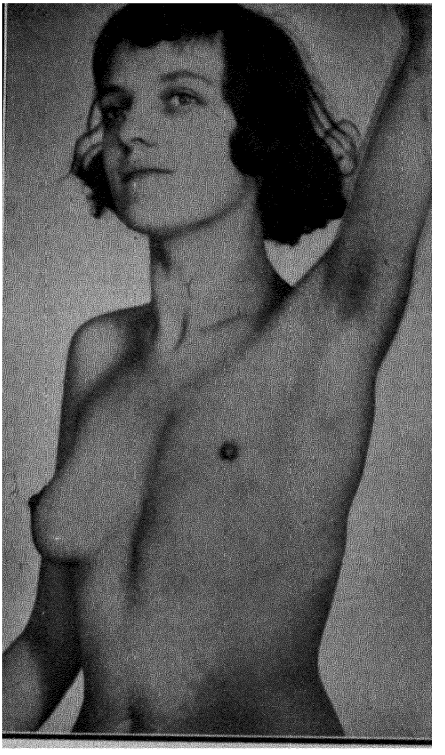

FIG. 731.—ABSENCE OF LEFT BREAST IN A GIRL AGED SEVENTEEN

The nipple is present

Amputation is required in those cases where the whole breast is enormous and contains numerous cysts. In other cases total mammectomy with free transplantation of the nipple and areola may be performed, while in those cases where it is desirable to reduce the size of the breast mammaplasty should be undertaken. Although there are many different forms of operation, the best is that devised by Biesenberger of Vienna, and advocated by Kilner in this country. The Biesenberger operation is as follows: An incision is made round the nipple and areola and the skin undercut. The nipple is then stitched by four sutures to the underlying breast (Fig. 733). A second incision is made down to the submammary sulcus. The large lax skin envelope covering the breast is now undercut in all directions until the whole of the breast is exposed. The greater part of the outer two quadrants of the breast is now removed (Fig. 734). The lower pole of the breast is pulled upwards and rotated inwards and sutured to the upper part of the breast (Fig. 735). The skin flap is now allowed to fall back and the redundant portion [illegible]

for twenty-four hours. There may be some areas of induration and tenderness in the breast for some weeks after the operation, but these gradually disappear. A supporting brassière should be worn for three months after the operation, as it helps in the final moulding of the breast.

Affections of the Nipple.

Fissures of the Nipple (cracked nipples) seldom occur apart from lactation, and may usually be traced to a want of care and cleanliness on the part of the mother, associated with a tender condition of the skin, which might have been prevented by bathing the parts during the later weeks of pregnancy with spirit, so as to harden them. The actual lesion is brought about by leaving the nipples wet after nursing. The superficial layers of epithelium become macerated, and are easily rubbed off, thus exposing the more delicate and sensitive deeper parts, which are irritated and inflamed by the repeated acts of suction. As a result, nursing becomes painful, and if persisted in, the wound may be infected, the inflammation spreading to the breast substance along the ducts or lymphatics, or extending along the superficial lymphatics to the axillary glands.

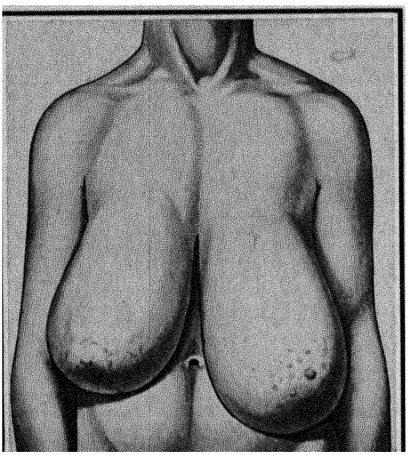

FIG. 732.—DIFFUSE HYPERTROPHY OF THE BREASTS

It occurred in a girl aged sixteen and a half years, and both organs had to be removed. The left breast weighed 9½ lbs., the right breast 9 lbs

Treatment.—The best way to prevent the occurrence of cracks is to bathe the nipples with some dilute antiseptic, such as boric acid lotion, immediately after nursing, and then to dry them thoroughly and apply lanoline, which keeps them soft and supple. When a fissure has formed, the milk should be withdrawn by means of a breast pump and the fissure dressed with cooling or antiseptic lotions, *e.g.* lotio plumbi or lotio acidi borici. Sometimes more stimulating applications are required, such as a solution of sulphate of copper, or even of nitrate of silver. It is also recommended to paint the sore with equal parts of glycerine and sulphurous acid.

Eczema of the Nipple may be of a simple nature, needing nothing but ordinary treatment, or it may take on special features, being then known as **Paget's Disease** (*dermatitis maligna*). This disease was first described by Sir James Paget in 1874, and since that date much controversy has taken place as to the exact pathology of the condition.

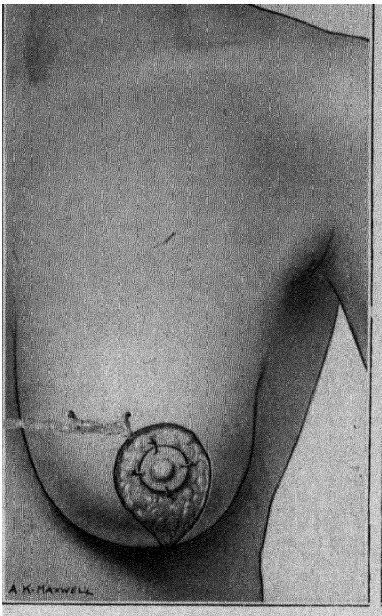

FIG. 733.—MAMMAPLASTY; PERI-AREOLAR SKIN STRIP REMOVED.

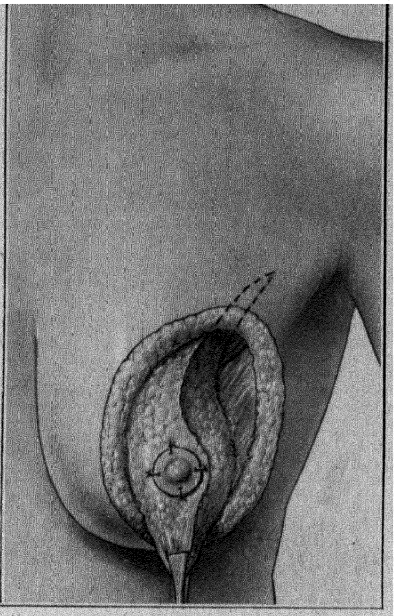

FIG. 734.—OUTER QUADRANTS REMOVED BY 'S'-SHAPED INCISION.



FIG. 735.—RECONSTRUCTION OF BREAST.

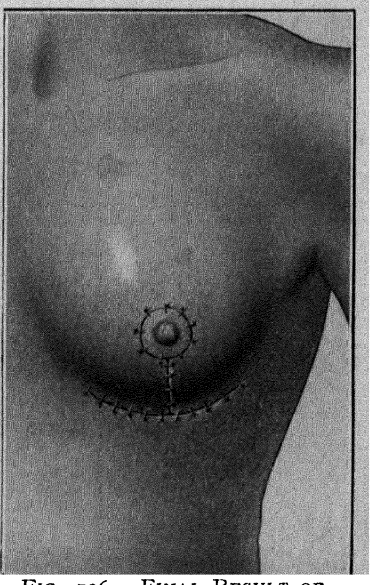

FIG 736 —FINAL RESULT OF MAMMAPLASTY

Inglis of Sydney* has recently written an excellent monograph on the subject, and his views are accepted by most surgeons and pathologists of to-day. Paget's disease is a surface cancer commencing at the junction of the lactiferous ducts with the epidermis. The growth extends down the duct and the surface ulceration is not excessive. The epidermis of the eczematous area is reduced to a layer of a few cells and the dermal papillæ are destroyed. In the dermis the lymphatic vessels are often distended with cancer cells and are surrounded by a round-celled infiltration. Large epithelial vacuolated cells, the 'Paget cells,' are characteristic of the condition. Although the condition may remain limited to the epidermis and ducts for some years, usually a scirrhous cancer forms in the substance of the breast. On clinical examination it presents a smooth, red, raw surface, discharging a yellowish viscid fluid, and may occasionally spread widely beyond the areola (Fig. 732). The projection of the nipple disappears, the raw surface being absolutely flat. Lymphatic glands are not involved, but the associated carcinoma follows its usual clinical course. No local treatment is of any avail, and the disease, when once recognized with certainty, is best treated by radical amputation, including the axillary glands.

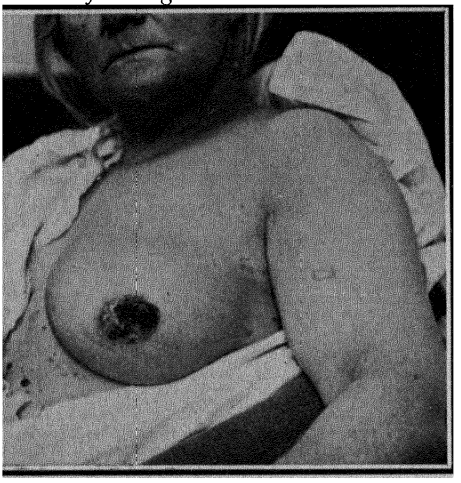

FIG 737.—PAGET'S DISEASE OF LEFT NIPPLE

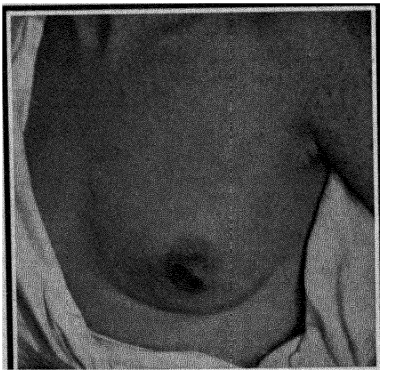

FIG. 738.—CHANCRE OF THE NIPPLE.

Paget's disease is rarely seen in parts other than the breast, but it may occur on the abdominal wall, vulva, cervix uteri, and the glans penis.

Abscess of the Areola is not uncommon in young girls about the age of puberty. It arises in the sebaceous follicles and should be treated by incision.

* Paget's 'Disease of the Nipple.' By Keith Inglis. Humphrey Milford. Oxford University Press, 1936.

Chancre of the Nipple (Fig. 738) is rarely seen in the mothers of syphilitic children (Colles's law, p. 164), but much more commonly in wet-nurses. It usually presents as a shallow ulcerated surface with a well-marked, raised, and indurated border. Not uncommonly the condition is symmetrical. The axillary glands are always enlarged and hard, and sometimes form a large tender mass.

Keratosis of the Nipple is a rare condition in which the nipple is replaced by a warty growth which constantly breaks off. The nipple disappears and is replaced by a depression filled with irregular horny masses. No satisfactory treatment has been discovered as yet, but X-rays may prove beneficial.

Primary Tumours of the Nipple are met with, such as papilloma, sebaceous cysts, and occasionally epithelioma.

Inflammatory Affections of the Breast.

Acute Mastitis is most often observed in *puerperal* women of an anæmic, weakly type, and usually results from a sore or cracked nipple, through which pyogenic organisms find their way into the lymphatics or acini of the breast substance. In the former case the inflammation is mainly interstitial in character, the pus diffusing itself widely between the lobules; in the latter the pus is primarily intra-alveolar. In *non-puerperal* women acute mastitis may result from injury, or may be pyæmic in origin. Occasionally a metastatic inflammation of the breast occurs after the disappearance of the parotid swelling in mumps. The organism responsible for the infection is usually the *Staphylococcus aureus*, but occasionally it is due to a streptococcus.

Under this heading may be included certain conditions which arise out of a disturbance of normal endocrine processes. In this connection may be mentioned **Mastitis Neonatorum,** a condition not uncommon soon after birth. One or both breasts become swollen and tender, and occasionally proceed to suppuration. It is probably due to an active proliferation of the duct epithelium which takes place as a response to maternal œstrogenic influence. No special treatment is necessary unless suppuration takes place, in which case an incision will be required.

At a later period of life the breasts, or a portion of them, may become enlarged, hard, and tender, giving rise to the **Mastitis of Puberty.** The condition subsides after a variable period of weeks or months and should be treated medically.

After parturition great swelling of the breast occurs as lactation develops, owing to the fact that several of the ducts are blocked with epithelial debris. This is termed **Milk Engorgement** and may be accompanied by a rise of temperature. The breast is dusky, swollen, and tender with prominent veins. It should be treated by withdrawal of the milk through a breast pump.

Signs and Symptoms.—An inflamed breast is characterized by the organ becoming swollen, acutely painful, and tender. The gland lobules are enlarged and indurated, and if lactation is progressing the secretion is to some extent impaired; but owing to the inability of

the mother to allow the child to relieve the organ, on account of the pain produced thereby, considerable tension results from accumulation of milk. If suppuration follows, the skin over the breast becomes red and œdematous, and, according to the situation of the pus, three different forms are described: (*a*) *Supramammary abscess* is a collection of pus in the subcutaneous tissues or beneath the nipple; it is often unconnected with the organ, and comes readily to the surface (Fig. 739). (*b*) An *intramammary abscess* is the most common variety, the pus developing within, and distending the lobules, or infiltrating the cellular tissue around them; it is usually diffused widely throughout the organ, and may point at several spots. When very acute, or in debilitated women, especially if it has been allowed to progress without treatment, the inflammatory process may actually determine gangrene of the glandular tissue. (*c*) A *submammary abscess* forms in the cellular tissue beneath the breast. It may spread from the deep lobules, but more frequently results from disease of some of the adjacent ribs or cartilages, or starts as a cellulitis. In these cases the breast is pushed forwards, and becomes prominent, floating, as it were, on a bed of pus. The abscess usually points at the periphery of the organ, perhaps in several places, but most commonly at the lower and outer quadrant.

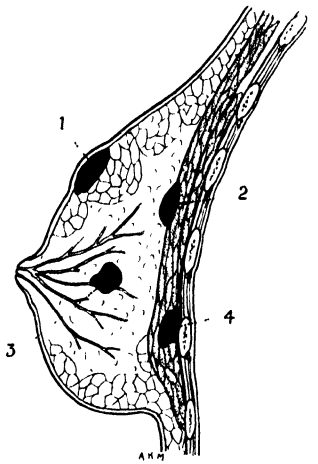

FIG 739.—VARIETIES OF ABSCESS OF THE BREAST

1, Supramammary, 2, submammary; 3, intramammary, 4, retromammary

The **Treatment** of simple acute mastitis consists, in the first place, in supporting the inflamed gland by means of a sling or bandage, and in binding the arm to the side, so as to keep at rest the pectoral muscle, on which it lies. Fomentations are applied, and any tension due to retained secretion is relieved by the breast-pump. The bowels are opened, and the patient placed on a light and nourishing diet.

If the condition quiets down, gentle friction of the part with warm oil or with belladonna ointment is often helpful in completing the process of resolution.

If, however, the part remains hard and swollen, with marked tensive pain and the temperature raised, suppuration is obviously threatening, and the surgeon must not be tempted to wait for the appearance of fluctuation before he opens up the abscess. Persistent œdema under these circumstances is quite sufficient indication that operation is required. Above all, the abscess must never be allowed to burst into or under a poultice, for then chronic suppuration and the formation of sinuses will almost certainly result from the mixed infection thereby determined.

In the *supramammary* variety it matters little in which direction the cut is made, since the pus is always superficial to the breast tissue. In the true *intramammary abscess* the incisions should radiate from the nipple. One or more may be needful, and these should be made with a free hand, so as to allow of the insertion of the finger, and the opening up of any pockets or lobules which are distended with matter. A large drainage-tube is inserted for a time, and gradually shortened day by day, until its entire removal is permissible. When the chief incisions are needed above the nipple, it is often wise to make a counter-opening in the lower half of the breast, and generally on the outer side, to permit of more efficient drainage. With such treatment the best of results may be attained, and it is interesting to note how quickly the contour of the breast is restored, and how slight is the permanent injury inflicted on the parts. The *submammary abscess* is best opened towards the lower and outer side, but also at any spot where pus points.

If discharging sinuses persist after an abscess has burst, their orifices should be enlarged, and their walls thoroughly scraped and disinfected; deep cavities should be efficiently drained and packed with gauze, so as to ensure the wounds healing by granulation; the arm must also be kept to the side.

Chronic Interstitial Mastitis is an affection which occurs not unfrequently in women with small or atrophic breasts, who have passed, or are near to, the climacteric. It is also met with at an earlier age in unmarried women, involving the whole of one or both breasts, or limited in its development to a portion of one breast, and is then sometimes mistaken for a malignant tumour.

Pathology.—A considerable amount of attention has been drawn to this condition during the past few years by Sir Lenthal Cheatle, who was the first to doubt the inflammatory character of the disease. There is little doubt now that the disease is endocrine in origin and due to an imbalanced action of the corpus luteum and the ovarian œstrin. The infiltration by leucocytes, which was formerly thought to indicate an inflammatory origin, is now known to occur normally in pregnancy and lactation. The essential feature in the process is hyperplasia of both the connective tissue of the breast and the epithelium, and it may pursue either a lobar or a lobular distribution. In the former the hyperplastic process is limited to one segment of the breast, giving rise to a swelling which strongly simulates carcinoma, and in the latter it is diffusely spread throughout the whole organ. The diffuse overgrowth of the connective tissue around and between the acini renders the gland hard and knobby. Epithelial proliferation involves both the ducts and the acini; at first the proliferated cells become detached into the alveoli, and collect in small cyst-like spaces to constitute a colostrum-like effusion. Later on, the cells remain attached to their base of origin, and the alveoli may be choked up with this new formation. Another stage consists in the growth of papilliform processes covered by epithelium which grow into dilated spaces. After a time the epithelial cells in any of these forms *may* change their type and become malignant in character, and then penetrate into the connective tissues and constitute a cancerous growth. A certain

amount of fluid exudate occurs within the acini, and may originate cysts in which the content is clear or turbid according to the number of cell-elements present. As a rule many of these cysts are scattered widely through the breast substance, but they are usually small and insignificant; occasionally one of them becomes notably enlarged and simulates a tumour, especially when covered in by a mass of thickened glandular tissue.

Clinical History.—The condition often passes unnoticed in the early stages, until a distinct lump has formed, which is nodular and indurated to the touch, and often very painful. The breast may be somewhat enlarged, and there is, perhaps, some retraction of the nipple, owing to contraction of the interstitial tissue; but this is by no means usual. A scanty serous discharge from the nipple is sometimes noticed. The skin seldom becomes adherent to the swelling, whilst the lymphatic glands in the axilla may be enlarged and tender, but they are never hard. On careful examination of the breast, the affection is rarely found to be limited to one particular region, for although a distinct enlargement of one portion may be present, yet the whole organ feels more or less 'lumpy,' and not unfrequently the other breast participates in the same change. Small, rounded, elastic spots can often be detected, and indicate the presence of cysts. There may be but little pain, although this is sometimes one of the most marked features of the case; it is of a neuralgic type, and usually increased at the menstrual periods.



FIG. 740.—GENERAL CYSTIC DISEASE OF THE BREAST, RESULTING FROM CHRONIC INTERSTITIAL MASTITIS

If left to run its course, the disease may remain much in the same condition for many years, and even in time disappear; but more frequently it slowly progresses, and then results in one of three conditions: (*a*) *General atrophy*, the breast becoming shrunken, hard, and nodular. (*b*) More frequently *general cystic disease* (Fig. 740) follows, a condition in which the organ becomes transformed into a number of cysts held together by dense connective tissue; occasionally a single big ('blue-domed') cyst is formed, giving rise to a firm elastic swelling which is often tender. (*c*) In not a few cases *cancer* is a sequela of this disease; there is abundant evidence to prove that any continued source of irritation in an organ like the breast renders an individual with a cancerous inheritance more liable to its development, especially if it commences at or about the climacteric.

The **Diagnosis** is sometimes easy, but the condition often simulates somewhat closely a scirrhous tumour. The chief points of distinction,

however, lie in the facts (i.) that the whole breast is more or less involved; (ii.) that the opposite organ is very often similarly affected; (iii.) that enlargement of the axillary glands is less common than in scirrhus, and even if enlarged they are not hard, as in the latter disease; (iv.) that the skin is usually free from the mass; (v.) that the tumour is never adherent to the pectoral fascia, nor is it of the stony hardness of a scirrhus; and (vi.) that it is often more disseminated and less defined than a cancerous growth. (vii.) Moreover, on careful palpation with the flat of the hand, it is often impossible to make out any distinct lump, the so-called tumour merging into the surrounding tissues; this never occurs in scirrhus, the growth always being easily detected with the flat of the hand. Small cysts can also be felt as localized elastic spots in the inflammatory mass. Of course it is possible for the two conditions to coexist, for a careful microscopic examination of these breasts after removal often reveals the presence of a cancerous nodule when there is no clinical evidence of its existence.

Treatment—In the early stages, and especially in the younger patients, friction with some sedative application containing belladonna may be used at the same time that the breast is supported. Firm and equable pressure, as by strapping, is also useful in some cases, whilst iodides may be administered. If a hormonic factor is thought to be responsible, œstrin or small doses of thyroid should be given; but, if relief does not follow, great benefit will often be obtained by deep X-ray therapy to the breast. Finally, if a definite tumour is present, or if many cysts can be detected, and especially if the patient is anxious and worried about herself, it is wise to remove the affected portion, or even better to excise the whole breast, especially when there is a family history of malignant disease.

Localized or Encysted Chronic Abscess usually occurs in women who have borne children, and may arise in connection with a retention cyst, or be of the residual type. It is characterized by the formation of an indurated mass in the breast substance, which slowly softens, giving rise to a sense of fluctuation, although when the abscess walls are very thick, as is often the case, this may be difficult to detect. Retraction of the nipple is not uncommonly present, and the axillary glands may be enlarged. The condition may closely resemble a carcinoma, and indeed in not a few cases the breast has been completely removed owing to a mistaken diagnosis. Sometimes, however, it is possible to detect a feeling of elasticity at the centre, which is almost always less resistant than the margin, whereas the opposite is the case with a tumour. When in doubt, the introduction of a grooved needle or an exploratory incision should precede a radical operation. A localized excision is all that is required for the cure of this type of case.

Fat Necrosis is a localized condition of the breast of doubtful ætiology. It is possibly traumatic in about half the cases. The prominent feature is the formation of a hard, painful area within the breast over which the skin may be slightly reddened and, in chronic cases, adherent and retracted. Section shows the hardness to consist of necrotic fatty tissue with much fibrous reaction and a few foreign-

body giant-cells. The condition is usually mistaken for carcinoma or an encysted chronic abscess.

Diffuse Tuberculous Disease of the breast is not very uncommon. Scattered nodules of caseous material are developed in the interacinous tissue, which break down into pus, and come to the surface at various spots. The breast may thus become riddled with sinuses discharging caseous pus. It may be associated with tuberculous disease of the lungs, whilst a like affection may arise secondarily in the axillary glands; possibly in some cases the primary trouble lies in the glands, the breast being subsequently involved.

Treatment should be carried out, if possible, by incision, scraping, and purification of the cavities; but if the tuberculous foci are multiple, it is wiser to amputate the breast.

Occasionally a *chronic tuberculous submammary abscess* forms as a result of disease of the ribs or costal cartilages. It develops slowly, pushing the breast forwards, and is easily recognized, although its cause can only be ascertained by exploration. Aspiration may suffice for its cure, although open treatment may be required for the affected bone.

Syphilitic Diseases of the Breast.—As already pointed out, a primary sore may be met with on the nipple; secondary mucous tubercles, or condylomata, are found in a similar situation or beneath a pendulous breast, whilst superficial and deep gummata have in rare cases formed in the tertiary period of the disease.

Actinomycosis of the Breast.—Primary actinomycosis of the breast is a very rare condition, but several cases have been recorded. Multiple sinuses, retraction of the nipple, and fissuring of the areola are constant features in this disease. Prolonged lactation and recurrent attacks of mastitis of the breast may be predisposing factors.

Local removal of the breast is the best form of treatment, combined with a course of prontosil.

Cysts of the Breast.

When the structure of the breast, its abundance of ducts and alveoli, and its complex lymphatic distribution are considered, it is not surprising that many different forms of cystic change are associated therewith. The following are the more important:

1. **Acinous** or **Retention Cysts** arise, as the name suggests, from some obstruction to the ducts or lobules, whereby the secretion of the organ is unable to escape. They are met with most frequently in women during or after the puerperal period, a milk cyst, or *galactocele*, being then produced. It usually results from compression of one or more of the ducts, connected with a sore nipple, and contains inspissated milk; it forms a rounded swelling and is located under the areola. The wall is lined with epithelium and surrounded by a fibrocicatricial layer, the thickness of which increases with the chronicity of the case. In very old-standing cases the fibrous wall becomes very dense, and may cause retraction of the nipple and puckering of the skin, closely simulating a scirrhus. The condition is treated by excision.

Similar glandular cysts form, as already described, in the course

of chronic interstitial mastitis, and in elderly women are known as *involution cysts*; in long-standing cases general cystic disease of the breast may follow.

2. **Neoplastic Cysts.**—Cystic dilatation of the ducts and lobules frequently occurs in connection with tumours of the breast such as cystadenoma, fibro-adenoma, duct papilloma, and duct carcinoma. In these cases hæmorrhage from the contained growth is often seen giving rise to a blood-stained discharge from the nipple. Cysts are also seen in association with a carcinoma of the breast due either to degeneration of the centre of the growth or to the supervention of a carcinoma upon a cystic mastitis.

3. **Interacinous Cysts** develop in the interstitial tissue of the breast.

(*a*) **Serous Cysts** originate from a dilatation of lymph spaces. They may be uni- or multi-locular, perhaps more frequently the latter. They are lined by a smooth, shiny layer of endothelium, and contain serum, perhaps blood-stained, and in old-standing cases cholesterine; being separate from the gland substance, they never give rise to a discharge from the nipple, and intracystic growths are unknown. They are usually surrounded by a wall of connective tissue which may become exceedingly thick and dense. Occasionally, however, they project under the skin, and if the walls remain thin, fluctuation, and even translucency, can be observed, leading to the condition sometimes badly termed a *hydrocele of the breast.*

The **Diagnosis** of a serous cyst, if the wall is thick, is often a matter of considerable difficulty, as it resembles in many ways a scirrhus. It is recognized, however, by the facts that the growth is incorporated with the breast substance, usually occurring near its under surface; that on careful examination an elastic resistance is transmitted to the fingers, quite distinct from the stony hardness of a scirrhus; that there is no retraction of the nipple and no enlargement of the axillary glands, whilst, as a rule, the patient complains of but little pain. The diagnosis in cases of doubt may be readily determined by inserting a grooved needle, or by an exploratory incision, which should be made of sufficient depth to ensure the thorough division of the mass, for fear that a small cyst surrounded by walls of fibrous tissue, half an inch, or even an inch, in thickness, should be mistaken for a solid tumour.

Treatment.—Such cysts should be removed.

(*b*) **True Hydatid Cysts** are occasionally met with, manifesting the general characteristics described at p. 231.

Radiographic Demonstration of Breast Lesions.—During the last few years the utilization of contrast media in the radiographic visualization of the kidney, the brain, and the gastro-intestinal tract has transformed clinical supposition in those fields into more accurate diagnosis, and now, with the use of thorotrast, the outline of the mammary ducts can be obtained.

Thorotrast is non-irritating and can be introduced into the ducts of the breast by means of a blunt No. 26 gauge needle, as is seen in Fig. 741. The breast must be thoroughly cleansed, as for any surgical procedure, and only sterile instruments and solutions used. A little

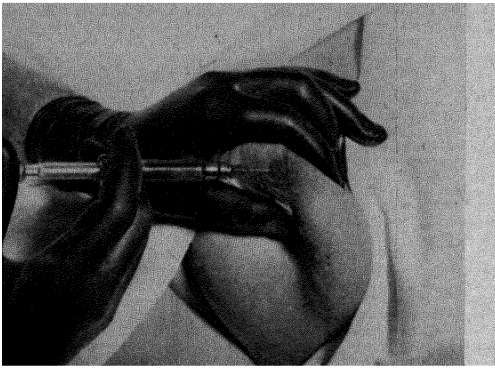

FIG 741 – METHOD OF INTRODUCING THOROTRAST INTO THE MILK DUCTS AFTER CANNULATION OF THEIR STOMATA WITH A BLUNT NO. 26 GAUGE NEEDLE (KODAK LTD)

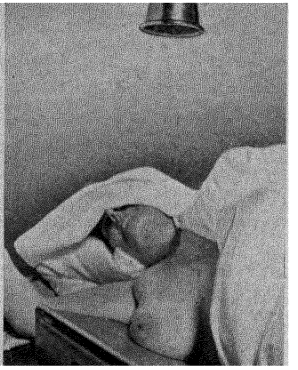

FIG. 742 —POSTURE OF THE PATIENT AND USE OF 23° ANGLE TILTING BOARD TO SUPPORT THE BREAST (KODAK LTD)

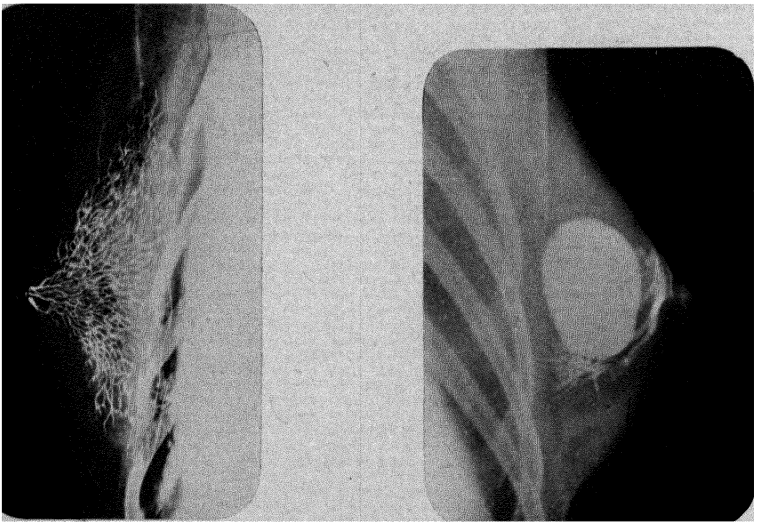

G 743 - MAMMOGRAPH OF A VIRGINAL BREAST IN WHICH FOUR MILK DUCTS WERE INJECTED WITH THOROTRAST (KODAK LTD).

he ducts have a small diameter and are uniformly dispersed throughout the matrix)

FIG 744 — MAMMOGRAPH OF LARGE CYST IN THE BREAST (KODAK LTD).

massage of the nipple will express drops of secretion from the lumina of the lactiferous ducts. About 0·5 to 1·5 c.c. of thorotrast are injected into the ducts, about eight or ten ducts usually being available for this purpose. After the injection the patient is placed in a lateral recumbent position so that the injected breast is supported by a 23 degrees angle tilted board, as is shown in Fig. 742. An X-ray is now taken, and the outlines of the ducts are clearly visible in the skiagram (Fig. 743).

There are a great variety of ductal patterns in the virginal and multiparous breasts, but by repeated study any gross abnormality can easily be detected. The X-ray picture thus obtained may be designated a 'mammograph.'

Cysts of the breasts can be depicted with ease and certainty (Fig. 744), while many malignant tumours can be visualized with the aid of mammographs.

Tumours of the Breast.

In investigating any case of tumour of the breast, the surgeon must never arrive at a hasty conclusion, but only give an opinion as to its nature after careful and detailed examination. Thus, the age and previous history of the patient should be considered, as also the family

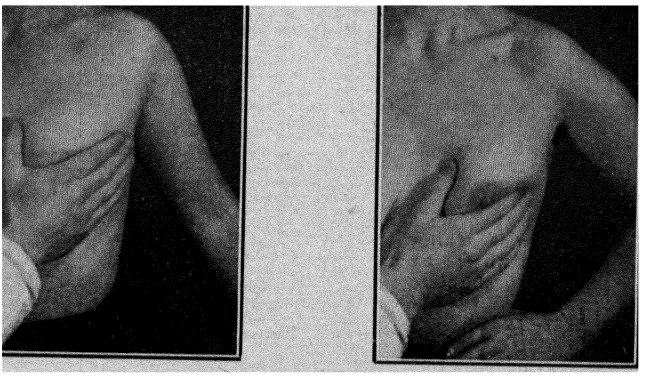

FIG. 745. — EXAMINATION OF THE BREAST WITH THE FLAT OF THE HAND.

FIG. 746. — TESTING THE FIXITY OF A TUMOUR OF THE BREAST.

history. Simple tumours generally arise at an earlier date than the malignant, whilst the sarcomata usually affect younger individuals than the carcinomata. There can be little doubt, moreover, as to the occasional tendency of tumours to run in families. The length of time for which the swelling has been observed should be ascertained, and whether or not it varies in size at the menstrual periods. The general appearance of the patient should be noted, as also the fact whether or not pain, local or neuralgic, is experienced. It is not

unusual for pain to be referred to that part of the shoulder supplied by the posterior division of the second intercostal nerve, the anterior branch of which goes to the breast. A careful inspection of the organ should then be made with the patient sitting and lying down, comparing it with the opposite breast, so that any signs of asymmetry may be noted. Dimpling of the skin, projection of the tumour or of the whole gland, and the situation and condition of the nipple, are the chief points to which attention should be directed. Examination of the tumour with the flat of the hand (Fig. 745), accompanied by gentle pressure of the finger-tips, must then be undertaken; it is not enough to pick up the breast substance between the fingers, as thereby false impressions are obtained. The relation of the tumour to the gland, its shape,



FIG 747 - EXAMINATION OF THE AXILLA FOR ENLARGED GLANDS

The patient's arm is abducted so as to allow the surgeon's fingers to palpate the first intercostal space.

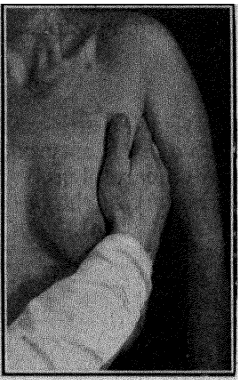

FIG. 748 —EXAMINATION OF AXILLA CONTINUED.

The patient's arm is lowered and the whole of the axilla can then be palpated.

its consistency, whether fluctuating or not, and its mobility on superficial, deep, and surrounding parts, should all be investigated. To this end the breast must also be examined with the patient's hand pressed to the hip, so as to put the fibres of the pectoralis major into action (Fig. 746); transverse movement of the organ across the fibres is always possible, unless the growth is fixed to the thoracic wall; movement in the direction of the fibres is at once limited if the tumour has invaded the muscle, or even if the overlying fascia is seriously involved. Finally, the lymphatic glands in the axilla must be carefully examined (Figs. 747 and 748), as also the supraclavicular glands and the opposite breast and armpit.

The chief types of tumour met with in the breast may be arranged in three groups: the fibro-adenomata, the sarcomata, and the cancers.

A few other conditions have been observed, but are so rare that they need no special description, *e.g.* lipoma, fibroma, chondroma, and osteoma.

Fibro-adenomata of the Breast are the most common innocent type. and occur mainly in two forms, the peri- and intra-canalicular; they are both characterized by the existence of spaces lined with epithelium, which does not extend beyond the basement membrane. The **Hard (Pericanalicular) Fibro-adenoma** (Fig. 749) shows increase in the interstitial tissue between the acini, which, although narrowed, are still in most cases patent. Cellular infiltration and epithelial hyperplasia are frequently present. These tumours correspond to the fibro-adenomata of the older nomenclature, and may be hard or soft according to the character of the stroma. In some cases the fibrous overgrowth is so marked that the ducts get squeezed out of existence and the tumour resembles a pure fibroma. On section the tumour is of a greyish-white colour, becoming pink on exposure to the air, and the cut surface slightly bulging. It is more or less foliated in texture, being compared by Virchow to the section of a cabbage; no juice can be obtained on scraping the cut surface with a scalpel, although on pressure some fluid of a thick glutinous or mucoid nature may escape. The tumour is distinctly encapsuled, except at the one spot, through which vessels enter, and at which it is connected with neighbouring mammary tissue. The **Soft (Intracanalicular) Fibro-adenoma** (Fig. 750) is caused by a marked increase of the cellular

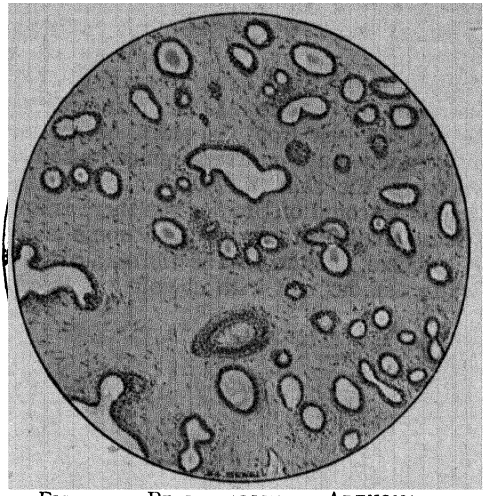

FIG. 749.—PERICANALICULAR ADENOMA

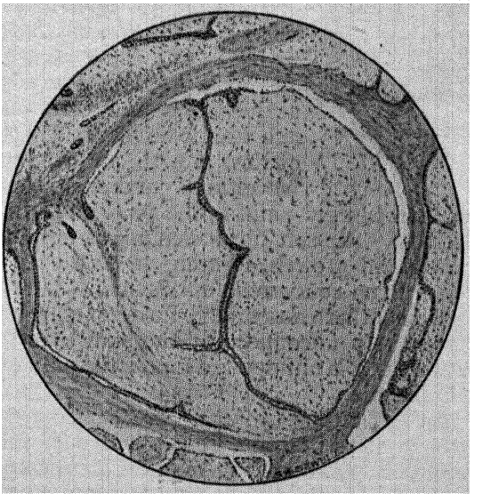

FIG. 750.—INTRACANALICULAR ADENOMA.

fibrous tissue beneath the epithelium, which grows out from the wall of the acinus or duct in papillary masses, which may occlude the lumen or determine cyst formation. The original fibrous stroma remains intact, or is stretched to accommodate itself to the new growth. The tumour is completely encapsulated, but it grows very rapidly and is very liable to undergo cystic degeneration (cystic fibro-adenoma), a condition to be distinguished from cystadenoma, a growth which is cystic from the start. Sometimes these degenerating cystic fibro-adenomata undergo tremendous and rapid enlargement, bursting through the skin, fungating, and giving rise to the so-called sero-cystic sarcoma of Brodie, but there is nothing malignant about them. Occasionally both forms of adenoma are found in the same breast.

Clinical Features.—The fibro-adenoma is the most common mammary tumour met with in young people before the age of thirty; it is often attributed to a blow or squeeze, and doubtless correctly. It occurs as a more or less rounded or oval mass, which, if placed superficially, moves freely in the breast substance, and, indeed, may be described as floating in it (Fig. 751); if situated deeply, it still appears quite movable, but its definition is less evident. Sometimes several such growths are found in the same breast. The hard fibro-adenoma is usually firm and more or less elastic in consistency, of slow growth, and it may be either painless, or in anæmic and neurotic women exceedingly painful, the pain often increasing at the menstrual periods. The soft fibro-adenoma is usually of softer consistency and more rapid growth, forming an elastic and often fluctuant swelling. There is no concurrent enlargement of the axillary glands unless arising from other causes; and no retraction of the nipple, with which it is entirely unconnected; the skin over it does not dimple. The general health is unimpaired unless the patient is suffering from an associated anæmia.

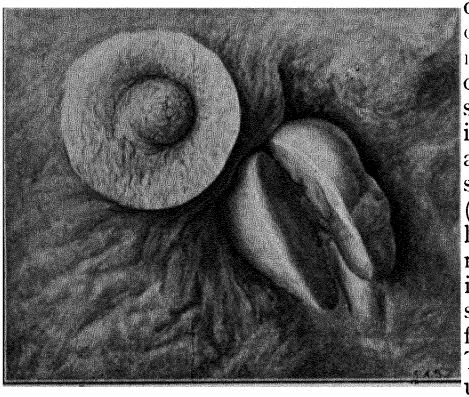

FIG. 751.—PERICANALICULAR FIBRO-ADENOMA MAMMÆ. (ROYAL COLLEGE OF SURGEONS MUSEUM.)

The **Diagnosis** is readily made if the above signs are considered. An adenoma differs from chronic interstitial mastitis or a serous cyst by its exact definition and free mobility, whilst from malignant tumours it is distinguished by its slow rate of growth, and its freedom from adhesions either to the skin or to surrounding parts. In women over forty great care should be taken, as early malignant tumour may be mistaken for an adenoma.

The **Treatment** consists in its removal, which is easily effected by

cutting down upon the tumour in a direction radiating fror
until the capsule is reached, when the mass is enucleated from its surroundings with a few touches of the knife. When the growth is situated deeply in the upper half of the breast, a crescentic incision may be made along the lower and outer border of the organ, and by burrowing upwards the breast can be turned over sufficiently to permit the tumour to be removed from the deep aspect; the scar will be subsequently hidden (Fig. 752).

Cysto-adenoma (*Syn.:* **Cysto-sarcoma, Adenocele, Intracanalicular Adenoma,** etc.).—This rare tumour is characterized by a marked development of intracystic growths within the dilated acini of a newly-formed mass of adenomatous tissue, or within the smaller ducts. It usually has a definite capsule, and then the normal gland tissue may be pressed aside, and perhaps atrophies. Several cysts are, as a rule, present, and may be of great size. The intracystic growths also vary; sometimes there is only one large cauliflower-like mass in a cyst; sometimes there are several smaller pedunculated growths; they are exceedingly vascular, and hæmorrhage into the cavity of the cyst frequently occurs, as also a blood-stained discharge from the nipple. The tumour produced is irregular or lobulated in outline, owing to the projection of the cysts (Fig. 753); it is usually painless, and unaccompanied by enlargement of the axillary glands; if of large size, blue veins are seen coursing over it. In the later stages the capsule becomes adherent to the integument, and finally, owing to the pressure of the tumour, the skin may give way, allowing the growth to protrude. This will be followed by the development of a fungating mass, which bleeds readily, and becomes extremely offensive. With care a probe can be passed between the intracystic portion of the growth and the thinned and stretched skin, which has merely given way, and is not incorporated with it; this fact is a ready means of distinguishing this condition from a fungating malignant tumour. The growth is essentially benign in nature; it is never disseminated generally; and, if completely removed, there is no recurrence. In the early stages it is often unnecessary to take away the entire breast, but in the later stages the whole organ should be excised.

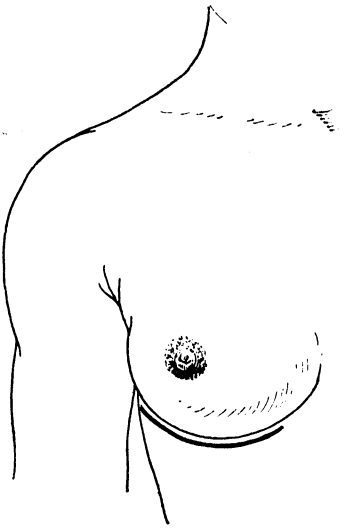

FIG. 752.—DIAGRAM OF THE INCISION FOR REMOVAL OF FIBRO-ADENOMA

Somewhat similar in nature to the above is the condition known as a **duct papilloma.** This is characterized by the development of a soft polypoid papillomatous mass, generally of small size, in the interior

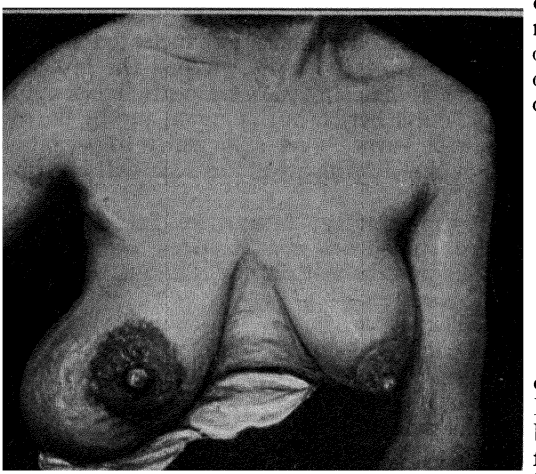

FIG 753.—CYSTO-ADENOMA MAMMÆ

of one of the terminal galactophorous ducts, which in consequence becomes dilated. A charge of blood-ined serum re-ts, and there is ıally no tumour be felt, although nipple may be ;htly pushed for-rds and rendered ıminent. It is en the precursor oı a duct cancer. It should be treated by radium in the first instance, either interstitially or in the form of a plaque; but amputation either in whole or part should be carried out if the condition does not immediately respond to radium.

Sarcoma of the Breast is not a common disease (2 per cent. of all mammary tumours). It originates in the connective tissue of the organ, being deeply placed in its substance, or perhaps more frequently developing in the outer and upper quadrant. It is of two chief types: (*a*) The *round-celled* sarcoma forms a soft, somewhat elastic swelling, which grows rapidly, and, though often limited at first by a fibrous membrane, the capsule sooner or later yields, allowing the growth to become diffused through the organ. It sometimes gives rise to secondary growths in the axillary glands, or becomes disseminated throughout the body by means of the blood-vessels. Myxomatous changes are also not unfrequently observed, and in the more rapidly growing recurrent tumours the mass is often a true myxo-sarcoma. It usually occurs in women between the ages of thirty and forty, *i.e.* somewhat earlier than scirrhus, whilst its rapid growth and the absence

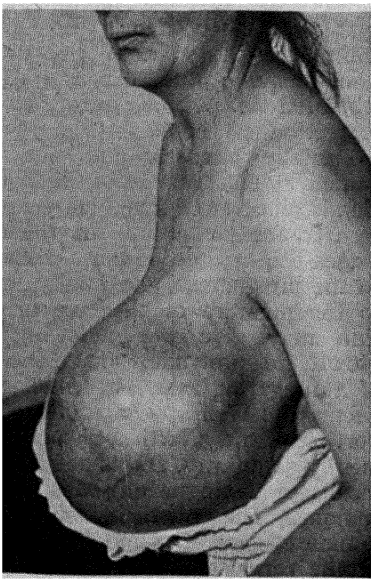

FIG. 754.—SARCOMA OF THE BREAST.



Sarcoma of the Breast

(Museum, University College Hospital)

[*To face page* 1146

of retraction of the nipple or dimpling of the skin are useful diagnostic features. Should pregnancy follow, the tumour may increase in size at an alarming rate. In the infiltration form (Fig. 754) it is difficult to distinguish it from encephaloid cancer, except on microscopic examination (see Plate XIX.). (*b*) A *spindle-celled* sarcoma, or fibro-sarcoma, is also met with, forming a rounded or oval tumour, more limited than the above, and growing less rapidly. It somewhat simulates an adenoma, but is more closely connected with the breast substance. The axillary glands are but rarely involved, and the sarcomatous nature is recognized by the microscope and by the great tendency of the growth to recur even after apparently complete removal; on account of this latter feature, the name of 'recurrent fibroid tumour' (Paget) was formerly applied to it. The recurrences generally take place at gradually diminishing intervals, and the tumour may then become softer and more vascular; occasionally the tendency to recur seems to wear itself out after the performance of several operations. **Treatment** consists in the removal of the entire organ at as early a date as possible, together with the axillary glands, followed by suitable irradiation.

Cancer of the Breast.

No organ of the body, with the exception of the uterus, is more frequently the seat of cancer than the female breast; it also occurs in the male subject, but is about a hundred times less common.

Ætiology.—Cancer of the breast is usually met with after the age of forty, although the disease may occur at a much earlier date. It equally affects women who have borne children and nulliparæ, and the question whether or not the woman has nursed her children seems to have but little influence. The left breast is more often affected than the right. It is frequently attributed to some injury, such as a blow or squeeze.

It may be associated with Paget's disease of the nipple, and chronic interstitial mastitis. Heredity may be a marked feature in some cases, but more often it is a factor of no importance. In about 1 per cent. of cases it occurs in the male.

Two main types of cancer are met with in the breast, *viz.* the spheroidal-celled acinous cancer and the columnar-celled (duct) cancer. The spread of the disease in the breast takes place as it does elsewhere in the body—that is, by local infiltration, by permeation, and embolism along the lymphatic vessels, and by way of the blood-stream. Spread by the lymphatics is the chief mode of extension, and is responsible for the local attachment of the tumour to the skin and deep fascia as well as to the regional lymph nodes in the axilla, supraclavicular fossa, and the mediastinum.

1. **Spheroidal-celled Acinous Cancer** includes the great majority of cases; the division into scirrhus and acute cancer depends clinically on the rate of growth and degree of hardness, pathologically on the greater or lesser amount of fibrous stroma present. Furthermore, either of these types presents further clinical subvarieties. Thus there is

Highland ‡ . جبَلي‡ بلاد جبليَّة . نَجْد
Highlander ‡ من أهل البلاد الجبليَّة ▫ جبلاويّ‡
Highminded‡ واسع الفكر . عالي الادراك*شهْم
Highway ‡ . نبيل . كريم ‡ طريق عموميَّة
King's —, سكَّة سلطانيَّة
Highway-man لِصّ . قاطع طريق
Hilarity هشاشة . بشاشة . خِفّة الروح . بهْجة
Hill تلّ . أكَمَة . هَضْبَة . رابيَة
Hillock تلّ صغير . رابية
Hilly كثير التّلال . كثير الهضاب
Hilt مِقْبَض . قَبْضة . يدّ . نصاب « السيف »
Hilum, Hilus سرَّة . باب (في التشريح)
Hind ايّلة . غزالة * مؤخّر . مؤخري . خلفيّ
Hinder ‡ مؤخري.خلْفي || اخَّر . عاق . منع.صدّ‡
Hinderance, *to* ▫‡ عطّل‡ عائق . مانع
Hindermost, Hindmost آخر . أخير . الاخير
Hindrance, *s.* Hinderance
Hinge مِفصل . مفصّلة * عقب الباب او مَداره * محور
Off the —s, مرتبك.مشوَّش . متضعضع
Hinny ولد الحمارة من الحصان . نَغل
Hint, *at* اشارة . ايماء . تلميح || لمَّح ▫ نوَّه . المَعَ
Hip ورْك . أعلى الفخِذ * ردف.اليَة*حَرْقَفة
— and thigh بعنف.بصرامة * بالباع والذراع
Hip-bone العظم الحرقفيّ
Hippocampus قرن أمون (في علم التشريح)
Hippocentaur, Hippogriff, *s.* Centaur
Hippodrome ملعب الخيل.ميدان لعب الخيل.مضمار
Hippopotamus ‡ فَرَس النهر. فرس اوجاموس
Hire ‡ البحْر . بَرْنيق.عِسنت‡ أُجرة . كراء
Hire || أكْرى . استأجَر . اجر* برطل
Hireling مأجور . أجير. مستأجَر * حادم
Hirsute خشن . أشعَر ▫ مُشْعِراني . ازبّ
Hispanic أسباني . اسبانيولي
Hispid شائك . مشوَّك * اشعر
Hiss صَفير.فحيح*كتّ.ازيز || صفر.فحّ*كتّ.ازّ
Hist! صه ▫ هسّ . اسكُت

Historian مؤرخ . مؤلّف في التاريخ
Historic, —al تاريخي . مختصّ بالتاريخ
History علم التاريخ . تاريخ * سيرة . قصّة
Hit ضرْبَة.صدْمة* اتفاق.مُصادفة || ضَرَب . خبَطَ . لطم*ارتطم.اصطدم*احكم . سدّد * ‡
‡ أصاب «المرمى»‡ احكم البيان.اصاب المحزّ
— off واقق . شاكل
— it off together, (*Coll.*) فتح عليه . انكشف له . عثر على
— upon ورَطة . صعوبة . شبْكة * عَقَبة . مانع ‡
Hitch ‡ || شَبَكَ . عقّد.تعقّد‡ الى هنا . لهنا
Hither حتى الآن . الى الآن
Hitherto خليَّة النحْل . قفير || ادَّخر . اودع * ثوى
Hive جلالته او جلالتها
H.M., His (*or* Her) Majesty خدمة
H.M.S., His Majesty's Service جلالته * سفينة جلالته
(*or* Ship)
Hoar ‡ سيَّج. احاط بسور‡ ابيض . أشيب
Hoard ‡* مخْبأ.كنز || جمع.خزّن. ادَّخر . كنز
Hoarfrost صقيع . جليد . صريد . سقيط
Hoarhound حشيشة السكلب
Hoariness بياض . شيْب
Hoarse اجشّ . أبحّ . مبحوح « الصوت »
Hoary أشيَب . شائب
Hoax اضحوكة.لعْبة|| صحِك من.سخر بر.لعب على
Hob, *s.* Hub
Hobble عرْجة. عرج * حيرة || عرَج . حجَل . خمعَ * قيَّد * عرقل
Hobble-de-hoy
Hobble-te-hoy } مراهق.شاب فتي * غِرّ.أبْله
Hobby باشق*غويَّة.غرَض محبوب ▫ غِيَّة
Ride a —, اكثر من ذكر هوبته * غوى الشيء
Hobby, Hobbyhorse حصان قوي * رهوان
Hobgoblin مارد . غول . بُعبُع
Hobnail مسمار كبير الرأس * جلف . فلاّح
Hobnob
Hob and nob } منادَمة . مشارَبة || نادَم. ناقلَ الكأْس
Hobson's-choice قبول اجباري . اختيار قهريّ
Hock صنف خمر * لحم فخذ الخنزير * عرقوب ‡
Hockey ‡ «الحيوان» || عرْقَب‡ لعب الصولجان

Lavatory مغتسل . محل الاغتسال * غسول * غاسيل
Lave, *s.* Bathe
Lavement حقنة . غسول دوائي للمستقيم
Lavender خزامى . نبات عطري □ لاوندا * ‡ ‡ لون ازرق فاتح ‡ ‡ . حوض . جُرن * طشت ‡
Laver غاسل . غسّال * ميضاءة . ميضاءة * رحضة ‡
Lavish مُسرف . مبذّر . مفرّط || اسرف . بذّر . بعزق
Lavishly باسراف . بتبذير . بافراط
Lavishment } اسراف . تبذير . بذل .
Lavishness } بَعْزقة . تفريط
Law ‡ شريعه . قانون . ناموس . سنة . فريضة * ‡ شَرْع . علم الحقوق ‡
— day يوم انعقاد المحكمة
— of nations القانون الدولي
— of nature قانون الطبيعة . سنة الطبيعة
— of the land شريعة البلاد . قانون البلاد
At —, تحت المرافعة
Go to —, تقاضوا . عرضوا الامر على المحاكم
Have, *or* take the — of, (*Coll*) قاضاه
Limb of the —, (*Coll*) محامٍ . متشرّع
Law-abiding خاضع للشرع . تحت القانون
Law-breaker مخالف الشريعة . ناقض الناموس
Lawful شرعي . قانوني . جائز . حَلال . مُباح
Lawfulness جواز شرعاً . جواز . قانونيّة . اباحة
Lawgiver } شارع . واضع القوانين . مقنّن *
Law-maker } صاحب الشريعة
Lawless عاصٍ . متمرد * غير جائز شرعاً . حرام
Lawlessness عصيان . تمرّد . مخالفة القانون . استباحة
Lawmerchant العرف التجاري * القانون التجاري
Lawn مرْجة . مخضرة * ميدان * شفّ □ شاش
Lawny اخضر كالمرج * منبسط * شاشيّ
Lawsuit دعوى . قضيّة
Lawyer محامٍ . مِدْرَة . متشرّع . عالم بالشريعة . قانوني
Lax غير مضبوط . سائب * ليّن . رخو . مرتخٍ * متراخٍ . متساهل * مُسهَل . سائب البطن * اسهال
Laxation ارتخاء . رخوّ * ليْن . اسهال * تساهل
Laxative مُسهل خفيف . مليّن
Laxator مُرْخٍ . راخٍ * عَضَلة راخية
Laxity } ارتخاء . تراخٍ . رخاوة * تساهُل *
Laxness } عدم تدقيق او دقة . عدم ضبط

Lay قصيدة . نشيد * علمانيّ . عامي || وضع . حط . القى * رتّب * بسط . مدّ * قدّم
— aside ادّخر . وضع جانباً * ترك . تخلى عن . القى عنه
— a wager راهن . شارط
— bare عَرّى . جرّد من « الملابس وغيرها »
— before عرض على . قدّم الى
— by جمع . ادّخر □ وفّر . خبّأ لحين الحاجة
— down ترك . سلّم لغيره * كتب . رسم . خطّ * حطّ
— eggs باضت . وضعت بيضاً
— hands on قبض على . مسك . القى الايدي على
— hold of امسك . قبض على . القى القبض على
— in جمع الشيء لاستعماله قريباً * تموّن
— low دفن . وارى في التراب * خفّض . وطّأ
— on ادخر . خزن * ادخل . قدم
— it on بالغ . اسرف . افرط . تطرّف
— open فتح . كشف . اظهر . عرض * فضح
— *himself* open استهدف . جعل نفسه عرضة
— out انفق . صرف * ثمّر المال او استثمره او وظّفه * كفّن * رتّب
— *himself* out for عَكَف على
— to صلّب المركب * اوقف السير * احجم .
— together توقف * تأكد او تيقّن من الامر * اجتهد
— under جمّع . جمع . ضم « الى بعض »
— up جعله تحت كذا . الزمه بكذا * عرض لـ
— upon ادّخر . حفظ لحين الحاجة * لزم فراشه
— wait for بسط على . مدّ
— waste كمن . ترصّد
A — brother خرّب . دمّر . اتلف . اعدم . اهمل
A — figure راهب غير مرسوم
بائعي الملابس » □ مَنيكين * آلة صماء
Layer طبقة □ راق . صفّ * مدماك * ترقيدة
Layering ترقيد (في الزراعة)
Layman علماني . عامي . من العوام
Lazar شخص مصاب بمرض معدٍ . مبتَلى * ابرص
— house } مستشفى الامراض المعدية او
Lazaret, —to } الوبائية * محجر صحّي

the usual scirrhus and what is termed atrophic scirrhus; the acute cancer presents the encephaloid and lactational types, while all varieties may undergo colloid or cystic degeneration.

Scirrhus is usually first seen as a hard circumscribed mass, situated most commonly in the upper and outer quadrant of the organ. It is closely united to, if not absolutely incorporated with, the breast substance, and on careful digital examination its margin is quite indefinite. In the early stages it is entirely distinct from the skin, which moves freely over its surface; but as growth proceeds the stroma contracts, and, by dragging on the suspensory ligaments of Cooper passing from the glandular substance to the skin, the latter structure becomes more or less fixed, and hence, on attempting to move it upon the tumour, an appearance of dimpling results. At the same time

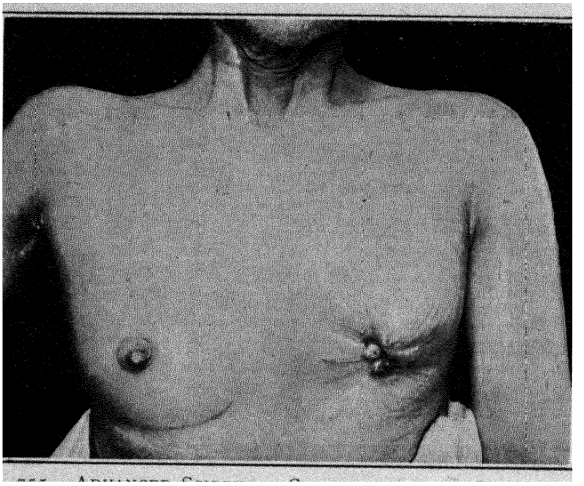

FIG 755.—ADVANCED SCIRRHOUS CARCINOMA OF THE LEFT BREAST
The retraction of the nipple and the shrinking of the breast are well seen.

the whole breast is acted upon in a similar manner, so that the affected organ sometimes seems to be smaller than the other; and, since the upper half of the gland is usually affected, the nipple may be drawn up so as to lie at a higher level than its fellow, as well as being retracted from the drag of the growth on the galactophorous ducts (Plate XX.). The tumour itself is rarely of great size and is usually quite painless. Occasionally it is tender and in the later stages may be painful, the pain being of a neuralgic type, extending to the shoulder, and perhaps elicited only on manipulation. As the growth increases in size it becomes adherent to the pectoral fascia, and may even infiltrate the underlying muscular substance, so that on examination, with the pectoral muscle contracted, it is found that, although movable across the fibres of the muscle, the breast cannot be moved with them (Fig. 755).

Histologically the columns of cells are surrounded by a dense stroma of fibrous tissue (Fig. 756).

In elderly women a chronic form of cancer is met with known as **Atrophic Scirrhus,** in which the disease lasts for many years without much definite extension. Cases have been known to persist for fifteen or twenty years, the patient at length dying of some intercurrent malady, although in the great majority dissemination has ultimately occurred. The special characters are due to the excessive contraction of the stroma as a result of which the cellular elements become crushed and practically destroyed. The nipple is deeply retracted, and the tumour and breast substance in the most marked cases are scarcely discernible.

The *lymphatic glands* in the axilla soon become enlarged, the disease rarely lasting many months without this complication. Those running with the long thoracic vessels under cover of the pectoralis major are first involved, and, as the case progresses, the remaining axillary and subscapular sets become similarly affected, and even, after a time, the supraclavicular. When the inner or deeper part of the breast is attacked, the disease may spread to the mediastinal glands along the lymphatics, which accompany the nutrient vessels arising from the internal mammary trunk; and thus intrathoracic deposits develop, which even extend along the subpleural connective tissue, and affect the pleural cavity and lungs.

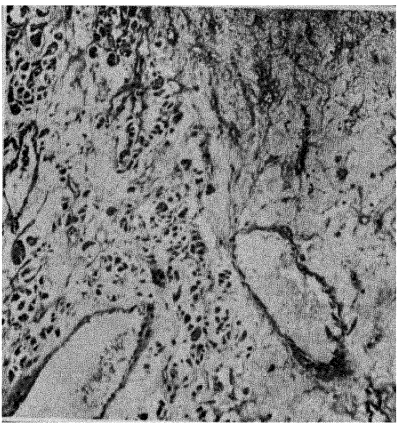

FIG 756.—MICROPHOTOGRAPH OF SPHEROIDAL CELL CARCINOMA OF THE BREAST (×82)

It is also from these intrathoracic deposits that involvement of the supraclavicular glands very often occurs. Hence enlarged glands in this region spell a bad prognosis. In those cases where the primary growth is situated near the inner border of the breast, the free lymphatic anastomosis across the middle line allows of the transmission of the disease of the glands in the opposite axilla, and sometimes a similar affection of the opposite breast arises from this cause.

The *skin* may be implicated in many ways: (*a*) The dimpling which is met with over the tumour in the early stages has already been mentioned. As the case progresses the cancer extends outwards along the suspensory bands of fascia, so that the skin itself becomes invaded, feeling firm and brawny, and looking congested and purplish in colour, whilst a branny desquamation is usually present. A crack or fissure at length forms, giving exit to a little serous discharge, which

at first scabs over, but finally leaves an ulcerated surface, which slowly extends, and may attain considerable dimensions. A typical *scirrhous ulcer* is hollowed out and excavated; its surface, if kept clean, is covered with smooth granulations, discharging a considerable amount of sanious fluid, but if neglected, it becomes sloughy and offensive; it is surrounded by a projecting elevation of the tumour substance, forming a sort of rampart around it. (*b*) Less commonly the disease becomes disseminated through the lymphatics of the skin, giving rise to a series of firm cord-like thickenings radiating from the nipple (Fig. 757). The skin itself is thickened and firmer than usual, so that it is impossible to pinch it up, and has an appearance like 'pig-skin,' or the rind of an orange (*peau d'orange* of French authors). This condition of *peau d'orange* is due to an œdema of the lymphatics of the skin due to their being blocked by tumour cells. The pitting occurs when the epidermis is anchored by hair follicles. Later the colour becomes dusky, and numerous button-like nodules of cancer develop here and there; the sebaceous glands may exude an abundant secretion, which becomes inspissated on the surface into crusts or scabs, which are independent of any ulceration. This process often extends widely beyond the limits of the breast, invading the whole thoracic wall, and even running over the shoulder to the back of the head or neck (cancer *en cuirasse*); in its most typical form it is slow in development, the patient perhaps living for many years. (*c*) Occasionally one meets with a much more rapid form of cancerous lymphangitis, in which the skin becomes affected with what is supposed to be a 'weeping' eczema; the surface is red, hot, and infiltrated, and on examining it with a lens the dilated lymphatics can be seen from which the secretion oozes. The process spreads widely and rapidly, and cancerous nodules appear here and there in the infiltrated area; the prognosis is, of course, very grave.

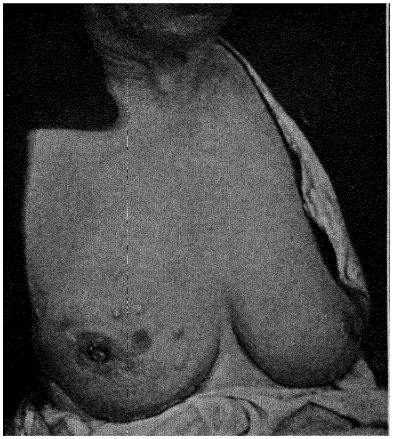

FIG. 757.—CARCINOMA OF RIGHT BREAST
Retraction of the nipple, an area of *peau d'orange*, and outlying secondary nodules are shown

In the later stages the patient passes into a state of cachexia, becoming emaciated and exhausted. Ulcerated surfaces of considerable size may exist, and the tumour is fixed to the thoracic wall, even invading the ribs. The arm on the affected side is swollen and brawny, owing to the pressure of enlarged glands on the main lymphatics and veins of the limb, constituting a condition of solid or lymphatic œdema

PLATE XX

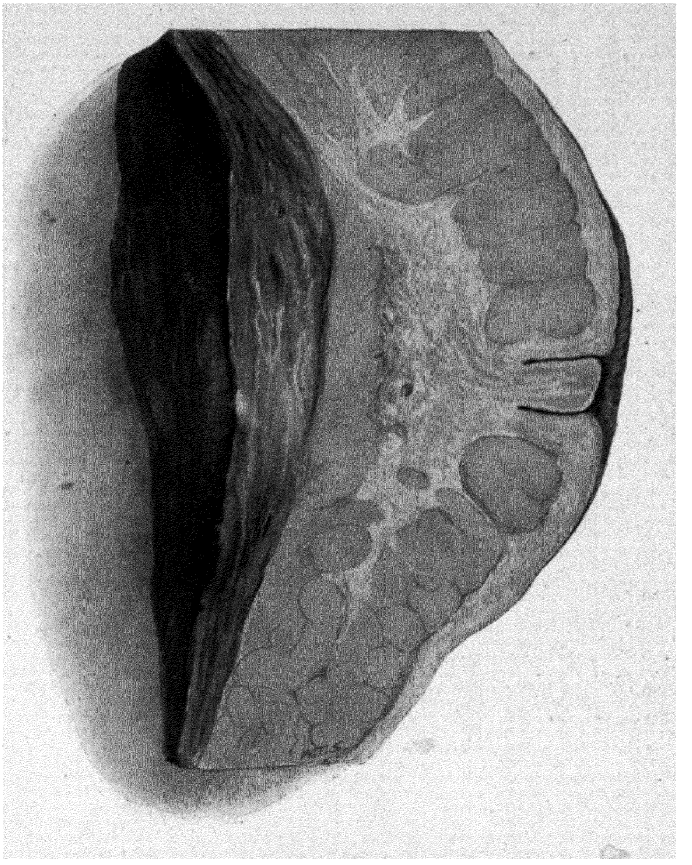

Carcinoma of the Breast
(*King's College Hospital Museum*)

[*To face page* 1150

(Fig. 758). Severe neuralgic pain of the arm results from involvement of or pressure upon the brachial nerves in the supraclavicular fossa.

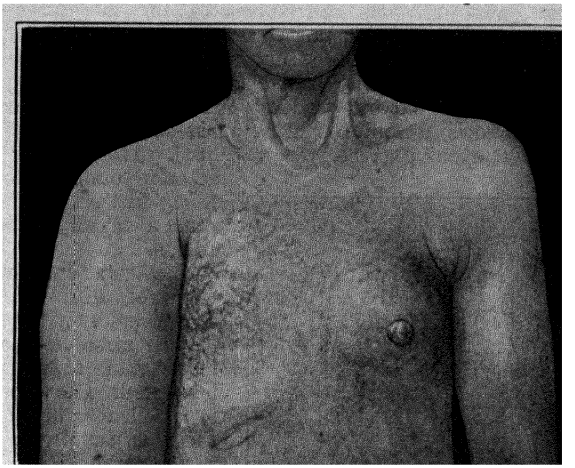

FIG. 758.—ŒDEMA OF THE ARM IN CANCER OF THE RIGHT BREAST. The breast has been removed, and a recurrence taken place

Secondary deposits develop in the viscera, especially the pleura, lungs, and liver. Not unfrequently the connective tissue between the rib cartilages and the pleura is invaded, and nodules of growth develop, which may in time project forwards through one of the intercostal spaces (usually the second). Deposits in the bones are also not unusual, the sternum, ribs, vertebræ, and upper ends of the femur and humerus being most often affected. Severe pain is caused by such lesions, followed perhaps by spontaneous fracture, which may heal effectively or remain un-united. Finally, death from exhaustion ends the scene.

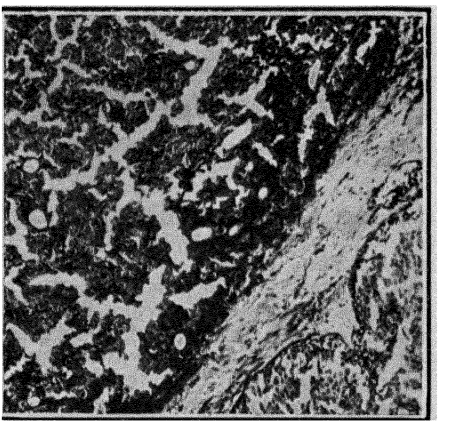

FIG 759.—MICROPHOTOGRAPH OF ENCEPHALOID CARCINOMA OF THE BREAST (×82)

Acute Encephaloid Cancer is fortunately not common, and appears as a somewhat soft, rapidly growing tumour, which quickly infiltrates the whole organ,

and gives rise to secondary lymphatic and visceral affections at a much earlier date than scirrhus. Histologically the stroma is scanty, the epithelial cells are spheroidal or in places almost columnar (Fig. 759). It does not cause retraction of the nipple or dimpling of the skin, the latter structure being distended, with blue veins coursing under it. The breast becomes enlarged and prominent, the skin is stretched and gradually invaded by the tumour, and, if ulceration follows, a foul fungating mass sooner or later sprouts up through the opening (Figs. 760 and 761). This variety usually attacks young women under thirty-five years of age, and runs a rapidly destructive course.

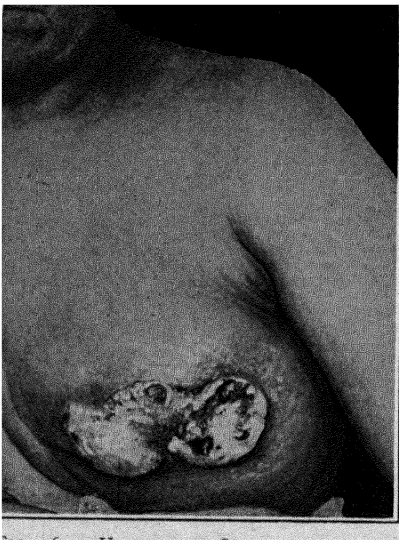

FIG 760.—ULCERATIVE CARCINOMA OF THE LEFT BREAST.

The **Lactational Carcinoma** is a more diffuse variety of the encephaloid type, seeming to involve the whole breast almost as soon as it is noticed. The whole breast is swollen and hot, and there is usually a rise in temperature. The condition, which is rare, is generally mistaken for acute mastitis and incised.

2 **Duct Cancer** is a somewhat rare form of the disease, the exact nature of which is still uncertain, and there is very little doubt that several distinct types have been described under this name. It is sometimes characterized by the development of one or more nodules of a malignant papillomatous nature within the dilated ducts, and usually situated not far from the nipple. It also, not uncommonly, supervenes upon a simple benign duct papilloma. These growths are covered with columnar epithelium, and may, indeed, be looked upon as forms of columnar cancer. They are exceedingly vascular, and a blood-stained discharge from the nipple is usual. They always grow slowly, and when situated near the skin give rise to a round dusky red swelling. The nipple is not retracted. It seldom gives rise to puckering of the skin, and lymphatic enlargement is not constant. In other cases the dilated alveoli are occupied by masses of proliferated epithelial cells of a spheroidal type, which arrange themselves into more or less definite papillomatous growths, whilst cystic degeneration also occurs. Either of these varieties may be associated with a development of ordinary scirrhus in some other part of the breast.

The diagnosis can be established with certainty only by microscopic examination.

Adeno-carcinoma is the term given by Halstead to a condition very similar to the latter variety of duct cancer. The growth consists of tubular spaces heavily lined with epithelium, it develops slowly, but frequently fungates through the skin and presents as a localized pedunculated growth, which readily bleeds. The axillary glands are usually free from infection, and the prognosis is good.

The **duration** of cancer varies considerably in the different forms. The encephaloid type runs a rapid course, and will probably destroy the patient's life in six to twelve months. Duct cancer is very slightly malignant, whilst atrophic scirrhus is similarly slow in growth, and in both death may be postponed for a considerable period, or is often

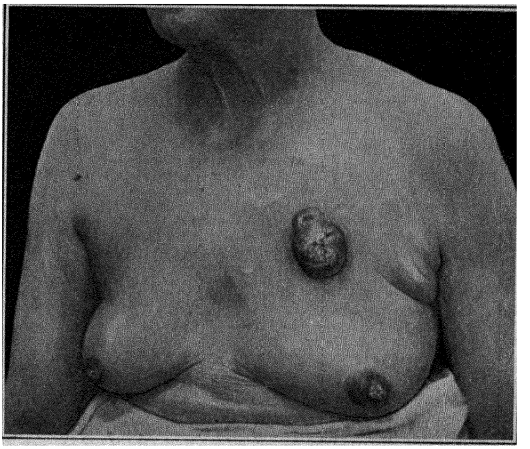

FIG 761.—CARCINOMA OF THE LEFT BREAST

The growth is seen at the upper edge of the breast ulcerating through the skin

due to some intercurrent malady. Cancer *en cuirasse* is variable in its course, being sometimes tolerably rapid, and at others chronic; it cannot be cured by operation on account of its early and extensive dissemination. A circumscribed scirrhous tumour is stated to end fatally, on an average, in two or three years if no operative treatment is undertaken. A rough clinical guide may be obtained by dividing the course of the growth into four periods of seven to nine months. During the first period there is a lump which is painless and not fixed. In the second period the lump is usually fixed to the deep fascia, but regional lymph glands are not enlarged. There may be slight tenderness In the third period the lump is fixed, glands are enlarged, and pain may now be a feature. In the last period metastases develop.

Colloid degeneration is not uncommon in carcinomatous growths of the breast, and in some is so marked that the title colloid carcinoma has been applied to them (Fig. 702). It is difficult at times to recognize the histological structure of such a cancer owing to the degeneration of the epithelial cells. At other times cystic degeneration may occur, but is not at all common.

The **Pathological Anatomy** of cancer is discussed at p. 221.

The **Diagnosis** of scirrhus from *chronic interstitial mastitis* and *chronic abscess* has been already considered. From *the adenomata* it is easily distinguished. The stony hardness of a scirrhus, its incorporation in the breast substance, its limited mobility, the dimpling of the skin, retraction of the nipple, and enlargement of the axillary glands, are the chief local characteristics to be noted. Non-malignant tumours are more elastic to the touch, more movable, and usually circumscribed in outline, whilst the skin, though expanded, does not become adherent; the nipple is rarely retracted, and the axillary glands remain normal. It is important to regard any hard or ill-defined lump in the breast of a woman over thirty-five years as being a cancer until proved otherwise. It is often impossible to distinguish a *sarcomatous tumour*, except on microscopic examination; it is usually more circumscribed—at any rate in the early stages, and is more defined in outline, does not cause retraction of the nipple or dimpling of the skin, and lymphatic enlargement is not constant. A *cysto-adenoma* presents no difficulty in diagnosis if the skin is entire and the cysts prominent, but when ulceration has taken place and a fungating bleeding mass protrudes, it is not unlike the later stage of an encephaloid cancer or a fungating round-celled sarcoma. It can be distinguished, however, by the fact that a probe can sometimes be passed under the skin for some distance between the tumour and the skin, and that lymphatic enlargement is rare.

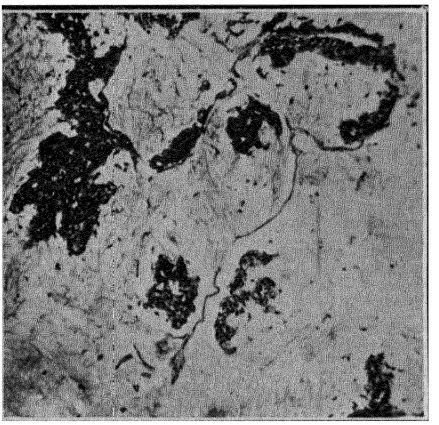

FIG. 702.—MICROPHOTOGRAPH OF COLLOID CARCINOMA OF THE BREAST (×82)

Treatment must be considered under two heads, according to whether it is undertaken by operation or by radium

Operation should be employed in all cases where there seems a reasonable chance of eradicating the disease, although certain surgeons are in favour of treating all cases with radium The contra-indications for operation are extensive adhesion to the thoracic walls, the presence

of visceral deposits, and the extension of the disease to the supra-clavicular lymphatic glands or to any on the other side of the body. In addition the encephaloid and lactational cancer or the presence of cancer *en cuirasse* or fungation suggest treatment by means of radio-therapy rather than surgery. Œdema of the arm and pain due to involvement of the brachial plexus also form contra-indications to operation. Atrophic scirrhus is often left alone in very old people, on the plea that the prognosis is so favourable as to render treatment unnecessary; if the patient is fairly strong, however, there is no objection to operation, and it certainly seems wise to remove a cancerous focus, however chronic it be. Speaking generally, rapidly growing tumours in vigorous patients are very unfavourable cases to deal with, whilst slow growth of the tumour and definite limitation of its outline are favourable signs.

In the old days, if 5 to 10 per cent. of the patients were free from disease it was thought to be as much as any surgeon could reasonably expect. Since we have learnt more of the anatomy of the organ and of the evolution of the disease, more extensive proceedings have been undertaken, with a gradual amelioration in the results, so that several surgeons have been able to report 70 per cent. five-year cures of Stage I. cases, *i.e.* cases in which the growth was not fixed deeply and there was no enlargement of the regional lymphatic glands. The percentage of five-year cures falls to 10 or 15 per cent. when Stage II. cases are considered, *i.e.* cases in which the axillary glands were involved, but the growth was not fixed deeply. In the more advanced Stage III. cases the number of five-year cures due to surgery alone is very poor, probably not more than 5 per cent.

The breast is a much more extensive organ than was formerly supposed, its lobules extending upwards nearly as high as the clavicle, outwards into the axilla, and for some distance downwards, so that removal merely of the prominent part of the gland may leave much behind, and thereby favour recurrence. Moreover, the deeper lymphatics pass into the fascia covering the pectoralis major, and so to the axilla, hence this muscle should always be removed, though some surgeons advocate leaving the clavicular portion. It is best to remove also the pectoralis minor muscle, as when this is left a proper dissection of the axilla cannot be undertaken. The subsequent movements of the arm are very little interfered with by these procedures. Again, lymphatics travel along the fibrous bands reaching from the breast tissue to the overlying skin, and thus this latter must never be dissected back from over the tumour. The nipple should under no circumstances be left behind, as it is part of the breast, and all the interlobular lymphatics converge to a plexus round it, and thence pass to the axilla by three or four main branches. In every case the axilla should be cleared of its lymphatic contents, since deposits in the glands are often found on microscopic examination where no clinical evidence of their presence had been previously noted. It is also important to remove the breast and axillary tissues in one piece, so as to avoid division of the lymphatics and possible infection of the wound with their cancerous contents.

Operation for Cancer.—The patient lies on the back, with the head directed towards the opposite side, and the arm raised and held to a little more than a right angle. The field of the operation is protected from the patient's face and the anæsthetist by sterile towels. The axilla should be previously shaved and the skin purified. The incisions employed vary with the size and position of the tumour; the primary object is to remove the growth together with the whole gland and all its accessible lymphatic connections; the question of being able to close the wound subsequently is secondary. As a rule, sufficiently wide undercutting will allow very extensive wounds to be closed; but when this is impossible, skin-grafting can be adopted, and no lengthy convalescence need ensue.

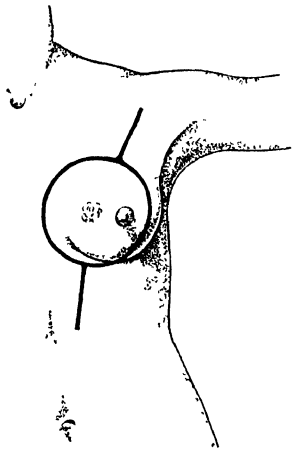

FIG. 763.—DIAGRAM TO SHOW THE INCISIONS IN THE RADICAL OPERATION FOR CARCINOMA OF THE BREAST (AFTER SAMPSON HANDLEY)

In planning the incisions, the growth should be taken as the centre, and a circle with a diameter 4 to 5 inches made; it is convenient to prolong the upper and lower portions upwards towards the axilla and downwards towards the epigastrium, so as to secure a straight line for the final suture (Fig. 763). The upper incision is prolonged towards the axilla, and runs up and curves down towards the insertion of the pectoralis major to the humerus.

The dissection of the axilla is started first in order to avoid an unnecessarily prolonged exposure of the chest wall. The skin flaps are undercut and retracted; a transverse incision in the fascia at the level of the insertion of the pectoralis major is made, the cephalic vein identified, and the anterior border of the latissimus dorsi exposed. The upper, lower, and lateral limits of the axillary dissection are thus defined. The pectoralis major is divided close to its insertion, and retracted inwards. The axillary fascia is incised so as to expose the axillary vein, and the dissection is then carried upwards and inwards towards the clavicle. The clavicular attachment of the pectoralis major is divided, and the insertion of the pectoralis minor severed close to the coracoid; by drawing these down the axillary contents are exposed, and can be dissected away from the axillary vein, together with the lymphatic area running up under the clavicle. Care is taken to identify and preserve the nerve to the latissimus dorsi and the nerve of Bell, which are exposed in the posterior part of the wound. Hot saline packs are placed in the axillary wound.

The lateral skin flap is then undercut, and the whole breast and axillary contents are drawn over towards the middle line, the dissection is carried forwards and inwards, starting from the outer border of the latissimus dorsi. The inner aspect of this muscle is cleared as well as the axillary surface of the subscapularis. The subscapular nerves are

identified and protected, and some branches of the subscapular vessels may need ligature. The serratus magnus can then be denuded of the overlying fascia, care being taken to secure branches of the intercostals, and finally the attachments of the pectoral muscles to the ribs and sternum are divided from below, anterior and lateral penetrating branches of the internal mammary vessels being ligatured. The mid-line of the sternum is thus reached, a portion of the rectus sheath being included in the dissection. The breast is then turned back to its original position, and the medial skin flap is dissected up across the middle line, the advantage of doing this step last being that the vessels have already been secured in the deep dissection. A few strokes with the scalpel then separate the fascia in the sternal mid-line, and the breast and axillary contents are removed. Great care is taken with hæmostasis, as there is considerable oozing from such a large raw area. A drain is introduced into the axilla through a stab-wound for twenty-four to thirty-six hours. The skin flaps are drawn together with tension sutures, and the wound closed. In dressing the case, it is advisable to place extra pads of wool in the axilla and under the clavicle, so that their presence may assist in the prevention of oozing. The arm should be kept at an angle of 45° away from the trunk, so as to allow the skin flap to fall against the chest wall; this does not interfere with the subsequent free movement of the arm.

Local Recurrence after Operation is always due to incomplete removal of the growth or to infection of the wound with cancer cells during the operation. The recurrence appears either in the neighbourhood of the cicatrix, the most usual situation, or in adjacent glands, in the other breast, or in the retrocostal connective tissue.

Treatment with Radium.—This method has come into prominence lately, and with a more satisfactory technique holds out a greater promise of cure than previous attempts suggested. Radium is advisable for the following types of cases:

(1) All inoperable cases, whether by reason of fixation to the chest wall, fixity of glands, or too great involvement of the skin.
(2) Cases with enlargement of the supraclavicular glands or involvement of the lymph glands on the other side of the body.
(3) For the encephaloid and lactational types, for cancer *en cuirasse*, fungation, etc.
(4) For all recurrences.
(5) When the growth is in the two inner quadrants of the breast.
(6) When the patient is unfit for a radical operation.

The **technique** consists in the use of a large number of needles, with small amounts of radium, planted in and around the disease, and retained for a long time. The primary growth is intensely radiated, as are the secondary growths, in the lymphatic glands. The possible lines of extension of the growth are also treated, and, inasmuch as the influence of the radium can spread to areas inaccessible to the scalpel, such as the intercostal lymphatics, a wider area can be treated than is practicable by excision.

The case is prepared as for operation, and the skin purified. The

insertion of the radium can be undertaken under either local or general anæsthesia.

The needles are prepared as already explained (p. 312). The area of the primary growth is treated first. Needles containing 2 or 3 mg. of radium are inserted into the tumour in the form of two concentric circles, or they can be placed between the growth and the pectoral fascia in parallel lines, with slight overlapping to compensate for the 'dead ends' of the needles which are not completely filled with radium. This method is far superior to the concentric, as the radiation is evenly distributed and the possibility of a central necrosis of tissue

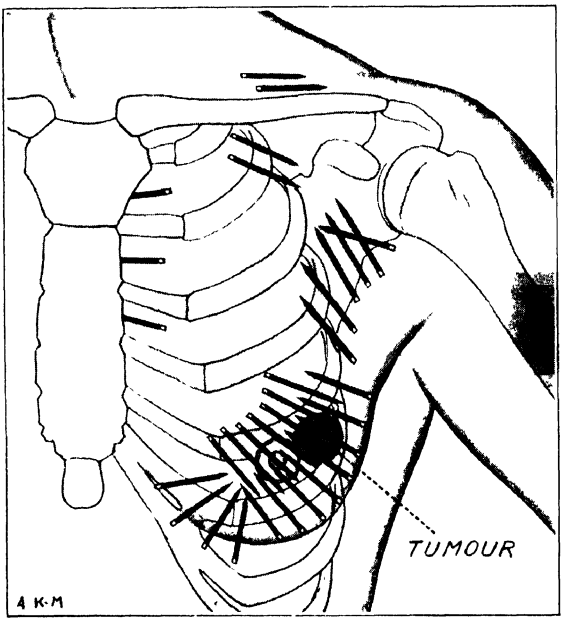

FIG 764.—DIAGRAM TO ILLUSTRATE THE TREATMENT OF CARCINOMA OF THE BREAST WITH RADIUM

is very much reduced. Accessory to these, needles are introduced as follows: (1) Needles of 2 mg. into the periphery towards the sternum, and also into the four upper intercostal spaces; (2) needles of 2 mg. into the axilla parallel with the axillary vessels, and needles of 3 mg. towards the axillary apex; (3) a row of needles of 2 mg. just anterior to the mid-axillary line, and another similar group along the lateral pectoral border; (4) needles of 2 mg. are inserted through the pectoral muscle into the costo-coracoid membrane, so as to influence the infra-clavicular region; and, finally, (5) a series of 3 mg. needles is placed parallel to and above the clavicle, so as to deal with the supraclavicular region (Fig. 764).

In all about thirty to forty needles containing about 60 to 100 mg. of radium are employed. If the needles are conical pointed, a small incision has to be made for the introduction of each one, whereas if the needles are trocar pointed no incision is necessary. The threads are arranged in series and knotted. A dressing is placed over the area and strapped firmly in position. The needles are removed on the tenth day, the total dose being about 14,000 to 21,000 mg. hours. Patients complain of a certain amount of pain and discomfort during the first days, and may require sedatives. It will be understood that each case is treated on its merits, some requiring a larger dose of radium in one area than in another, according to the site of the primary growth and its more obvious lines of extension (Fig. 765). It must also be remembered that damage may be done by the physical pressure of the needles unless due care is exercised; thus in dealing with the left breast, needles introduced too vertically into the intercostal spaces may perforate the pericardium or even the heart.

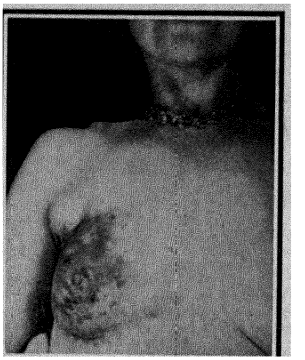

FIG 765.—ADVANCED CARCINOMA OF BREAST AFTER THE REMOVAL OF RADIUM NEEDLES

The patients are usually able to leave the hospital after fourteen days, and should be seen weekly. At the end of a month an opinion can be formed as to the success of the treatment. If signs of activity persist, further treatment is required, and may be undertaken by means of deep X-ray therapy or by means of two Columbia paste jackets, one for the front and one for the back. About 100 mg. of radium are distributed over the jacket between two layers of plaster. The front and back are irradiated alternately for twelve hours each for fourteen days.

Amputation of the breast for *non-malignant* conditions is a very different operation from that described for cancer. The incisions usually employed are crescentic and placed obliquely; they need not include much more skin than that indicated by the breadth of the areola. The integument is dissected up from the glandular tissue on either side, and the organ freed from its attachments to the pectoral fascia; the axilla is frequently not opened.

CHAPTER XXXVII.

ABDOMINAL SURGERY.

General Remarks on Abdominal Operations.—No branch of the surgical art has grown so rapidly or attained such importance as that directed to the abdominal contents. Operations directed thereto are now of everyday occurrence, and no surgeon hesitates to open the peritoneal cavity whenever it appears necessary, even with the object of merely exploring its contents. Success is, however, entirely dependent on minute and careful attention to detail. The peritoneum properly treated is a good friend to the surgeon; it resents, however, rough handling or prolonged exposure, and serious trouble may follow slovenly work, jeopardizing the patient's life, or even, if he live, giving rise to such disabilities and discomfort as may impair his usefulness. In no department of operative surgery is rapid and yet minutely careful work so well repaid.

The patient should be *prepared,* when circumstances permit, by regulating the diet and bowels for some days previously, and thoroughly cleansing the teeth and mouth, so that the intestinal canal may be as free from organisms as possible. During the previous day the patient is kept quiet, perhaps in bed, and an effective purgative given, *e.g.* 1 ounce of castor oil; an enema may be desirable on the morning of the operation to ensure that the lower gut is empty. The abdominal wall is shaved, as also the pubes, and purified beforehand in the usual way, special care being directed to the umbilicus, where dirt is very liable to lodge.

No food should be allowed by mouth for three or four hours, and immediately before the administration of the anæsthesia the bladder should be emptied, if need be by catheter.

The patient should be warmly wrapped up and protected from cold, no unnecessary exposure being allowed. The operating room should be warm, not below 70° F.; a temperature of 80° F., though trying for the surgeon and his helpers, is better for the patient. Complete anæsthesia is desirable, so as to diminish shock, but this should be obtained with as small a dose of anæsthetic as possible. A preliminary injection of morphia and atropin, or of omnopon and scopolamine, about half an hour before the operation is desirable. When possible, gas and oxygen, or spinal anæsthesia, should be employed. Intraperitoneal operations are not painless, for although the visceral peritoneum is not acutely sensitive, yet the parietal layer is, as well as that included in the mesenteries, and any handling of these structures, especially traction, gives rise to pain and necessarily to increased shock. If the patient is very collapsed beforehand, as in emergency

work, *e.g.* perforation of the stomach, it is often advisable to maintain an intravenous saline infusion throughout the operation; or a preliminary intravenous saline infusion or a whole-blood transfusion may be desirable.

As a general rule the patient lies flat on the table, but if the operation involves the pelvic viscera, the *Trendelenburg position* is often adopted, in which the patient is placed with the head considerably below the rest of the body. All modern operating tables are provided with arrangements for the rapid and easy adoption of this position. Care must be taken to see that the arms are not kept above the head, or musculo-spiral paralysis may follow; they are best fixed under the patient's buttocks or close to the sides. This position must not be adopted when it is probable that the pelvis is occupied by a fluid inflammatory exudate, nor in conditions where obstruction is present, as the stomach is then likely to be filled with offensive material which might gravitate into the mouth and suffocate the patient; in these cases the stomach should always be well washed out and thoroughly emptied before the anæsthetic is given.

Antiseptics are carefully avoided in intraperitoneal operations; after efficient sterilization of the hands of the surgeon and his assistants and of the skin of the patient, nothing is employed in the shape of lotion except sterilized salt solution. Instruments are boiled previously and counted. Swabs, each with a long tape, are best done up in packets of a dozen, wrapped in gauze; it is thus easy to keep account of the number employed. Gauze strips for packing, abdominal cloths, etc., are dealt with in the same way; a careful record of the number employed must be made before and after operation.

Parietal Incision.—In planning the incision for any abdominal operation, three desiderata have to be kept in view: (i.) Suitable *access* should be provided to the part to be explored; naturally a longitudinal incision near the middle line gives the best approach in the majority of cases where a general exploration is desirable, and in many other conditions it is most useful. But when dealing with such structures as the appendix or gall-bladder, an incision placed laterally is usually more convenient. It is always well to remember that incisions should not be placed too near to the bony or cartilaginous boundaries of the abdominal wall. (ii.) It must be so placed as to ensure an *effective blood-supply*, and thereby avoid as far as possible the risk of defective union or of post-operative hernia. Naturally the middle line from this point of view is not desirable, and the linea semilunaris is even worse. Particularly is this the case when the linea alba has been stretched, and the recti muscles separated one from the other. Perhaps the best incisions from this point of view are those which pass through muscular fibres, splitting and separating, but not dividing them. McBurney's incision for the removal of a quiescent appendix is of this nature; it gives a sufficient approach when there are no adhesions, and when the appendix is not displaced. A paramedian incision with displacement outwards of the rectus is also useful, taking the place of the old middle-line incision, the peritoneum being opened through the posterior sheath of that muscle. (iii.) A point to which

considerable attention has been given in recent years is the *nerve-supply* of the abdominal wall. As far as possible the incisions should be planned so as to avoid division of the motor nerves, especially those going to the rectus abdominis, inasmuch as paralysis of this muscle may result in considerable discomfort, and loss of tone of the abdominal wall may follow. From this point of view an incision through the linea semilunaris is one of the worst that could be devised, and the paramedian incision, with displacement of the rectus outwards, the best.

Some surgeons have recommended a *transverse* incision of the abdominal wall, especially in dealing with pelvic lesions; the chief difficulty lies in gaining effective union of the divided ends of the rectus muscles. To prevent their retraction the fibres must be carefully stitched with mattress sutures to the anterior wall of the sheath before being divided; on the whole this method of approach has not been much employed, although it leaves beautiful scars.

The muscles and aponeuroses should always be cleanly divided, and it is wise to see that bleeding is stopped before opening the peritoneum. In most cases, especially where there is a considerable quantity of subcutaneous fat, towels should be attached to the aponeurosis of the muscles, these serving to prevent any infection of the skin by organisms that may pass through the wall of the intestines during manipulation. The peritoneum can usually be picked up by dissecting forceps, and opened with scissors or a knife, air rushes into the cavity, and it is easy to secure the margins with Spencer Wells or other forceps. Holding these well up, the incision can be prolonged up or down as far as may be considered necessary.

The intestines must be carefully guarded during the intraperitoneal portion of the operation, as if they are unduly exposed to the air the endothelial lining is quickly shed; adhesions may then form subsequently, and bacterial invasion from the gut is favoured. If they have to be withdrawn from the abdomen, they should be wrapped in cloths wrung out of warm salt solution, and it is the assistant's duty either to replace these from time to time by warm cloths, or better to keep them moist and warm by pouring fresh salt solution over them; no unnecessary handling of intestine is permitted. If any infective focus is to be opened, or the intestine incised, the surrounding parts must be carefully protected from infection by 'walling off' the area of operation; this is effected by surrounding it with abdominal cloths of suitable size and material, or strips of sterilized white gauze, wrung out of warm salt solution, or by placing them in directions where pus or other fluid might gravitate. A record of these must be kept, and it is wise to have tapes attached to each one, and never to cut any of them into smaller pieces. It is undesirable to use dry gauze for this purpose, as it is likely to stick to the intestine, and its removal may disturb the endothelial covering.

Closure of the Wound.—A careful toilette of the peritoneum must be undertaken before the abdomen is closed. All bleeding is stopped and blood-clot removed; swabs are counted, and, if thought necessary, the site of operation cleansed with sterilized salt solution at a tempera-

ture of about 105° F. Many different methods of closing the parietal incision have been adopted, but perhaps the best consists in first securing the peritoneum by a continuous catgut stitch; then the muscular coats are approximated by deep interrupted stitches, usually of thicker catgut, which remain buried; and, finally, the skin is united by means of a continuous suture of silkworm gut or silk, which is subsequently removed, by interrupted silkworm gut stitches, or by Michel's clips. It is often advisable to put in some deep tension sutures, especially where clips are used, these passing through, in the case of a paramedian incision, the anterior rectus sheath. In order to avoid these stitches cutting through the skin, before being tied they are often threaded through a small piece of fine loose rubber tubing, which serves to distribute the pressure on the skin surface over a larger area. In some parts it is difficult to secure the peritoneum separately, and then it is well to include everything except the skin by deep interrupted sutures, and some surgeons even include the skin in the grasp of these deep stitches.

Drainage is not usually called for in abdominal operations. If the surgeon is careful in his manipulations, and avoids measures which are liable to lead to subsequent oozing, the peritoneum may be closed with safety. When adhesions likely to bleed have been divided, or raw surfaces left such as occur after enucleating a parovarian cyst from the broad ligament, some means should be provided whereby any considerable effusion of fluid can escape, and this can often be best effected by the use of a rubber tube for twenty-four hours, in which a strip of aseptic gauze is placed to act as a lampwick, and along which, by capillary action, the effusion finds its way into the general dry dressing placed over the wound.

On the other hand, when an infected focus has been opened, *e.g.* an acute appendix abscess, drainage is essential, and this is best accomplished by the use of a rubber drainage-tube.

After-Treatment.—After the completion of the operation, the patient is replaced in bed with the head low. The object of this is twofold: first, it tends to combat any shock that may be present, and secondly, if the patient is vomiting, there is then little risk of any inhalation of the vomit. But this position need not be maintained for any length of time, and after a gastro-enterostomy, or in cases of diffuse peritonitis, it is better to place him in the Fowler position at once. If there is much shock, the patient is warmed up by one or more electric lamps attached to a cradle placed over him under a blanket, and a rectal injection of hot coffee (4 or 5 ounces) is desirable. The continuous administration of hot saline solution *per rectum* is inaugurated from the first; this is best undertaken by employing an apparatus similar to that represented in Fig. 766. The fluid is kept at a temperature of 105° to 110° F. in a thermos flask, and allowed to escape through a suitable dripper into a tube which passes 6 inches up the rectum; the fluid escapes from the tube very slowly, so that it takes perhaps an hour and a half to administer a pint. This is generally tolerated very well, and may be continued for a day or two. It is of value not only to relieve shock, but also to make good

the results of hæmorrhage, to allay thirst, and to assist in ridding the body of harmful toxic products by increasing diuresis and diaphoresis.



FIG. 766.—APPARATUS FOR ADMINISTRATION OF SALINE SOLUTION BY THE RECTUM.

The flask to hold the fluid is supported by a bar fixed to the bedpost, and the rate of flow is regulated by the tap placed just below the flask and above the glass dripper.

In those cases where the severity of the operation has been great, such as in an abdomino-perineal resection of the rectum, a blood transfusion followed by a continuous intravenous drop saline and glucose is invaluable. It is better, where the transfusion is likely to be continued for a day or so, to cut down on to a vein and insert a glass cannula directly, though sometimes this may be avoided by the use of a trocar and cannula of the Jubbé type. This has the advantage over a simple needle in that when the trocar is withdrawn there is no tendency, as there is in the latter, for it to push through the wall of the vein.

Sedatives may be employed if the patient is restless or irritable, such as a hypodermic of morphia (gr. $\frac{1}{4}$). At the same time it is important to use as little sedative as possible, and in not a few cases of simple operation, such as the removal of an appendix, it will suffice to introduce into the rectum, immediately after the operation, 30 grains of bromide of potassium and 15 or 20 grains of aspirin.

In those cases where the nature of the operation has been comparatively trivial, as in an interim appendicectomy, it is quite unnecessary to give the patient a long period of post-operative starvation. As soon as he has recovered from his anæsthesia his feeds may be gently built up, and his diet on the day following the operation can be regulated by his wishes.

But in those cases where there has been much abdominal manipulation and exposure of the bowel, the natural reaction of the latter, as has been explained in considering paralytic ileus, is towards a natural inhibition of all intestinal movement, and this must not be

interfered with, until it passes off in about twenty-four hours, by the injudicious administration of food. Body fluids lost during this period are replaced by rectal or intravenous administration of saline and glucose. At the end of twenty-four hours this may be stopped and feeds commenced by mouth. At first about an ounce of albumen water is given hourly, this being increased after three or four feeds to double the quantity. Milk and water in increasing quantities can then be given, and solids started in about forty-eight hours after the operation. Special directions will be found for the feeding of particular cases, such as gastro-enterostomy, where the continuity of the intestinal canal has been interfered with.

Attention to these procedures reduces post-operative distension and discomfort to a minimum, but if, in spite of all, ileus develops, it must be treated in the manner recommended in its description.

Treatment of the Wound.—In cases where the wound is clean, there is often no need to change the dressing until the stitches are removed

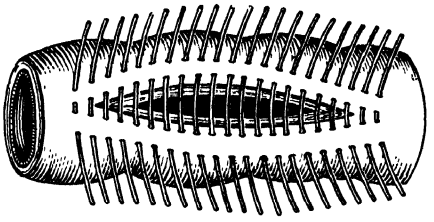

FIG 767.—LEMBERT'S SUTURE AS APPLIED FOR A LONGITUDINAL WOUND OF THE BOWEL

The stitches are carried well beyond the extremities of the incision, so as to obliterate the groove always caused by this method of suturing

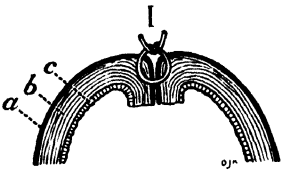

FIG 768.—LEMBERT'S SUTURE SEEN IN SECTION, TO SHOW CHARACTER OF APPROXIMATION.

I, Suture; *a*, serosa, *b*, muscularis, *c*, mucosa.

about the ninth day. If tension stitches have been inserted in addition to cutaneous approximating sutures, these are removed about the fifth day, the remainder being left till the ninth day. Where Michel's clips have been employed these should be taken off about the fourth day, as their function of approximating the skin edges is then finished, but the deep sutures must be left in longer.

In cases where sepsis is present, the dressings must be changed daily and the wound treated with some mild antiseptic, and, in addition, it is wise to approximate the wound edges by zinc-oxide strapping applied to the abdomen in the form of a corset. This relieves any tension caused by wriggling or distension from falling directly on the suture line and, therefore, tends to prevent the stitches from cutting out and the wound from gaping or even bursting.

Stitch Suppuration is a troublesome and irritating sequela of abdominal operations. It may be due to faulty technique, but occurs quite apart from this. The most careful sterilization of suture material will not always prevent its occurrence, and then it must be attributed either to tying the suture too tightly and strangling the tissue within

its grasp, or to its becoming drawn too tight owing to post-operative abdominal distension, and to auto-infection of this strangled tissue, or of some collection of blood around it. Not a few cases have also been attributed to the employment of sutures taken directly out of spirit, which acted thereby as a caustic. All suture material should be carefully washed in sterilized salt solution or weak antiseptic lotion before using it for this purpose. The trouble may start early or late, and its occurrence is not unfrequently indicated by a slight but persistent rise of temperature (say to 100° every night), associated, perhaps, with an increased rate of pulse. The external wound may apparently heal perfectly, and then ten or twelve days after the operation the cicatrix yields, and a quantity of pus may escape. Under these circumstances efficient drainage should be arranged, and, if need be, the exposed stitches must be removed. Of course, this process weakens the abdominal wall, and extra precautions must be taken to prevent the formation of a ventral hernia.

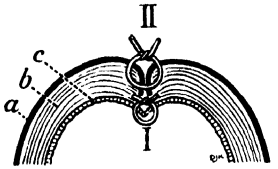

FIG 769.—CZERNY-LEMBERT SUTURE.

I, Stitch securing divided mucous membrane, II, ordinary Lembert suture for the serous coats, *a*, serosa, *b*, muscularis, *c*, mucosa.

Intestinal Sutures.—The interior of the bowel is occupied by material which, as long as it remains in its proper place, is innocuous enough; but should it find its way into the peritoneal cavity, an acute and often fatal peritonitis is almost certain to follow. Hence, every union made by the surgeon must be air- and water-tight, and capable of accommodating itself to varying degrees of intra-intestinal pressure. It is also essential that on its peritoneal aspect the line of union should present nothing but serous membrane, as otherwise adhesions are likely to form, and the comfortable action of the bowel may be subsequently impaired. Special forms of stitches have therefore been adopted, the more important of which are described below.

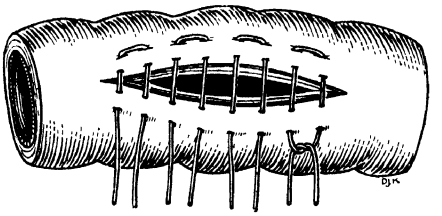

FIG. 770.—HALSTEAD'S MATTRESS SUTURE

Lembert's Suture, originally proposed at the end of the eighteenth century, has for its object the bringing of surfaces of peritoneum together without encroaching on the mucous membrane, any stitch which involves the whole thickness of the wall is liable to be followed by leakage of the intestinal contents, and possibly by peritonitis. The needle is passed at right angles to the axis of the wound through a small fold of the serous and muscular coats, going down to the submucosa; each fold is placed about $\frac{1}{2}$ inch from the margin of the incision (Fig. 765). On drawing up and tightening the stitch, the margins

of the wound are tucked in (Fig. 768), and only the serous coats brought into apposition. A series of similar stitches are inserted along the whole extent of the wound, numbering about ten or twelve to the inch, or it may be carried on as a continuous stitch. In closing a longitudinal incision in this way, a groove will be formed at either end which must be obliterated by two or three extra sutures. For a small puncture the same type of stitch is utilized, but it may be introduced circularly around the opening like a purse-string, and by tightening it the margins of the aperture are turned in and buried.

The *Czerny-Lembert Suture* is very similar in its nature, but consists of two rows: the first has for its object the closure of the wound in the mucous membrane (Fig. 769), and in a longitudinal wound this may be of the continuous type, the second row consists of the ordinary Lembert stitches, continued or interrupted according to the requirements of the case (Fig. 769). By this means the knots of the first series of sutures are covered over and buried by the second row. When carefully

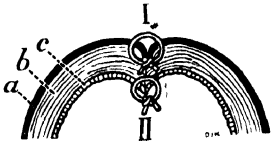

FIG. 771.—WOLFLER'S SUTURE

I, Stitch through serous and muscular coat applied and tied from within, II, stitch uniting divided mucous membrane over the former, so as to cover it in, *a*, serosa, *b*, muscularis, *c*, mucosa.

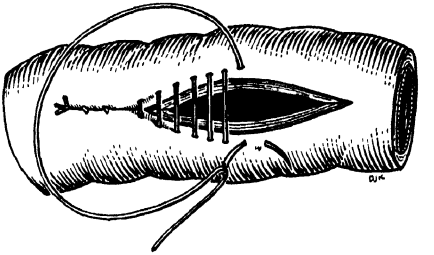

FIG. 772.—CUSHING'S RIGHT-ANGLED SUTURE FOR UNITING THE SERO-MUSCULAR COATS OF THE STOMACH OR INTESTINE

For the sake of clearness the preliminary row of stitches through the mucous membrane is omitted in this diagram.

introduced, these stitches not only serve to approximate the divided walls of the intestine, but also are valuable hæmostatic agents, especially if inserted continuously.

Halstead's Mattress Suture (Fig. 770) is a very useful one, and constantly utilized. It consists practically of a double Lembert, a loop being thus formed at one end, whilst the knot is tied at the other. It is introduced with exactly the same precautions as the original Lembert.

Occasionally it happens that two segments of bowel have to be stitched together from inside, since the surgeon cannot reach the outer coats owing to this portion being fixed. Thus, in an exploratory gastrotomy it may be necessary to stitch up the posterior wall of the stomach after having opened it from the front. The stitches must then be inserted by what is known as *Wolfler's Method* (Fig. 771). They are first passed through the serous and muscular coats on either side (I), the knots being tied on the inner aspect, *i.e.* towards the lumen of the open viscus. The mucous membrane is then secured by

a second row of stitches (II), so as to cover over the first series of knots. In many forms of intestinal anastomosis this plan has also to be employed; as soon as possible, however, one changes to the Czerny-Lembert method.

Cushing's Right-Angled Suture (Fig. 772) is a most useful one when surfaces of some extent have to be approximated by a continuous stitch. The suture is introduced at one end of the incision and tied according to the usual Lembert method, and then it is carried on as a continuous Lembert suture, except that the needle is introduced *parallel* to the margins of the wound and at a distance of about $\frac{1}{8}$ inch from it, instead of at right angles to it. The edges are thereby tucked in very neatly. Of course, the mucous membrane is first dealt with separately by some form of continuous suture. It may be employed very advantageously in gastro-enterostomy or any similar procedure.

Injuries of the Abdominal Wall.

These may be divided into three main classes—contusions, non-penetrating and penetrating wounds; but, of course, the most important point about them is as to whether or not visceral complications are present.

Simple Contusions of the abdominal parietes differ but little from those of any other region of the body. Any form of lesion, from a slight bruise to a well-marked hæmatoma, or an extensive muscular laceration, may be included in this category. The rectus is the muscle most often involved, and its laceration may result not only from injury, but also as a consequence of sudden and forcible contractions, *e.g.* in tetanus. The hæmorrhage may be limited by the lineæ transversæ if it only involves the anterior aspect, but may diffuse itself widely through the sheath if the back of the muscle is torn. All abdominal hæmatomata are very liable to suppurate, the abscess either pointing locally or burrowing widely between the muscular planes, and coming to the surface at some weak spot, *e.g.* Petit's triangle or the external abdominal ring. The pus is usually redolent of the *B. coli*, suggesting that the organism found its way into the extravasated blood from some damaged or bruised coil of intestine in the neighbourhood. Occasionally the parietal peritoneum is torn, causing shock and intra-peritoneal extravasation of blood. In almost all abdominal contusions shock is an important early symptom, but in the absence of visceral lesions it is neither severe nor prolonged. Muscular lesions are sometimes liable to determine the occurrence of hernia at a later date, and hence must be carefully treated. In the rectus spasmodic contraction of one of the segments may give rise to what is known as a 'phantom tumour,' usually found in hysterical females and disappearing under anæsthesia.

Treatment consists in keeping the patient in bed until the tenderness and pain have disappeared. Shock is dealt with in the usual way, and fomentations or a firm compress of dry hot wool will give much comforting support. Rupture of the rectus muscles necessitates the adoption of the sitting position, with the knees flexed over pillows; at

a later date support, as by strapping or a well-fitting abdominal belt, will be required.

Non-Penetrating Wounds of the Abdominal Wall have no special significance, and if uncomplicated by visceral lesions are treated on general principles. If the epigastric artery is divided, extensive extravasation is likely to ensue; the wound must then be enlarged and the bleeding points secured. If the abdominal muscles are widely divided, steps should be taken, after thorough purification, to draw together the severed muscular or aponeurotic fibres by deep stitches, so as to diminish the tendency to a ventral hernia.

Penetrating Wounds of the Abdominal Wall may occur with or without injury or protrusion of the abdominal viscera. In all cases there is a certain amount of hæmorrhage, greater or less according to the size of the vessels divided, and of shock, which latter is very marked when the viscera are injured, whilst mere protrusion without injury may cause but little effect. Thus, cases are on record in which a patient has walked to the surgeon for treatment, supporting some coils of intestine in his hands. The protruded viscera, usually small intestine or omentum, are often large in amount compared with the size of the opening, causing them to be more or less congested or even strangled. Necessarily, in all cases the great danger is that of diffuse septic peritonitis, caused either by rupture of the intestine or by infection from without.

Treatment.—The external wound is thoroughly cleansed, the skin margins and damaged muscular tissues are excised, and protruding viscera are carefully examined. If omentum has escaped, it is wise to ligature and remove it, whether it is injured or not. Intestine should be gently washed with warm saline solution and replaced; if slightly bruised, it may be returned, but the external wound should not be entirely closed, and a cigarette gauze drain is inserted, so that if bacillary invasion or fæcal extravasation occurs subsequently, a ready exit is provided. Small incisions or punctures must be infolded and sutured, but when small intestine is seriously damaged, enterectomy should be undertaken if the patient's general condition is sufficiently good; otherwise it must be fixed to the abdominal wall, and a temporary artificial anus provided. With the large intestine this latter course is required more often, and especially in cases where the bowel is loaded with fæces; the gut must then be fixed in the wound as in colostomy, and the defect dealt with at a subsequent period.

In cases where it is not certain whether the peritoneum has been implicated, the surgeon should always enlarge the wound so as to make sure, and if the serous membrane has been involved, he should carry his investigations still further, and ascertain whether any damage has been done to the viscera.

The external wound must (except in the cases mentioned above) be carefully closed with sutures so as to minimize the risk of a subsequent ventral hernia.

Visceral Complications are likely to be associated with any injury to the abdominal wall, and may transform it into a lesion of the gravest import. The liability to visceral injuries varies with the character

of the violence, and with the condition of the abdominal wall and of the subjacent viscera. If the blow is slight, the effects are probably not serious, and the patient merely suffers from a localized contusion with some amount of shock. If the blow is expected, and the muscles are rigid, but little harm may follow, even when the violence is great; but when the abdominal wall is relaxed and the blow unexpected, a slight injury may do much mischief. Hollow viscera, *e.g.* the stomach, intestine, or bladder, may be torn, and when distended they are more liable to such an accident. Solid viscera, such as the liver, spleen, or kidneys, may be bruised or torn, and grave hæmorrhage result therefrom; a soft fatty condition of the organs, especially of the liver, predisposes to such a lesion. Displacement of organs sometimes occurs, and it must not be forgotten that any sudden sharp concussion, especially if directed to the epigastrium, is liable to be followed by severe shock from irritation of the subjacent solar plexus, and life itself may be destroyed in this way by syncope without the appearance of any evident lesion. The omenta, mesenteries, and peritoneal ligaments may also be torn, and give rise to hæmorrhage, or to the formation of apertures or bands, which can determine obstructive phenomena at a later date.

The clinical history of these injuries will be described under the various organs, and only a few general statements need be made here. It is obvious that a serious responsibility rests upon the medical attendant in any case of abdominal injury, and that the gravest results may follow a mistaken conclusion as to the nature of the lesion, or a hesitant policy in undertaking operation. In a large proportion of cases abdominal injuries, even including rupture of intestine, are amenable to treatment by operation, if only it is performed sufficiently early, when, however, it is delayed until the gut is paralyzed and peritonitis well established, death is almost certain to ensue, whether the abdomen is opened or not. Unfortunately, no absolute rules can be laid down as to when operation is necessary, but the surgeon should remember that exploration in a doubtful case probably does far less harm than waiting until the diagnosis is made certain by an outbreak of diffuse inflammation, providing always that the patient is not so profoundly collapsed as to contra-indicate all interference.

Cases of serious abdominal injury group themselves into three sets. (1) Where, in addition to a localized lesion of the parietes, there is severe shock due to contusion of viscera, but with no justification for laparotomy; (2) where there is serious intraperitoneal hæmorrhage, as from a ruptured liver or spleen, a tear of the mesentery or mesocolon, intraperitoneal rupture of the kidney or pancreas, or rupture of a pre-existing tumour such as an ovarian cyst or renal hypernephroma; and (3) where a hollow viscus is opened and peritonitis is at once lighted up.

Shock is almost always well marked in abdominal lesions, but, unless there is a serious wound of some viscus, it usually passes off in less than twenty-four hours if the patient is left quietly in bed. *Intraperitoneal hæmorrhage* causes various symptoms according to its amount and site of origin; in addition to the initial shock, the general symptoms and signs characteristic of this condition show themselves. There is

acute tenderness of the abdomen over the region of the injury, and there is rigidity in this region Dulness may be noted in one or both flanks, according to the situation of the lesion, being influenced by the attachment of the mesentery and the position of the patient, whether lying or able to sit or stand up, thus blood from the liver may gravitate into, and for a time be limited to, the right lumbar region and iliac fossa without reaching the pelvic cavity; blood from the spleen will pass freely down into the pelvis along the left side of the mesentery, producing dulness in the left loin and not in the right. It must be remembered, however, that a large quantity of blood may escape into the peritoneal cavity without the production of any recognizable area of dulness, it is then lodged under the costal arch, or amongst the intestines, or in the pelvis. In ruptures of the liver the blood may collect above this organ, pushing it downwards and the right leaf of the diaphragm

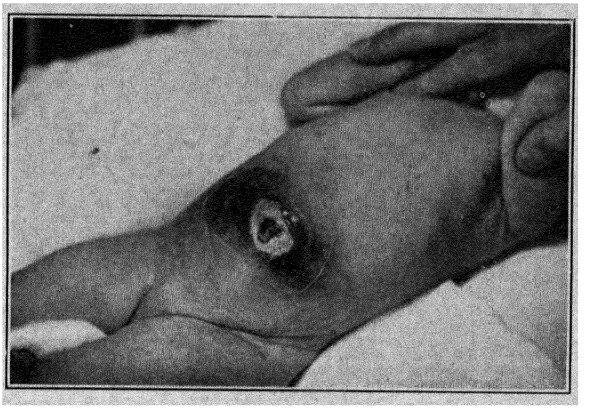

FIG 773.—DIPHTHERITIC ULCERATION AT THE UMBILICUS (DR A R THOMPSON'S CASE)

upwards, with resulting collapse of the lung. When the bleeding is less severe the patient complains of a severe tearing pain, becomes pallid and anæmic, but may recover, and the blood be absorbed; not unfrequently the temperature rises after the initial shock has passed, and remains up for some days. The onset of *peritonitis* is indicated by persistence of the collapse and vomiting or hiccough, whilst the abdominal wall is held rigidly steady, and the breathing becomes thoracic; probably some fixed spot of maximum tenderness will be noted, especially when the intestine is injured, abdominal distension comes on later.

Treatment.—The patient having been put to bed, and the initial shock combated in the usual way, a most careful examination of the patient and his abdomen is instituted. Conditions which indicate immediate operation are: (*a*) the signs of intraperitoneal hæmorrhage, (*b*) blood-stained vomiting, indicating a rupture of the stomach; (*c*) a fixed and rigid abdominal wall coming on quickly after an injury,

with severe pain and localized tenderness, suggesting a rupture of the intestine; and (*d*) the phenomena due to a ruptured bladder. Under such circumstances no delay is justifiable, and, even if severe shock is present, operation should be commenced, unless death is evidently imminent. A large intravenous injection of hot saline solution or a blood transfusion will usually rally the patient sufficiently to warrant the surgeon in proceeding.

If, however, well-marked shock is present, with perhaps localized pain, but with no absolute evidence of visceral lesions, *expectant* treatment should be adopted. The patient is kept warm in bed; perhaps a little opium is administered to allay pain and restlessness and to check peristalsis, but as little as possible should be given, since symptoms are so completely masked thereby. If there is any vomiting, rectal alimentation should be employed after the lower bowel has been washed out. If the manifestations of intraperitoneal hæmorrhage subsequently make themselves evident, or if at the end of not more than twenty-four hours the patient is still, more or less, in a condition of collapse, and especially if he complains of a fixed tender spot with a rigidly contracted abdominal wall over it, or if vomiting or hiccough has supervened, then operation can still be undertaken with some prospect of success.

Affections of the Umbilicus.

The various forms of umbilical hernia are described elsewhere.

Inflammation and **Ulceration,** perhaps running on to eczema, may arise from want of cleanliness after separation of the cord. Tetanus neonatorum probably owes its origin to this source, as also the erysipelas of infants, both of which diseases are exceedingly fatal, the latter being often accompanied by sloughing of the neighbouring abdominal parietes. The eczematous condition merely requires cleanliness, and the application either of an antiseptic dusting-powder or of some simple ointment. Umbilical ulceration due to diphtheria is rarely seen (Fig. 773). It may be associated with diphtheria elsewhere, but it is usually the only localization tending to occur at the end of the first or during the second week of life. The general condition of these babies is not much affected at first, and the prognosis is good provided that it is recognized early and treatment commenced before the clinical picture becomes masked by secondary infection. In adults inflammation occasionally results from the accumulation of dirt in the umbilical fossa, which may even at times constitute a *calculus,* giving rise to suppuration and ulceration.

In hepatic cirrhosis with marked portal obstruction varicose veins occur around the umbilicus, constituting the stellate ' caput medusæ.'

Occasionally a **Polypoid Excrescence** is met with growing from the umbilicus, and is probably derived from the remains of the umbilical vesicle. On microscopic examination, it is found to consist of a number of tubular glands held together by connective tissue. All that is needed is to ligature the base and cut it away.

Cancer of the umbilicus may be primary, occurring either as a

squamous epithelioma, starting in the skin as a result of prolonged irritation, or as a columnar carcinoma, arising in some fœtal relic. More frequently it is secondary to some deep abdominal focus, such as cancer of the stomach, ovary, or the breast.

Umbilical Fistulæ not unfrequently occur, and may be congenital or acquired. Three varieties are described:

(*a*) A *Fæcal Fistula* of congenital origin arises from non-closure of the vitello-intestinal duct, and opens into the intestine either directly, or by means of a passage of greater or less length, which corresponds to Meckel's diverticulum, and is connected with the lower part of the ileum. Sometimes this passage is closed at the intestinal end, and then only discharges mucus. Acquired cases are usually due to perforation of the bowel following strangulation of an umbilical hernia, or to tuberculous peritonitis. A careful dissection is necessary to trace them to their origin, when they are excised with diathermy and the end invaginated.

(*b*) A *Congenital Urinary Fistula* is due to non-closure of the urachus; occasionally merely a sinus persists, leading towards the bladder, but not opening into it. It may be dealt with by excision of the mucous membrane; its destruction by the galvano-cautery, or by freshening the edges and subsequent suture.

(*c*) A *Biliary Fistula* sometimes forms at the umbilicus, resulting from an abscess connected with the gall-bladder.

Affections of the Peritoneum.

Peritonitis arises from many different conditions and presents many diverse manifestations. It may be acute or chronic in its course, localized or diffuse in its distribution, and protective or rapidly destructive in its results.

Ætiology.—Peritonitis is almost invariably due to the action of micro-organisms, and the symptoms largely depend on the toxæmia determined thereby. The bacteria light up an inflammatory reaction characterized by effusion of varying type; in the mildest forms it is usually abundant and localized, in the severer types it is generalized, and in the worst cases death may ensue from toxæmia before there has been time for the development of marked anatomical changes.

1. Infection may start from any part of the intestinal canal from stomach to rectum. It may be due to traumatic or pathological rupture or perforation, to the extension outwards of ulcers, to the impaction of foreign bodies, or the damaging influence of interference with the blood-supply, as in strangulation, volvulus, etc. The vermiform appendix is the commonest site of onset of this group of cases. The *Streptococcus pyogenes* and *B. coli* are the organisms most frequently present, but some of the other inhabitants of the intestine, especially those that are anaërobic, are occasionally causative. On the whole the gastric contents are less noxious than those of the intestine, and the fluid contents of the small gut are more liable to be diffused, and therefore do more harm than the more solid fæces in the large.

2. A somewhat similar type of origin causes *puerperal peritonitis*,

the organisms (usually streptococci, but of any pyogenic form) extending from the uterus through the lymphatics of the broad ligament, etc., to the peritoneum; it is therefore possible for the mischief to limit itself to the pelvic viscera.

3. Infection may occur from without, as in perforating wounds, operations, etc., any of the ordinary pyogenic organisms being responsible, but especially the streptococcus. The question of infection depends largely on whether or not the peritoneum is bruised; rough handling and prolonged exposure are only too likely to destroy the surface endothelium and diminish its resisting powers, whilst the same conditions check the power of absorbing fluids, and hence permit of bacterial growth.

4. Peritonitis may be due to the *gonococcus*, and then has usually spread up the Fallopian tube; to the *pneumococcus*; and possibly to the organism of *acute rheumatism*, then, perhaps, starting in the appendix.

5. The *B. tuberculosis* is responsible for the development of acute or chronic tuberculous peritonitis.

6. Simple chronic peritonitis of a protective character arises when any irritative lesion of a viscus slowly approaches the peritoneal surface. Adhesions of various types may result from this reaction, and grave developments (obstruction, strangulation, etc.) may follow at a later date.

7. A group of cases occurs in which the cause is mechanical or chemical, *e.g.* extravasation of bile from a ruptured gall-bladder, or the irritation produced by torsion of a wandering spleen, or an ovarian cyst, or even of the omentum. Severe reaction follows such a lesion, but it is possible that the focus may be shut off from the general cavity by plastic adhesions, and be thereby encapsuled or absorbed, or the inflammation may extend to neighbouring coils of intestine, and when once these become paralyzed bacterial invasion is almost certain to follow.

Varieties.—1. **Acute Diffuse Peritonitis** results from infection of the peritoneal cavity with a large dose of infective material (as by rupture of the stomach or intestine), or by the introduction of a small dose of virulent organisms when the resisting powers are low.

Pathological Anatomy.—The peritoneal surface becomes congested and a little sticky, and its shiny appearance is lost (as a result of the proliferation of the endothelial cells and a commencing œdema of the subserous connective tissues); this change is most advanced in the neighbourhood of the site of infection, but rapidly spreads, and in the gravest forms of peritoneal toxæmia, where death takes place under twenty-four hours, there is but little other evidence of the disease. In the great majority of cases, however, effusion occurs; sometimes the fibrinous element is most marked, the intestines being matted together, and the fibrin thickest along the lines of contact of adjacent coils; sometimes there is an abundant serous exudate, but more frequently it is sero-purulent or consists simply of pus, which may gravitate to the loins and pelvis, or travel upwards under the diaphragm, or be shut up in pockets by the development of adhesions. The effusion is intensely infective, and any wounds caused during the operation or in post-mortem examination of such a case are likely to be followed by severe cellulitis or even septicæmia. Gas may be

present, resulting either from the laying open of an air-containing viscus, or from the presence of a gas-producing organism.

The intestinal walls become paralyzed, as a direct result of the action of toxins upon the contained nervous plexuses, and in consequence the contents of the gut stagnate and undergo decomposition. The omentum becomes congested and infiltrated with effusion, or even pus; it may occasionally, however, form a barrier across the abdomen, shutting off the lower from the upper part, limiting the mischief to some particular section.

The toxins developed in the exudate are absorbed by the peritoneum, and whilst causing a generalized toxæmia of varying severity, they may also determine a well-marked subperitoneal œdema. The rapidity of absorption is very considerable, especially from the under surface of the diaphragm, where the lymphatics are practically continuous with the peritoneal cavity, and quickly carry toxins and bacteria to the mediastinal glands. The upper half of the abdomen is therefore a less favourable site for peritonitic trouble than the lower, and all available means, such as position, drainage, etc., must be employed to limit or prevent the extension of the trouble in this direction.

Symptoms.—The onset varies somewhat with the cause of the affection; but when due to traumatic infection from without, the symptoms usually commence with abdominal pain and rigidity, followed by distension, together with flatulence and vomiting. The pain may be localized at first to some particular region, or is referred to the umbilicus; soon, however, it becomes diffuse, and is associated with exquisite tenderness and great distension. In a typical advanced case the phenomena are very characteristic. The patient lies on his back with the knees drawn up, partly to relax the abdominal muscles, partly to prevent the bedclothes touching the body. The abdomen is distended, hard, and extremely tender; it is at first generally tympanitic, but later on, if effusion should become marked, dulness may be noted in the flanks, although this is not a common feature. The pulse is quick, hard, and wiry in the early stages, though later it becomes weak, rapid, and compressible. The respirations are quick, shallow, and thoracic in character. The temperature, perhaps raised at first as a result of the causative lesion, sometimes becomes subnormal from toxæmia before the end is reached. Vomiting is usually a prominent symptom, associated perhaps with hiccough; to commence with, the contents of the stomach alone are expelled, but later on they may be mixed with bile, or with the decomposing contents of the upper coils of intestine. Though very constant and troublesome, it is much less distressing than that which arises from intestinal obstruction, and, owing to the pain induced by any sudden contraction of the abdominal muscles, the patient ejects the vomit with but little force. Constipation and the absolute arrest of flatus are almost always present in peritonitis, owing to the cessation of peristalsis induced by the inflammation, and hence meteorism is a marked symptom. On auscultation the peritonitic abdomen is absolutely silent. As the case progresses the patient's strength rapidly diminishes, his face becomes pinched

and drawn (*facies Hippocratica*), the extremities are cold, the temperature is usually subnormal, and death results from collapse and toxæmia.

When due to sudden perforation of the bowel, the onset of the symptoms is associated with profound shock, and the course is very rapid if the opening is large, and the intestinal contents early extravasated. Vomiting, too, is usually more marked than when due to other causes. If, however, the perforation is small, the immediate shock is less, and the symptoms progress more gradually.

Treatment.—In the early stages, if the diagnosis is in doubt, or the desirability of operation is in question, the patient is kept quietly in bed, and preferably in what is known as *Fowler's position* (Fig. 775), *i.e.* with the head and trunk raised from the horizontal plane about 30° or 40°, so as to determine the flow of fluid exudate down towards the pelvis rather than backwards into the kidney pouches, whence it may spread up to the dangerous subdiaphragmatic area. No food is administered by the mouth, and no purgative given; the lower bowel may be emptied by enema, and subsequently saline injections administered to relieve thirst. Morphia and opium are used with the utmost caution as long as the diagnosis is uncertain, for fear of masking symptoms. By determining a cessation of vomiting and a false sense of comfort, unjustified hopes may be encouraged, and delay in operation result; at the same time they may be useful in localizing the trouble and allowing adhesions to form. Whilst the patient is being prepared for operation and the necessary arrangements are being made, a moderate dose of morphia may save him much suffering and help to conserve his powers.

The actual scope and particular features of the operation vary naturally with the many causes that may have been operative in determining the outbreak of the condition, and these will be suitably referred to afterwards. It is only possible here to deal with the general features. The incision is generally median or paramedian in type, and the lower half of the abdomen is opened rather than the upper, unless the latter is distinctly indicated. The objects of the operation are threefold: (1) To *find and deal with the cause* of the affection, such as a perforation which needs to be closed, or a perforated or gangrenous appendix which must be removed. (2) To *cleanse the peritoneum* and remove the effusion, and for this the majority of surgeons at the present time rely on simple mopping up of the exudate and perhaps washing away escaped débris of food, as in a perforated gastric ulcer. The surgeon must make certain that there is no retained collection of exudate in Douglas's pouch or in the right kidney fossa after a perforated duodenal ulcer; if present, the collection must be carefully mopped away. The peritoneum has a great power not only of absorbing fluid, but also of destroying bacteria, and hence, if the primary focus of trouble is satisfactorily removed or dealt with, may be largely left to defend itself. (3) At the same time *drainage* is necessary in many cases where a collection of fluid has formed in the pelvis; this may be effected by the use of rubber tubes, with or without gauze wicks, or of a cigarette drain. It is probably wise to change the tube for a smaller one after forty-eight hours, which in turn is followed by a strip of rubber glove as soon as the

discharge diminishes sufficiently. The abdominal wall is, of course, only partially closed after these proceedings. Experience, however, has

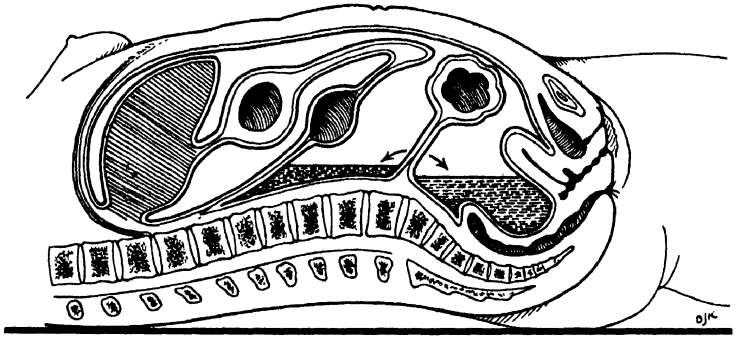

FIG. 774.

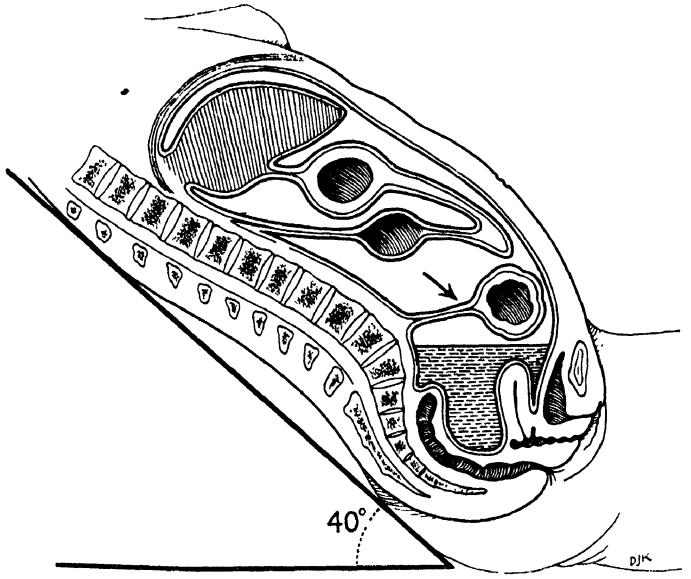

FIG 775.

FIGS. 774 AND 775.—DIAGRAMMATIC MESIAL SECTION OF FEMALE ABDOMEN TO REPRESENT THE VALUE OF FOWLER'S POSITION IN THE TREATMENT OF INTRA-ABDOMINAL INFLAMMATORY EFFUSIONS

In Fig. 774 the patient is horizontal, and it is obvious that an inflamed appendix lying over the brim of the pelvis will cause effusion, which drains in two directions: upwards towards the liver and diaphragm, and downwards to the pelvis. In Fig. 775 the body is in Fowler's position, and the resulting effusion will collect in the pelvis.

shown that the peritoneum has considerable antiseptic and defensive powers, and that where the exudate is merely sero-purulent drainage

may often be omitted, granted that the case is an early one and that the local causative focus is efficiently treated.

When intestinal distension is very great, so that it may be difficult to reach the cause of the trouble or to return the extruded viscera, it may be advisable to tap a coil of small intestine and empty the contents, or to stitch in a rubber tube and allow the bowel subsequently to empty itself, dealing with the fistula so produced at a later date. The reduction of the distension is an essential element if a successful issue is to follow, but undue manipulation must be avoided. Post-operative treatment for any associated post-operative ileus is that described in the appropriate section.

As soon as the patient has recovered from the anæsthetic, he should be raised from the recumbent to the sitting posture (*Fowler's position*), with a view to permitting the fluid effusion to gravitate into the pelvis. Continuous infusion of salt solution into the rectum (*proctoclysis*) or subcutaneous tissues should also be employed in order to dilute the toxins and facilitate their elimination. Improvement in the condition of the patient shows itself almost at once by a fall of temperature and of pulse; the vomiting ceases or becomes less urgent, pain and tenderness decrease, and the patient looks and feels better. On the second day the bowels are likely to become distended with flatus, and it is necessary to obtain relief; this is best effected by a turpentine enema in the first place, followed by a dose of castor oil, or of sulphate of soda, or repeated small doses of calomel. As soon as the bowels have acted well, the urgency of the symptoms diminishes, and it is probable that the patient will recover.

The American school of surgeons, led by Crile and Oschner, however, recommend a quite different method of after-treatment, and equally good results follow. The stomach is washed out before operation and nitrous oxide anæsthesia, followed by local infiltration analgesia, is alone employed. Adequate drainage of the peritoneal cavity is provided, and the patient put back to bed in Fowler's position. Large fomentations are placed over the abdomen, reaching well down to the sides, and continuous 'drip' administration *per rectum* of 5 per cent. saline with 5 per cent. glucose is continued for as long as it can be tolerated. Large quantities of normal isotonic saline are given hypodermically till the time of danger is passed (2,500 to 3,000 c.c. per diem), and the patient is placed fully under the influence of morphia till the respiration falls to 10 to 14 per minute; this is maintained until the patient is out of danger, but not in streptococcal cases.

2. **Acute Localized Peritonitis** usually arises in connection with some limited lesion of the abdominal contents, which is of such a nature as to permit of the general peritoneal cavity being shut off by adhesions, the process being thereby localized. It is frequently followed by suppuration, the abscess being thus intraperitoneal, although not involving the general peritoneal cavity. The abscesses arising in connection with appendicitis or pelvic peritonitis are not uncommonly of this nature. They may burst through the barrier of adhesions, and thus light up a diffuse inflammation of the peritoneal sac, or they may burrow to the surface and point externally, or open into one of the hollow viscera.

The **Symptoms** complained of are deep pain and tenderness, more or less localized to the affected area, together with fever, vomiting, and constipation. At first no swelling or tumour is to be made out, but a feeling of resistance may be noticed in the abdominal wall, which is held tense and rigid, as if guarding some focal point of mischief. As the effusion increases in amount, a tumour, dull or tympanitic on percussion, may become evident; it is mainly due to a matting together of the intestines and omentum, but is often associated with a variable amount of effusion; if, however, it is placed deeply, the dulness may be absent owing to the fixation of one or more coils of intestine in front of the inflammatory focus. If an abscess forms and travels towards the surface, the abdominal wall becomes infiltrated, red, and œdematous, the component tissues being brawny to the touch, and cutting like bacon. Finally, a fluctuating area presents itself in the midst of this indurated mass, and the abscess either discharges itself or is opened. The pus contained therein is often offensive, owing to the presence of the *B. coli*. Of course this process is attended with considerable increase in the pain and constitutional disturbance. If the cavity is opened aseptically and drained, it rapidly contracts and a cure is accomplished, although intraperitoneal adhesions may persist and lead to subsequent trouble from hampering the intestinal movements. The determination as to the existence or not of suppuration is by no means easy, and a blood-count, perhaps repeated more than once, is often of the greatest value.

Treatment.—In these cases resolution can sometimes be obtained by keeping the patient absolutely quiet and on a low diet, with perhaps a little morphia, and by applying fomentations locally, whilst the lower bowel is emptied by an enema. Such a course must, however, not be persisted in for too long when suppuration is likely to have occurred, for fear of the inflammation spreading to the general peritoneal cavity, or of the abscess bursting into it. An early exploratory laparotomy is advisable under such circumstances. The line of treatment marked out for appendicitis is that which should always be followed.

3. **Simple Chronic Peritonitis** in itself rarely requires surgical attention, since it is to be looked on rather as a protective than as a destructive process. It is characterized by infiltration and thickening of the peritoneum, whereby the intestinal wall is strengthened and bacterial invasion hindered. It is localized or diffuse in character, and arises as the result of some pre-existing inflammation. In the more diffuse forms the intestines may be hopelessly matted together, or the omentum rolled up and contracted into a rounded cord-like mass, lying transversely across the upper part of the abdomen; chronic obstruction is almost certain to arise sooner or later from this condition.

More frequently it is the consequence of some localized injury or inflammation. In the former plastic lymph is deposited over any breach of continuity of the serous membrane, and to this the omentum or intestine becomes adherent; the under surface of a laparotomy wound is not unfrequently affected in this way. Localized areas of inflammation are similarly liable to originate adhesions, which are thus found in connection with gastric ulcers, an inflamed vermiform

appendix, enlarged mesenteric glands, or a pyosalpinx. Under favouring circumstances many such adhesions are absorbed in the early stages, but if they persist, they are modified by the intestinal movements, and are likely to become lengthened and rounded, thus originating the bands and cord-like structures so often the causes of acute obstruction. The omentum is frequently involved in this process, and thereby constitutes one of the most important agents for checking the spread of inflammatory affections. Intestinal adhesions often given rise to no symptoms; but sometimes they determine attacks of colic and of irregular peristalsis, and occasionally an adhesion to the abdominal wall, *e.g.* one springing from the stomach, causes a constant localized pain which justifies exploration.

4. **Tuberculous Peritonitis.**—This disease is almost limited to young people, and is usually secondary to some other focus of tuberculosis, *e.g.* in the intestine, mesenteric glands, Fallopian tube, testis, etc. It is sometimes limited in its development to a portion of the peritoneal cavity, especially when originating from the pelvis or vermiform appendix, but is more frequently diffuse.

Several different types occur, which may be associated with or follow one another: (1) In the *ascitic* variety the peritoneum becomes thick and hyperæmic, and is studded over with tubercles, some of them small, grey and translucent, others larger and undergoing caseation. The effusion is generally abundant, and consists of straw-coloured or opalescent serum, perhaps blood-stained in the more active cases. Flakes of fibrin may be found covering the membrane here and there, but there is no extensive matting of the intestines. Occasionally the effusion becomes *encysted*, giving rise to localized fluid swellings shut in between the coils of intestine. (2) In the *fibrous* variety the intestines are matted together by extensive adhesions and between them foci of tubercle are found. The mesentery may become infiltrated and shrink, fixing the intestines back *en bloc* to the posterior abdominal wall. The omentum is often invaded, and contracts upwards to form a sausage-like tumour lying transversely above the umbilicus. There is but little effusion, and that is usually encapsuled. It is obvious that such a condition is very likely to lead to obstructive phenomena, due to kinking of the intestine. (3) The *suppurative* variety is characterized by the presence of tuberculous foci of some size between the coils of intestine; caseation and suppuration follow, and the abscesses are likely either to open into the intestine, possibly into two coils, causing thereby a fistulous communication (*fistula bimucosa*), or perhaps to travel to the surface and open externally, and then most frequently at the umbilicus, possibly giving rise to a fæcal fistula.

In each of these varieties acute manifestations may develop at any time as a result of infection from the bowel with the *B. coli*, and then the symptoms of acute diffuse peritonitis may supervene.

The **Symptoms** are extremely variable, and the early stages of the disease are sometimes not easy to recognize.

A few cases have an *acute* onset with abdominal pain and distension, and continued pyrexia of a mild type. The abdominal wall, however, is rigid, and there is well-marked tenderness, often localized to the

right iliac fossa, and simulating acute appendicitis. Free fluid is present, and though vomiting and constipation exist they are not marked features. The patient does not look so ill as the local symptoms would suggest, but naturally goes down-hill and wastes quickly. A careful examination of the pelvic viscera should always be made in girls and young women, as this condition is not an uncommon complication of genital tuberculosis.

In the more *chronic* forms the earliest symptoms are weakness with some slight abdominal discomfort, and not uncommonly diarrhœa, alternating perhaps with constipation. The temperature becomes of a hectic type, and periods of improvement may alternate with attacks of increasing pain and weakness. On the whole, the patient gradually gets worse, his wasted frame comparing markedly with the protuberant and enlarged belly. The phenomena discoverable on abdominal palpation vary considerably with the conditions present within.

Treatment in the early stages, and especially in the acute variety, is often successfully undertaken by the physician. Hygienic measures of the sanatorium type are adopted, the patient living in the fresh air, and, of course, being always in the recumbent position. Plenty of good digestible food is given, as also cod-liver oil, and perhaps intestinal antiseptics, such as salol, creasote, etc. The external application to the abdomen of iodine, either as a paint or an ointment, is much commended by some physicians, whilst Scott's dressing is relied on by others.

Should the condition undergo no improvement, it may be justifiable to operate, especially when chronic ascitic accumulation is present. All that is needed is to remove the fluid by tapping or laparotomy; in the latter case irrigation is not required and the wound should be closed completely; in nearly 75 per cent. of such cases a cure may be anticipated. In the acute forms operation is undesirable, and but little good results, moreover, tuberculous infection of the wound often follows the escape of the highly infective fluid from the peritoneal cavity, and healing may be thereby delayed. Where diffuse or localized suppuration is present, adhesions which can be reached may be gently broken down, and exit given to the pus; but no prolonged search after suppurating foci should be made, or the intestine may be torn. The results of treatment in this variety are not nearly as satisfactory as in the former.

Pneumococcal Peritonitis may arise as a primary manifestation, or may be secondary to lesions such as pneumonia, empyema, or throat and ear trouble caused by pneumococci. The primary variety is usually, though not entirely, seen in young girls of between four and fourteen years of age, and the infection usually spreads from the vagina by way of the genital passages; it is more common amongst children who are not kept clean, and is more often seen in the summer months when the children are more likely to sit about in but little underclothing. In many cases virulent pneumococci are to be isolated from the vaginal secretion of these children. The outbreak is sometimes preceded by slight diarrhœa, but the onset is usually sudden and definite in the shape of abdominal pain. This is accompanied by shock, fever, and toxic manifestations, often taking the form of drowsiness and confusion,

or sometimes of delirium; vomiting is present, and the pulse rapid. The most characteristic feature is that abdominal rigidity is generally slight. After a few days, during which the temperature remains steadily high, there is a considerable effusion of pus into the peritoneal cavity, accompanied by intermittent abdominal pain, whilst the swelling increases, but the abdomen is still on the soft tumid side. Leucocytosis now becomes more marked. In the third stage the effusion is likely to localize itself to some part of the abdomen—either as a subdiaphragmatic abscess, or one rising up in a dome-like fashion from the pelvis, even encroaching gradually upon the whole cavity; typical dulness may be noted, and the patient wastes rapidly. The abscess sometimes evacuates itself either into one of the viscera or externally, *e.g.* through the umbilicus, and a spontaneous cure may follow. In the more acute cases the course is very similar to the diffuse pyococcal type described above; prostration is generally rapid, and death early; the chief distinguishing features are the presence of looseness of the bowels, or even of diarrhœa in some cases, a high leucocyte count, and a less rigid abdomen. The pus is usually like that in a pneumococcal empyema, being greenish-yellow in colour and with a faintly sweet smell, containing an abundance of false membrane. **Treatment** in the early stages is expectant, consisting in rest in the Fowler position, the administration of opium, and ice to the abdomen. Anti-pneumococcic serum should be used, and whole-blood transfusion may be helpful. Most surgeons consider that early operative treatment is of little avail; but when the pus is localizing itself it should always be evacuated and drainage established.

Gonorrhœal Peritonitis almost always occurs in women as a direct extension of a gonococcal inflammation upwards from the uterus, being preceded or accompanied by the phenomena of salpingitis or ovaritis; it has, however, been known to develop in men. There is usually a definite history of gonorrhœa with a more or less abundant discharge, but the attack generally follows a menstrual period, or the manipulation of the tubes and ovaries. The onset is sudden and acute, the patient complaining of severe pelvic pain, which is accompanied by vomiting, abdominal distension, and fever. A swelling may be felt above the brim of the pelvis. Under suitable treatment the trouble often abates rapidly, and the patient recovers; but adhesions are likely to be left, determining sterility, or the tubes may remain full of pus (pyosalpinx). In other cases exudation is abundant, though there is a tendency to limitation of the trouble, and the prognosis is generally favourable. **Treatment** consists in absolute rest, fomentations to the abdomen, hot vaginal douches, and suitable limitation of diet. If rapid improvement does not follow, a median laparotomy should be undertaken in order to let out the pus and permit of suitable drainage. The tubes and ovaries should always be explored in such cases, and may perhaps need to be removed.

Subphrenic Abscess.—Those suppurations that occur in the space bounded above by the diaphragm and below by the liver are included in the term subphrenic abscess. The disposition of the peritoneum divides these abscesses into two main groups, the extraperitoneal

and the intraperitoneal, the former being again subdivided into two, the anterior and the posterior, these being separated by the very close adherence of the coronary ligament to the diaphragm. The posterior extraperitoneal compartment is really a potential space, situated between the diaphragm and the peritoneum covering the right lobe of the liver, and it may be infected from such conditions as an acute appendicitis or pelvic suppuration, or some infection of the neighbouring kidney.

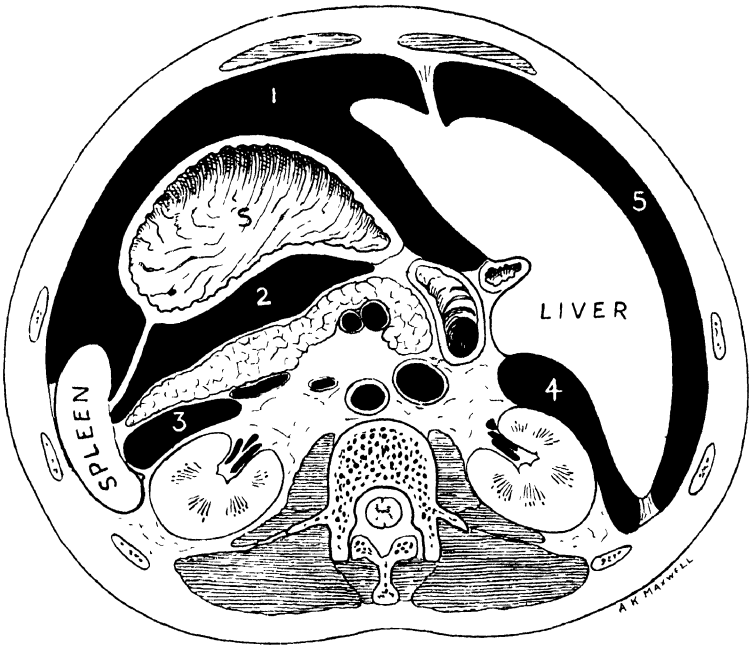

FIG 776.—DIAGRAM SHOWING THE DIFFERENT PERITONEAL COMPARTMENTS IN WHICH AN ABSCESS MAY FORM

1, Left anterior, 2, left inferior, 3, left inferior extraperitoneal, 4, right posterior, 5, right anterior

The infection from the viscera low down in the abdomen is usually lymph borne, but where a retrocæcal appendix is present the infection may be direct.

Suppuration in the anterior extraperitoneal space is rare, and usually occurs as a result of suppurations in the region of the umbilicus.

The disposition of the peritoneal ligaments and the liver divide the intraperitoneal space into six compartments. The coronary on the falciform ligament divides the space above the liver into left and right areas, the right lateral ligament subdividing the latter into an anterior and a posterior region. The inferior compartment on the right side

is single, but the lesser omentum divides that on the left into anterior and posterior, the latter being the lesser sac of peritoneum (Fig. 776).

These spaces are affected by pathological conditions of various organs with which they are in close relation. Thus the right inferior intraperitoneal space may be infected from a gall-bladder, the perforation of a duodenal ulcer or a liver abscess, and, in addition, is commonly infected from subacute appendicitis (Fig. 777). Infection may again be lymph borne, or fluid may track up the paracolic gutter on the outer side of the ascending colon and infect this and the right postero-superior compartment with which it is in communication. Acute pancreatitis or a perforated gastric ulcer on the posterior stomach

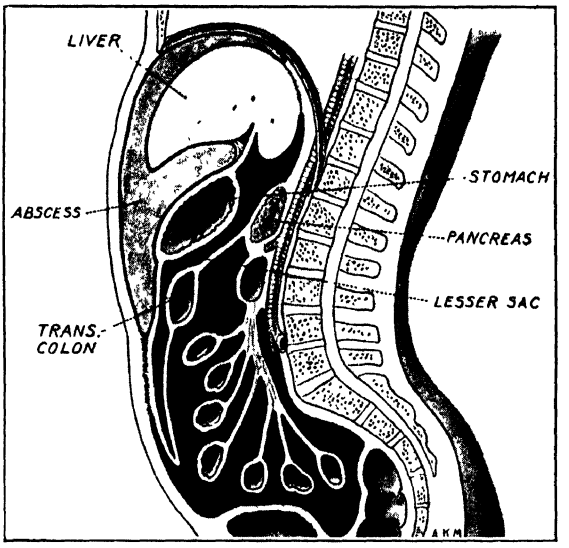

FIG. 777.—DIAGRAM OF SUBPHRENIC AND SUBHEPATIC ABSCESS, DUE TO EXTENSION FROM AN ULCER OF THE ANTERIOR WALL OF THE STOMACH.

wall may infect the postero-inferior left space, whereas the anterior space on the same side may be infected from a perforated anterior ulcer (Fig. 778).

There is no doubt that in infections of the abdomen these spaces must often become infected, but, owing to perhaps a good resistance, suppuration does not always occur. It may be further prevented by early diagnosis and early treatment and, subsequent to the treatment, the adoption of the Fowler's position.

The first **Symptoms** of a subphrenic abscess are constitutional in type. After an operative procedure, the temperature, instead of settling, is irregular, raised, and intermittent. The pulse rate goes up, and the patient shows signs of toxæmia. There is often a characteristic dry cough due to irritation of the diaphragm. Occasionally the

patient may have a rigor, and he complains of pain over the lowest rib, posteriorly on the subcostal margin in front, according to the position of the infected space. Sometimes there is referred pain in the shoulder, and in cases of extraperitoneal infection pain is complained of in the loin. The muscles in the upper abdomen are on guard, and in some cases the liver is pushed down by the accumulation of pus on its superior surface so that its edge may be palpated. If gas is present in the abscess cavity, a band of resonance may be identified between the liver on the one hand and a collapsed lung on the other. Sometimes there is a spread of infection through the diaphragm with the formation of an empyema, and in other cases the abscess may

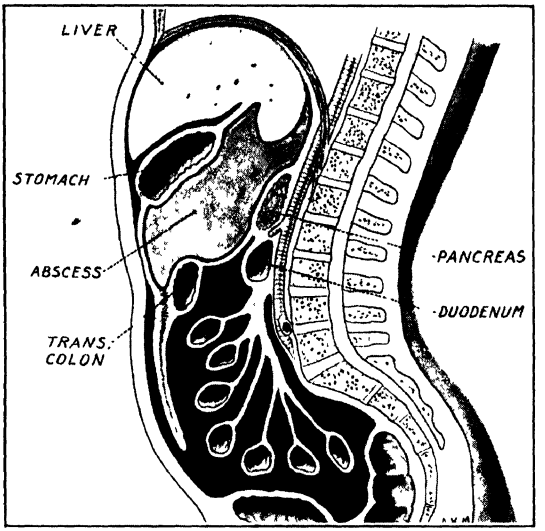

FIG 778.—DIAGRAM OF SUBPHRENIC ABSCESS IN THE LESSER SAC OF THE PERITONEUM, DUE TO EXTENSION FROM AN ULCER OF THE POSTERIOR WALL OF THE STOMACH.

discharge into the pleural cavity. X-ray examination is invaluable, and will reveal a raised immobile diaphragm on the affected side, and, on the left, upward displacement of the heart.

Treatment.—Patients presenting these signs and symptoms have an infection of the subphrenic spaces, which may or may not have gone on to suppuration. In the early stages of the infection conservative treatment, consisting of putting the patient in Fowler's position and hot foments to the subcostal region, should be employed; but if the temperature and pulse do not settle, and the signs and symptoms increase, operation must be performed.

Aspiration, as an aid to diagnosis or as a treatment, is mentioned only to be condemned on account of the danger of infecting an uninfected pleural or peritoneal space.

Up till very recently it had been the custom to open up these abscesses through the pleural or peritoneal space, according to whether they were situated posteriorly or anteriorly. This, again, has the disadvantage of endangering the uninfected pleural or peritoneal space, even if the diaphragmatic pleura is sewn to the parietal layer. Doing the operation in two stages, by first opening the pleural cavity and packing gauze into it to cause adhesions to be formed between the two layers, has the great advantage of delaying opening the abscess for several days.

The best form of treatment is to open and drain the abscess extra-peritoneally or extraphrenically according to its position. In the latter procedure an incision is made obliquely over the last rib, a portion of which is removed subperiosteally. A transverse incision is then made through the bed of the rib and incises the diaphragm below the pleural reflection. The peritoneum is then peeled up, away from the posterior abdominal wall, until the abscess is found. Extra-peritoneal drainage is instituted by making a subcostal incision and reflecting the peritoneum away from the diaphragm until the abscess is reached, when it is opened and drained.

Ascites.—By this term is meant an accumulation of fluid, and that usually of a serous type, within the peritoneal cavity. It results chiefly from cirrhosis of the liver, chronic Bright's disease, and various cardiac affections; but is also a consequence of any obstructive pressure on the portal vein, as by malignant glands in the portal fissure secondary to carcinoma of the stomach or of the intestine, or by fibrous adhesions, the consequence of duodenal ulceration or stones in the gall-bladder. Fluid also collects in the abdomen as the result of diffuse malignant deposits scattered over the peritoneum, or from the presence of mildly irritative foci, such as hydatid cysts, etc. *Chylous* ascites is a condition in which the fluid is milky from an admixture of chyle, and usually results from rupture of the receptaculum chyli in consequence of the pressure on the thoracic duct of malignant glands secondary to cancer of the stomach. *Encysted* ascites results from the distension of a portion of the cavity which has been shut off by adhesions.

The **Signs** of ascites are easy of recognition. The abdomen is distended, like a barrel, but with bulging flanks. Dulness is present in the loins when the patient is recumbent, and extends forwards to about the same level all round, the only resonant area being about the umbilicus, this is due to the floating forward of the intestines. On rolling the patient over to one side, the dull and resonant areas shift, the part that is highest becoming resonant. This sign is occasionally absent if the mesentery is short or if the intestines are tied down posteriorly. On flicking the abdomen, a well-marked thrill is usually transmitted from one side to the other. Necessarily, the fluid also finds its way into any diverticula of the peritoneum, such as an unclosed funicular process or a hernial sac. The **diagnosis** of ascites is not difficult, but the recognition of its cause may not be easy until the fluid has been removed, so that the abdominal viscera become palpable. Light may also be thrown on an obscure case by a cytological examination of the fluid; in malignant disease, cancer cells and blood may often be found.

Treatment necessarily varies with the cause of the accumulation. Should it persist, and the patient's breathing be hampered by the abdominal distension, removal by *paracentesis* is essential. The usual plan is to seat the patient on a chair and to encircle the abdomen with a flannel binder, the ends of which are split to within 6 inches of the middle line. The unslit portion is placed over the abdominal wall in front, and the divided portions cross behind, and are held by assistants, so as to maintain continuous pressure. The bladder is emptied, and then the abdomen is percussed, and a spot of absolute dulness selected; here a small incision is made after purification of the skin, and a suitable trocar and cannula inserted. The median line below the umbilicus is the place usually chosen for the puncture, but there is no objection to inserting the trocar through the flanks. If it is desirable to withdraw the fluid more slowly, so as to prevent the shock often experienced from its rapid removal, two or three small-sized trocars and cannulæ may be inserted.

In cases due to hepatic cirrhosis, **Epiplopexy** (the Talma-Morison operation) may possibly be of some use. The object is to relieve the obstruction to the portal system by opening up fresh communications between it and the systemic veins. The method consists in fixing the great omentum to the abdominal wall and determining the formation of adhesions; necessarily the peritoneum has to be drained and kept dry during this procedure, and the question arises as to whether this drainage is not the cause of the improvement. The mortality is not inconsiderable, especially when the liver is small, the best results have been gained with hypertrophic cirrhosis. In other cases the internal saphenous vein has been dissected up, tunnelled under the skin towards the abdomen, and fixed just inside the peritoneum with the object of draining the ascitic fluid into the systemic circulation.

Affections of the Great Omentum.

The omentum is of great surgical importance in the abdomen, in that it covers in and protects the viscera, and by its mobility is able to apply itself to many a weak spot where perforation or infection might occur, and thereby guard the patient from serious inflammatory mischief. The result of this process is, however, the formation of adhesions which by the irritation of constant movement may stretch and become rounded and cord-like, and various forms of intestinal obstruction (by strangulation, kinking, etc.) may result therefrom. The value of this protective power of the omentum is recognized by surgeons in the employment of *omental grafts* to add security to a line of junction in the intestinal wall with which they are not quite satisfied. The best method to adopt is to detach the graft entirely from its former connections, wrap it round the gut and stitch it in place.

The omentum may be torn, and holes may be formed in it as a result of **injury.** The immediate symptoms are pain, shock, and the phenomena of intraperitoneal hæmorrhage; but it is likely that other injuries co-exist. At a later date the hole might be the site of internal strangulation.

Acute Inflammation (epiploitis) has been lighted up as a result of the application of a septic ligature to the omentum in a hernia operation. The phenomena vary with the virulence of the organisms, an acute diffuse peritonitis perhaps resulting. In the milder forms a localized inflammatory disturbance follows, with all the phenomena of a limited peritonitis; suppuration may ensue, and a large intraperitoneal collection of pus may develop.

Torsion of the omentum is an occasional complication of an irreducible hernia, and that usually on the right side. The lesion generally follows some heavy strain, and results in venous stasis, effusion of a blood-stained fluid, the formation of extensive adhesions, and possibly gangrene and general peritonitis if left long enough. The symptoms often start abruptly with colicky pain in the right iliac fossa and scrotum, together with constipation and sickness; the hernial swelling becomes enlarged, and extending upwards from the iliac region a sensitive mass may be detected on palpation, which is dull on percussion, and sometimes reaches to the epigastrium. The temperature is normal, though the pulse-rate is accelerated. Treatment is obviously operative, and consists in removal of the omentum.

Chronic peritonitis, whether simple or tuberculous, may cause the omentum to be rolled up into a more or less solid mass, which lies transversely across the abdomen a little above the umbilicus. There is usually a band of clear resonance between it and the hepatic dulness which is of great diagnostic importance.

The omentum also becomes infiltrated with secondary cancerous nodules, which can sometimes be palpated, and their presence is always an important indication as to the undesirability of operative treatment. Colloid degeneration is not uncommon in omental cancers, and huge masses of this growth have been sometimes discovered in the dead-house. Omental carcinoma usually leads to a considerable effusion of fluid into the peritoneal sac.

Affections of the Mesentery.

Wounds may be caused by penetrating or non-penetrating injuries. They are usually associated with laceration of the intestine, and the resulting phenomena will be those of hæmorrhage, followed by general peritonitis from the intestinal lesion. Simple mesenteric wounds not involving the bowel are generally due to penetrating or gunshot injuries. Hæmorrhage to a varying degree may follow, and if the patient lives, the nutrition of the intestine may be seriously endangered. If such a lesion is found on exploration, bleeding-points must be secured and the opening in the mesentery closed, but before this is undertaken, careful consideration must be given to the vascular supply of the intestine, as the ligature of a main branch of a mesenteric artery may determine gangrene, and necessitate resection of a portion of the bowel.

Occlusion of the Mesenteric Vessels, apart from strangulation or volvulus, is usually the result of embolic obstruction of the artery, secondary to such conditions as auricular fibrillation, endocarditis, aortic aneurism, or arteriosclerosis, but may sometimes commence in the veins, as a thrombosis caused by portal obstruction or some

infective conditions such as acute appendicitis or thrombosed hæmorrhoids. The process is associated with acute pain, and is followed by the symptoms of acute obstruction. The bowel becomes engorged with venous blood, and dies; its lumen is often occupied by a blood-stained effusion, and the passage of dark tarry stools may be noted. The peritoneal cavity contains a quantity of blood-stained serum which after a time becomes offensive. A diagnosis is rarely reached apart from operation for the obstructive phenomena, and the only hope for the patient is removal of the gangrenous bowel (if that be possible) and a temporary enterostomy. Should the patient live (a very doubtful contingency) the continuity of the gut may be subsequently restored.

The **Mesenteric Glands** are frequently inflamed in consequence of intestinal lesions, *e.g.* typhoid ulceration or chronic appendicitis. No special notice is taken of this occurrence, unless suppuration ensues, when the abscess must be opened. In less severe cases, however, it is often associated with a patch of localized peritonitis, resulting in the deposit of plastic lymph; to this some other viscus, *e.g.* the free end of the omentum, the fimbriated extremity of the Fallopian tube, the vermiform appendix, one of the appendices epiploicæ, etc., may become adherent, and an adhesion may develop which subsequently leads to intestinal obstruction. As a matter of fact, the great majority of intra-abdominal bands are connected at one end with the mesentery.

Tuberculous Disease of the mesenteric glands is a common affection in children, constituting a condition known as *tabes mesenterica*. It is probably secondary to intestinal lesions, and when widely diffused through the mesentery is, of course, to be dealt with only by hygienic and medical measures. The results of such treatment are frequently very satisfactory, but tuberculous peritonitis may follow. Sometimes the glands undergo calcification, and these may lead to a mistaken diagnosis if a patient is examined radiographically for supposed ureteral calculus. At other times the caseated glands may liquefy and give rise to an inflammatory attack that may be mistaken for appendicitis, if the mesentery of the lower end of the ileum is involved. Limited masses in the iliac fossa may sometimes be amenable to surgical measures, and are removed; and occasionally the surgeon has to deal with a gland which has suppurated and requires to be opened. Adhesions also form between the glands and surrounding parts, and intestinal obstruction may result.

Cysts of the mesentery are not common and are usually of lymphatic origin; they may be single, containing either lymph or chyle, or multiple, then constituting a cavernous lymphangioma. Blood cysts have been known, and also dermoids, which are usually located in the mesentery of the ileum. A rounded, tense intra-abdominal swelling gradually develops behind or below the umbilicus; it is freely movable from side to side, and is usually accompanied by some derangement of intestinal function. When of large size, the swelling is dull, but is often crossed by the affected loop of bowel; it may possibly be mistaken either for an ovarian or a pancreatic cyst. The diagnosis is usually made on the

operating-table, and the treatment consists in enucleation or drainage, with or without removal of the affected coil of intestine.

Tumours form occasionally in the root of the mesentery and behind it, constituting the retroperitoneal lipoma or sarcoma. The former may grow to a large size, and destroy life by its pressure phenomena; the latter, though sometimes resembling the former in structure, invades surrounding tissues earlier. The diagnosis is uncertain until the abdomen is opened, and the question of removal is dependent on the relation of the growth to the mesenteric vessels, which must not be injured. It is seldom that a retroperitoneal sarcoma can be enucleated, and treatment by irradiation must be employed.

Affections of the Stomach.

The cardiac orifice lies about 4 inches behind the junction of the seventh costal cartilage with the sternum; the highest part of the fundus reaches the fifth left rib in the mammary line; the pylorus when the stomach is empty is in the middle line midway between the suprasternal notch and the symphysis pubis (Addison's transpyloric plane). When the stomach is full, the pylorus passes more or less to the right of the middle line and descends slightly. The lower border can usually be defined with tolerable accuracy by auscultatory percussion; this is performed by applying a stethoscope over the centre of the stomach area and percussing outwards over the margin; a change in note is readily recognized on reaching the border of the stomach.

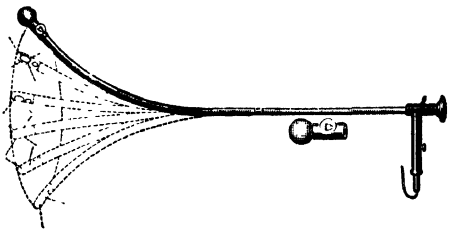

FIG. 779.—GASTROSCOPE

When the stomach is pathologically dilated, the pylorus and lesser curvature are retained more or less in position by the gastro-hepatic omentum, so that the organ pouches down towards the pelvis and becomes an elongated sac, in which fluids accumulate and decompose and gas collects. Peristaltic waves can often be seen crossing the viscus, and on succussion or tapping the organ with the finger-tips, gurgling and splashing sounds are heard.

Radiography has also proved of service in demonstrating the activity and shape of the stomach after the administration of a barium meal, which consists of a mixture of 2 or 3 ounces of barium sulphate in gruel or bread and milk. X-ray photographs or screen examinations are then made at intervals, so that the changes in shape of the stomach as indicated by the shadow cast by the barium can be ascertained. The greater curvature of the stomach should reach to a little below the level of the umbilicus (this owing to the weight of the barium meal), and the viscus should empty itself in about four hours. The

PLATE XXI



1. Closed pylorus.



2. Large benign ulcer on the posterior wall of the stomach; the floor of the ulcer being formed by the pancreas.

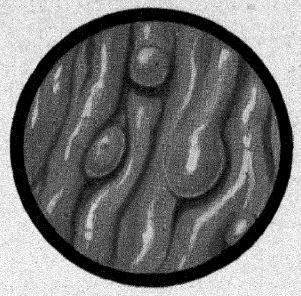

3. Multiple polypi on the posterior wall of the stomach.

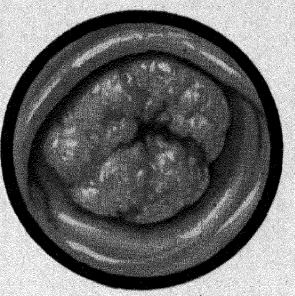

4. Carcinoma of the pylorus. Ulceration has taken place.



5. Large infiltrating carcinoma of the pylorus.



6. Posterior gastro-enterostomy opening as seen with the gastroscope.

Gastroscopic Pictures

shape of the pyloric end is also a matter of great significance. Considerable variations in the results, however, occur according to the position of the patient during the examination, *e.g.* whether erect or recumbent; the latter possibly gives more accurate information.

Gastroscopy has of late become a useful adjunct to the surgeon since the introduction of the flexible gastroscope. The contra-indications are the same as for the introduction of any tube into the stomach, namely, aneurism, carcinoma of the cardia and œsophageal varices. The modern flexible gastroscope (Fig. 779) has three main advantages: (1) safety, (2) visualization of the greater part of the stomach, (3) minimum of discomfort (Fig. 780)

The movements of the stomach can also be observed. Ulcers on the lesser curvature and early carcinomas can now be definitely

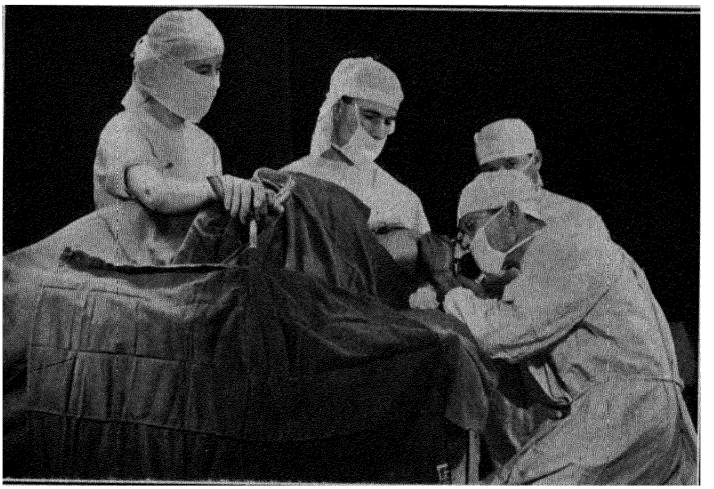

FIG. 780.—THE GASTROSCOPE IN USE (MR H C EDWARDS)

diagnosed with this instrument. Duodenal ulcer and the juxta-pyloric ulcer, however, remain invisible (Fig. 781 and Plate XXI.), and must be diagnosed by means of radiography.

Much may be learnt of the functions of the stomach by a careful examination of its contents and secretions. It is a simple and often very valuable procedure to remove the **gastric residuum** by means of a Reyfuss tube and a 20 c.c. syringe. The patient is allowed no food or drink overnight, *i.e.* for twelve hours or more, and the contents of the fasting stomach are then withdrawn and examined as follows:

(*a*) *Chemically.*—The normal volume of the gastric residuum varies from 20 to 50 c.c.; a quantity greatly in excess of this suggests dilatation of the stomach. The average normal total acidity is about 0·11 grm.

per cent., calculated as hydrochloric acid; the average normal content of free hydrochloric acid is about 0·07 grm. per cent. About 10 per cent. of healthy individuals, however, exhibit hyperchlorhydria, and about 4 per cent. achlorhydria. The presence of organic acids, *e.g.* lactic acid, is pathological, indicating the existence of fermentation, which can only occur in the more or less complete absence of free HCl, because the organisms responsible for this change cannot thrive in an acid medium. The finding of blood may be significant, if one can exclude its origin from the gums or mouth, or from injury by the tube. The presence of bile denotes regurgitation from the duodenum, but this is really of little significance, as it has been demonstrated in a certain proportion of healthy individuals. There should not be more than a trace of mucus, and no starch should be present.

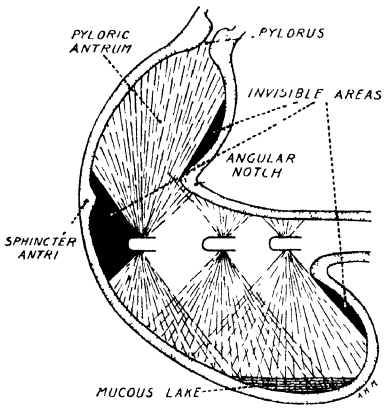

FIG 781 — DIAGRAM SHOWING THE EXTENT OF THE INTERIOR OF THE STOMACH SEEN BY THE GASTROSCOPE

(*b*) *Microscopically.* — There should not be any cells, food residue, or organisms other than those derived from the mouth by swallowing the saliva. In pathological conditions pus cells may be found, as also red blood-corpuscles, endothelial (wandering) cells with phagocyted blood-pigment, or rarely tumour cells. Squamous epithelial cells are of no significance, being frequently detached from the mouth, pharynx, or œsophagus. Starch granules, cellulose remains, or undigested muscle fibres indicate great delay in digestion.

(*c*) *Bacteriological* examination is generally regarded as of little value. Boas-Oppler bacilli are fairly common whenever lactic acid fermentation occurs, and are accordingly not unusual in gastric carcinoma.

The chief value of examining the gastric residuum is that the microscopical picture is not lost in a host of starch granules and yeast cells, as in the Ewald test meal. The disadvantage is that it is not an investigation of the response to a stimulus.

In the original **Ewald test meal** toast without butter and tea without milk were administered on a fasting stomach. At the end of one hour the gastric contents were withdrawn and examined as outlined above. Under these conditions the average normal total acidity is 0·15 to 0·26 grm. per cent., estimated as HCl, and the free HCl 0·07 to 0·15 grm. per cent. This test is improved by a preliminary withdrawal of the gastric residuum, which in particular cases may amount to several hundred c.c. of fluid, and so materially affect the results.

The Ewald test meal has been largely replaced by fractional methods of gastric analysis, because it has been shown that the acidity values

vary considerably at different intervals after the meal. In the **fractional test meal** a Ryle or other tube is passed after a night's fast, and the gastric residuum removed and examined (Figs. 782 and 783). With the tube *in situ* a meal of oatmeal gruel previously strained through muslin is given, and at intervals of fifteen or twenty minutes a small sample (5 to 10 c.c.) of the gastric contents is removed until the stomach is empty. The acidity results are plotted, and the form of the curve examined. Considerable modifications occur, so that these records alone are not diagnostic of any particular disease, but must be considered in conjunction with the results of chemical and microscopical examinations and with the clinical findings. The normal period for the complete disappearance of starch from the stomach is two hours or slightly less. **Hyperchlorhydria** is present in the great majority of cases of chronic duodenal ulcer, and is not uncommon in other examples of reflex dyspepsia, *e.g.* gall-stones or appendicitis, and in pyloric lesions causing spasm of the sphincter. **Achlorhydria** is present in many, but in by no means all, cases of gastric carcinoma. There is no constant finding in gastric ulcer.

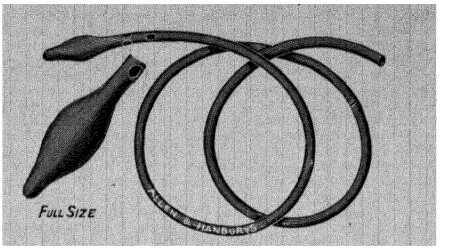

FIG 782.—RYLE'S TUBE, FOR USE IN ASPIRATION OF CONTENTS OF STOMACH

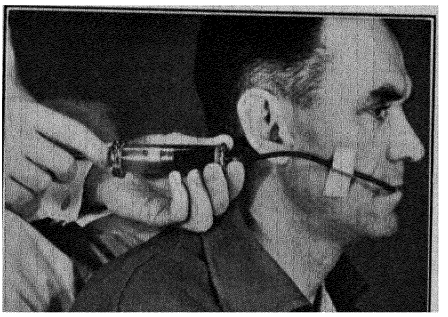

FIG. 783.—ASPIRATION OF STOMACH.

A Ryle's tube is in the stomach and a 10 c.c. glass syringe is attached to its free end. A piece of adhesive plaster keeps the upper end of the tube fixed to the cheek.

Rupture of the Stomach results from blows or falls upon the epigastrium, especially after a heavy meal, and then usually involves the pyloric end or the greater curvature near the cardiac orifice. It may also follow a penetrating injury, such as a stab or a fall upon a spike or railings. Neighbouring viscera are not unfrequently involved, especially the liver or spleen.

The **Symptoms** are those of severe and prolonged shock, with epigastric pain and vomiting, the ejected material sometimes containing blood, acute septic peritonitis usually ensues in a very short time, causing rapid collapse and death. If, however, the wound is small, or the organ empty, there is little or no extravasation, and then a localized intraperitoneal abscess may form, shut off from the general

peritoneal cavity by adhesions, and sooner or later bursting and discharging into the stomach, colon, or one of the hollow viscera, or else coming to the surface and bursting externally; sometimes the barrier of adhesions gives way, and a late general peritonitis results. If the posterior wall of the stomach is alone injured, the resulting phenomena are very similar to those due to the perforation of an ulcer in this region (*q.v.*).

Treatment—As soon as the diagnosis is tolerably certain, the only hope of saving the patient's life lies in immediate operation. A median incision is made above the umbilicus, the situation of the injury in the stomach ascertained, and the aperture closed by a double row of sutures (Czerny-Lembert), which infold the margins, and extend a little beyond the lesion at either end (Figs. 767 and 769). All extravasated material should be carefully sponged or swabbed away, and if the general cavity has not yet become inflamed, irrigation should be avoided for fear of carrying infective material to other regions. If the posterior wall is also injured, as by a bullet wound, an opening should be made through the omentum so as to deal with it, as also to explore and cleanse the lesser sac of the peritoneum. If the case has been operated on early and there is but little peritoneal inflammation, the parietal wound may be closed entirely; but it is sometimes necessary to insert a cigarette gauze drain in the upper part of the serous cavity. If the general cavity is inflamed, the treatment suitable to acute peritonitis must be instituted.

Foreign Bodies in the stomach consist either of those which have been swallowed accidentally or intentionally, or of concretions, *e.g.* hairs, wool, etc., due to the constant ingestion of small portions, which remain in the viscus and after a time form large masses. The presence of the former is known from the history, whilst the latter give rise to symptoms of gastric irritation, the cause of which is inexplicable until the mass has attained such a size as to suggest the presence of a tumour. The only treatment for a large foreign body is to open the organ and remove it (gastrotomy); where, however, it is small, *e.g.* a coin, it may be allowed to pass onwards.

Acute Phlegmonous Gastritis is an affection due to bacterial invasion of the submucous coat of the stomach, which is infiltrated with leucocytes and fibrinous exudation, together with many organisms, especially streptococci. This process usually ends in suppuration, which may manifest itself as a diffuse purulent infiltration, or as a more or less localized abscess; or the whole mucous lining of the stomach may be cast off as a slough and vomited. Such a condition, if not fatal from exhaustion, toxæmia, or general peritonitis, will be followed by extensive stenosis, which may demand operative treatment. The disease usually occurs in men who suffer from chronic dyspepsia, and is lighted up by injudicious dietary, excess of alcohol, or possibly the taking of corrosive poisons. It may develop as a secondary result of ulceration or of operation. The symptoms consist of epigastric pain, persistent vomiting, and marked restlessness, going on to delirium or collapse; the pulse is quickened, and there is moderate fever. The diagnosis is usually uncertain, perhaps that of a perforated ulcer being most commonly made. At operation, if a localized abscess in the stomach

wall is found, this may be drained and a jejunostomy instituted. Usually, however, the whole stomach is involved, and in these cases some recommend the exteriorization of the whole organ, maintaining it in this position by a glass rod passed underneath it through the lesser sac, this latter also being drained and an enterostomy performed. Multiple incisions are then made into the stomach wall to let out the pus.

Chronic Peptic Ulceration.

In discussing gastric and duodenal ulcers of this type, it is desirable to include them under the general heading of peptic ulceration, as they have so many signs and symptoms and ætiological factors in common, and to point out in the course of the discussion the differentiations which are dependent on the site of the ulcer.

Peptic ulceration is a condition which is said to occur at one time or another in 10 per cent. of the population. Although there are many known factors which are associated with the causation of the ulcer, the latter is unknown. Many of these ætiological causes are common to humanity, and yet only a proportion of those living under similar conditions are afflicted with the disease. Peptic ulcer of a chronic type is more common in men than in women, in the proportion of three to one, though the acute ulcer is more common in women. This is remarkable in that it seems probable that chronic ulceration starts originally as a small pin-point acute condition. Gastric ulcers are said to be becoming more uncommon and duodenal ulceration more frequent, but it must be pointed out that many cases of ulceration in the duodenum, close to the pylorus, have been included in the category of pyloric and therefore gastric ulcers. The proportion of chronic ulcers to-day occurring in the duodenum is, however, 80 per cent.

(*a*) The **Acute Ulcer** (Fig. 784) is not uncommon in young women between the ages of twenty and thirty years, and is associated with pain, vomiting, and hæmatemesis. It commences probably as a small abrasion, crack, or fissure, which deepens quickly, and may thereby involve an arteriole and cause bleeding. Its progress is sometimes so rapid that perforation occurs, owing to the lack of a defensive reaction in the peritoneum. It is probably due largely to an infective condition of the mouth and teeth, or sometimes of the appendix or biliary passages. It is rarely larger than a sixpenny-piece, and 'develops with almost equal frequency at any spot between the cardia and the pylorus along the upper margin of the stomach, and more frequently on the posterior than on the anterior surface' (Fenwick). 'It is not unusually multiple, two ulcers being often found exactly opposite one another, suggesting an infective origin. They are circular in shape, and with the edges sharply defined and clearly cut; each successive coat is destroyed to a less degree than the one internal to it, so that the sore is funnel-shaped. Should perforation occur, the opening is not central, but slightly to one side. These acute ulcers heal without much difficulty, as is evident from the number of radiating cicatrices seen on the post-mortem table. They give rise to

no stenosis, except perhaps when they are actually situated within the pyloric orifice. Hæmorrhage from this variety is not uncommon, but rarely fatal.

The **diagnosis** and **treatment** rest rather with the physician than with the surgeon, but his assistance is always required in cases of perforation, and sometimes he is consulted concerning hæmorrhage. The symptoms and treatment of *Perforation* are very similar to those for the chronic variety, and need not be discussed separately. As regards the treatment of *Hæmorrhage*, the surgeon must never be tempted lightly to undertake operative measures in the hope of finding and dealing with the bleeding point. The condition is rarely fatal, and reliance must be placed on the usual medical measures, *viz.* complete rest to the organ, both physical and physiological, the administration of morphia, possibly the application of an ice compress to the abdomen, the hypodermic injection of blood-serum, as a hæmostatic or a whole-blood transfusion, and the rectal infusion of an abundance of salt and water with glucose. All sources of infection in the mouth, nose, or pharynx should be dealt with, and if the bleeding recurs seriously it may be desirable to explore the abdomen for other sources of trouble, *e.g.* the appendix or biliary tracts, but not until the bleeding has ceased and the patient's condition justifies it. Of course, other causes of gastric hæmorrhage connected with the liver, spleen, or heart must be remembered and taken into consideration.

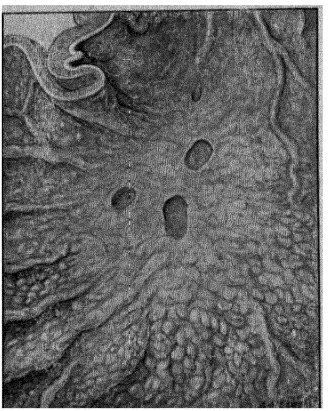

FIG. 784 — ACUTE ULCERS OF STOMACH (KING'S COLLEGE HOSPITAL MUSEUM)

Chronic Ulcer.

Ætiology—1. **Predisposition.**—There seems no doubt that there are certain types which may be said to be predisposed to either duodenal or gastric ulceration. Duodenal ulcer is relatively common in the active, 'full of energy,' mentally alert, and intelligent type of patient, those so often found in the professions. Barum meals in this type show a fairly small transversely placed stomach, the so-called 'steer horn' stomach, an appearance which is never associated with gastric ulcer. These latter occur in patients, as a rule, of rather the opposite type, the slow and rather sluggish, in whom X-ray reveals a somewhat toneless J-shaped stomach. These factors of themselves will not give rise to an ulcer, but, associated with other divergences from the normal, the liability to ulcer formation is increased.

2. **Acid Factor.**—An increase above the normal in the free acid is present in peptic ulceration, this being greater in duodenal than

gastric ulcer; yet this of itself is not the only factor, as has been confirmed in animal experiments where free acid, far in excess of that found in man, has been introduced without ill result.

3. **Traumatic Factor.**—The majority of gastric ulcers (some 70 per cent.) occur along the lesser curvature of the stomach, about 20 per cent. in the pylorus, and the remainder elsewhere. This peculiar viability of the lesser curvature has been explained by supposing that it is more subjected to trauma than other parts, or the gastric contents are propelled along this so-called 'Magenstrasse.' The common site of duodenal ulceration in the duodenal bulb is similarly explained by supposing that this is always receiving the full impact of the gastric contents forcibly ejected through the pylorus.

4. **Vascular Factor.**—There is undoubtedly a poor blood-supply along the lesser curvature, and this has been suggested as a contributing cause in the production of ulceration in this region.

5. **Toxic Factor.**—It has long been known that peptic ulceration may be associated with septic conditions, such as may occur with appendicitis or with burns. Rosenow has, in animal experiments, produced peptic ulcers by inoculation with non-hæmolytic streptococci isolated from gastric ulcers and from infected throats. It thus seems that any focus of infection in the body may, in all probability, be instrumental in producing a lesion in the stomach mucosa which may perhaps, with the influence of other factors, proceed to a chronic state.

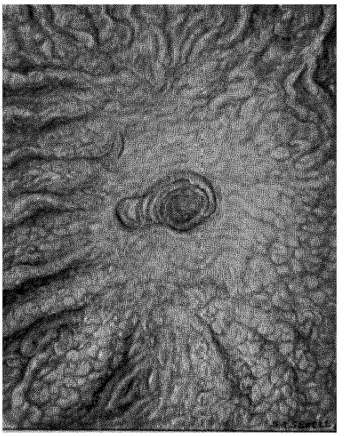

FIG. 785.—CHRONIC ULCER OF STOMACH. (KING'S COLLEGE HOSPITAL MUSEUM)

6. **Neurogenic Factor.**—Cushing has brought forward evidence to show that stimulation in the region of the mid-brain can produce ulceration, which in some of his cases has proceeded to rapid perforation and hæmorrhage. It seems, therefore, that in a proportion of cases ulcers may have their causation in some nervous factor.

7. **Vitamin Deficiency Factor.**—A comparison of the foods in those parts of India where ulcer is rare and where ulcer is common has shown that in the latter there is a marked deficiency of vitamin A. That this lack of vitamin may play a prominent part in ulcer causation is emphasized by the fact that in those districts where ulcer incidence is common, it is rare in the army where a well-balanced diet is taken.

8. **Diet Factor.**—There is no doubt that alcoholic excess, heavy smoking, and the taking of highly spiced foods are associated in patients

with an abnormally high proportion of peptic ulcer. These factors are instrumental in producing a high gastric acidity, and this, as has been noted, is an essential for the production of ulceration.

Pathology.—Peptic ulcers are usually single, although more than one may be present (Fig. 785). This is of importance in that perforation may occur at the same time from two separate foci. In size they extend to an inch or more, though the very large ulcers are suggestive of malignant change. All coats of the stomach are involved in the eroding process, and the whole is surrounded by an area of infiltration. This thick fibrous tissue probably accounts for the lack of natural healing in that the blood-supply is diminished and healthy granulation and new epithelium are difficult to establish. The ulcer is covered by debris, under which is poor anæmic granulation tissue lying on hard fibrous tissue, and, if it has extended to the peritoneal surface, adhesions to neighbouring organs are likely to form. Old ulceration is represented by scarring on the outer side of the stomach, and this may be so marked as to obliterate its lumen, with the production of an hour-glass stomach, or pyloric stenosis.

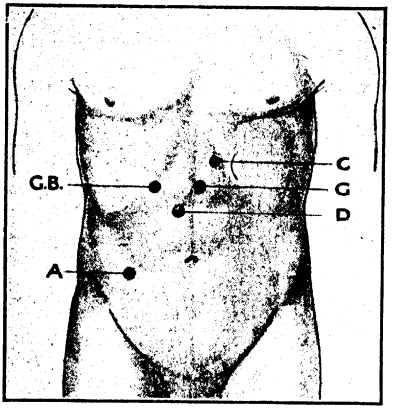

FIG 786.—TENDER SPOTS IN ABDOMINAL LESIONS.

C, In ulcer of stomach near the cardiac orifice; G, in the ordinary type of gastric ulcer; D, in duodenal ulcer; GB, in affections of the gall-bladder, A, in appendicitis.

Malignancy occurring in gastric ulceration is most common in the region of the pylorus, and, although there is no uniformity of opinion as to its rate of occurrence, it probably occurs in some 8 per cent. of cases.

It is impossible to discuss the **Symptoms** *in extenso*, medical works must be consulted for a full consideration of that subject. It must suffice here to indicate the more important points. The patient is generally brought under observation for *pain*, which has probably already lasted for some time; it is referred to the epigastric region and to the back, and is accompanied by a tender spot a little below the ensiform cartilage (Fig. 786) and by muscular rigidity of the upper part of the abdominal wall. It develops frequently at night, and may be sufficiently severe to waken the patient. Its relation to the ingestion of food is interesting, in that there is usually an interval of freedom after meals, lasting from a quarter of an hour up to perhaps two hours, increasing with the nearness of the ulcer to the pylorus. Rest and careful dieting relieve this symptom, as also the vomiting, which is of pretty constant occurrence in this condition (Plate XXII.). *Hæmorrhage* is very liable to take place; if in small quantities, it may

PLATE XXII.

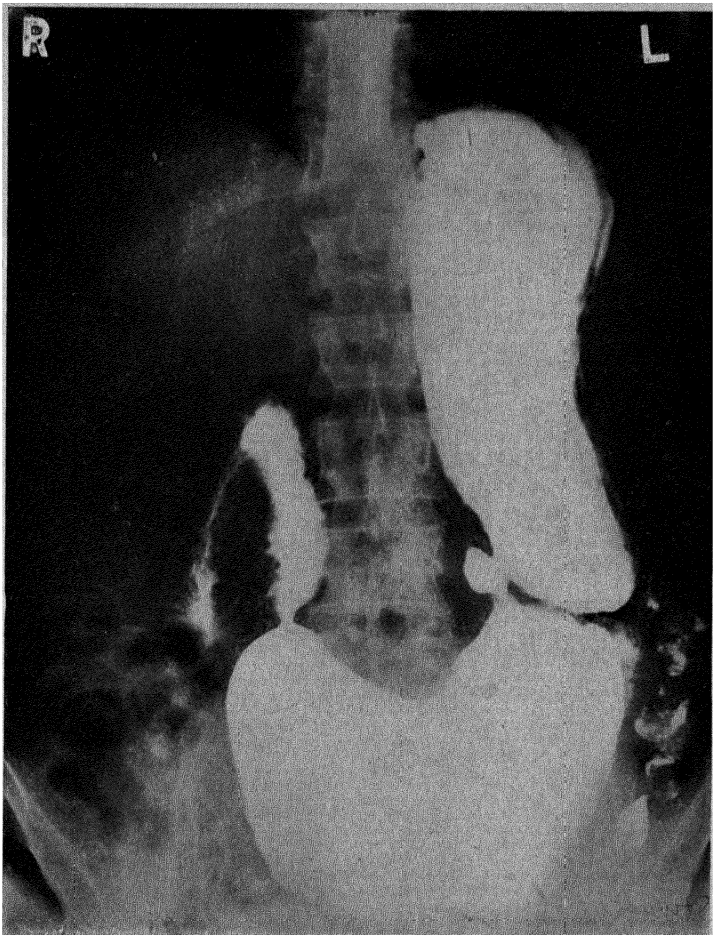

GASTRIC ULCER CAUSING HOUR-GLASS CONTRACTION

Note the barium-filled excrescence on the lesser curvature, and the deep incisura, opposite it, invaginating the greater curvature (Confirmed by operation)

be occult, and must be looked for in the fæces microscopically or chemically; but if abundant, it becomes obvious either as hæmatemesis or melæna, and may prove fatal before help can be given. The quantitative and qualitative examination of the gastric contents may throw some light on the case, but the results, though interesting, are not as a rule absolute *Radiography*, on the other hand, is really helpful, but requires expert assistance. It is possible for some of the barium of a test meal to remain in the hollow of the ulcer, and it can sometimes be seen, especially in profile, as an abiding dark patch.

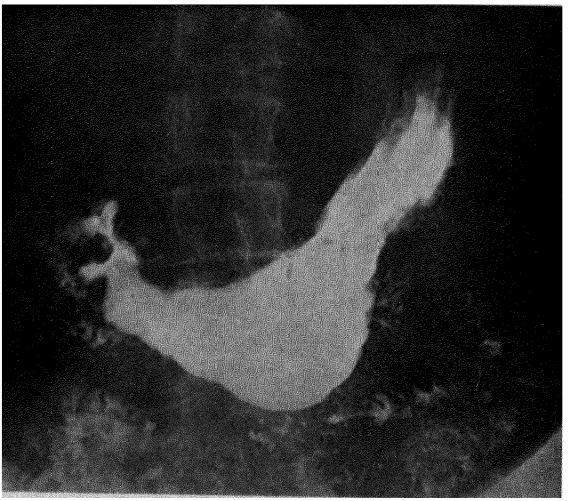

The ulcer crater is seen as a barium-filled excrescence on the inner border of the first part of the duodenum, radiologically termed the 'cap' or 'bulb.' The inner border and the outer border show general deformity, owing to associated scarring and spasm (Confirmed by operation)

Irregularity in filling of the organ and abnormality of the duodenal cap also occur (Figs. 787 and 788), whilst contraction of the stomach may lead to a constriction deformity easily recognizable.

The course of such a case of chronic ulcer is often prolonged. Periods of improvement, as a result of rest and careful dieting, alternate with attacks of pain and vomiting, and at any time the complications noted below may supervene. Finally, it is possible that carcinoma may develop on the site of a chronic ulcer.

There is no doubt that cases of gastric and duodenal ulceration should be subjected to a prolonged period of **Medical Treatment,** and this must include attention to those factors suggested in discussing the ætiology of the condition, before any surgical interference is contemplated. Duodenal ulcers respond more readily to medical

treatment than gastric ulcers, although they are more likely to recur. When, however, this fails, without the presence of any other complications, surgical intervention is indicated.

At the present time there can be said to be no uniformity of opinion with regard to the line of **Surgical Treatment** to be adopted, for, up till recent years, gastro-enterostomy was pre-eminent, but many surgeons now prefer to do a partial gastrectomy. Yet now there is



FIG. 788.—SKIAGRAM OF A CASE OF DUODENAL ULCER.

The 'cap' is constricted by spasm into a typical trefoil shape. The ulcer, which is on the posterior wall, and therefore covered by the barium in the cap, can just be distinguished in the radiogram as a spot of increased barium density in the outer part of the inner leaf. On screening, the remainder of the barium could be expressed from the cap and the fleck of barium residual in the ulcer crater seen. (Confirmed by operation)

a swing back to gastro-enterostomy, for the successes of the latter operation are not so outstanding as was at first thought. Simple excision of the ulcer is attended by a recurrence rate of at least 50 per cent., and its use has been abandoned.

Gastro-enterostomy may be performed for gastric ulcer either alone or in association with excision of the latter, this procedure, according to its advocates, having a mortality of about a third that of partial

gastrectomy—that is, 2 to 3 per cent. compared with 8 to 10 per cent. Moreover, they state that excellent results are obtained in some 80 per cent. of cases, recurrence of ulceration or anastomotic ulceration being stated to be some 6 per cent. It is impossible to obtain any absolute figures as the statistics disagree, and, moreover, some authorities include all ulcers occurring in the region of the pylorus as gastric, and others as duodenal ulcers. Most are probably the latter. Gastro-enterostomy allows a rapid emptying of the stomach, thus freeing the ulcer from unnecessary trauma, and associated with this emptying is a quick neutralization of the acid by the alkaline intestinal content. Partial gastrectomy, although associated with a very much higher primary mortality, aims at removing the acid-bearing area of the stomach, and thus one of the most important factors in ulcer production. Yet, in spite of the excellence of its conception, anastomotic ulcers and recurrences of ulceration occur, and deaths have been reported, resulting from perforation, in cases where an efficient gastrectomy has been performed. Moreover, there is a considerable proportion of cases in which the relief of symptoms is by no means complete, and the operation carries with it a number who, by reason of absolute achlorhydria or anæmia, become chronic invalids. In cases, however, where an ulcer is present on the greater curvature in the region of the fundus, in the pyloric region, or where, by virtue of its size, any doubt may be cast on the innocency of the condition, a partial gastrectomy is the operation of choice in that the liability of death from carcinomatous change is reduced.

A controversy on the value of the two operations in conditions of duodenal ulcer also exists. Those in favour of partial gastrectomy argue that these cases are always associated with a very high degree of gastric acidity, and only by removing the stomach in part can this be sufficiently reduced to allow of healing. On the other hand, gastro-enterostomy, associated with occlusion of the pylorus, is stated by others to be sufficient to allow of healing, though there seems to be no doubt that anastomotic ulceration is somewhat higher following this operation for duodenal ulcer than is the case in gastric ulceration.

Operative Treatment—Gastro-enterostomy.—There are various modifications of this procedure, which consists essentially of an anastomosis between the stomach and the duodenum or jejunum.

Many of these patients are in a poor condition on account of their previous inability to take an efficient diet without the onset of pain, and pre-operative treatment will consist in medical administrations and the gradual building up of the patient's strength by a controlled diet, including adequate quantities of glucose and fluid.

Posterior Retrocolic No-Loop Gastro-enterostomy is the operation of this type most recommended. A right paramedian incision is made and, after examining the abdominal contents, the duodeno-jejunal flexure is identified, and the first loop of jejunum is withdrawn from the abdomen and covered with a hot moist towel. The omentum and the transverse colon are then drawn at right angles out of the wound, and a comparatively bloodless area, to the left of the middle colic artery, is identified in the mesocolon and incised. The stomach is

drawn through this orifice and manipulated until an almost vertical segment, extending from the lesser to the greater curvature, of about 3 to 4 inches, protrudes. One half of a pair of gastro-enterostomy clamps are placed on this, the second pair being clamped to the loop of jejunum of similar length, after this has been drawn just tight enough, so that at the end of the operation there shall be no redundancy between the stoma and the duodeno-jejunal flexure. The clamps are approximated in such a way that the proximal part of the jejunum lies against the lesser curvature end of the stomach. A seromuscular continuous suture is then sewn, approximating the similar walls of the two viscera. The stomach and jejunum are opened near the first suture line. A second atraumatic needle and suture is then used to approximate all coats of the corresponding two walls of the stomach and jejunum towards the posterior aspect of the abdomen,

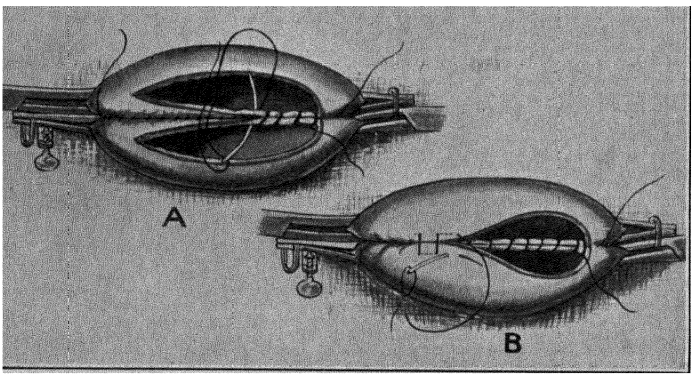

FIG 789.—POSTERIOR GASTRO-ENTEROSTOMY

A, Introduction of first hæmostatic suture, after the sero-muscular suture is completed, B, the return hæmostatic suture

and is continued to include those two situated anteriorly, great care being taken to ensure hæmostasis and watertightness in turning from the one pair to the other. The first seromuscular stitch is continued as a seromuscular stitch in front of the anterior stomach wall. It is advisable, before stitching this layer, to loosen the clamps so that any bleeding may be recognized and dealt with, and, when the final layer is sewn, these are removed altogether (Fig. 789).

Finally, before closing the abdomen, the opening in the mesocolon is closed about the stoma, usually being stitched to the stomach, any internal herniation is thus prevented.

Anterior Antecolic Gastro-enterostomy.—In this procedure a long loop of jejunum is brought in front of the colon, and an anastomosis is made with the front of the stomach wall. This operation is sometimes preferred by surgeons to that previously described, and especi-

ally is it valuable in cases where the stomach is small, where there is a gross amount of fatty tissue, or where the mobility of the organ is limited by adhesions obliterating the lesser sac, and perhaps attaching the stomach to the pancreas. An alternative in these cases is to bring the jejunum forwards through the transverse mesocolon, behind the colon, and to perform an anastomosis with the front of the stomach, the so-called **retrocolic anterior gastro-enterostomy.**

Gastro-duodenostomy has been recommended by some. There seems no definite advantage in this operation, and its technique is difficult. Moreover, it is often impossible to mobilize the duodenum sufficiently, and, secondly, the stoma is often so small that an added gastro-enterostomy has to be performed.

Any of these procedures may be associated with a local excision of the ulcer, diathermy to it, or pyloric occlusion, this latter being of importance in duodenal ulceration.

Post-operative Treatment.—The patient is treated for any shock that may be present on return to the ward, although this is usually slight. It is advisable to give nothing by mouth for twenty-four hours, but, in order to replete the body fluids, saline and glucose are administered either by mouth or by the rectum, strict attention being paid to oral hygiene. At the end of this period the patient is allowed an ounce of water hourly for eight hours, this quantity being doubled during the next similar period. Milk and water is then allowed, and the diet is gradually built up along the lines of medical treatment for peptic ulceration. For a prolonged period of six months to a year the patient should be exceedingly careful of his diet, and, as far as is possible, those factors that have been mentioned as ætiological causes of the condition should be avoided.

Complications are rare, as evidenced by the low mortality of the operation. Such conditions as chest complications or paralytic ileus, common to every abdominal operation, may occur. Vomiting, with the exception of post-anæsthetic vomiting which persists perhaps for twelve to twenty-four hours after the operation, is rarely seen with the posterior no-loop operation. It may occur if a long loop is left, if the stoma has been made too small, or if during the suture of the last through-and-through stitch the posterior wall has inadvertently been included.

Hæmorrhage is a complication that must be remembered. It may occur through inefficient hæmostasis at the time of the anastomosis, or, if the ulcer present has not been removed, this may bleed in the early days following the operation. The treatment is at first conservative, by administering morphia and the setting up of a drip transfusion of blood; but, if the bleeding persists, it is essential, before the patient has become too exsanguinated, to reopen the abdomen and deal with the bleeding point either by unsuturing the anastomosis and resuturing it effectively, or by opening the stomach and inserting another hæmostatic suture line from inside this viscus (Figs. 790 and 791). Bleeding from an ulcer may be controlled by excision or by undermining the bleeding point.

Anastomotic Ulcer is the term used to describe those ulcers occurring

in the region of the stoma following an anastomosis between the stomach and intestine. They may occur actually along the anastomosis, or an inch or so from it in the efferent loop, but very rarely occur in the afferent loop, presumably on account of the fact that it is bathed with an alkaline secretion. The causation of these ulcers is probably due to a persistence of the conditions producing the original ulceration, although various factors, such as the using of clamps, or unabsorbable ligature material, or the removal of redundant mucosa, have been blamed in the past. It is most common, occurring in some 6 to 8 per cent. of cases, where a gastro-enterostomy has been performed for duodenal ulceration associated with a gross degree of hyperacidity; even where a partial gastrectomy has been performed for this condition the incidence of anastomotic ulcer is still appreciable, about 1 per cent. In cases where gastro-enterostomy has been carried out for gastric ulcer, gastro-jejunal ulceration occurs in some 4 to 5 per cent. of cases.

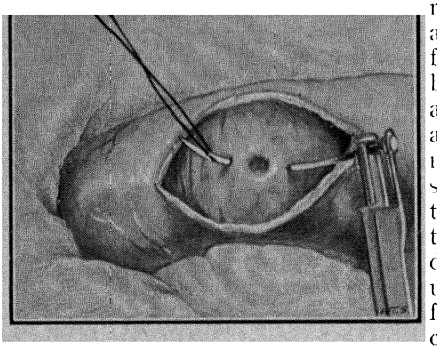

FIG 790.—SEVERE HÆMORRHAGE FROM A CALLOUS ULCER ON THE POSTERIOR WALL OF THE DUODENUM, SUCCESSFULLY CONTROLLED BY INCISION OF ANTERIOR WALL OF DUODENUM AND THE EMPLOYMENT OF A HEAVY NEEDLE OF THE BONNEY-REVERDIN TYPE (G GORDON TAYLOR)

Where no ulceration into the neighbouring transverse colon has occurred, the chief complaint is of pain, situated in the region of the epigastrium, of a particularly severe type, and less constantly related to poor intake than in the case of gastric or duodenal ulceration. Vomiting, and the administration of alkali, nearly always relieves the pain. Hæmorrhage, in the form of melæna or hæmatemesis, may occur and be of such severity as to necessitate

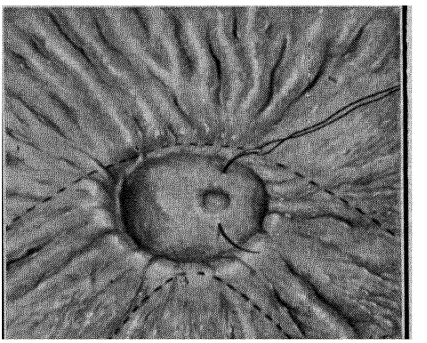

ULCER SUCCESSFULLY CONTROLLED AFTER ULCER HAD BEEN EXPOSED THROUGH AN INCISION IN THE STOMACH (G GORDON TAYLOR)

The bleeding was controlled by mattress sutures introduced by means of a Moynihan curved needle The jejunum is indicated in the illustration by dotted lines

surgical interference. Perforation occurs in about 10 to 15 per cent. of cases.

X-ray examination will often reveal one of several findings, usually a stenosed or deformed stoma, the presence of an ulcer crater, or the retention of barium in this crater when the rest of the stomach is emptied.

Initially, a prolonged period of medical treatment should be instituted, but if this fails to cure the condition operation should be advised. Various operative procedures, such as local removal of the

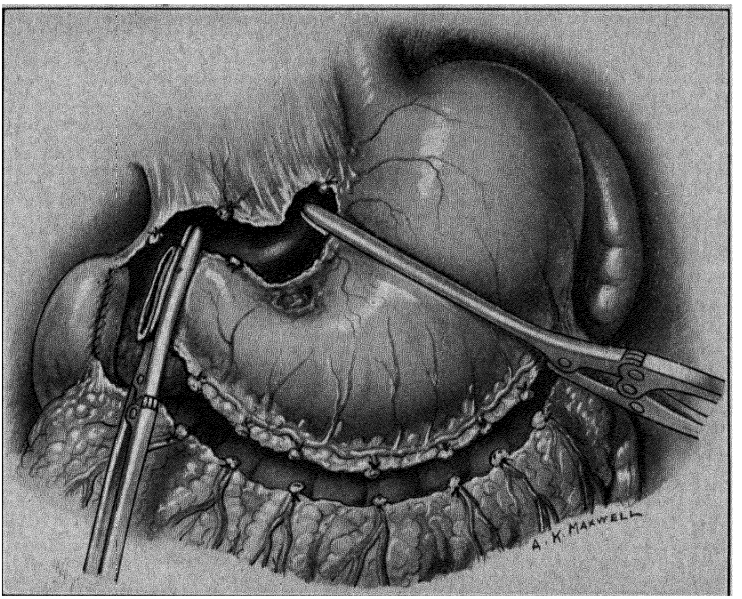

FIG. 792.—PARTIAL GASTRECTOMY
Clamps applied and the duodenum divided

ulcer, or the formation of a new gastro-enterostomy stoma with or without the repair of the old, have been tried, but the best procedure of all is to carry out a partial gastrectomy.

When a fistula occurs, either between the stomach and the colon, or the jejunum and the colon, or between all three, the patient rapidly loses weight and goes down hill. There is often severe vomiting, the vomit containing fæcal material, and this is associated with intractable diarrhœa. Pain is often conspicuous by its absence, as in many of these cases the actual ulcer rapidly heals.

Operation, which will consist in resection of the affected regions of the stomach, jejunum, and colon, with restoration of continuity of

the lumina, carried out in either one or two stages, should be performed. Some surgeons advise associating this with a partial gastrectomy.

Partial Gastrectomy.—In this operation, performed for peptic ulcer, an attempt is made to remove the acid-bearing area of the stomach

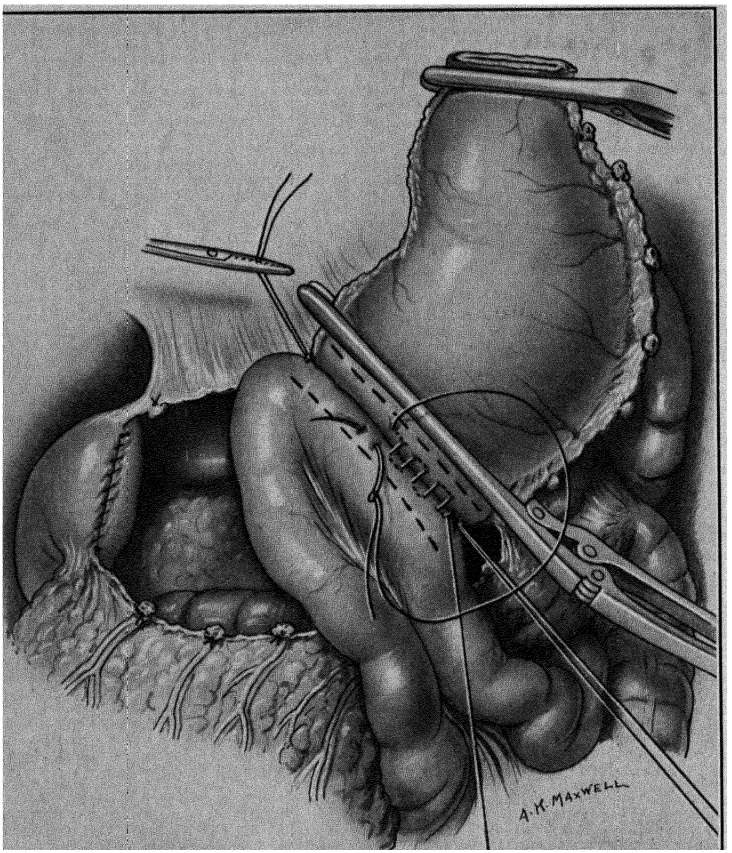

FIG 793.—PARTIAL GASTRECTOMY

The jejunum has been joined to the stomach in front of the transverse colon.

by an excision of that part of the viscus distal to a line joining the upper third of the lesser curvature with about the juncture of the lower with the upper three-fifths of the greater curvature (Figs. 792 and 793). In those cases where the operation is performed for duodenal ulceration, removal of the first part of the duodenum is indicated,

but in gastric ulcer this is not essential and not desirable, because the longer the duodenal stump the more easy is its invagination.

The original operation, carried out by Bilroth, consisted, after excising the required area of the stomach, in re-establishing continuity by anastomosis of the duodenum with the proximal end of the stomach (Fig. 794). This, however, was possible only if a very limited excision had been performed, and it was replaced by the Bilroth II. method, in which both the cut end of the duodenum and the cut end of the stomach were closed, and continuity established by means of a posterior gastro-enterostomy (Fig. 794). Nowadays one of the modifications of the Polya operation is usually performed. Through a paramedian incision the stomach is exposed, and the great omentum separated from its lower border, the right and left gastro-epiploic arteries being divided. The gastro-hepatic omentum is divided, identified, and ligatured. Two crushing clamps are placed on the pyloric end of the stomach or the first part of the duodenum after the latter has been carefully separated from the head of the pancreas, and with a cautery or diathermy the viscus is divided between the two. The duodenal stump is then closed by a continuous through-and-through stitch passing over the clamp, the suture being drawn tight and tied as the clamp is removed. A further layer or two of Lembert's sutures serve to ensure absolute closure of the stump.

The stomach is drawn well over to the left and the coronary artery identified and ligatured just proximal to the line along which resection of the stomach is to be performed. A light non-crushing clamp of the Sterren pattern is placed on the stomach again just proximal to the line of section. A loop of jejunum is then chosen, and this may be brought either in front of the transverse colon, or behind it through the mesocolon to the left of the middle colic artery. In the Moynihan modification the jejunum is lined from left to right by the side of the stomach, and in the Balfour modification from right to left, a second non-crushing clamp being used to steady the bowel and aid in its approximation. A sero-muscular stitch is used to sew the corresponding walls of stomach and duodenum together, the suture in the former being placed just proximal to the line of resection. The stomach is resected and then, after opening the jejunum, suture of the two viscera is attained in much the same way as in a gastro-enterostomy (Fig. 794).

It is desirable at the completion of the suture to sew the mesocolon to the anterior and posterior walls of the stomach where the operation is a retrocolic one, but in cases where resection has been extensive this will be impossible, and suture to the afferent and efferent limbs of the jejunum must be performed. Lahey, by dividing the ligament of Treitz, mobilizes the duodeno-jejunal flexure and brings this through and above the transverse mesocolon.

The after-treatment and immediate post-operative complications are similar to those described for gastro-enterostomy. In some cases, where only a very small duodenal stump is left for invagination, this may be inadequately performed and leakage occurs, giving rise either to a general peritonitis, a localized intraperitoneal abscess, or a sub-

phrenic abscess. If such a complication occurs, suitable treatment, including drainage of the pus, must be carried out.

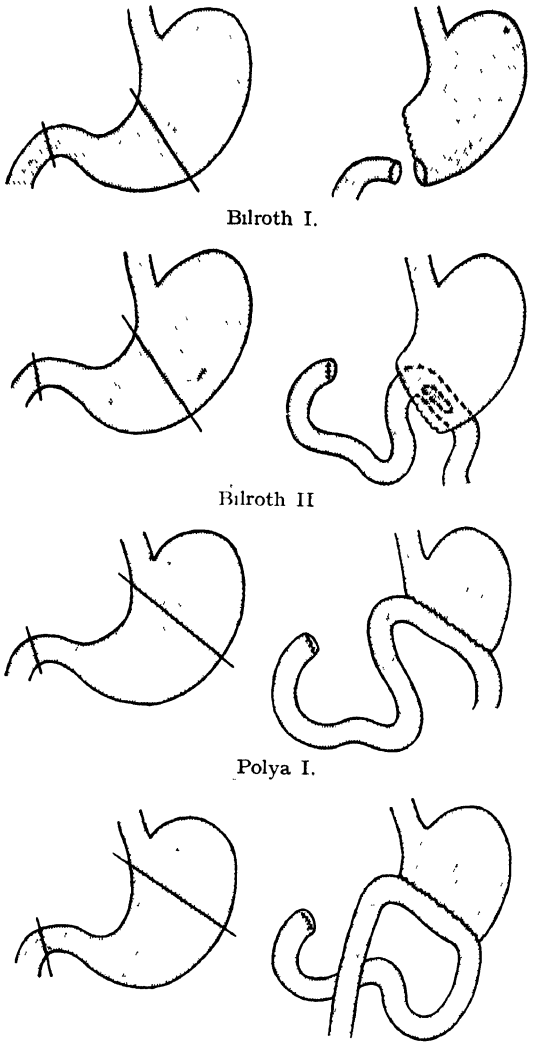

FIG 794.—METHODS OF PERFORMING PARTIAL GASTRECTOMY

Vomiting, except for post-anæsthetic vomiting, is extremely rare after the Polya type of operation. Should it occur, treatment should be conservative, by means of stomach wash-outs, as any œdema of

the stoma producing obstruction will settle down in a few days. Should it persist, however, a second operation may become necessary. If there is stagnation in the afferent loop, this must be anastomosed to the efferent loop, whereas if kinking has occurred as a result of retraction upwards of the stomach, the stitches in the mesocolon, suturing this to the jejunum, must be cut and the latter mobilized sufficiently, probably by division of the ligament of Treitz, so that it may be drawn well up to prevent any further obstruction. In some cases where the efferent loop is obstructed, this may be overcome by passing a nasal tube during the operation and directing this into the afferent loop. This is allowed to remain in position for a few days, at the end of which time the presence of œdema will have disappeared from the stoma and the orifice will prove sufficiently patent.

The **Complications** of ulcers of the stomach which call for surgical assistance are alike for the acute and chronic varieties, and may be considered together.

1. **Hæmorrhage** is responsible for a considerable proportion of the deaths from gastric ulcer. In the *acute* superficial form that occurs in young women, it is usually derived from some small arteriole, but, as suggested above, does not require operative treatment. Rightly handled, it is not a fatal condition. In the more *chronic* ulcers serious hæmorrhage may be derived from vessels of greater size, and then may even prove fatal before help can be given. Thus one of the larger branches of the coronary artery may be involved, or one of the enlarged varicose veins which are often found in the neighbourhood of an old ulcer; where there has been much destruction of the posterior wall, the base may be formed by the structures lying behind the lesser peritoneal sac, *e.g.* the pancreas, and the splenic artery is then sometimes opened, and an immediate fatality results. The treatment of this condition is one that calls for a fine degree of judgment in deciding when conservative treatment is to be abandoned and surgical treatment substituted. Most are agreed that if a hæmorrhage occurs this should be treated at first by sedatives and a continuous-drip blood transfusion, although some continental surgeons prefer to treat these cases by immediate operation. It is when the bleeding is not controlled at an early period by this treatment that the surgeon has to decide whether to persist with it for a little longer or operate at once. These patients are bad operative risks, and some cases will, when seemingly hopeless, recover with medical treatment. If operation is to be carried out, it must not be delayed to a point where the patient is so exsanguinated that little chance of survival is offered. We consider that if, in spite of the transfusion, the pulse is rising, and if a second hæmatemesis occurs, operation is indicated. This will take one of several forms. The ulcer may be excised, a bleeding point may be underrun, or a partial gastrectomy or gastro-enterostomy, with occlusion of the ulcer, carried out. After the operation blood transfusions, by the drip method, should be given.

2. **Perforation** is the commonest cause of death in patients suffering from peptic ulcer. It occurs more commonly in males than in females

and in duodenal more than in gastric ulceration, the perforation in 90 per cent. of cases being situated on the anterior wall. Perforation in acute cases of ulcer is rare. When the perforation is situated on the posterior wall, it may, in duodenal cases, give rise to an infection about the kidney, and this may track down in front of the psoas muscle, ultimately forming an abscess in the region of the right iliac fossa, which may mistakenly be diagnosed as an appendix abscess. Perforation from a posterior ulcer in the stomach may localize in the lesser sac of peritoneum, giving rise to one form of subphrenic abscess, or it may cause an infection between the two layers of the gastro-hepatic omentum. Where the ulcer has been isolated by the formation of adhesions round about it, the ultimate perforation will give rise to a perigastric abscess shut off from the general peritoneal cavity, and thus the patient will not manifest the signs and symptoms present when the perforation involves the whole abdominal cavity.

Rarely the signs of a perforation are the first signs of any gastric lesion, but usually the patient will give a history of severe dyspepsia.

The **Symptoms** vary with the size of the perforation, which may be minute or the size of a threepenny piece, and also with the distension and condition of the contents of the stomach. If there is much gastritis, they will be more heavily infected and obviously the onset of peritonitis is more rapid.

The patient is suddenly seized with agonizing abdominal pain first referred to the centre of the abdomen, but rapidly spreading all over. There is a gross degree of shock, although in the early stages the pulse rate is not raised. The patient lies perfectly still with his legs slightly flexed, afraid to move because of the pain that such movement produces. He is covered in a cold perspiration and is collapsed, and the collapse may be so severe that death results from this alone. The abdominal muscles are rigid, and no movement of respiration occurs in the abdomen. Vomiting occurs in about 50 per cent. of these cases. After a few hours the patient feels improved and the shock is diminished. But in spite of this, and the improvement in the volume of the pulse, the rigidity and abdominal tenderness persist. If operative interference is delayed, all the signs of diffuse peritonitis supervene.

Treatment.—As soon as a diagnosis has been made the patient's shock should be treated, morphia given to relieve the pain, and the patient prepared for operation. It is imperative to operate at an early hour, because delay is associated with a rapidly increasing mortality.

A paramedian incision is made and the ulcer sought for, the area of induration and deposition of fibrin normally making this quite obvious. If the œdema is gross, or if the patient's condition is extremely bad, the simplest procedure of tying a tube into the duodenum, through the perforation, should be employed. In other cases the ulcer should be closed by Lembert's sutures, which enfold and bury the ulcer, the site of lesion being reinforced if possible by an omental graft. A rapid inspection should be carried out to make certain that a second perforation does not exist. It is unnecessary to wash out the peritoneal cavity, and only where food is present is it necessary to do more than swab out the excess fluid. In cases where the perforation has

been present for more than a few hours, drainage through a suprapubic stab wound should be instituted.

The after-treatment of these cases is similar to that employed following gastro-enterostomy, the patient being nursed in the Fowler's position. Complications, such as subphrenic abscess, pelvic abscess, a paralytic ileus, must be treated as they arise.

In recent years some surgeons have advocated additional or alternative procedures, such as partial gastrectomy or gastro-enterostomy; but, in view of the low mortality associated with the simple operation of closure, this remains pre-eminent.

3. **Perigastric Inflammation** is a common result of ulceration, it may be either adhesive or suppurative in character.

Adhesive Perigastritis is in the first place protective in nature, consisting of a localized thickening of the serous wall. It is more marked in connection with chronic than with acute ulcers. The posterior gastric wall often becomes adherent across the lesser sac of the peritoneum to the serous membrane lying in front of the pancreas, and this fixity may be one of the factors which prevent the ulcer from healing, even as fixation to the periosteum over the tibia delays healing in an ulcer of the leg.

In a few cases adhesions form between the anterior wall of the stomach and the parietal peritoneum, and these may give rise to a localized fixed epigastric pain, usually increased considerably by distension of the organ; internal strangulation or obstruction may also be thereby determined. It can sometimes be treated by division of the adhesion between ligatures.

Suppurative Perigastritis may follow a small perforation with limited leakage, but is more usually due to a gradual extension of the ulcer and an invasion of the perigastric tissues by organisms which escape from the stomach. The result of this is the formation of what has been already described as a subphrenic abscess, which may or may not contain gas. It may burst anteriorly through the abdominal wall, or may perforate the diaphragm, giving rise to a basal empyema; and this in turn may burst into the lung or through the chest wall, so that fistulæ may appear in various places, through which the contents of the stomach may be discharged.

The abscess must be opened and drained in the way already indicated, but should a fistula form, it is almost hopeless to attempt to deal with it locally, and a gastro-enterostomy may then be required.

4. **Stenosis**, either in the region of the pylorus or in the body of the stomach, is always liable to follow cicatrization of peptic ulcers. In addition ulceration which has given rise to perigastric inflammation and adhesion formation may by virtue of this produce obstruction, the adhesions either distorting the body of the stomach or dragging on the pylorus. Spasm of the stomach muscles, secondary to a peptic ulcer, may simulate an organic obstruction, but this may be eliminated by the administration of belladonna.

Duodenal ulceration gives rise, in about 8 per cent. of cases, to pyloric obstruction, and in most of these patients it will be found that the ulcer is quiescent and healed. It occurs more commonly in males

and at a younger age than stenosis due to an hour-glass obstruction. Although the most common factor in producing this type of stenosis, other conditions such as carcinoma of the pylorus, carcinoma of the head of the pancreas, chronic pancreatitis, cholecystitis or carcinoma of the hepatic flexure may all give rise to it. In addition there is sometimes found no factor to account for the stenosis, and these cases are believed to be a persistence into adult life of congenital hypertrophic pyloric stenosis, a condition which will be considered subsequently.

In an endeavour to overcome the obstruction, the wall of the stomach hypertrophies, this eventually giving rise to dilatation of such a degree that the viscus may fill the major portion of the abdominal cavity.

Signs and Symptoms.—The patient will usually give a history suggestive of duodenal ulcer in the past. He complains of a more or less continuous dull, full feeling in his stomach, accentuated by fluid and solid intake. He notices that he starts to vomit, that this relieves the pain, and that the vomit is often very offensive and of large quantity. The patient may, when asked, state that he has noticed that he returns particles of identifiable food such as pips or pieces of skin taken many hours previously. There is loss of weight and appetite, halitosis, and increasing constipation.

On examination of the abdomen the outline of the distended stomach may sometimes be seen, and, rarely, waves of peristalsis may be observed. Percussion confirms the great increase in the size of the organ, and a sharp bimanual thrust given to the viscus may produce a splash, although no food or drink has been taken for hours previously. A barium meal will confirm the diagnosis.

Treatment consists in performing a gastro-enterostomy after thoroughly washing out the stomach on each of several days previous to the operation.

Hour-glass Stomach is produced usually secondarily to a horseshoe ulcer of the lesser curve of the stomach, this, by its healing by fibrosis, drawing up the greater curvature until the cavity of the stomach is divided into a distal and a proximal segment, the latter undergoing hypertrophy and dilatation in exactly the same way as the whole stomach does in pyloric obstruction. Rarely, if two ulcers are present, the stomach may be divided into three compartments. The condition occurs in older patients and, in addition to being the end result of a healing gastric ulcer, may exist as a congenital abnormality, be produced as a result of gastric carcinoma or specific ulceration, or occur as a result of perigastric adhesions.

The signs and symptoms are similar to those of pyloric stenosis, the patient, however, giving a history of gastric as opposed to that of duodenal ulceration. According to the situation of the constriction, whether towards the cardiac or pyloric end of the stomach, so the vomiting will follow rapidly on the intake of food or be delayed for some little while. In high obstruction in hour-glass cases the vomiting may follow so soon the taking of food as to simulate œsophageal obstruction.

Treatment.—Before operation is considered this is similar to that applying to pyloric stenosis. Many operative schemes have been devised, such as a double gastro-enterostomy, in which an anastomosis is made into each pouch, wedge-shaped excision of the area of stenosis with gastro-enterostomy, devised by Walton, gastro-gastrostomy, *i.e.* an anastomosis of the proximal with the distal pouch; or partial gastrectomy. Either the last or Walton's operation is probably the best procedure.

Congenital hypertrophy of the pylorus is a condition occurring more commonly in males, and in 50 per cent. of cases in first-born infants. The ætiology of the condition, in which there is a gross hypertrophy of the circular, and to a lesser extent the longitudinal musculature of the pylorus, of sufficient degree to produce obstruction, is obscure; it may possibly be due to prenatal hyperadrenalism or to an incoördination of the sympathetic and parasympathetic nervous system (Fig. 795).

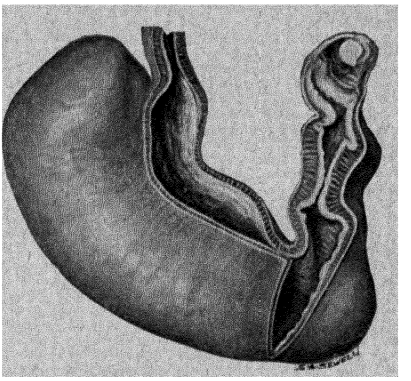

FIG 795.—CONGENITAL HYPERTROPHIC STENOSIS OF THE PYLORUS (ROYAL COLLEGE OF SURGEONS MUSEUM)

The child normally does well for the first two or three weeks of its life, and then it starts to vomit its feeds, the vomiting being of a projectile nature. A dietetic cause is often diagnosed, and the infant is either taken off the breast or a change is made in the food given it. For a few days it seems to improve, but the vomiting restarts. There is loss of weight and increasing constipation. The child is obviously hungry and thirsty, and will suck ravenously at any feed that is offered In the later stages of the disease the vomiting ceases to be projectile and oozes out of the child's mouth and nostrils.

The child is best examined following the administration of a little glucose water, when visible peristalsis may be made out. On palpation a solid cylindrical mass, about an inch in length, will be felt deep under the right costal margin, and the presence of this is the only certain diagnostic sign.

Treatment.—After preliminary treatment, consisting in stomach wash-outs, small frequent feeds up to two hours before the operation, injections of saline, Rammstedt's operation should be performed under either local or gas-and-oxygen anæsthesia. The pylorus is brought to the surface through a short right paramedian incision about 1½ inches in length. Steadied by the left hand, the pyloric sphincter is divided longitudinally throughout its length, the incision reaching well on to the stomach, where the muscular fibres shade off, but very cautiously towards the duodenal end, where the fibres end

abruptly and the mucous membrane may project and is liable t wounded (Fig. 796). The incision lies as near the continuation o lesser curve as possible, *i.e.* well back. When complete, the mu membrane projects into the gap as a hernial protrusion, and is l that condition. Bleeding is unusual, and can be arrested by pres and then the pylorus is replaced and abdominal wall closed. S is likely to be severe, and must be combated; the results of the oper are excellent. These patients are nearly always very greatly hydrated and their chlorides are very low. The mortality ca lessened if an abundant supply of saline solution is given both b and after operation. About six hours after the operation small of glucose and saline are commenced, these being gradually up with breast milk.

Fibromatosis of the Stomach, or **plastic linitis, cirrhosis of stomach,** is a very rare disease, characterized by a diffuse fi thickening of the submucous coat of the stomach (Fig. 797)

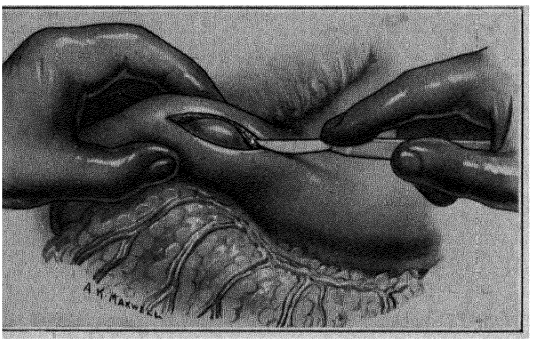

FIG 796.—RAMMSTEDT'S OPERATION FOR CONGENITAL PYLORIC STENOS

ætiology of this condition has been much discussed, some wi considering that it is secondary to diffuse atrophic carcinoma others that it is innocent. The condition has no connection wha with syphilis or tuberculosis.

It is more common in men than in women, and may be conside disease of adult life. The stomach may first be of normal size later becomes contracted. It has a whitish or pearly-white appea which is characteristic. On section (Fig. 797) the wall of the sto is found to be much thickened, the submucous coat being espec affected. The mucous membrane is normal, or may at times be u ated. The thickening is usually most pronounced in the pyloric re where ulcers are common, and the condition is possibly due to infe from this source.

The symptoms produced by fibromatosis are naturally vague, the diagnosis is rarely made except by X-ray examination.

With regard to treatment, gastrectomy should be performed v

stomach, and is of a lower-grade malignancy, having an adeno-carcinomatous appearance microscopically. Unfortunately, this type of growth, on account of the position it occupies in the stomach, is often slow to manifest itself, and is discovered only at a late stage in its growth. Colloid changes may occur in this type.

In the linitis plastica, or leather-bottle stomach, the walls of the organ are invaded by sclerosing carcinomatous growth in which many sections may have to be examined until one showing carcinoma cells is seen. The fibrosis draws in all coats, but mostly in the submucosa, and it may be either diffuse or limited to the pyloric region. The

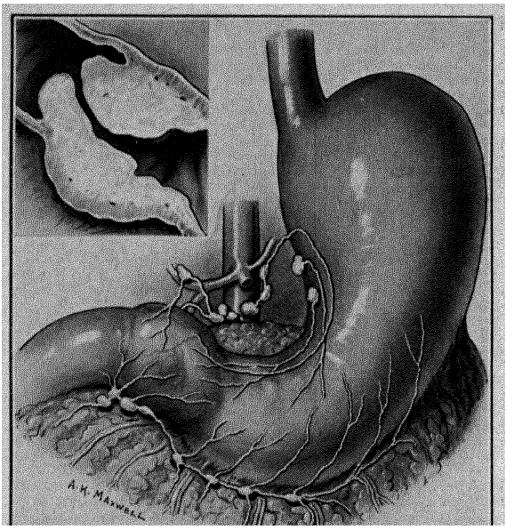

LYMPHATICS

Inset shows the growth at the pylorus on section.

stomach becomes eventually small and grossly contracted with a capacity reduced to two or three ounces.

In addition to local *spread*, the growth usually gives rise to early glandular metastasis. The pyloric glands are involved in growths situated towards the distal extremity, and the coronary and paracardial glands in growths higher up (Fig. 798). Glandular metastasis is late in carcinomas, occurring in the region between these two lymphatic areas of drainage. Glands in the region of the portal fissure become involved secondarily, and from here growth may spread along the ligamentum teres to give rise to secondary deposits at the umbilicus. In about 2 per cent. of cases the thoracic duct becomes invaded, and

secondary deposits are formed in the supraclavicular glands of Virchow in the posterior triangle of the neck—the so-called sentinel gland.

The extension of the growth outside the stomach will give rise to invasion of any of the neighbouring viscera, such as the pancreas, the liver, the transverse colon, or the jejunum. In addition, small clumps of cells may be detached and give rise to peritoneal transplants, especially in the pelvis, where they grow, subsequently giving rise to gross ascites.

Vascular invasion will give rise to secondary deposits in the liver, lungs, bone, or brain.

Signs and Symptoms may be so slight and indefinite that, unless extreme care is taken in assessing all the factors in the diagnosis, a mistake will be made in those early cases where surgery offers its best chance of cure. The late cases are so obvious that a diagnosis is easy, but, at such a stage, cure is unlikely.

Any patient over forty-five complaining of symptoms suggestive of disease of the stomach, where previously none has existed, should be suspected of having carcinoma of the stomach until this is disproved. Complaint may be made of loss of appetite, vague feelings of discomfort and fulness after food, flatulence, or loss of weight. Some may come complaining of breathlessness and palpitations, the result of the melaena so often associated with the disease. Nausea and sickness, actual pain in the stomach or the back, not relieved by food intake or alkaline, present on and off, day and night, with occasional relief in vomiting, are others of the rather indefinite complaints which may accompany a cancer of the stomach.

In those cases of chronic gastric ulcer in which malignant change is occurring, the characteristic pain of the former gives place to pain at first not so easily relieved by alkalies, and finally not relieved by them at all. The attacks become increasing in their severity and number, and the pain, instead of being relieved by vomiting, persists, and is present from the time of one meal to that of the next.

In those cases where the growth is high up in the stomach, the early symptoms resemble those of carcinoma of the œsophagus. There is difficulty in swallowing, perhaps pain behind the sternum, with often heartburn and water-brash. String mucus, sometimes bloodstained, may be vomited up in the morning. Loss of appetite and weight accompany the picture.

Where the growth is causing pyloric obstruction, it is often impossible to differentiate a carcinomatous cause from a non-malignant one, except that, in the latter, a history of past peptic ulceration is usually obtained. The stomach becomes enormously distended, and the presence of quantities of fluid is disclosed by ' balloting ' the organ. This is periodically vomited as large quantities of offensive content, often showing the presence of ' coffee grounds ' where bleeding has occurred.

In the late stages of the disease the patient becomes grossly cachectic and anæmic. Secondary deposits may be obvious in the skin or in Virchow's gland, and a mass is often easily palpable in the epigastric region. The leather-bottle stomach can sometimes be detected as a

solid mass emerging from under the left costal margin. The liver may be enlarged with deposits, ascites present, due to peritoneal deposits or to pressure on the portal vein, and the patient may be jaundiced if the glands in the portal fissure are enlarged and pressing on the common hepatic or common bile duct. Pressure on the inferior vena cava will give rise to œdema of the legs and a varicose condition of the superficial abdominal veins.

Aids to Diagnosis.—In all cases where indefinite origins and symptoms suggest trouble in the stomach, a barium meal should be given, though in cases of early carcinoma this is not always positive, and, if the symptoms persist in spite of medical treatment, a laparotomy should be used as a diagnostic method. X-ray may show a large ulcer crater perhaps on the greater curvature, or a filling defect, or an absence of the normal waves of peristalsis, pointing to an involvement of the muscle coat, in one particular area of the stomach, or even just an increase in the emptying time on account of the poor motor power of the viscus (Fig. 799). Obstruction, high up or low down, will also be identified. Examination of the stomach contents will usually show a diminution in the hydrochloric acid present, and an increase in the lactic acid. In cases, however, where there has been a recent malignant change in a peptic ulcer, the acidity may be increased. Rarely fragments of growth may be identified and blood may be discovered.

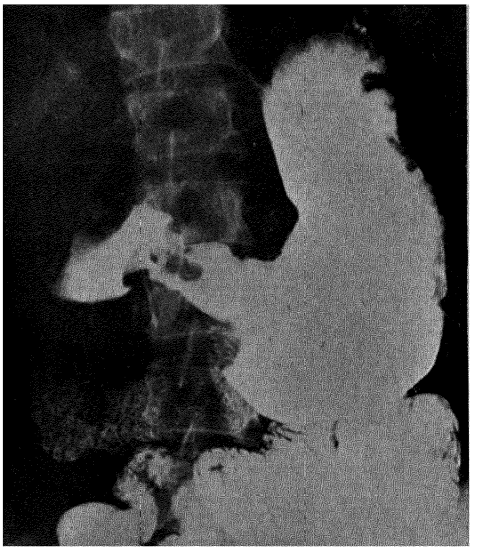

FIG 799.—SKIAGRAM OF CARCINOMA OF THE STOMACH

Note the 'filling defects' in the pyloric antrum, and of the lesser curvature of the pars pylorica

Treatment.—So few of these cases come into the surgeon's hands at a time when operation holds out a fair chance of success that every effort must be made to recognize these obscure symptoms earlier, and, in those cases which fail to clear up with medical treatment, an exploratory laparotomy is justifiable. At present in only about 50 per cent. of cases is operation, with a view to radical procedure, possible, and in only 50 per cent. of these cases can it be carried out. Where

lymphatic glands are not involved—that is, in the early cases—in about 50 per cent. of cases a five-year cure rate can be obtained. As a preventive measure some surgeons advocate a partial gastrectomy, or at least the excision of the ulcer, in cases of peptic ulceration as a treatment to prevent the onset of any malignant change.

Because a tumour is palpable it does not mean that, although the case is advanced, it is inoperable. Where there is evidence of secondary deposits, where there is ascites, where the general condition of the patient is such as to preclude more than a minimal procedure, then it is best in these cases, if obstruction is not present, not to operate.

Prior to any operative procedure it is essential to improve the patient's condition as far as possible by such measures as graduated dieting, stomach wash-outs, the administration of intravenous saline, and blood transfusions where necessary.

The operation of choice is a partial, or in some cases a total, gastrectomy. Where diffuse extension of the disease is shown by involvement of the liver, or diffuse infiltration of the omentum by peritoneal deposits, especially those occurring in the pelvis, or by gross glandular metastases, nothing more than a palliative operation can be carried out, but local extension to a neighbouring viscus, such as the colon, does not necessarily mean inoperability, as this may be resected. Where the growth is high up at the cardiac orifice, radical cure is impossible Total gastrectomy is applied in those cases where the lesion is high up on the lesser curvature or in the fundus of the stomach, and in those cases of linitis plastica, cases where an efficient excision of the growth can be attained only by complete removal of the viscus.

Where pyloric stenosis is present in an otherwise inoperable case, gastro-enterostomy will make the patient's few remaining months more comfortable, but care must be taken to place the stoma as far from the site of growth as possible to avoid invasion and occlusion. Where the cardiac orifice is involved, the only operation of any value is a gastrostomy, Steinmann's method being that most commonly used. A small incision, sufficient to take a No. 12 catheter, is made into the stomach wall, the catheter being fixed by a purse-string suture surrounding it. Slight pressure is exerted on the catheter to invaginate it into the lumen of the stomach, and it is fixed in this position by a second purse-string suture. Further invagination is carried out, and three, four, or more similar sutures produce an ' inkwell ' effect. The stomach wall is then sutured to the peritoneum, and the rectus sheath and the tube brought out through the top of the wound. Small, gradually increasing feeds are administered through this. At the end of some twelve days the tube loosens, and should be removed and replaced.' The orifice will become stenosed if the tube is allowed out for any length of time, and the patient, before discharge, must be instructed how to change and feed himself through it.

Sometimes the stomach is so contracted that it is impossible to effectively invaginate the gastrostomy tube, and, in these cases, Witzel's method should be employed. Here the tube is laid along the long axis of the stomach, after passing its end for an inch or so into the viscus, and it is fixed in position by a series of interrupted

Lembert's sutures, sewing the sero-muscular wall of the stomach over it.

Where the stomach is so involved by growth that a gastrostomy is impossible to perform, a jejunostomy may, if thought advisable, be carried out.

In carrying out a partial gastrectomy, the removal is more radical than that performed for a simple ulcer, almost the whole of the lesser and about two-thirds of the greater curvature, together with the lymphatic glands and the first part of the duodenum, being removed. An ante- or retro-colic anastomosis of the jejunum with the cut end of the stomach completes the operation. Some surgeons, in addition, make a point of removing the whole of the great curvature.

Sarcoma of the stomach is a rare disease, usually of limited malignancy. It may take the form of a fibro-sarcoma, growing into the abdominal cavity from the subperitoneal tissue or into the lumen of the stomach from the submucosa. In the former case, a tumour may readily be palpable, and, as they often have only a limited attachment to the stomach wall, may be freely mobile to such an extent that it may be mistaken for a fibroid or ovarian tumour. Occasionally the whole stomach is invaded by a sarcomatous growth so that it becomes indistinguishable from linitis plastica.

The symptoms are often vague, suggestive often of a carcinoma. Loss of appetite, indigestion, vomiting, perhaps of blood-stained material, a feeling of fulness in the epigastrium, and anæmia are all complained of. A barium meal, which may reveal a filling defect, or the abdominal examination revealing a tumour, will necessitate an exploratory operation. In the case of the infiltrative type of the disease, a total gastrectomy should, if possible, be performed, and in other cases removal of the growth, with a limited resection of the stomach, is all that is required, as the malignancy of the condition is low.

Innocent Growths.—These include myomata, fibromata, angiomata, lypomata and adenomata. Again, these may be extragastric or intragastric, and the symptoms to which they give rise are those indicated in considering sarcoma. There is one type of multiple adenomata or gastric polyposis in which many polypoid masses are present, either throughout the stomach mucosa or lineated to the pyloric segment and the adjacent portions of the greater curvature, and these growths can undoubtedly undergo malignant change.

The treatment of these growths consists in resections of the affected area of the stomach, if they are giving rise to symptoms, and if the wall of the stomach is involved. Where multiple polyposis exists, it is probably better to treat the case medically by frequent gastric lavage and the administration of hydrochloric acid, as these cases are usually associated with hypochlorhydria. The only operative treatment of any value is a total gastrectomy.

Gastroptosis is a condition met with not very unfrequently, in which the stomach is displaced downwards and dilated, usually as a complication of general visceroptosis (Glénard's disease), and hence is likely to be associated with dropping of the liver and

mobility of the right kidney. The *symptoms* produced are those of a chronic atonic gastritis with a dilated stomach; vomiting is not a marked sign, but acid eructations, gastric discomfort, and constipation are very troublesome, and the patient steadily loses weight; neurasthenic manifestations are prominent. The downward displacement of the stomach may be so great as to permit the pancreas to be felt above the lesser curvature. Hæmatemesis is sometimes present, but the acidity is normal or diminished, and the diagnosis from gastric ulcer is thereby determined. Radiographic examination after a barium meal assists in determining the extent of the displacement. **Treatment** consists in lavage and electricity to the organ in the first place, with careful dieting, and external support by a suitable belt is of some value. In more advanced cases, operative treatment has been often undertaken, but is of little value.

Acute Dilatation of the Stomach (Fig. 800) is a curious condition occasionally met with as an unexpected and unwelcome sequela of injury or operation, and that by no means necessarily limited to the abdomen. It sometimes develops without apparent cause in the course of debilitating illnesses. It is characterized by a sudden onset, the vomiting of enormous quantities of fluid, and severe general symptoms, which usually terminate fatally in a few days. The stomach becomes enormously dilated, and the walls are more or less paralyzed, as peristalsis is rarely evident. The pathology is uncertain, but it is possibly due to constriction of the third piece of the duodenum by the superior mesenteric vessels and the root of the mesentery through a downward drag of the intestines. **Treatment** consists in regular lavage, and raising the foot of the bed, and in some cases the abdominal decubitus has given relief; rectal alimentation is required. Surgical treatment is very unlikely to do good, unless there is some associated obstruction near the pylorus.

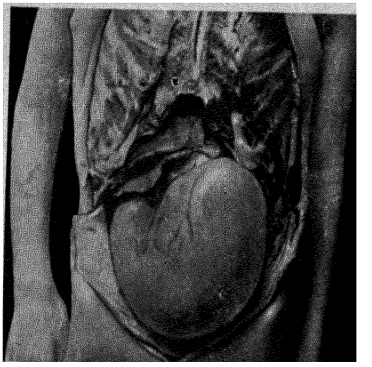

FIG 800.—ACUTE DILATATION OF THE STOMACH

Affections of the Intestine.

Radiography of the intestines is often of great assistance in the diagnosis of the condition and position of various lesions. As already mentioned, the stomach should be empty in about four hours, and about the same time (four and a half hours) the barium should begin to enter the cæcum; it is not usually possible to trace the barium in the duodenum or along the small intestine. There is not uncommonly some hindrance to the escape of barium through the ileo-cæcal valve, and it may collect in the lower end of the ileum and be seen in the pelvis.

The hepatic flexure is generally reached in five to eight hours, the splenic flexure in seven to fourteen hours, and the iliac colon in eight to sixteen hours, the barium normally disappears from the bowel in from twenty-four to thirty-six hours. Irregularities in the course of the intestine can often be detected by this means, such as strictures, kinks, diverticula, etc. The appendix can occasionally be recognized, and difficulty in the escape of the barium from the small to the large intestine may suggest the existence of adhesions binding down the appendix. Too much stress must not be laid on radiographic reports apart from a careful consideration of the clinical phenomena. Barium is heavy, and a downward displacement of the intestine when loaded with it is a natural consequence; it is also somewhat astringent in type, and determines contraction of the intestinal wall, so that the diverticula of the colon become exaggerated. Finally, it must ever be

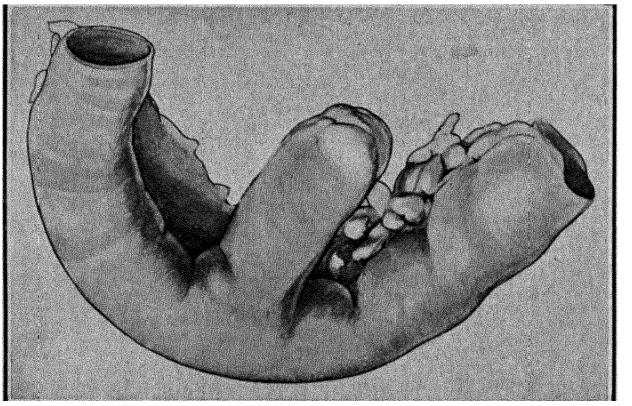

FIG 801.—MECKEL'S DIVERTICULUM.

remembered that radiographs are shadow pictures, and unless taken stereoscopically it is possible to imagine the existence of severe kinks due to the overlapping of the shadows, when in reality nothing of this type is present; this warning especially needs emphasis in reference to the interpretation of radiographic representations of the flexures of the colon.

Congenital Conditions are occasionally met with affecting the intestine, and perhaps giving rise to serious complications. (*a*) The most common of these consists in what is known as *Meckel's diverticulum* (Fig. 801), which occurs as an outgrowth from the lower end of the ileum. It may be patent for 1 or 2 inches, terminating possibly in a fibrous cord, which floats free among the intestines, or may contract adhesions, and thus determine an internal strangulation; sometimes it persists as an open tube as far as the umbilicus, giving rise to a congenital fæcal fistula. It is due to non-obliteration of the omphalo-

mesenteric duct. Many forms of acute abdominal trouble have been caused by this structure, and even inflammatory attacks similar to acute appendicitis, gall-stones or enteroliths have lodged within it and caused perforative peritonitis. (*b*) *Congenital stenosis* of the duodenum occurs at the junction of the fore- and mid-gut, *i.e.* opposite the entrance to the common bile-duct, and a similar condition may arise in the lower part of the ileum at a spot corresponding to the site of Meckel's diverticulum. (*c*) Diverticula may be met with in any

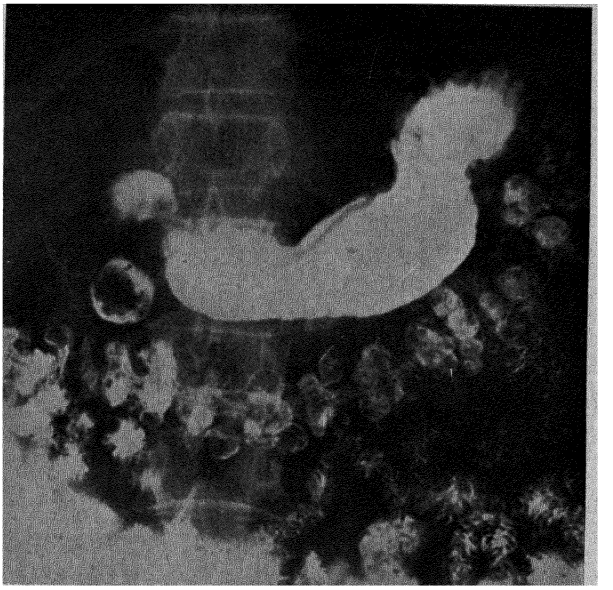

FIG. 802 — DIVERTICULUM OF DUODENUM WITH DIVERTICULOSIS OF COLON

Note the rounded shadow in the second part of the duodenum, and also the extra-lumenal shadows due to diverticula, projecting from the transverse colon. This skiagram was taken after a second barium meal given when the transverse colon was full, in order to show the two conditions together.

part of the small intestine; they are usually discovered during X-ray examination. When occurring in the duodenum they may give rise to symptoms suggesting ulceration (Fig. 802).

Injuries to the Intestine are of increasing frequency of occurrence in view of the number of road accidents. A simple blow on the abdomen may cause a rupture of the intestine, the likelihood of this injury occurring being increased if the blow is unsuspected. Where the muscles are on guard the force of the blow is taken by them. The injury to the intestine may not be of sufficient severity to cause

laceration, but it may cause a simple bruising, accompanied by a certain amount of pain and shock from which the patient soon recovers, but this hæmatoma may become infected, giving rise at a subsequent date to a localized or generalized peritonitis. **Treatment** of these contusions is conducted along the same lines as those of the abdominal wall, *viz.* where there is no absolute evidence of rupture, an expectant attitude may be adopted, but the surgeon must be ready to interfere immediately should any grave or suspicious symptoms arise. Acute enteritis induces diarrhœa and the passage of blood-stained mucus, and such symptoms will indicate the use of bismuth, and perhaps a little morphia, whilst a fluid diet or rectal feeding is alone permissible.

Rupture of the Intestine, a common accompaniment of severe road injuries, is due to a tearing force dragging across the abdomen, pulling on the intestine and rupturing it at either one of its fixed points, namely the duodeno-jejunal junction or the lower part of the ileum close to the cæcum, or to nipping the intestine between the pelvic brim and the actual constricting force, or to compressing strongly a loop of bowel so that the pressure exerted on its contents is sufficient to rupture the wall.

The **Diagnosis** of a rupture of the intestine may be one of severe difficulty or supreme ease. In the latter type of case, following the injury the patient shows signs of extreme shock, with cold, clammy skin and rapid and poor pulse, and he may give a story of having vomited soon after the accident. On examination of the abdomen, signs of injury to the abdominal wall may be present, such as bruising or abrasion, and the whole wall will be rigid and tender to palpation, these signs being most marked in the region of the injury.

Occasionally the liver dulness may be diminished if air has escaped and ascended above this again, and, if much fluid has been extruded from the site of injury, shifting dulness may be detected in the flanks. Associated bleeding from injury to another viscus, such as the liver, or from injury to the mesenteric vessels, is suggested by the rapidly rising pulse, the increasing air hunger and dyspnœa, extreme tenderness, and perhaps an abnormal degree of shifting dulness.

Auscultation in this, as in all types of rupture of the intestine, reveals that there is a complete absence of all intestinal sounds, a point of most important diagnostic value.

At the other end of the scale is the patient who has suffered an abdominal injury, perhaps felt sick or vomited soon after and showed a few of the signs of shock from which he rapidly recovered. He may walk to hospital, and examination, except for auscultation of the abdomen, reveals nothing to suggest that in a few hours the patient will gradually develop all the signs and symptoms of general peritonitis.

Between these two extremes of cases there are many gradations.

Treatment in these cases, and where there is any doubt, is immediate laparotomy after preliminary shock has been treated, as delay is dangerous. A thorough examination of the whole length of the intestine must be made as injuries are often multiple, and these must be oversewn and invaginated by Lembert's sutures. In those cases where the mesentery is so damaged as to interfere with the viability

of the gut resection, an anastomosis must be performed. Drainage of the peritoneum may be necessary.

Punctures or **Stabs** involving the intestine lead to a similar series of phenomena; but the diagnosis may be easier, as gas or fæcal material may escape through the external wound. The direction of the incision in the gut is of importance, since a longitudinal cut (running parallel to the axis of the bowel) is more likely to gape than a transverse one, owing to the greater power of the circular muscle fibres; a small puncture may be almost closed by a protrusion of mucous membrane. Shock is not necessarily so severe as in cases of rupture by violence without penetration; abdominal pain is always present, and acute peritonitis quickly follows.

Treatment.—Every wound of the abdominal wall where penetration is suspected should be carefully explored. If the peritoneum is not opened, the different layers of the abdominal wall are sutured together. If the peritoneum has been involved, the opening in it should be enlarged, so as to determine with certainty whether or not the gut has been wounded. If a small punctured or incised wound of the intestine is present, it is invaginated and closed; if a more extensive lesion exists, excision of the damaged portion may be necessary; but if the patient is deeply collapsed from the supervention of peritonitis, it may be wiser to bring the divided ends to the abdominal wall, and form a temporary fistula, which is dealt with when the patient's general condition has improved. As to the treatment of the resulting peritonitis, the reader is referred to what has been written concerning rupture of the stomach.

Perforation of the Intestine arises from many different causes, such as the impaction of a foreign body, or the yielding of an intestinal ulcer, as in tuberculous disease or typhoid fever, or from that form of enteritis which follows strangulated hernia. Perforation of an ulcer of the stomach or duodenum has been already discussed, and perforation of the appendix will be alluded to subsequently (p. 1273).

When the jejunum or upper portion of the ileum is involved, perforation is usually due to the impaction of a foreign body, such as a fish-bone, or to yielding of a tuberculous ulcer. In the former case general peritonitis is almost certain to follow, but in tuberculous cases the lesion is of a more chronic type, and then adhesions may form, allowing an intraperitoneal abscess to develop, and should it open externally, a fæcal fistula results. In not a few cases the process of cicatrization may lead to a spontaneous closure of the fistula, and no operation should be undertaken until sufficient time has elapsed to determine whether or not this will occur.

In the lower portion of the ileum, *typhoid fever* is the most usual cause of perforation. Occasionally in cases of the so-called 'ambulatory typhoid' it is the first evidence of the presence of the disease, but it generally occurs about the end of the second or in the third week, and rarely more than one perforation is present. It is most commonly seen in bad cases associated with meteorism and hæmorrhage, but is not limited to these. The symptoms are usually those of sudden collapse, as indicated by a falling temperature and a quick and feeble

pulse, whilst severe and persistent abdominal pain followed by increasing distension indicates the development of general peritonitis. Even when the patient is already collapsed by the disease, some slight fall of temperature with acceleration of the pulse may occur, associated with abdominal pain and meteorism. Early rigidity of the belly wall is an important diagnostic sign, whilst there may be some irritability of the bladder. The only *treatment* which holds out any prospect of saving the patient is operation, but owing to his depressed condition the outlook is not particularly bright. Obviously, when he is moribund, it is useless to interfere; but the fact that the death-rate after operation has gradually fallen from 90 to 69 per cent. indicates that in cases diagnosed early a fair proportion of success may be anticipated. The abdomen should be opened in the middle line below the umbilicus, or directly into the right iliac fossa, and if the lesion is not at once obvious, the ileum is sought for at its junction with the cæcum, and the bowel brought up and carefully examined inch by inch till the perforation is found; it may then be closed by sutures introduced so as to close the wound in the transverse axis of the gut. The peritoneum is cleansed and drained in the usual way, after determining that no second perforation is present or imminent.

In the large intestine the most common cause of perforation is ulceration due to diverticulitis, chronic obstruction, or malignant disease. In many cases acute perforative peritonitis follows, but occasionally the mischief is limited, and an intraperitoneal abscess forms, followed by a fæcal fistula.

Foreign Bodies in the intestine are of three types:

1. *Gall-stones* give rise to no symptoms unless they are of large size the smaller ones enter the canal through the common bile-duct after an attack of biliary colic, and are voided in the stools. Larger stones usually gain entrance to the intestine by ulceration from the gall bladder into the duodenum. A coating of fæcal matter is likely to form around them, and thus they increase in size as they pass downwards, whilst the intestine gradually diminishes in calibre from the duodenum to the ileum, so that they are likely to become impacted in the lower ileum (Fig. 803). Women over fifty are most often the subjects of this condition, and there may be only a history of some inflammatory condition of the region of the gall-bladder, and none of biliary colic.

2. *Enteroliths* are of three classes: (*a*) Calculi of phosphate of lime or inspissated fæces form around some foreign body as a nucleus (*b*) Masses of indigestible vegetable material may be matted together with inspissated fæces, mucus, etc.; they are said to be not uncommon in Scotland (the so-called *avenolith*), consisting largely of the husks of coarse oatmeal. They have also been known to consist of hair, or of coconut fibre in a patient engaged in mat-making. (*c*) Calculi have been found consisting of insoluble mineral salts, *e.g.* phosphate or carbonate of magnesia or calcium, salol, etc., taken as medicine. Whatever their origin, such enteroliths are likely to become impacted near the cæcum, and may cause acute obstruction. In thin persons their presence may sometimes be detected by palpation of the abdomen.

3. *Foreign Bodies accidentally or intentionally swallowed* occasionally pass through the stomach and become lodged in the intestinal canal. Lunatics and children are most frequently affected, and in the former the most astonishing collections are occasionally found.

The **Symptoms** caused by such conditions will be either those of intestinal obstruction or of perforation. In the latter the process is usually gradual, rather than sudden, giving time for adhesions to form, thereby limiting the mischief. Suppuration follows, and possibly the foreign body may be extruded naturally or removed by the surgeon through the abscess cavity, with or without the formation of a fæcal fistula.

Small spiculated foreign bodies, *e.g.* fragments of glass or metal, the husks of cereals, etc., may sometimes lodge in the pouches of the colon, and give rise to localized inflammatory phenomena (see on diverticulitis, p. 1030).

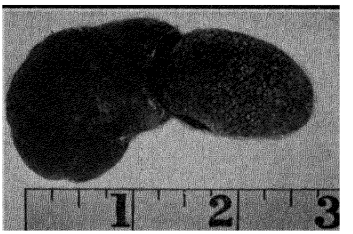

FIG. 803.—TWO LARGE GALL-STONES WHICH ULCERATED INTO THE DUODENUM AND CAUSED INTESTINAL OBSTRUCTION

Enteritis, or inflammation of the mucous membrane of the intestine, is a condition usually treated by the physician, occasionally it complicates surgical cases and needs suitable treatment. Thus it may follow the exposure of a coil of intestine in the depths of a wound which has to be packed for drainage purposes. Severe diarrhœa may result, and the inflammation may even spread through the whole thickness of the gut wall and lead to the establishment of a fæcal fistula. Enteritis also occurs as a post-operative complication of strangulated hernia. Whatever its origin, it is always characterized by diarrhœa of varying type and by pain or abdominal discomfort and perhaps vomiting. *Treatment* consists in the use of a bland diet, *e.g.* milk, and the administration of soothing astringent drugs, such as bismuth and perhaps opium. It must not, however, be checked without ascertaining so far as possible that the causative irritant has been removed, and not uncommonly the best treatment to start with is the administration of a good dose of castor oil.

Colitis is an affection occasionally needing surgical treatment. The cause is usually chronic constipation, but bacteria of various types or the *Entamœba coli* may be present. In the simpler cases (**mucomembranous colitis**) the patient complains of griping pains in the course of the colon, diarrhœa, the passage of mucus in the stools, perhaps in membranous flakes or rolled up into strings, and definite tenderness of the colon on palpation. The appendix is not unfrequently inflamed at the same time, and one of the most tender spots may be over this organ; it is possible that in a few cases it constitutes the nidus in which develop the organisms that cause the trouble. *Treatment* of this form consists in emptying the bowel by enemata, keeping the patient quiet

in bed on a milk diet, and possibly ordering bismuth or a little chlorodyne. When the patient is convalescent and all tenderness has disappeared, the causative chronic constipation must be treated. Purgatives usually cause irritation and pain, and must be avoided as far as possible, but paraffin is useful. Abdominal massage and the methodical use of remedial exercises to increase the power of the abdominal muscles, and thereby give tone to the relaxed colon, will often work wonders in these cases. The use of medicinal waters and irrigation of the colon, as practised at Bath, Harrogate, and Plombières, often give excellent results. In a certain percentage of cases removal of the appendix does good in colitis, but the surgeon must not promise too much.

The graver cases (**ulcerative colitis**) are associated with the discharge of pus and the exfoliation of patches of mucous membrane. The patient's health may be profoundly affected in this disease, pus of a most offensive type pouring out from the rectum, or fever of a marked hectic character being present. The nutrition is necessarily impaired and he wastes to a shadow, and often shows an advanced degree of anæmia. In some cases the hæmorrhage from the bowel is of such a degree as to kill the patient, or the ulceration may be so extensive as to cause peritonitis. The treatment of these cases is at first essentially medical. Rest in bed on a low residue diet, and freedom from worry and anxiety, are necessary in the acute stages; and this is combined with high colonic irrigations. Many fluids, such as simple saline, dilute potassium permanganate, albargin, or dettol, may be used, but best of all is one containing adrenalin, drachms iv, to a pint of saline. Each irrigation must be continued until all the pus and blood has been washed away and will entail using several gallons of the solution. In addition, such drugs as kaylene, or kaylene oil, if the bowels are constipated, tinct. opii, red gum, or atropine may be given. An endeavour to change the intestinal flora by the administration of lactic acid is sometimes of value, but Bargen's serum has not proved of much benefit. Blood transfusions are very often necessary and beneficial.

If, in spite of such treatment, the condition fails to clear, an appendicostomy or cæcostomy may be performed with a view to resting the lower bowel and to effect more efficient irrigation.

Diverticulitis (*Syn.: Pericolitis, Sigmoiditis, Sacculitis,* etc.).—Under this title is described an inflammatory condition arising in connection with the secondary, acquired, multiple, false diverticula of the large bowel, particularly and nearly always found in the sigmoid flexure. They are situated usually in rows, often projecting into the appendices epiploicæ (Fig. 804). Though occasionally found in the cæcum and appendix, they are most commonly situated in the descending and pelvic portions of the colon. At first they are merely semi-globular pouches, consisting of all the intestinal coats, but later the muscle fibres atrophy, and the pouches become more flask-shaped with a definite neck, but rarely are larger than a hazel-nut. It is possible that they are associated with some congenital weakness of the wall, but frequently stenosis or constipation is present, leading to increased

PLATE XXIII

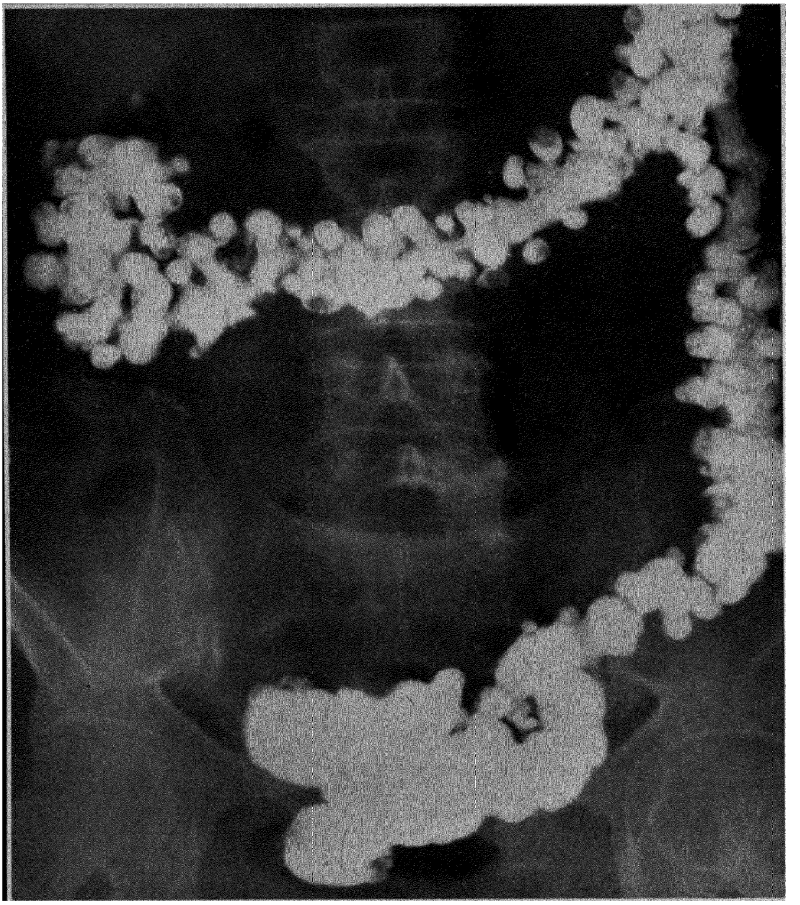

DIVERTICULA OF THE COLON.

intra-intestinal pressure. Fæcal material enters and may become inspissated, so as to constitute an enterolith, foreign bodies may find lodgment, and thus the basis of a whole series of pathological phenomena very similar to those of appendicitis is laid. Acute inflammation occurs, leading to ulceration, gangrene, or perforation, followed by acute local or general peritonitis; abscesses may develop, opening externally or into some viscus, *e.g.* the bladder, and leading to fæcal fistulæ. In other cases chronic inflammatory hyperplasia results, giving rise to the formation of a mass resembling a carcinomatous tumour and ending in stenosis. Carcinoma itself is an unfrequent sequela.

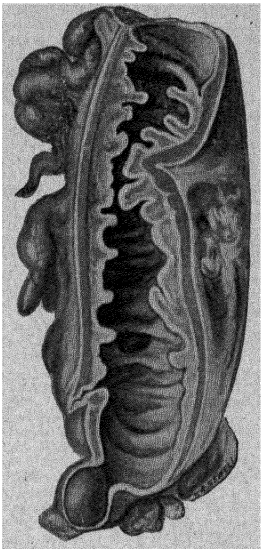

FIG 804.—LARGE INTESTINE, SHOWING A NUMBER OF DIVERTICULA (KING'S COLLEGE HOSPITAL MUSEUM.)

The **Symptoms** of acute diverticulitis usually occur in those who have passed middle life, and is twice as common in men as in women. The patients are often fat and well nourished, and there is a history of preceding constipation. The symptoms closely resemble those of appendicitis, and, indeed, the term 'left-sided appendicitis' has been applied to it. The sigmoid flexure is usually involved, and then the site of maximum tenderness may correspond to McBurney's spot on the left side. The symptoms of abscess formation and peritonitis have no peculiar features. In the more *chronic* cases, the development of a tumour-like chronic inflammatory mass is the most marked feature, lying over the left side of the pelvic brim. It is very likely to be mistaken for a cancerous growth, and, indeed, it is probable that most of the reported cases of the disappearance of a supposed intestinal cancer after operation of an exploratory type, where excision was not performed, were of this nature. The points of differential diagnosis are that in diverticulitis the patient is generally in good health, and, indeed, tends towards obesity. The history is of some duration, and points to recurring slight inflammatory attacks in the left lower quadrant of the abdomen, with absence of blood in the stools. Radiography is of assistance in that the characteristic features of cancer are absent, and it is often possible to demonstrate the presence of diverticula (Plate XXIII.).

Treatment.—In the *pre-inflammatory* stage (the so-called 'diverticulosis'), treatment must be directed to cleansing the intestine by douches, to protecting the mucous membrane by administering liquid paraffin, and to preventing the admission of irritating ingesta. Abdominal massage is avoided, as it might cause rupture of a weakened spot. In the *acute* stage treatment is akin to that for acute appendicitis; abscesses are opened and drained, and the communication with the

colon will then often close of itself by granulation. The administration of *B. Welchii* serum is of value in these cases. Excision of the affected portion of the colon is desirable some six months after the initial operation. For the chronic hyperplastic type excision is the only effective treatment, followed by end-to-end or lateral anastomosis; in a few cases a permanent colostomy has to be established. The existence of fistulous communications with the bladder is no contra-indication to operation; if the sigmoid is set free, it is not a difficult task to close the vesical opening, and the result is likely to be satisfactory.

Tuberculous Disease of the Intestine usually occurs in the ileo-cæcal region, and manifests itself in two main varieties:

1. **Tuberculous Ulcers** are generally multiple, though occasionally single. They are of the usual tuberculous type, with undermined margins, and extend along the course of the blood-vessels and lymphatics, *viz.* around the gut, so that if they heal stricture is almost certain to follow. In their early stages they are seldom seen by the surgeon, but later on obstructive phenomena may supervene, and these may be due not only to the stenosis, but also to associated peritonitis; neighbouring mesenteric glands are usually infected, and together with the bowel and omentum may form a palpable mass, in the midst of which suppuration may occur. Should the abscess burst externally, a fæcal fistula may result. Operation may be needed for the relief of the obstructive phenomena, or for the suppuration, and some form of anastomosis, or even excision of the mass, may be required.

2. The disease is sometimes of a hyperplastic type, and is then chiefly limited to the cæcum, producing a well-marked tumour, which can be palpated from outside, known as the **Tuberculous Cæcal Tumour.** The disease is liable to extend along the ascending colon for some distance, and less frequently along the ileum. The intestinal wall is thick, congested, and infiltrated with a tuberculous deposit; the outer coat is rough and nodulated; the mucous lining is ulcerated, and often presents vegetations and polypi of a granulomatous type; the mass is firm, but not hard to the touch. Enlarged glands are found in the mesentery and along the inner border of the ascending colon. Adhesions may be present, and lead to kinking or twisting of loops of bowel. In the early stages constipation and diarrhœa may alternate, but later on obstructive phenomena may supervene, or even well-marked pyrexia of a hectic type. The diagnosis from a cæcal carcinoma is not always easy; the chief points in favour of tubercle are the earlier age (under forty years), the longer duration of symptoms (two or three years), the associated pyrexia, and the presence of tuberculous lesions elsewhere. The diagnosis is, however, not uncommonly made on the operating-table. *Treatment.*—Prior to operation, sanatorium treatment combined with local and general heliotherapy should be employed; but if the patient does not react satisfactorily and quickly, operation must not be delayed. Removal of the cæcum, together with the lower end of the ileum, the ascending colon, and such glands as are readily accessible, is undertaken along similar lines as for cancer, and an

anastomosis established between the ileum and transverse colon. The results are usually most satisfactory. If for any reason this procedure is impracticable, the disease may be short-circuited, and good results may be expected to follow.

Crohn's Disease, or Regional Ileitis.—Of recent years, a number of cases have been collected in which the patient has usually had most of the signs of acute appendicitis, but in whom at operation a normal appendix has been found associated with an acute inflammation of the lower part of the ileum. No specific organism has been isolated from the affected bowel, although *B. coli* and streptococci have been implicated. At first only described as occurring in the ileum, it is now recognized that cases may occur throughout the length of the intestines.

Some cases occur in a subacute form, where there is the complaint of periodic attacks of pain in the right iliac fossa, with perhaps vomiting and a rise in temperature and pulse. Abscess formation may result, with the formation of sinus and fæcal fistulæ.

There is a chronic form of the disease, probably subsequent to some subacute attacks, in which the ileum becomes thickened and infiltrated, with eventually the diminution of its lumen to such an extent that obstruction ensues.

The **Treatment** in the acute cases is operative, as a diagnosis can rarely be made between this disease and acute appendicitis. Although these cases usually clear up if nothing beyond a laparotomy is carried out, it is advisable to resect the affected area of the bowel as this precludes any danger of perforation or ultimate stenosis. Where the latter exists in chronic cases, either a short-circuiting operation or an excision of the bowel will be required.

For **Actinomycosis of the Cæcum,** see p. 1279

Stenosis of the Intestine arises from two main causes—the contraction of cicatrices or adhesions, and the development of tumours, usually malignant.

Simple cicatricial stricture results (1) from the healing of ulcers which have extended more or less circularly around the bowel, hence, tuberculous ulcers lend themselves to its development more than the typhoid lesion. Syphilitic ulceration is followed by it, especially when involving the rectum; but the upper part of the jejunum is also occasionally affected. In the large intestine dysentery is the most common cause, and the stenosis, like the ulceration, may be irregular and extensive. (2) It may follow strangulated hernia as the result of ulceration along the actual site of constriction; and, similarly, it may develop after the separation of an intussusception. (3) An end-to-end anastomosis of the gut may lead to stenosis unless care is taken not to encroach too much on the lumen. (4) The contraction of adhesions outside the intestine is by no means an uncommon cause; thus it may be due to many forms of localized peritonitis, and frequently ensues after pelvic cellulitis. (5) The final stages of Crohn's disease often give rise in their chronic form to stenosis.

Since the contents of the *small* intestine are of a somewhat fluid nature, a stricture often exists here for some time before any symptoms

of urgency arise. The patient may complain of a certain amount of indigestion and discomfort, but sooner or later the narrow aperture of the gut becomes blocked either by a fold of mucous membrane or by a portion of undigested food, and thus an attack of obstruction is induced. In the early stages of the disease this can be remedied by purgatives, but each recurrence is likely to increase in severity, until finally an acute attack supervenes, which kills the patient, unless relieved by prompt surgical interference.

In the *large* intestine very similar phenomena appear, but the attacks of obstruction are of a somewhat different character, since there is less pain and vomiting, and aperients, instead of relieving the patient, as they often do in the small gut, always aggravate the symptoms, there is also much greater distension of the abdomen. Radiography may determine the diagnosis in a certain number of cases, and the sigmoidoscope will be of assistance for the lower foot or more of the bowel, otherwise the nature of the case, though strongly suggested by the symptoms, can only be actually settled by an exploratory operation.



FIG 805.—LIPOMA OF THE JEJUNUM WHICH CAUSED AN INTUSSUSCEPTION

The **Treatment** in the earlier stages consists of suitable dieting, and the administration of purgatives or of large enemata, and for a time this will be successful. Sooner or later, however, a more than usually serious attack of obstruction will call for something more radical, and readers are referred to the chapter on obstruction for details of the treatment to be adopted. Apart from the question of obstruction, a stricture of the small intestine is to be treated by enterectomy. For stricture of the cæcum or ascending colon, some short-circuiting method, whereby the ileum is implanted into the colon below the stricture (ileo-colostomy), is perhaps the best plan to adopt; in the transverse colon excision is sometimes possible, as also in the sigmoid flexure. Failing these measures, the establishment of an artificial anus will be required.

Tumours of the Intestinal Wall may be simple or malignant, primary or secondary. *Simple* tumours are unusual, and consist of papillary polypi, adenoma, myoma, lipoma, and a few other varieties (Fig. 805). They may cause irritation and irregular action of the gut, resulting perchance in intussusception; hæmorrhage, sometimes of a serious character, is associated with multiple papilloma or adenoma; and obstruction occasionally ensues. It is unusual for a diagnosis to be made apart from an exploratory laparotomy, unless the rectum is affected. The *treatment* is governed by the location of the growth and by the symptoms it causes.

Sarcoma of the intestine is not common; it may involve the ileum or cæcum, and give rise to a localized tumour or diffuse infiltration. Obstruction may ensue, or considerable peritoneal irritation resulting in an abundant blood-stained exudate which leads to abdominal distension, and may be recognized as due to a new growth on tapping. *Treatment* consists in removal of the affected coil of gut if the disease has not progressed too far.

Carcinoma of the Small Intestine is an uncommon condition, and represents only 0·5 per cent. of all carcinomata of the gastro-intestinal tract from the cardiac end of the stomach down to and including the rectum. These tumours are usually situated in the duodenum or jejunum, and may develop either as or as an adeno-carcinoma arising from a solitary polypus. In the past these tumours were rarely diagnosed except after operation for some urgent symptom, but to-day, with the use of modern X-ray equipment, more cases are diagnosed prior to operation. The growth is commonly annular (Fig. 806), due to lymphatic spread, and gives rise to colicky pain, and occult blood may be found in the stools. Anæmia is often very marked when the patient comes under the observation of the surgeon.

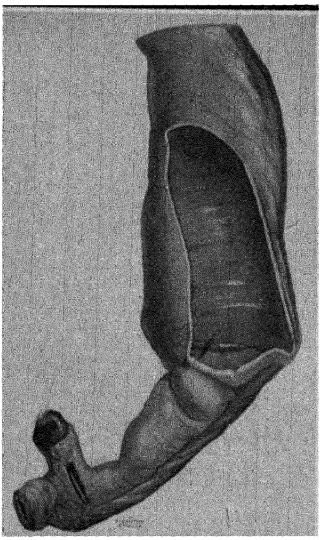

FIG 806.—CARCINOMA OF THE TERMINAL ILEUM JUST PROXIMAL TO A SMALL MECKEL'S DIVERTICULUM.

Excision of the growth with side-to-side anastomosis is often quite an easy operation. Remote secondary deposits in the mesentery and the liver are rare, probably because the growth gives rise to symptoms before such dissemination takes place.

Cancer of the Colon.—The brilliance of the surgical results in cases of this disease is entirely dependent on early diagnosis, upon which emphasis will be laid. Nearly all of these cases, where the growth is situated distal to the cæcum, and in some where it is in the viscus itself, give a history of irregularity in the normal bowel action. A patient who for the rest of his life has had usual bowel action may remark on what was to him a quite trivial incident, namely that he suffered from a period of constipation some months ago, or that he remembers an attack of diarrhœa. Any patient who is of an age when cancer of the bowel is likely, who comes complaining of irregularity of his bowels, should be considered to be a case of carcinoma until the existence of the complaint is disproved by investigation. This latter will consist of a general examination, the carrying out of

a barium enema and a sigmoidoscopic examination. This latter is all-important because some growths low down in the pelvic colon are not recognizable with X-ray investigation as a filling defect may be covered by the barium in a loop of bowel either in front of it or at its side. Sigmoidoscopic examination can easily be carried out by the general practitioner after the patient's bowels have been emptied by means of a purgative or washout, the all-important point in the examination being never to push on the instrument without always having the lumen in view. When the recto-pelvic junction is reached no lumen will be seen as the bowel takes a right-angle bend at this



FIG 807.—MICROSCOPICAL DRAWING OF CARCINOMA OF THE SIGMOID COLON

point, and therefore no attempt should be made to push the instrumen farther.

No anæsthetic is necessary, and the patient should be examined in the left lateral position with a small pillow under his buttocks, as this tends to make the colon straighten out.

Pathologically, carcinoma of the colon exists in three forms: the scirrhous type, the hypertrophic type, and the ulcerative type (Fig. 807)

The former is the most common, especially in the left side of the colon, the bowel being invaded by a sclerosing growth which, by it contractures, gradually produces obstruction to the passage of the fæcal contents of the intestine. The growth is greater around than in the length of the bowel, that proximal to it undergoing steady dilatation and hypertrophy in an endeavour to overcome the obstruction. In the later stages the dilatation is much in advance of the hypertrophy, the walls of the bowel being thinned, and perhaps ulcerated, by fæcal irritation, this being particularly so in the case

of the cæcum, which may be so dilated as to fill the whole of the lower abdomen.

Perforation of the bowel may obviously result if the obstruction continues to its logical conclusion.

The bowel distal to the site of obstruction is often dilated, due to the cutting off of its nerve supply by the actual growth, and ballooning of the rectum is an important diagnostic point of the presence of a growth beyond the reach of the finger.

The hypertrophic type occurs most frequently in the cæcum, and is rare in the pelvic colon (Fig. 808). It is of a low degree of malignancy, but, because it is later in producing signs and symptoms which bring it to notice, these patients are usually seen late. It gives rise to a

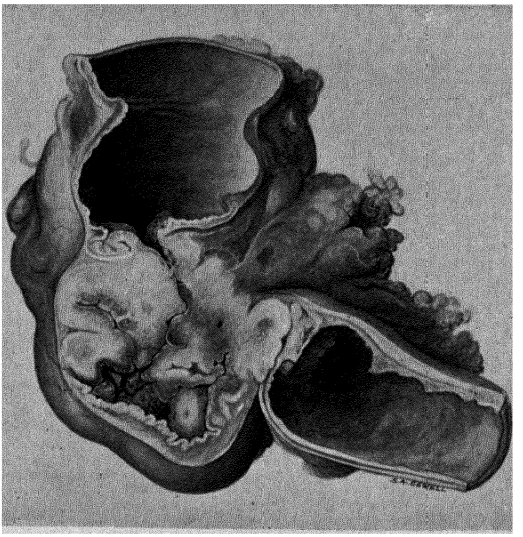

cauliflower-like mass growing from the wall of the bowel, which becomes ulcerated and bleeds, and eventually produces obstruction. Colloid changes may be present.

The rarest type is the ulcerative type, which rapidly metastasizes and erodés its way through the wall of the bowel.

The spread of the growth and the infection accompanying the ulceration may cause it to bind down the adjacent structures although the adhesions are not necessarily malignant. Thus, a carcinoma of the pelvic colon may become adherent to the bladder and, in rare cases, perforate into this organ (the vast majority of vesico-colic fistulæ are secondary to diverticulitis), or it may stick and adhere to the Fallopian tubes or ovaries. Other cases may steadily ulcerate

through the colonic wall, giving rise to a localized abscess or general peritonitis. A fistula may be found between the stomach and transverse colon in cancer of the latter.

Glandular spread occurs first in the paracolic glands, then in those at the root of the mesentery. The lumbar glands and those in the hilum of the liver next become involved, with eventual involvement of the liver. Direct extension of the growth will involve the peritoneum and perhaps the ureters, so that the patient may die of urinary obstruction and infection. In late cases, where obstruction does not result, a generalized blood-stream extension may occur, with secondaries in the brain, lung, bones, skin, and other organs.

The part of the large intestine most commonly involved in carcinoma is the sigmoid, the cæcum being the next in order of frequency. Fig. 809 gives the site of the growth in a series of cases.

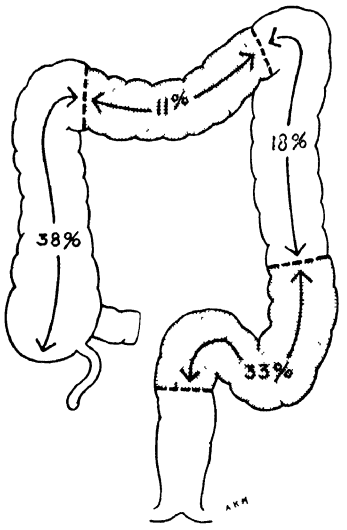

FIG. 809.—DIAGRAM SHOWING THE RELATIVE FREQUENCY OF CANCER OF THE COLON IN A LARGE SERIES OF CASES

Carcinoma of the Cæcum usually starts in its lateral wall immediately opposite the ileo-cæcal valve, and the growth is frequently large and fungating (Fig. 808). The onset of the condition is usually insidious, and the duration of the symptoms prior to diagnosis is usually about eighteen months. In a critical review of twenty-five cases which were published in 1932 in the *British Journal of Surgery*, it was found that the cases present themselves complaining of one or other of the following symptoms, or some combination of them:

(1) Mild dyspepsia, pain in the right flank, constipation, borborygmi (often diagnosed as chronic appendicitis).
(2) A mass in the right iliac fossa.
(3) Anæmia and debility.

Blood may appear in the stools, and there may be attacks of diarrhœa. On further investigation some degree of anæmia and leucocytosis is usually found. A tumour is frequently palpable. A barium enema often clinches the diagnosis, as a definite filling defect is seen in the region of the cæcum (Fig. 810).

Cases of carcinoma of the cæcum are, therefore, commonly seen before any obstruction has occurred, and the patient can be well prepared for the operation, which consists in excision of the cæcum, ascending colon, hepatic flexure and part of the transverse colon as well as the terminal 6 inches of the ileum (Fig. 811). The best incision is a right paramedian, packs being inserted to keep the small intestine

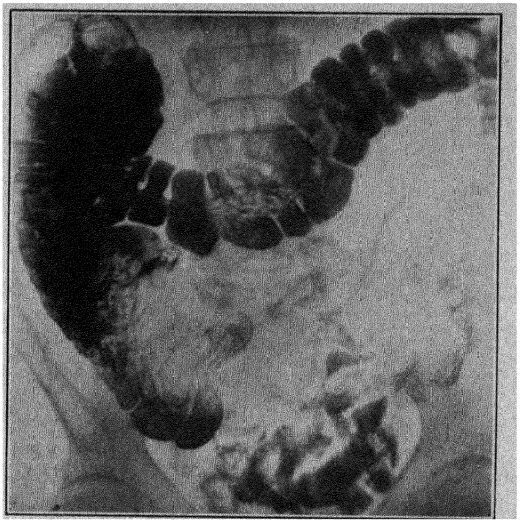

FIG 810.—SKIAGRAM OF CASE OF CARCINOMA OF THE CÆCUM SHOWING 'FILLING DEFECT' IN CÆCUM

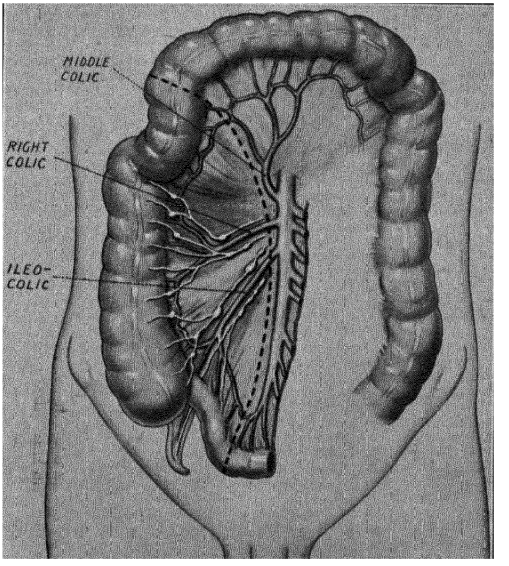

FIG 811.—THE EXTENT OF RESECTION OF THE GUT REQUIRED IN CARCINOMA OF THE CÆCUM

out of the field, only the bowel to be removed to be kept in view. Clamps are applied to the ileum and it is divided. The operator, working from below upwards and from the outer side of the colon where he incised the peritoneum, proceeds to mobilize the ascending colon with its blood and lymph supply (Fig. 812). Care is taken

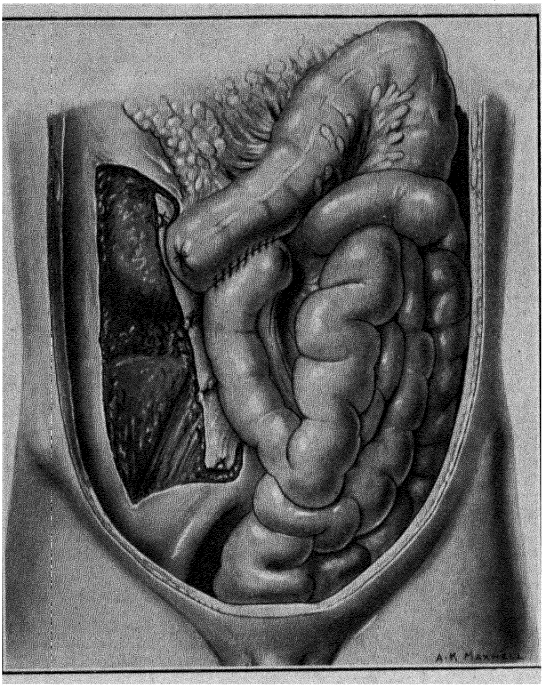

FIG. 812.—THE COMPLETED OPERATION FOR EXCISION OF THE CÆCUM FOR CARCINOMA.

If a raw surface is left on the posterior abdominal wall because of lack of peritoneum it should be covered by omentum so as to prevent the formation of adhesions.

to avoid injury to the ureter and spermatic vessels. The hepatic flexure is freed by blunt dissection and snips with scissors, but care must be taken not to damage the retro-peritoneal portion of the duodenum. The transverse colon is now divided between clamps, and the portion of the omentum on the proximal part ligatured ready for removal. The blood-vessels to the cæcum and colon can now be clamped and the bowel cut away portion by portion. The divided ends of the bowel are next invaginated by a series of purse-string sutures and the end of the ileum drawn alongside the transverse colon. A side-to-side anastomosis is then made between them, the

sutures being inserted as in a gastro-enterostomy. The suture line is reinforced with the omentum. The final stage is to reperitonize the raw area left by the incision made on the outer aspect of the colon and the section through its vessels. This is done *secundum artem*. The abdomen is closed with drainage, which should never be omitted because of the exudate from the raw area on the posterior abdominal wall. The tube may be brought out through a separate stab wound.

Carcinoma of the Colon becomes more obvious the lower it is situated. Although obstruction, with some alteration in the bowel action, may occur in all cases, it is obvious that these signs will manifest themselves earlier in cases of carcinoma of the pelvic colon than in carcinoma, say, of the hepatic flexure, because the stools are much more solid lower down and more readily held up (Figs. 813, 814, and 815). Moreover, bleeding and the discharge of mucus, which may be quite slight but definite, is more mixed with fæcal material in high growths and may go unnoticed by the patient. In carcinoma low down, the bright blood and the mucus rarely fail to escape his attention.

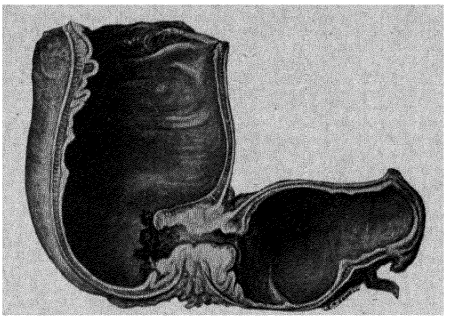

FIG 813.—CARCINOMA OF THE TRANSVERSE COLON (KING'S COLLEGE HOSPITAL MUSEUM)

Signs and Symptoms.—Patients come complaining of a variety of symptoms. It may be constipation, or diarrhœa, or the two alternating with one another, colicky pain, due to increased peristalsis, pain across the back (where the growth has extended to involve nerves), or they may have noticed increasing abdominal distension. Others complain of the passage of blood and mucus, or frequency and burning on passing water, while some have noticed loss of energy and weight with the increasing paleness of anæmia.

Occasionally these patients are seen when obstruction is acute, and then a history of absolute constipation for several days will be given, but careful enquiry will reveal some of the symptoms mentioned above of months' duration.

On examination, the patient may show obvious signs of loss of weight and in some cases of cachexia. The tongue is furred, a sign of the anæmia from which all these patients with chronic obstruction suffer. The abdomen may be distended, mostly along the lines of the large intestine, and it may be possible to percuss or palpate a grossly distended cæcum. The actual tumour is more often not palpable than palpable, although impacted fæces, recognizable by their indentation when subjected to pressure, may be identified. The liver should be examined for enlargement, and in some cases secondary deposits with typical umbilication can be palpated. A rectal examination, with the

patient lying on his right side, enables a tumour to be palpated through the rectal wall higher up than if the subject lies on his left side, because the colon tends to fall on the examining finger.

Even when sigmoidoscopy reveals a growth a barium enema should



FIG 814.—SKIAGRAM TAKEN AFTER A BARIUM ENEMA SHOWING CARCINOMA OF THE TRANSVERSE COLON, DIVERTICULOSIS AND DIVERTICULITIS IN THE SAME PATIENT (MR H C EDWARDS'S CASE)

always be given, as occasionally a second growth may exist at a higher level.

The **Treatment** of these cases is surgical, except in those few cases where obstruction is not imminent, but the presence of ascites, an enlarged liver with palpable secondary deposits, and a general cachexia, show that death is not far off, which are best treated conservatively.

The operative procedure consists in the removal of the affected gut, together with its lymphatic drainage, and as this will often entail the removal of the blood-supply of a large area of bowel this latter must also be removed. Thus, in carcinoma of the ascending colon the same removal as that described for carcinoma of the cæcum must be carried out. In cancer of the transverse colon, this and the two flexures should, if possible, be excised, and in diseases of the splenic flexure, that, the distal half of the transverse colon, and the descending colon will require removal. For the sigmoid colon, a more limited resection, consisting of about four inches of gut above and below the cancer, together with a wedge-shaped excision of the corresponding part of the mesentery, will suffice.

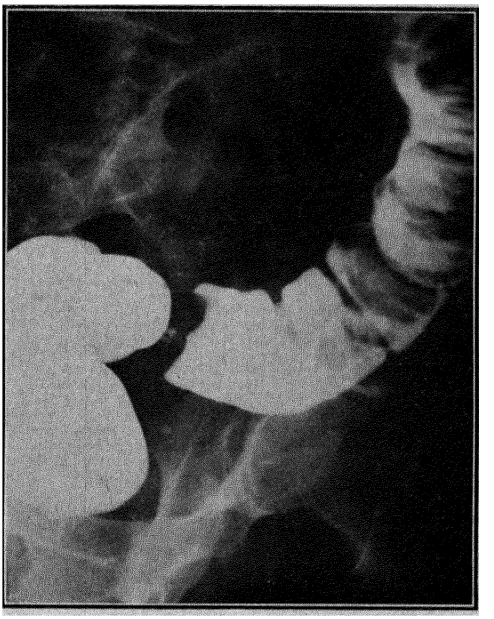

FIG 815.—SKIAGRAM OF RECTO-SIGMOID JUNCTION AFTER BARIUM ENEMA

Oblique view showing carcinomatous stricture. It is very important to take an oblique view in these cases, as an ordinary antero-posterior view frequently does not reveal the stricture

There are, however, dangers attached to these apparently technically easy operations which in the past have accounted for many deaths, but which can nowadays be prevented by efficient pre-operative treatment and the performance of a two-stage operation if necessary. These patients are often in a poor condition, and all should be admitted some ten days before operation in order that they may be given a nourishing low-residue diet containing plenty of fluids and glucose, and, if their blood-count and hæmoglobin warrant it, a blood transfusion, repeated if necessary, is invaluable.

In operating on these patients there are two factors that go against success. Firstly, the bowel is filled with stagnating, grossly infectious fæcal contents, which, if allowed to come into contact with the general peritoneal cavity, will give rise to general peritonitis and death; and, secondly, the bowel above the obstruction is dilated and perhaps œdematous, considerably larger in diameter compared with the bowel

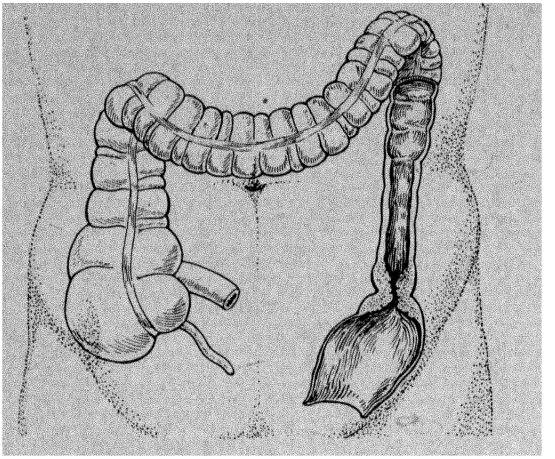

FIG 816.—DIAGRAM OF CONSTRICTING CARCINOMA OF THE SIGMOID COLON

Dilatation of the cæcum, hypertrophy of the descending colon and dilatation below the growth due to paralysis of the bowel.

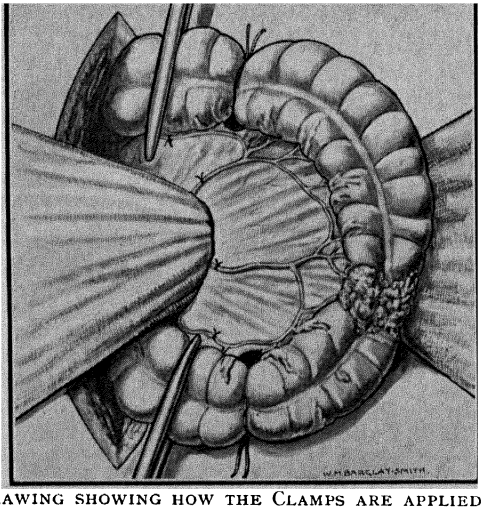

FIG 817.—DRAWING SHOWING HOW THE CLAMPS ARE APPLIED AFTER MOBILIZING A GROWTH IN THE SIGMOID COLON.

below, to which it is anastomosed—factors which make it very dubious as to whether a watertight union can be effected, especially as one side of the bowel may not be covered with peritoneum. The bowel can in many cases be cleansed, and the œdema reduced to such an extent that a safe one-stage operation can be performed by the following treatment. On the morning of admission the patient is given 1 oz. mist alba, hourly ½-oz. doses for five hours. On each succeeding day until forty-eight hours before the operation, that is for about ten days, he is given a further ½ oz. of the mixture. Each morning and evening during this period the patient is given a colonic wash-out. If at any time during this period of preliminary treatment signs of obstruction

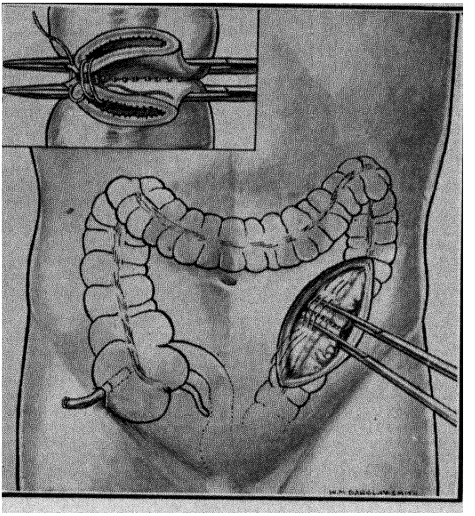

FIG 818.—DIAGRAM SHOWING THE COMPLETION OF THE OPERATION FOR RESECTION OF THE SIGMOID COLON WITH END-TO-END UNION

A cæcostomy has been performed some days previously The inset demonstrates the method of suture

supervene, a cæcostomy must be performed. Under this treatment the patient will visibly improve, losing his toxic appearance, while the distension of his abdomen disappears.

The abdomen is explored with a paramedian incision, and the operability of the growth estimated. Peritoneal involvement, the presence of masses of glands, secondaries in the liver, will all indicate that only a palliative procedure can be attempted. This may take the form of a short-circuiting operation, operation whereby the bowel proximal to the carcinoma is anastomosed to that distal to it by a side-to-side anastomosis or a colostomy performed in the transverse colon if the site of the obstruction is distal to this. Where the condition

is operable a resection along the lines indicated is performed, the descending and pelvic colon being mobilized by incising the peritoneum along their outer margin. Where the ileum is anastomosed to the transverse colon, a side-to-side anastomosis is best, but elsewhere end-to-end re-establishment of continuity is desirable (Figs. 816-818).

In anastomosis on the left side of the abdomen it is a good plan to extraperitonealize the line of suture, by stripping up the parietal peritoneum on the lateral abdominal wall and suturing it to the peritoneum on the inner side of the bowel above and below the junction. A drainage tube is then brought out through a stab wound made in the flank, so that if leakage does occur it is extraperitoneal and not associated with general peritonitis.

A further measure of safety is to bring a small piece of the cæcum out on to the surface and fix it there by a few sutures, so that if any abdominal distension occurs relief of tension on the suture line may be effected by opening the viscus and converting it into a cæcostomy.

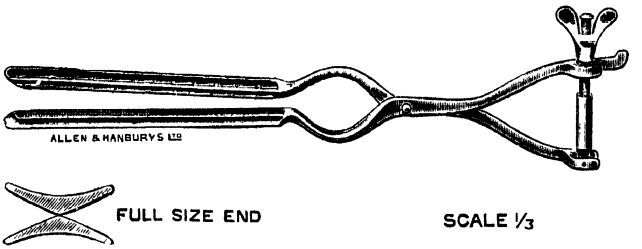

FIG. 819.—A USEFUL ENTEROTOME (DEVINE'S)

In all cases where the preliminary treatment has failed to diminish the size and œdema of the distended bowel, all procedures should be preceded by preliminary colostomy or cæcostomy.

An alternative method, which has much to commend it, is the operation associated with the name of Paul and Mikulicz. This type of operation can be performed in the presence of moderate degrees of obstruction. A free incision is made over the tumour, which is then mobilized. The bowel is divided between clamps and the growth removed. The ends of the divided bowel are lifted out of the wound and their adjacent sides united by suture, the clamps being left *in situ*. The wound is now closed and dressings applied around the clamps. At the end of twenty-four hours the upper clamp is removed and the bowel functions through this colostomy. By the third day the second clamp may be removed, and repair of the fistula commenced. On the spur between the two loops of bowel an enterotome (Fig. 819) is placed, and the pressure gradually increased. Sutures hastening the closure may be inserted at the bedside without any anæsthetic. In about four weeks' time, in a favourable case, the fistula will be quite healed, and, under a local novocain injection, the parietes can be incised and the bowel allowed to drop back into position.

There is, perhaps, one criticism of the Paul-Mikulicz operation, and

that is that it does not always allow the excision of a generous margin of normal intestine or of the segment of the mesentery that contains lymph nodes. Rankin has devised a modification of this operation in which the growth-bearing segment of bowel with its mesentery is mobilized, the blood-supply is ligatured, and the whole segment is resected over a three-bladed clamp (Fig. 821). If there is much obstruction, a catheter can be tied into the proximal limb of the bowel just in front of the clamp (Fig. 822). By this method an outlet is provided for the passage of gas and fæcal contents and the wound is allowed to heal soundly. The catheter is placed in the bowel after the abdomen has been closed.

Where acute obstruction exists, a cæcostomy in desperate cases is all that the patient will stand, exploration being postponed until he has recovered. In other cases, a laparotomy should be performed because an idea can then be obtained as to the operability or no of the tumour, and appropriate treatment carried out.

When perforation has taken place, the patients are often *in extremis*. The surgeon can only do a colostomy or cæcostomy in the region of the perforation and drain the abdomen. In those cases that survive the outlook is quite bright.

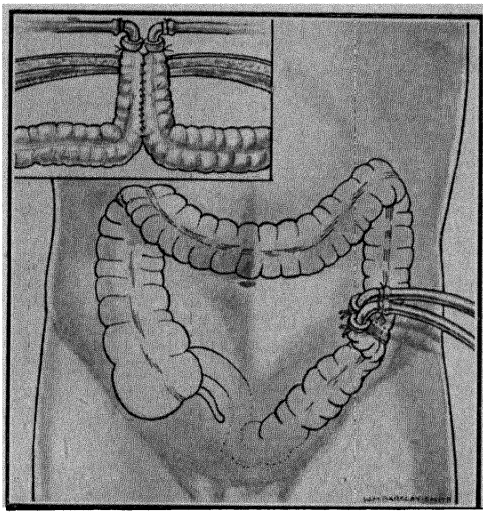

FIG 820.—DIAGRAM SHOWING HOW TWO PAUL'S TUBES ARE FASTENED IN THE COLON AFTER RESECTION OF THE SIGMOID COLON

The smaller drawing illustrates how the two loops of the colon are joined prior to inserting the Paul's tubes

Hirschsprung's Disease, or idiopathic dilatation of the colon, is a condition of infancy and childhood more common in males, which persists if the subject survive into adult life, due rarely to a band constricting the back of the rectum, or a hypertrophied fold of mucous membrane at the pelvi-rectal junction producing obstruction, but more commonly to a neurogenic inco-ordination at the pelvi-rectal junction. There is enormous dilatation of the large intestine, sometimes spreading round as far as the cæcum. This dilatation is accompanied by marked hypertrophy of the bowel wall and, in some cases, ulceration due to the presence of hard fæcal material, which may persist to such an extent that perforation and general peritonitis occur.

Signs and Symptoms.—From an early date these children suffer from intractable and increasing constipation, the bowels being opened once in weeks, when the motions are extremely offensive. Purgatives merely give rise to nausea and vomiting, and enemata are often retained. The passage of a flatus tube often gives exit to much foul-smelling flatus. At first these children do not show any of the signs of toxæmia, but gradually the foul breath and furred tongue, the loss of energy and appetite, the ready tendency to infection show themselves, and either as a result of this or perforation these children die. The abdomen is enormously distended, and the costal margins are everted by distension, visible peristalsis may be marked.

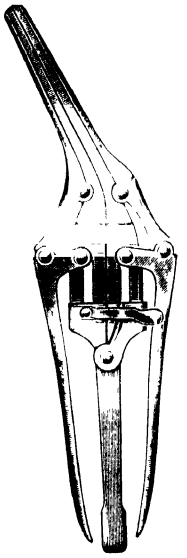

FIG. 821. THREE-BLADED CLAMP.

Treatment.—Those cases which are the result of neurogenic inco-ordination are cured by division of the sympathetic plexus around the first inch of the inferior mesenteric artery. The rest of the cases, if there is no obvious constricting band, must be treated medically. In order to determine which of those cases are suitable for sympathectomy, a spinal anæsthetic is given after a barium enema, usually of many pints, has been run in. The majority of this will be returned into the bed if the condition is due to spasm at the pelvi-rectal sphincter, as the spinal anæsthesia cuts out the nervous impulses to it.

Enteroptosis, or Glénard's disease, is a not uncommon condition in which there is a displacement downwards of the stomach and intestine, but the liver, spleen and kidneys are often involved (general visceroptosis). The cause varies, but sometimes the condition appears after an acute illness; more usually it is chronic and develops gradually. The relaxed abdominal wall which follows repeated pregnancies is often present, and tight-lacing used to be an important causative factor. Women are much more frequently affected than men. The condition *per se* is not necessarily associated with symptoms, but in a considerable number of cases marked neurasthenia is present, possibly from the drag of the viscera upon the sympathetic plexuses in the posterior abdominal wall. The amount of displacement is no measure of the severity of the symptoms. The stomach may be well below the costal arch, and when inflated stands out prominently, both curvatures being visible, it is usually distended atonically, and succussion sounds may be heard. The relaxation of the small intestines is alluded to in connection with the ætiology of hernia (p. 1333). The transverse colon may sag downwards into the pelvis, and the kinking of the splenic and hepatic flexures thereby induced may be an important element in the production of constipation. It also drags on the duodenum, and may give rise to symptoms erroneously attributed to gastric or duodenal ulceration. The spleen and liver may also slip downwards. Displacement of

the kidneys is referred to under the heading 'Movable Kidney' (p. 1441)

Treatment must be suitably modified according to circumstances and due allowance made for the neurasthenic element. A course of Weir Mitchell treatment, *i.e.* rest and feeding, is often valuable, both for its influence on the nervous state and also in assisting to increase the deposit of fat. Electricity and massage to the abdominal walls,

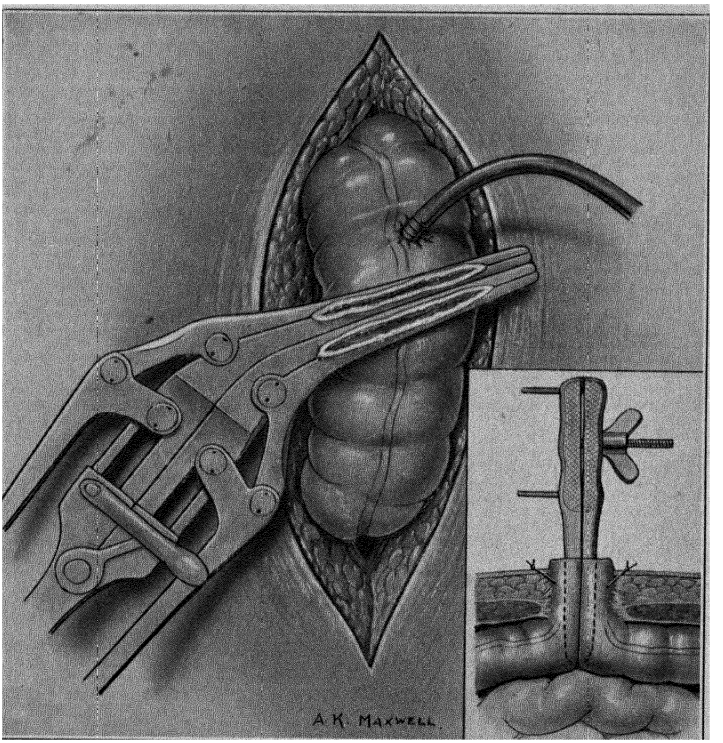

FIG. 822.—RESECTION OF CARCINOMA OF THE COLON (RANKIN'S METHOD)
(The inset is the method employed for closing the colostomy.)

together with appropriate remedial exercises, help to restore their tone and to improve the condition of the underlying viscera. An abdominal belt or bandage will do much to relieve symptoms, especially if applied with the patient in the Trendelenburg position. Operation is not to be lightly undertaken; but if a fair test has been given to the above measures, it may be justifiable to open the abdomen and stitch up into place organs like the stomach, transverse colon, liver, or spleen, or to brace up the abdominal wall by some plastic operation such as that

suggested on p. 1253. For treatment of movable kidney, see p. 1442. The question of removing or short-circuiting the kinked colon may also have to be considered.

Intestinal Stasis is a term introduced to indicate a condition of abnormal delay of the bowel contents in some part of the intestinal canal, especially the colon. This delay allows putrefactive changes to occur, and in consequence toxins may be absorbed therefrom and produce not only a general depreciation of health, but also considerable degenerative changes in many of the viscera and tissues. Sir Arbuthnot Lane has done excellent work in emphasizing the character and dangers of this condition, although his theories and conclusions are not accepted by all surgeons. He attributes the whole range of phenomena to the assumption by man of the erect attitude and the natural consequential tendency of the intestines to drop. To counteract this, a reactive formation of peritoneal bands and membranes occurs, producing results more or less similar to those following peritonitis, and attaching the intestines to parietal structures. Thus to the outer side of the ascending colon one often finds a set of membranous bands running downwards and inwards from the parietal peritoneum to lap over the intestine and be attached to the front of the ascending mesocolon; this thin vascular veil is sometimes termed *Jackson's membrane* (Fig. 823), and if at all exaggerated may cause interference with the activity of the colon. At the hepatic and splenic flexures similar developments occur, and may cause such contraction as to kink the gut severely. Even more importance is attached by Lane to a band of adhesions running from under the surface of the mesentery to the anti-mesenteric border of the ileum, a few inches from the cæcum; the contraction of this band causes a kink at the termination of the ileum (*Lane's ileal kink*, Fig. 823), and thus determines retention of the ileal contents. The result of this is increased sagging of the small intestine in the pelvis and dragging on the duodeno-jejunal flexure; this is stated to cause a reactive formation of bands, which first support the flexure, but, if excessive, subsequently kink it, causing dilatation of the stomach and duodenum (C). Similar bands and kinks may be developed elsewhere. The phenomena are looked on as mechanical and reactive, and not inflammatory, although structures such as the appendix or gall-bladder are often involved in the adhesions. This view is not universally accepted; many surgeons look on the bands as the result of inflammatory attacks, and Sir Arthur Keith has shown that many

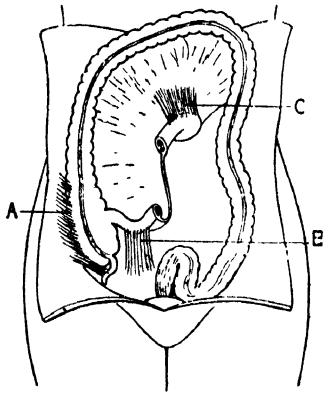

FIG 823.—PERITONEAL BANDS OR THICKENINGS OFTEN ASSOCIATED WITH INTESTINAL STASIS

A, Jackson's membrane, B, Lane's ileal kink; C, kink at flexura duodeno-jejunalis

of them are of congenital origin and due to an exaggeration of the antenatal plastic peritonitis which fixes the colon in its place.

The **Symptoms** arising from intestinal stasis are threefold: (i.) *Mechanical* results follow from distension of different portions of the intestinal canal, *e.g.* the stomach, duodenum, ileum, or colon. Most of these have been alluded to already, but one would especially emphasize the troubles that arise from prolapse of the colon into the pelvis. The colon becomes filled with liquid fæcal material which cannot be evacuated. (ii.) *Inflammatory* phenomena of many types follow this stasis, *e.g.* gastric and duodenal ulceration, appendicitis, colitis, etc. (iii.) *Toxic* results necessarily ensue, and include such conditions as enfeebled circulation, cold sweating, cyanosed extremities, facial pigmentation, muscular weakness, with sundry nervous and perhaps mental perturbations. The resistance of the individual to bacterial invasion is also lowered, and various infective diseases may supervene.

Treatment.—Early and mild cases can often be treated effectively by improving the tone of the abdominal wall and increasing the motor power of the colon by a course of abdominal massage and suitable remedial exercises. Purgatives, intestinal antiseptics (such as liquid paraffin), careful attention to diet, and a sufficiency of rest in the recumbent posture, will do good; a relaxed abdominal wall, of course, requires remedial exercises, a suitable external support, or operative treatment to tighten it up. It must be accepted as a cardinal dictum that mere looseness and displacement downwards of the colon is a matter of comparatively little importance in itself. Where, however, some definite cause of obstruction is present, *e.g.* a band across the ascending or transverse colon, the cæcum and part of the ascending colon may hang down into the pelvis, and be literally transformed into a cesspool filled with putrid fæcal material; the walls are often 'soggy,' thickened and inflamed. Under such circumstances cæcoplication may suffice, but more often complete removal of the cæcum and ascending colon is advisable, and excellent results follow a hemicolectomy. The mortality is comparatively small (2·5 per cent.). Under no circumstances should a complete colectomy be undertaken for intestinal stasis; the operation is a serious one, giving even in the most capable hands a mortality of 16·5 per cent.; and the after-results are sometimes most unfortunate, the patient suffering from constipation of an aggravated type, or from incessant and intractable diarrhœa owing to the removal of what is in reality the drying ground of the fæces.

Fæcal Fistula.—This term is applied to any abnormal communication with the intestine through which passes a certain amount of the bowel contents (Fig. 824). It differs from an artificial anus in that the greater portion or the whole of the fæcal matter passes through the latter; in a fistula only a small portion is thus discharged.

Fistulæ may be of two types, the *external* and the *internal*; in the former, the opening is in the skin; in the latter, the abnormal communication is with some viscus, *e.g.* the bladder. The term *fistula bimucosa* indicates the existence of a communication with another section of the intestinal canal; it may be of little importance if the

affected segments are close together, but should an opening be established between an upper and a lower segment, *e.g.* between the upper end of the jejunum and the transverse colon, nutrition will be seriously affected if the fistula is large enough to allow of the deflection of the greater part of the intestinal contents

The condition may result from many *causes*, but it is needless to discuss them *in extenso*. They may be divided into the following groups (1) Those due to conditions inside the bowel, such as the impaction of a foreign body, this will lead to inflammation, ulceration, and localized peritonitis, which will attach the affected coil of gut either to the abdominal wall or to some other viscus; suppuration occurs, constituting a localized intraperitoneal abscess, which bursts either externally through the skin or internally into the attached bowel, and possibly permits the foreign body to escape. If the cause thus disappears or is removed, the fistula will often close spontaneously.

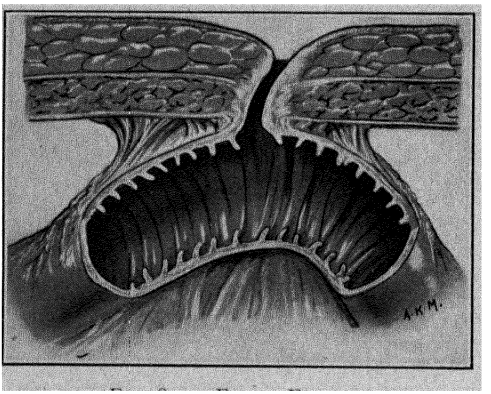

FIG 824.—FÆCAL FISTULA

(2) Cases associated with primary disease of the intestinal wall are not uncommon, and amongst them may be mentioned appendicitis, diverticulitis, tubercle or actinomycosis, and malignant disease. Strangulated hernia sometimes results in the formation of a fæcal fistula in consequence of a localized gangrene of the bowel wall. (3) Extra-intestinal conditions may also lead to the establishment of a fæcal fistula, as, *e.g.*, tuberculous peritonitis, where an abscess forms outside the gut in the diseased peritoneal focus, and opens both externally and internally; this occurs most frequently in the neighbourhood of the umbilicus Wounds of the abdominal wall, such as stabs, would be included in this category. (4) Finally, one must mention the congenital variety resulting from the persistence of a Meckel's diverticulum, and this again is usually umbilical in position, and (5) the post-operative, where the fistula is made deliberately for drainage, irrigation, or feeding purposes (cæcostomy or jejunostomy).

All these conditions are referred to in the various sections dealing with the originative disease or condition, and it is needless to discuss treatment of them apart from that of the cause to which they are due.

Operations on the Intestines.

1. **Enterotomy** is a term which is only correctly applied to an incision made into the intestine either for the removal of a foreign body, such as a gall-stone, or for the examination of its interior. The wound should always be placed in the longitudinal axis of the gut, and along its antimesenteric border; it is closed by a single or double row of sutures.

2. **Enterostomy,** or the formation of an artificial opening into the bowel, may be undertaken for several reasons, and any part of the gut may be opened.

(*a*) The jejunum may be brought to the surface and opened (*jejunostomy*) in cases of cancer of the stomach where gastro-enterostomy and pylorectomy are impossible and the patient is dying of inanition; he can subsequently be fed by the fistula in this way produced. The actual operative procedure is as for gastrostomy. It may also be employed with advantage in ulcers of the stomach which have contracted extensive adhesions posteriorly, and especially to the pancreas, when the condition of the patient does not warrant the performance of a serious operation. After feeding by this means for six or eight weeks, excision can sometimes be undertaken safely, and it may be found that the ulcer is completely healed, and that the adhesions to the pancreas are slight on account of the subsidence of the inflammatory phenomena. Some surgeons advise that the jejunum should be brought to the surface through a hole in the omentum so as to prevent any possibility of leakage. Jejunostomy is also sometimes used in the treatment of acute obstruction when the patient is too ill to permit of any exploratory procedure directed to the cause.

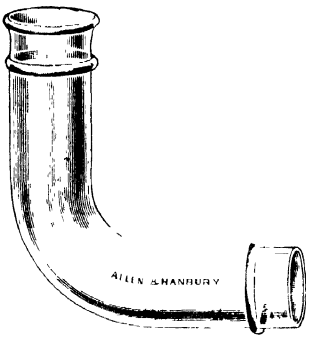

FIG. 825.—PAUL'S TUBE (GLASS)

(*b*) The ileum may need to be opened (*ileostomy*) and drained in cases of obstruction not lower than the cæcum or ascending colon, when the small gut is much distended and the patient's general condition so bad that no prolonged search for the cause and no attempt to deal directly with it, even if obvious, are possible. The abdomen is opened either in the middle line or in the right iliac region, a suitable distended coil is withdrawn and incised after carefully protecting the peritoneal cavity from fæcal infection. A large trocar and cannula are introduced so as to allow the first gush of flatus and fluid contents to escape, the opening is then enlarged and a rubber drainage-tube stitched in, or a Paul's (glass) tube tied in (Fig. 825) by means of a purse-string suture passing in and out through the whole thickness of the bowel wall, and the affected coil of intestine fixed to the abdominal wall. A thin tube of rubber is attached to the other end of the glass tube,

and through this the intestinal contents are temporarily allowed to escape without contamination of the peritoneal cavity or of the wound.

If the patient recovers from the acute symptoms, a second operation will be needed in order to deal with the cause, as well as to re-establish the continuity of the intestinal canal.

3. **Appendicostomy** is performed in some cases of ulcerative colitis. Local anæsthesia is sufficient in most cases, and the appendix is exposed as in the operation of appendicectomy. The peritoneum is sutured to the cæcum around the base of the appendix (Fig. 826). Care is taken to preserve the mesentery of the appendix. The wound is closed in the usual manner. After seventy-two hours, the appendix is cut off down to the last inch, which is then split longitudinally and the flaps anchored back (see Fig. 826). This can be performed with a diathermy cautery.

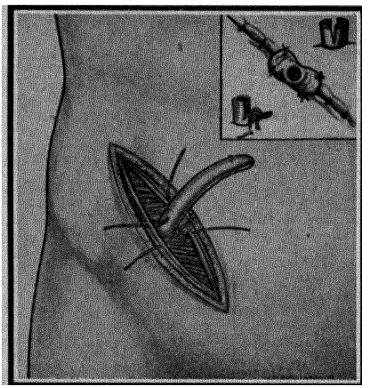

FIG. 826.—APPENDICOSTOMY

a, The base of the cæcum is sutured to the peritoneum, *b*, special method of dividing the appendix and suturing flaps

Appendicostomy is preferred to cæcostomy or ileostomy because it is easily and quickly performed with a negligible mortality. There is a minimal fæcal leak and no odour. It is in fact a very satisfactory method of irrigation of the large bowel.

4. **Cæcostomy** is sometimes required in cases of membranous or ulcerative colitis where there is an abundant secretion of pus and the patient's life is threatened by pyrexia and toxic exhaustion, and in those cases where the appendix has been removed. The object of the operation is twofold, *viz.* to prevent the irritation caused by the passage of the fæces over the ulcerated mucous membrane, and to permit the colon to be irrigated. Inasmuch as the contents of the bowel at this level are fluid and irritating, the opening must be as small as possible, and this is effected by stitching firmly into the bowel a piece of rubber drainage-tube as in gastrostomy, and then fixing the bowel to the skin and abdominal muscles. It is possible, however, that in spite of every precaution the skin will become inflamed.

Cæcostomy is also required for acute obstruction of any portion of the colon above the pelvic segment in order to empty and drain the distended and paralyzed bowel. It must, of course, be followed by excision of the growth with restoration of the continuity of the intestine or by some suitable short-circuiting operation, and until the restored colon is functioning satisfactorily the cæcal fistula must not be closed The fact that this opening is in the right iliac fossa permits the major

operation to be undertaken without infection of the wound. Finally, the cæcal fistula is closed by a plastic operation.

5. **Colostomy** consists of making an artificial opening into either the transverse or sigmoid colon. It is customary to refer to a temporary and a permanent colostomy, the former being used, as its name implies, as a temporary measure (Figs. 827 and 828). In order that closure should be effected with ease, in such a colostomy only the antimesenteric border of the gut is approximated to the skin surface, and no spur of mesocolon is formed as when a small loop of bowel is brought out and retained in position by one of several means. The closure of such a colostomy is admittedly easy, but it is very imperfect in its function, as much of the fæcal material which should be short-circuited passes down the efferent limb so that in nearly all cases a spur colostomy is required.

A **transverse colostomy** is the operation usually to be performed when an inoperable carcinoma of the sigmoid colon is present or

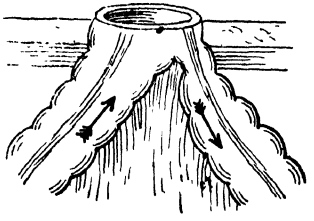

FIG. 827.—DIAGRAM OF TEMPORARY COLOSTOMY, SHOWING THE SINGLE OPENING ON A LEVEL WITH THE SKIN, THE PASSAGE TO THE LOWER BOWEL BEING BLOCKED BY A SPUR OF MUCOUS MEMBRANE.

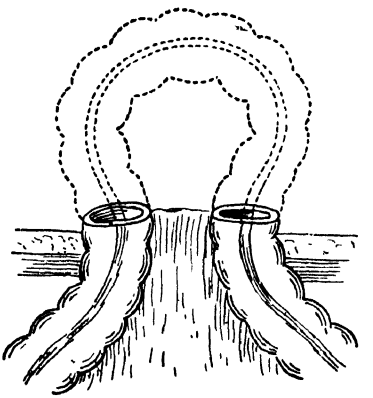

FIG. 828.—DIAGRAM OF PERMANENT COLOSTOMY, SHOWING THE TWO OPENINGS SEPARATED ONE FROM THE OTHER BY A SECTION OF THE MESENTERY.

where an inoperable carcinoma is present higher up, and in which a short-circuiting operation, obviously the most desirable, cannot be carried out for such reasons as the age and condition of the patient and the fact that effective mobilization is impossible. In cases where a colostomy is necessary as a first stage in a resection of a growth in the descending or sigmoid colon, or in cases of diverticulitis, this is the most desirable, more so than a cæcostomy, in that cleansing of the bowel is easier and short-circuiting of the intestinal contents is more complete.

If an exploratory laparotomy has been performed, the transverse colostomy may be established at the upper end of the incision or through a separate longitudinal incision piercing the fibres of the rectus muscle. The transverse colon is identified and a small incision, some 2 inches long, made through the omentum over it. The portion selected for the colostomy is then brought with some of its mesocolon through this aperture in the omentum, the edges of the latter then

being stitched to the transverse colon and mesocolon to prevent any herniation of small intestine which might otherwise result.

One of two methods of retaining the colostomy at the surface and preventing it slipping back into the abdomen may be used. In the first a thick solid glass tube is made to pierce the mesocolon fairly close to the bowel. The wound is then sewn together, care being taken to approximate it snugly round the colostomy, and as an added precaution to prevent the latter disappearing, the peritoneum is sutured to it with a few catgut sutures. One end of a piece of rubber tubing is then slipped over each end of the glass tube to prevent the latter slipping out before its removal in about ten days when adhesions have formed around it (Fig. 829).

The other method is that of Miles, in which a thick piece of silk is made to surround the mesocolon, passing through it close to the bowel on either side of the colostomy. This suture is then drawn sufficiently tight to cause partial constriction of the veins in the mesocolon, and is fixed to the abdominal wall by tying it over a silkworm gut loop tied in the abdominal wall. The congestion produced causes the rapid formation of adhesions, with prevention of any return of the colostomy into the abdomen If acute obstruction is not present, it is desirable to delay opening for about twelve to twenty-four hours

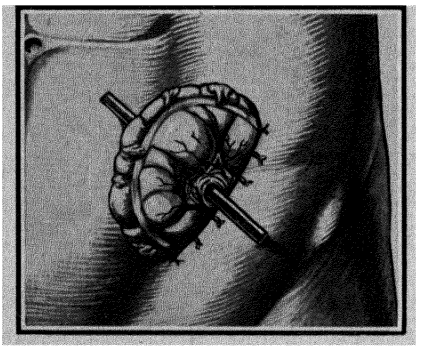

FIG 829.—ILIAC COLOSTOMY

A glass rod supports the colon on the abdominal wall

Iliac Colostomy consists in making an artificial opening into the sigmoid colon. It is required under the following conditions: (1) For congenital absence of the rectum, when a perineal incision has failed to discover it, (2) for chronic obstruction of the lower end of the large intestine, which cannot be relieved by enemata or medical means, such as that arising from simple or malignant stricture, or from the pressure of pelvic tumours, (3) for carcinoma of the rectum or sigmoid flexure, whether obstruction is present or not, if a radical operation is impracticable, or as a preliminary to excision, (4) for some cases of syphilitic, tuberculous, and other forms of ulceration of the rectum, which cannot heal as long as they are irritated by the passage of fæces; (5) for irremediable cases of recto-vesical and recto-vaginal fistula, whatever their origin, (6) for volvulus of the sigmoid flexure, the iliac operation being needed not only to relieve the obstruction, but also to prevent recurrence; and (7) for gunshot or other wounds involving the rectum with extravasation of fæces.

In most cases it is probably best to explore the abdomen through

a paramedian incision, as the extent of any lesion may then be determined, and, in addition, a pelvic colon bound down to the posterior abdominal wall, or one in which the mesocolon is deficient, may be mobilized sufficiently to allow of its being exteriorized by incising the peritoneum on its outer side. The loop of bowel is drawn through a separate oblique incision, some 3 inches long, with its centre over a point at the junction of the outer with the inner two-thirds of a line joining the umbilicus to the anterior superior iliac spine.

Either of the two methods described for establishing a transverse colostomy may be employed to prevent any slipping back of the bowel, or, alternatively, by making the incision in the iliac fossa-shaped so that the apex of the skin flap may be pulled through the mesocolon and sutured by several silkworm gut sutures to the skin on the opposite side of the colostomy, thus establishing a skin bridge.

The colostomy should be so placed that the afferent loop is drawn fairly tight, as otherwise it is liable to prolapse into the wound. The peritoneum in all types of colostomy should be sutured to the bowel wall to prevent prolapse of intestinal contents.

Complications occurring in a colostomy are: (1) Prolapse of the intestine through the wound, due to inefficient suturing. (2) Prolapse of the sigmoid itself where the afferent limb has not been drawn tight. (3) Production of a hernia where the muscles have been incised. (4) Stenosis of the colostomy where a skin bridge has been used. (5) Internal obstruction due to adhesions or perhaps a coil of bowel looping round a limb of the pelvic colon.

Care of a Colostomy.—An aperient is often necessary to start the colostomy working, and this should be given on the fourth night after operation, colostomy wash-outs beginning on the following morning. During the first fortnight or so, until the bowel begins to work regularly, a pint of soft soap solution is used, but this is subsequently replaced by water and saline. It is unnecessary to give any aperients with these wash-outs. In an attempt to control the action of the bowel by purgatives no regularity can be assumed, and the patient may have several actions during the day. But if the bowel be completely washed out in the morning, a procedure taking some three-quarters of an hour, it can be completely emptied, and, except for an occasional irregularity, is clean until the following morning. As regards a belt that is worn, this should be fitted with no cup, at the most one which is almost flat, as the former predisposes to herniation.

If closure of the colostomy is required, this should be effected extraperitoneally by suturing the walls of the bowel together and sewing the muscle layers and skin over this.

1. **Enterectomy,** or excision of a portion of the bowel, is required in the following conditions: (*a*) For the removal of gangrenous gut after strangulation, whether internal or external; (*b*) in the treatment of multiple penetrating wounds, as after a stab or gunshot injury; (*c*) for the closure of an artificial anus or fæcal fistula; (*d*) for the removal of a simple or malignant stricture; and (*e*) in some cases of intussusception. Naturally, the results vary largely with the condition for which it is performed, with the site of the lesion, and with

the experience and skill of the operator; a much higher rate of mortality follows when the excision is done for malignant disease, for gangrene following strangulation, or for intussusception, than when performed for other causes. Operations on the large intestine are also less favourable than those directed to the small gut. Whenever practicable, the bowel should be thoroughly emptied prior to operation, and rendered as sterile as possible by the use of such drugs as calomel (gr. i. daily), salol, β-naphthol, kerol, etc., for a few days previously. Should this be impossible, and when the bowel is distended, it must always be opened previously and drained, and the anastomosis delayed until the bowel is empty.

The abdomen is opened by any suitable incision, and the portion to be removed clearly defined, the general peritoneal cavity being protected by a careful packing with abdominal cloths or gauze. The bowel must then be *clamped* on either side of the seat of operation, so as to prevent the escape of intestinal secretions or fæces.

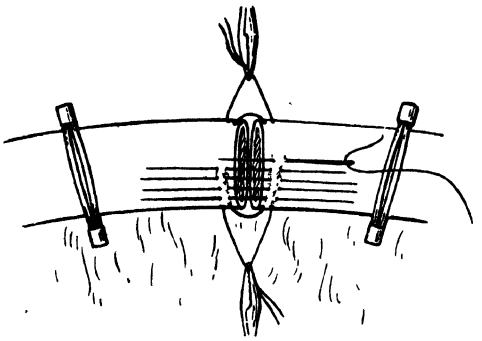

FIG 830.—END-TO-END ANASTOMOSIS BY SIMPLE SUTURING.

For clearness' sake, the first row of stitches in the mucous membrane has been omitted, and the sero-muscular sutures of the Lembert type are represented as interrupted. In practice one would use a continuous stitch.

The affected portion is removed by scissors or diathermic cautery, and a V-shaped portion of the mesentery, after securing as far back as possible the main nutrient vessels to the diseased area. It must be remembered that the terminal vessels run circularly round the gut, and have but few lateral anastomoses, and therefore it is desirable that the incisions should diverge slightly from the mesenteric attachment, otherwise the projecting edge of the anti-mesenteric border is certain to slough, and septic peritonitis will result. The wound in the mesentery is subsequently secured by sutures, and the divided ends of the bowel united by either an end-to-end or a lateral anastomosis.

2. **End-to-end Anastomosis** is effected by *simple suturing* without any special apparatus, the surgeon trusting to the deftness of his fingers and the accuracy of his stitches.

The mesenteric and anti-mesenteric borders are first united by stitches which are left long for the assistant to hold; the gut is thereby steadied (Fig. 830). Two rows of sutures are used; the first passes through the whole thickness of the bowel walls, but as close to the divided edges as possible, so as not to invert too large a portion and thus diminish the lumen. The second is a

sero-muscular stitch of the Lembert or Cushing type. Catgut is the suture material employed. Extreme care must be taken in dealing with the mesenteric attachment, as the peritoneal coats separate there in order to enclose the bowel, and the muscular coat retracts considerably; leakage is more likely to occur at this point than at any other.

3. **Lateral Anastomosis** of the intestine is often employed in order to undertake the short-circuiting of some malignant growth, or of a stricture which cannot otherwise be dealt with. It is also used instead of end-to-end anastomosis to unite divided segments of intestine. The open ends are first entirely closed, after division by knife or thermo-cautery. The portions of bowel are now made to overlap, and the actual anastomosis is performed as for gastro-enterostomy (Fig. 831) Suitable clamps are applied above and below, and the coils are brought into close apposition. Longitudinal incisions are made through the

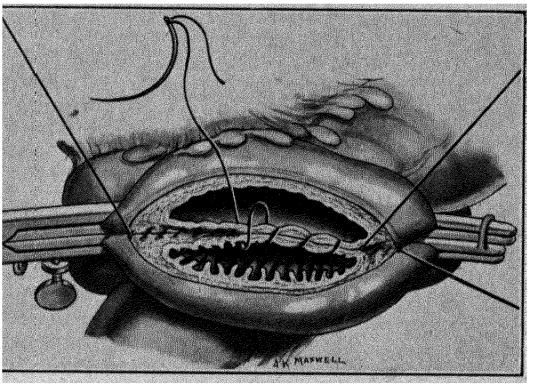

FIG 831 — LATERAL ANASTOMOSIS OF BOWEL AFTER COMPLETE DIVISION.

sero-muscular coats, and these are united on the posterior aspect of the proposed junction. The segments of bowel are then opened, and any fluid or solid contents carefully mopped up and removed. A continuous suture through the whole thickness of the wall is carried round the opening back and front, and serves not only to unite the segments together, but also as a means of hæmostasis. A sero-muscular row of stitches completes the anastomosis. Finally, the divided edges of the overlapping segments of the mesentery are sutured so as not to leave an aperture through which internal strangulation might occur.

4. **Lateral** or **End-to-side Implantation** is a procedure not uncommonly required in order to connect the divided end of the ileum to the transverse colon. The junction may be made by simple suturing, two rows of stitches being introduced.

5. **Colectomy,** or excision of a large or small portion of the large intestine, is not quite so simple a matter as removal of a part of the small bowel, owing to the greater complexity of the peritoneal

reflections and its less mobility. The latter difficulty can, however, be largely overcome, and the colon freely 'mobilized,' by dividing the peritoneal attachments on the outer sides of both ascending and descending colon, or by detaching the transverse colon from the under side of the omentum; the varying portions of the bowel can then be freely drawn over to the middle line with the vessels, nerves, etc., being held merely by one layer of peritoneum. By the assistance of this procedure, large portions of the colon can be removed without much danger or difficulty, and union of the upper and lower segments can be readily effected, either by end-to-end or by lateral anastomosis, after closing the divided ends. One essential precaution must be observed if success is to be obtained, *viz.* the colon *must* be satisfactorily emptied beforehand; in any case of partial or complete obstruction with retention of the fæcal contents a preliminary cæcostomy should be undertaken.

6. **Cæcoplication** is occasionally required in the treatment of a dilated atonic cæcum, which is often displaced downwards into the pelvis. It consists in infolding the wall by suturing together two of the longitudinal muscular bands, thus reducing the lumen by one-third. This suturing extends from the caput cæci as far as, or a little beyond, the ileo-cæcal valve. It is not a desirable procedure when subacute inflammatory changes are present in the cæcum and ascending colon, but apart from these it is sometimes useful.

Appendicitis (*Syn.* : Perityphlitis, Epityphlitis, etc.).

Appendicitis is an affection which may appear at any time of life, but it is most common in young adults, and the male sex is more frequently attacked than the female. The disease is sometimes of but slight significance, but occasionally runs such a virulent course as to destroy life in a few hours. Its importance lies in the fact that it is an infective process, and inasmuch as the peritoneal envelope is generally involved, a certain degree of peritonitis is almost necessarily a consequence.

Ætiology.—Many different conditions contribute either directly or indirectly in determining an attack of appendicitis. (1) The appendix is usually looked on, not as an actively functional structure, but as a degenerated relic of little importance. It often has but a poor blood-supply, derived from the posterior ileo-cæcal branch of the ileo-colic artery (Fig. 832). The main nutrient vessels run along the free border of the meso-appendix, but a second twig often runs down the base of the mesentery. (2) A large amount of lymphoid tissue is present in the mucous membrane, especially in young people, so that the title of 'abdominal tonsil' has been applied to it. The lymphoid follicles have a tendency to atrophy with advancing age. Bacteria are constantly found within the lumen and in the lymphoid follicles, and inflammatory processes are set up by them within its walls. Is it possible that herein lies the secret of the appendix, *viz.* that it plays some part in producing immunity from these germs, and that indiscriminate removal of healthy appendices is an interference with one

of Nature's immunizing mechanisms as injudicious and often as harmful as is unnecessary removal of tonsils and adenoids? Acute appendicitis is then to be looked on as a losing fight put up by the appendix on behalf of the body generally; the germs prove too powerful for the local immunity. Chronic appendicitis would then represent a maintained fight against a persistent enemy, and A. obliterans a condition resulting from a successful campaign at the expense of the defensive mechanism. This may also explain why removal of a chronically inflamed appendix is often followed by so little benefit to the patient. (3) Its length and direction vary considerably in different individuals In length it may measure anything between 1½ and 11 or 12 inches, but is usually 3 to 4 inches long, obviously

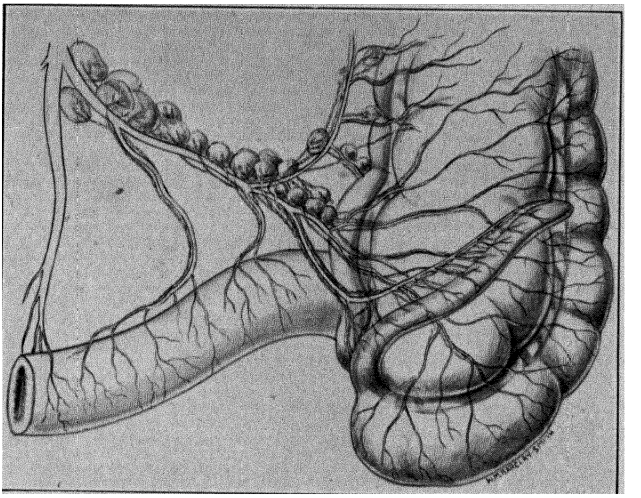

FIG 832.—THE POSTERIOR SURFACE OF THE CÆCUM, SHOWING THE BLOOD-SUPPLY AND LYMPHATIC DRAINAGE OF THE APPENDIX

added length means increased liability to harmful kinks and twists. As to direction, it may lie in any axis, and the clinical picture is largely influenced by its anatomical position The commonest situation is behind the cæcum and ascending colon, directed upwards (Fig. 833), but it is not unusual for it to overhang the pelvic brim, and then pelvic complications almost always accompany an attack of appendicitis. When the appendix lies to the outer side of the cæcum, the inflammatory reaction may be more localized. (4) The extent of attachment of the meso-appendix is an important element, since the portion which projects beyond its free border is less well supplied with blood As a matter of fact, the mesentery often does not extend beyond the junction of the middle with the distal third, and perforation not unfrequently occurs about this spot. (5) The communication with the

cæcum is usually small, and is guarded by an insignificant fold of mucous membrane, known as the valve of Gerlach. Sometimes this aperture becomes blocked, or the orifice stenosed, as the result of a preceding inflammation of the mucous lining of the cæcum, so that an accumulation of mucus occurs within the appendix, leading to its dilatation into a cyst-like pouch. (6) The *content* of the normal appendix consists of a little mucus and a certain number of bacteria, similar to those found in the neighbouring intestine; a generalized infection of the intestinal canal, perhaps the result of oral sepsis, will obviously add to this number. *Foreign bodies*, such as pips, pins, etc., are occasionally found within it, and by their presence and irritation may light up an attack of appendicitis. They are much less common than was formerly imagined, and the fact that the opening into the

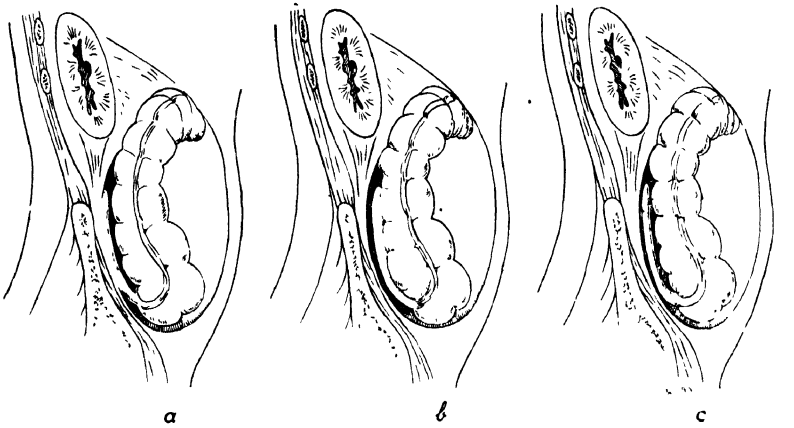

FIG. 833.—THE VARIOUS ATTACHMENTS OF THE RETROCÆCAL APPENDIX

a, Attached to the posterior abdominal wall in the right iliac fossa, *b*, attached to the posterior wall of the cæcum, *c*, lying free in the retrocæcal fossa

intestine is generally not larger than to admit a No. 8 catheter will explain this rarity. *Fæcal concretions* are comparatively common, they are oval bodies, varying from ½ to 1 inch in length, and usually laminated, consisting of dried fæcal material mixed with myriads of bacteria, and perhaps with a pip or foreign body as a nucleus. They are not very hard, and can easily be cut with a knife, or even crushed between the fingers. Occasionally they can be recognized in a radiograph of the pelvis taken for other reasons. (7) Appendicitis is not unfrequently associated with a true typhlitis or with a more generalized colitis, probably due to chronic constipation. Dysenteric ulceration may involve the appendix, or lead to stenosis of its orifice, but it is rarely implicated in typhoid fever. (8) *Injury* in the shape of a strain or sudden twist is not unfrequently mentioned as the cause of an outbreak, and probably acts by displacing a long appendix in such a way as to lead to kinking and possibly to obstruction of the nutrient

vessels. When a concretion is present, the final attack may be determined by some traumatism which modifies the vascular conditions around it.

There can be no question as to the greatly increased frequency of appendicitis at the present day, especially amongst those who live in large towns or cities. It is difficult to assign any one cause for this, but possibly many conditions may be at work, *e.g.*: (*a*) Dental disease and degeneration, and consequent oral and intestinal sepsis. (*b*) The bolting and non-mastication of meals associated with the hurry and scurry of modern life, leading to chronic irritation of stomach and

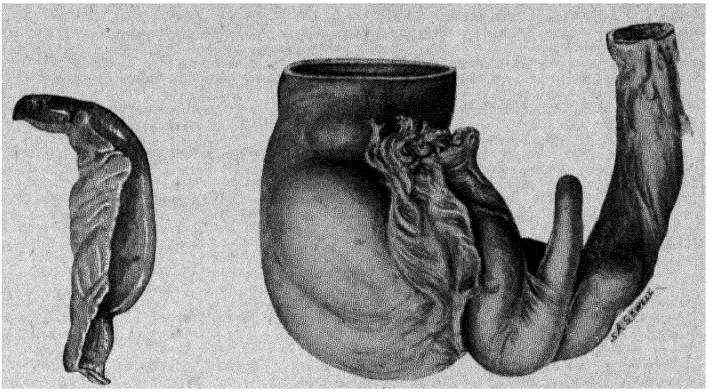

FIG 834.—APPENDIX WITH STRICTURE AT PROXIMAL END

The patient was a boy, aged seven years, who had had several attacks of pain in the abdomen, with high temperature lasting a few hours, sickness, and tenderness in the right iliac fossa, evidently due to retention of secretion

FIG 835.—VERMIFORM APPENDIX TIED DOWN BOTH TO CÆCUM AND ILEUM, AND DOUBLED ON ITSELF BY OLD-STANDING ADHESIONS

The appearances in this illustration are very characteristic of what is frequently seen; but the case from which it was taken was a very unusual one It occurred in a baby of seven days, who was operated on for acute obstruction due to the adhesions, which were old-standing, and evidently ante-natal. The child died, and the cæcum was subsequently removed.

bowel. (*c*) Chronic constipation is a most important factor. (*d*) The greatest dietetic change of recent years consists in the increased amount of meat that is eaten.

Pathological Anatomy.—Appendicitis is an infective malady, due to invasion of the walls of the appendix by organisms, especially the *Streptococcus pyogenes*, the *B. coli*, and other intestinal bacteria. These find an entrance into the wall of the appendix, either through an eroded area of the mucous membrane due to the impaction of a foreign body or of fæcal concretion, or else they are absorbed into the lymphoid tissue so abundantly present, and are able to overwhelm the protective mechanism provided thereby. The results may be best described under the following headings

(1) **Changes in the Appendix itself.**—In the simpler forms a mere *catarrh* of the appendix results. The organ looks red and swollen, and its peritoneal surface may be smooth, or roughened by loss of endothelium and deposit of lymph. It feels stiff from effusion, and has lost its natural flexibility. The muscular coats are often infiltrated with leucocytes, and this is especially noticed around the hiatus muscularis through which the vessels enter. The mucous membrane is thickened, engorged, and infiltrated with polymorphonuclear leucocytes, and here and there erosion or ulceration is present. If the process goes no further, healing occurs after a time, and this is often associated with *fibrosis*, which may show itself (*a*) as a more or less generalized sclerosis of the whole appendix, which may remain stiff and hard, and is perhaps doubled on itself (Fig. 835), or (*b*) as a stricture of the tube (Fig. 834), which leads to retention of a mucous or mucopurulent effusion (hydrops or empyema of the appendix), or (*c*) obliteration of the appendix may occur (*appendicitis obliterans*) This usually commences at the tip and works up towards the gut, but is not completed until the patient has suffered from many mild attacks. (*d*) Occasionally small *diverticula* or pouches (Fig. 836) form as the result of a hernial protrusion of the mucous membrane through some gap in the muscular wall, *e.g* the hiatus muscularis. They are usually not larger than a hempseed, but are of importance, since the thin walls readily give way, and thereby a perforative peritonitis may be lighted up.



FIG 836.—DIVERTICULA OF APPENDIX (KING'S COLLEGE HOSPITAL MUSEUM)
One has perforated, the others are intact.

When *ulceration* occurs, the appendix is likely to be more seriously invaded with micro-organisms, and *suppuration* of many types may ensue. It may contain muco-pus in its lumen, and this may increase to the point of determining rupture of the appendix within a few hours, or the whole substance of the tube may be yellow with a diffuse purulent infiltration. The ulceration may gradually spread through the walls and lay open the peritoneal cavity, giving rise to a local or diffuse suppurative peritonitis.

Necrosis or *sloughing* of the appendix is due to an acute interstitial inflammation spreading from an impacted concretion, or from an ulcer of the mucosa, or results from kinking and thrombosis of the appendicular vessels in the meso-appendix. The whole appendix may slough, or merely a portion, and then usually the tip or the part immediately opposite the distal end of the meso-appendix. The

necrotic tissue is soft and easily torn, of a blackish, brown, or green colour, and always extremely offensive. It may be associated with a *perforation*, through which the concretion may escape. In all these cases a grave peritoneal infection follows.

(2) **Changes in the Cæcum** may accompany appendicitis. In the *catarrhal* variety a generalized typho-colitis is often present, and perhaps it would be more correct to speak of appendicitis as a complication of that condition. In these cases most careful discrimination is needed in order to prevent needless operation which will not improve the patient's health. In *suppurative* appendicitis the cæcum is generally inflamed and infiltrated, but rather from the peritoneal aspect than from within; operative treatment will then be quickly followed by resolution. Rarely does the inflammation become so severe as to lead to suppuration or necrosis of the wall of the cæcum; should this occur, it usually involves the base of the appendix, and may be followed by a fæcal fistula.

(3) The **Peritoneal Phenomena** associated with appendicitis are of the utmost importance.

In the milder cases the peritonitis is *protective* in type. The serous coat of the appendix becomes inflamed, sheds its endothelium, and becomes roughened by a deposit of lymph, and this results either in a thickening of the wall, or in a formation of *adhesions* which tie down the appendix in various directions. Most commonly it is simply fixed to the cæcum along part of its length, but sometimes it is firmly united to it for its whole extent. Adhesions may develop between the appendix and the omentum, the mesentery, or ovary, etc.; in fact, it may be united to almost any of the viscera, and may thereby give rise to some form of acute obstruction. It may also contract adhesions to the fascia over the psoas sheath or iliac vessels.

In the more serious cases an *infective* peritonitis occurs, and a *localized intraperitoneal abscess* is by no means uncommon; its extension is limited by the formation of adhesions between the omentum, the parietes, and neighbouring coils of intestine. Its exact anatomical relations depend on the original situation of the appendix. Frequently it is located below and behind the cæcum; sometimes it burrows down into the pelvis; in other cases it passes inwards amongst the intestines; or it may track up towards the liver either on the inner or outer side of the ascending colon.

Sometimes, when the general health is good and the infection not too virulent, the abscess may remain quite limited, and the pus be completely absorbed, or it may be encapsuled and inspissated. More frequently it increases in size, and may burst externally, its approach to the surface being heralded by brawny swelling, redness, and œdema; the most usual sites for external pointing are the outer part of the iliac fossa and the lumbar region. It may also open into any of the viscera, and then most commonly into the cæcum or bladder. Finally, it may break through the peritoneal adhesions, and involve the general serous cavity, causing acute diffuse peritonitis; in other cases a serous effusion into the peritoneal cavity is found, resulting from the irritation

of the abscess, and disappearing when it is opened. The pus contained in the abscess is usually of a stinking character, and in cases of sloughing of the appendix the fœtor may be intense; but the amount of smell is no gauge of the virulence of the process. Sometimes the débris of a broken-down concretion can be recognized in the pus, and sometimes a portion of the appendix as a slough. Gas is also present in some cases, having escaped from the bowel or been generated by the activity of gas-producing organisms, of which the *B. perfringens* (*Welchii*) is the most important.

In the worst cases a *spreading septic peritonitis* is observed, with but little tendency to limitation. The line of diffusion is governed by the anatomical relations of the appendix. If it is situated above the brim of the pelvis and on the outer aspect of the meso-colon, the effusion may extend to the right kidney pouch, and a subphrenic abscess be determined; if it is on the mesial aspect of the meso-colon, the effusion will probably be limited by the mesentery to the lower half of the abdomen, and will occupy the pelvis and left iliac fossa. In time, however, the whole peritoneal cavity will be affected, and then operative treatment is little likely to be successful. The effusion in the first place is serous and due to streptococci, but later it becomes turbid, and finally fibrino-purulent or frankly purulent.

(4) Various **complications** may be associated with any of these different types of appendicitis. (*a*) The veins in the meso-appendix may become thrombosed and infected with pyogenic organisms; detachment of emboli may lead to the occurrence of *pylephlebitis* and pyæmia. (*b*) *Thrombosis* of the femoral vein may develop; if on the right side, it is probably due to implication of the right iliac vein in the inflammatory process; but if it happens, as is much more common, on the left side, it must be due to general toxic causes; or, if it occurs after operations, to thrombosis spreading from vessels divided in the anterior abdominal wall. (*c*) Chronic or subacute ovaritis often accompanies appendicitis in women; it is probably due to the position of the appendix, which hangs over into the pelvis. (*d*) Various renal complications may supervene, usually from pressure of the inflammatory mass on the renal vein, or on the ureter as it crosses the pelvic brim, resulting either in hæmaturia or in renal colic. (*e*) Inflammation of an appendix located in a hernial sac is referred to hereafter. (*f*) Lastly, obstructive phenomena may be induced by the paralyzed condition of the inflamed intestinal wall, or true obstruction may develop later from kinking or strangulation of a coil of intestine by bands or adhesions.

Clinical History.—(i.) The mild variety of the disease, known as a simple **catarrhal appendicitis,** to which is added merely a localized plastic peritonitis, usually commences somewhat suddenly, though the attack may be preceded by malaise and abdominal discomfort. The patient is seized with pain, at first referred to the umbilicus or to any part of the abdomen, but at the end of twenty-four to forty-eight hours it localizes itself in the right iliac fossa; it is often of a sharp, cutting character, but varies much in intensity and duration. Fever is usually present, and the patient complains of nausea and vomiting,

but the latter symptom does not last long. Constipation results, but in children it is sometimes replaced by diarrhœa, and that even blood-stained, so that the condition may even be mistaken for typhoid fever.

On examination the abdominal wall is found to be more rigid than usual, especially over the right iliac fossa, and the right leg is often drawn up to relax the muscles. Definite tenderness is noted on pressure, and the patient will often, but by no means constantly, refer it to a spot about 1½ inches from the anterior superior iliac spine along a line drawn to the umbilicus (McBurney's spot; Fig. 786). Sudden lifting of the hand after deep pressure often elicits sharp pain in appendicitis or other inflammatory lesions. In many cases, when the appendix is directed backwards, there is marked tenderness in the lumbar region, but if it points downwards into the pelvis, the pain and tenderness may not be evident except on rectal or vaginal examination, which should never be neglected. A definite swelling may sometimes be detected by palpation, usually above the outer half of Poupart's ligament, but varying in its position with the site of the appendix; it may be dull on percussion, but is frequently tympanitic, since it consists of coils of intestine and omentum matted together around the appendix.

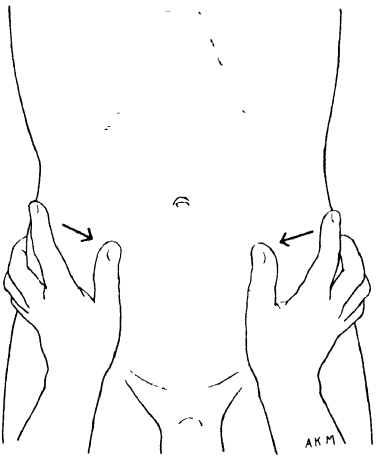

FIG 837.—SIGN WHICH MAY BE OF VALUE IN THE DIAGNOSIS OF A RETRO-CÆCAL APPENDIX

Cutaneous *hyperæsthesia* is manifested in more than half the cases of appendicitis. It is demonstrated either by stroking with a pin-point held at right angles to the surface, or by light pinching. In the former the two sides of the abdomen must be tested, as also the regions above and below the appendix area, which is usually contained within the triangle marked out by the middle line, Poupart's ligament, and a line drawn horizontally outwards from the umbilicus. In the pinch test corresponding portions of skin are gently pinched between the thumb and finger on both sides of the abdomen, and the patient estimates the difference in sensation. The area of hyperæsthesia varies with different viscera, but it is uncommon to find it present in the absence of peritoneal inflammation. The appendix area corresponds in the main with the distribution of the tenth dorsal segment. Hyperæsthesia is better marked in young adolescents than in older patients, and may be exaggerated in hysterical or neurotic people. As the inflammation subsides, the area of hyperæsthesia gradually diminishes; its total disappearance without improvement of the general

condition usually signifies grave mischief in the appendix, such as gangrene.

A useful sign in cases of retrocæcal appendicitis is elicited by placing the hands over the patient's pelvis (Fig. 837), each index finger being placed on the anterior superior iliac spine. The thumbs are gently moved over the iliac fossæ, and an area of tenderness may in this way be discovered. The right hand acts as a control on the left side.

An important aid to diagnosis in many mild cases, especially in the presence of adhesions, is the causation of pain in the region of the appendix by pressure over the *left* side of the abdomen directed towards the middle line. In not a few cases tenderness is also noted along the inner border of the ascending colon and upwards towards the navel; this is probably due to swelling of the mesenteric glands, which on operation are often found enlarged and congested.

(ii.) The more serious variety, resulting in a **localized abscess,** may commence in a similar way, but with more acute symptoms. There may be an initial rigor, and the temperature soon runs up, even to 104° F. General abdominal tenderness and distension follow; constipation is often absolute, and fæcal vomiting may occur. The muscles on the right side of the abdomen are held tense and rigid, and a well-marked fulness can sometimes be seen as well as felt in the iliac fossa; it is not necessarily limited to the right side, but may be found in the middle line of the abdomen or elsewhere. Under a careful régime this may disappear, and the symptoms gradually abate in their severity, the temperature and the pulse falling concurrently; but it is very common for suppuration to ensue, and this is indicated by the temperature persisting at its original high level or by the pulse-rate increasing in rapidity. The abscess develops round the appendix, and is primarily intraperitoneal. Occasionally it bursts into the bowel, and thereby relief is gained without the assistance of surgery; some authorities, indeed, maintain that this occurs in every case of the more severe type which resolves. In other instances it may point externally, either through the anterior abdominal wall, which becomes congested and œdematous as the pus approaches the surface, or through the loin. Not unfrequently it tracks up along the inner or outer side of the ascending colon, and then may get into relation with the under surface of the liver. In other patients, and especially when the tip of the appendix lies over the brim of the pelvis, the pus travels downwards and forms a collection in front of the rectum; the surgeon must never omit a rectal examination in appendicitis, where the temperature is of such a nature as to suggest the existence of an abscess, and yet no evidence of one can be found. Should it burst into the peritoneal cavity, all the phenomena of acute perforative peritonitis with grave toxæmia supervene, probably indicated by severe pain, sudden fall of temperature, rapid collapse, and failure of the circulation, leading rapidly to a fatal issue, preceded by increasing abdominal distension.

In not a few cases the patient's general symptoms improve after the first outbreak; the temperature may become normal, the pain decrease, and the vomiting cease. It is often difficult to be certain

whether this improvement is merely temporary or is the commencement of a true convalescence. Under the former circumstances, *i.e.* if it is merely an *interval of quiescence*, careful examination will probably reveal some disturbing factor; either the abdominal distension persists, or perhaps hiccough is present, or well-marked tenderness continues, perhaps only to be detected *per rectum*, or the pulse-rate may remain unduly high. After a few days the temperature begins to rise once more, the focal symptoms become more urgent, and a localized abscess forms.

A blood-count will often assist in making a diagnosis as to the presence of pus. Readers are referred back for a full consideration of *leucocytosis*; it will suffice here to state that a leucocyte count under 20,000 is merely indicative of an inflammatory attack well resisted; if suppuration is present, the leucocytes are usually over 20,000. In the early stages, however, a high leucocyte count means comparatively little; but a maintained leucocytosis is a valuable sign of suppuration.

When gangrene of the appendix, or part of it, has occurred, the early acute pain and cutaneous hyperæsthesia may disappear entirely, and the patient may feel fairly comfortable; the pulse is, however, usually rapid, and the general appearance bad; there may also be well-marked local rigidity.

(iii.) **Obstructive Appendicitis.**—Wilkie has recently drawn attention to a distinctive group of appendicitis caused by complete block of the lumen of the appendix due to kinking, band, or stercolith. The patient is seized with pain and tenderness in the right iliac fossa and vomiting; there may be no rise in the pulse-rate or temperature in the early stages, but examination reveals a local rigidity and tenderness which does not correspond with the constitutional symptoms.

Immediate surgical treatment is called for in these cases, as perforation is liable to occur at any moment, with a spreading generalized peritonitis.

(iv.) In the graver forms of **diffuse or generalized peritonitis,** the onset is usually sudden, the patient becoming collapsed with the severity of the pain; vomiting often accompanies the outbreak and occasionally a rigor. These symptoms sometimes pass over directly into those of generalized peritonitis, as described, death ensuing in two or three days; the temperature in such cases may be low, and the absence of reactive phenomena is indicated by a leucopenia. In the sero-purulent type the course is not quite so acute; pain, which at first is referred to the umbilicus, becomes localized to the right iliac fossa; the abdominal wall on that side is held rigid, and the rigidity gradually spreads across the abdomen to the left iliac region and upwards towards the liver; vomiting and absolute constipation are present, and the temperature is usually raised three or four degrees; the pulse varies from 100 to 120, and the amount of urine passed is diminished in quantity. If surgical treatment is not undertaken early, the typical phenomena of acute diffuse peritonitis are soon developed.

(v.) **Relapsing Appendicitis** is the term applied to a condition when an attack passes off, but not quite satisfactorily. There may be a slight persistent rise of temperature at night; or the appendix remains

palpable and tender; or some amount of appendicular pain, often of a colicky character, may be present. Many of these cases are due to unhealed ulceration of the mucous lining or to stenosis of the tube. If left alone, a more acute outbreak may supervene, or bacterial invasion of the vessels in the meso-appendix may follow, and serious consequences develop.

(vi.) **Recurrent Appendicitis** is characterized by repeated attacks of varying gravity in an individual who has been once the subject of the disease. They may occur only at prolonged intervals, or be so frequent as entirely to incapacitate the patient, and are usually associated with the presence of some abnormal adhesion or constriction. It is not uncommon for the appendix to become fixed to the sheath of the psoas muscle, and then any excessive movements of the limb may light up an attack. Where stenosis exists, secretions containing bacteria may be pent up, and from time to time the patient suffers from severe pain of a colicky nature, with or without fever, probably due to an attempt to get rid of the excess of mucus. Such attacks have been named **appendicular colic.** In a few cases the appendix becomes totally obliterated after a time and incorporated in a mass of adhesions, a natural cure being thus established; more frequently, the patient finally develops an acute attack which demands operation.

(vii.) **Appendicular Gastralgia** is the name applied to cases in which all the signs and symptoms of the disease are referred to the epigastrium, and closely mimic those of a gastric or duodenal ulcer. The patients are usually women, and a test-meal examination reveals a hypersecretion of gastric juice, in which the hydrochloric acid is usually increased. Laparotomy shows no lesion in the stomach or duodenum, but chronic appendicitis is present. That the previous symptoms were due to the appendix is proved by the relief to the symptoms and the changes in the gastric secretion after appendicectomy. Not unfrequently these patients are also the owners of a movable and tender right kidney.

On the other hand, it must not be overlooked that a gastric or duodenal ulcer is often accompanied by pain referred to the right iliac fossa, and many an appendix has been removed without benefit to the patient for these conditions. The history of the case must be most thoroughly investigated. Pain in gastric or duodenal lesions is more persistent than in appendicitis, and the intervals of freedom between attacks shorter. Vomiting, too, is less marked in appendicitis, and does not give the relief experienced in duodenal lesions. A barium enema is often of help in these conditions, as in diseased conditions of the appendix it may show kinking or failure to fill or, on screening, tenderness may be palpated over a partially filled appendix.

Diagnosis.—In a well-marked case the symptoms of appendicitis are so typical that the diagnosis can never be in doubt. The pain, tenderness, fever, vomiting, constipation, abdominal rigidity, and perhaps swelling, constitute a picture that is quite characteristic. The disease, however, often presents symptoms so varied, and manifestations so protean, that one is never surprised to meet with it in all sorts of diverse settings.

The early stage of *pneumonia* is sometimes associated with severe pain and tenderness in the iliac fossa, especially in children, and the resemblance to appendicitis is the more marked when the onset is sudden, and abdominal rigidity and vomiting are present; the abdominal symptoms are probably due to the existence of a diaphragmatic pleurisy. It will be noted that the pain is superficial, and that deep pressure is painless if made carefully. The leucocyte count, too, is usually higher than in appendicitis. A careful examination of the lungs should never be omitted in the case of children with suspected appendicitis. The diagnosis is sometimes helped by turning the patient over to the left side; in a case of appendicitis, griping abdominal pain is complained of; if the lesion is thoracic, the patient coughs. Cases which commence with diarrhœa may be mistaken for *enteric fever*, but the absence of the rash and a blood examination should guard the practitioner from error. *Acute pyelitis*, too, sometimes simulates appendicitis, but as a rule the temperature is higher, the abdominal muscles are relaxed, the tenderness is placed deeply in the loin, and pus and bacteria are present in the urine. Occasionally, however, the appendix is in close contact with the ureter as it crosses the brim of the pelvis, and then hæmaturia and even renal colic may be caused; in such cases the renal region is free from tenderness, and the pain is situated at a lower level.

Perforation of the duodenum, or even of the *stomach*, may lead to symptoms very similar to those of acute appendicitis, due to the inflammatory mischief tracking downwards. The initial pain will usually be referred to the upper part of the abdomen, and there may be evidence of free gas in the peritoneal cavity. If gas escapes from the abdomen on operation, and is free from odour, the probability is that the lesion is gastric or duodenal. *Mucous colitis* simulates chronic appendicitis, and the appendix is indeed often involved in the mischief. The distinction is made by the tenderness being located over the whole course of the colon, and by the passage of mucus in the stools. *Tubal* and *ovarian* diseases are recognized on pelvic examination; but the fact must not be overlooked that chronic appendicitis is often associated with inflammation of the right ovary, and then attacks of pain may occur at each menstrual period. A small ovarian dermoid with a twisted pedicle may resemble appendicitis very closely in the absence of a vaginal or rectal examination.

Cases of constipation may occasion difficulty, especially in young female adults. Vague abdominal pain and nausea are complained of, and the tongue is furred and halitosis present as in appendicitis. The temperature and pulse may also be slightly raised. There is never, however, definite tenderness or rigidity in the right iliac fossa, and rectal examination will often reveal masses of fæcal material. The diagnosis is, nevertheless, often difficult.

In children spasm of the psoas muscle may be causing flexion and rotatory deformity of the leg give the appearance of a lesion of the hip-joint.

Suppuration in the deep iliac glands may give difficulty in diagnosis, but the vomiting and abdominal pain of appendicitis are not present, and a focus of infection on the lower limb may usually be found.

A considerable swelling in the right iliac fossa may result from repeated attacks due to a matting of the parts together, and a diagnosis from tuberculous or malignant disease is sometimes difficult apart from operation. The history may be spread over a longer time, however, in appendicitis.

The **Prognosis** is never absolutely certain. The more one sees of the condition the more one learns to distrust it, and the surgeon is frequently seeing cases in which at operation he expects to remove a mildly acutely inflamed appendix, but in which perhaps he removes a gangrenous one in which free fluid is present in the abdomen. The absence of a raised temperature, with perhaps only a slight raising of the pulse, does not necessarily mean that the case is a mild one, because the condition of the patient may be such that he does not react to the infection that is present. A rapid pulse associated with a temperature that has been raised and is now falling is a sign of gross toxæmia and grave prognosis.

The existence of a swelling in the iliac fossa is not a bad sign, but is in fact the reverse, because it shows that the body is exciting a sufficient resistance to the infection to produce a localization.

Treatment.—All surgeons are not agreed on the correct treatment of **acute appendicitis,** but we think that on account of the difficulties in assessing what course the infection is going to take, and what actual pathological changes are occurring in the abdomen, immediate operation, with removal of the offending organ, should be carried out if the case is seen within about forty-eight to seventy-two hours after the onset of the illness. This course of treatment lends itself to the contention that many of these cases would recover without operative procedures, and that those cases which would require operation can, by conservative treatment during the initial hours of the infection, be differentiated and then operated on. This is true to a certain extent, but, emphasizing again the uncertainty as to what is actually happening in the patient's abdomen, by this treatment a certain proportion of cases will come to operation at a time when the appendix is gangrenous, or general peritonitis exists, cases which, if all were operated on at an early stage, would have stood a better chance of recovery. We admit that many appendices are by this method removed from patients who would have recovered from the acute attack without operation, but even these may be the subjects of future attacks, or appendicular dyspepsia, or perhaps obstruction by adhesions formed during the acute attack, and in all probability an intensive appendicectomy will be advised. Moreover, at this stage the operation is usually easy, as few adhesions have formed. In those cases where there is doubt as to the diagnosis, as may occur in constipation or tubal disease, provided the condition of the patient is satisfactory, conservative treatment akin to that advocated in the Oschner-Sherren treatment should be adopted. The patient is nursed in the Fowler position, and nothing is allowed by mouth, except sips of water, until the pulse and temperature settle. If much fæcal material is present in the rectum, an enema should be given. An hourly pulse chart is kept, and no morphia or its derivatives must under any circumstances be given. If the pain

is not relieved, if the pulse rate increases, if vomiting ensues, if there is diarrhœa, or if a lump forms in the right iliac fossa, this form of treatment must be immediately abandoned and operation performed.

In those cases that are seen after forty-eight to seventy-two hours from the onset of the illness, there is again discrepancy in the opinion of the line of treatment to be adopted. There are those who would operate on all cases irrespective of the time of onset, on the grounds that there is still the danger of infection progressing. We are, however, not in agreement with this, because by this time many adhesions are forming and the separation of these may liberate infection into the general peritoneal cavity, especially as at this time an appendicectomy may be extremely difficult. Naturally if the condition of the patient is deteriorating in any way, as evidenced by a rising pulse, vomiting, increasing tenderness or distension, operation must be performed at once, or when the patient when first seen has signs of general peritonitis or an appendix abscess, appropriate operative treatment must be carried out, but in other cases we believe that the patient should be treated in the manner indicated for those cases about which doubt exists, the appendix being subsequently removed some three months after this acute attack. This conservative treatment should be undertaken only in an institution, so that operation may be performed at once if necessary.

In those cases where general peritonitis is present, immediate operation, with removal of the appendix, if possible, and drainage, suprapubic and from the appendix bed, are indicated.

Drainage following operation for an acute appendix is another factor about which opinion is not dogmatic. We think that in those cases where there are many rather œdematous adhesions and in which the appendix, although not perforated, is swollen and perhaps turning gangrenous, and of course in those cases where perforation and general peritonitis exist, drainage is indicated, and cases so treated are less liable to the complications of residual abscess formation.

In children, in whom the condition is common above the age of two, the urgency of operation is greater than in adults, as complications are far more frequent. Often the signs and symptoms are less obvious, although the temperature is usually higher and vomiting more marked and tenderness over the appendix always present. Similarly in the aged operative treatment is more urgent than in the younger adult, because the patient does not react to the infection, and with a comparatively low pulse and perhaps subnormal temperature, and with very slight abdominal signs, a perforated gangrenous appendix may exist.

Relapsing and recurrent appendicitis and that associated with gastric symptoms should all be treated by appendicectomy.

Appendix Abscess.—Usually the opening of such an abscess is not a matter of immediate urgency, as it is obviously a condition which will occur several days after the onset of the attack, and the very fact that an abscess has formed is indicative that the body is getting on top of the infection. Where there is resonance over the mass, indicating that it is not yet involving the parietal peritoneum, if the signs of toxæmia are not excessive, it is best to wait for a day or so until

involvement of that layer has commenced, because then when the abscess is spread there is no danger of spreading the infection to the general peritoneal cavity. Where at operation the peritoneum lining the anterior abdominal wall is found not to be involved, this must be stripped up towards the abscess until an area where it is involved and adherent is reached, and through this drainage is instituted. If the appendix can be easily seen, it should be removed, but in other cases its removal should be left for three months.

In those cases where a pelvic abscess is present, either following an appendicectomy or as a later stage in an acute appendicitis, if it is involving the wall of the vagina or rectum in the mid-line—and this may be estimated by the fixity of the mass and the bogginess, œdema, and tenderness of the wall—it should be opened through one of these cavities. In other cases drainage should be established through an abdominal incision.

Operation.—The muscle-splitting plan suggested by McBurney may well be adopted when it is probable that but few adhesions are present. The incision is transverse or oblique, about 2 to 3 inches long, crossing McBurney's spot or a little below it, and parallel to the outer end of Poupart's ligament. The external oblique is incised in the course of its fibres, and the divided segments are held well aside. The fibres of the internal oblique and transversalis muscles are separated in the direction of their fibres.

The introduction of large deep retractors will expose a square or diamond-shaped area of subperitoneal fat or peritoneum about 1½ to 2 inches in diameter. Should this space be insufficient, the incision is carried inwards and the rectus sheath opened, the muscle is drawn inwards by a suitable retractor, and the sheath back and front freely incised. The peritoneum is divided transversely, and the margins grasped for identification purposes. The cæcum probably presents, and is gently withdrawn. The anterior longitudinal muscular band conducts to the appendix, which is freed from adhesions and removed. The meso-appendix is first divided after securing its vessels. A crushing clamp is applied to the base of the appendix, and when it is removed after a few seconds there is only a thin tube of the serous coat (Fig. 838), which is ligatured with catgut and divided with a carbolized knife just beyond the ligature. To prevent leakage of the contents before cutting off the appendix, its proximal end is seized with artery forceps. A purse-string suture is then introduced through the serous and muscular coats of the cæcum around the base of the appendix, which is gently invaginated into the cæcum by a pair of forceps, and the suture tied; by this means the stump of the appendix is completely buried (Figs. 838 and 839). The site of detachment of the meso-appendix, or of the position from which the appendix itself has been detached, may require a few sutures in order to ensure a complete peritoneal coating, and thus minimize the risk of subsequent adhesions. In females it is always well to explore the right ovary and tube before closing the abdominal wound.

If it seems probable that many adhesions are present—that is, when the condition has been present more than a few hours and the signs

and symptoms of the disease are well marked—the muscle-splitting operation should be avoided, and the abdomen should be opened by a good-sized right paramedian incision. The abdomen is quickly examined and the diagnosis established by feeling the inflamed appendix itself or an adherent mass. Adhesions are gently divided, keeping to the outside of the appendix, as then damage to its mesocolon, with consequent severe hæmorrhage, is avoided. It is well in these acute cases to pack off the rest of the abdominal cavity with towels soaked in hot saline. Sometimes the difficulty of mobilizing the appendix is such that a retrograde appendicectomy has to be performed—that is, the root is divided and the stump buried, and then the free appendix is removed. If an abscess is opened, great care must be taken to

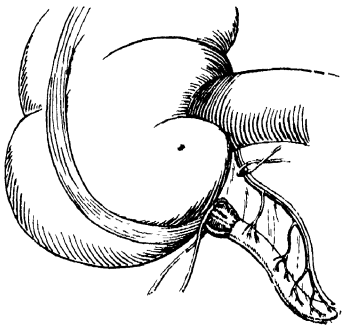

FIG 838.—REMOVAL OF THE APPENDIX
A ligature is placed on the meso-appendix, and the base of the appendix crushed and tied

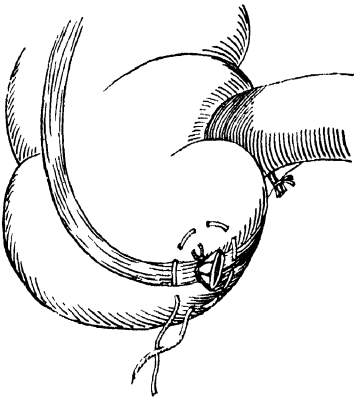

FIG 839.—SERO-MUSCULAR PURSE-STRING SUTURE INSERTED TO INVAGINATE THE STUMP.

see that general contamination does not occur. It is probably best in these cases to pack the cavity in such a way that the abscess is drained and the general peritoneal cavity protected.

In these very acute cases care must be taken not to burst the organ in manipulating it or when it is clamped across its base. Moreover, in tying ligatures on the meso-appendix and its vessels they very easily slip off or cut through on account of the œdema present. Care must be taken to try to see that this does not happen, or if it does to clamp and ligature immediately that part of the meso-appendix again, as otherwise post-operative hæmorrhage may occur. Where the patient has had more than one rigor previous to the operation, it is advisable to tie the ileo-colic vein as it is probable that such a patient is in danger of pylephlebitis.

Post-Operative Treatment.—In those cases where peritonitis is present, or where the appendix and its bed have been very acutely inflamed, the patient should be given no fluid by mouth for twenty-four hours, the fluid being introduced intravenously or *per rectum* in

the form of glucose and saline. The patient is nursed in Fowler's position. These severe cases often benefit by the administration of *B. welchii* antitoxin, some 20 c.c. being given intramuscularly for two or three days after operation.

In simple cases the patient may eat and drink what he fancies from the time of his recovery from the anæsthetic. He should be got out of bed as soon after the operation as possible. In an interim appendicectomy only a day or two in bed is all that is required, the patient gaining in morale and muscular fitness by this procedure. When the case has been very acute, the date of getting up must be controlled by the temperature and pulse charts, and by the presence, or otherwise, of discharge.

Complications such as paralytic ileus, subphrenic abscess, pelvic abscess, first recognized by the passage of mucus *per rectum* associated with diarrhœa, and pylephlebitis may occur. The only hope of saving the patient's life in this complication, which is ushered in with rigors, swinging temperature, raised pulse, toxæmia and pain over the liver, and which is caused by septic emboli from the appendix bed lodging in the liver, is an immediate second operation with ligature of the superior mesenteric vein or its branches above the site of the clot.

Another complication that may occur following the removal of acutely inflamed appendices is obstructive vomiting coming on about a week after the operation, and caused by the flakes of lymph laid down as a protective phenomenon producing adherence between neighbouring loops of bowel with resulting kinking. A second operation is necessary to relieve this kink.

Late complications are obstruction, caused by bands or adhesions which may require operative interference, the formation of a chronic sinus, or even a fæcal fistula, where an abscess has not been dealt with efficiently, and in those cases where suppuration of the wound has occurred associated with drainage of an abscess.

A *ventral hernia* sometimes follows from the yielding of the cicatrix in the abdominal wall. Both omentum and bowel, perhaps matted together and adherent to the cicatrix, are found in the protrusion. In some cases it may suffice to protect and restrain it with a truss, but in others operation is required; adhesions must be divided or broken down, and often the opportunity can be taken for removing the appendix, if this has not already been accomplished. The margins of the divided muscles are then sought for, and united by a row of buried sutures in the ordinary way, or overlapped as described in discussing the subject of ventral hernia.

Intussusception of the Appendix.—This is an uncommon condition, and fewer than 100 cases are recorded in the literature. The appendix is herniated into the cæcum (Fig. 840), and produces the clinical signs of acute appendicitis. The majority of cases occur in children. It seems quite probable that the same factors are playing their part in the causation of intussusception of the appendix as are responsible for the entero-colic type of intussusception in infants. The constant feature in these cases is the presence of enlarged glands in the root of the mesentery and in the ileo-cæcal angle (see Fig. 921, p. 1388).

Also there is a preponderance of lymphoid tissue in the terminal ileum and in the appendix itself. This increase of lymphoid tissue acts as a foreign body and causes increased and irregular peristalsis of the bowel and appendix, which, at times, culminates in an intussusception. In other cases a stercolith may be an exciting cause of the intussusception, while in others the presence of worms may play a part.

Treatment consists in reducing the intussusception if possible, and removing the appendix, in some cases this is impossible, and a portion of the cæcum, into which the appendix has been invaginated, has to be excised.

Tuberculosis of the Appendix is found not uncommonly in patients who have died of other manifestations of the disease, especially phthisis (30 per cent. Keen), it is not often seen as an independent condition

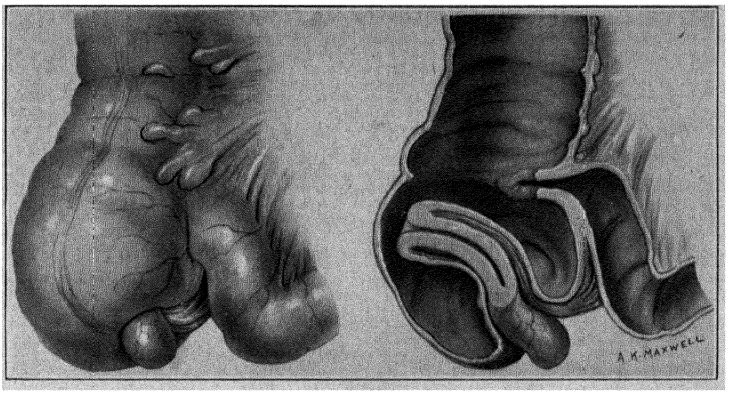

FIG 840.—INTUSSUSCEPTION OF THE APPENDIX, SHOWING EXTERNAL ASPECT AND ON SECTION

of twenty and forty, who are the subjects of urino-genital tuberculous disease. The affection may develop as an ulceration of the mucous membrane, which slowly spreads from the tip and destroys the walls of the organ, giving rise finally to a large pericæcal abscess, which opens into the bowel or discharges externally. In other cases the condition is merely an element in the evolution of the hyperplastic tuberculous growth of the cæcum described elsewhere. Occasionally the appendix is involved in a tuberculous peritonitis, and then the trouble may either have started in the appendix, or have reached it secondarily from the serous coat. The symptoms of these conditions are in no way peculiar, and correspond to those of a chronic appendicitis.

Actinomycosis attacks the appendix, together with the cæcum, more frequently than any other abdominal organ. The disease usually originates from the ingestion of infected material, and the result is the production of a hard, slowly-enlarging mass, infiltrating the tissues in

the right iliac fossa. Sooner or later the skin gives way, and then the discharge of glairy pus and of the yellow sulphur-like granules, together with the musty smell, is pathognomonic. Pyococcal infection of the sinuses is only too likely to follow, sometimes originating from within the bowel, and the case then becomes complicated by a suppurating element, which has an important bearing on the result. Secondary foci are common, especially in the liver. **Treatment** consists in excision of the appendix, and even of the cæcum, if such be practicable, and in the exhibition of large doses of iodide of potassium with curettage and



FIG 841.—LOW-POWER DRAWING OF A SECTION THROUGH THE TIP OF AN APPENDIX, SHOWING HOW A CARCINOID TUMOUR FILLS THE LUMEN

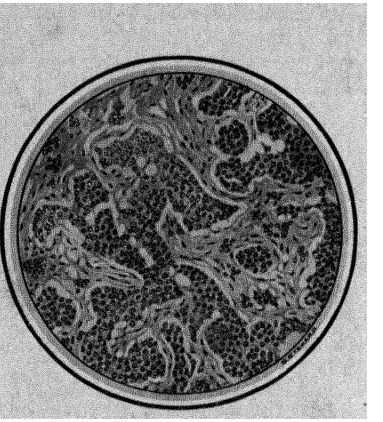

FIG 842.—MICROSCOPICAL DRAWING OF A CARCINOID OF THE APPENDIX, SHOWING THE SMALL CELLS ARRANGED IN MASSES

drainage; but even when the organisms have been destroyed by the drug the discharge of pus may continue, and the affection may prove fatal.

Tumours of the Appendix are uncommon, but more would be discovered if every appendix that was removed was submitted to microscopical examination. Carcinoma is rare, and behaves like a carcinoma of the bowel, forming metastases which cause death of the patient. Carcinoid tumours are not uncommonly found in the appendix, and are usually situated towards the free extremity of the organ, quite often forming a rounded bulbous tip to the appendix. In some cases, however, they are to be found near the base of the appendix, when they have a tendency to cause diverticula of the appendix, and, at times, even acute appendicular obstruction. These carcinoid growths present an alveolar structure which is quite like a cancer (Fig. 841). They may be so minute that they cannot be seen by the naked eye, and are only discovered accidentally on microscopical examination. The cells of these carcinoid tumours are somewhat small, arranged in

irregular masses in the submucous coat, and extending in places into the other coats of the appendix (Fig. 842). There are, in the cells, minute granules which have the power of reducing silver salts, and hence they are called 'argentaffine' cells. It is because of this that some pathologists have called such tumours of the appendix 'argentaffine tumours.' It is most uncommon for any metastases to occur, and carcinoid tumours may be looked upon as benign growths.

Affections of the Liver.

Displacements of the Liver are obviously not likely to be common since the organ is well supported both by ligaments and attachments to deep structures, and by the intra-abdominal pressure Should, however, the abdominal parietes be relaxed and the intra-abdominal pressure lessened, it is possible for the liver to sink, and thus **hepatoptosis** becomes an element in the syndrome known as Glénard's disease. The displaced liver is rotated forwards, so that its upper wall presents anteriorly, with obvious resulting physical signs. An enlarged liver may manifest somewhat similar phenomena, but dulness is then found over the normal hepatic area; in hepatoptosis the normal site is resonant. Some amount of dragging pain and discomfort may be complained of, but this is not generally great enough to demand treatment other than the support of a belt, together with such measures as shall assist in the restoration of the abdominal wall to a state of normal tonicity.

Riedel's lobe is the name applied to a linguiform enlargement of the right lobe, which projects downwards into the loin, and is likely to be mistaken for a floating kidney. It is frequently associated with an enlarged gall-bladder, probably containing stones, which is covered in by the projection. The lobe may have a broad base of attachment to the liver, or may be almost severed from it, and then its mobility is considerable, and may be independent of the liver. A little care in examination should enable the surgeon to differentiate between this condition and a floating kidney; if the patient be laid over on the left side, the examining hand can be insinuated between the lobe and the kidney. Treatment is not required, except for the condition of the gall-bladder.

Rupture of the Liver is produced by injuries to the abdominal walls, such as blows, kicks, or crushes, or it may be torn by the broken end of a rib. Penetrating injuries also occur, as from sword or dagger thrusts, and the organ may be involved in a gunshot wound. The resulting lesion varies considerably; the gland may be merely torn or contused from a non-penetrating blow, or freely incised by a sharp-cutting implement, in which case some of the larger venous trunks are likely to be divided; a bullet sometimes produces almost total disorganization. The amount of injury depends, to some extent, on the condition of the organ; if it is firm and sclerosed, it may receive little damage from a blow which would otherwise do it considerable harm, whilst if it is enlarged and fatty, it is readily torn.

The chief **Symptoms** are shock, which is often not very excessive, pain and tenderness in the right hypochondrium, and the evidences of loss of blood. The last is, perhaps, the most important, and upon its severity depends to a large extent the result. Should the capsule remain intact, there is considerable intraglandular ecchymosis and laceration, but no free blood escapes into the peritoneal cavity; such a lesion is not unlikely to be followed by an abscess of the liver. When the capsule is torn, intraperitoneal hæmorrhage and escape of bile are sure to ensue; if slight, the patient, though suffering from all the phenomena characteristic of loss of blood, may recover, the blood being absorbed, and the wound in the liver cicatrizing. This process is usually attended by a certain amount of jaundice and some vomiting, whilst the urine is also tinged with bile-pigment. Well-marked pyrexia may follow the initial shock, and the abdominal wall is held rigid. The blood collects at first in the upper part of the abdomen, but gradually extends downwards; not uncommonly there is some associated injury of the gut wall, through which intestinal bacteria find their way, giving rise to a localized or general peritonitis. In the more severe lesions, where perhaps the left lobe is entirely torn off or a portion hopelessly contused, death from hæmorrhage is almost certain to ensue in a very short time.

The **Diagnosis** of hepatic rupture turns mainly on the history of the accident, the situation of the blow, and the resulting symptoms. Evidences of intraperitoneal bleeding, associated with pain in the right side, are extremely suggestive. It must not, however, be forgotten that much shock, considerable local pain, and tenderness may be caused by an injury, and yet the liver may have sustained no serious damage.

The **Treatment** in the more simple cases consists merely in careful expectancy, the surgeon holding himself in readiness to interfere should any untoward symptoms supervene. The patient is kept quietly in bed; ice may, if necessary, be applied to the side, the diet is limited to fluids, and the lower bowel emptied by enema. In the more serious cases, where the diagnosis of ruptured liver is tolerably certain, an exploratory laparotomy should be undertaken, and an attempt made to deal with the wound (Figs. 843-846). Quite a number of wounds occur on the under surface of the liver, and it is most important that this surface should be explored carefully. The surgeon's left hand is inserted into the abdomen and the liver grasped and gently rotated upwards (Fig. 843) until the inferior surface is completely exposed (Fig. 844). A right paramedian incision is used (Fig. 845) and the rent in the liver exposed. If the laceration is on the inferior surface the liver must be rotated with the left hand so as to expose it (Fig. 846). Outlying ragged portions of the gland may be totally removed, preferably by the diathermic cautery, though one often has to depend upon plugging the wound with gauze in order to effect hæmostasis. Clean linear cuts may be sutured with silk, but there is considerable difficulty in preventing the stitches from tearing out of the friable hepatic tissue; it is wise to insert all the stitches first, taking up a wide margin of the gland substance before

attempting to tie any. The wound is then carefully closed by the fingers, and the sutures slowly and gently tightened. A blood transfusion is given while the operation is in progress, and this alone has considerably reduced the mortality in these cases. Very shallow wounds which it is impossible to stitch or plug satisfactorily may be

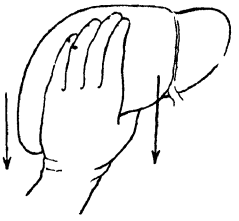

FIG 843.

The left hand is inserted and the interior surface of the liver rotated upwards.

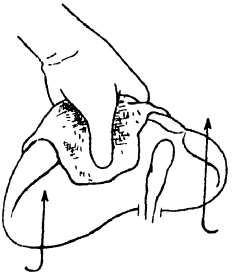

FIG. 844.

A piece of gauze held in the hand will often facilitate the exposure of the inferior surface

seared with the cautery so as to stop bleeding, and then a gauze drain is placed over them, and brought out of the external wound.

Abscess of the Liver is due to a variety of causes.

1. *Multiple Abscesses* in the liver may be blood-borne, and the infective emboli may be carried to the organ either by the hepatic

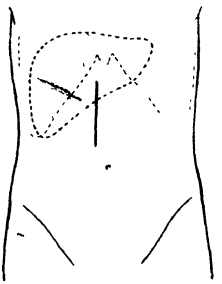

FIG 845 — DRAWING SHOWING RELATION OF PARAMEDIAN INCISION TO RENT IN LIVER

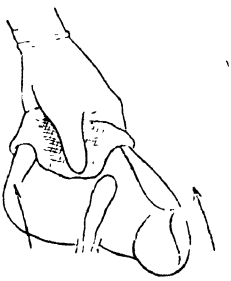

FIG 846 — COMPLETE EXPOSURE OF INFERIOR SURFACE OF LIVER

artery or the portal vein. Cases of the former are rare and are associated with a generalized septicæmia.

Infected emboli may spread up the portal vein in cases where thrombosis accompanies such conditions as acute appendicitis, thrombosed hæmorrhoids, typhoid fever, or infection at the umbilicus in children. The abscess is acute, suppurative pylephlebitis, varying in size, and scattered throughout the liver substance. Usually the infection is a mixed one of staphylococcus and *B. coli*.

Signs and Symptoms.—Following an operation, or recovering from some septic condition, the patient, instead of getting better, starts to go down-hill. The temperature and pulse rise again, there are rigors and night sweats, and the patient becomes toxic and rapidly wastes. Vomiting may be complained of. On examination the patient is not usually jaundiced, but of a very muddy colour. The abdomen is often distended, and a painful liver edge is palpable. A leucocyte count will confirm the fact that a suppurative process is present.

Diagnosis is often difficult, and the condition must be distinguished from subphrenic abscess, in which condition the diaphragm will be raised and inactive.

2. *Suppurative Cholangitis* is another cause of multiple abscess of the liver. It consists of an inflammatory affection of the biliary duct and passages, and results from the spread of organisms from the intestine, or occasionally from the gall-bladder after an operation. The biliary ducts in the liver become enormously dilated, and filled with a mixture of bile and pus which closely resembles yellow ochre. It is accompanied by pain over the gland and the general phenomena of pyrexia, but rigors are not present. The patient is not usually jaundiced, but bile may be found in the urine. Treatment is of little avail, but if a diagnosis can be made, and the gall-bladder has not been already incised, it may relieve tension to open and drain it.

3. Hydatid cysts may suppurate, and require treatment as for an abscess of the liver.

4. **Solitary Abscess of the Liver** usually occurs in men who have travelled or lived in the tropics, and is very generally a sequela of amœbic dysentery, it is likely that unwise indulgence in alcohol predisposes to its development. The bacillary forms of dysentery may lead to the development of multiple or pyæmic abscesses of the liver, but not often to the large solitary abscess. It is most frequently situated in the right lobe towards the back, but of course any part of the organ may be affected. Though generally single, the cavity is often loculated, indicating that several original foci of suppuration have united together, if multiple, they are most frequently near the surface. These abscesses contain material which is reddish-brown in colour and has been compared to anchovy sauce or chocolate; it consists mainly of broken-down necrotic liver substance and altered blood, with but little true pus. The walls of the cavity are shaggy and necrotic in the early stages, subsequently becoming firm and fibrous.

The causal organism is the *Entamœba histolytica*. This is an actively moving amœba which has the power of penetrating the submucous coat of the intestine and causing ragged and undermined ulcers, in which, as in the liver abscess, there is but little inflammation. The amœba possesses active phagocytic powers, and is frequently found to contain red blood-corpuscles; this is one of the points that distinguishes it from the common and non-pathogenic *E. coli*. In the liver it occurs mainly in the walls of the abscess, and may not be found in the material which escapes when it is first opened; in a day or two, however, it may

make its appearance. These abscesses usually contain no bacteria, cultures inoculated therefrom remaining sterile.

The **Symptoms** are in some instances extremely slight, the patient perhaps dying of peritonitis due to its rupture without its presence having been ever suspected, or retaining the pus encapsuled for years. The individual usually complains of a sense of pain and fulness in the right hypochondrium, and in the more acute cases this may be accompanied by severe pain and localized tenderness over the whole hepatic region, the pain being also referred to the right shoulder. When the pus encroaches on the upper surface of the liver, a cough on taking a deep breath is rather characteristic. A certain amount of febrile disturbance occurs, the degree of which depends on the rapidity of formation of the abscess; in the more acute forms the temperature is high and rigors may be present; in the more chronic variety there is some fever in the evening, and night sweats occur. The pyrexial phenomena are associated with loss of appetite, rapid and well-marked emaciation, and perhaps a slight amount of icterus. On physical examination a more or less evident enlargement of the liver will be detected; but there is neither fluctuation nor a sense of elastic tension unless the abscess is very superficial. The dulness often extends up towards the thorax rather than downwards, though the contrary obtains when the abscess is situated not far from the free margin of the liver.

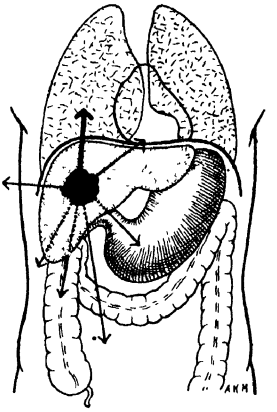

FIG 847.—DIAGRAM SHOWING THE VARIOUS WAYS A LIVER ABSCESS MAY SPREAD

Left to itself, the abscess may become adherent to the anterior abdominal wall and point in the epigastrium, its onward passage being indicated by congestion and œdema of the parietes, or it may open into the peritoneal cavity, or into one of the hollow viscera, such as the colon or duodenum; or, again, it may travel upwards, burrowing through the diaphragm, and either bursting into the lung, its contents being expectorated, or into the pleural cavity, leading to an empyema (Fig. 847). Occasionally it remains passive as a chronic encysted abscess, and then the walls become very thick.

In many cases the **diagnosis** of suppuration is by no means easy, and mistakes are often made, the condition being looked on as one of simple hepatitis. A history of dysentery is of great importance, and assistance may often be afforded by an examination of the stools, as, although the amœbæ themselves are only present in the acute stage, the resting or encysted forms may persist for long periods. These are spherical, refractile bodies containing four nuclei, and must be carefully distinguished from the cysts of the *E. coli*, which are usually oval, and may contain up to eight nuclei. A blood-count may also help, and especially a differential count; but sometimes it is of little value, since

a leucocyte count of 20,000 or more can occur without suppuration. A marked increase in the polymorphonuclear leucocytes, together with a diminution in the small lymphocytes, is always suggestive of the presence of pus, due to pyogenic organisms; in a pure amœbic abscess, leucocytosis occurs with a comparatively small increase of polymorphs. A doubtful diagnosis can sometimes be confirmed by the aspirator or exploring syringe, but this should not be utilized *unless one is fully prepared for immediate operation in the case of pus being found.* Manson directs that the aspirator needle should be introduced in the following situations: (1) In the right axillary line through the seventh or eighth costal interspace; (2) just below the ribs in the right nipple line; (3) immediately below the lung in the line drawn downwards from the angle of the right scapula. Some recent work suggests that the injection of a dye (thorotrast) may be of use in the X-ray diagnosis of these cases, but there are considerable risks attendant on its use.

Treatment.—It is important to realize the prophylactic value of emetine in the early treatment of amœbic dysentery, as it is found that the patients who have been given this drug during the acute stage of the dysentery show only a comparatively small proportion of liver abscesses. In the acute stage of amœbic hepatitis, moreover, injections of emetine (0·06 grm. daily) will often succeed in determining resolution without suppuration. At a later date it is also probable that treatment by emetine will turn an amœba-containing abscess into a sterile cavity, and thereby permit of the absorption or encapsulation of the pus; cases of this type are on record. In the majority of patients, however, operation is necessary, but, if time permits, a prophylactic course of emetine is desirable.

Aspiration, repeated once or twice, has been frequently employed, and with some success, when preceded by a course of emetine; but apart from this, it is possible to determine an attack of septic peritonitis or pleurisy from infection through the needle puncture. It has also been suggested by Sir Leonard Rogers that inasmuch as the entamœba is easily killed by comparatively weak solutions of quinine, all that is needed in amœbic abscesses is to aspirate the cavity and then introduce 30 to 40 grains of bi-hydrochlorate of quinine, and employ no drainage. The results hitherto have been encouraging. A rapid microscopic examination of the pus should be made at the time, and if organisms other than the amœba are found, the ordinary operation can be carried out at once.

The practice usually followed is in accordance with the surgical law of treating suppuration, *viz.* by *incision* and *drainage.* If pointing in front and adherent to the parietes, there is no difficulty or danger in making an incision over the most prominent spot and laying the cavity open; it is then well flushed out and a drainage-tube inserted. If on dividing the abdominal parietes it is found that the liver is not yet adherent, precautions must be taken similar to those employed in dealing with the intraperitoneal abscess connected with appendicitis. The general serous cavity must be carefully walled off by sterilized gauze before letting out the pus, which is of course done slowly, and

the assistant must keep the parietes in close contact with the hepatic tissue. It may be possible to insert a few stitches through the liver substance, securing it thus to the parietal peritoneum; otherwise one must trust to careful packing. After opening the abscess, it is usually advisable to wash it out, and this may with advantage be repeated subsequently. A large drainage-tube is inserted, and packed around with gauze to prevent purulent extravasation.

When the abscess is in its most common situation, *viz.* the back of the right lobe, it is often most satisfactory to open it from the side; a similar proceeding is sometimes needed when an abscess has been opened from the front, and does not drain properly. An incision is made a little behind the mid-axillary line through the ninth or tenth intercostal space, and a portion of one of the adjacent ribs removed. The pleural cavity is opened, and the costal pleura stitched carefully to that portion which covers the diaphragm; it will be found that this structure lies nearly vertical in this position, and but little difficulty is experienced in shutting off the general pleural cavity. The diaphragm is then divided, and not unfrequently the peritoneal cavity is opened it must be carefully protected by gauze packing, and then the liver is incised; less commonly adhesions may have already formed, or a bare area of the liver may be found, through which the pus can be withdrawn and the abscess opened. The progress of these cases is often most satisfactory, if effective drainage is maintained. Occasionally, without any obvious reason, healing is delayed and suppuration persists; this is sometimes due to a re-absorption of amœbæ from the bowel, and it may be desirable under such conditions to administer a suitable course of emetine.

Hydatid Cysts occur in the liver more frequently than in any other part of the body. For general details as to the life-history of the *Tænia echinococcus* and the structure of hydatid cysts, see p. 231. They produce a localized painless enlargement of the liver, the cysts varying in size from a small marble to a child's head; the outline is well defined if superficial, but not so if placed deeply; the cavity is usually filled with fluid and daughter-cysts. Fluctuation may be distinguished, and a hydatid fremitus or thrill (arising from the concussion of the contained daughter-cysts) may, it is said, be elicited on palpation. The diagnosis is easily made if the cyst projects from the lower border, but when deeply embedded in the organ it may be exceedingly difficult, and the tumour can be distinguished with certainty from carcinoma or syphilis only by the use of the Cason's test, in which a local reaction follows the injection of some hydatid fluid under the skin, or the complement fixation test, using hydatid fluid obtained from sheep as antigen. The character of the fluid withdrawn from a hydatid cyst is also conclusive, as it is of low specific gravity, slightly opalescent, with no albumen, and a trace of salt; the presence of scolices or hooklets (Fig. 94, p. 231) is the pathognomonic feature. This test, however, is dangerous, and should not be carried out, as infection with the hydatid is liable to occur along the track of the aspirating needle.

Terminations.—The cyst may remain latent and innocuous, or may actually dry up and form a mass somewhat like wet mortar, owing

to the death of the organism; or it may burst and be evacuated in different directions, with or without suppuration. Thus, it may open externally through the abdominal parietes, or into the peritoneal cavity, causing fatal shock and in many cases peritonitis; or into the stomach or intestines, spontaneous cure usually resulting; or it may penetrate the diaphragm, and the contents be expectorated, or set free in the pleural cavity, causing a rapidly fatal pleurisy. It has been known to open into the pericardium, or even into the hepatic veins, the contents then being impacted in the right auricle; in both cases immediate death resulted.

Treatment.—The best plan of dealing with a hydatid cyst is to lay it open either through the anterior abdominal wall, or through the costal parietes and diaphragm, to empty it of its contents, and if possible to enucleate the lining wall or ectocyst, which is often but loosely connected to the granular endocyst. This is usually accomplished at one sitting. Similar precautions as to protecting the peritoneum are taken as for an abscess. When the surface of the liver is exposed, it is advisable to puncture the cyst first with a trocar and cannula, so as to reduce the tension within it, and then inject into it some 5 to 10 c.c. of commercial formalin, the quantity varying with the size of the cyst, this killing the contents in five minutes where granddaughter-cysts are not present. It is then incised freely and the loose daughter-cysts removed. This is facilitated by flushing out the cavity with sterilized salt solution. The endocyst is removed either by enucleation with the fingers or a blunt dissector, or it may be possible to detach it by irrigation, the nozzle of the irrigator being inserted beneath it. If enucleation is completely successful, the lesion in the liver may be closed, and the abdominal wound sutured in the ordinary way without drainage (Hamilton Russell), dependence being placed on the aseptic organization of the blood-clot which fills the cavity in the liver. If for any reason this seems undesirable, a gauze packing is introduced into the cavity, and healing by granulation is allowed to proceed. If, however, part of the lining wall is left, a drainage-tube must also be introduced, and the cavity subsequently irrigated at each dressing.

No attempt should be made to remove the fibrous ectocyst, as it is closely connected with the liver substance, and grave hæmorrhage might follow any interference with it.

A suppurating hydatid cyst is dealt with according to the same rules of treatment as hold good for abscess of the liver.

Tumours of the Liver are rarely **primary**. *Adenomata* develop as sharply defined masses usually in the right lobe, and only cause symptoms by their size and weight. In some cases suitably situated, removal is quite possible. *Angiomata* may be similarly localized, but their removal is rarely feasible on account of their size, and in that they are likely to be multiple. *Carcinoma* may be primary and removal practicable, but one can never be certain that secondary nodules impossible to recognize are not already in existence. Extension of malignant disease of the gall-bladder to the liver may tempt the surgeon to undertake removal, but it is almost certain that when once the disease

has spread outside the gall-bladder it has developed in directions other than that which is visible, and removal will be useless. **Secondary** tumours are common, and follow a carcinoma of the intestinal canal, especially of the stomach or large intestine (Fig. 848), or perhaps may be a sequel of cancer of the ovary, uterus, or breast. The liver is also involved secondarily in melanotic disease of the skin or retina. In all these cases the organ becomes enlarged and its surface irregular, due to the projection of nodular masses of the growth, in cancer they are frequently more or less umbilicated. Pain is not generally a prominent symptom, but ascites and jaundice develop in malignant cases from pressure on the portal vein and biliary ducts in the portal fissure, and œdema of the legs may be caused by compression of the inferior vena cava.

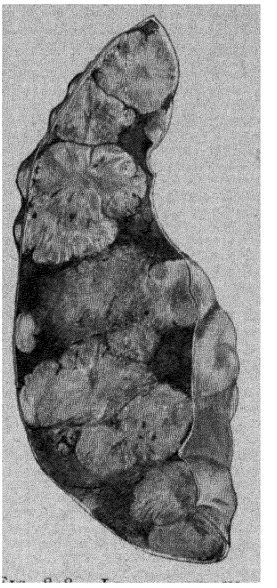

FIG 848.—LIVER CONTAINING MANY SECONDARY DEPOSITS

The primary growth was in the stomach

Gummata are developed in inherited and acquired syphilis, and are of sufficient size to need careful diagnosis from the more serious growths which develop in the liver. They are single or multiple, and occur in the form of rounded, yellowish, non-vascular masses, which caseate, and are surrounded by much fibrous tissue. Absorption is followed by considerable cicatrization, which leads to deformity. The diagnosis from secondary carcinoma is not always easy. The history of the patient must be carefully considered, and if any doubt arise, the Wassermann reaction is tested. Carcinomatous growths have hard umbilicated surfaces (Fig. 848), if they can be felt, enlarge rapidly with marked cachexia, and early produce jaundice and ascites. Gummata are slow in their progress, do not generally affect the structures in the portal fissure, and may be associated with an enlarged spleen from lardaceous or gummatous disease. A course of antisyphilitic medicine will necessarily influence the case very decidedly.

Actinomycosis of the liver is usually secondary to an affection of the alimentary canal, particularly the appendix or transverse colon, or may be due to a direct spread of the infection. The liver is enlarged, and may be covered with adhesions. On section the affected area presents a trabeculated honeycombed appearance, which has been compared to a sponge soaked in pus There is much fibrosis around, and the trabeculæ are markedly fibrous. The pus contains the characteristic granules of the fungus. The clinical history is that of an hepatic abscess, and the prognosis is bad. Treatment is as for the disease elsewhere.

Affections of the Gall-Bladder and Biliary Passages.

The **Gall-Bladder** (Fig. 849) is a pear-shaped sac lying under cover of the liver and projecting into the peritoneal cavity. Its average length is about 3 to 4 inches, and it is normally capable of holding about an ounce of fluid. An *enlarged* gall-bladder projects downwards and towards the umbilicus, constituting a rounded swelling which moves with respiration, and is almost always in close relation with the anterior abdominal wall; it is freely mobile from side to side, and has attained such dimensions that it has been operated on in mistake for an ovarian cyst. It is attached to the liver by reflections of the peritoneum, which vary somewhat in their insertion, as a rule

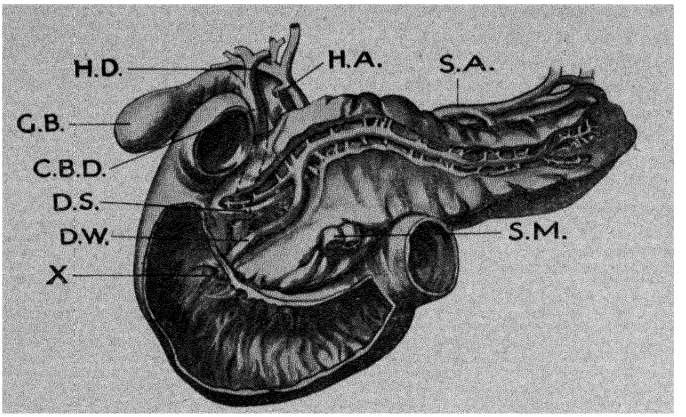

FIG 849.—DIAGRAM OF THE BILIARY PASSAGES AND THEIR RELATION TO THE DUODENUM, WHICH HAS BEEN LAID OPEN, AND PANCREAS

GB, Gall-bladder, HA, hepatic artery, HD, hepatic duct; CBD, common bile-duct, DS, duct of Santorini; DW, duct of Wirsung; X, opening of common bile-duct and duct of Wirsung in the duodenum; SA, splenic artery; SM, superior mesenteric vessels

about a fifth of the circumference of the gall-bladder is in contact with the liver. The attachment is loose, and when once the right layer has been reached it is easy to strip the gall-bladder from the liver. The cystic artery reaches it at some distance from the fundus.

In a few cases the gall-bladder has a complete peritoneal investment, swinging loose from the liver on a mesentery, and in two cases the writer has seen serious colic develop apparently from this lax attachment, much in the same way as a long appendix can cause appendicular colic. Removal of the gall-bladder demonstrated the absence of stones and cured the condition. Such a condition may be termed *Gall-Bladder Colic*, to distinguish it from the biliary colic produced by gall-stones. On another occasion *torsion* of the gall-bladder was observed. The patient came into hospital for a supposed acute cholecystitis, but on operation the gall-bladder was found to be twisted around on its own

hepatic attachment and to be practically gangrenous; the symptoms had only lasted for twenty-four hours.

The **Cystic Duct** is about 2 inches in length, or rather less, and is arranged more or less in a spiral fashion by the attachment of the peritoneum. It will ordinarily permit of the introduction of a No. 5 catheter, but probably in a healthy state the mucous membrane is in such folds that a probe cannot be passed along it. The **Hepatic Duct** (HD) is 2 inches in length, and is formed by the junction of the right and left ducts which issue from the liver at either end of the transverse fissure and unite together at a very obtuse angle. The duct passes down with the hepatic artery, and a little above the upper border of the first piece of the duodenum is joined at a very acute angle by the cystic duct. The **Common Bile-Duct** (CBD) is about 3 inches in length, and takes a No. 7 catheter; one inch or more of it is to be found above the duodenal border, and then it dips behind the viscus; and after lying between the inner border of the gut and the head of the pancreas, it perforates the bowel obliquely (X), sometimes being distended just before its termination to constitute the ampulla of Vater, and into this the duct or ducts of the pancreas also open.

There is no satisfactory clinical or laboratory test of the efficiency of the liver, on account of the fact that such a large proportion of the organ can be diseased without producing any recognizable effect. The levulose and galactose tolerance tests seek to measure the efficiency of the liver by administering these sugars and plotting a blood-sugar curve, and noting the presence of any carbohydrate in the urine. Abnormally high curves or the presence of sugar in the urine, when 100 grms. of the former or 40 of the latter are given, indicate failure of the liver to store the carbohydrate, and hence failure of at least part of its function.

The power of the liver to break down amino-acids into urea is estimated by the urinary nitrogen coefficient, which expresses as a percentage the ratio of the urea nitrogen to the total nitrogen in the urine. In health this is about 80 per cent, but falls in liver disease. Radiography can detect calculi only if there is sufficient calcium in their substance (Plate XXV.). Recently, however, a method known as *Cholecystography* is used, by means of which some idea of the gall-bladder can be secured prior to operation. It consists in a radiographic examination of the gall-bladder after the administration by mouth or intravenous injection of a suitable dose of sodium tetra-iodophenolphthalein. The patient is prepared as for a barium meal by purgation and starvation, and the dose is then administered; if by mouth, in gelatine capsules, which will not dissolve until the intestine is reached; if by the veins, 4·5 grms. dissolved in 40 c.c. of double-distilled water. The greatest care must be taken to prevent the slightest trace of this solution escaping outside the vein, or sloughing and suppuration will inevitably occur. A radiograph of the right subcostal region is taken previously for comparison, and again after intervals varying from twelve to twenty-four or thirty-six hours. Details of procedure vary much, but the results are very promising. If there is no hindrance to the entrance of bile or to its

escape from the gall-bladder, and if the organ is capable of carrying on its concentrating work normally, then it becomes visible as a shadow owing to the presence within it of the drug, which is opaque to the X-rays (Plate XXIV.). If, on the other hand, the excretory duct is blocked as by a calculus or malignant growth, or if the part is incapable of undertaking its function as a concentrator of the bile, no shadow will appear. Variations in the shape of the gall-bladder may be detected when they are due to extrinsic causes, such as tumours or adhesions; and calculi may reveal themselves as a mottling of the shadow if the ducts are patent.

Rupture or Perforation of the Gall-Bladder results from such injuries as blows, crushes, kicks, etc., but it may also be produced by penetrating wounds or bullets; occasionally it follows ulceration from within, as from a large impacted gall-stone. Blood and bile escape into the peritoneal cavity. Pure bile is sterile, but if any inflammation of the biliary passages has occurred, organisms are sure to be present. If a considerable quantity of bile escapes suddenly into the peritoneal sac, acute peritonitis is certain to follow sooner or later, whether organisms are present or not; slight jaundice arises from absorption by the peritoneum of bile, which may also be found in the urine. A more gradual escape of the secretion will probably lead to the formation of a localized intraperitoneal abscess or collection of fluid, associated with jaundice and possibly clay-coloured stools. In a penetrating wound bile and blood will escape on the surface, and septic peritonitis is almost sure to follow. The prognosis of cases of perforation due to stone is always bad, since the patient has probably been accustomed to severe attacks of pain, and the change in type may not be recognized until too late.

The immediate **Symptoms** are those of shock and severe hypochondriac pain, and this will be succeeded either by acute peritonitis or by the formation of a localized intraperitoneal swelling, together with mild jaundice. When the existence of such a lesion is suspected, **Treatment** always consists in an exploratory laparotomy. The condition has probably been diagnosed as one of perforated gastric or duodenal ulcer, and it is only the character of the exudate that calls attention to the biliary passages. Should only a small injury be found in the gall-bladder, it is perfectly feasible to close it by sutures; a gauze wick should, however, be passed down to the lesion for a few days, so as to provide a means of drainage should leakage occur. A more serious rupture necessitates removal of the gall-bladder. Should the common bile-duct be entirely divided, the ends may be united by suture, but in grave cases, where the gall-bladder is undamaged and healthy, it may be wiser to close the ends completely and undertake a cholecystenterostomy.

Inflammation of the Biliary Passages is of frequent occurrence, and generally arises as a sequela of gastro-duodenal catarrh. The affection is similar in nature to that commonly seen in other tracks lined with mucous membrane, and may be limited to the main bile-ducts and their extensions into the liver (*cholangitis*), or may also involve the gall-bladder (*cholecystitis*). The catarrh is determined by the presence of micro-organisms, and streptococci, staphylococci, or the *B. coli*,

PLATE XXIV

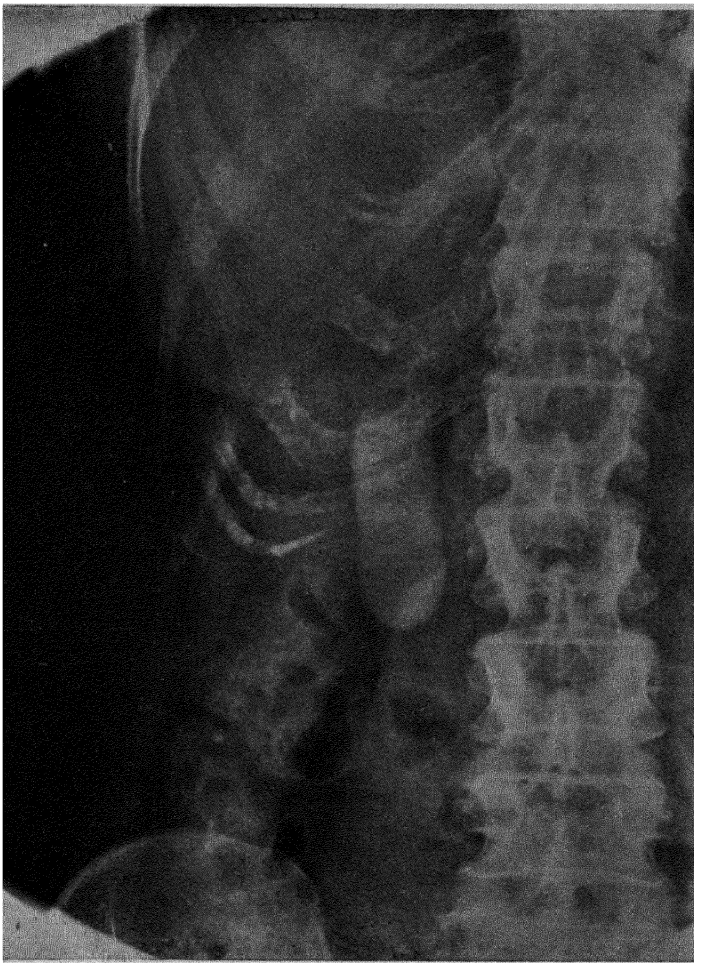

NORMAL CHOLECYSTOGRAM (ORAL METHOD.)

The gall-bladder fills normally, and no gall-stones are present This does not, however, exclude cholecystitis, since we depend on the filling of the gall-bladder to show non-opaque gall-stones (the result of chronic cholecystitis).

PLATE XXV.

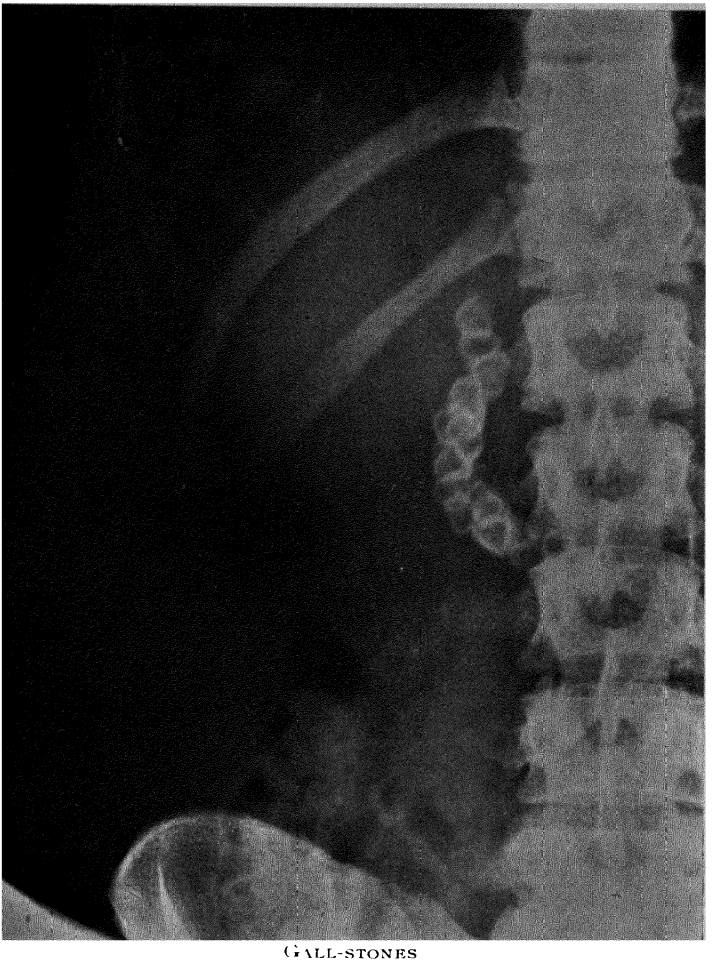

GALL-STONES

Note the facets on the shadows, also their dense periphery and less opaque centres, due to the deposition of lime salts on the cholesterin gall-stones.

are most frequently present; the condition may be limited to a simple catarrh, or suppuration may follow.

Catarrhal Cholangitis is of frequent occurrence, and presents two chief clinical types, the acute and the chronic. In the *acute* form it is common in young people, arising from over-eating or injudicious food, combined perhaps with exposure to cold and wet. The patient feels ill, perhaps shivers, looks a little sallow, or maybe is actually yellow (*catarrhal jaundice*). Abstinence from all but fluid food and the administration of mild purgatives, especially of the saline type, will generally free the patient from his symptoms in a very short time.

Sometimes the condition is of a more *chronic* type, occurring then in people of middle life, who are the subjects of persistent dyspepsia, often caused by late hours, irregular and injudicious meals, constipation, and perhaps mental and nervous tension. Indulgence in alcohol adds to the trouble. These people are frequently 'livery' and look more or less sallow, but are not actually jaundiced; they lose weight, and are irritable to a degree; but none of the graver symptoms of malignant disease are to be found. The liver is probably a little enlarged and may be tender, and the gall-bladder may be palpable. It is this type of patient in whom gall-stones are liable to develop, and for whom courses of water do so much good, as at Carlsbad or Harrogate, where hydro-therapeutic measures are combined with early hours and a rigid dietary. The essential elements of the treatment can be quite well carried out at home if the patients will submit to the restrictions that must be enforced.

Infective Cholangitis is a much more serious affection, and in severe cases may lead to a fatal issue. It is usually due to the presence of a stone or stones in the common bile-duct, but may arise from other causes, *e.g.* ascarides or hydatid cysts which have escaped into the biliary passages, from malignant disease, or it may spread backwards into the liver from a suppurating gall-bladder. The general phenomena which follow an attack of biliary colic, owing to the attempted or successful passage of a gall-stone, are due to this cause, and hence fever, with or without a shivering fit, a certain amount of jaundice (which is easily comprehended when one remembers the low pressure at which the bile is secreted), enlargement and tenderness of the liver, are to be looked on as the characteristic features of a mild attack. *Treatment* necessarily consists in removal of the cause, if possible, or, failing that, in draining the biliary passages by cholecystostomy. It must not be forgotten that the persistent presence of such a condition may lead not only to mischief in the liver, but also to chronic pancreatitis, and to adhesive peritonitis, which may complicate future operative procedures, and therefore in any patient with well-marked symptoms operation should never be long delayed.

In the more serious type of this affection suppuration extends along the biliary passages in the liver, and leads to multiple abscesses, a condition already noted. Drainage of the gall-bladder with removal of the causative stones, if present, is the only hope of cure, but the prognosis is very grave.

Cholecystitis, or inflammation of the gall-bladder, is an infection due to such organisms as the streptococcus, or staphylococcus, the *B. coli*, or *B. typhosus*, which are probably in nearly all cases blood-borne, seen most commonly in females of the 'fat and forty' variety, although it may occur in males and at all ages. It used to be supposed that the infection spread up the common bile duct and reached the gall-bladder in this manner, but the pathological findings that in early cases the inflammation is confined to the outer routes of the viscus preclude such a supposition. It is, however, possible that in some cases the infection may be lymph-borne from such neighbours as the colon or duodenum.

The gall-bladder undergoes pathological changes varying from the minimal of acute catarrhal cholecystitis to the maximal of suppurative and phlegmonous as in the case of inflammation of the appendix; but there is the essential difference that, in the latter, perforation, with general peritonitis, is far more common. This is solely due to the fact that the gall-bladder is more able, by virtue of its normal amount of distensibility, to withstand increase in the volume of its contents, and cases have been reported where the viscus has been opened in the pelvis and in an inguinal hernial sac.

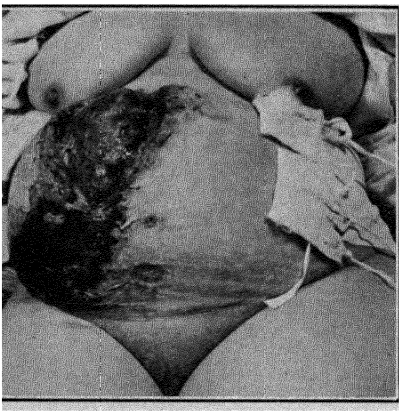

FIG 850.—SUPPURATION AND GANGRENE OF THE ABDOMINAL WALL AFTER OPERATION FOR ACUTE CHOLECYSTITIS.

Acute Cholecystitis.—This may be divided into three types, catarrhal, suppurative, and phlegmonous or gangrenous, the latter two usually being associated with the presence of gall-stones, a history of previous attacks, and, pathologically, signs of an acute superimposed or a chronic infection. The former is often accompanied by a catarrhal jaundice. The patient complains often of pain initially in the region of the umbilicus, but settling to the right hypochondrium. There is a feeling of nausea, with vomiting on occasions, associated with a general malaise. Pain may be referred to the right shoulder, or to just below the right scapula. The temperature and pulse are raised, and on examination there are tenderness and a certain amount of rigidity over the gall-bladder when palpation is carried on in the right subcostal region. A sign of value in inflammatory conditions of the gall-bladder is that described by Murphy. If gentle pressure is exerted in this region and the patient instructed to take a deep breath, the gall-bladder descends on to the palpating fingers, and if inflamed, the pain so produced will cause the patient to catch his breath. If there

is associated jaundice, there will of course be an absence of pigment in the stools and an increase in the urine.

Treatment.—Where such an attack is an initial one, medical treatment is to be preferred, as many of these mildly inflamed gall-bladders will return on quiescence to a normal condition; but where a previous history of trouble is given, operative treatment, if the case is seen early on, should be advised. It has, in the past, been customary to treat these cases conservatively during the acute phase, and to operate on them in a quiescent period; but the danger of operating on them if seen within forty-eight hours of the onset of the inflammation is no greater, as adhesions of any gross degree have not yet formed, and, in addition, the course of the disease is cut short. An added argument in favour of this line of action is the fact that small as are the dangers of immediate complications such as perforation or subphrenic abscess, these are eliminated. However, infection of the abdominal wall may follow in these cases (Fig. 850).

If medical treatment is adopted, it will consist of the application of hot foments to the subcostal region, the administration of a fat-free diet of bland fluids during the acute stages, and such drugs as hexamine, which have a germicidal action when excreted by the liver. Attention must of course be paid to the bowels, and in this respect doses of calomel are probably best.

Suppurative and gangrenous cholecystitis are, as has been mentioned, associated with previous trouble in the gall-bladder. A stone in a previously infected viscus may become impacted in the cystic duct and a free outlet to the secretions of the gall-bladder prevented. Suppuration steadily ensues, and the fibrosed gall-bladder wall becomes thick and œdematous. This suppuration, perhaps associated with the ulcerating and pressure effect of a stone, may give rise to a spreading gangrene with ultimate perforation and general peritonitis or, if adhesions have formed sufficient to localize the infection, a subphrenic abscess.

The patient gives a previous history often of gall-stone colic or jaundice. The present symptoms are similar to those of acute catarrhal cholecystitis, but all of much increased severity. Shivering attacks and belching are frequent, and the temperature and pulse are high. If perforation has occurred, the severe shock and intense pain simulate a perforated ulcer, although an aid to the diagnosis is the past history and the age and sex of the patient—usually old and female.

Examination reveals the signs of acute cholecystitis all more marked and severe. Occasionally it is possible to palpate the gall-bladder, but this is rare, as the condition is usually associated with a chronic fibrosed viscus.

Treatment.—This is essentially surgical. Where the condition of the patient merits it, cholecystectomy should be performed, but in severe cases the operation will be limited to cholecystostomy.

Chronic Cholecystitis is the result of attacks of acute or subacute inflammation, and is often associated with gall-stones. In most cases the viscus is thickened and contracted, and the neighbouring

liver shows signs of chronic hepatitis. But where a single stone, usually a cholesterol solitaire, has obliterated the lumen of the cystic duct before gross inflammation has set in, then the gall-bladder will be found distended with its own secretion of mucus, so that it may become palpable below the costal margin. If perhaps the occlusion is not absolutely complete, and some bile regurgitates, secondary mixed stones may form in the gall-bladder. Around the viscus adhesions form, binding it down to the duodenum and pylorus, and there is no doubt that many of the symptoms complained of by the

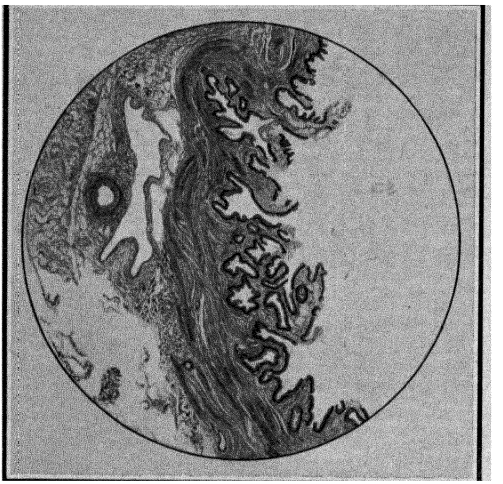

FIG. 851.—HISTOLOGICAL DRAWING OF THE WALL OF A GALL-BLADDER WITH COMMENCING CHOLESTEROSIS (× 25)

patient are due to interference with the normal function of these organs.

Symptoms and Signs.—Complaint is made of 'chronic indigestion' and an incomplete enjoyment of meals, a feeling of fulness and epigastric discomfort, the passing of much wind, and periodic bilious attacks. Pain may be complained of in the shoulder or in the back in addition to subcostal discomfort, while constipation is usual. Periodically the attacks may become acute, and may result in gangrene or suppuration.

Examination usually reveals a fat woman of middle age, and pain may be elicited on deep palpation in the subcostal region. Aid to diagnosis has been sought by means of X-ray, sodium tetraiodophenolphthalein when taken orally being excreted by the liver and concentrating in the gall-bladder. Failure of the dye to show in the gall-bladder should be desirably followed by a second examination in order to make quite sure that the dye has been absorbed, and in

such a case, or where the presence of gall-stones is shown by a filling defect, a pathological viscus can usually be safely diagnosed, and its removal results in great improvement. In those cases, however, where only a poor concentration is reported, indicating an apparently pathological condition, removal is not always followed by success, and, conversely, the removal of a gall-bladder in which the dye concentrates well is successful in alleviating the patient's symptoms. It is probable that in many cases an associated, and still present, gastritis may account for the perpetuation of the symptoms following removal

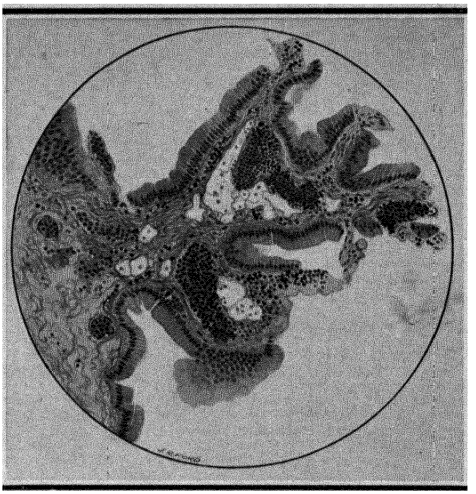

FIG 852.—HIGH-POWER MICROSCOPICAL DRAWING SHOWING ONE PAPILLARY PROCESS WITH FOAMY CELLS (× 160)

of a pathological gall-bladder. Where the diagnosis is in doubt, or in mild cases, a course of hexamine is often of value.

Cholesterosis of the Gall-Bladder.—In this condition the following changes take place: the epithelium and stroma become infiltrated with lipoids and cholesterol, and in the stroma large 'foamy' cells of very characteristic appearance occur; these cells are epithelial in origin (Figs. 851 and 852). The condition is usually associated with cholecystitis, and gall-stones may be present; it is more common in middle life, and has no relation to sex or social status.

The mucous membrane of the gall-bladder is congested, and scattered over it are innumerable nodular specks of a bright yellow colour, the whole appearance resembling that of a ripe strawberry (strawberry gall-bladder). Removal of such a gall-bladder, if not associated with other changes, is followed by poor post-operative results.

Cholelithiasis is the term applied to the presence of gall-stones in the gall-bladder and biliary passages, occurring most commonly in

middle-aged women. It may be said at once that the actual causation of gall-stones is unknown, although factors such as obstruction, infection, and cholesterolæmia are of ætiological import. In diseases where there is excessive destruction of red blood cells, such as acholuric jaundice, stones of almost pure calcium bilirubinate may be formed.

The stones are of several types:

1. *Mixed,* formed of a nucleus of bacteria and mucus round which are deposited layers of the calcium salts of bilirubin and biliverdin with a certain amount of cholesterol in the interstices, and found in a chronically fibrosed gall-bladder The stones are faceted where

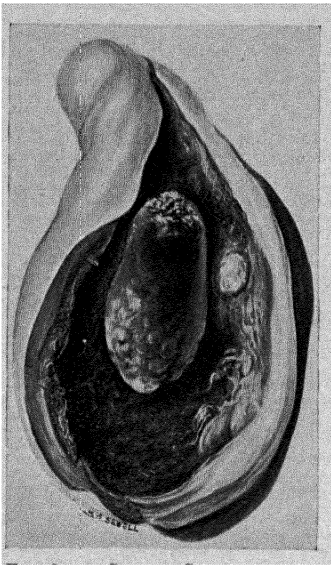

FIG. 853.—SINGLE GALL-STONE IN THICK-WALLED GALL-BLADDER. (KING'S COLLEGE HOSPITAL MUSEUM)

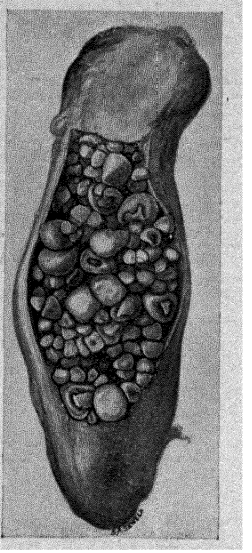

FIG 854 —MULTIPLE GALL-STONES IN THIN-WALLED GALL-BLADDER. (KING'S COLLEGE HOSPITAL MUSEUM)

they lie in contact with one another, and any number from a few to several hundred may be present. Their size, too, varies enormously; but in one gall-bladder where they are not all of the same dimensions, groups of families of the same size may be recognized, presumably laid down during periods of successive infection in the viscus. Occasionally a single stone of this type is found, often dumb-bell-shaped where the gall-bladder seems to have grasped it round its waist (Figs. 853 and 854).

2. The *cholesterol solitaire,* composed of pure cholesterin and associated with some disorder of cholesterol metabolism. It is often situated towards the neck of the gall-bladder, with consequent ob-

struction to the cystic duct and dilatation of the gall-bladder, which is filled with mucus. If infection supervenes and bile manages to pass into the gall-bladder, mixed stones will also be present, and the solitaire may become coated with a brown layer of bile salts.

3. *Pigment stones*, coal black and shining, with irregular surface.

4. *Calcium carbonate stones*. Although these of themselves are extremely rare, it is often found that the outer layer of mixed stones is composed of almost pure calcium carbonate, and it is suggested that this is deposited when absolute obstruction to the cystic duct exists in the presence of infection. Gall-stones formed in the biliary passages rarely contain much cholesterol, being formed of bile pigments and calcium salts.

The fact that gall-stones are frequently found unexpectedly on the operating-table or in the post-mortem room suggests that they may remain quiescent for years, and only cause trouble when attempting to escape, or if associated with some inflammatory disturbance. Thus the first evidence of the presence even of a large stone may be an attack of acute suppurative cholecystitis, and then, unless prompt attention is given, diffuse peritonitis results. Sometimes they cause chronic irritation of the gall-bladder, the walls of which become thickened and hyperæmic at first, but subsequently white and opaque; in time a process of sclerosis supervenes, which may lead to contraction of the wall upon the stones which are thereby encapsuled, and all attempts to displace them come to an end; cancer may also supervene. Adhesions often form between the gall-bladder and surrounding tissues, and thereby the movements of the pylorus or transverse colon may be hampered. More frequently the gall-bladder contains enough fluid to keep its walls distended, and then efforts to expel the stones follow, giving rise to definite painful symptoms. Sometimes the stones slip back, at others they pass on, and may escape into the bowel or may be blocked in the cystic or the common bile-duct, and find it impossible to progress further. Ulceration into various viscera, such as the stomach, duodenum, colon, or pelvis of the kidney, may then occur, and thereby relief be given to the symptoms, or they may escape into the general peritoneal cavity and cause diffuse peritonitis.

The **Clinical History** of a case of cholelithiasis is obviously very variable according to the exact location and condition present.

1. In what has been termed the *Prodromal Stage*, when the stones are free in the gall-bladder, and not doing much harm, the symptoms are referable rather to the stomach than to the hypochondrium. The patient complains of a sense of weight and fulness in the epigastrium, particularly after meals, accompanied by flatulent distension, which is relieved by belching, or entirely removed by vomiting. This may last for years, and is usually accompanied by constipation. Sometimes the discomfort amounts to acute pain, which doubles up the patient, and may be more severe on taking a deep inspiration. With these phenomena there may be a sense of chilliness scarcely amounting to a rigor, and when the pain passes the patient may perspire. He is often a little sallow, especially on days when he feels bilious, and there is some tenderness over the gall-bladder; but the diagnosis of gall-stones is

scarcely warranted unless the pain is very acute. Unfortunately, in this stage radiography does not often help in the diagnosis.

2. When the gall-stones are loose in the bladder and attempting to escape, more definite and distinct phenomena result. *Pain* is perhaps the most marked feature, and may be of various types. (*a*) There is the localized pain, due to the irritation of the gall-bladder itself, which is rather a dull ache referred to the right hypochondrium, shooting through to the back about the level of the tenth rib, and perhaps up to the right shoulder; this form is usually increased on movement. (*b*) Pain is also complained of, due to the adhesions which form about the gall-bladder and hamper the movements of the stomach or intestine; this is often epigastric in location, and may be of a colicky nature, especially after meals. (*c*) The worst pain is the typical *biliary colic*, due to the efforts of Nature to expel the stones. This is often of an excruciating character, starting suddenly, continuing for a while, and often ceasing as suddenly as it commenced when the stone passes on or slips back; the patient may be collapsed owing to its severity. It radiates from the right hypochondrium, shooting over the scapular region and into the back, the gall-bladder may be enlarged and tense during the attack, and the liver somewhat swollen. Vomiting usually occurs during or after an attack, and jaundice generally follows it, being due to the swelling of the mucous lining of the biliary passages, which prevents the escape of bile; if the stone slips back, it is not so likely to occur. The presence of many loose gall-stones often determines an enlargement of the gall-bladder, which can be felt from the outside.

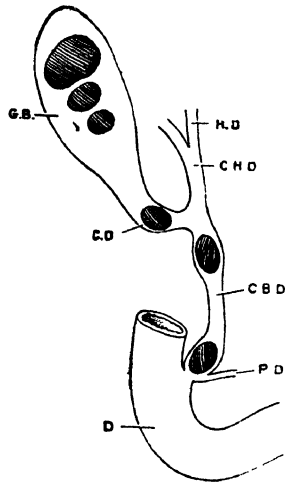

FIG 855.—DIAGRAM OF GALL-BLADDER AND BILE-DUCTS TO INDICATE THE USUAL SITUATIONS FOR IMPACTION OF GALL-STONES.

GB, Gall-bladder; HD, hepatic ducts; CHD, common hepatic duct, CD, cystic duct; CBD, common bile-duct; PD, pancreatic duct, D, duodenum.

3. *Impaction* of a stone *in the cystic duct* (Fig. 855) is characterized by pain, which is more or less persistent, but with paroxysmal exacerbations, and the gall-bladder may become distended with its own mucoid secretion (*hydrops*), until it may attain a considerable size. Jaundice is usually absent. Not uncommonly acute inflammatory phenomena follow (acute suppurative cholecystitis), and this may lead to ulceration or perforation. Less frequently chronic suppuration occurs, constituting an *empyema* of the gall-bladder.

4. Occasionally a stone becomes lodged at the junction of the cystic and the hepatic ducts, and then the manifestations of obstruction are very severe, and the pain may be very acute. Icterus is intense, but the gall-bladder may be empty; the liver is certain to be much enlarged.

5. The presence of gall-stones *in the common duct* (C.B.D.) may give rise to symptoms of the most diverse type; a small stone may originate very severe phenomena, whilst a much larger stone may cause less trouble. Frequently several stones are present and sometimes they are embedded in a mass of soft 'biliary mud,' consisting of inspissated bile salts. Their location, too, varies considerably; a single stone is perhaps found most frequently in the lower part of the duct, whilst multiple stones involve its whole length. The symptoms caused are pain of a paroxysmal character accompanied by vomiting, and jaundice, sometimes of a severe type, occasionally less marked, but rarely as persistent as the jaundice due to malignant disease. The stone is more or less movable, and acts as a ball-valve, at times allowing a certain amount of bile to pass. In malignant disease the obstruction is often absolute, and the jaundice is of a more maintained character. If the stone is located in the ampulla of Vater (Fig. 849), it is easy to understand that pancreatic troubles are likely to be associated with the jaundice. In this position it may ulcerate into the duodenum without much difficulty, but should a perforation form posteriorly, the retroperitoneal cellular tissue becomes involved, and a subphrenic abscess may result.

The **Treatment** of gall-stones is in the first place medical in character, and consists in a rigid attention to the diet, which should be simple and easily digestible, avoiding rich and fatty foods and all condiments; this is accompanied by regular exercise and the use of alkaline purgatives of a saline character, and an abundance of pure water. This is best carried out at a spa such as Harrogate or Carlsbad, but can be arranged for at home if the patient will submit to the necessary regulations. Biliary colic is treated by fomentations, and if need be by an injection of morphia and atropine; it is perhaps wise to administer hexamine as a biliary antiseptic, and salicylate of soda assists in increasing the fluidity of the bile. It is quite an arguable question as to what happens in such cures, whether the stones are softened and passed, or whether they become acclimatized in the gall-bladder and cease to cause trouble. At any rate, it is important not to waste too much time in this direction, should the symptoms persist. It has been already pointed out that gall-stones are not to be looked on as perfectly innocuous; inflammatory troubles of a serious character and even malignant disease may be caused by them, and therefore the persistence of symptoms, and especially their aggravation, indicates the necessity for surgical interference.

In cases where the stone is discovered by accident during a laparotomy for some other condition, removal followed by suture of the gall-bladder (*cholecystotomy*) is permissible, and if the gall-bladder wall is tolerably thick and healthy, the abdominal incision may be closed without drainage.

When on exploration a number of stones are found in the gall-bladder and no complications exist, removal, followed by drainage of the gall-bladder (*cholecystostomy*), was formerly the custom, but it has been abundantly proved to be ineffective. The mere existence of gall-stones connotes a chronic inflammatory condition of its mucous lining, which in this operation is still left behind, and recurrence of calculous

formation was only too frequent after it. At the present time surgeons are practically unanimous in insisting that complete removal of the gall-bladder (*cholecystectomy*) is necessary, as well as of the calculi. The operation, moreover, must never be completed without a thorough examination of the common bile-duct and of the hepatic ducts. This can usually be effected without much difficulty by palpation; a finger of the left hand is passed within the foramen of Winslow, and the common duct then lies immediately in front of it, and by the practised finger even minute calculi can be detected.

In acute cholecystitis, associated with impaction of the stone in the cystic duct, or in the fundus of the gall-bladder, or in the proximal pouch-like end (Hartmann's pouch), the case must be treated in a similar way to an acutely inflamed appendix, *viz.* by complete removal. Very gentle manipulation is often necessary in order to prevent rupture of the viscus and escape of infective material.

In old-standing cases where the patient has had repeated mild attacks of biliary colic and definite though not very deep jaundice, it is possible that a large number (perhaps hundreds) of calculi are present, and experience has shown that they are to be found not only in the gall-bladder, but also in the common bile-duct, and even in the smaller hepatic ducts, which may be considerably dilated. Sometimes, too, the bile-ducts are full of a muddy deposit difficult to remove. In such cases drainage of the biliary apparatus is absolutely essential, and the employment of the gall-bladder for this purpose, if it be possible, is generally ineffective, owing to the small calibre of the cystic duct. The gall-bladder, therefore, must be excised, and either the divided stump of the cystic duct dilated and used for drainage, or it may be ligatured in the usual way and the common bile-duct opened and drained.

Impaction of a stone at the junction of the cystic and hepatic ducts is treated by cholecystectomy and division of the cystic duct close to the stone, it is usually feasible to 'milk' the stone backwards through the opening of the divided cystic duct. If not, the stump of the cystic duct must be slit up, the stone removed, and the opening used for drainage purposes.

A stone in the common bile-duct is removed by exposing and incising the duct (*choledochotomy*). There is but little difficulty in effecting this if the stone is in the upper part above the duodenum; with a finger of the left hand in the foramen of Winslow, it is localized and steadied, and a longitudinal incision through the peritoneum and duct wall permits readily of its removal. Careful packing with gauze swabs is necessary to protect the peritoneum from the flow of bile, which is often considerable. The duct is then palpated upwards towards the liver and down to the intestine, so as to ascertain, if possible, the absence of other calculi, and the downward passage of a probe into the intestine makes certain that the papilla is patent (Fig. 856). *After-drainage.*—In a few cases where there has been found but a solitary stone, and the history suggests its recent extrusion from the gall-bladder, it may be permissible to close the incision in the common duct by sutures. Of course, a drainage-tube is carried down to the site of the incision and maintained

for a few days to ensure an exit in case of leakage. In the great majority of cases, however, the calculi in the bile-duct are multiple, and the symptoms of some duration and gravity, the hepatic ducts are then certain to be inflamed more or less, and may be considerably dilated, sometimes a good deal of grit or bile-mud is present. Under these circumstances drainage is essential, and may be effected in two directions: (i.) A small catheter is passed down the duct through the biliary papilla into the duodenum, and retained there. This causes dilatation of the papilla, and thus provides a means of escape for bile, and possibly for mud or grit, it also permits the administration of abundance of fluid (saline or carbonate of soda solution with glucose) by the 'drip' method, as well as fluid meals every three or four hours. (ii.) Tubes are also passed upwards, and for choice these should be of small size, so as to enable them to be placed, if thought desirable, in various dilated branches of the hepatic ducts. Drainage is thereby secured, and an exit provided for calculi, etc. Where mud or grit is present, the tubes may advisably be of the Carrel type; after the peritoneal cavity is shut off (in twenty-four or thirty-six hours), intermittent irrigation with saline solution may be instituted and maintained until the bile is quite clear, this may take two or three weeks.

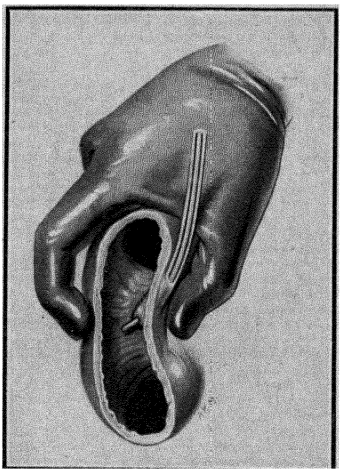

FIG 836.—METHOD OF PASSING PROBE DOWN THE COMMON BILE-DUCT AND PALPATING THE AMPULLA OF VATER

If a stone is lodged behind the second piece of the duodenum, it is often possible to manipulate it upwards, and deal with it above the bowel; if this is impracticable, the duodenum must be mobilized by dividing the peritoneum on its outer edge, and then it can be displaced inwards sufficiently to enable the duct and stone to be reached.

When a stone is impacted in the ampulla of Vater, and cannot be manipulated upwards, the duodenum should be opened on its anterior aspect, the biliary papilla sought out, and a longitudinal incision made upwards from this, so as to open the ampulla and allow the stone to be removed. The walls of the bile-duct and duodenum are then sutured together, thereby determining the formation of a large communication between the two (*internal choledocho-duodenostomy*), which permits of effective drainage of the biliary apparatus, and is a most satisfactory and beneficial procedure.

Bronchobiliary Fistula.—A rare complication of acute cholecystitis is a bronchobiliary fistula. In the majority of recorded cases the most

common position for the fistula was in the dome of the diaphragm over the apex of the right lobe of the liver (Fig. 857). Most of the cases end fatally, bile-stained sputum being expectorated, while signs of pneumonia develop in the chest.

Operations on the Biliary Passages.—No special preparation of the patient is required, except in cases that have been long jaundiced. This condition is often associated with excessive hæmorrhage, due to defective coagulability of the blood, and this probably arises from a deficiency of calcium salts. It is therefore advisable to administer intravenously 5 c c. of a 10 per cent. solution of calcium chloride for three days before operation; blood transfusion may in some cases be a better procedure.

It is wise in all operations on the biliary passages to introduce a firm sand-bag or triangular air-cushion horizontally beneath the patient's back, so as to throw the liver forwards, and thereby gain better access to the deeper parts.

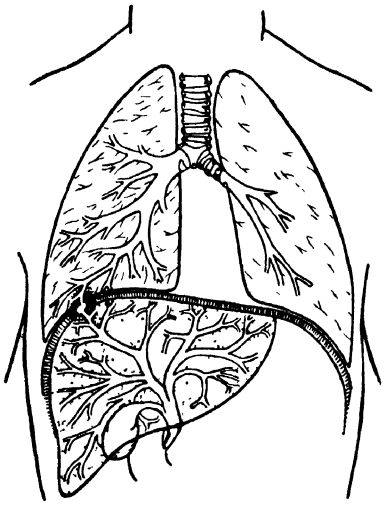

FIG 857 — DIAGRAMMATIC DRAWING SHOWING THE SITE OF THE BRONCHO-BILIARY FISTULA

A right paramedian incision is that usually employed. It has, however, been recommended by Perthes that the incision should be made close to the middle line, extending from the ensiform cartilage nearly to the umbilicus, and then crossing the rectus horizontally outwards to the margin of the ribs. The fibres of the rectus muscle are secured by mattress sutures to the anterior layer of the sheath above and below before being divided, so as to prevent retraction, and the rectangular flap of skin and muscle is then dissected up off the posterior layer of the sheath and peritoneum, which are divided by an oblique incision. The main object of this procedure, which gives an admirable approach to the biliary passages, is to avoid division of the nerves supplying the rectus muscle. It may be employed with advantage, except in cases where drainage is likely to be necessary.

The peritoneum being opened, the liver is rotated upwards and outwards, and the intestines, stomach, and omentum are pressed downwards and inwards after protecting them by abdominal cloths. In the absence of adhesions, the object of the operation can usually be attained without much difficulty, but not unfrequently the presence of adhesions complicates matters considerably; they must be carefully divided with a view to preventing subsequent hæmorrhage. If the gall-bladder is much distended, it is sometimes necessary to tap it and

remove its fluid content before a decision as to diagnosis or treatment can be reached. Care must be taken not to allow the peritoneum to be soiled by the escape of bile, mucus, pus, or stones, which are almost always infected.

For **cholecystotomy** the trocar puncture is enlarged by the knife, and the stone or stones removed by forceps, scoop, or by digital extrusion, and then the opening is closed by sutures which do not encroach on the mucous membrane. One or two rows of stitches may be employed according to the condition of the gall-bladder wall, and it may be wise to strengthen the site of union by an omental graft. For **cholecystostomy** a medium-sized drainage-tube without lateral openings is stitched into the gall-bladder by catgut sutures, which should last about a week. The gall-bladder is then fixed to the parietal peritoneum, and the remainder of the wound closed. The outer end of the tube is passed into a bottle lying by the patient's side, in which the bile collects. When the tube becomes loose, the wound is lightly packed with gauze, and for a time the patient's condition is uncomfortable, as the bile escapes into the dressings, which must be frequently changed. As, however, the wound granulates, it becomes more difficult for the bile to escape externally, and more easy for it to follow its natural course, and hence after two or three weeks the external flow usually ceases, and the wound may be allowed to close. Should the escape of bile persist, further operative treatment becomes necessary. If the presence of a certain amount of bile in the motions indicates that the common bile-duct is free from obstruction, the opening in the gall-bladder may be completely closed by sutures after freeing it from adhesions. The absence of bile in the stools, however, suggests the presence of some stricture or obstruction in the bile-duct, and if this cannot be dealt with, cholecystenterostomy must be undertaken.

Cholecystectomy, as already mentioned, is the operation of choice in the majority of cases of gall-stones. It is usually not a difficult procedure, and the mortality is small. The serous coat is divided on either side and over the fundus about a centimetre from its reflexion from the liver, and a line of cleavage is generally found without difficulty between the capsule of Glisson and the body of the viscus. It is then easy to separate it from the liver; the cystic vessels are secured by ligature, and finally the cystic duct is tied and divided. If possible, the peritoneal coat is drawn together over the gap left by the removal of the gall-bladder, but it is often necessary to pack this space with gauze for a few days on account of oozing of blood. In many cases the surgeon is able with advantage to reverse this programme, and commences by freeing and dividing the cystic duct and by securing the cystic vessels; it is then easy to detach the gall-bladder, and the loss of blood is less (Figs. 858 and 859).

A danger that must be avoided in this operation is the possibility of dragging up the common bile-duct together with the gall-bladder and removing a section of it unwittingly. The cystic duct may be very short, or adhesions may be present between the proximal end of the gall-bladder and the peritoneum over the common bile-duct; it is

necessary, therefore, to define very exactly the position and character of the duct before dividing it. Injury to the common bile-duct is a grave accident which must, if recognized, be dealt with without delay by suturing the ends together, or by constituting a new bile-duct; secondary operations for this purpose are much more difficult and less satisfactory.

Cholecystenterostomy, or the formation of an artificial communication between the gall-bladder and the bowel, is required in cases where

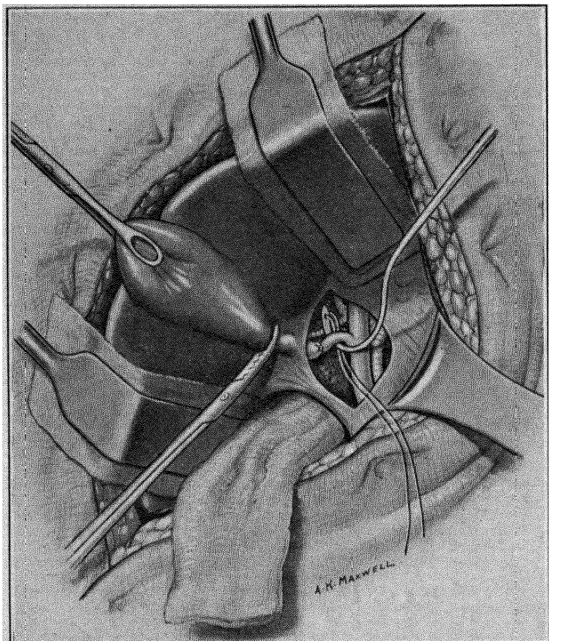

FIG 858.—CHOLECYSTECTOMY. LIGATURE OF THE CYSTIC DUCT

jaundice persists, owing to absolute stenosis of the common duct. It has also been undertaken for the relief of jaundice due to malignant disease, either of the common bile-duct, the head of the pancreas, or of the intestine, the relief given under these circumstances is, of course, only temporary. The parts are exposed as described above, the gall-bladder and duodenum are brought into contact, and a lateral anastomosis made by simple suturing, the technique being similar to that employed for a lateral anastomosis of the intestine.

Tumours of the Gall-Bladder and Biliary Passages are usually malignant, and of a columnar carcinomatous type; benign tumours are very rare, and merely of pathological interest. Cancer is comparatively

PLATE XXVI

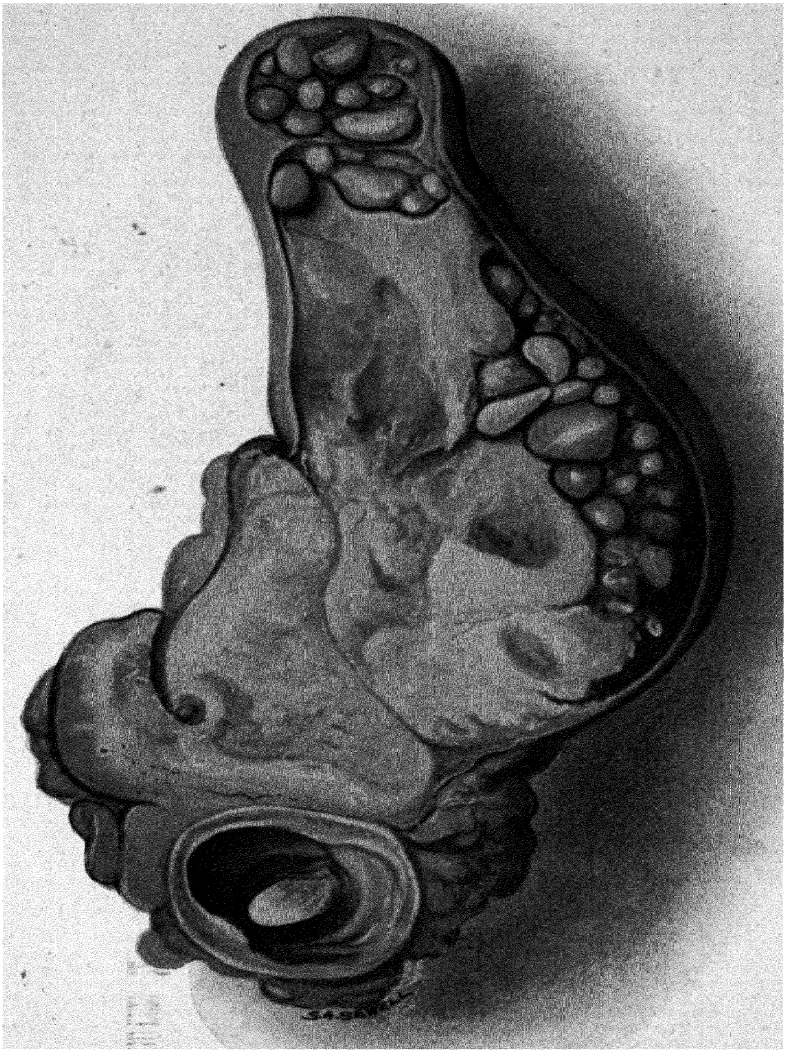

Carcinoma of the Gall-bladder with gall-stones

(*Museum, Royal College of Surgeons*)

common, and is so constantly associated with gall-stones (some authorities state that 90 to 95 per cent. of such cases also have gall-stones) as to suggest that the irritation of the latter may induce the neoplastic formation (Plate XXVI.). The disease is about three times as common in women as in men. Cancer of the gall-bladder usually commences near the fundus and spreads upwards. The symptoms and signs are those of a hard, painless swelling in the region of the gall-bladder, with progressive loss of weight, and later on jaundice

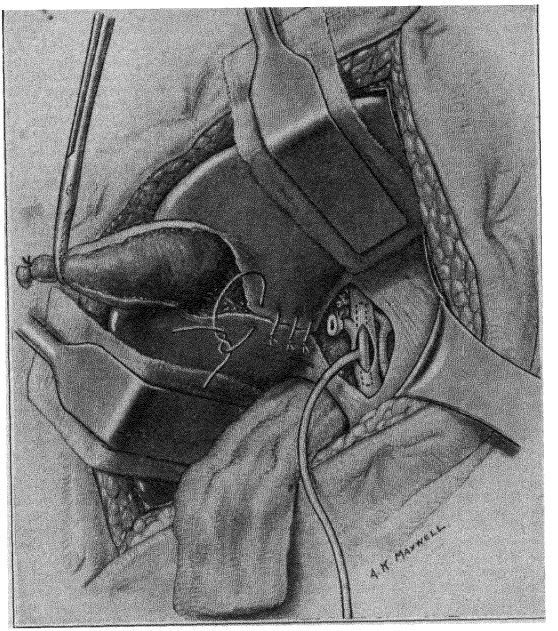

The gall-bladder is partially removed and its bed in the liver peritonized
A T-tube has been placed in the common duct

and ascites. Primary cancer of the common bile-duct is rarer, and may commence at the bile-duct papilla, or higher up. At first it causes jaundice, without pain, and sometimes distension of the gall-bladder, the jaundice is persistent, and gradually increases in severity. Gastric symptoms from pressure on the pylorus or duodenum may follow, and extension in various directions may determine different manifestations. In either of these affections lymphatic dissemination along the falciform ligament may lead to the appearance of a secondary nodule near the umbilicus, which is both of diagnostic and prognostic import.

Treatment is rarely practicable, as the disease is usually recognized

too late. Excision of the gall-bladder, and, if need be, of the neighbouring portion of the liver, may be practicable in a few cases, but is rarely successful. For tumours of the common bile-duct excision is sometimes possible, but recurrence usually follows; cholecystenterostomy may relieve the intense jaundice and add to the patient's comfort.

Torsion of the gall-bladder is a rare condition, associated usually with adhesions and the presence of a loose reflection of the peritoneum of the viscus on to the liver. The signs and symptoms are similar to those of gangrenous cholecystitis, and the treatment is operative, with removal of the gall-bladder.

Affections of the Pancreas.

The pancreas is a glandular organ secreting an active digestive juice, which escapes into the intestine through the duct of Wirsung, this traverses the whole length of the gland, and opens with the common bile-duct into the ampulla of Vater; a small accessory duct of Santorini (DS) opens into the bowel about an inch higher up (Fig. 860). There

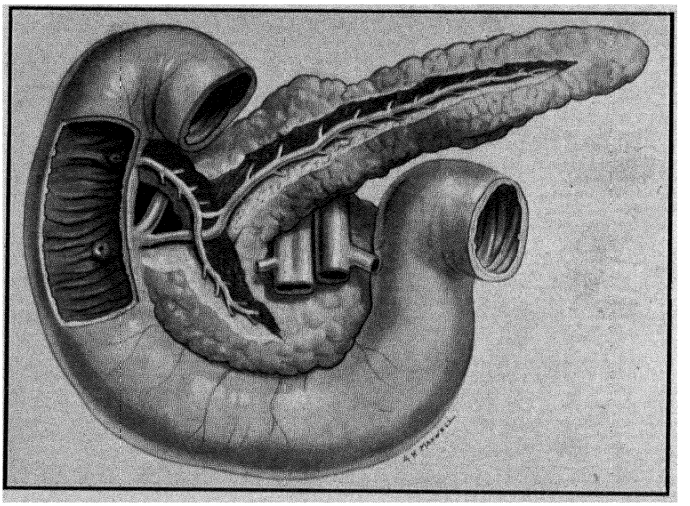

FIG. 860.—DISSECTION OF THE PANCREATIC DUCTS SHOWING THE METHOD IN WHICH THEY OPEN INTO THE DUODENUM

are two chief methods of approaching the gland: (1) The transperitoneal, in which the abdomen is opened in the middle line above the umbilicus, it is reached either above the stomach by dividing the small omentum, or by traversing the great omentum just below the great curvature of the stomach, or by opening through the transverse mesocolon. (2) The retroperitoneal method consists in an incision

below the last rib in the lumbar region, but only the head or the tail is exposed by this procedure.

There are various abnormal ways in which the common bile-duct and the duct of Wirsung may open into the duodenum (Fig. 861).

There are two chief risks associated with pancreatic lesions or operations: (i.) The organ is very freely supplied with blood, and it is extremely difficult to ensure hæmostasis. Ligature of the pancreatic tissue causes necrosis, and from the necrotic tissue ferments are set free which act injuriously on the tissues around, and predispose to further hæmorrhage. Deep stitches and effective tamponade can alone be relied on in this direction. (ii.) The leakage of pancreatic juice is a serious danger to the patient in that it is likely to determine necrosis of fat wherever it spreads; hence foci of fat necrosis may be found scattered extensively through the omentum and mesentery in all acute pancreatic lesions. Moreover, it acts most prejudicially on the peri-

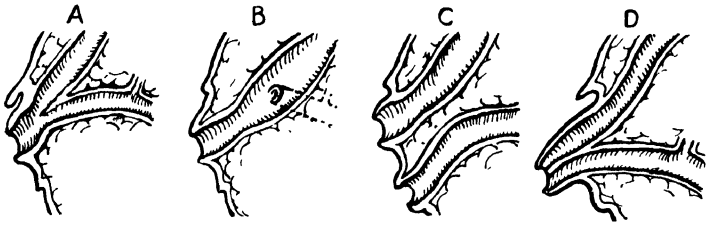

FIG. 861.—THE VARIOUS WAYS IN WHICH THE COMMON BILE-DUCT AND THE DUCT OF WIRSUNG OPEN INTO THE DUODENUM

A, Normal, B, duct of Wirsung opening into common bile-duct, C, two separate openings, D, two openings on a papilla

toneum, and induces either an aseptic peritonitis and intestinal paralysis which may prove fatal, or determines an infective peritonitis if bacteria are present.

Wounds of the Pancreas are due to direct violence applied to the epigastrium, and may result from penetrating or non-penetrating injuries. They are usually accompanied by lesions of other viscera, such as the stomach or duodenum, and surgeons should remember the necessity for examining this viscus in any traumatic condition in the neighbourhood. Deep sutures and tamponade must be used in all cases where solution of continuity has occurred, the latter being needed not only as a hæmostatic agent, but also in order to drain away any leakage of pancreatic fluid. A certain number of non-fatal cases of injury to the pancreas are followed by fistula formation.

Pancreatic Fistula.—Although the majority of cases of pancreatic fistulæ follow traumatism from without, a few cases have been known to occur after accidental injury to the gland during upper abdominal operations. In some rare cases of resection of the duodenum for carcinoma or excision of a cancer of the common bile-duct a fistula results. If possible the duct of Wirsung should be intubated and the catheter made to traverse the duodenum and open through the abdominal wall. After

ten days or more, when the catheter is removed, the fistula often closes. It is surprising how much pancreatic juice is secreted each day, an average being 1,300 c.c. per diem. Each year cases are recorded in which a successful end-result has been obtained.

Acute Pancreatitis is a grave affection involving women rather more frequently than men. Although its name suggests that its nature is inflammatory, it seems perhaps probable that the changes present in the organ in this condition are essentially vascular in nature. The ætiology of acute pancreatitis is obscure, although the frequent association of the presence of gall-stones in some 60 per cent. of cases is noted by all writers. An endeavour has been made to attribute it to activation of the inactive trypsinogen by a regurgitation of bile along the duct of Wirsung, the regurgitation being due to an impaction of a stone in the region of the papilla of Vater. Experimentally, however, it is found that only when bile is injected into the pancreatic ducts at a pressure sufficient to rupture the alveoli does any change resembling acute pancreatitis occur, and the very rare occasions in which an impacted stone is actually found are noted.

Others have attributed a spasm of the sphincter of Oddi as instrumental in producing reflux of the bile, but it has been shown, however, that anatomically in a majority of cases the sphincter is placed on the common bile duct proximal to its junction with the pancreatic duct.

Others believe that the disease is due to a lymphatic or blood-borne infection, but the fact that the condition is not initiated with the common associations of an infective condition makes this unlikely.

Obstruction in the pancreatic duct, with stagnation and perhaps activation of the enzymes, may be due to such rare conditons as calculi, the presence of a worm, or pressure due to a duodenal diverticulum, but recently attention has been drawn to the presence of a proliferative metaplasia often found in the condition, and to the presence of heterotopic rests under the duct epithelium which may well cause interference with adequate drainage.

Finally, the theory held by certain French surgeons that the condition is due to an interference with the blood supply of the organ by nervous inco-ordination must be mentioned.

The pancreas rapidly becomes enlarged, œdematous, and reddened, hæmorrhage occurring into it and into the tissues around. Liberation of the pancreatic enzymes causes a splitting of the fat in the mesentery and omentum, the retroperitoneal fat, and sometimes in the abdominal wall, with the formation of scattered areas of a granular nature in these positions. At first there is produced a non-infective peritonitis with resulting dilatation of the intestine and effusion into the peritoneal cavity. This, however, usually becomes infected. Occasionally blood is present in the effusion, this being due either to the proteolytic action of the trypsin on the walls of the blood-vessels, with subsequent erosion and bleeding, or to an escape from dilated capillaries and blood-vessels where thrombosis of the superior mesenteric, splenic, or portal veins occurs.

In very severe cases the whole pancreas may slough, become

infected with the production of an abscess, whereas in milder cases effusion limited to the lesser sac of peritoneum only may form.

Symptoms.—The patient, usually middle-aged, is seized with acute abdominal pain localized to the epigastrium and hypochondria, and associated with a marked degree of collapse. Pain may be complained of in the back of a severe, piercing nature, although its severity is scarcely as great as that associated with perforated duodenal ulcer, or renal or gall-bladder colic. The temperature is subnormal, but the pulse much raised and thready, and the respirations shallow and increased. Cyanosis and a moist clammy skin are usually present, while occasionally slight jaundice is observed. Persistent vomiting, first of bile-stained material and latterly of intestinal contents, is almost invariable. Blueness round the umbilicus, probably due to thrombosis of the portal system, is sometimes present and associated with a poor prognosis, while discoloration in the loins has also been noted.

The abdomen is tender in its upper part, though rigidity is not extreme, and soon rapid distension ensues, with associated constipation. Occasional hæmatemesis has been present.

The uncertainty of Loewe's adrenalin test has caused its general abandonment, but a determination of the urinary diastatic index, normally 4-50, will reveal an early rise of anything up to 2,000. The presence of glycosuria or raised blood-sugar, and the presence of bile in the urine, are variable findings.

Differential Diagnosis.—From acute pancreatitis must be distinguished acute pericarditis, associated with friction sounds, an enlargement of the area of cardiac dulness and collapse of the base of the left lung, and perforations in which the degree of collapse is less and the pulse rate in the early stages is comparatively slow, and acute intestinal obstruction.

Treatment.—Although some surgeons have recently swung to conservative treatment of this condition where complications such as abscess formation do not exist, we believe that in acute cases operation should be advised, a waiting policy being preserved for the less acute cases in which the diagnosis is sure.

The abdomen is opened through a paramedian incision, and the lesser sac opened where the diagnosis is confirmed by the finding of areas of granular fat necrosis. It is best to open the sac through the interval between the stomach and transverse colon, although some surgeons prefer to incise the lesser omentum or the transverse mesocolon. Necrotic areas of the pancreas are removed and a large drainage tube placed down to the organ. If an abscess is present, this must of course be opened and drained, care being taken to pack off the rest of the abdominal contents.

Should the gall-bladder be diseased and the patient's condition satisfactory, it should be removed or drained after the removal of any stones present. If gross peritonitis is present, a suprapubic drain should be instituted.

Following operation, an intravenous saline transfusion should be set up.

Conservative treatment will consist in giving intravenous saline transfusions to combat the shock and toxæmia, and, if vomiting is severe, passing a Ryle's tube and carrying out repeated stomach wash-outs and aspirations. A fluid diet only will be given as soon as vomiting ceases, and morphia and atropine administered freely to alleviate the pain.

Chronic Pancreatitis is not to be looked on as a very uncommon lesion. It is frequently associated with gall-stones and inflammation of the biliary passages, and may follow gastro-duodenal catarrh or ulceration. The organ may be larger and harder than usual, or is shrunken and sclerosed. It may produce a swelling in the epigastrium which somewhat resembles a pancreatic carcinoma, and the symptoms caused thereby are of a dyspeptic type. Fixed epigastric pain is often present, and a tender spot a little above the umbilicus. Diabetes may arise in certain forms of chronic inflammation; offensive diarrhœa with undigested fat in the stools and rapid wasting are also suggestive symptoms. Operative treatment may be of value, since pancreatic or biliary calculi may be found obstructing the duct, apart from this, benefit has certainly been derived by cholecystostomy or cholecysto-gastrostomy and drainage of the biliary passages.

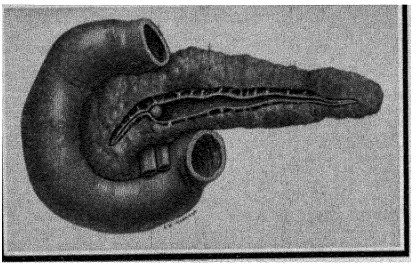

FIG. 862.—CALCULUS IN THE PANCREATIC DUCT, CAUSING CONSIDERABLE DILATATION OF THE DUCT.

Pancreatic Calculi. — It may be said that pancreatic lithiasis is a rare condition, for less than 150 cases have been reported in the literature, and in less than ten of these a correct diagnosis was made.

There are two different types of calculi: (1) True stones, consisting of carbonate of lime and found in the ducts; and (2) false stones, or calcification of the parenchyma resulting from pancreatitis. In the case of false stones, in all probability the ætiological agent is in most cases to be found in disease of the biliary track. True pancreatic stones are rounded and smooth, and cause considerable dilatation of the pancreatic duct (Fig. 862). Stones may become impacted and give rise to acute abdominal pain which radiates round the flank into the small of the back. X-ray examination may reveal a stone, and such an examination may be most useful, but is mostly omitted. Changes in the stools are also an aid to diagnosis. The stools may be bulky, frothy, and rather foul; excess of fat is not usually present. Jaundice may or may not occur, depending on the situation of the stone and the presence of pancreatitis or associated disease of the biliary tract. Diabetes is quite frequently associated with pancreatic lithiasis.

Treatment consists of exploration and removal of the stone.

Pancreatic Cysts are of rare occurrence, and usually are due to

previous trauma with the formation of a pseudo-cyst, not actually associated with the substance of the pancreas but situated in front of it, and containing altered blood confined in a space, the walls of which are fibrous and devoid of any epithelial covering. Rarer forms may be due to defective development of the organ and are sometimes found in association with polycystic disease of the kidney. True dermoid cysts have been reported. True cystadenomata, sometimes associated with inlets of Langerhans, and giving rise to symptoms of hypoglycæmia, cystadenocarcinomata, and teratomatous cysts, are also described. It is probable that other cysts found in this region are the result of developmental abnormalities of enterogenous or congenital origin.

Simple complete obstruction to the duct has been proved experimentally not to be a sufficient cause for the disease.

Occasionally a hydatid infection will give rise to a cyst in the pancreas.

The fluid in these cysts is turbid and brownish from altered blood, alkaline in nature, and contains ferments which will peptonize albumen and break down fat and starch.

These cysts are usually seen in men of middle age, and attention may be drawn to them by their being felt when bathing, or by the vague abdominal symptoms to which they may give rise. Usually dyspepsia is complained of, jaundice or constipation may be produced if the common bile duct or transverse colon is sufficiently compressed.

On examination the patient is often emaciated, as the functions of the pancreas may be interfered with and the absorption of fat and the end products of protein metabolism diminished. The complexion is dirty and unhealthy-looking. The cyst can be felt as a rounded, tense, fluctuating or elastic swelling, placed deeply in the abdomen, immovable, and perhaps transmitting the aortic pulsation. The relations of a cyst to the stomach and transverse colon vary (Figs. 863-865), the cyst primarily forms behind the stomach, but when it attains any considerable size it projects anteriorly, and then most commonly approaches the abdominal wall below the stomach and above the transverse colon (Fig. 864). More rarely it presents above the stomach (Fig. 863), or below the transverse colon (Fig. 865).

Treatment will be operative, and consists in exposing the cyst either through the greater or lesser omentum according to which is more convenient. Ideally complete removal is indicated, but this is seldom possible on account of the gross adhesions present and the anatomical situation of the cyst. Alternatively, after draining the cyst with trocar and cannula, it is marsupialized by stitching its wall to part of that of the abdominal incision. Packing the cyst from the exterior will hasten its being filled with granulations, though occasionally a permanent fistula will result. Ulceration of the abdominal wall by the ferments present must be prevented by copious application of horse serum or vaseline.

Adenoma of the Pancreas is very rare, but each year as it passes seems to yield one or two reported cases. The adenoma arises in the islands of Langerhans and gives rise to attacks of hyper-insulinism.

The attacks may be ushered in by a period of listlessness, yawning, muscular twitching and tremors, perspiration, and aphasia. After

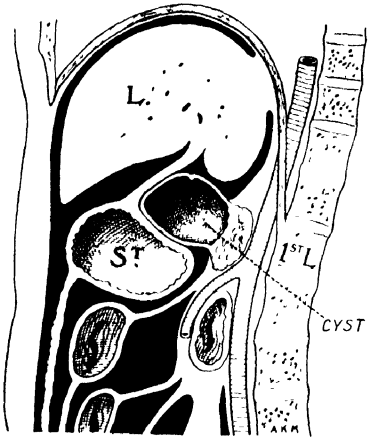

FIG 863.—DIAGRAM SHOWING PANCREATIC CYST PROJECTING FORWARDS BETWEEN STOMACH AND LIVER

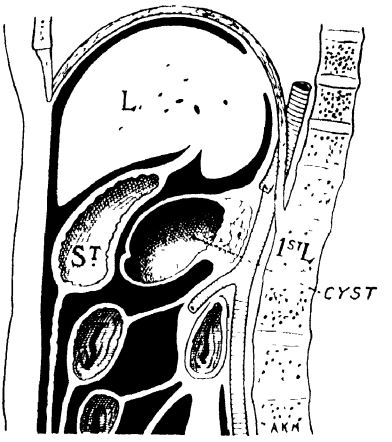

FIG. 864.—PANCREATIC CYST PROJECTING FORWARDS BETWEEN STOMACH AND TRANSVERSE COLON

this the patient often becomes unconscious. The treatment consists in removal of the adenoma through a paramedian abdominal incision. A few successful cases have been reported.

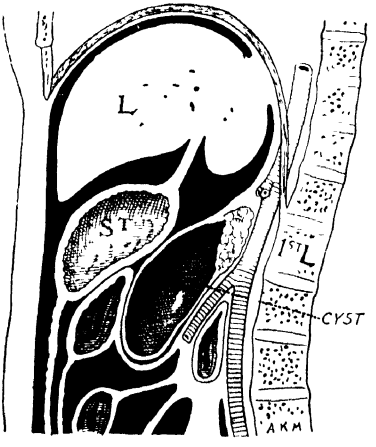

FIG 865.—PANCREATIC CYST PROJECTING DOWNWARDS BETWEEN TRANSVERSE COLON AND COILS OF SMALL INTESTINE

Carcinoma of the Pancreas is met with either as a primary growth of a spheroidal-celled type, usually scirrhus, or is secondary to a similar disease of the stomach or pylorus. The condition is not necessarily painful in the early stages, and may produce an ovoid or oblong mass at the junction of the epigastric and right hypochondriac regions. As it develops it becomes more painful, and the patient wastes and loses appetite and energy. Jaundice gradually supervenes and becomes absolute, with an enlarged gall-bladder. A barium meal may reveal a very dilated duodenum, due to pressure of the growth on the third part of the duodenum (Fig. 866).

An anastomosis between the gall-bladder and the stomach (cholecystogastrostomy), or the jejunum (cholecystenterostomy), will relieve

the jaundice with its very troublesome itching. Sampson Handley has recently reported some cases in which good results have followed the insertion of radium into the actual growth. Usually, however, the prognosis is bad, the abdomen becomes distended with fluid from pressure on the portal vein, and the legs become œdematous from involvement of the inferior vena cava. Secondary growths may develop in the liver, and the pylorus may even be pressed upon by the growth before death ensues.

Sarcoma of the pancreas is very rare, and produces similar signs to those of carcinoma.

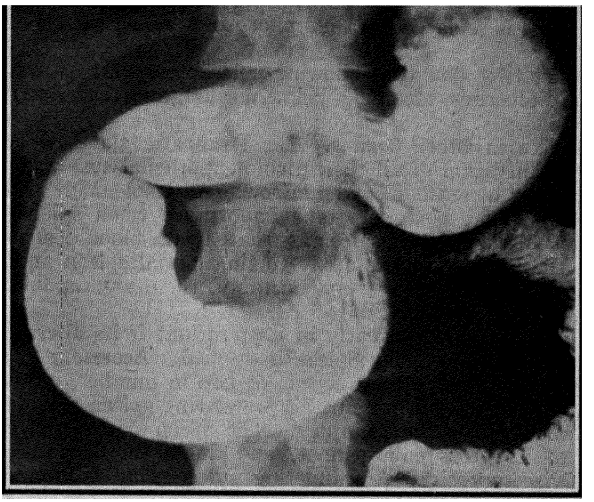

FIG 866.—BARIUM MEAL SHOWING GREATLY DISTENDED DUODENUM, IN A CASE OF CARCINOMA OF THE HEAD OF THE PANCREAS

Surgical Affections of the Spleen.

The spleen is normally situated in the left hypochondrium, its long axis corresponding with the axis of the tenth rib. Its upper border extends as high as the upper border of the ninth rib and its lower border to the lower edge of the eleventh rib. It extends as far forward as the anterior axillary line. It is not palpable in the normal abdomen, except in young children, when a just palpable spleen apart from other symptoms is not of significance. It weighs about 4 ounces.

Functions.—The spleen is not essential to life, and its removal leads to no lasting disability. It acts as a reservoir of red blood cells, and by active contraction it can deliver these cells to the circulation in times of emergency (hæmorrhage—carbon monoxide poisoning and the like). The spleen plays an important part in the metabolism of red

cells. In the fœtus it plays a formative rôle, but in the child and adult its action is mainly destructive. It is also thought to destroy platelets. Numerous other functions have been attributed to the spleen, especially in relation to detoxication and phagocytosis, but these need not be considered here in further detail.

The changes following removal of the spleen may be summarized as follows:

A. **Changes in the Blood**—1. **Anæmia.**—The fall in the red cell count is associated with a fall in the hæmoglobin percentage and diminished fragility of the red cell. The anæmia usually recovers in two to six months.

2. **Leucocytosis.**—At first this is a polymorphonuclear leucocytosis, but later this is replaced by a lymphocytosis which persists for some months.

3. **The Platelet Count.**—Following splenectomy the platelet count at first rapidly rises, next falls below normal, and then fluctuates for a long period.

B. **Changes in Other Organs.**—The lymphatic glands enlarge and there is proliferation of all the reticulo-endothelial system. There is frequently an increase in red marrow. Any splenculi will hypertrophy, this point being of some importance when splenectomy is advised for diseases of the spleen associated with blood destruction.

While the above remarks apply to the normal spleen and changes which normally obtain after splenectomy, these are capable of wide variation.

The spleen may vary greatly in its position; if its aberrations are severe the term **Wandering Spleen** is applied. **Accessory Spleens** are not uncommon. These may be one or two in number, or there may be dozens of splenculi present. A wandering spleen may be due to congenital defects, or due to injury. The spleen may also be displaced because of its gross enlargement, and finally in Glénard's disease (general visceroptosis). A wandering spleen may be found in the thorax in a diaphragmatic hernia—in the left or right iliac fossa, or even in the pelvis. In most of these cases the spleen has a long, narrow pedicle, and congestion and engorgement of the spleen is inevitable. A more serious complication is torsion; this leads to strangulation of the spleen—a serious acute abdominal catastrophe. The symptoms of wandering spleen in the uncomplicated state are those of vague abdominal discomfort and flatulent dyspepsia. A floating or wandering spleen is best treated by splenectomy. This is usually safe, and is then an absolute cure. In certain cases the spleen can be fixed into its normal position, the operation being termed 'splenopexy.' This is done by preparing an extra peritoneal bed for the spleen and slipping the latter into it through a hole in the parietal peritoneum. If this gives an unsatisfactory result, subsequent splenectomy may be fraught with great danger from hæmorrhage. The diagnosis is made by palpating the organ with its characteristic notched anterior border. In cases of torsion with which is associated thrombosis of the splenic vessels, the symptoms are those of agonizing abdominal pain, vomiting and generalized rigidity. Prostration is

marked. A diagnosis is not usually made until the abdomen is opened for an exploratory laparotomy.

Enlargement of the Spleen.—Splenomegaly or enlargement of the spleen is a concomitant of most of the splenic affections. The condition is appreciated from the following signs. The tumour is in the long axis of the spleen, *i.e.* the enlargement follows the line of the tenth left rib, and an enormously enlarged spleen will finally arrive in the right iliac fossa. The tumour moves on respiration. It is dull to percussion, but a resonant note is found behind it in the flank (*i.e.* the colonic resonance). The final and most characteristic feature is the fact that a deep notch, or sometimes notches, is found on the anterior or superior edge.

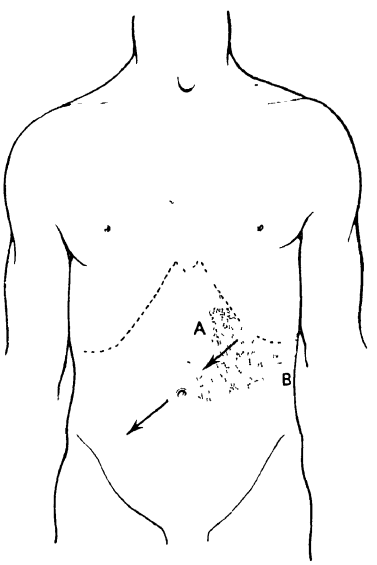

FIG. 867.—DIAGRAM TO CONTRAST AN ENLARGED SPLEEN WITH AN ENLARGED LEFT KIDNEY

A, Notch on anterior border, B, area of resonance behind tumour. Arrows, direction of enlargement

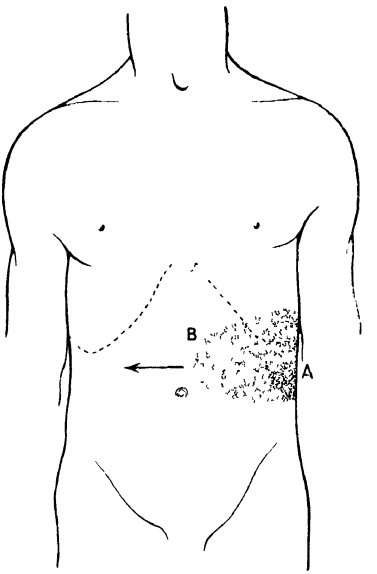

FIG. 868.—DIAGRAM SHOWING AN ENLARGED LEFT KIDNEY.

A, Dull in flanks, B, resonant area. Arrow, direction of enlargement

The condition has to be differentiated from an enlarged left kidney, a tumour (carcinoma) of the stomach, or of the splenic flexure of the colon, a cyst of the pancreas or omentum, or great enlargement of the left lobe of the liver (Figs. 867 and 868). Careful examination will usually render a differential diagnosis easy. Enlargement of the spleen may be enormous, the organ finally coming to rest in the right iliac fossa, where the pelvis supports its weight. The larger the spleen the

more dangerous is the operation for its removal (other things being equal), and therefore the student should always be on the lookout for minor aberrations. The size of the spleen has long been known, and ancient Greek runners whose speed was impeded by an enlarged spleen (malarial) submitted to treatment for the condition.

Surgical Affections of the Spleen.—These may be listed as follows; a more detailed description of the more important will then be given:

1. **Rupture of the Spleen :**
   - Traumatic rupture.
   - Pathological rupture.
   - Non-traumatic rupture of normal spleen (very rare).
   - Rupture of a splenic aneurism.

2. **Wandering Spleen :**
   - Symptomless.
   - With symptoms.
   - With complications.
   - With cysts of the spleen (Fig. 869).

3. **Infection—Bacterial :**
   - Typhoid.
   - Tubercle.
   - Syphilis.
   - In septicæmia.
   - In amyloid disease.

   Infection—Parasitic :
   - Malaria.
   - Kala-azar.
   - Hydatid.
   - Spirochæta ictero-hæmorrhagica.
   - Egyptian splenomegaly—bilharzia.

4. **Neoplasms :**
   - Primary sarcoma.
   - Lympho-sarcoma.
   - Angioma.
   - Endothelioma (Gaucher's disease).

5. **Blood Dyscrasias, and Diseases of Doubtful or Unknown Ætiology :**
   - Splenic ænemia.
   - Von Jaksch's anæmia.
   - Myelogenous leukæmia.
   - Lymphatic leukæmia.
   - Pernicious anæmia.
   - Acholuric jaundice.
   - Hodgkin's disease.
   - Polycythæmia.
   - Purpura.

As a general statement it may be said that many of the above conditions, after appropriate preliminary treatments, may ultimately require splenectomy. Obviously in other cases, *e.g.* rupture, preliminary treatment will not be required. In some cases operation may be avoided, *e.g.* malarial spleen, gummatous spleen. The indications for splenectomy may be considered under three heads, *viz.*:

(1) **Absolute Indications.**—Where no doubt exists, the general consensus of opinion being in favour of splenectomy, successful operation is usually a cure.

(2) **Relative Indications.**—Here much doubt may exist as to the value of the operation, which at best is only palliative; the operation may tend to check further progress of the disease.

(3) **Contra-indications.** — Here splenectomy is definitely valueless, and may additionally be harmful. The diseases are now re-listed under these headings. The relative mortality is included, as of course the operation may be absolutely indicated in a condition where the mortality is high, splenectomy, however, being the patient's only chance

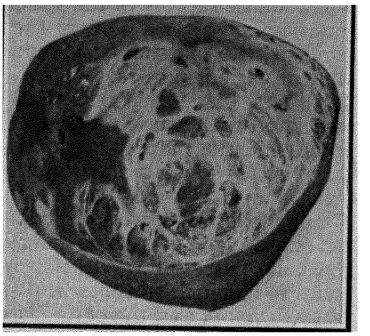

FIG 869.—LARGE CYST OF SPLEEN SEEN ON SECTION.

Absolute Indications.	*Relative Indications*	*Contra-indications*
(1) Ruptured spleen, all forms, 10 to 20 per cent	Splenic abscess	Pernicious anæmia
(2) Wandering spleen with symptoms, 4 per cent, with complications, 40 per cent	Splenic anæmia (indicated in the early stages), 10 per cent	Leukæmia myeloid and lymphatic
(3) Idiopathic cysts of spleen, 15 per cent	—	Amyloid disease.
(4) Hydatid cyst, 15 per cent	Syphilis (a very rare indication)	—
(5) Egyptian splenomegaly, 12 per cent	Malaria (a very rare indication).	—
(6) Neoplasms: sarcoma, angioma, endothelioma, 20 per cent	—	Lymphosarcoma (use X-ray therapy).
(7) Acholuric jaundice, 4 per cent	—	Hodgkin's disease (use X-ray therapy).
(8) Thrombocytopenic purpura, 8 per cent	—	Non-thrombocytopenic purpura
(9) Von Jaksch's anæmia	—	—

1. **Ruptured Spleen.**—Rupture of the spleen may be of traumatic origin or due to disease in the spleen. The former, namely traumatic

rupture, is infinitely the commoner. Spontaneous rupture of a normal spleen is exceedingly rare. When splenomegaly due to malaria, typhoid, or blood dyscrasias, is present, spontaneous rupture, due to minor injuries, is not rare. Obviously this liability is much greater in the tropics.

Traumatic rupture of the spleen appears to be on the increase in this country, and after a blow in the left chest or abdomen, or a run-over accident, its possibility should never be overlooked. Two main clinical varieties occur:

(1) **The Classical Type.**—Following the injury, which usually is associated with much shock, the signs of intra-peritoneal hæmorrhage occur, and the patient becomes rapidly worse, soon dying of hæmorrhage unless saved by laparotomy and splenectomy.

(2) **The Delayed Type.**—Following the injury the patient suffers from a moderate degree of shock, which typically responds to the usual measures. There is some pain in the left hypochondrium, but this gradually passes off. After an interval, which varies from forty-eight hours to as much as three weeks, the signs of intra-peritoneal hæmorrhage develop, and the case, like type 1, becomes of grave urgency.

It will be seen that while type 1 is the more immediately dangerous, type 2 is the more insidious. In over 30 per cent. of the type 2 cases the patient has been discharged back home, or to work after the causative injury and before the onset of the hæmorrhage. The student should be on the watch for left subcostal pain, often with referred areas to the left shoulder in these cases. As ruptured spleen is common only in young healthy adults, such injuries must always be carefully treated. In about 10 per cent. of cases other viscera are also damaged. A typical case can be considered under three stages:

(1) The stage of shock.
(2) The stage of recovery from shock but commencing hæmorrhage.
(3) The stage of advanced hæmorrhage.

After a typical injury, *e.g.* falls from a height, run-over accidents, blows with cricket balls, the only common differential diagnoses are:

(1) Fractures of left ribs.
(2) Left-sided hæmothorax.
(3) Active collapse of left lung.
(4) Rupture of left kidney (complete rupture without hæmaturia).

Careful examination will usually serve to differentiate these conditions.

Special Signs and Symptoms.—Those of shock need not be mentioned here. The features of internal hæmorrhage—rapid pulse, restlessness (in marked contrast with the quiet attitude of shock), air hunger, pain, pallor, and thirst—are classical, but not indicative of the cause of the hæmorrhage. The signs which point to the spleen as the cause are upper abdominal pain, tenderness and rigidity. Shoulder pain (Kehr's sign) is frequently present. The area of dullness and rigidity may spread if the condition is left, the blood pouring into the left iliac fossa, and later the pelvis and right iliac fossa. Ballance's sign,

viz. fixed dullness in the left flank and shifting dullness in the right flank, is not to be waited for. It indicates a very advanced state.

Treatment.—In these cases treatment is urgent laparotomy and splenectomy. In all cases an assistant should arrange for a transfusion, but this should never be waited for, the surgeon's first duty being to stop the hæmorrhage. Operation should be undertaken however hopeless the case appears, as it offers the only chance of recovery. The pulse improves the moment the splenic vessels are secured. The operator should examine for evidence of injury to other organs, *viz.* the liver, duodenal-jejunal flexure and kidney. The usual operation is splenectomy; in a few cases the spleen can be sutured, but this may be dangerous. Where splenectomy proves difficult owing to adhesions, or its size, a combination of suturing and gauze plugging may be employed.

Infections of the Spleen.—Most of these need no comment, their treatment being entirely in the province of the physician. Occasionally an abscess localizes in the spleen and splenectomy may be indicated; this is more common in tropical climates. An abscess may follow enteric fever or an infected embolus, or a cyst may suppurate. Fever, abdominal tenderness and leucocytosis should suggest the condition.

Splenectomy may be indicated in malarial enlargement of the spleen (after thorough anti-malarial treatment has been tried). The rational treatment is the removal of a spleen which is highly liable to rupture and also the removal of a reservoir of parasites.

Neoplasms.—The spleen is a very rare site for neoplastic affections. Primary growths are uncommon and, what seems more remarkable, secondary metastases are even more rare. The spleen thus stands in these respects in sharp contradistinction to the liver. The prognosis in sarcoma of the spleen is very poor. The majority of cases die within eighteen months. Endothelioma of the spleen, or Gaucher's disease, is a condition characterized by enormous enlargement of the spleen of a very chronic type. There is an associated anæmia and discoloration of the hands and face, especially of the conjunctiva.

Splenic Anæmia.—A comprehensive account of this condition will not be given here. Its main features may be summarized as a disease characterized by splenic enlargement and secondary anæmia running a progressive course. Later hepatic fibrosis (cirrhosis) sets in, and hæmorrhages from œsophageal varices are not uncommon. The disease usually starts in early adult life. Its course extends over some years, seldom more than ten, and it has a uniformly fatal ending. No medical treatment is of any real value, and radiation therapy is of doubtful utility. Splenectomy is of definite benefit in the early stages, and there is evidence that the course of the disease is long delayed, if not arrested. In the later stages, when the liver is enlarged, splenectomy is of doubtful value, and the mortality, which is low in the early case, is very high in the later one.

Purpura.—Purpura is the name given to a syndrome due to many causes, but characterized by numerous capillary hæmorrhages in the skin and mucous membranes The condition may be latent or mani-

fest. If the condition is latent and it is desired to demonstrate it, the tourniquet test may be tried. A tourniquet is fastened tightly round the patient's limb, and left in position from one to three minutes. Its removal is followed by a crop of petechial hæmorrhages, *i.e.* a purpuric eruption. This constitutes a positive tourniquet test. The rash, when on the limbs, affects the extensor surfaces. The condition has to be differentiated from scarlet fever, measles, and flea bites. The rashes which occur in septicæmia are true purpuric ones, and therefore do not really enter the differential diagnosis.

Purpura is thus of surgical interest from aspects of diagnosis, prognosis, and treatment.

Purpura in Diagnosis.—Purpura is usually considered in two main varieties:

(1) **Primary or Idiopathic Purpura :**

(*a*) *Hæmorrhagic Purpura :*

P. simplex.
P. hæmorrhagica.
P. fulminans.

(*b*) *Anaphylactoid Purpura* ·

P. rheumatica.
Henoch's purpura.

(2) **Secondary or Symptomatic Purpura :**

Infective :

Endocarditis.
Septicæmia.
Scarlet fever.
Leukæmia.
Scurvy.
Drug eruptions.
Severe jaundice.

The above list is not meant to be absolutely inclusive, but to indicate the main possibilities.

In **Diagnosis** purpura rheumatica (Schonlein's disease) has to be separated from acute infective arthritis. The occurrence of rashes may elucidate the diagnosis. Henoch's purpura may give symptoms suggestive of an acute intussusception, and, indeed, an intussusception following the submucous hæmorrhages in the intestines may occur. Usually the patient is older than the common age for acute intussusception, and the presence of purpuric spots on the skin will suggest Henoch's purpura.

In **Prognosis** the incidence of purpura is important. In septicæmias and the infective conditions purpura is usually of grave import. Purpura in jaundice is a warning to the surgeon to take careful steps to prevent bleeding at any operation such as laparotomy (*e.g.* pre-operative calcium, hæmoplastin, ascorbic acid and transfusions).

Purpura from the Aspects of Treatment.—Purpura calls for surgical aid in certain of its manifestations. All the primary purpuræ in their

acute states are benefited by transfusion. Later the condition should be investigated to consider the value of splenectomy. In cases of purpura simplex this will be unnecessary. In the other two cases, if the platelet count is low, splenectomy should be performed. Splenectomy must never be attempted during an acute exacerbation. It is valueless, of course, in the secondary purpuras.

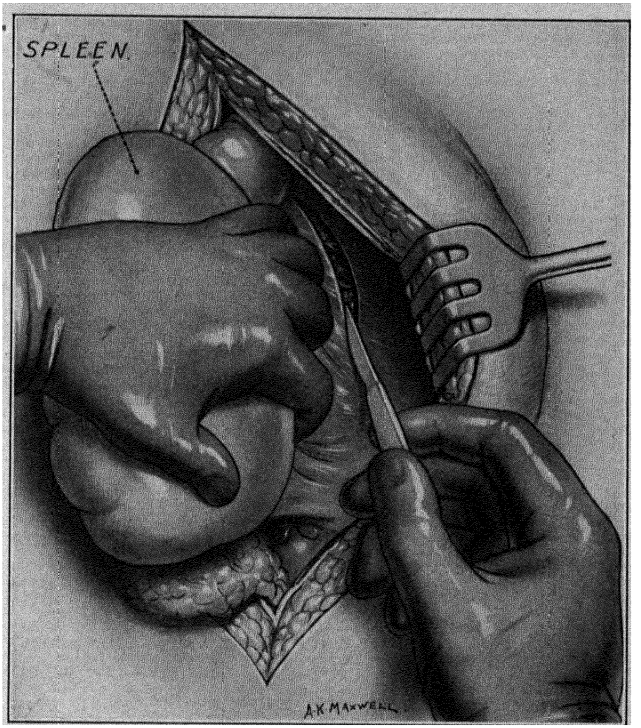

FIG 870.—SPLENECTOMY DIVISION OF THE PERITONEUM ON THE OUTER SIDE OF THE PEDICLE

Acholuric Jaundice.—This disease is of considerable surgical interest. It is frequently congenital and familial in origin, though spontaneous adult cases occur. The disease consists of slight jaundice with absence of bile from the urine and a normal bile content in the fæces. The essential factor is excessive fragility of the red blood cells. These are readily destroyed by the spleen, which is usually enlarged. There may be few symptoms at first, though the jaundice may be obvious. A special characteristic of this condition is the tendency to form pure pigmented gall-stones. These may be definite pigment stones, or the

whole bile may be thick with pigment particles, the condition being termed 'biliary mud.' Acholuric jaundice is one of the rare conditions where stones can form primarily in the ducts rather than in the gall-bladder. That this can happen is a point of considerable practical importance when operative treatment for these stones is contemplated.

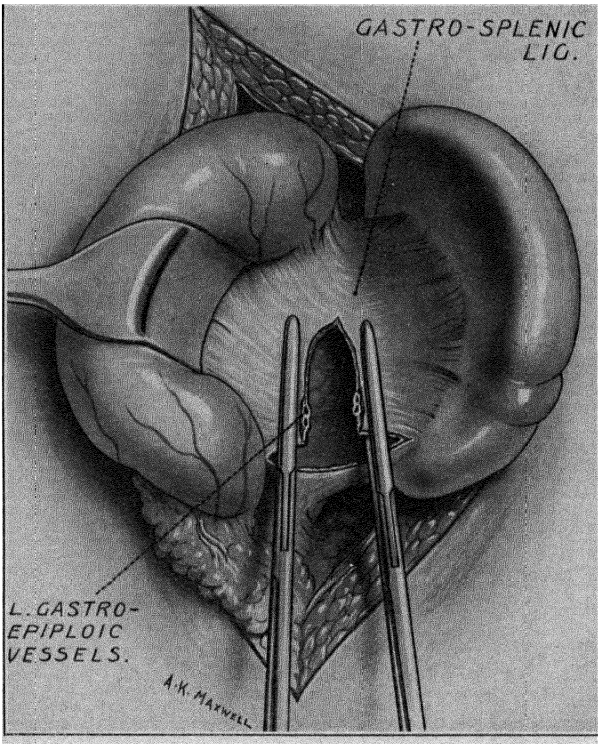

FIG 871.—SPLENECTOMY DIVISION OF THE GASTRO-SPLENIC LIGAMENT

During the course of the disease crises occur which may be due to excessive blood destruction (a form of protein shock), or to biliary obstruction by stones, or both.

Treatment.—During a crisis the treatment is entirely symptomatic. The curative treatment during an interval is splenectomy. If this is undertaken early the results are extremely gratifying. Jaundice disappears promptly, and there is great improvement in the anæmia and general well-being. It should be undertaken early, and if possible before stones have developed. At splenectomy the condition of the

biliary passages should be investigated. At a later date cholecystectomy may be required or cholecystostomy or choledochostomy.

Von Jaksch's Anæmia.—This condition essentially resembles splenic anæmia, but differs from it in occurring in children three to five years old, and in its improved response to splenectomy. The anæmia is very profound, and the splenic tumour may be enormous. The lymphatic glands may also be enlarged. The cause of the condition

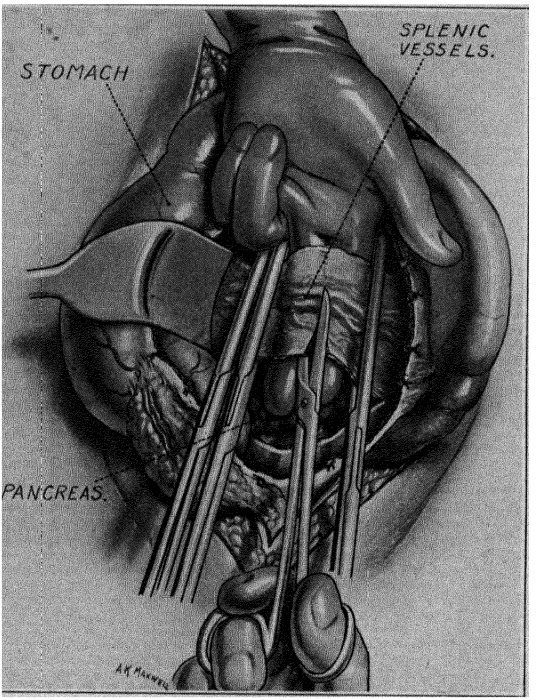

FIG. 872.—SPLENECTOMY. DIVISION OF THE TRUE PEDICLE CONTAINING THE SPLENIC VESSELS

is quite unknown. The treatment, after a preliminary medical period, is splenectomy.

The Technique of Splenectomy.—A free abdominal incision should be made, a left median, left transrectus, or left subcostal incision being the most frequently used. Where very wide access is required, a Perthes incision, where the rectus muscle is stitched to its sheath and then transversely divided at a tendinous intersection, may be combined with a paramedian incision. The spleen and other abdominal viscera are examined. The spleen may be irremovable if numerous

adhesions are present. To attempt removal in these cases is to invite fatal hæmorrhage. Minor adhesions are broken down and the spleen delivered. Oozing is controlled by hot packs. The spleen is then separated from the stomach by clamping and cutting the gastro-splenic omentum; care is taken not to damage the vasa brevia to the stomach (Figs. 870 and 871). The spleen is then rotated medially and the posterior peritoneal fold of the lieno-renal ligament divided. This further mobilizes the organ.

The Vascular Relations of the Spleen.

The tail of the pancreas is pushed away with gauze and the main pedicle ligatured securely and divided (Figs. 872 and 873). The

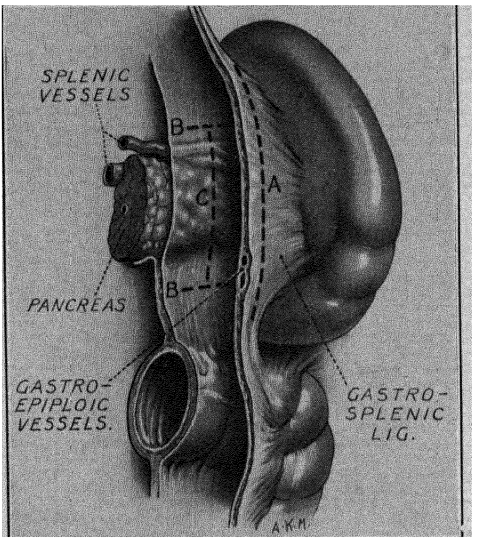

FIG 873.—DRAWING SHOWING THE TWO PEDICLES WHICH REQUIRE TO BE CLAMPED AND DIVIDED IN SPLENECTOMY

important post-operative complications are shock, hæmorrhage, local fat necrosis from pancreatic injury, and pleurisy and pneumonia.

The Surgery of the Adrenal Glands.

During recent years considerable research work has been accomplished dealing with the adrenal glands. In this country the names of Broster and Vines must be mentioned in this connection.

Tumours may occur either in the cortex or the medulla of the gland. Those occurring in the cortex give rise to sex precocity in children and virilism and hirsutism in the adult. Females are more

commonly affected, and there is a trend towards masculine characteristics.

It may be said that cortical tumours, or hyperplasia, give rise to endocrine disturbances of three varieties: (1) hypertension; (2) adrenal insufficiency if the tumour is bilateral; (3) a

This syndrome may be defined as a condition in which secondary male sex characters appear in the female. At the same time there is a retrogression of the primary and secondary sex characters and their functions. There is an appearance of hair according to the male pattern and distribution (Fig. 874). There is often a moustache and a beard, or 'mutton chop' whiskers. Enlargement of the clitoris and deepening of the voice frequently occur. The whole bodily contour approximates towards the male (Fig. 875). The final picture of the syndrome will be determined by the type of lesion and the age of onset (Fig. 876). The lesion, whether tumour or hyperplasia, is dependent on a positive reaction in the cortical cells to the Ponceau-Fuchain stain.

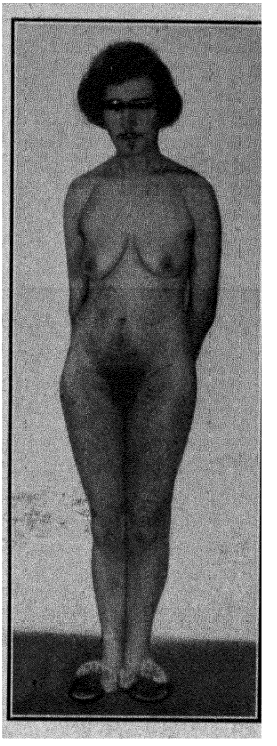

FIG 874.—POST-PUBERTAL VIRILISM (MR BROSTER'S CASE)

A very thorough biochemical investigation is required in these cases. A routine X-ray examination of the pituitary fossa should be carried out; it is commonly small in these cases. An intravenous pyelogram should be taken to ascertain if there is any evidence of adrenal tumour causing deformation of the renal pelvis.

In the majority of cases, after complete investigation it is impossible to be sure which adrenal is the most affected. Exploratory laparotomy is therefore carried out and the adrenals palpated, the larger one being the one to be removed. Laparotomy also has the added advantage of allowing the surgeon to inspect the uterus and ovaries of the patient, and thus detect any abnormalities. Ten days or so after the laparotomy the enlarged adrenal is removed through a high kidney route by fracturing the last rib. The operation can be conveniently carried out under gas-and-oxygen anæsthesia. The surgeon has to work in a confined space, and bleeding may be troublesome.

Tumours of the medulla may be classified as—

(1) Neuroblastomas, which are highly malignant tumours occurring in infancy.

* 'Adrenal Cortex,' by Broster and Vines (H. K. Lewis and Co.), 'Adrenogenital Syndrome,' by L. R. Broster (*Lancet*, vol. i., 1934, p. 830).

(2) Neurocytomas, which vary in their malignancy, but metastasize readily in bones and give rise to a profound anæmia.

(3) Gangliomas.

(4) Paraganglioma s which are derived from the chromaffin cells. These tumours are rare, and usually occur in adults, giving rise to permanent or paroxysmal hypertension; they may be removed by adrenalectomy, and good results are obtained.

As so often happens, now that the operation of adrenalectomy has been perfected it has been used for numerous other conditions with the hope that some benefit might ensue. It may be definitely stated, however, that adrenalectomy is valueless in epilepsy. It may be beneficial in cases of obliterative arteritis and in Raynaud's disease, but time alone must be the judge, as immediate good results may not be permanent. Bilateral adrenal denervation in two stages is being carried out in cases of hypertension, chiefly in America In all cases of malignant tumour, unless diagnosed very early, the prognosis is very bad.



FIG 875.—POST-PUBERTAL VIRILISM (MR BROSTER'S CASE)

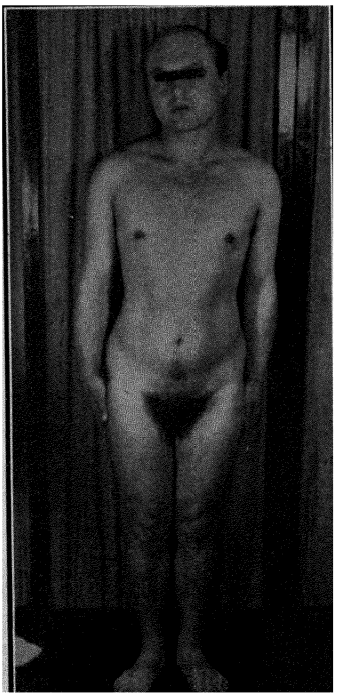

FIG 876 — ADRENAL PSEUDO-HERMAPHRODITISM (MR BROSTER'S CASE)

Pre-pubertal with primary amenorrhœa Both adrenals greatly enlarged

CHAPTER XXXVIII.

HERNIA.

By the term **Hernia** is meant the protrusion of some viscus from its normal situation through an opening in the walls of the cavity within which it is contained. This may affect not only the abdominal viscera, but also the brain and lungs, giving rise to conditions which have been already described. The present chapter is limited to hernia as met with in connection with the abdomen.

The most common **Situations** at which hernia occurs are those spots where the parietes are weakened by the transmission of such structures as the spermatic cord and round ligament (inguinal hernia), or at the entrance of the crural canal, where the main vessels of the leg pass under Poupart's ligament (femoral hernia), or at the umbilicus (umbilical hernia). Hernial protrusions may, however, develop through the obturator foramen, sciatic notch, the diaphragm, and in various other situations.

Ætiology.—*Congenital Causes* are rather predisposing than exciting in nature, and must be looked for amongst the many malformations and conditions of imperfect development to which the abdominal parietes and contents are liable. The following are the most important. (*a*) The non-obliteration of the funicular process of peritoneum, which in the male precedes and accompanies the testicle on its progress downwards from the abdominal cavity to the scrotum, and in the female passes along the round ligament. The so-called congenital inguinal hernia results from this, although it must be remembered that the rupture does not necessarily show itself at birth, and, indeed, may not appear till after puberty. It is probable that most cases of acquired oblique inguinal hernia are in reality congenital in origin (Hamilton Russell). In females under the age of twenty-five, hernia into the canal of Nuck, as this peritoneal tube is called, is the most frequent variety met with. (*b*) The late descent of the testis, whether it finds its way into the scrotum or not, is usually associated with the formation of an inguinal hernia of the congenital type, or of some form of interstitial hernia. (*c*) Inherited weakness of the abdominal muscles and parietes, with unusual patency of the rings, will certainly predispose to this condition, and, moreover, there is no doubt as to the tendency of hernia to run in families. (*d*) Abnormal length of the mesentery or omentum may have some influence when other conditions are present, but *per se* can have little effect. (*e*) Congenital phimosis, by inducing forcible acts of micturition, acts as an exciting cause. (*f*) Congenital apertures occur in the linea alba or linea semilunaris, especially opposite one of the tendinous intersections in the rectus, and through these one form of ventral hernia

may develop. (*g*) The umbilicus is sometimes imperfectly developed at birth, permitting the viscera to protrude into the base of the umbilical cord (congenital umbilical hernia). (*h*) The diaphragm is also occasionally defective, allowing the stomach or other viscera to find their way into the thoracic cavity.

Acquired Causes.—Hernia may result from any condition which tends either to weaken the abdominal parietes or to increase the intra-abdominal pressure. Thus (1) it may be *post-operative*, resulting from the imperfect repair of the abdominal wall after laparotomy. In this respect a badly performed Battle's incision, in which the nerve supply to the rectus muscle is damaged, gives rise to far more post-operative herniæ than a paramedian incision. (2) It may be the outcome of *direct traumatism*, and may then occur away from the hernial regions. If seen early, the affected area will probably show signs of injury, such as tenderness, swelling, and ecchymosis, but it is unusual for an ordinary complete hernia to develop after injury or severe strain, unless a preformed sac is present, and then immediate strangulation is not an uncommon sequence; apart from this, the hernia, if seen soon after the alleged accident, is imperfectly developed, and in the bubonocele stage. (3) Much more frequently hernia is due to *chronic strain*, such as occupations which involve lifting heavy weights. Prolonged and severe bronchitis, and frequent straining to pass water in cases of enlarged prostate or stricture, may determine the development of a hernia; chronic constipation, too, is a frequent factor in its production, especially if the patient makes use of a closet with a high seat, whereby the inguinal canals are left unprotected; a patient with weak and bulging inguinal regions may with advantage use a low commode. (4) *Relaxation of the abdominal parietes* also favours hernia, especially if associated with or followed by severe straining. Thus pregnancy brings about a stretching of the wall, especially if frequently repeated and followed by imperfect involution; and parturition determines the development of hernia, either in the crural region or through the linea alba. In old and weakly people the abdominal wall becomes relaxed and atonic, and an additional cause may be found in the slipping downwards of the mesenteric attachment, causing the intestines to occupy the lower part of the abdomen rather than the upper. (5) *Obesity* is also a predisposing factor to hernia, the accumulated fat being deposited in the omentum, mesentery, and subperitoneal tissue, thus increasing the intra-abdominal tension. Sudden removal of this fat, due to acute illness, may leave the inguinal canals unguarded, and chronic strain of any type may then determine the development of hernia.

Structure.—A hernia consists of a sac and its contents, the sac being formed of peritoneum, perhaps thickened by additional coverings, derived from the abdominal parietes, and the contents being the protruded viscera.

The **sac,** or peritoneal investment of an acquired hernia, is in the early stages funnel-shaped, small, and thin; as the rupture increases in size it becomes larger, partly by stretching, and partly by the drawing down of fresh membrane from the neighbourhood. Occasionally it

stretches irregularly, and becomes sacculated or even occasionally hour-glass-shaped. The sac is described as consisting of two portions—the neck and the fundus. The *neck*, sometimes large and open at first, gradually becomes narrowed, and is generally thickened. The body, or *fundus*, varies much in size and shape, and may undergo considerable alterations in structure.

Inflammation results from injury or pressure, constituting a form of localized peritonitis; if of a chronic type, the sac becomes thickened and opaque, as in old irreducible herniæ. Acute or subacute inflammation may determine the formation of adhesions between the inner wall and the contained viscera, or between the opposite sides of the sac, if no other structures interpose. Natural cure of a hernia may occasionally be produced in this way by adhesions forming across the neck of the sac, or by an adherent plug of omentum occluding the communication with the peritoneal cavity. The lower portion of the sac may in a similar way be shut off from the upper, either by a band of adhesions or by a septum of adherent omentum; this isolated cavity is sometimes the seat of a serous effusion, known as a *hydrocele of a hernial sac.*

The *coverings* of the sac are indurated in old-standing cases, and matted together, especially at the neck of the sac, which is often so thickened as to constitute an important element in the production of strangulation. The opening through which the hernia protrudes becomes more or less circular, and so displaced that an oblique passage, such as the inguinal canal, becomes straight, the internal abdominal ring lying almost immediately behind the external.

Contents.—Any viscus in the abdomen may be found in the sac of a hernia, except, perhaps, the pancreas; as a rule, however, one finds only small intestine or omentum.

An *enterocele* is the name given to a hernia containing some portion of the bowel. It is at first usually reducible; but if the gut becomes adherent, either to the sac or to some other contained structure, it is rendered irreducible. It may also participate in an inflammatory condition of the sac; whilst, if irreducible, obstruction may ensue from impaction of its contents, and if its vessels are constricted strangulation supervenes. For a description of these conditions, see p. 1382. The small intestine is much more frequently involved than the large gut. The amount of bowel protruded varies from a few inches to several feet.

If omentum is found in a hernial sac, the condition is known as an *epiplocele.* As long as it remains reducible, it is likely to retain its normal texture; but when large in amount, and especially if irreducible, it becomes thickened, brawny, and matted together to such an extent as almost to constitute a solid tumour; it is often the seat of an excessive deposit of fat, and in consequence of this it may become irreducible, even when no adhesions are present. In some cases openings are found in it of sufficient size to allow the gut to pass through and become strangulated. When omentum and bowel are present in the same sac, the condition is known as an *entero-epiplocele.*

The *Cæcum* sometimes occupies a hernial sac, either in aggravated or large herniæ, or in children with congenital hernia; it has even been

found in a hernia on the left side. Since the cæcum has generally a complete serous covering and usually a mesentery, it is freely movable, and may pass into a hernial sac in the same way as any other mobile part of the intestine.

The *Vermiform Appendix* is occasionally found in a hernial sac on the right side. It is rarely free, but generally fixed by adhesions and irreducible (Fig 877) The hernia is more painful than usual, and on palpation the appendix can sometimes be felt enlarged and tender, pressure causing pain referred to the umbilicus. The patient is likely to give a history of recurrent attacks of inflammation in the sac. In rare cases strangulation, sometimes of a retrograde type, occurs (Fig. 878).



FIG 877.—ADHERENT APPENDIX IN A HERNIAL SAC

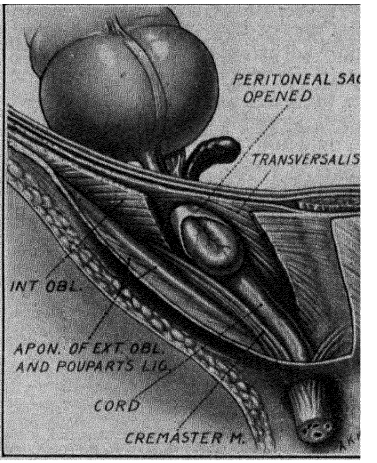

FIG 878.—RETROGRADE STRANGULATION OF THE APPENDIX IN A HERNIAL SAC

The *Bladder* may be associated with a hernial sac in the inguinal or femoral region, the former position being the more common (Fig. 879). Herniæ of the bladder may be divided into three varieties, according to their position in the peritoneum: (1) Extraperitoneal, (2) paraperitoneal, and (3) intraperitoneal. Such herniæ may be primary or secondary, the primary are of two types, extraperitoneal or paraperitoneal; while the secondary are intraperitoneal or paraperitoneal.

In the *extraperitoneal* form the anterior or lateral extraperitoneal surface of the bladder enters the inguinal or crural canal (Fig. 880). Fortunately, this is the rarest type, as in it the bladder is easily mistaken for the hernial sac and opened.

In the *paraperitoneal* variety the bladder always lies on the inner side of the hernial sac (Figs. 880 and 881). The serous covering of the superior surface of the bladder forms the inner wall of the peritoneal

sac. It is the most common of the three varieties, and the easiest to treat successfully.

The *intraperitoneal* hernia of the bladder is rare and usually secondary in origin. It practically always occurs in the inguinal region. There is a complete hernial sac which is external to the deep epigastric artery, the upper and posterior part of the bladder enters this sac, and, in addition, loops of small intestine and omentum are frequently found (Fig. 882). Occasionally, a diverticulum of the bladder may

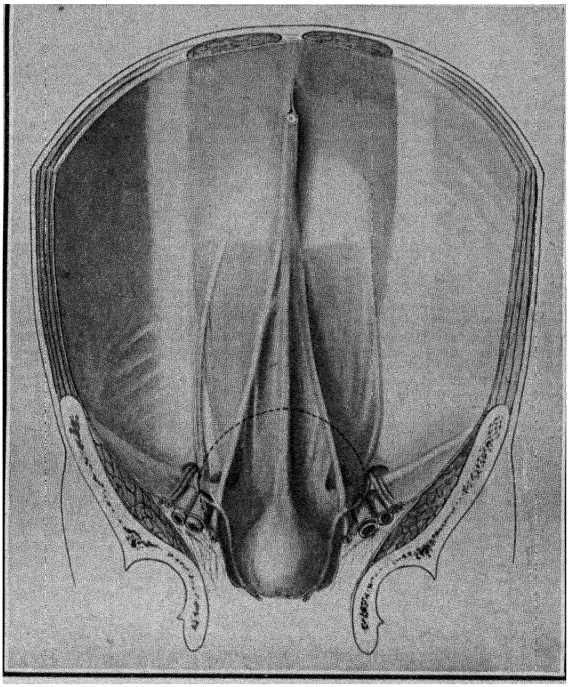

FIG. 879.—DIAGRAM OF POSTERIOR SURFACE OF ANTERIOR ABDOMINAL WALL, SHOWING RELATION OF THE BLADDER TO THE HERNIAL ORIFICES

become adherent to a hernial sac, and is then very liable to be laid open during an operation for the radical cure. If such an accident should happen the saccule should be excised, and the opening at once closed by sutures, which should not penetrate the mucous membrane. Failure to recognize this accident is followed by urinary extravasation, possibly intraperitoneal, and will require prompt treatment if a fatal issue is to be avoided. The wound must be reopened, the gap in the bladder wall found and closed, and effective drainage provided.

The *Ovary* and *Fallopian Tube* are occasionally found in an inguinal

hernia, more often in a child than in an adult, and give rise to an irreducible swelling, pressure on which causes a sickening pain.

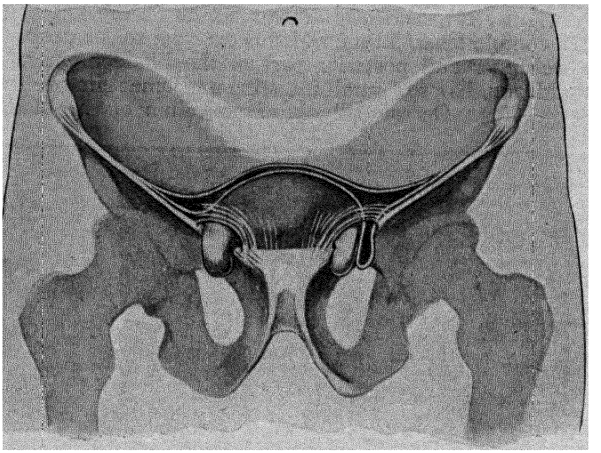

FIG 880.—DIAGRAM SHOWING PARAPERITONEAL HERNIA OF THE BLADDER ON THE LEFT SIDE AND AN EXTRAPERITONEAL HERNIA ON THE RIGHT

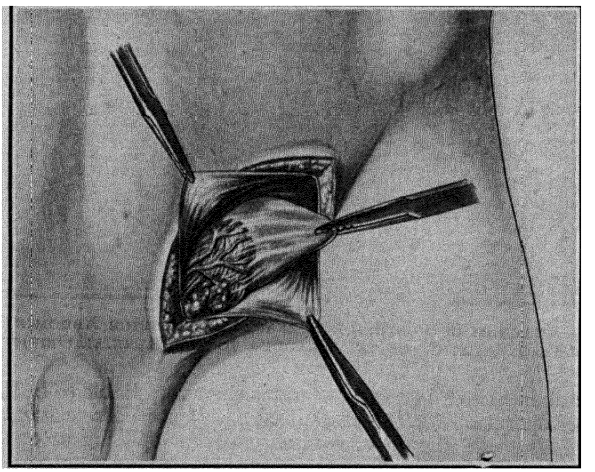

FIG. 881.—PARAPERITONEAL HERNIA OF THE BLADDER SEEN AT OPERATION ON THE INNER SIDE OF AN INGUINAL HERNIA SAC.

Signs and Symptoms.—The characteristic features whereby a hernial protrusion is recognized consist in the presence of a rounded or pyri-

form swelling in one of the normal or abnormal situations already mentioned, which increases in size when the patient stands, coughs, or strains, having, as it is termed, 'an impulse on coughing.' If intestine is present, it may be possible to obtain a tympanitic note on percussion, whilst the tumour is tense and rounded, and on pressure slips back into the abdomen with a distinct gurgle. An enterocele often gives rise to dyspeptic phenomena, and perhaps to colicky pains. An omental hernia feels soft and doughy, has a less distinct impulse,

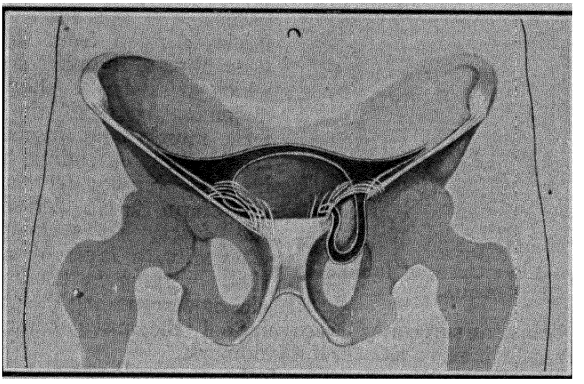

FIG. 882.—INTRAPERITONEAL HERNIA OF THE BLADDER

or even none, on coughing, and is replaced without a gurgle; it is dull on percussion.

The **Treatment** of hernia, whether palliative by means of trusses, or radical by means of operation, differs so greatly in the various forms that it will be better to discuss each one separately.

Special Forms of Hernia.

Inguinal Hernia.—The term **inguinal hernia** is limited to those conditions in which a protrusion occurs into the inguinal canal, and if allowed to progress, finally makes its way through the external abdominal ring. If it extends into the scrotum, it is termed *complete*, or scrotal, whilst if it does not pass beyond the external abdominal ring, it is known as a *bubonocele*, or incomplete inguinal hernia. The neck is always in relation with the deep epigastric artery, and the structures of the cord are either spread out over the sac or are in close proximity to it. In the early stages, the pubic spine can be felt to the outer side of the neck of the sac, but as it increases in size it lies over the spine, which can be felt only after pushing the hernia upwards and inwards.

Two main **varieties** of inguinal hernia are described, *viz.* the oblique and the direct.

An **Oblique Inguinal Hernia** (Fig. 883) is one which passes down the whole length of the inguinal canal, entering at the internal and

emerging at the external abdominal ring, the deep epigastric artery is thus placed to the inner side of the neck. During its passage through the canal every form of oblique hernia pushes before it and becomes covered by structures representing the various layers of the abdominal parietes. Hence in cutting down on such a sac the surgeon will divide, in addition to the skin and subcutaneous tissues, (*a*) the inter-columnar fascia, derived from the transverse fibres of the external oblique which pass across the external abdominal ring, (*b*) the cremasteric muscle and fascia, representing and extending from the internal oblique, (*c*) the infundibuliform fascia derived from the fascia transversalis; and (*d*) finally, a layer of subserous tissue varying in thickness and closely surrounding the peritoneal sac. Probably the surgeon will recognize only the muscular fibres of the cremaster, which serve as a useful landmark.

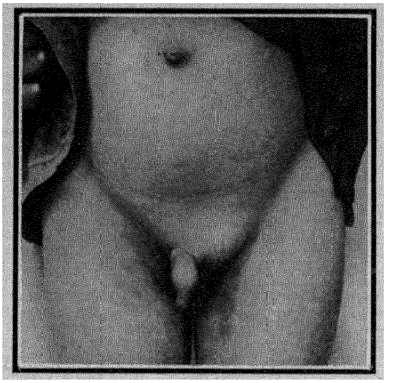

FIG. 883.—LEFT OBLIQUE INGUINAL HERNIA

There are three different forms of oblique inguinal hernia, *viz.* the acquired, the congenital, and the infantile or encysted.

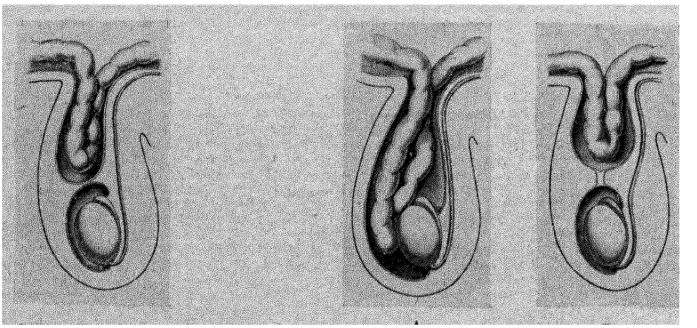

FIG. 884.—DIAGRAM OF ACQUIRED INGUINAL HERNIA, SHOWING SEROUS SAC WITH INTESTINE COMING DOWN TO THE TOP OF THE TESTIS

A B

FIG. 885.—CONGENITAL INGUINAL HERNIA.

A, Vaginal variety; B, funicular type.

1. An *Acquired Inguinal Hernia* (Fig. 884) is one in which the sac consists entirely of peritoneum protruded from within the abdomen. It gradually increases in size, and finds its way along the cord to the scrotum. The sac usually extends as far as the head of the epididy-

mis, but if of large size it may overlap the testicle, which lies behind it. The structures of the cord are frequently spread out over the sac. In old-standing cases the internal ring is dragged downwards and inwards and often lies directly behind the outer. Even in the earliest stages the sac is distinctly flask-shaped, suggesting that the condition is in reality of congenital origin.

2. *Congenital Inguinal Hernia* (Fig 885) is due to non-closure of the funicular process of peritoneum, which passes down to the scrotum with the testicle, and is usually obliterated completely except below, where it forms the tunica vaginalis. As already mentioned, the hernia does not necessarily appear in infancy, its occurrence being often delayed until puberty, or when the patient has to undertake heavy work. This form of hernia is much more frequently met with on the right side

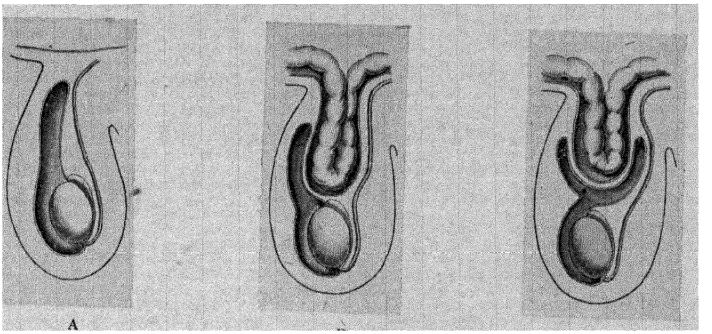

FIG. 886.—INFANTILE INGUINAL HERNIA

A, Pre-hernial condition with tunica vaginalis extending upwards to inguinal canal, B, hernial sac coming down behind tunica, C, sac invaginating the tunica vaginalis.

of the body, owing to the fact that the right testicle descends into the scrotum at a later date than the left It is always characterized by becoming complete at once, and its development may be immediately followed by acute strangulation.

When the non-obliteration is complete and the patent funicular process is continuous with the tunica vaginalis, the protruded viscera lie in contact with the testis, this is known as a *congenital vaginal hernia* (Fig. 885, A). More frequently the funicular process is patent only as far as the head of the epididymis, being shut off from the tunica vaginalis. The hernia under such circumstances exactly resembles the acquired variety, but becomes complete at once, and is termed a *congenital funicular hernia* (Fig. 885, B).

In congenital hernia the structures of the cord are usually more intimately adherent to it than in the acquired form. Phimosis is often associated with this condition in young boys.

3. The *Infantile* or *Encysted Hernia* is one in which the funicular process, although shut off from the abdominal cavity above, remains patent below, communicating with the tunica vaginalis (Fig. 886).

The real hernial sac passes down behind the open process, or invaginates it (B and C). It cannot be recognized except on operation, when the surgeon is apt to open the tunica vaginalis, which, though reaching upwards, does not communicate with the general peritoneal cavity; on removing or displacing this, the true sac of the hernia is found behind it.

A **Direct Inguinal Hernia** (Fig 887) is one which, though passing through the external abdominal ring, has only travelled through a portion of the inguinal canal; it is never congenital, and usually smaller than the oblique type, not becoming scrotal. The neck lies to the inner side of the epigastric artery (Fig. 888), which is often arched very distinctly over it, passing also along its upper wall. The hernia thus escapes through the lowest portion of the linea semilunaris, and traverses the space known as Hesselbach's triangle, which is bounded internally by the outer border of the rectus muscle, by the deep epigastric artery externally, and by Poupart's ligament below (Fig. 888). The obliterated hypogastric artery (H) passes across the space in a direction parallel to its outer border, dividing it into two parts, and according to whether the hernia protrudes through the outer or inner segment, it is known as an external or internal direct hernia (2 and 3). The spermatic cord usually lies to the outer side of a direct hernia, and its constituent elements are never spread out over the sac as in the oblique form. A direct hernia is rarely found in young people, and there is often a considerable amount of subperitoneal fatty tissue around the sac. The coverings are practically the same as in the oblique variety, although the cremasteric investment may be less complete.

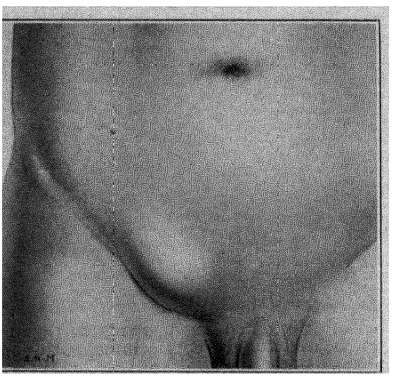

FIG. 887.—DIRECT INGUINAL HERNIA

Interstitial Hernia is the name given to an inguinal hernia which develops in some abnormal relation to the abdominal wall. Three varieties are described. (*a*) Where a sac exists between the transversalis fascia and the peritoneum (*intraparietal* form, or *properitoneal* hernia), either with or without a hernia in the usual position. This abnormal pocket of the sac is found either between the symphysis pubis and the bladder (hernia inguinalis ante-vesicalis), or it extends outwards towards the iliac fossa (hernia inguinalis intra-iliaca) As no external swelling is caused by this condition, it is usually impossible to recognize its existence prior to operation, occasionally it is the cause of a continuation of the symptoms of strangulation, when apparently successful taxis has been performed owing to the strangled bowel having

been pushed backwards from the superficial into the deeper portion of the sac. (*b*) An abnormal sac forms between the internal and external oblique muscles (*interparietal* form), producing a swelling in the inguinal canal, covered by the external oblique aponeurosis, and gradually spreading upwards and outwards parallel with Poupart's ligament. It may be associated with late descent of the testis, the external abdominal ring being closed, so that the organ, and with it a hernia, can travel only forwards and outwards beneath the external oblique aponeurosis. Sometimes the condition is due to the existence in the sac of an ordinary oblique hernia of a more or less complete septum at the level of the external abdominal ring, formed either by adhesions or by a mass of adherent omentum. The sac is then shaped like an hour-glass, and as the usual downward course of the hernial contents is prevented the upper part of the sac yields laterally above the site of the obstruction, and passes between the muscles. (*c*) The hernia escapes as usual from the external abdominal ring, but travels outwards along Poupart's ligament, somewhat simulating a femoral hernia (*extra-parietal* variety). This form is generally associated with late descent of the testis, and a contracted state of the scrotum, so that it is easier for the hernia to pass into the thigh, and be guided by the fascia in the direction indicated.

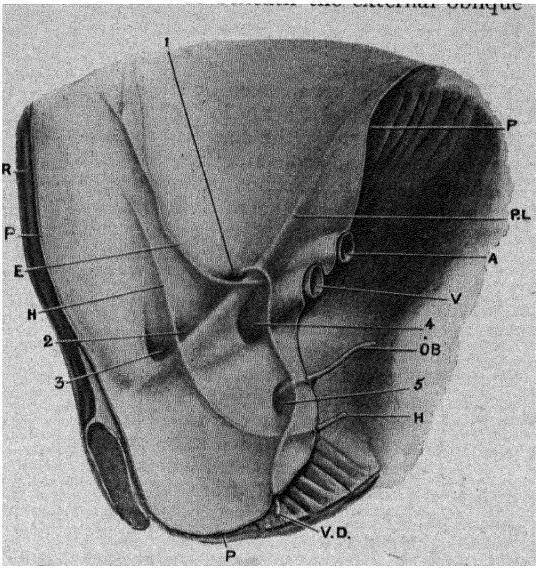

FIG 888.—ABDOMINAL WALL FROM WITHIN, TO SHOW HERNIAL APERTURES.

A, V, External iliac artery and vein; P, peritoneum, PL, Poupart's ligament; VD, vas deferens; E, epigastric vessels; R, rectus abdominis; H, obliterated hypogastric artery, OB, obturator artery; 1, internal abdominal ring; 2 and 3, sites of direct hernia in Hesselbach's triangle, 4, crural ring for femoral hernia; 5, obturator foramen and vessels

Hernia-en-Glissade.—In certain cases of inguinal hernia the bowel may be drawn down into the inguinal canal, attaching itself to, and lying outside, the actual sac. Usually it is the cæcum or the pelvic colon that is present, and the importance of recognizing the condition lies in the fact that at operation it is in most cases impossible to

separate the sac from the bowel without injury to the latter. Thus, in these cases, it is possible to excise the sac only as far as the lower attachment of the bowel, with the result that a recurrence of the rupture is more likely to occur.

The **Signs** of an inguinal hernia correspond to those already described as the general clinical features of a rupture. In the early stages, where merely a bubonocele exists, a fulness is noted in the inguinal canal, which increases when the patient coughs, it is best detected by a finger passed through the external ring into the canal. When it becomes scrotal the swelling increases in size from above downwards, and in the oblique variety is continuous with the inguinal fulness. The structures of the cord are masked by the hernia, but the testicle is to be felt more or less distinctly at the lower and back part of the swelling. When of the direct variety, the cord lies to the outer side, and although the hernia can be felt projecting from the external ring, it passes directly backwards, and there is no fulness along the course of the canal.

Inguinal hernia is the most frequent type met with in the male sex, the oblique variety being more common in the young, and the direct in elderly patients. In the female sex it is not rare, however, in girls and young nulliparous women; in such cases it is almost always congenital, passing into the labium along the canal of Nuck, but rarely attains any considerable size.

The **Diagnosis** of an inguinal hernia is a tolerably simple matter if it is uncomplicated by any other condition, it may, however, be difficult, and in old-standing cases it is often impossible to distinguish the oblique variety from the direct. The conditions for which it may be mistaken are best considered in two groups

1. Whilst the hernia is still incomplete and in the bubonocele stage, it has to be distinguished from the following. (*a*) *Encysted hydrocele* of the cord, which is recognized by its smooth globular outline and tense walls, the impulse on coughing is less distinct, and, although freely movable in the canal, the hydrocele cannot always be entirely reduced into the abdomen, whilst the characteristic gurgle of a hernia is absent, traction on the testis, moreover, fixes the tumour, and renders it immobile. The exact limitation of the upper end of the swelling, if it can be reached, is very characteristic of a hydrocele. (*b*) A *chronic abscess* originating in the abdominal parietes, or within the abdomen or pelvis, will sometimes point through the external abdominal ring. In such cases, although there is a distinct impulse on coughing, and although the swelling is reducible, it has not the definite outline and characteristic sensation of a hernia, being usually soft and fluctuant. Other evidences pointing to the existence of the original disease may also assist in determining the nature of the swelling. (*c*) *Enlarged glands in the groin* which have become adherent to the external oblique are sometimes mistaken for a hernia, owing to the fact that on coughing a distinct impulse is communicated to them; it is, however, merely heaving in nature, and not expansile, and on digital exploration of the inguinal canal the absence of a hernia may be readily ascertained. (*d*) A *testicle retained in the inguinal canal* is recognized by that side of the scrotum being empty, and on pressing the swelling testicular

sensation may be elicited. The rounded upper end of the testis can often be detected. (*e*) *Tumours consisting of fat or other tissues* are occasionally seen in the inguinal canal, but are characterized by the strict limitation of their upper border, and usually by the absence of a distinct impulse on coughing. On the other hand, as described elsewhere, a mass of fat simulating a lipoma is often present, resulting from a protrusion of the subperitoneal tissue, a hernial sac being sometimes found embedded within it. (*f*) *Hæmatocele of the cord* is recognized by a history of injury, the presence of pain and ecchymosis, and the absence of an impulse on coughing, whilst reduction is impracticable.

2. *When the hernia extends into the scrotum,* less difficulty is experienced in its diagnosis. By examination of the cord immediately outside the external abdominal ring, all purely scrotal swellings, such as hydrocele or sarcocele, are readily eliminated, since in them the cord can, in the early stages, be felt perfectly free. A varicocele can also be similarly recognized from an omental hernia by the condition of the cord in its upper region; moreover, if the patient is made to assume the recumbent posture, the swelling disappears in each instance; but if a finger is placed firmly over the inguinal canal so as to prevent any protrusion of omentum, and he is then directed to stand up, the swelling immediately reappears if it is venous in character. To the practised hand the diagnosis is never a matter of difficulty, since the enlarged veins of a varicocele and omentum are not at all alike to the touch, the veins moving freely under the finger 'like worms in a bag.' When a hernia is associated with a hydrocele or sarcocele, a little more care is necessary in order to distinguish between the two swellings.



FIG. 889.—INGUINAL TRUSS.

The **Treatment** of inguinal hernia is either palliative, by means of trusses, or radical, by means of operation, or injection with sclerosing solutions.

Palliative Treatment.—A truss is an appliance which is designed to prevent by pressure the descent of the hernia. No one form is capable of dealing with every case, and hence the truss must be selected with care, so as to suit the special needs of the particular patient. A good truss consists of a pad kept in position over the hernial aperture by a steel spring (Fig. 889), which fits the patient accurately, resting behind on the middle piece of the sacrum, and passing laterally midway between the crest of the ilium and the top of the great trochanter. If the hernia is unilateral, the spring ends on the sound side just behind the anterior superior spine, and is prolonged anteriorly into a leather thong or cross-strap, which is secured to a stud on the pad. To prevent it from slipping up, an under-strap passes from the affected side close behind the anterior superior spine along the fold of the

nates to the inner side of the thigh, being fixed finally to a second stud on the pad. The pad may be rounded or oval in shape, and usually consists of soft iron protected by cork, but polished vulcanite, wood, or an indiarubber cushion filled with air, water, or glycerine may be employed instead; it may be covered with leather, and the strength of the spring must be so adjusted as to retain the hernia under all conditions of strain to which it may be subjected, but without the use of undue force. In ordering a truss from an instrument-maker, the only measurement required is that around the body, following the line taken by the truss, and reaching in front to the symphysis pubis; it is also advisable to indicate the size of the hernia, and whether the opening of the abdominal parietes is large or small. In the earlier cases of oblique hernia the pad should rest rather over the inguinal canal than over the external abdominal ring, the object being to restore the valve-like action of the canal by approximating its sides. In a direct hernia the pad must be applied directly over the opening. It is very uncommon, though possible, for an acquired hernia to be cured in this way; but in the congenital hernia of children a cure may be confidently expected in a year or two if the mother or attendants of the child conscientiously carry out the necessary details. If the hernia is once allowed to slip down, even after six or twelve months' treatment, all the previous good will have been undone.

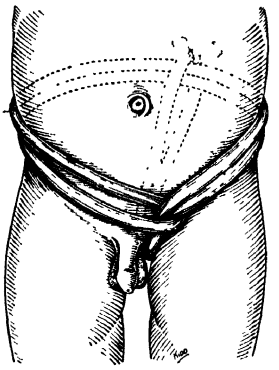

FIG 890. — WOOL TRUSS FOR TREATMENT OF LEFT INGUINAL HERNIA IN AN INFANT.

In infants, an efficient support is afforded by a skein of wool (specially known as 'fingering'), divided at one end, so that when placed round the body the cut ends of the skein can be passed through the loop, forming a knot over the inguinal canal, which acts as the pad of a truss. The cut ends are now passed under the perineum, and tied to the transverse portion behind (Fig. 890). This apparatus is changed night and morning when the child is bathed, and also, if need be, at shorter intervals, the mother being previously instructed as to how to support the hernia whilst the apparatus is being removed. In cases of double rupture in infants, an indiarubber band with two pneumatic air-pads (Fig. 891), arranged

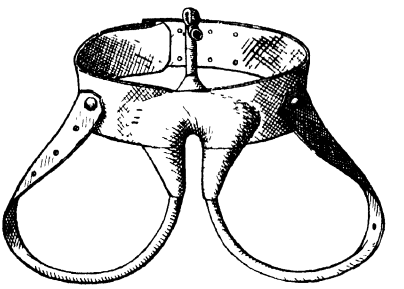

FIG 891 —INDIARUBBER BAND TRUSS, WITH AIR-PADS, FOR INFANTS

The air-pads fit around the root of the penis, and are inflated through the tube tied up in front. The under-straps fit around the child's thighs

so as to fit over the inguinal canals, and with suitable straps and studs, will often suffice, and is certainly more comfortable than a spring truss. In addition to such pressure, it is important to remove all causes of intra-abdominal tension, as by circumcision, where phimosis is present, or by regulating the bowels.

The **Radical Cure** of inguinal hernia by operation gives excellent results if the cases are carefully selected, if the technique is satisfactory, and if the after-treatment is efficient. The mortality is so small as to be negligible.

The selection of cases for an operation of this type, which is not an essential, but only a desirable means of treatment, is a matter requiring some judgment and discrimination. In an individual whose occupation does not subject him to heavy strain or exertion, and who possesses a hernia which, under ordinary circumstances, is easily commanded by a suitably applied truss, no operation is absolutely necessary, although one is perfectly justified in urging him to submit to it, since he will be thereby freed from the irksomeness of wearing a truss, and from the possible occurrence of strangulation. If, however, the subject is a labouring man, exposed to injury and strain, and who may find it difficult to provide a suitable series of trusses, the operation should always be undertaken unless distinctly contra-indicated (1) by a general inherited weakness of the abdominal muscles, (2) by a relaxed and atonic condition of the abdominal parietes, which is commonly associated in elderly people with slipping downwards of the mesenteric attachment of the intestine (enteroptosis), so that the hypogastrium obviously bulges; or (3) by such constitutional disease as precludes all unnecessary operative interference. (4) Again, in cases of very large irreducible hernia, the sudden return of considerable masses of intestine which have lain for years in the hernial sac so increases the intra-abdominal tension as to disturb the heart's action and frequently to determine recurrence locally or elsewhere; operative interference, though very desirable owing to the great risk of strangulation incurred by the patient, is often followed by very bad results, unless the patient has previously been put through a course of semi-starvation and persistent taxis in order to reduce gradually the size of the protrusion. Obviously in those cases where the hernia is secondary to such conditions as an enlarged prostate, or a stricture, it is essential to treat the primary condition first.

As to the best age at which to operate, statistics definitely prove that it is essentially an operation of adolescence, the results gradually getting worse as the age increases. Young children can often be cured by careful truss pressure, but if after a year's trial this is ineffective, operation should be undertaken, and is usually both simple and satisfactory.

The operation for the radical cure of an inguinal hernia has been gradually evolved, and is based on the recognition of two general principles, *viz.*: (i.) It is essential to remove the sac completely, or otherwise so to deal with it as to make it harmless; and (ii.) the defect in the abdominal wall must be closed in such a manner as to leave sufficient room for the due protection of the spermatic cord. In young people

the sac is the important element, and the muscular defect of less importance; as age progresses, the lesion in the wall requires more careful attention, until in old people with small direct hernias the sac may often be neglected, and attention given solely to the abdominal parietes. It must also be noted that in young people the upper part of the canal is the chief area of weakness; but in elderly people this shifts to the lower part of the canal.

Many different operations have been described, and in efficient hands they are all capable of giving good results. It must here suffice to describe carefully one typical operation, *e.g.* Bassini's, and then to note some of the modifications which have been suggested.

Bassini's operation may be described in the following stages: (1) The pubic region having been previously shaved and thoroughly purified, an incision is made in the direction of the inguinal canal and cord, about 2½ inches in length, its centre being a little above the external abdominal ring. This is deepened until the cord is reached, the superficial external pudic artery being necessarily divided *en route*; the pillars of the ring are clearly defined, and the external oblique aponeurosis is slit up in the direction of the cord. (2) The sac has now to be identified; if the hernia is one of old standing, or contains adherent omentum or intestine, it is easily recognized; but if it is thin, empty, and of recent formation, and especially in the case of a bubonocele, its identification may be a matter of some difficulty. The cremaster and other coverings of the cord are incised longitudinally, and the sac looked for and isolated with as little handling and disturbance of the parts as possible. Enlarged veins may be removed, as also fatty protrusions from the subperitoneal tissue. It is sometimes necessary to lift up the structures of the cord in order to define the sac, which is often recognized by the white convex border of the fundus. (3) If the sac is empty, it is freed from its connection with the structures of the cord without opening it, and isolated as far as or beyond the internal abdominal ring, as indicated by a collar of fatty subperitoneal tissue surrounding the neck. If the hernia is irreducible, the sac is laid open, its contents freed from adhesions, and the intestine returned into the abdomen, whilst omental tissue is removed and the stump replaced. Adhesions are carefully divided either by the finger or between ligatures; if the gut is closely adherent to the sac, it may be necessary to leave a small portion of this attached to the intestine, which is then returned. Omentum, whether adherent or not, should be removed, as the elongated fringes are very liable to contract adhesions to the abdominal parietes, which subsequently produce mischief. In removing omentum, it is not advisable to encircle a large mass with a single ligature, as it is then more difficult to replace, the vessels are less securely commanded, and a pocket or pucker may be produced, possibly leading to internal strangulation at a later date. Small portions, including one or more of the larger vessels, should be taken up one after another, and tied separately and with advantage at different levels, so as to assist in the subsequent return of the stump. The protruded mass is then cut away below the ligatures, and the stump replaced, after seeing that no bleeding point remains unsecured.

The sac, being now emptied, is isolated as far as the internal ring. (4) The neck, drawn firmly down, is transfixed as high as possible, and ligatured with sterilized catgut, so that when the sac is cut away below the ligature, the stump retracts well above the internal ring, and presents a flush surface towards the intestines. (5) The opening in the abdominal parietes is closed by a row of sutures passing through the arched fibres of the internal oblique and transversalis muscles or through the conjoined tendon on the inner side, and through Poupart's ligament on the outer, the stitches being all placed *behind* the cord. To effect this, the cord is drawn up out of the wound and held aside by a retractor (Fig. 892), whilst the divided margins of the external oblique aponeurosis are grasped by pressure forceps. Gentle traction on the lower pair

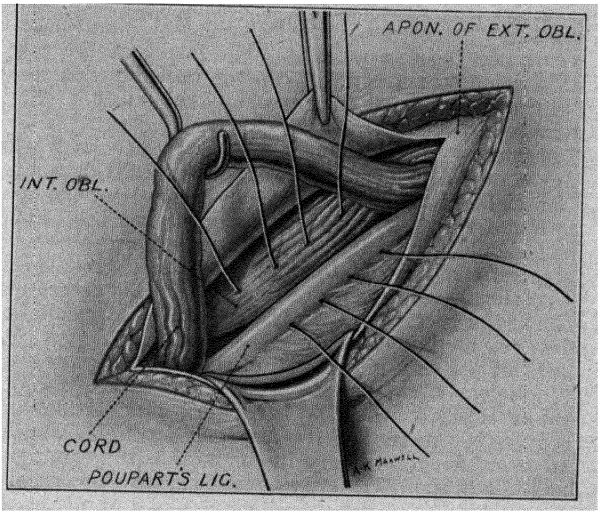

FIG 892.—BASSINI'S OPERATION FOR RADICAL CURE OF HERNIA.

enables the deepest portion of Poupart's ligament to be defined and seen. The stitches must secure a good hold of the tissues, but should not include the external oblique aponeurosis, and when dealing with Poupart's ligament the proximity of the iliac vessels must not be forgotten. Either interrupted or looped mattress sutures may be used; but if the latter, they must not be tied too tightly, as they may strangle the portions of tissue included in their grasp and cause necrosis. The opening in the abdominal parietes is in this way commanded as far down as the pubic spine, but sufficient room must be left at the upper end for the passage of the cord, sometimes it is desirable to introduce a stitch above the cord in order to command a spot where recurrence is not uncommon. When the three or four needful stitches have been introduced and tightened the cord is replaced, and the

divided portions of the external oblique are sutured together over it, as also the deep fascia (6) The wound in the skin is closed by a continuous suture and usually no drainage-tube is needed

There are obvious disadvantages in this operation. The abdominal musculature of the normal adult contracts when he embarks on any act of straining, and the curved fibres of the conjoined tendon, which are muscular in a large part of it, extend, straighten out to obliterate the inguinal canal and prevent the descent of the congenital sac of peritoneum If an endeavour is made to obliterate the inguinal canal by tying the sutures between the conjoined tendon and the deep aspect of Poupart's ligament tightly, the blood supply of the musculature of the former is interfered with, and fibrosis results, so that the musculature is weaker after the operation than before If the sutures are tied loosely, they soon become absorbed, and the slight inflammatory reaction that occurs is insufficient to obliterate the canal, so that a recurrence becomes possible The fact that the operation is successful in some 90 per cent of cases is probably due to complete removal of the sac, and not to the subsequent repair of the inguinal canal attempted in this operation

After-Treatment.—The patient is placed in bed with the knees slightly flexed over a pillow The wound, as a rule, does not require dressing for eight or ten days, when, on removal of the stitches, it should be found completely healed, if asepsis has been maintained The patient should turn to the opposite side in order to pass water, and the greatest care must be taken to prevent the dressing becoming soiled Occasionally retention of urine follows this operation, necessitating the use of a catheter In the case of children, it is well to employ the open method of treatment suggested

The length of the stay in bed and of the subsequent convalescence varies with the age of the patient and the character of the operation In the case of children, where no hard work is undertaken, the stay in bed need not last more than ten days or a fortnight, and they may be allowed to return to ordinary life as soon as they are fit Young adults should be kept in bed for two weeks, given two or three weeks for convalescence, and may then return to light work, heavy strain should be avoided for three months Older people, especially in cases of direct hernia, should stay in bed for three weeks, another three weeks should be spent in convalescing, and no hard work be undertaken for six months Trusses are not needed after an efficient operation, and indeed do harm by causing pressure-atrophy of the scar tissue Where, however, there is doubt as to the efficiency of the cure, and especially if stitches have given way owing to suppuration, or if the abdominal walls are badly developed, or in elderly people, a light truss may sometimes be worn with advantage. Of course, special peculiarities of particular cases necessitate modifications of these general suggestions

The treatment of *congenital hernia* differs in no particular from that already described, except that the sac must be divided below as well as above, and the lower opening secured by suture or ligature, so as to close the cavity of the tunica vaginalis. The operation often proves

difficult owing to the intimate adhesions between the sac and the structures of the cord, and it is sometimes wiser merely to open up the canal and secure the neck of the sac high up where it is more readily isolated.

In inguinal hernia no operation should be performed which does not expose the whole of the inguinal canal, so that the hernial sac can be transfixed at the internal abdominal ring.

The other operations which require to be mentioned are as follows:

(*a*) In *Halstead's* operation the inguinal canal is opened up as in Bassini's method, and the cremaster divided longitudinally along the

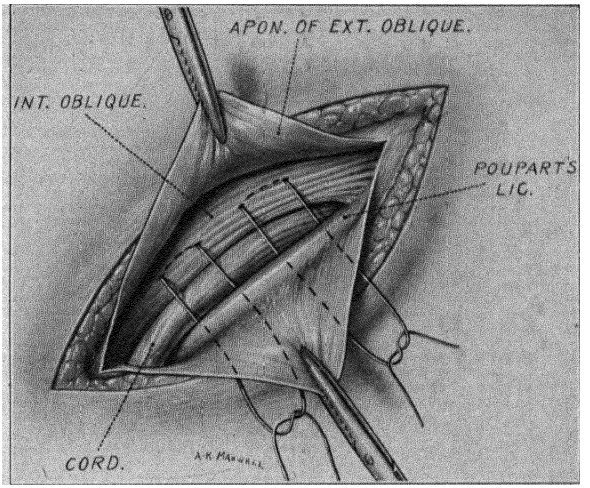

FIG. 893.—OPERATION FOR INGUINAL HERNIA.

The inguinal canal is opened up, and the sac removed as high as possible. The cord and cremaster (not represented here) are pressed back and covered over by approximating the internal oblique and transversalis to the under surface of Poupart's ligament by mattress sutures, which are introduced as indicated above, and tied on the outer aspect of the ligament. The divided segments of the external oblique are then overlapped and sutured.

upper border of the cord, and dissected back, so as to enable the sac and any enlarged veins, etc., to be removed. The lower border of the internal oblique is defined, and the upper edge of the cremaster is sutured to the under surface by a series of mattress stitches. The lower edge of the internal oblique and conjoined tendon is then sutured in front of the cord to the under surface of Poupart's ligament, and finally the divided portions of the external oblique closed by overlapping. If there is much tension in the deeper stitches, a longitudinal incision through the sheath of the rectus muscle will give suitable relaxation.

(*b*) For some years extensive employment of a somewhat similar

difficult owing to the intimate adhesions between the sac and the structures of the cord, and it is sometimes wiser merely to open up the canal and secure the neck of the sac high up where it is more readily isolated.

In inguinal hernia no operation should be performed which does not expose the whole of the inguinal canal, so that the hernial sac can be transfixed at the internal abdominal ring.

The other operations which require to be mentioned are as follows:

(*a*) In *Halstead's* operation the inguinal canal is opened up as in Bassini's method, and the cremaster divided longitudinally along the

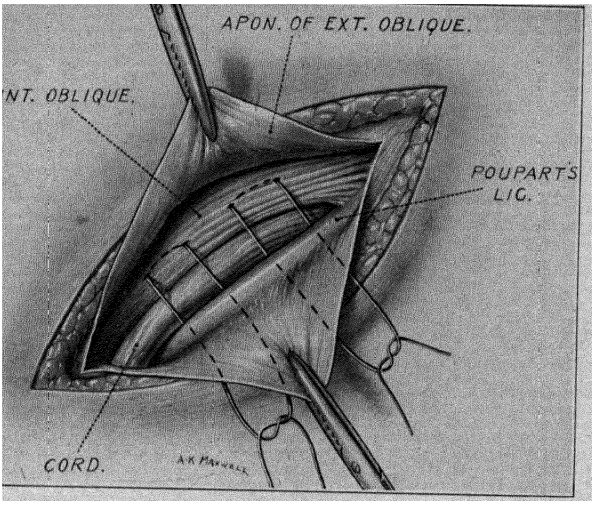

FIG. 893.—OPERATION FOR INGUINAL HERNIA

The inguinal canal is opened up, and the sac removed as high as possible. The cord and cremaster (not represented here) are pressed back and covered over by approximating the internal oblique and transversalis to the under surface of Poupart's ligament by mattress sutures, which are introduced as indicated above, and tied on the outer aspect of the ligament The divided segments of the external oblique are then overlapped and sutured

upper border of the cord, and dissected back, so as to enable the sac and any enlarged veins, etc., to be removed. The lower border of the internal oblique is defined, and the upper edge of the cremaster is sutured to the under surface by a series of mattress stitches. The lower edge of the internal oblique and conjoined tendon is then sutured in front of the cord to the under surface of Poupart's ligament, and finally the divided portions of the external oblique closed by overlapping If there is much tension in the deeper stitches, a longitudinal incision through the sheath of the rectus muscle will give suitable relaxation.

(*b*) For some years extensive employment of a somewhat similar

proceeding has given most satisfactory results. The canal is opened in the same way and the sac excised, the ligature being placed as high as possible. The fibres of the internal oblique are then exposed by thorough retraction of the divided external; and mattress sutures are introduced through the internal oblique and transversalis, or edge of the rectus sheath, carried across in front of the cord *through* Poupart's ligament, and tied on its *outer* surface (Fig. 893). This constitutes a firm muscular barrier across the canal; one or two such sutures usually suffice. The lower or outer segment of the external oblique is then carried up and stitched down to the internal oblique well above the mattress sutures; the inner segment of the divided external oblique is then made to overlap the outer, and stitched down to Poupart's ligament; the deep layer of fascia is also carefully secured by sutures, and the wound closed. Healing almost invariably occurs without suppuration; and even should this happen, the stitches are easily removed, as the knots are on the outer side of Poupart's ligament, and not on the inner, as in Bassini's and Halstead's methods. In these methods epididymitis and hydrocele occasionally develop as sequelæ. The disadvantages of this operation are those mentioned in connection with Bassini's method. In addition, it would seem that the obliteration of the potential space in the inguinal canal is less easily accomplished unless carried out behind the cord.

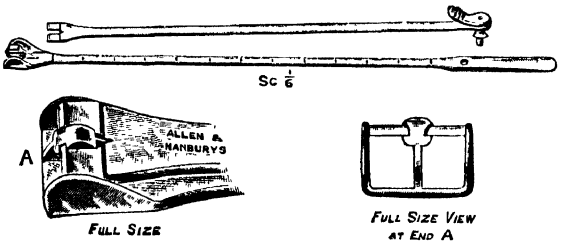

FIG 894.—FASCIAL STRIPPER

The most satisfactory operation of all, and that associated with the least number of recurrences, is some modification of Gallie's operation. The essential feature of this procedure is the obliteration of the canal by a fascial graft sewn between the deep aspect of Poupart's ligament and the internal oblique and conjoined tendon. The fascial strip used may be dissected off the aponeurosis of the external oblique, or, preferably, removed from the fascia lata of the thigh, as from this source a larger strip may be obtained.

It was originally necessary to make a long incision for the purpose of obtaining a fascial strip from the thigh, but nowadays a very adequate segment may be removed subcutaneously with the aid of a fascial stripper. A 2-inch transverse incision is made over the lower part of the fascia lata in the thigh, and a piece 1 inch wide is dissected up for a little way. This free end is then threaded between the blades of the fascial stripper, which latter is then negotiated subcutaneously up the thigh to its full extent of about 8 inches. A tenotomy knife is then used to divide the strip of fascia through the skin at its upper extremity.

In using the strip it is best first to divide it longitudinally to an inch from one extremity. At this point a catgut suture is inserted to prevent the split running up further. A small longitudinal incision is then made into the undivided extremity and a suture similarly placed at either end. The fascial strip is then ready for use (Fig. 894).

For threading the strips between the conjoined tendon and the ligament of Poupart, the ends may be attached to Gallie's needles (Fig. 895), or else they may be drawn through with the aid of a modified Miles' fascia forceps. In either case the two free ends are drawn through the fascia over the pubic bone, and are then threaded through the hole in the wide extremity. A firm fixation for the fascial strip is thus obtained. The two ends of the strip are then laced criss-cross, underneath the end, which is retracted well out of the way, between the conjoined tendon and the deep aspect of Poupart's ligament as far as the internal abdominal ring, where the ends are fixed with a catgut suture. It is essential that no tension be placed on the fascial strip, else the disadvantage mentioned in connection with Bassini's operation will apply in this case, and it is a good plan to suture the loops of the fascial strip periodically so that there is no danger of their being drawn tight (Fig. 896).

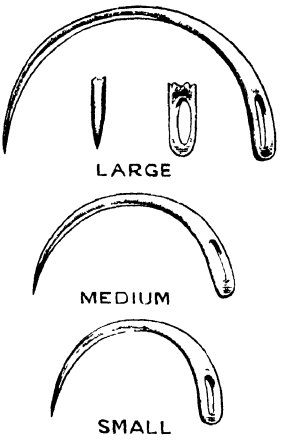

FIG 895.—GALLIE'S HERNIA NEEDLES

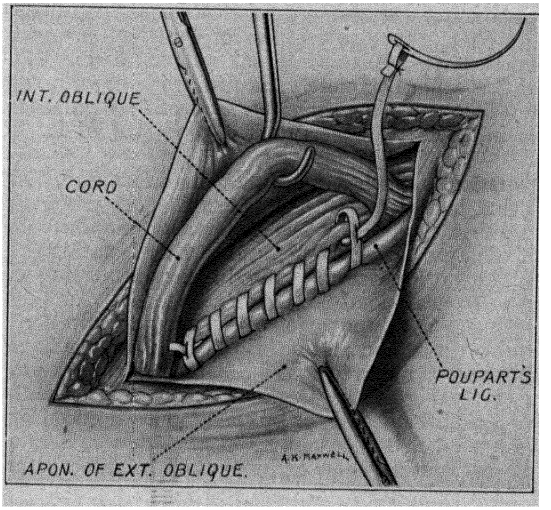

FIG. 896.—RADICAL CURE OF INGUINAL HERNIA, USING STRIPS OF FASCIA LATA (AFTER GALLIE)

A modification of Gallie's method has been introduced whereby thick silk is used in place of the fascial graft. In support of the use of this material it is pointed out that the silk remains unabsorbed

and that it gives rise to a strong fibrotic reaction, but it seems to us that with modern methods of removing the fascial graft the advantages of inserting a living material outweigh the more simple use of silk.

Treatment by Injection.—This form of treatment was used as long ago as in 1832 by the American George Heaton. With the advent of Listerian surgery its use was largely abandoned, but of recent years, on account of the recurrences following some of the operations performed for herniæ, it has become more popular. It is only suitable for those cases that can be controlled by trusses, and consists in the injection of a sclerosing fluid into the inguinal canal about the sac. A solution containing zinc sulphate and phenol is generally used. A series of twenty or thirty weekly injections are necessary. Throughout the course of treatment the patient must be instructed to wear a well-fitting truss night and day, for, until the sclerosis of the canal is complete and firm, the entry of any abdominal contents into the sac will undo all the good that the previous injections have done.

The *treatment of direct inguinal hernia* is modified by the fact that the condition usually occurs in elderly men. In many it is wise to order a double truss and avoid operation; but in some operation is permissible. The prognosis is never so good as in the oblique variety—(*a*) because it occurs in older subjects, and is often predisposed to by chronic obesity, cough, or difficulty in micturition; and (*b*) because the chief weakness is at the lower, and not at the upper, end of the canal, and hence the deep ring lies almost directly behind the opening in the external oblique. In these cases experience has taught that the best plan to adopt is to displace the cord entirely, bringing it out through the muscles opposite the internal abdominal ring, and closing up the rest of the canal completely, as in a woman, with the aid of a fascial graft. The more superficial position of the cord does not seem to affect it injuriously, especially if a good pad of fat is sutured around it.

Recurrence after Operation is much less common than formerly, and statistics go to prove that in experienced hands less than 10 per cent. of the cases recur, and that rarely after the first twelve months. It is often due to a want of appreciation of the necessity for isolating the sac as far as possible, since otherwise the infundibuliform opening at the top of the closed peritoneal canal is certain to persist. Another cause of recurrence is pyogenic contamination of the wound; if the deep stitches are not involved, no great harm is done; but whenever they have been removed or come away, recurrence is probable. Relapses are also due to splitting or tearing of the tendinous structures around, either by the mere passage of the needle, or by the traction induced by tightening the sutures; indeed, it is usually the case that a hernia originally oblique is after operation followed by one that is direct, and probably from this cause.

Whenever it appears likely that recurrence may occur, a light truss should be ordered. If, however, a hernia has developed, a second operation may be performed, if warranted by the condition of the abdominal parietes.

Femoral Hernia.—A femoral hernia is one which, travelling down

the crural canal, presents at the inner and upper part of the thigh through the saphenous opening. It occurs most commonly in women on account of the greater expansion of the iliac crests allowing increased space beneath Poupart's ligament, and especially in those who have borne children. During parturition the inguinal regions are in a measure protected, and hence inguinal hernia is rarely caused in this way. In young people, however, it is more common in the male sex.

The crural canal constitutes the inner compartment of the femoral sheath, a space usually occupied by fatty cellular tissue, lymphatic vessels, and perhaps a lymphatic gland. It is about ¾ inch in length anteriorly, and 1½ inches along its posterior wall; it is closed above by a thickened portion of the subserous cellular tissue known as the septum crural, and its lower end is formed by the saphenous opening, and closed by the cribriform fascia. Hence a femoral hernia, as it passes downwards, receives the following coverings: (*a*) peritoneum, (*b*) subserous cellular tissue, including the septum crurale, a layer sometimes known as the fascia propria, and occasionally represented by a thick fatty envelope; (*c*) the anterior layer of the femoral sheath, derived from the fascia transversalis; (*d*) cribriform fascia; (*e*) subcutaneous tissue; and (*f*) skin. In its passage through the canal it is situated immediately internal to the femoral vein, and pressure upon this may produce œdema of the leg, whilst Gimbernat's ligament lies to the inner side. The spermatic cord or round ligament is placed just above and internal to it, but on a superficial plane, whilst the epigastric artery is not very far from the outer side of the neck. Occasionally the obturator artery arises from this latter vessel (once in three and a half subjects); it may pass to the inner side of the neck of the sac along the border of Gimbernat's ligament (once in seventy-five times), but more commonly runs between the neck and the femoral vein. When once it has emerged from the saphenous opening, a femoral hernia usually travels upwards and outwards along Poupart's ligament towards the anterior superior iliac spine, being guided by the attachment of the deep layer of the superficial fascia; when of large size, it may extend considerably above the level of Poupart's ligament. Femoral herniæ are less likely to contain omentum than the inguinal variety; a portion of the ileum is most often present, but occasionally the ovary or Fallopian tube may be found in the sac.

Rarely the hernia passes in front of the femoral vessels or to the outer side. In other cases it may pass through the ligament of Gimbernat, and occasionally it burrows through a deficiency in the pectineus muscle.

The **Signs** of a femoral hernia are very characteristic. A rounded swelling with an impulse on coughing, and more or less reducible, forms on the inner side of the thigh, its neck or aperture of communication with the abdomen lying to the inner side of the femoral vessels, and to the outer side of the pubic spine, which can always be easily felt (Fig. 897). There is usually but little difficulty in making a **diagnosis,** although occasionally some care is needed. (*a*) An *inguinal hernia* is recognized by the fact that its neck occupies the inguinal canal, the saphenous opening being free; whilst it is also above and internal to the

pubic spine, and above Poupart's ligament at its point of exit; it tends to pass downwards into the scrotum, or in females into the labium. Femoral hernia, on the other hand, usually (but not invariably) occurs in women over twenty-five years of age, the inguinal canal is free, whilst the neck is in the situation of the crural canal, below and external to the pubic spine, and below Poupart's ligament, moreover, it travels upwards and outwards, the labium being unaffected. (*b*) An *enlarged lymphatic gland* over the saphenous opening may simulate this condition very closely, but the absence of impulse on coughing and of the usual hernial signs is generally sufficient to distinguish it, when, however, the hernia is purely omental and irreducible, the impulse is so slightly marked that correct diagnosis in a stout woman is often difficult without an exploratory incision. (*c*) A small *lipoma* in the canal somewhat resembles a hernia, but the limitation of the tumour, its greater mobility, and the absence of an impulse on coughing, should suffice to prevent a mistake. (*d*) A *psoas abscess* pointing at the saphenous opening resembles a hernia in the existence of a reducible swelling with an expansile impulse on coughing. It is distinguished from it by the fact that there is no gurgle on reduction; that the abscess, as it passes under Poupart's ligament, lies to the outer side of and behind the vessels; and that a tense swelling occupies the iliac fossa, between which and the swelling presenting at the saphenous opening fluctuation can be readily detected; the characteristic signs of spinal caries are also usually present.

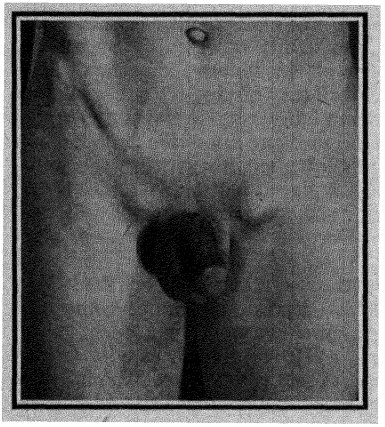

FIG. 807.—BILATERAL FEMORAL HERNIA

(*e*) In *varix of the internal saphena*, a pouch or ampulla developing close to its upper end may be mistaken for a femoral hernia on account of the marked impulse on coughing, and because the swelling disappears on assuming the recumbent position. The impulse, however, is of a different character from that of a hernia; the blood can be felt to be driven past the examining finger with a thrill, instead of there being merely an expansile bulge. Moreover, if the swelling is reduced by recumbency, and a finger is then placed over the upper end of the crural canal so as to occlude it, the dilated vein fills up again from below on assuming the erect position, the hernia does not descend. Finally, other signs of varix are usually present in the limb.

Treatment.—When reducible and of small size, a femoral hernia may be treated by the use of a *truss*, similar in nature to that used for an inguinal hernia, except that the pad extends somewhat lower,

so as to maintain pressure along the course of the canal. It is not, however, a desirable practice, on account of the difficulty in controlling the hernia, and on account of the liability to strangulation.

Operative Treatment, with a view to radical cure, is always desirable, when practicable, and ought to form part of all operations for the relief of strangulation. The complete removal of the sac is an essential part of the procedure, and the blocking of the entrance to the crural canal or its obliteration by approximating its anterior and posterior walls is the only sure preventive of recurrence. Two chief methods

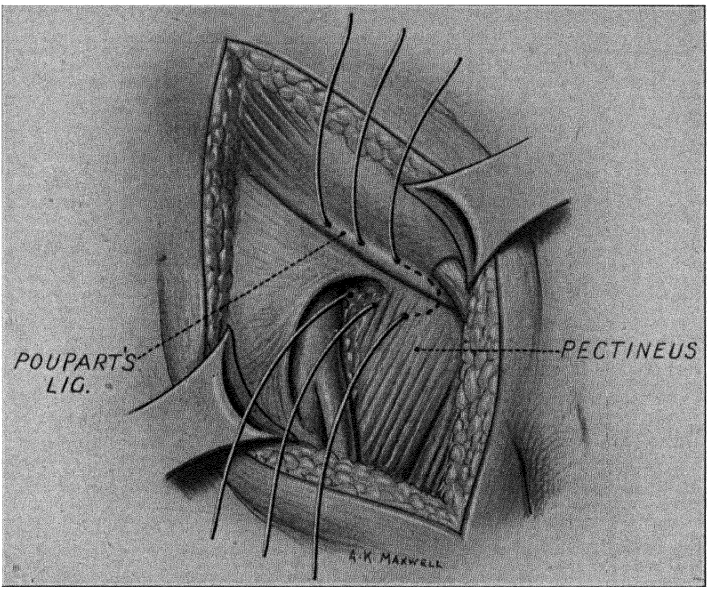

FIG. 898 — DIAGRAM OF THE RADICAL CURE FOR FEMORAL HERNIA

of approach are possible, one from below in the groin, the other from the inguinal canal.

1. In the operation from below, the sac is exposed by a vertical incision along the course of the crural canal, cleared completely of its fatty covering, which is often thick and abundant, emptied of its contents by reduction, and then cut away after transfixing and tying the neck. Some surgeons, however, retain the sac, pushing it back into the abdomen, and using it as a pad across the upper opening of the canal. The deep ring is then commanded by one of the following methods (1) In many of the simpler cases it will suffice to introduce three sutures through the inner end of Poupart's ligament (Fig. 898), and deeply through the horizontal fibres of Cooper's liga-

ment, which lie in close apposition to the horizontal ramus of the pubis. There are but few cases where this manœuvre, if effectively carried out, is not sufficient to determine closure of the canal, but for this purpose the hernia needle must be carried down to the bone, and not merely through the fascia over the pectineus. (2) In a few cases, perhaps, where the opening is larger, it may be desirable to approximate Poupart's ligament to the horizontal ramus by some other method, and for this purpose Roux has advised the use of a ∩-shaped metal staple, which traverses the ligament, and the free ends of which are driven into the bone. This plan appears to us undesirable, since the staple occasionally works loose, and then the proximity of the femoral

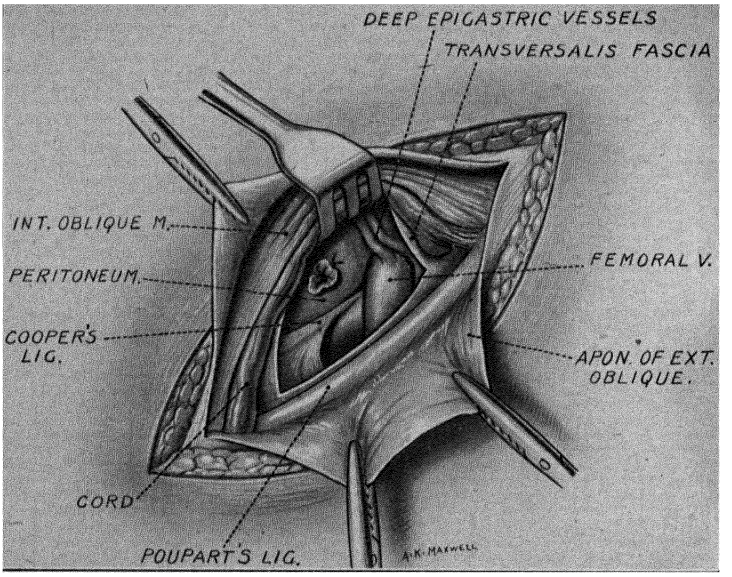

FIG 899.—LOTHEISEN'S OPERATION.

vein makes it an unwelcome neighbour. (3) A good substitute for this plan was practised by Nicoll of Glasgow, who drills the horizontal ramus from below upwards in two spots, and passes a mattress suture through Poupart's ligament, and the free ends through these drill-holes, tying them below, the ligament is thus safely approximated to the inner and upper aspect of the pubis.

The general results of this operation have proved very unsatisfactory in the hands of most surgeons, a large percentage of cases recurring (10 to 20 per cent.). This is probably due to three causes, *viz.* ligaturing the sac below the crural canal without sufficient traction; insufficient clearance of the neck of the sac, some of the

fatty envelope which descends with the sac remaining, and preventing perfect occlusion of the canal; and inefficient closure of the canal.

2. To obviate these defects, an *Inguinal Operation* (Lotheisen's operation) has been practised of recent years, so as to deal more effectively with the neck of the sac and to avoid the dangers associated with the close proximity of the femoral vein. An incision is made as for inguinal hernia, but is carried a little further inwards over the pubes. The inguinal canal is opened up by incising the external abdominal ring and carrying the incision up and out. The internal oblique and transversalis, together with the cord or the round ligament, are drawn aside by one retractor, whilst the external oblique is retracted outwards by another. The floor of the canal can now be seen, and is carefully explored so as to lay bare the subperitoneal fat covering the neck of the sac which is defined. If the hernial contents are reducible, the sac can often be pulled up without trouble into the wound, and there ligatured and excised; but if there is difficulty with this, the sac must be exposed below Poupart's ligament by pulling down the lower flap of skin. It can then be cleared of its fatty envelope, opened, and its contents dealt with by open reduction or removal, so as to enable the sac to be pushed up through the crural canal into the upper part of the wound. There its neck is cleared, transfixed and ligatured, and the fundus cut away. The femoral ring is now clearly visible, and can be controlled by sutures passed between Cooper's ligament behind and Poupart's ligament in front, under the guidance of the eye, and it is this, together with the complete removal of the sac, that constitutes the special merit of this procedure, there is no groping in the dark, but the surgeon can see what he is doing (Fig. 899). In cases of difficulty, where considerable tension is likely to fall upon the stitches, it may be desirable to detach a flap of the anterior sheath of the rectus muscle and secure it across the upper opening of the crural canal by stitching it to the under-side of Poupart's ligament as far out as the femoral vessels, or better still to use a fascial strip obtained from the thigh. Careful closure of the inguinal canal completes the operation, which has been followed by good results.

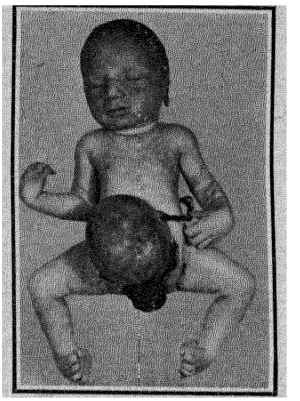

FIG 900.—A CASE OF EXOMPHALOS

Umbilical Hernia.—Three different forms of umbilical hernia are described.

1. **Congenital Umbilical Hernia, or Exomphalos,** is an exceedingly rare condition, due to imperfect closure of the abdominal walls, as a result of which part of the intestine is found at birth in a cavity at the base of the umbilical cord, which is bulbous and enlarged (Fig. 900). If the condition is overlooked, it may be included in the ligature with which the cord is tied, and fatal strangulation, or at the best a fæcal

fistula, will result. If left untreated until the cord has separated, the peritoneal cavity will be laid open, and septic peritonitis ensue. The question of *Treatment* depends entirely on the state of development of the abdominal wall. If there is a prospect that the margins of the gap can be drawn together, operation must be undertaken forthwith, so as to avoid septic complications; if the abdominal wall is insufficient for the purpose, nothing can be done.

2. The **Umbilical Hernia of Infants and Young People,** or as it is commonly called 'starting of the navel,' is due to weakness of the umbilical cicatrix, which yields before the intra-abdominal pressure. Its occurrence is often determined by chronic constipation or phimosis, necessitating continual straining in order to evacuate the bowels or bladder. The condition rarely persists till adult life, as it is easily cured. *Treatment* consists in regulating the bowels and in the performance of circumcision, if necessary, whilst the local condition is dealt with by strapping the abdominal wall in such a way as to tuck the umbilical cicatrix inwards; no pad is required. In persistent cases it may be necessary to lay the sac open and remove it, suturing the parts together, as described in detail below. In these cases the opening is often a transverse chink rather than a round hole, and it is therefore advisable to introduce the sutures in a vertical direction, thereby securing transverse apposition.

3. The so-called **Umbilical Hernia of Adults** is usually due to a protrusion of omentum or intestine through an opening in the linea alba, either immediately above or below the umbilicus, the former being the more common. A more frequent variety is that seen in women who have borne children, being sometimes due to stretching or actual rupture of the linea alba and separation of the recti muscles. A peritoneal sac is present, but in old-standing cases it is extremely attenuated, and so adherent to surrounding parts as to be unrecognizable, whilst the contents may be matted together in an almost inextricable confusion. Under such circumstances obstruction is very liable to ensue, and if combined, as is not uncommon, with a subacute form of inflammation, it may even run on to strangulation. Moreover, the skin over the tumour becomes stretched, atrophic, and not unfrequently ulcerated, so that perforation may threaten. The hernia is often lobulated in outline, and a considerable deposit of fat may sometimes surround it.

Treatment by retentive apparatus is of little value, and certainly has no curative effect when the hernia is irreducible, neither does it hinder it from increasing in size. Possibly in the early stages of a small reducible hernia a closely-fitting elastic belt or bandage with a suitable pad over the opening may be of some use, but the pressure required to make it effective is often a source of great discomfort.

The actual operative treatment of these cases is never easy, as the patients are not favourable subjects, often fat and unhealthy, and possibly the subjects of chronic bronchitis. A preliminary course of treatment is always desirable, so as to unload the bowel completely and to reduce the amount of fat; hygienic and dietetic measures with this end in view must be instituted. The character of the operation will

vary according to whether the hernia is more or less limited to the umbilical area, or whether in addition the linea alba is generally weak and relaxed. In the former a modification of the plan suggested for the infantile type of umbilical hernia may be adopted; in the latter, it may be well to work through a longitudinal, and not a transverse, incision, so as to be able to deal with the relaxed linea alba at the same time. In both cases the same principle is adopted, *viz.* that of overlapping or imbricating the edges so as to gain surface-to-surface union, for the margins of the hernial opening are so unhealthy and fibrous that edge-to-edge union could never be expected.

In the so-called *Mayo operation* for umbilical hernia, transverse crescentic incisions are made both above and below the hernia so as to encircle it. The sac is carefully defined and cleared of fat, as also the aponeurosis of the recti muscles for some way around (Fig. 901). The aponeurosis is then divided close to the neck by transverse incisions, and the sac opened. The contents are turned out and examined. Omentum is almost always present, and often adherent, both to intestine, sac and margins of the opening. Generally speaking, most of the omentum thus found is removed; it usually constitutes a thick fibro-fatty mass, tangled and adherent, and useless as omentum. Special care is directed to the margins of the opening, which must be completely cleared. The intestine, both small and large, is generally reduced without difficulty when the omentum is set free. The sac, the adherent tags of omentum within it, and the overlying skin are then cut away completely, and great care is taken to secure hæmostasis of the cut edges. The opening is now limited by two peritoneo-aponeurotic flaps, above and below respectively, and is closed by superposing the upper of these over the lower by means of mattress sutures introduced through the margins of the lower and passed under and through the upper from within outwards, as far up as one can conveniently reach (Figs. 902-904). The upper flap is then stitched down over the lower, which it usually overlaps to the extent of nearly 2 inches. Kangaroo tendon may be employed

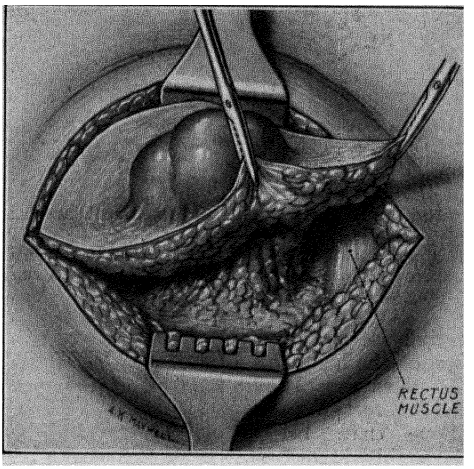

FIG 901.—THE INCISION AND REMOVAL OF FAT FROM THE ABDOMINAL WALL IN MAYO'S OPERATION

for these sutures or well chromicized catgut, so that they are not too easily absorbed. The subcutaneous tissues are brought together by buried stitches; provision is made for drainage, and the skin wound is closed.

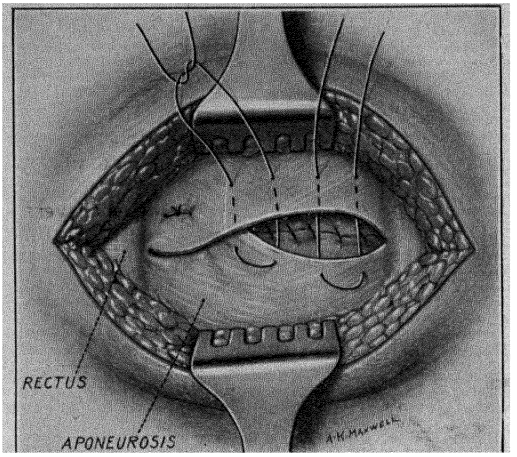

FIG 902.—MAYO'S OPERATION FOR UMBILICAL HERNIA

The peritoneal layer is closed, and mattress sutures have been inserted to produce horizontal overlapping of the rectus sheath

A **Ventral Hernia** is the term used in describing any protrusion occurring at some spot in the anterior abdominal wall other than those already mentioned. Several forms may be met with:

1. It consists not uncommonly of a protrusion of subserous fatty tissue through a congenital or acquired opening in the linea alba, lineæ semilunares, or lineæ transversæ, especially at the junction of the last with the former. They are more common above than below the umbilicus, and if, as not unfrequently happens, the fatty tissue proliferates, a localized tumour resembling a lipoma is produced which goes by the name of a *fatty hernia of the linea alba*. A portion of the peritoneum is drawn through the opening into the centre of these masses, after they have persisted for some little time, and a true hernia is thus

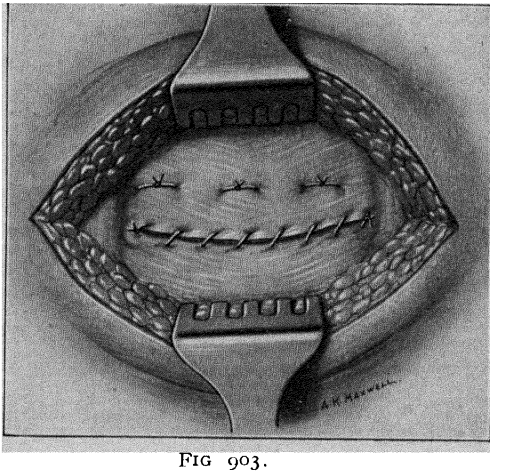

FIG 903.

The mattress sutures are tied, and the overlap is secured with interrupted sutures.

induced. Considerable pain and abdominal disturbance (vomiting, colic, etc.) accompany almost every movement of the body, being caused partly by the traction of the peritoneum, partly by the con-

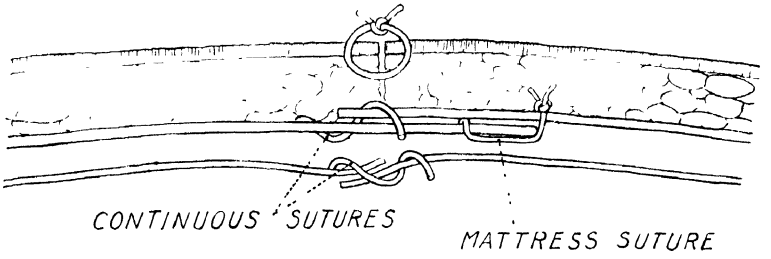

FIG 904.—A SECTION THROUGH THE ANTERIOR ABDOMINAL WALL SHOWING THE METHOD OF CLOSURE IN MAYO'S OPERATION FOR UMBILICAL HERNIA.

striction of the neck of the sac against the sharp edges of the small opening. *Treatment* consists in the removal of the projecting mass, care being taken not to include any viscera in the suture with which the base is surrounded. The stump is pushed back into the abdomen, and the opening closed by deep sutures.

2. After operations involving the division of the abdominal parietes, ventral hernia may be caused by the yielding of the cicatrix, especially if the wound suppurates, and the deep stitches come away or are removed, or if the opening is left patent for the purpose of draining an intra-abdominal abscess (Fig. 905). *Treatment* of such cases is conducted along the lines suggested for that of an umbilical hernia, *viz.* by freeing the margins of the gap from adhesions, and replacing or removing the contents, the sac is then excised, and perhaps the overlying fat and skin, the opening is closed by overlapping the walls, or by implanting a fascial graft, or by deep fascial stitches (Gallie). Considerable skill and judgment are required if this procedure is to be effective, but good results may be anticipated.

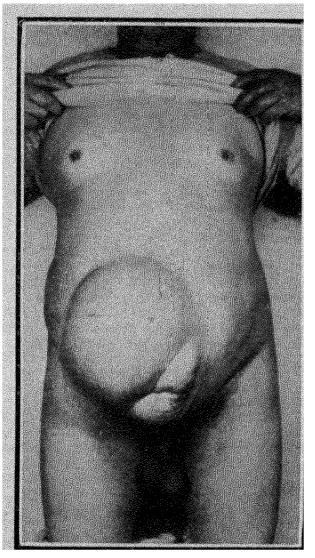

FIG 905. VENTRAL HERNIA FOLLOWING OPERATION FOR ACUTE APPENDICITIS

Gallie of Toronto recommends the employment of sutures of living fascia lata cut in long strips and laced across the opening in several layers, so as to constitute an effective barrier; it remains *in situ* and leads to a considerable fibrous development around. Excellent results have followed its use.

3. In women who have borne children the linea alba often stretches and yields, allowing considerable separation of the recti muscles for almost their whole length, and this apart from any umbilical hernia. If placed in the recumbent posture, and told to raise the head and shoulders from the bed without using the elbows for support, the linea protrudes as a longitudinal ridge of considerable breadth. Much discomfort and dyspepsia arise from this cause, owing to the inefficient support given to the intestines. A firm abdominal belt may be used as a palliative measure, but operation is very desirable. The thinned linea alba is split down the middle from top to bottom if need be; on one side—say, the right—it, together with the neighbouring rectus muscle, is separated from the subcutaneous tissues and tucked under the rectus on the left side, its free end being secured by a row of mattress sutures passing through its edge and the left linea semilunaris, and being tied superficially. The left free edge is subsequently secured to the right linea semilunaris by a row of stitches. Redundant fat and skin are removed and the wound closed by sutures. In this way the abdominal wall is drawn together like a double-breasted coat, and excellent results follow. In other cases a good plan is to detach the recti muscles from their insertions, cross them over one another, and reinsert them on the opposite side (Figs. 906-908) as recommended by Nuttall of Liverpool.

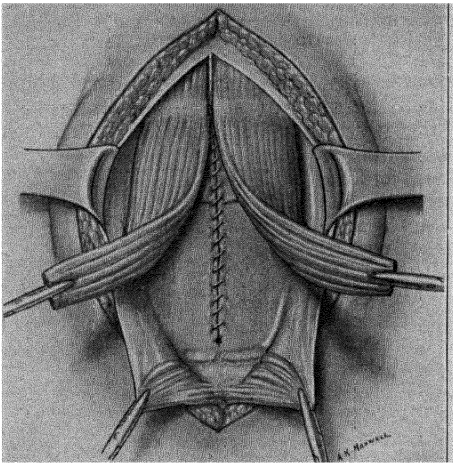

FIG 906.—NUTTALL'S OPERATION FOR VENTRAL HERNIA

The recti are detached from their origins

A **Lumbar Hernia** is a condition of considerable rarity, in which the abdominal viscera protrude by the side of the erector spinæ between the latissimus dorsi and the external oblique, in the space known as Petit's triangle. It is perhaps seen most frequently after operations upon the kidney where suppuration has occurred, and the deep stitches have had to be removed. The ordinary signs of hernia are present, and with a little care the condition is readily distinguished from a lumbar abscess. *Treatment* may be conducted along the same lines as for a ventral hernia.

A **Diaphragmatic Hernia** is usually congenital in origin, arising from imperfect development of one or both halves of the diaphragm, and then generally on the left side; or it may result from traumatic lesions,

such as stabs, or gunshot wounds involving the diaphragm. The omentum, transverse colon, and stomach protrude into the thorax without any peritoneal sac, and give rise to various inflammatory and obstructive phenomena. It is readily recognized by a radiographic examination (Fig. 909). *Treatment* by operation can be successfully undertaken in traumatic cases by opening the pleural cavity after excising the 9th or 10th rib, exposing the upper surface of the diaphragm, and suturing the margins of the gap. In congenital cases the prospects are less promising.

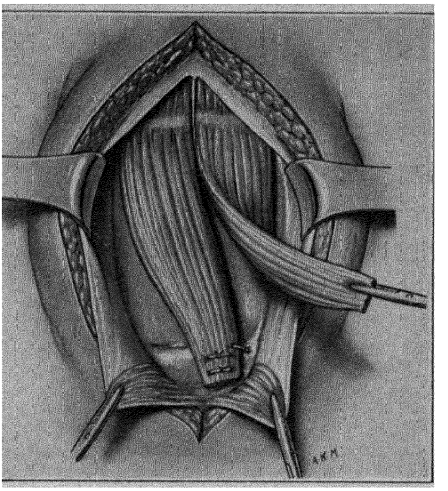

FIG. 907.—NUTTALL'S OPERATION RECTI CROSSED

Obturator Hernia consists in a protrusion of intestine through the upper part of the thyroid foramen, and has usually been observed in elderly females. Multiple pregnancy is an important factor in its causation owing to the relaxed condition of the peritoneum produced. It is not often recognized in the living, except when strangulated, and even then it is more likely to be discovered from the abdominal aspect during a laparotomy for acute obstruction than diagnosed apart from operation. In a few cases, however, it has been noted that, in addition to the general signs of strangulation, there was a sense of deep resistance and of fulness close to the origin of the adductor muscles, and that pain was referred down the obturator nerve to the inner side of the knee (Fig. 910). Rectal or vaginal examination may throw

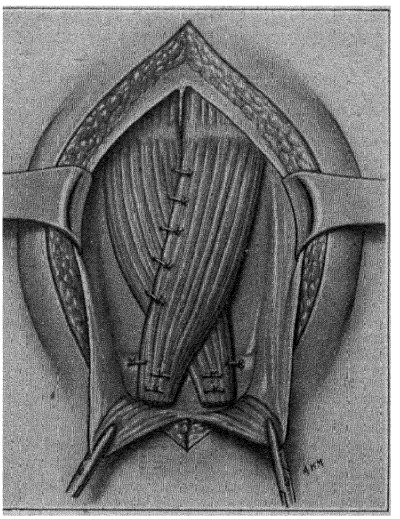

FIG. 908.—NUTTALL'S OPERATION. COMPLETE

some light on the nature of the case (Fig. 911). *Treatment* has generally been confined to cases of strangulation, and in these exposure has been by means of an abdominal incision, with the patient in the Trendelenburg position, over the hernial protrusion, or by a combination of these routes. In these rare cases, where strangulation is not present and a diagnosis has been made, the sac may be exposed by an inguinal incision with retraction of the aponeurosis of the external oblique and the cord upwards. The sac when found should be opened, and strangulation relieved by stretching digitally or, if this fails, cutting upwards the constricting fibrous ring, the obturator vessels being usually situated below the neck of the sac. If found during a laparotomy for obstruction, the same precautions must be taken as for a Richter hernia in the femoral region when discovered in the same way. It is possible to close the abdominal opening by a peritoneal purse-string suture introduced from above, if the patient is in the Trendelenburg position.

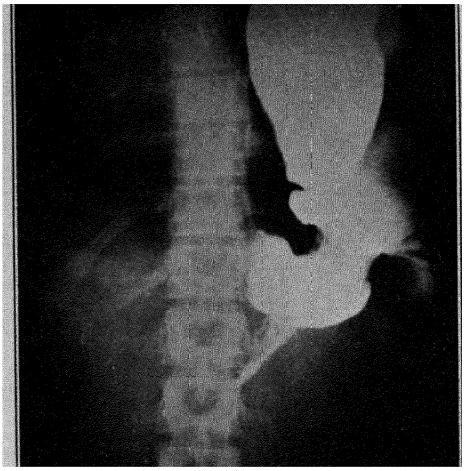

FIG 909.—SKIAGRAM OF DIAPHRAGMATIC HERNIA, MOST OF THE STOMACH BEING IN THE LEFT PLEURAL CAVITY

Other forms of hernia, *e.g.* **pudic, pudendal, vaginal, sciatic** (Fig. 912), etc., have been described, but are so uncommon that they need no special mention.

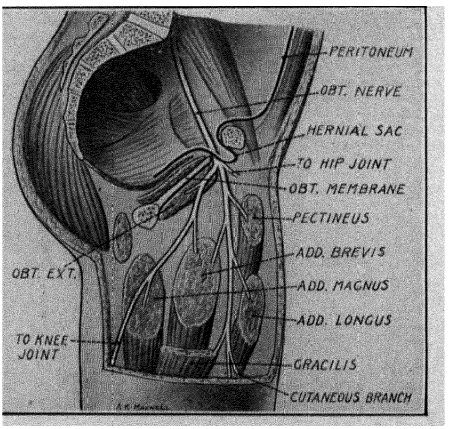

FIG 910.—RELATION OF OBTURATOR NERVE TO THE OBTURATOR CANAL

Abnormal Conditions of Herniæ.

Irreducibility of a Hernia is generally due to the presence of adhesions, either between the contents and the sac, or between the contents themselves

which are thus united into a mass too large to pass through the aperture of communication with the abdomen. This is often associated with contraction of the neck of the sac, which arises either from the pressure of an ill-fitting truss or the constant drag of the contents. Overgrowth or an excessive deposit of fat in the omentum may also result in irreducibility. The local signs of this condition are very evident; dyspepsia, colicky pains, and a sense of dragging are among the most prominent symptoms.

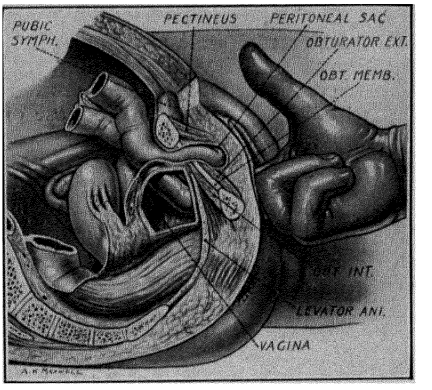

FIG 911.—OBTURATOR HERNIA SAC FELT ON VAGINAL EXAMINATION

Treatment.— In healthy individuals, and if the hernia is not too large, operation in these cases is desirable, and indeed essential, since a truss cannot be worn safely, and to leave the condition unprotected is a confession of failure. The operation is conducted along the usual lines of a radical cure, and adhesions are dealt with suitably, omentum being removed and intestines set free so as to enable complete reduction to take place. A radical cure completes the procedure. It has already been pointed out that it is undesirable to replace suddenly large masses of intestine or omentum that have been long outside of the abdominal cavity for fear of interfering with the heart's action; and therefore in such cases preliminary rest in bed with suitable purging, starvation, and massage of the hernia should be adopted, so as to reduce its bulk, and if possible reduce its contents before operation.

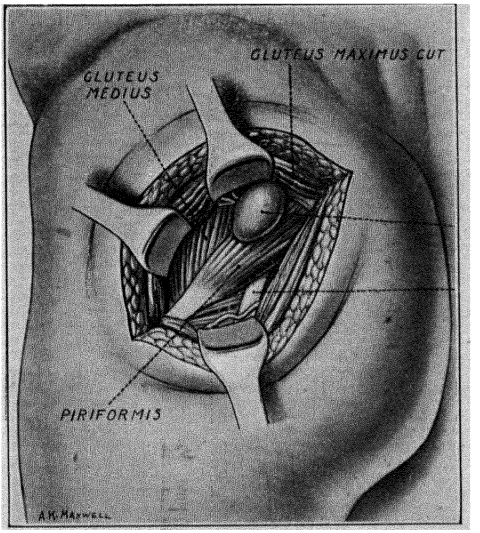

FIG 912.—SCIATIC HERNIA SAC EXPOSED ABOVE THE PYRIFORMIS MUSCLE

Failing such measures, the only plan is to support the hernia in an elastic support, which is tantamount to leaving it to take care of itself.

An **Inflamed Hernia** is characterized by the existence of a localized peritonitis involving the sac and perhaps also the contents. It usually arises from injury, such as ill-directed taxis, or from injudicious truss pressure. The symptoms are those of a local inflammation, the part becoming hot, painful, tender, and swollen, and perhaps the skin over it congested; this is associated with general fever, malaise, nausea, and vomiting, whilst constipation is generally present. A condition is thus induced somewhat resembling strangulation; but it is distinguished from this by the presence of fever instead of shock and the absence of tension in the sac. The hernia is irreducible, at any rate for a time, probably more on account of the pain, which prevents taxis, than from any mechanical reason, except in old-standing cases where previously formed adhesions exist. Lymph is deposited on the serous surfaces, and this usually leads to the formation of adhesions. Occasionally, where omentum is alone present, an attack of this type may result in a natural cure, especially in the umbilical variety.

The **Treatment** consists in putting the patient to bed and restricting his diet to fluids, whilst fomentations are applied to the part. A little opium may also be administered to allay the pain, and the lower bowel is emptied by an enema. Should the condition persist in spite of treatment, it will be wise to operate, as otherwise strangulation may follow.

Obstructed Hernia is a condition in which the onward passage of fæces through the gut contained in a hernial sac is prevented. It is most frequently seen in the umbilical variety, and, of course, only involves the large gut. It is due to an accumulation of undigested food or fæces, the condition being aggravated by the presence of flatus derived from the decomposition of the contents of the bowel. Nausea and vomiting are induced, the latter, however, rarely becoming fæculent, whilst constipation is usually present, although the lower bowel may empty itself and flatus may pass. Locally, the tumour becomes irreducible and distended, but not tense as in strangulation, and a doughy mass, which can be moulded and indented by the fingers, is felt within the sac. There is no tenderness, but the patient complains of a good deal of intermittent colicky pain. If unrelieved, a subacute form of inflammation may supervene, and this may pass on to strangulation, and even death.

Treatment consists in the use of copious enemata, and the application of an icebag to the hernia, followed by carefully applied taxis, so as to assist the onward passage of the impacted contents. As soon as the obstruction is overcome, a brisk purge should be administered.

Strangulated Hernia.

A hernia is said to be strangulated when the contents are constricted in such a way as to obstruct and ultimately to arrest the flow of blood in the vessels contained therein. Interference with the passage of

fæces is not an essential in this condition, since omentum alone may be involved, or the intestine, if present, may only have a portion of its lumen constricted, as in the form known as **Richter's hernia** (Fig. 914), whilst in **Littré's hernia** a diverticulum is similarly affected (Fig. 913).

Two chief varieties of strangulation are described: those occurring within the abdomen, which are dealt with more fully in Chapter XXXIX., and those which are extra-abdominal; it is only the latter to which we shall now direct attention.

External Strangulated Hernia arises in one of two ways: (*a*) The hernia becomes strangled immediately after its formation; this is most frequently seen in children or adolescents, the hernia being then of the congenital type, and having a long narrow sac. (*b*) In adults it more frequently results from extrusion of an additional amount of the abdominal contents into the sac, as the outcome of some sudden violent effort. This condition usually obtains in old-standing herniæ, the neck of the sac having previously become thickened and contracted either by the pressure of a truss or the irritation of the protruded viscera. The former of these two conditions is generally acute in character, the latter more often subacute.

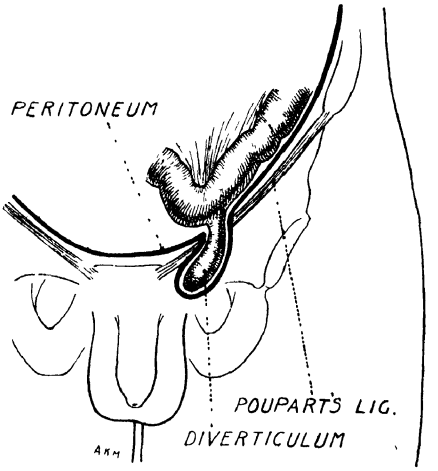

FIG 913.—LITTRÉ'S HERNIA

The site of the constriction is either at the neck of the sac, or in the dense tissues external to it, but occasionally it exists elsewhere. Most frequently the active agent in the strangulation is the thickened sac wall itself, but in femoral and umbilical herniæ structures outside the sac, such as Gimbernat's ligament or the linea alba, may be the actual cause of the constriction, whilst it may also be produced by the passage of a coil of intestine under a tight adhesion or through a slit or aperture in the omentum contained in the sac. In those herniæ which become strangulated immediately after their protrusion, the constricting cause is invariably the resistance of the tissues surrounding the opening in the abdominal parietes.

Pathological Phenomena.—The effects of strangulation vary somewhat with the tightness of the constriction. The circulation is seldom arrested entirely at the onset of the symptoms; but the pressure affects first, and more especially, the veins, and later, by the congestion and exudation thus produced, the flow in the arteries is brought to a standstill. Hence the constricted tissues are congested to begin with,

and then, partly as a result of the deficient supply of arterial blood, mainly in consequence of bacterial invasion, gangrene ensues, with or without an intervening period of inflammation.

When a *portion of intestine* is strangulated, it first becomes of a dusky red, chocolate, or claret colour, owing to vascular congestion, it is thickened and stiff from exudation into its walls, and distended by the formation of gas within its lumen, owing to the arrest of peristalsis and the putrefaction of its contents. The surface for a time remains smooth and shiny, but as the exudation into the sac increases, the endothelium is shed. Occasionally some of the superficial capillaries rupture, giving rise to ecchymoses, and in rare instances, possibly as the result of injudicious taxis, the congested vessels completely empty themselves into the sac, which is thus filled with clotted blood, the intestine in consequence becoming lax and yellowish-grey in colour. When the strangulation is relieved in this early stage, the bowel soon regains its former healthy appearance. If inflammation occurs, the surface becomes rough from the deposit of lymph, and entirely loses its shiny and polished aspect. Gangrene results partly from the prolonged stagnation of blood, and partly from the invasion of the intestinal wall by the *B. coli* and other anaerobic inhabitants of the gut, which, as soon as the vitality of the intestinal wall is sufficiently impaired, migrate through it, and by their development produce toxic bodies which still further assist the gangrenous process. As soon as it is established, the intestine turns an ashy grey or black colour, usually at one or more spots, which gradually spread, lose all lustre and polish, and after a time become soft, lacerable, and offensive. Gangrene is much more common in the femoral and umbilical forms of hernia than in the inguinal (19·5 per cent. in femoral against 6·1 per cent. in inguinal), it is generally developed in two or three days, but occasionally may supervene in less than twenty-four hours from the onset of the strangulation. It is more often seen in small herniæ of recent origin than in large old-standing ones. *At the point of strangulation* the gut is completely anæmic and liable to ulceration or gangrene, which may subsequently result in perforation; adhesions may, however, form between it and the neck of the sac, thus preventing contamination of the general peritoneal cavity. The intestine *above the site of strangulation* becomes paralyzed, and peristalsis is entirely arrested, even in a Richter's hernia. Fæcal material, accumulating and undergoing decomposition, gives rise to a catarrhal enteritis, and even occasionally to stercoral ulcers, which may perforate and cause general peritonitis; this, however, is not very common in external strangulation, since the small intestine is usually involved, and solid fæces are absent. In more chronic cases gangrene of the gut may be induced by the pressure of the accumulated contents and the action of the *B. coli*. The portion of the bowel *below the constriction* may be affected in a similar manner, owing to the arrest of the peristalsis, but to a slighter degree.

Omentum, when strangled, is at first congested and of a dark red or purplish colour, and later on infiltrated and matted together. After a time gangrene supervenes, and the omentum then becomes ashy grey or brown in colour, and is pultaceous and friable. It does not

become offensive unless associated with intestine, since it does not contain any intrinsic source of putrefaction. If, however, it has contracted adhesions to the sac, and no gut is present, the trouble may subside, since its vitality may be maintained through the adhesions, and a natural cure of the hernia may result.

The *sac* is usually distended with fluid, which at the commencement is serous in character, and perhaps blood-stained; this subsequently becomes turbid and mixed with lymph, and, finally, it is dark brown or yellowish-green, with a marked and most objectionable odour. Sometimes there is but little or no effusion of fluid, a condition generally due to complete strangulation of arteries and veins simultaneously, and often the precursor of early gangrene. The serous lining of the sac is but slightly affected in the early stages; as, however, the case progresses, it becomes inflamed and ultimately gangrenous from the activity of bacteria, which by this time have penetrated to the turbid serum contained within it. The skin and surrounding tissues become œdematous, congested, and crepitant, and finally a natural cure may be determined by sloughing and the establishment of an abnormal anus.

The **Clinical History** of a case of strangulation is usually so characteristic that there can be but little uncertainty as to the diagnosis. The *general* symptoms are similar to those described as occurring in all cases of acute intestinal obstruction. The patient during some sudden effort notices a severe pain, localized at first to one of the hernial regions, or referred to the umbilicus, this is accompanied by the usual evidences of shock, *i.e.* he feels faint, the pulse becomes slow and weak, the temperature falls, and the surface is covered by a cold, clammy sweat. This shock is often not very prolonged, and is associated with or quickly followed by vomiting, at first gastric, then bilious, and finally stercoraceous or fæcal. As this continues, the pain increases in severity, and radiates over the whole of the abdomen, which becomes tense, tender, and tympanitic. Symptoms of exhaustion supervene, caused partly by the pain and vomiting, and partly by the inability to take food, probably the absorption of toxic material from the intestines also assists in its production. Complete constipation is usually present, but the patient may pass flatus or fæces from the lower part of the intestine. The onset of gangrene is generally accompanied by a sudden fall of temperature and a cessation of pain, gradually the pulse becomes weak, rapid, and intermittent, the surface is covered by a cold sweat, the countenance becomes shrunken and drawn (the so-called *facies Hippocratica*), hiccough follows, and finally the patient dies, usually as a result of toxæmia due to the absorption of products developed either in the bowel wall or sac, or in consequence of acute generalized peritonitis.

Locally, a tumour is found in one of the usual sites of a hernia, or if already the subject of this condition, the patient may notice that his rupture has suddenly become larger. The swelling is irreducible, tense, extremely tender and painful, and without impulse on coughing. It is hard and rounded if bowel is involved, softer and more doughy to the touch if omentum. When gangrene ensues, the tension

within the sac is reduced, pain and tenderness cease, and the skin over the tumour becomes dusky, inflamed, and œdematous; finally, evidences of gangrene show themselves externally, the parts becoming dark in appearance, and soft and emphysematous to the touch. If the patient survives, the necrotic tissues separate, and an abnormal anus is produced either naturally or through the intervention of the surgeon. Suppuration within the sac is uncommon.

Occasionally, however, cases are met with in which the above-described signs are considerably modified, and gangrene of the gut may occur without the exaggerated phenomena of a serious toxæmic type indicated above. In one case the patient complained of no inconvenience beyond slight pain, although incipient gangrene was present; he walked into hospital saying that he never felt better in his life. In other cases the bowel itself may give way, either along the line of constriction or above it, and the general peritoneal cavity may then

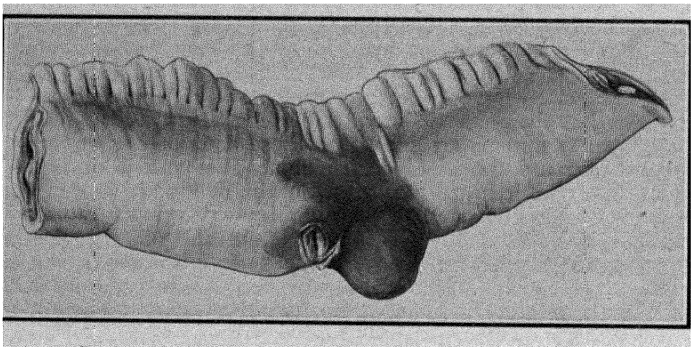

FIG. 914.—INTESTINE AFTER STRANGULATION IN A RICHTER'S HERNIA. A PERFORATION HAS TAKEN PLACE (UNIVERSITY COLLEGE HOSPITAL MUSEUM.)

be flooded with liquid decomposing fæcal material, which quickly determines a fatal issue.

The early symptoms arising from strangulation of a portion of the lumen of the intestine (*Richter's hernia*, Fig. 914) are sometimes less marked than when a complete loop is constricted, but the later phenomena are always very severe. It is usually of the femoral variety, and the ileum is most frequently involved. If less than half the circumference of the bowel is constricted, the obstruction is not always complete at first, flatus and fæces being sometimes passed, but where more than half the circumference of the bowel is engaged, complete obstruction from kinking or paralysis of the gut ensues. The vomiting is less marked than in other cases, and is not so commonly fæculent. The tumour produced is small in size, but tense and tender. It is quite possible, however, for it to be overlooked, even when the groin is examined, and the diagnosis is then likely to be made either on the operating or post-mortem table. The prognosis in these cases is always grave, partly from the difficulty experienced in diagnosis, partly from

the tightness of the constriction; death usually results from perforative peritonitis. A rare but dangerous type of strangulation occurs in the so-called Maydl's hernia. In this type of rupture a W-shaped loop of bowel is involved, the gut entering the hernial sac, then protruding again into the general peritoneal cavity, re-entering the sac before finally leaving it. Strangulation may result in gangrene of the free loop of intestine, and, because this is not contained in the confines of the hernial sac but in the peritoneal cavity, general peritonitis rapidly ensues.

The occurrence of *strangulation in a pure epiplocele* is very rare; the symptoms are vague in character, and the diagnosis is often difficult. The presence of a soft, doughy, tender swelling in any of the hernial regions, combined with pain, bilious vomiting, and possibly constipation, is always a significant feature. So long as no kinking of the bowel is caused thereby, the symptoms may remain indefinite, the vomiting never becoming fæcal; but as time goes on, arrest of peristalsis may lead to true obstruction, or even general peritonitis.

The mortality rate of strangulated hernia is much higher than one would expect in a condition that is easily diagnosed; recent statistics show that the mortality of external strangulated hernia is 17·8 per cent.

The **Treatment** of a strangulated hernia is usually operative, taxis rarely being used to reduce the contents.

Taxis is the term employed for the manipulation by means of which a hernia is reduced. In cases of strangulation it must be used with gentleness and great care, since the involved portion of intestine is congested and easily torn. The patient is laid on a couch with the head supported and the thighs slightly flexed, so as to relax the abdominal muscles. The fundus of the tumour is then grasped with one hand, and steady pressure made, having for its object the emptying of the congested blood-vessels and consequently a diminution in the size of the hernia; the fingers of the other hand manipulate the neck of the sac, in order that the part which has most recently been protruded may be first returned. The direction in which taxis is made varies in different types. In inguinal hernia it should be directed upwards, outwards, and backwards. In a femoral hernia which has extended beyond the saphenous opening, taxis is first employed downwards and inwards in order to make the gut re-enter the crural canal, and then finally backwards and upwards, the margins of the saphenous opening being relaxed by flexing and slightly inverting the thigh. In umbilical hernia, the pressure is mainly directed backwards.

In the past taxis has often been used injudiciously, and in cases where it could not be expected to do any good; the bowel has sometimes been ruptured or its wall bruised, the mesentery torn, and other serious results have followed. At the present day operative treatment for hernia is eminently successful, and open exploration prevents the likelihood of returning to the abdomen an infected and even gangrenous focus. *Taxis is permissible* when the hernia is of large size, particularly if inguinal, when the symptoms have a mild onset and do not become severe, and especially if taxis has been successful on former occasions. Reposition may be assisted in such cases by applying fomentations for

half an hour, followed by the use of an icebag, reduction sometimes taking place spontaneously or being brought about by taxis. The heat relaxes the tissues around the neck of the sac, and the effect of the cold is not only to constrict these tissues, but also to induce contraction of the intestinal blood-vessels and muscles. *Taxis is objectionable,* and if employed at all should be used very cautiously, when the hernia is small and tense, and particularly if femoral; when the onset is acute and sudden; when the symptoms are well marked, and especially if they become so in the early stages of the case, if strangulation follows on the first development of the hernia, and of course if the case has lasted for some time and fæcal vomiting is present. A final attempt may in suitable cases be made before operation when the patient is anæsthetized.

Persistence of Symptoms after Apparently Successful Taxis.—It happens occasionally that, although the surgeon may have apparently reduced the hernia satisfactorily, the symptoms of strangulation, *viz.* pain, vomiting, and constipation, persist. (i.) Infective gangrene may involve the released coil of gut and spread to the portion above it, causing death from peritonitis and toxæmia. (ii.) Ulceration and perforation may occur along the 'constriction groove.' (iii.) The rupture reduced may not be the one which has given rise to the symptoms, an internal hernia, or one in some other region, co-existing. (iv.) The strangulation may have been caused, not by the neck of the sac, but by a slit in the omentum contained in the sac. Reduction in such a case would, of course, not relieve the symptoms. (v.) A *volvulus* may have been present, either wholly or partly in the sac, and may have been reduced untwisted. (vi.) The hernial sac may have a diverticulum or pocket communicating with it at its upper end (intraparietal interstitial hernia), or it may be shaped like an hour-glass It is possible to reduce the intestine from the lower portion of this so-called *hernia en bissac* into the upper pocket, and then the symptoms persist. (vii.) Reduction *en bloc* or *en masse* ought never to be seen, as it can only occur when considerable, and therefore an unjustifiable, amount of force has been employed. The sac and its contents are together reduced from their superficial position to the deep aspect of the abdominal parietes, and the constriction remains. The hernia in such a case disappears gradually, and without the characteristic gurgle, but is liable to reappear after an interval. When occurring in the inguinal region, the canal appears to be unduly patent, and a tense rounded swelling can be detected at its upper end.

The **Operative Treatment** of strangulated hernia should always be undertaken as soon as possible. Nothing can be gained by waiting, whilst the delay of even an hour may make it doubtful whether the result will be successful or not. There is always sufficient time to permit of efficient purification of the parts, and it is desirable to empty the lower bowel by an enema, and to wash out the stomach. The administration of an anæsthetic needs care, and in the worst cases local infiltration or spinal analgesia should be employed. A suitable incision is then made down to the sac, which is recognized by its tense and rounded outline. It is cleared as far as possible from surrounding structures, and then carefully opened. The amount of fluid varies

much, and is sometimes very small, so that the possibility of injuring the bowel must be kept in mind. Having given exit to the fluid from the sac and noted its characters, the surgeon carefully examines the bowel or omentum. The cause of strangulation is then looked for and divided by a special hernia knife, which practically consists of a curved blunt-ended bistoury, the cutting blade being limited to an extent of about ¾ inch from the blunt end. If such is not to hand, an ordinary blunt-ended curved bistoury will suffice. The index-finger is employed to repress and guard the intestine, and acts better than a director, since intestine is liable to curl up on either side of the latter, and may thus be injured. The knife is then slipped on the flat under the constriction, and turned so as to divide it, it is better to nick it slightly in two or three places than to incise it by one deep cut.

The gut is carefully drawn down into the wound, and its condition at the site of strangulation examined; it is sometimes a matter of difficulty to decide whether it should be returned or not.

1. If the gut, though congested, shows no sign of gangrene or perforation, it may be safely reduced. This is not always a matter of ease, owing to the œdematous condition of its walls, which are stiff and firm. Slight enlargement of the opening will permit the gut to be returned to the abdomen. All manipulation directed to the intestine must, of course, be of the gentlest nature, since its congested state makes it more friable than usual. Omentum is removed or returned according to its condition. After the return has been effected, a radical operation for the cure of the hernia must be carried out if the condition of the patient warrants it.

2. If the gut has been more seriously damaged by the constriction and its condition is doubtful, it is well douched with warm saline solution, and the effect of this on the loop carefully noted. If, after a short time, the colour of the gut changes and becomes of a lighter hue, it is still alive and may be returned into the abdomen Gangrenous gut loses its sheen, is sodden and inelastic to the touch, and often the mesenteric vessels are thrombosed. Special note must be taken of the condition of the bowel along the line of constriction. In case of doubt it is returned just inside the abdomen and a large drainage-tube is inserted down to it. There is no need to fix the bowel; it is already inflamed and paralyzed, and hence will not change its position, especially if a small dose of opium is subsequently administered. In this way, even if gangrene or perforation occurs, a track is left for the escape of the contents, whilst a localized plastic inflammation will shut off the general peritoneal cavity. A fæcal fistula may thus be formed, but it often closes spontaneously at a later date.

3. If, on the other hand, the colour of the bowel is not affected by douching, or if patches of it show up definitely as damaged or gangrenous areas in the midst of the portion where the circulation is returning to the normal, and still more so if there is any suspicion of odour caused by the *B. coli*, the death of the bowel, or of a portion of it, is assured, and treatment must consist of intestinal drainage in the first place, followed by resection of the damaged area and anastomosis. In those cases where there is gangrene only at the site

of the obstruction, or where perhaps there is just one small area of non-viable gut, oversewing of these patches with Lembert's sero-muscular stitches may be sufficient.

It would appear at first sight that the most desirable treatment for a case in which the bowel is gangrenous would be an immediate enterectomy with restoration of the canal by suturing. Thereby an intestinal fistula, with its complications of sepsis and inflammation of the abdominal wall, would be avoided and the emaciation resultant on a high enterostomy prevented. Moreover, the dangers and difficulties of a second operation for closure of the fistula would not present themselves. This procedure, however, carries with it an immediate mortality of about 50 per cent., and, except in expert hands and with comparatively fit and youthful patients, should not be attempted.

In some cases who are less fit, but who will stand a little more than a simple enterostomy, the most desirable procedure is to draw the bowel well down, and at positions several inches away from the gangrenous gut perform a lateral anastomosis. Just above this junction a tube is passed into the bowel and is brought out through a stab incision away from the main wound. The gangrenous gut is then fixed in position by a glass tube passed through its mesentery, and the wound is closed snugly about it. The enterostomy tube is connected to a bottle, and the contents of the distended bowel are allowed to drain slowly away.

It is essential that care be taken not to allow the distended gut to empty itself rapidly, because the sudden relief of tension produces dilatation of the blood-vessels, and the increased blood supply leads to an excess absorption of toxic products present in the lumen and wall of the affected intestine.

At the end of twenty-four hours, when adhesions have glued the margins of the skin to the gangrenous gut, the latter is cut away and Paul's tubes are fixed into the free ends. These may be connected to one another in order that there shall be no loss of fluids to the body.

In about ten days' time the two ends are closed extraperitoneally, and, after carefully cleansing the wound, the peritoneum is opened and the bowel replaced into the general abdominal cavity.

Where the condition of the patient is such that it is impossible to do more than an exteriorization and resection of the gut, it is probably best to open the abdomen subsequently through a paramedian incision, and perform a lateral anastomosis before attempting to close the free ends as described.

The **After-Treatment** in cases of strangulated hernia is of the greatest importance. The patient is placed in bed, and absolute quiet is maintained, no food being allowed for twenty-four hours. If there is no pain, opium need not be administered, as it helps to maintain the paralyzed condition of the bowel; severe pain may, however, call for the hypodermic injection of a dose of morphia. Liquid food can usually be taken at the end of twenty-four hours. Saline should be administered rectally by the drip method, subcutaneously, or intravenously; this prevents thirst and replaces the chlorides that are lacking owing to the obstruction, and if the patient's condition remains

satisfactory, it is unnecessary to administer any purgative, the bowels often acting naturally; if they remain unrelieved for five or six days, a dose of castor oil should be given.

Post-operative Complications.—(1) *Vomiting* may persist for a time as a result of the anæsthetic. It loses, however, its fæculent character, and may generally be stopped by washing out the stomach. (2) The *Paralytic* condition of the gut may cause prolonged constipation, and may progress to gross ileus. The treatment of the condition is fully referred to in the appropriate section. (3) *Acute Enteritis* may arise either in the portion of strangulated gut or just above. This is usually indicated by localized pain and the passage of mucus, perhaps tinged with blood, which may be so abundant as to amount to diarrhœa; the vomiting, moreover, persists, but is no longer stercoraceous. It is best treated by the administration of bismuth combined with chlorodyne, whilst all solid food is interdicted. (4) It is possible that, although the gut looks healthy at the time of operation, its walls are in reality already infected, and, in spite of the relief of the constriction, *infective gangrene* may follow, causing death from peritonitis. (5) Occasionally acute septic peritonitis results from a localized perforation, either of a small gangrenous patch or from ulceration along the 'constriction groove.' *Treatment.*—The condition is obviously one of the gravest import, and must be dealt with actively if the patient is to be saved. The abdomen must be opened, the affected coil identified, and if need be resected, or fixed in the wound and opened for drainage purposes. The peritoneal cavity itself is dealt with according to the rules already given. (6) *Localized Peritonitis* may be looked on as a conservative measure, whereby Nature isolates some focus of danger from the general peritoneal cavity. Occasionally localized suppuration follows as the result of a limited ulceration or perforation of the gut; the pus must then be let out at the earliest possible moment, but a fæcal fistula is very likely to follow.

It is impossible to describe in detail every form of strangulated hernia. A few facts, however, must be stated about the more important varieties. In **Strangulated Inguinal Hernia** the constriction most commonly occurs at the neck of the sac, usually close to the external abdominal ring, as a result of the condensation of the surrounding tissues. The signs are generally very characteristic, and the condition can rarely be mistaken. Some difficulty may be experienced in distinguishing it from *inflammation of an undescended testis*; in this, however, there is no persistent vomiting or constipation, whilst the absence of the testis below, and the existence of the peculiar testicular sensation when the swelling in the canal is compressed, should make the diagnosis obvious. Occasionally the two conditions co-exist, and then a correct diagnosis, apart from an open exploration, may be almost impossible. *Torsion of the spermatic cord* and subsequent strangulation of the testis give rise to a swelling not at all unlike a strangulated hernia, but should be distinguished by the history and by careful palpation.

The operation is conducted along the lines already described for the radical cure. It is always wise to open up the inguinal canal by division of the external oblique, and in not a few cases this will suffice

to enable reduction to be effected, although it is desirable to open the sac and examine the bowel. If the strangulation persists, the constriction is divided by cutting directly upwards. It is often difficult in old-standing cases to be certain whether the hernia is direct or oblique, and by following this rule there is less likelihood of wounding the deep epigastric artery.

In **Strangulated Femoral Hernia** it is more common to find the bowel than omentum, and it is in this situation that partial herniæ (Richter's) are most frequently seen. A tense painful swelling is felt, situated in the neighbourhood of the saphenous opening, and the diagnosis from inflamed lymphatic glands and phlebitis of a varicose saphena vein may not be altogether easy, particularly if omentum alone is present. The history of the case and a careful consideration of the physical signs and symptoms should generally be sufficient to clear up the diagnosis.

The *Treatment* of this condition may be undertaken by either of the methods described above as suitable for the radical cure. If the inferior operation is undertaken, the sac is cleared and opened, the bowel examined, and the constriction, usually at Gimbernat s ligament, divided by cutting directly inwards. The plan already mentioned of nicking it in one or two places rather than of freely dividing it is especially desirable in this situation on account of the occasional abnormal course of the obturator artery along the edge of the ligament. Division of this artery would be recognized by the occurrence of free hæmorrhage after the use of the hernia knife, and would require for its treatment opening up of the external oblique above Poupart's ligament and securing the vessel by ligature. When the constriction is very tight, as in some cases of Richter's hernia, the introduction of the hernia knife under the constriction is difficult and liable to injure the bowel.

For these and other reasons, practice has of late years been tending more and more to the employment of the inguinal operation (Lotheisen's) in all cases of strangulated femoral hernia. The constriction is then under the eye, and the surgeon can see what he is dividing. The sac is opened from below, and its contents examined; the constriction is divided from above, and reduction can then be effected. The sac is freed from adhesions and displaced up through the canal and removed, and a radical cure follows. If gangrene is present, it is easy to carry the incision upwards and thus open the abdomen, and thereby resection, if necessary, can be effected more readily and safely.

It is quite possible to overlook the existence of a small Richter's hernia, and only to discover its presence during a laparotomy for an acute attack of obstruction. Under these circumstances the greatest gentleness must be exercised in any attempts to withdraw the bowel from the sac, for fear of tearing the gut and flooding the peritoneal cavity with fluid fæces. It is usually well to cut down on the hernia from outside, open the sac, and divide the constriction; and then, partly from without, partly from within, to reduce the strangled portion of bowel, which is brought to the surface and carefully examined. In many such cases gangrene is likely to follow, if not already present, and drainage of the gut by a Paul's tube will be required, and a subsequent enterectomy.

CHAPTER XXXIX

INTESTINAL OBSTRUCTION.

Intestinal Obstruction is a condition in which the natural onward passage of the intestinal contents is prevented. It may be associated with an interference of the vascular supply of the affected part of the bowel, when strangulation is said to exist. The obstruction may be acute or chronic, or the acute form may supervene on the latter condition.

Acute Obstruction.

The mortality of the acute condition, whether associated with or occurring apart from strangulation, is appallingly high, being in the region of between 40 and 50 per cent., this largely being due to late diagnosis. The classical symptoms and signs of acute obstruction are those associated with impending death, when surgical interference is too often unavailing.

There are many causes of acute intestinal obstruction, some of which have such differentiating features that they may be recognized; but before discussing individual conditions it is necessary to discuss the causation of the common manifestations of the disease.

The onset is sudden with severe abdominal pain, often referred at first to the centre of the abdomen, but perhaps localizing later to the seat of the obstruction. In cases accompanied by strangulation there is, from the first, severe sign of shock. The patient is collapsed, his skin is cold and clammy, the pulse is rapid and feeble and the temperature subnormal. Vomiting may occur from the start of the condition, and often the patient may pass flatus and fæces. These signs are less marked where strangulation is not a complicating factor, but violent intestinal colic, caused by the gut above the obstruction endeavouring to force the intestinal contents past the hold-up, is prominent. In cases where the abdomen is thin, it is often possible to observe waves of peristalsis passing down the intestine.

In the early stages the vomit consists of stomach contents, which are stained with bile, but in late cases it has a fæculent appearance, and an appearance which foreshadows an early end. The exact causation of this vomiting is unknown, some authorities attributing it to antiperistalsis, but there is no doubt that in part it is of nervous origin, as it occurs if omentum alone undergoes strangulation.

With this severe vomiting the patient rapidly becomes dehydrated and possessed of an insatiable thirst. His tongue becomes dry and furred, small ulcerations may occur about the mouth, and his superficial tissues are lax owing to the extreme loss of fluids that is occurring.

The abdomen rapidly becomes distended. This is due to two

factors: the first that there is an obstruction to the onward path of its natural contents, and secondly when the bowel is distended a vicious circle is set up in that the distension mechanically interferes with the blood supply to the bowel and, therefore, to the absorption of its gaseous contents which normally takes place. So with the increasing meteorism, as this distension is called, the blood supply to the gut diminishes with resulting increased dilatation. Obviously where strangulation is present the onset of dilatation is more rapid.

The extreme dilatation of the bowel gives rise to marked thinning of its walls, and ulceration may occur as a result of infection from the stagnating intestinal contents or by trauma from the intestinal contents. If of sufficient severity, perforation may ensue with a quickly fatal result from general peritonitis, whereas in other cases a localized peritonitis may ensue due to escape of bacteria through the damaged gut wall.

In the later stages the patient rapidly becomes worse and death ensues, the onset being quicker in cases of high obstruction than in that occurring lower down.

Numerous animal experiments have been carried out with a view to ascertaining the actual cause of death. It was originally supposed that these patients died of a toxæmia, the result of absorption of bacterial toxins absorbed from the damaged bowel, and antitoxin of the *B. Welchii* was often administered, this being thought to be the predominating organism. No evidence, however, has been produced to show that these bacterial toxins actually exist. Hartwell and Hongel showed that by administering large amounts of saline subcutaneously they were able to prolong the life of dogs in which a high intestinal obstruction had been induced for several weeks, the control animals dying in a few days. It was at once supposed that death in cases of high obstruction could be accounted for in terms of fluid loss and failure of absorption, but chemical and experimental investigation showed that not only fluid, but the actual salt, was essential. Moreover, in these cases it is found that there is a diminished secretion of urine and an increase in the blood urea—in fact a condition of partial uræmia exists which in some cases may pass on to a complete condition

It was thought that this explanation of the lethality of high intestinal obstruction would apply to that occurring lower down, but experiments have shown that life in animals is not much prolonged by the administration of saline in these cases. The actual causation of the sudden collapse that occurs is not certain, but it has been shown by Holt that there are absorbed certain toxic amino-acids and proteoses, although the toxins of *B. Welchii* are never absorbed. It is a well-known factor that death may occur after an apparently successful operation performed to relieve the obstruction. In this case it may be that the sudden emptying of a collapsed segment of the bowel may so increase its blood supply that toxic products present in the wall are rapidly absorbed and circulated with the onset of a profound toxæmia. The additional factor of the extreme degree of intestinal dilatation in these cases, which by stretching the mesentery must cause some reflex nervous stimulation, possibly plays its part.

In the case of the large gut obstruction is an acute phase superimposed on a usually chronic condition, and, even in these cases, the urgency of the condition is less. There is little dehydration and toxæmia, probably on account of a certain natural stasis of the intestinal contents at this level. In spite of this, the mortality of any big operative procedure in this region of the bowel is high, this probably being due to the extremely poor condition of many of these patients.

We have indicated that the obstruction in the bowel differentiates itself roughly by its manifestations according to the level at which it occurs, and in this respect three zones may be recognized: upper bowel obstruction, including the stomach, duodenum, jejunum, and the first part of the ileum; middle bowel or low small gut obstruction; and lower bowel or large gut obstruction.

Upper Bowel Obstruction.—In this category are included:

1. Acute dilatation of the stomach and duodenum.
2. Pyloric stenosis.
3. Internal hernia of the duodenal-jejunal flexure.
4. High adhesions.
5. Obstruction caused by (*a*) tight ligament of Treitz, and (*b*) in infants complete atresia of the duodenum.

The symptoms of this type are those of intense vomiting and rapid dehydration, followed by a condition of severe shock and collapse, with early death if the cause is untreated. There is abdominal discomfort and distension localized to the upper abdomen. In the case of an internal hernia of the duodenum the shock is usually more marked on account of the fact that strangulation is present.

The treatment of these cases, with the exception of the latter, is conservative and takes the form of the administration of intravenous saline by the continuous-drip method, washing out the stomach and, if necessary, leaving a tube *in situ* so that periodic aspiration may be carried out, and of postural drainage, in which the foot of the patient's bed is raised and he is nursed in the prone position in an endeavour to relieve the tension of the obstructing agency.

In cases of *duodenal hernia* a resonant swelling may often be palpated close to the midline, and laparotomy, after preliminary treatment by intravenous saline and stomach washes, should be carried out.

Two types of this hernia are found at operation: one, the left duodenal hernia, which is directed downwards and lies to the left of the transverse colon; and the right duodenal hernia, passing downwards and to the right. Every endeavour should be made to avoid cutting the neck of the sac, as either the inferior mesenteric vein or the superior mesenteric artery will be in danger. If stretching the ring does not avail, the volume of the contents of the hernia must be reduced by tapping the bowel to relieve the distension.

Although in cases where the obstruction is due to the ligament of Treitz, or a band, operation can be staved off by conservative treatment, numerous periodic subacute attacks may ensue, which, although there is not present absolute obstruction, are accompanied by pain and vomiting and some degree of collapse which will eventually

necessitate surgical interference. Complete atresia of the duodenum will give rise to absolute obstruction from the time of birth. A palliative enterostomy may be performed, but death is the usual termination.

Middle Bowel Obstruction.—The causes of this are many, the chief of which are as follows:

1. Obstruction by congenital bands or by adhesions.
2. Internal and external herniæ.
3. Intussusception.
4. Impaction of foreign bodies.
5. Presence of congenital atresia of the ileum.
6. Paralytic ileus.
7. Mesenteric embolism and thrombosis.
8. Volvulus.

This type of obstruction is less acute than that first considered. It has been seen, in discussing the cause of the toxæmia and collapse, that in this type it is probably due to the absorption of toxic products from the bowel, and these obviously take some time to accumulate. The condition is characterized by early abdominal pain of a colicky type, vomiting, and, after perhaps an initial passage of flatus and fæces, absolute constipation. A large proportion of these cases are accompanied by strangulation, so that early shock is often present and is severe. The abdomen rapidly becomes distended, but, until general peritonitis develops, there is absence of tenderness on palpation. Visible peristalsis, passing down the coils of the intestine in a zigzag fashion, may sometimes be seen in cases where the abdominal wall is not covered by a gross degree of fat.

It is important in all these cases to auscultate the abdomen, because the increased peristalsis is very obvious, and differentiates the condition very easily from internal hæmorrhage or peritonitis, where the bowel is in a state of quiescence and the sounds are absent.

In all cases where the early shock is extreme, the pulse rate is rising, and, perhaps in later cases, signs of general peritonitis may have ensued, strangulation will be diagnosed, and with a minimal delay, in which the shock is treated, operation must be carried out at once. In the early cases of simple obstruction operative treatment is the method of treatment of choice, but in late cases the post-operative results subsequent to the relief of the obstructing agent are so bad that conservative treatment, in the event of no other complication, is best.

It may be possible to diagnose the causes of the condition, and these will be considered in detail.

1. **Obstruction by Congenital Bands or by Adhesions.**—This is the commonest cause of obstruction and accounts for some 70 per cent. of cases.

(*a*) A Meckel's diverticulum may remain attached to the umbilicus.

(*b*) Secondary to inflammation an appendix epiplocele, a diverticulum, or a segment of the omentum may become attached to the abdominal wall or another viscus, this fibrinous attachment becoming eventually drawn out to produce a cord or band (Fig. 915).

(*c*) Following appendicitis the appendix may be reduced to a fibrous cord and, if not bound down, may give rise to an obstructing band.

(*d*) Following on any inflammatory condition in the abdomen such as appendicitis, salpingitis, peritonitis, or subsequent to operative procedures, there is an exudate which eventually becomes converted into fibrous adhesions and bands. In these cases the obstruction usually comes on at a considerable time, measured in months or even years, after the initial cause; but in some cases where there has been an excessive exudate of lymph, as may occur in acute appendicitis, there is sufficient to glue adjacent coils of intestine together, often causing a kinking of the bowel, with resultant acute obstruction coming on a week or so after the removal of the inflamed viscus.

Obstruction in these cases may be caused by a loop, usually of the lower few feet of the ileus, passing over or under a band during peristaltic waves and being unable to return, or on other occasions the band may be of sufficient length to form a noose through which a knuckle or loop of gut may protrude. Sometimes a band may press on the bowel, constricting it against the posterior abdominal wall.

Although complete obstruction is the initial complaint in some of these patients, many of them will give a history suggestive of past subacute attacks characterized by colicky pains, perhaps some vomiting, and a period of difficulty with the bowels.



TESTINE IN A CHILD BY A BAND ADHERENT TO A MESENTERIC GLAND (UNIVERSITY COLLEGE HOSPITAL MUSEUM.)

These cases are usually accompanied by strangulation, so that operation should be carried out as soon as the diagnosis is made. The operative procedure may be simple, consisting in the division of a constricting band, or the adhesions may be so complex as to necessitate a short-circuiting. In cases where gangrene is present the affected loop of bowel must be removed, and only in desperate cases should it be exteriorized and drained. Pressure gangrene at the site of the obstructing band should be looked for, and, if present, oversewing with Lembert's sutures is effective. An endeavour should be made to obliterate raw areas, because if this is omitted a recurrence of the symptoms at a subsequent date is likely.

2. **Internal and External Herniæ.**—In addition to the external herniæ, which have been discussed in a previous chapter, obstruction and strangulation of the bowel may occur if the gut enters one of the fossæ of the peritoneum formed during development. Although there are dozens of these fossæ, those in which strangulation is likely to occur are as follows:

(*a*) The duodenal fossæ, of which there are two of importance: (i.) the paraduodenal fossa, which has in its anterior wall the inferior mesenteric vein; (ii.) the right duodenal fossa, which runs under the superior mesenteric artery or some of its branches. These internal herniæ have never been known to contain anything other than small intestine.

(*b*) Fossæ in relation to the cæcum, two of which are important: (i.) the ileo-cæcal fossa and (ii.) retrocæcal fossa running behind the cæcum.

(*c*) The retrosigmoid fossa, which opens downwards and to the left, and lies behind the pelvic mesocolon in front of the division of the left common iliac artery. In this category may be included those cases of obstruction due to congenital or acquired deficiencies in the diaphragm. In the former variety there may or may not be a true hernial sac, according to the stage of development at which the hernia joined, whereas in the latter a true hernial sac may or may not be present.

Rarely the intestine may undergo obstruction and strangulation by passing through the foramen of Winslow.

Diagnosis.—The symptoms of this type of obstruction resemble those of external hernia, but obviously the position and presence of the hernial sac is not so obvious. The patient is seized with abdominal pain and vomiting, the degree of collapse depending on whether strangulation is present or not. As has been shown in the general discussion of obstruction, the degree of vomiting depends on the height of the lesion.

On abdominal examination it is sometimes possible to palpate a mass in the position of one of the internal hernial orifices, but if this is unavailing operation must not be delayed.

Treatment.—Laparotomy is carried out, and if strangulation is present this will often reveal itself by the presence of blood-stained fluid in the abdomen. By tracing down the distended gut the site of obstruction is readily found. The reduction, however, often presents difficulties in that, on account of the proximity of vessels, the neck of the sac cannot be cut through. Where reduction cannot be effected by gentle manipulations, the gut must be tapped by a trocar and cannula, every precaution being taken to prevent contamination of the general peritoneal cavity. This greatly reduces the volume of the contents of the hernia and allows of their ready reduction. The site of perforation by the trocar is surrounded by a purse-string suture and invaginated. Subsequent treatment of the bowel in case of gangrene is similar to that indicated above.

3. **Intussusception.**—By *Intussusception* is meant the protrusion or invagination of one part of the intestine into another, giving rise to the condition illustrated in Fig. 916. The constituent parts are seen more diagrammatically in Fig. 917. The upper portion is always prolapsed into the lower, except occasionally during the irregular peristalsis which takes place during the death-throes. The invaginated portion (*a*) is known as the *intussusceptum*, whilst the lower portion (*b*) into which it is protruded is known as the *intussuscipiens*. An intussusception, then, consists of three layers—the outer or *ensheathing* layer (I.), an inner or *entering* layer (III.), and between the two the *returning* layer (II.). Not only does the intestine enter, but with it a certain portion of the

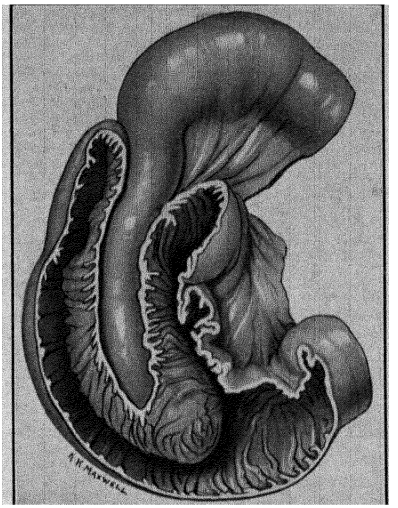

FIG 916.—INTUSSUSCEPTION (ROYAL COLLEGE OF SURGEONS MUSEUM.)

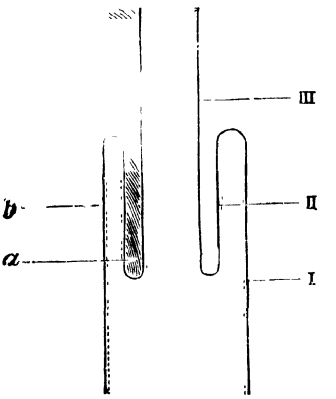

FIG 917.—DIAGRAM OF INTUSSUSCEPTION.

a, Intussusceptum, *b*, intussuscipiens, I, ensheathing layer, II, returning layer, III, entering layer.

mesentery, and it is to the constriction of the vessels contained therein, and later on, possibly to their complete obstruction, that the more serious phenomena are due, *e.g.* gangrene, perforation, or rupture of the gut. In addition to this, actual obstruction to the passage of the intestinal contents may be brought about by the traction of the mesentery, which renders the orifice of the intussusceptum slit-like, by the swelling and congestion of the intestinal wall, or perhaps by the impaction of a portion of undigested food within the lumen of the gut. Peritonitis usually follows, being possibly due to the invasion of a portion of the damaged intestinal wall by the *B. coli* or other intestinal organisms. If limited in extent, it may merely lead to irreducibility of the intussusception, owing to adhesions forming between the serous

coats of the entering and returning layers. In other cases, and especially when ulceration or gangrene is present, a diffuse peritonitis may be lighted up, and this may result in the death of the patient. The bowel above the site of invagination becomes dilated in the more chronic cases, and possibly stercoral ulcers may then develop.

The **Cause** of intussusception is generally stated to be irregular and violent peristalsis, however induced, whether by the presence of irritating ingesta, or by the existence of polypoid tumours, malignant growths (Fig. 918), or possibly worms, or even an attack of violent diarrhœa; the presence of scybalous masses of fæces may also lead to its occurrence. In a few cases injury, *e.g.* blows on the abdomen, or severe strains during jumping, have been held responsible for its onset, but very frequently no cause can be assigned

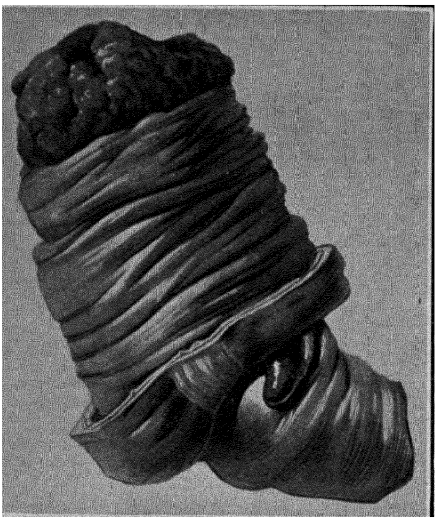

FIG 918.—HYPERTROPHIC CANCER OF THE CÆCUM INVAGINATED INTO THE TRANSVERSE COLON

This growth was successfully removed, and an ileo-colostomy performed The patient was alive and well ten years later.

Intussusception is met with in four chief **situations:** (1) The *ileo-cæcal* variety is much the commonest, constituting 44 per cent of all cases (Fig. 919) In it the ileum is protruded into the colon, the apex of the intussusceptum being formed by the ileo-cæcal valve. Owing to the great mobility of the ileum, a considerable portion of gut may be thus invaginated, and a good many cases have been observed in which it has actually projected through the anus. (2) The *enteric* variety involving the small intestine comes next in order of frequency, being met with in 30 per cent. of the cases. It is most often seen in the lower jejunum, and is rarely of great size. (3) The *colic* form may occur at any part of the colon or rectum, and, owing to the fixity of this portion of the gut, is limited in extent. It is met with in about 18 per cent. of the cases. (4) The *ileo-colic* occurs in 8 per cent only, in it the ileum is prolapsed through the ileo-cæcal valve, which for a a time retains its normal position; but after the intussusception has attained a certain size the valve and cæcum are also invaginated into the ascending colon (Fig. 920). In each of these varieties, except the

last, the intussusception grows at the expense of the external or ensheathing layer, the apex of the protrusion being always formed by

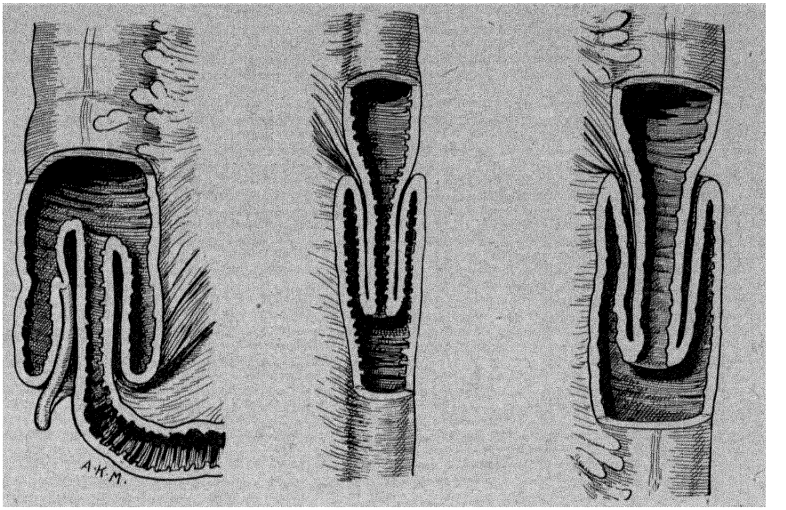

FIG. 919.—VARIETIES OF INTUSSUSCEPTION

the same portion of gut, but in the ileo-colic variety, as just stated, it increases by the passage of more and more of the ileum through the

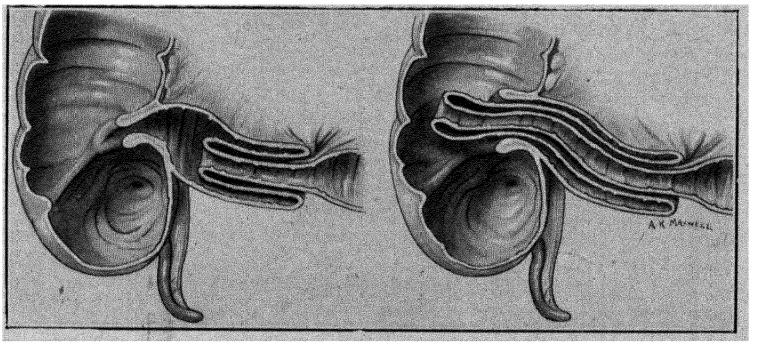

FIG. 920.—THE FORMATION OF AN ILEO-COLIC INTUSSUSCEPTION
An enteric intussusception is first formed, and this gradually passes through the ileo-cæcal valve

valve; after a time this stops, and is replaced by the ordinary type of growth.

In infants the ileo-cæcal valve possesses very large lips which contain a large amount of lymphoid tissue. There are often enlarged glands in the ileo-cæcal angle. Both of these are factors in the causation of intussusception (fig. 921).

Intussusception is occasionally met with as a *post-mortem* phenomenon, resulting from the irregular intestinal movements which occur during the death crisis. The condition is recognized as being of this nature by the absence of inflammatory signs, by the fact that it is sometimes due to a reverse peristalsis, and by more than one intussusception being present.

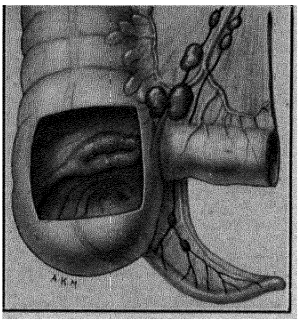

FIG. 921.—THE ILEO-CÆCAL ANGLE OF AN INFANT, SHOWING THE LARGE LIPS TO THE ILEO-CÆCAL VALVE AND GLANDS IN THE ILEO-CÆCAL ANGLE.

The **Clinical History** varies according to whether the condition is acute or chronic.

Acute Intussusception occurs most frequently in infants under two years, being the most common cause of obstruction at this age. The onset is sudden, the child being attacked with severe pain, possibly localized and more or less paroxysmal at first, but rapidly becoming continuous and diffused over the abdomen. This is followed by vomiting, which, however, is less severe than in acute strangulation, and not so often fæculent. The patient rarely suffers from absolute constipation, but diarrhœa and the discharge of blood-stained mucus, perhaps associated with tenesmus, and often without fæces, are common. Collapse soon supervenes, and in the worst cases this may be so severe as to kill an infant within twenty-four hours; otherwise a fatal issue from exhaustion or peritonitis is reached within a week. On examining the abdomen, but little distension or tenderness is noticed, unless acute peritonitis is present; in more than half the cases a distinct tumour can be felt, cylindrical in outline, and sometimes described as 'sausage-shaped,' following the course of the intussusception and generally curved, owing to the traction of the mesentery. In the ileo-cæcal variety it extends from the right iliac fossa across the brim of the pelvis to the left, the colon being dragged downwards. This may be associated with an absence of resistance in the right fossa, which feels empty, constituting what is known as the 'signe de Dance.' In other cases the tumour may be more limited, and distinctly movable. The rectum should always be carefully examined, and preferably under an anæsthetic, so as to permit a thorough bimanual examination of the rectum and abdomen to be made.

A natural cure occasionally follows, resulting either from spontaneous reduction, or from sloughing of the intussusceptum, the peritoneal cavity is then shut off by a circle of plastic lymph uniting the ensheathing and entering layers of the gut. When the latter takes place, the

subsequent condition is not very satisfactory, owing to the formation of a fibrous stricture.

Chronic Intussusception is referred to here for the sake of completeness. It occurs more frequently in adults than in children, the onset being gradual and the course varying widely in different cases. The patient complains of intermittent attacks of pain of a colicky nature, which recur at intervals, and become more frequent and prolonged as the case progresses. Vomiting is often but little marked during the intermissions. The bowels are irregular in their action, and there is sometimes a blood-stained mucous discharge. The general condition is not at first much affected, but as the case progresses emaciation and general asthenia may supervene. On examination the abdomen is found to be flaccid and free from tenderness, although visible coils of intestine may be observed in some cases, and perhaps a tumour felt. The symptoms are rather those of subacute enteritis and chronic obstruction than of strangulation, and the case may be brought to a fatal termination either by an acute attack of obstruction or by peritonitis. It may, however, last a long time before being recognized.

Treatment.—In acute intussusception the patient should be at once placed under the influence of opium, in order to still peristalsis and prevent the increase of the tumour. It is often possible to reduce, and at the same time obtain an X-ray record of the case, by running in barium at a height of 1½ to 2 feet above the abdomen. If the child is examined under a screen, the apex of the intussusception can be observed to be gradually pushed backwards as the barium runs in. Should this not succeed, laparotomy should be performed without delay, and, indeed, where skilled surgical help is available, operation is usually relied on solely. Babies have but little power of resistance, and therefore rapidity combined with gentleness of execution is an essential element for success. If the infant is in a state of shock, hypodermic injections of saline solution should be administered and the child must be kept very warm. Gas and oxygen with local novocaine infiltration is the best form of anæsthesia A vertical paramedian incision is the best, and no undue escape of bowel should be permitted. The swelling when found is, if possible, drawn up outside the abdomen, and reduction is attempted by manipulation. The intussuscipiens is grasped and compressed by the palm of the left hand, and the right hand steadies the intussusceptum. Gradually, by a mixture of pressure and kneading, the intussusceptum is delivered from the grasp of the intussuscipiens, but no attempt must be made to pull out the intussusceptum. Complete freedom is essential if there is to be no recurrence, and the last dimple may be difficult to obliterate.

In a small number of cases reduction by this method fails. Gentle attempts to stretch the obstruction, caused by the tightness of the junction between the returning and ensheathing layers, are made with the fingers or by stretching open a pair of Spencer Wells. If failure still results, this obstruction must be incised longitudinally, the rest of the abdominal cavity having been carefully packed off, when ready

reduction is obtained. Suture of the incision into the bowel is then performed.

In those cases when on reduction of the intussusception gangrene has been suspected, resection must be carried out, although the mortality of the operation is high.

Maunsell's operation, designed for irreducible cases and those in which gangrene has supervened, consists in suturing the ensheathing to the entering layer and then incising the ensheathing layer over the intussusception, finally excising this and suturing its two layers.

Chronic intussusception is more favourable in its prognosis. It is frequently unrecognized until an exploration of the abdomen is made, and hence reduction by inflation is not commonly attempted. In some cases the tumour may be reduced by simple manipulation, but as a rule too many adhesions are present. Excision of the mass should then be undertaken, and the results gained have been very encouraging.

4. **Impaction of Foreign Bodies.**—*Impacted Foreign Bodies*, which may cause intestinal obstruction, are of three types. gall-stones, foreign bodies that have been swallowed, or intestinal concretions (enteroliths).

Gall-stones cause obstruction only when of large size, and then usually gain entrance to the intestine by ulceration from the gall-bladder into the duodenum (Fig. 922). The usual site of impaction is in the lower ileum. Women over seventy are most often the subjects of this condition, and there may be merely a history of some inflammatory lesion in the region of the gall-bladder, and none of biliary colic. These patients frequently suffer from intermittent colicky pain, together with subacute attacks of incomplete obstruction, which, though severe for a time, pass off. Sooner or later a final acute attack supervenes, which begins suddenly with pain, followed by vomiting, which is constant and copious, and in twenty-four to thirty-six hours becomes fæcal. The obstruction is often incomplete, flatus and even fæces being occasionally passed. The abdomen is soft and flaccid, and the affected coil and the gall-stone are rarely to be felt. Necessarily the symptoms vary with the site of impaction, usually becoming more urgent as the duodenum is approached. Death results from peritonitis or exhaustion.

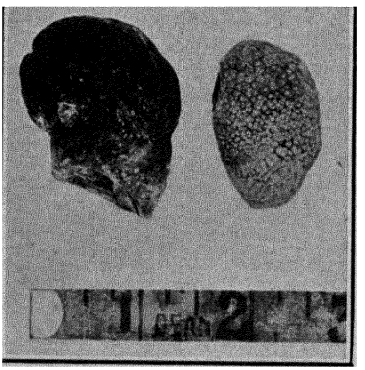

FIG. 922.—TWO LARGE GALL-STONES REMOVED FROM THE ILEUM

5. **Presence of Congenital Atresia of Ileum.**—In these cases complete or partial atresia, or the presence of a complete or partial septum, may exist, usually towards the lower end of the ileum. In the complete cases absolute obstruction is present from birth, whereas in the incomplete variety the existence of a small fæcolith in later

life may precipitate this condition. An attempt may be made in infants to divide the septum, if present, or if there is atresia the only hope is a short-circuiting anastomosis; but in view of the fact that these subjects will not stand any gross operative procedure well a fatal termination is usual.

6. **Paralytic Ileus.**—This is a condition in which without any organic obstruction there is an increasing distension, first of the small intestine, then of the duodenum and stomach, and finally of the colon—a distension which may ultimately produce the death of the patient. The condition is most commonly associated with abdominal operation in which there is a gross degree of trauma to the bowel and the mesenteries, and especially is it likely to occur if in addition sepsis is present. It is undoubtedly a final stage in the pathology of cases suffering from simple obstruction from strangulation, and it does occur, rarely, associated with conditions of toxæmia, as in uræmia and pneumonia, or in conditions of severe shock such as may occur in severe injuries or in torsions. Peritonitis is always associated with paralytic ileus, and occasionally it may be an association of gall-bladder or renal colic.

The condition is one in which there is an interference with the normal waves of peristalsis passing along the bowel. This may be due to (*a*) excess sympathetic stimulation, as occurs, for example, in shock and in operative manipulations where the bowel is much pulled upon; (*b*) to anoxæmia of the bowel wall, as in cases of strangulation or even simple obstruction, in which latter case the wall is so distended as to interfere with its intrinsic blood supply; (*c*) lesions of the nervous plexus of Auerbach, situated between the internal and external longitudinal coats of the intestine and its myoneural junctions, as occurs, for example, in conditions of toxæmia, or peritonitis, or of strangulation.

Following one of the predisposing conditions mentioned, there is gradual and increasing abdominal distension, associated with vomiting and much discomfort and aching due to the stretching of the muscle fibres of the bowel wall. The patient's pulse rate rises steadily, and ultimately death may result from exhaustion and toxæmia due to absorption from the dammed-up intestinal contents, or, owing to the gross thinning of the wall of the bowel secondary to the distension, ulcerations and necrosis with resulting peritonitis may supervene.

Auscultation with a stethoscope will reveal complete absence of the sounds normally present, showing that peristalsis is completely in abeyance.

Treatment.—Obviously associated conditions, such as peritonitis, strangulation, the presence of a renal calculus, or pneumonia, should be treated primarily.

In most cases the surgeon comes into contact with these patients following operation, and many can be avoided by efficient preoperative technique. Under no circumstances should violent purgatives be given before operation, as by so doing the colic produced exhausts the bowel and makes it more prone to this condition, and, nevertheless, gentle emptying with a mild purgative or enema is desirable to remove the intestinal contents, which are usually in a

condition of stenosis if the patient has been confined to bed for a day or two. He should, prior to operation, be given a light, low residue diet containing ample glucose and fluid content, and pre-operative rest of body and mind should be induced, if required, by the administration of drugs.

At operation an ample and efficient incision should be made in order that the abdominal manipulations that may be required do not result in unnecessary trauma. Great aid to the operation is afforded by efficient anæsthesia, and in this respect the perfect relaxation obtained by the use of spinal anæsthetics should recommend these. However, it does seem that even in efficiently administered ether or chloroform anæsthesia the incidence of subsequent paralysis is greater than with the use of spinal anæsthetics. Care must be taken to expose as little bowel as is possible, and this must be protected from exposure to the air by wrapping it in towels wrung out in hot saline. Wherever a septic organ is being removed, or an anastomosis performed, the area of operation should be well protected from the general abdominal cavity by suitable packs. By the exercise of these precautions, and by the use of gentleness and care, the incidence of post-operative paralysis of the gut is reduced to a minimum.

Treatment.—Paralytic ileus occurring as a post-operative phenomenon usually starts about the second day. The natural reaction of the bowel following any operative procedure of magnitude is one of quiescence, and this must be encouraged by the administration of sedatives, and for the first twenty-four hours or so nothing must be taken orally. During this period, however, it is necessary to replete the body fluids by giving a rectal or intravenous drip saline with 5 per cent. glucose.

In most cases a mild purgative or enema at the end of this period will restore the normal function of the bowel, but in those cases which do not react, and which start to become distended, further treatment is essential to prevent gross ileus and death. A continuous-drip intravenous saline and glucose transfusion should be set up, and, if the patient is vomiting, the stomach must be washed out, and it is a good plan to leave a tube in the duodenum so that continuous suction of the intestinal contents may be procured.

Acetylcholine is sometimes of value, 1 grain being given at two-hourly intervals for several doses, and injections of 5 c.c. of prostigmine sometimes produce good results. Large enemata are of little value. If the patient is still distended, intravenous pituitrin should be administered, up to 1 c.c. being given in a dilution of 1 in 10 with normal saline. It should be injected slowly, and coramine and adrenalin should be at hand in case there are any signs of cardiac failure. The results are uniformly good, the patient passing flatus and fluid stools during the actual injection.

In the past, in patients who have been grossly distended an enterostomy has been performed, but nearly always with a fatal result, and in view of the success associated with the intravenous administration of pituitrin, should not be employed.

Spinal anæsthesia has been given in some cases with good results.

7. **Mesenteric Embolism and Thrombosis.**—This may be due to pathological conditions of the veins or arteries. Thrombosis of the veins may be secondary to portal obstruction, or to infection arising from such a lesion as acute appendicitis. In the case of the arteries it is usually an embolism arising from the heart or the aorta which gives rise to the condition. Rarely thrombosis of the branches of the superior mesenteric artery may produce it. Behind any embolus there is an area of thrombosis, so that the affected area of gut gradually increases.

The clinical picture is one of acute obstruction, associated usually with bleeding into the bowel and its passage per rectum. If an enema is given, this may be returned blood-stained. There is often an associated clinical condition of the heart which may be recognized as likely to produce emboli.

Treatment consists in immediate laparotomy and resection of the affected area of bowel.

8. **Volvulus of the Small Intestine.**—This is a rare condition due to some pathological contraction of the root of the mesentery tending to approximate its ends. It therefore follows conditions such as tuberculous peritonitis, or some other form of localized infection, the coils of gut rotating around the sclerosed mesentery. A pre-operative diagnosis is rarely made, the clinical conditions merely pointing to an acute obstruction of the middle bowel type associated with strangulation.

Treatment consists in immediate laparotomy and untwisting of the volvulus. If this is impossible, the distension of the bowel must be reduced by tapping it with trocar and cannula, and in cases where gangrene is present resection with end-to-end anastomosis must be performed.

Low Bowel Obstruction.—These obstructions, with the exception of volvulus, which is considered separately, are usually acute conditions superimposed or chronic, and even so their acuteness is less compared with conditions in the small gut. They are the result of neoplastic growths, diverticulitis, impaction of fæcal material or foreign bodies, stricture following inflammatory processes, or chronic intussusception.

The patient will usually give a history of increasing constipation, often alternating with periods of diarrhœa, the latter being due to gradual disintegration of the contents of the bowel above the site of obstruction associated with irritation of the mucosa. He may have noticed that the abdomen has been increasingly distended. Finally comes the time of complete obstruction with absolute constipation and increasing abdominal distension located in the flanks and across the abdomen in the region of the transverse colon. Vomiting is present, though at first not severe, and the patient suffers considerably from the colicky pain due to peristalsis.

Nearly all these cases are those of simple obstruction without strangulation, and, in view of the high mortality of operative procedures in these cases, every endeavour should be made to relieve the acuteness of the condition by resort to enemata. If, in spite of this, the condition is not alleviated, operative procedures must be minimized as far as

possible. They will consist, if the patient is desperately ill, of a blind cæcostomy, and in other cases of a laparotomy with a colostomy or cæcostomy above the site of obstruction, the surgeon in all cases resisting the temptation to deal primarily with the condition causing the obstruction.

Volvulus is the most common cause of acute primary obstruction of the large intestine. By it is meant a rotation of the gut upon its own mesenteric axis in such a way as to interfere not only with the passage of the intestinal contents, but also sooner or later with the circulation, determining a condition of strangulation. Occasionally a similar result is brought about by the intertwining of one coil, usually of small intestine, with another. The sigmoid flexure is the part generally affected, although it occurs in the cæcum when there is a definite mesentery, or, as has been noted, in the small intestine. In the former situation it is predisposed to by a long narrow sigmoid mesocolon, so that the two ends of the loop are brought closely together; this condition may be of congenital origin, but is usually due to the traction induced by prolonged chronic constipation; a distended sigmoid hanging into the pelvic cavity drags upon and elongates the mesocolon, thereby approximating the two ends of the loop, and necessarily causing a slight obstruction at these spots. Some irregular movement of the gut or of the abdominal walls suffices to cause rotation of the pedicle, and thus brings about the volvulus. When once present, plastic peritonitis soon fixes the coil, and then the pressure on the vessels causes venous congestion and such obstruction to the arterial supply of the gut as almost certainly to end in its death. Distension of the coil with gas from decomposition of the retained fæces aggravates the condition.

Symptoms.—Volvulus is rare before the age of forty, and apparently occurs more often in the male sex. A history of chronic constipation precedes it, but the acute symptoms start abruptly. Pain is always present, at first intermittent, but finally constant, and there is usually tenderness over the sigmoid flexure. The pain, vomiting, and collapse are not so severe or marked as in other forms of strangulation, but abdominal distension from excessive flatus, and resulting dyspnœa and thoracic embarrassment, are very distressing. Tenesmus is occasionally present. A localized peritonitis is usually developed, but sometimes it becomes diffuse. Natural cure is unknown, the patient dying either in five or six days from collapse and interference with respiration, or at a somewhat later date from peritonitis.

Treatment.—In those cases seen within a few hours of the onset of the condition, an attempt may be made to relieve the tension in the distended loop of pelvic colon by passing a flatus tube and trying to manipulate it into the bowel. If this is successful, there will be the passage of much flatus and a diminution in the distension. In other cases a laparotomy must be carried out and, under direct vision, a further attempt made to pass the tube. If this fails, the loop must be manually unwound, a procedure which sometimes necessitates relieving the tension in the distended loop by tapping it with a trocar and cannula, subsequently invaginating the site of puncture.

Chronic Intestinal Obstruction.

The **Causes** of chronic obstruction are very numerous, and, looked at from an anatomical standpoint, may be divided into the following groups:

1. Intra-intestinal conditions, *e.g.* impaction of fæces, foreign bodies, etc.

2. Affections of the intestinal wall, such as stricture, new growths, especially those of a cancerous type, adhesions or matting together of coils of intestine, contraction or kinking of the gut from mesenteric gland disease, etc.

3. Compression of the bowel by tumours, cicatricial bands, etc., developing outside the intestine.

Fæcal impaction and the development of a cancerous growth are far and away the commonest causes of chronic obstruction.

The **General Symptoms** of chronic obstruction are more or less as follows: The patient suffers from gradually increasing constipation, alternating occasionally with watery diarrhœa, spurious in nature, and set up partly by a catarrhal enteritis due to the irritation of retained fæces, partly by decomposition of the fæcal material. At irregular intervals more severe symptoms arise, consisting of pain, colic, vomiting, and absolute constipation, owing to some temporary complete obstruction, as by the impaction of a mass of undigested food or fæces, assisted perhaps by a valve-like fold of mucous membrane across the passage. The abdomen becomes distended, and coils of gut may be seen in a condition of active peristalsis. These attacks usually pass off after a time, a copious evacuation of the bowels taking place, either naturally or after the administration of a purgative. Finally, one of these seizures persists and destroys the patient, either by exhaustion or by perforation followed by peritonitis, unless suitable treatment is promptly adopted. The vomiting is never such a marked feature as in acute obstruction, until the final stage, when it becomes fæcal. The abdomen is always more or less distended and tympanitic, and its contour varies with the site of the obstruction; if this is situated above the ileo-cæcal valve, the swelling is mainly central, but if in the rectum or lower portion of the colon, it is most marked in the flanks. Distended coils of intestine can be plainly seen through the abdominal walls in thin subjects, as also evident peristalsis. When arising from simple stricture, no tumour is to be felt; but if due to malignant disease, and if the abdomen is not very distended, the growth may possibly be detected.

Fæcal Impaction occurs in adult females who have previously suffered from chronic constipation. The cæcum and sigmoid flexure are the most common seats of obstruction, but the transverse colon is not unfrequently affected (Fig. 923). A doughy tumour may often be felt at one of these spots, which can in some cases be indented with the fingers, whilst in others it may be of stony hardness. The surface of the mass is usually more or less nodulated, and the intestine tender from the accompanying inflammation. The temperature is often raised from toxic absorption through the intestinal wall, and there

may even be a rigor. The acute symptoms are always preceded by a prolonged period of malaise and ill-health, the appetite being defective, the breath offensive, and the tongue foul. On rectal examination the presence of scybala may often be detected.

The special symptoms arising from the other conditions which give rise to chronic obstruction, such as stenosis of the bowel, have been already referred to.

The **Diagnosis** of chronic obstruction is obvious, but it is often by no means easy to ascertain the exact cause of the trouble. A thorough investigation of the case, according to the plan given hereafter, must be undertaken, and by this means some conclusion may be arrived at as to the nature and seat of the obstruction.

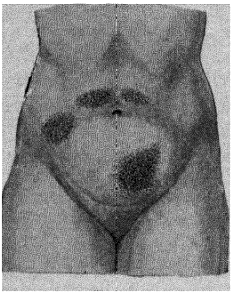

FIG. 923.—DIAGRAM TO INDICATE THE USUAL SITES OF FÆCAL IMPACTION — VIZ, THE CÆCUM, TRANSVERSE COLON, AND SIGMOID

The **Treatment** of chronic obstruction is always a matter of difficulty and anxiety, owing to the uncertainty often felt as to the diagnosis. It ought to be possible, however, to decide whether the block is located in the large or small intestine, since the character of the abdominal distension and the symptoms are tolerably distinctive in the two forms.

If the case is not of the most urgent type, the patient is put to bed, the diet restricted to fluids, and belladonna administered. At the same time copious enemata should be given two or three times daily, and preferably in the genu-pectoral position, or lying on the right side with the pelvis well raised. Purgatives are studiously avoided, as also opium, probably the patient has taken plenty of the former before coming under observation, whilst the latter, although it may check vomiting and relieve pain, is certain to mask symptoms, and thus prevent the true course of the disease from being watched. Should the symptoms be urgent from the commencement, or the treatment suggested fail, the question of operation has to be faced. If the obstruction is located in the small intestine, a laparotomy must be undertaken, using the same precautions as in acute cases. If the cause of the trouble is easily found, a coil situated just above is withdrawn from the abdomen, opened, and a Paul's tube tied in so as to allow retained fæcal material to escape. It is wiser not to deal with the local trouble until the urgent symptoms have disappeared. If, however, the patient's condition is serious, and the site of obstruction cannot be readily found, any distended coil (ileum or jejunum for choice) may be withdrawn and opened. The practice of allowing numerous coils of intestine to escape in order to facilitate the exploration of the abdomen is not to be recommended.

When the cause of the obstruction is located in the large intestine above the pelvic colon, cæcostomy is usually required, followed by excision at a later date. If the rectum or sigmoid flexure is clearly

the seat of the trouble, iliac colostomy is the operation of choice. When there is no indication as to the part of the colon involved, cæcostomy should be undertaken as a preliminary measure.

In chronic peritonitis, where the intestines are hopelessly matted together, but little can be done beyond the administration of enemata and possibly abdominal massage. The history of the case will generally suffice to suggest its nature, and operative treatment should then be avoided.

Fæcal impaction requires the regular and repeated administration of large enemata, given through a long tube, and belladonna together with calomel may also be administered. Should hard scybala be lodged in the rectum, it may be necessary to break them up *in situ*, and remove them piecemeal.

Diagnosis and Method of Examination of a Case of Intestinal Obstruction.

A grave responsibility rests upon the medical attendant in every case of obstruction. The condition is incompatible with life beyond a few days, and the time occupied in observing the patient and making up one's mind as to the nature of the case is valuable time lost, which may ruin the patient's chances of recovery. There are three things to be avoided in conducting a case of this nature: (i.) *Purgatives*.—The patient has probably taken plenty before sending for assistance, and the only result to be expected is an increase of pain and vomiting. (ii.) *Opium* has its place in the treatment of obstruction, *viz.* in relieving the agony associated with its onset; but beyond this it merely masks symptoms, and can do no good but comfortably to conduct the patient to the grave. It causes intestinal paralysis, and therefore may check the most distressing symptom, vomiting, but it aggravates the condition which needs treatment. (iii.) *Delay* in sending for surgical assistance is responsible for more deaths than is the condition itself. When once the gut has become generally paralyzed, there is but little hope for the patient.

In the investigation of a case various problems of some difficulty have to be solved, and it is well to undertake this task methodically.

1. The medical attendant must satisfy himself that obstruction is actually present, and not merely aggravated constipation. In the latter, however, flatus passes readily, and the general condition is not much impaired. As already mentioned, when complete arrest of flatus and fæces has lasted for twenty-four hours, and especially if turpentine enemata have been administered during that period, a diagnosis of obstruction is justified, and if abdominal pain and vomiting co-exist, the presence of some serious lesion is certain.

2. It is essential to determine whether the obstruction is paralytic or mechanical.

3. The question as to whether the lesion is *acute* or *chronic* must next be settled. Initial severe pain and collapse, the rapid onset of vomiting, a localized spot of fixed tenderness, and the quick depreciation of the patient, all point to some acute vascular lesion of the

intestinal wall, which will prove fatal in a few days unless suitably treated. On the other hand, chronic cases are often preceded by constipation and other troubles of defæcation; they come on gradually and are at first unaccompanied by constant pain and vomiting, although colic of a severe type may be present. The examination of the abdomen is also of the greatest assistance; in acute cases intestinal paralysis dominates the picture; in chronic cases, vigorous peristalsis can be felt and often seen, unless the patient has been left too long.

4. An effort must be made to determine the *site and nature* of the lesion. As to the question of site, the following points may be noted:

(*a*) When the *upper part of the small intestine* is involved, the vomiting is early, tumultuous, and persistent; the vomit is bilious, but not fæcal. Abdominal distension involves the epigastrium, and particularly the stomach. The lower part of the abdomen may be retracted. Collapse is early and rapidly increases. The thirst is terrible; the urinary secretion is slight or even suppressed; gas and fæces may pass from the lower bowel.

(*b*) When the *lower part of the small intestine or cæcum* is involved, fæces and flatus cannot pass; the vomiting becomes offensive, and later fæcal; meteorism is marked, and involves the central part of the abdomen, the flanks not being affected. In chronic cases peristalsis is very evident.

(*c*) When the *colon* or *rectum* is the site of obstruction, the symptoms are more chronic as a rule, and even in acute cases, such as volvulus, the initial collapse is slight. Vomiting is later in appearing, but may, of course, become fæcal. Meteorism may be very marked, and involves the flanks as well as the centre; sometimes it is possible to recognize that the lesion is not lower than the splenic flexure by distension of the left flank being absent. The condition of the cæcum must be carefully investigated, for on it the stress of all large intestine obstruction falls. It is sometimes possible to see that it is distended, and on palpation it may be felt to harden under the examining hand. Under these circumstances a diagnosis of a block below the ascending colon can usually be ventured.

The determination of the *nature* of the case will largely turn on the patient's previous history, and not uncommonly one has to admit that, although one can locate the site of mischief, there is no clue as to its nature beyond the generalizations learnt from statistics.

The actual examination of the patient is carried on along the following lines:

1. The **Previous History** of the case should be carefully gone into, in order to ascertain whether or not the patient has suffered from biliary colic, chronic constipation, acute diffuse or localized peritonitis, uterine derangements, syphilis, or dysentery, etc.

2. The **History of the Present Attack** should then be ascertained, noting especially the manner of onset, whether acute or gradual, the duration of the symptoms, and whether or not preceding subacute attacks have occurred from time to time.

3. The more prominent **Symptoms** must then be considered.

(*a*) *Collapse* is due partly to reflex nervous disturbance, partly to the absorption of toxic materials, and partly to withdrawal of fluid from the body as a result of the vomiting; the portal area is also much engorged, and this adds to the want of fluid in the systemic circulation. The nervous cause is most active in the early stage of acute obstruction, especially in infants, whilst the toxic is largely responsible for the exhaustion seen at the end of an acute attack or in the chronic variety. Hence collapse is early in acute cases, late in chronic. Moreover, the higher the lesion, the greater the shock, owing to the fact that the upper portion of the bowel is more intimately associated with the sympathetic nervous centres.

(*b*) *Pain* is a very marked symptom, being usually referred at first to a little above the umbilicus, and is more severe in lesions of the small intestine than in the colon. It varies greatly with the completeness or not of the obstruction. When the obstruction is only partial, the pain is intermittent; but when the block is complete, the pain becomes continuous. Hence in acute strangulation pain is almost invariably constant, whereas in stricture it is markedly intermittent and of a colicky nature. The amount of pain, moreover, varies with the nervous excitability of the patient; it is increased by anything which induces peristalsis, *e.g.* food or purgatives, and it is diminished on the supervention of gangrene.

(*c*) *Abdominal tenderness* is rarely observed in the early stages, being caused by the onset of peritonitis.

(*d*) *Vomiting* is an almost invariable accompaniment of obstruction. Its cause has been already discussed. When the obstruction is situated in the jejunum or upper part of the ileum, the vomiting is never absolutely fæcal, although, if it has been temporarily checked by opium, the ejecta may be exceedingly offensive and dark in colour, owing to decomposition; fæcal or stercoraceous vomiting can only come from an obstruction to the lower ileum or colon.

(*e*) *Constipation*, although usually present, is not necessarily absolute, as it is possible for the lower bowel to be emptied in cases of obstruction, whilst the patient sometimes passes a motion as gangrene supervenes or death is approaching.

4. A most careful **Physical Examination** must now be instituted.

(*a*) *An inspection* of the uncovered abdomen should first be made. The amount and character of the distension is observed, and whether or not it is situated in the centre, as when the small intestine is involved, or in the flanks, when the obstruction is in the rectum or sigmoid flexure. The existence of visible peristalsis or enlarged coils of intestine should be noted; such are rarely seen in the acute cases, but may be very evident in the chronic forms. Sometimes one coil remains persistently distended and always at the same spot; its appearance always suggests that the site of obstruction is not far away. Sometimes a series of distended coils are seen crossing the abdomen like a row of organ pipes. The rise and fall of the abdomen during respiration should be watched to ascertain whether the movements are equal on both sides, or if any prominence, such as would be caused by a tumour, is noticeable. The general condition of the patient,

whether emaciated or not, as also the appearance of the face and the position in which he lies, should be observed.

(*b*) All the normal and abnormal hernial apertures are thoroughly investigated, and a careful examination made from the rectum and vagina.

(*c*) The abdomen is carefully palpated, so as to ascertain the existence of any tumour or increased resistance of the abdominal walls.

(*d*) *Percussion* and *auscultation* may also throw light on the case.

(*e*) A rectal examination should always be done, as it frequently gives valuable information.

(*f*) Finally, in chronic cases, some information may be gained by the use of *enemata*. When the obstruction is low down and not far from the anus, it may be impossible to introduce more than a small quantity of fluid, and this in spite of modifying the position. Too much reliance, however, must not be placed on this sign. It is also desirable to auscultate the colon during the administration of a large enema; it is sometimes possible to hear gurgling sounds as far round as the cæcum, indicating that the large intestine is free from obstruction. We would call attention here to the fallacy of using a long tube in the expectation of being able to pass it into the sigmoid flexure. A careful study of the rectum and its valves will show the difficulty of this, whilst the use of the genu-pectoral position renders it unnecessary.

CHAPTER XL.

AFFECTIONS OF THE RECTUM AND ANUS.

THE rectum from the anatomical standpoint consists of the lowest 5 inches of the intestinal canal, but for the surgeon it represents the lower 6 or 8 inches, which can be reached more or less from the anus.

Examination of the Patient.

The fact that a patient's symptoms are referred to the rectum does not obviate the necessity for a careful examination of the abdomen.

Position of the Patient for Rectal Examination.—The two positions which are used are the left and right lateral, in both of which the

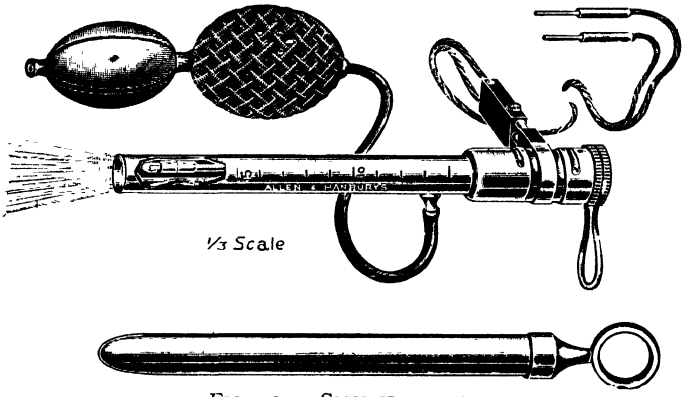

FIG 924.—SIGMOIDOSCOPE.

patient lies on the appropriate side with his knees drawn well up towards the chin. Of these two positions the latter is preferable, because in palpating for piles the pelvic colon tends to drop towards the right side, causing venous congestion, thus rendering the hæmorrhoids easily recognizable with the examining finger. Moreover, growths high up in the sigmoid; if not adherent, tend to fall against the finger passed into the rectum and may be felt through its wall.

In the right lateral position the left index finger is used for examination and in the alternative position the right index; very rarely the knee-elbow position, when the patient kneels on the couch, bearing the weight on the elbows and knees, is used.

Digital Examination.—With a good light the condition of the anus and surrounding skin should first be carefully examined for skin

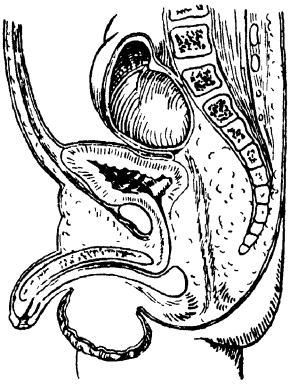

FIG. 925.

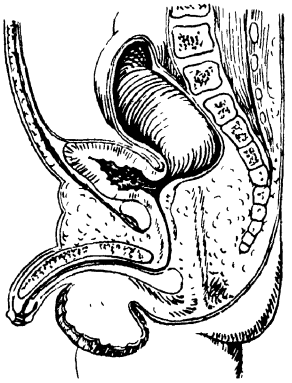

FIG 926.

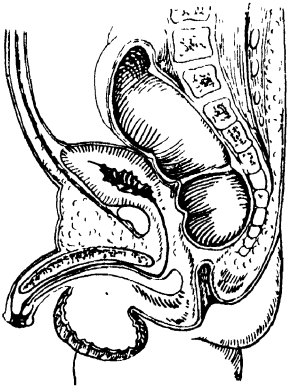

FIG. 927.

changes, tags, the orifices of fistulæ, etc., and the anal margins gently separated to determine the presence of a fissure. The index finger, well lubricated and pressed against the lateral wall, is gently inserted. The majority of rectal lesions occur within the last inch of the bowel. After this has been carefully examined the finger is passed as far as possible, and finally a bimanual examination is made.

Proctoscopy.—There are many different forms of proctoscope, the essentials of which are that it should give a good view and that its insertion and manipulation should not inflict pain. A good light is essential, and this may be obtained by the use of a head lamp or a light fixed to the base of the proctoscope. In this way the lower 4 inches of the bowel can be examined.

Sigmoidoscopy is employed for examining the upper part of the rectum and the lower sigmoid. The instrument (Fig. 924) consists of a hollow straight tube, 14 inches long, with its length marked on the outside so that one may know how far it has been introduced. Suitable arrangements are made for distending the bowel with air, and for illuminating and seeing its interior. An obturator is used to facilitate its introduction in the first instance, but this is withdrawn when it is within the bowel. There is no danger in the use of the sigmoidoscope provided that throughout the instrumentation the lumen of the bowel is kept well in view.

Congenital Malformations of the rectum and anus are fortunately extremely rare. At an early stage of fœtal life the lowest part of the hindgut is a common chamber, the cloaca, into which the allantois opens in front and the hindgut above. With

FIGS. 925-927.—THREE VARIETIES OF MALFORMATION OF RECTUM

In Fig. 925 the bowel ends at the brim of the pelvis in a cul-de-sac, and there is no evidence of an anus; in Fig 926 the anus is absent, and the bowel opens into the bladder, in Fig. 927 the anus and bowel are only separated by a thin septum.

development the hindgut grows backwards beyond its cloacal opening, forming the post-allantoic gut, and its communication with the cloaca becomes closed. The cloaca forms no part of the rectum, but becomes the trigone of the bladder. The post-allantoic gut acquires its communication with the outside of the body by its junction with an epiblastic ingrowth from the perineum, known as the proctodeum.

The rectum and anus are thus developed from three distinct embryonic structures: (1) the hindgut; (2) the post-allantoic gut; (3) the proctodeum. In the adult the junction of (1) and (2) is at the reflection of the peritoneum from the anterior surface of the rectum, and that of (2) and (3) at the level of the anal sinuses. Failures in typical development result in various clinical types of malformation:

(1) The original communication with the cloaca may persist. In the male the usual situation is in the region of the trigone or the prostatic urethra (Fig. 926); in the female in the posterior vaginal wall. This condition is usually associated with:

(2) Non-development or arrested development of the post-allantoic gut. Here the rectum may end at the level of the peritoneal reflection with or without a communication or a fibrous cord attaching it to the prostatic, urethral, vaginal or anal region. The anus in these cases may be normal, absent or mal-developed.

(3) Imperforate anus. A complete membranous septum may persist between the post-allantoic gut and the proctodæum placed about an inch from the anal verge and bulged downwards by retained meconium, or it may have been partially obliterated, forming a stricture.

The **Treatment** of these cases must be instituted at once. Anal stenosis is treated by dilatation with the finger or bougies. Where only a membranous septum persists between the rectum and anus, this should be incised and cut away, followed by the regular passage of the finger or bougies to prevent stenosis. When the anus is absent, whether or not there is any indication of a rectum, such as bulging in the perineum or crying, the child is placed in the lithotomy position and a perineal incision is made through the site of the anus, and carried upwards and backwards along the concavity of the sacrum strictly in the middle line for not more than 2 inches. It is an open question whether it is justifiable to proceed further by removing the coccyx and part of the sacrum, since the membranes of the spinal cord extend much further down in the infant than in the adult. If found, the dilated and bulbous cul-de-sac is drawn down as far as possible, and opened towards its posterior aspect; the mucous membrane is then, if feasible, stitched all round to the skin so as to leave no surface to granulate, thereby preventing subsequent stenosis. In cases where no rectum is present, iliac *colostomy* must be performed. When once a passage for the fæces is established, abnormal openings into the bladder, etc., usually close without difficulty. In a female infant the rectum may open into the vagina, and if the opening is sufficiently large no immediate operation is necessary. An operation can subsequently be performed when the child is much older.

Various malformations in connection with the post-anal gut have been already described.

Injuries of the rectum are usually due to falling on some pointed body, such as a stick or railing, or upon a piece of broken china, but are sometimes caused by the forcible introduction of foreign bodies by lunatics or criminals. They may merely involve the mucous membrane, or may pass through the perineal tissues, enter the bowel, and penetrating the upper wall lay open the peritoneal cavity. Hæmorrhage, pain, and shock follow, and acute peritonitis if the serous membrane has been wounded. Inflammatory troubles may involve the peri-rectal tissues, and sinuses may result from suppuration. A thorough examination must be made under an anæsthetic, and the wounds either sutured or left open to granulate. In women the recto-vaginal septum may be torn, but the surgeon need be in no great hurry to interfere if the wound is but small, as it often closes of itself; if, however, the lesion is of some length, immediate suturing may be desirable. If the peritoneal cavity has been laid open, a laparotomy is usually required in order to cleanse it and close the wound; if, however, the wound is small and the rectum at the time of injury empty, it may be justifiable to delay interference till some sign of inflammatory reaction shows itself; a piece of sterilized gauze in the rectal wound will often suffice to limit the inflammatory mischief. Peri-rectal complications are dealt with as they arise. In serious lacerated injuries, such as those which occur in war, a colostomy is often required as a primary measure; later, when the injury to the bowel has been repaired, the artificial opening may be closed.

Foreign Bodies are derived from various sources. Generally they have been swallowed, and have traversed the intestinal canal. Fish-bones and small tooth-plates are most commonly seen, and they usually lodge just above the anus in one of the so-called 'pouches of Morgagni.' They give rise to severe pain, especially on defæcation, and possibly to some form of peri-rectal abscess. Large gall-stones are sometimes lodged in the lower end of the rectum, just above the sphincter. Foreign bodies may be introduced from without, and cause various forms of traumatic inflammatory lesions.

Inflammation of the Rectum (*Proctitis*) causes pain of a bearing-down character, a sensation of fulness, constantly recurring tenesmus accompanied by a discharge of mucus, muco-pus, or blood. It may arise from any local source of irritation, *e.g.* the presence of foreign bodies, or of a polypus, parasites, or piles; gonorrhœa is an occasional cause—in women possibly owing to infection from the vaginal discharge, in men probably from direct infection. In the past much proctitis arose from the failure to wash thoroughly or change gloves when passing from one patient to another. It seems that the rectum is well able to deal with its own organisms, but not with those transferred to it on a dirty glove. In dysentery and in ulcerative colitis the rectum is often involved as well as the colon. Proctitis may have an acute or an insidious onset without apparent cause. If the inflammation becomes chronic, a simple fibrous stricture may result. In acute proctitis the mucosa is œdematous, inflamed, and covered with muco-pus; in chronic forms it is thickened, granular, and bleeds easily when touched with a probe. Ulcers are not commonly seen.

Treatment.—Any exciting local lesion should first be excluded and a smear of the pus examined. In acute cases the patient is confined to bed, and if necessary a starch and opium enema, or belladonna and morphia suppositories, given to relieve pain and tenesmus, while liquid paraffin will prevent the formation of hard fæcal masses. Rectal irrigations of saline or hazeline, 2 drachms to the pint, may be used, and potassium permanganate in early gonococcal cases.

Chronic proctitis is often extremely resistant to treatment. Irrigations and the occasional local application of silver salts are used. Injections of bismuth subgallate (5 per cent.) in olive oil and irrigation with zinc sulphate have been advocated (Lockhart Mummery). It is important to recognize and treat any secondary anæmia which may occur in these patients. A palliative colostomy may be necessary where stricture has developed.

Thread-worms (*Oxyuris vermicularis*) are the most constant source of irritation of the rectum in infants and children. They give rise to pruritus ani, a discharge of muco-pus, and many reflex phenomena. In treating a case of this type, a sharp purgative may be given every morning (*e.g.* pulv. scamm. co., grs. v.), and salt and water or an infusion of quassia used as an injection. Sometimes this is ineffective, and it is possible that the cæcum or even the appendix is the main site of lodgment of the worms; santonin may then be necessary in order to clear the intestinal canal.

The **Bilharzia hæmatobia** is occasionally found in the rectum as well as in the urinary passages. It gives rise to papillomatous polypi, within which the ova can be readily demonstrated; these are rounded or oval bodies, differing from those found in the urine in that they possess a lateral spine-like projection, whilst in the latter it is terminal. Considerable tenesmus, diarrhœa, and discharge of blood are present, and the hæmorrhage may become so abundant as to destroy the patient's life, especially when urinary symptoms are co-existent. This condition is found in some portions of Egypt, where it is very common, and in other tropical regions. The living ova can be destroyed by intravenous injections of tartar emetic, but the papillomata persist, and need to be dealt with by operation. Removal of isolated masses by injection with pure carbolic acid, or even by diathermy, is usually of little value; the only successful measure for extensive disease has been found to be excision of the affected mucous membrane.

Rectal and Peri-rectal Suppuration is not uncommon, and is very liable to lead to the formation of fistulæ. It may be due to the impaction of foreign bodies, the extension of ulcerative processes, or the suppuration of piles. Occasionally the trouble starts in the skin around the anus, and sometimes the pus reaches the peri-rectal tissues from other viscera, *e.g.* the neck of the bladder, prostate, etc., or from above, in connection with spinal or pelvic abscesses. Not unfrequently the abscess is attributed to injury or to cold, as from sitting on a damp stone or a draughty closet; but probably these are merely the final exciting agents.

1. An **Anal Abscess** forms immediately under the anal integument, and superficial to the external sphincter (Fig. 928, 4), it is usually due

to inflammation of one of the numerous sebaceous follicles in that locality. It may be acute or chronic, and is one of the most frequent causes of fistula-in-ano. It must be freely opened throughout its whole length, and packed. The packing is removed in this and all fistulæ at the end of about forty-eight hours, after which the wound is allowed to granulate from the bottom.

2. A **Submucous Abscess** (Fig. 928, 2) usually results from a suppurating internal pile. The pus spreads up and down under the mucous membrane, and gives rise to a blind internal fistula (Fig. 928, 4). It is generally confined to one side of the bowel, and causes great pain on defæcation. Digital examination is extremely painful. **Treatment** consists in draining it at the most dependent spot, close to the anus, but it is often necessary to slit up the undermined mucous

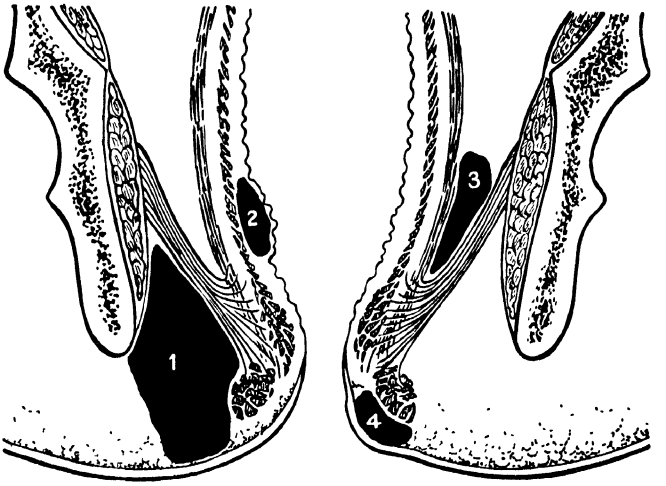

FIG. 928.—DIAGRAMMATIC SECTION OF ABSCESSES SITUATED NEAR THE LOWER END OF THE RECTUM.

1 Ischio-rectal abscess, 2, submucous abscess, 3, pelvi-rectal abscess, 4, anal abscess

membrane. If, however, the abscess extends high into the rectum, division of the mucosa may give rise to serious hæmorrhage. In order to obviate this a probe director is insinuated into the lower opening and is pushed through the mucosa at its upper extremity. Two silk ligatures are then tied to the end of the probe, which is manipulated so that its end protrudes through the anus. The ligatures are then drawn down through the fistulous track and separated from the probe. One is tied to include the mucosa to the right of the track the other to include the mucosa to the left. The intervening area sloughs and the abscess heals by granulating from the bottom.

3. **Acute Ischio-rectal Abscess** is due to infection of the loose fatty tissue filling the ischio-rectal fossa (Fig. 928, 1), the organisms reaching it either through the perineum or from the bowel. The *B. coli*

is usually present, and in consequence the pus has the ordinary characteristic offensive odour. A red, painful swelling is noticed on one side of the anus, which is at first hard and brawny, but soon becomes soft and fluctuating. Defæcation is exceedingly painful, as also digital exploration of the bowel, and the patient is unable to sit with any comfort. If left to itself, it may burst internally or externally, or in both directions, and a fistula-in-ano is very liable to follow. An abscess in one ischio-rectal fossa may spread across behind the anus to involve the other side, and the fistulous opening which is often present in these cases is usually found in the mid-line posteriorly between the internal and external sphincters.

Treatment.—Any abscess in this region should be opened at once, since any delay increases the risk of a fistula. Under efficient anæsthesia, a cruciate or T-shaped incision is made, and the flaps cut away to allow adequate drainage (Fig. 929). If the abscess has extended to the other ischio-rectal fossa, both sides and the communicating track should be laid open and lateral relieving incisions made. If a subsphincteric fistula is present, it should be laid open by passing a probe through the internal orifice between the two sphincters into the bowel and dividing the external sphincter.

At the end of the operation the wound should be tightly packed with wool soaked in 1 in 500 perchloride of mercury, and subsequent to its removal irrigations and baths should be employed. It is essential that all wounds in this region should heal from the deepest part. Gauze may be lightly introduced to the bottom of the wound, but tight packing, except for that initially used to control oozing, delays healing and prevents free drainage.

4. **Chronic Ischio-rectal Abscess** is usually met with in run-down or tuberculous individuals during young adult life, and is not unfrequently a complication of phthisis. A deposit of tuberculous material replaces the fat ordinarily occupying the ischio-rectal fossa, and this after a time undergoes caseation or forms an abscess, which gradually spreads without pain or other inflammatory disturbance, and may extend very widely. After it has burst, the orifices of sinuses may be found at a considerable distance from the anus. **Clinically,** an indurated and painless mass forms in the fossa, and slowly spreads, softens, and is transformed into a more or less extensive abscess sac; this is associated with some general asthenia, slight pyrexia, and a certain degree of localized pain. Operative **Treatment** is desirable in most of these cases, and if possible before suppuration has occurred, incision, removal by a sharp spoon of all tuberculous tissue, and dressing the wound with gauze infiltrated with iodoform are the essential elements. Where extensive sinuses or fistulæ exist, treatment as for fistula-in-ano may be required, but it is wise not to attempt too much if serious pulmonary mischief is present. Treatment of the sanatorium type must, of course, be instituted in all cases.

5. The **Pelvi-rectal Abscess** (Fig. 928, 3) consists in a localized collection of pus in the loose cellular tissue above the levator ani between it and the rectum. It may be secondary to rectal lesions, such as penetration of the wall above the internal sphincter or extension of

ulceration from a carcinoma; but not uncommonly it is caused by pelv cellulitis, or suppuration in the mesorectum, prostate, etc. Tl ordinary phenomena of a deep abscess are produced, and the pus ma burrow downwards through the levator ani to the ischio-rectal foss or may travel up and involve the pelvic peritoneum. Sometimes extends around the bowel, causing one type of horseshoe fistul Other collections of pus may find their way into this region fro different parts, *e.g.* a psoas abscess from spinal disease, append abscesses, etc. Rectal examination indicates the existence of a painf swelling high up in the bowel. As soon as a diagnosis is made, tl abscess should be freely laid open on to the surface in the ischio-rect region, and to facilitate drainage a small incision may be made into tl levator ani in the direction of its fibres. Never must the abscess l laid open into the bowel or permanent incontinence will result. Usual the abscess will heal only at the top, leaving a residual track to tl surface. This again must l laid open fully at a secor operation, and a third fourth may be required befo healing is complete. Of cours an abscess which is secondai to a tuberculous spine is ɛ exception to this rule.

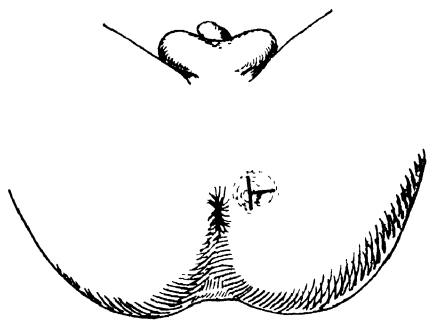

FIG 929 — SITUATION OF T-SHAPED INCISION REQUIRED FOR OPENING AN ISCHIO-RECTAL ABSCESS.

6. Occasionally a *diffuse* for of cellulitis involves the pei rectal connective tissue, n uncommonly resulting in ga grene (*gangrenous periproctitis* It is most likely to be seen weakly individuals and asthen old people. The suppuratic may extend above the levat ani, and lead to deep fistulo tracks. The parts must be freely opened up, the gangrenous tissi scraped away, and the raw surfaces treated with peroxide of hydroge The wounds are then packed with iodoform gauze, and subsequent well irrigated twice a day. Free stimulation is always required these cases, but the prognosis is very bad.

Fistula-in-Ano.—This term is somewhat loosely applied to all co ditions in which suppurating tracks are found in the neighbourhoc of the anus and the lower end of the rectum. Many of these are mere sinuses which have but one opening. Fistulæ are usually due to rect or peri-rectal suppuration, but sometimes result from the ulceration a simple, syphilitic, malignant stricture of the gut, the inner openir being either above, in the substance of, or below the stricture, this more likely to be the case when the fistulæ are multiple.

The Varieties of Fistulæ are determined by the arrangement of tl lymphatic plexuses around the rectum and anus, and according the infection of these channels so the different forms of fistula aris This classification conforms with the teaching of Ernest Miles.

1. **Subcutaneous.**—There is a plexus under the skin in the perianal region, infection of which results in the formation of a subcutaneous fistula. Three varieties of them are recognized (Fig. 930, D): (*a*) the blind external, in which the orifice is external to the anus; (*b*) the blind internal, in which the orifice is just inside the anal canal and nearly always associated with a fistula; and (*c*) the complete fistula, in which are present both internal and external orifices.

Treatment.—This is simple. A probe-pointed director is passed along the track of the fistula and the overlying tissues are divided longitudinally. A few lateral relieving incisions are made and the ulcer allowed to granulate from the bottom.

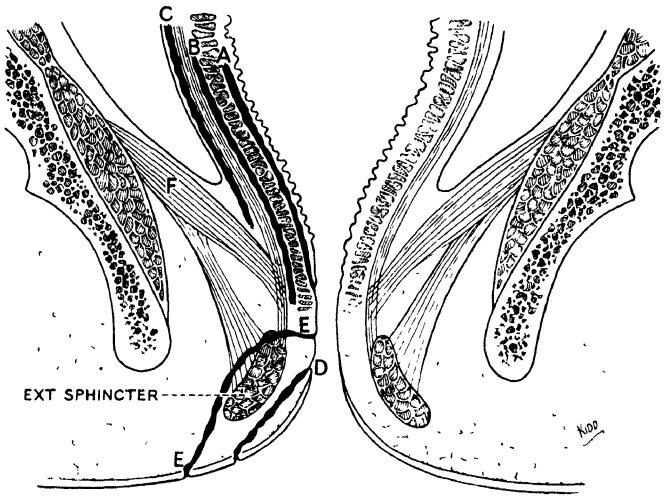

FIG 930.—VARIOUS FORMS OF FISTULA-IN-ANO.

A, Submucous, B, intermuscular, C, pararectal, D, subcutaneous, E, subsphincteric; F, levator ani

2. **Subsphincteric.**—Here the plexus external to the external sphincter is infected and the infection is prevented from spreading to the ischio-rectal fossa by a downward expansion of the longitudinal coat of the rectum to the skin of the perianal region. There are three varieties: (*a*) blind internal, with the opening situated between the internal and external sphincters; (*b*) complete, where in addition there is an external opening on the skin just lateral to the external sphincter; (*c*) bilateral, in which lateral extensions have carried the infection in front of the anus (Fig. 930, E).

Treatment.—In all cases the track must be laid open and relieving incisions made. This will necessitate division of the external sphincter muscle, but this is of no consequence. In those cases in which the external orifice is situated on or in front of a transverse line dividing the anus the internal orifice between the two sphincters is situated

radially opposite. Where, however, the external orifice is behind this line the track takes a curved course backwards to open in the mid-line posteriorly

3. **Submucous.** There are four varieties of this (Fig. 930, A): (*a*) blind external, in which the pus under the mucosa has gravitated downwards to open at the anal margin, (*b*) blind internal, in which the opening of the fistula is inside the lumen of the bowel, usually associated with a tear of the mucosa, or a torn anal valve or polyp; (*c*) complete, in which both internal and external orifices are present, (*d*) bilateral, in which the abscess is situated above the internal sphincter and before opening in the mid-line posterior spreads laterally to form a T-shaped fistula.

Treatment.—This has been indicated in discussing submucous abscess.

4. **Intramuscular.**—This is a rare form. The lymphatic plexus posteriorly between the two muscular coats of the rectum becomes infected. It is rarely more than an inch long (Fig. 930, B).

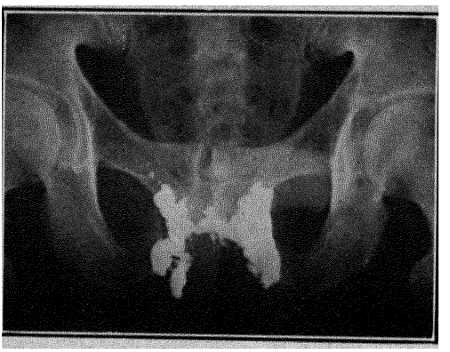

FIG 931.—SKIAGRAM OF BILATERAL PARARECTAL INTRAMUSCULAR FISTULA AFTER THE INJECTION OF LIPIODOL INTO THE FISTULOUS TRACT

Treatment.—This consists in laying open the fistula into the bowel.

5. **Pararectal.**—These, the worst type of fistulæ, are produced by the involvement of the lymphatic plexus situated between the fascia propria of the rectum and the external longitudinal muscle (Fig. 930, C). The infection sometimes occurs as a result of perforation of the rectal wall above the internal sphincter. There are three varieties of this fistula: (*a*) blind internal, which is really an abscess cavity situated between the fascia propria and the longitudinal muscle, and communicating through a small opening with the lumen of the bowel, (*b*) complete, in which the abscess present in the first variety has broken through the levator ani muscle to involve the ischio-rectal fossa, and eventually to perforate through the skin; (*c*) bilateral, in which the original abscess has tracked round the rectum before bursting through the levatores ani on either side (Fig. 931).

In either of these two latter varieties there may be many subcutaneous extensions in the ischio-rectal fossa, and in addition there is often present a subsphincteric fistula.

The diagnosis of this type of fistula depends on the fact that the original abscess is recognized on rectal examination above the internal sphincter, and if the condition is complete a grooved probe director

when passed from the external to the internal orifice will not be felt clearly on rectal examination on account of the thickness of muscular tissue which lies between it and the examining finger.

Treatment.—On no account must this type of fistula be opened into the bowel, as by so doing the internal sphincter will be divided and permanent incontinence will result.

In the blind internal type a knife must be plunged into the ischio-rectal fossa and guided by a finger placed in the rectum through the levator ani into the abscess cavity; large radiating incisions are made into the tissue and skin of the ischio-rectal fossa to ensure as adequate drainage as is possible. By the time these incisions have almost healed the abscess cavity at the top of the pyramid thus formed will have closed considerably from the apex, leaving a small fistulous track to the skin. A second, third, or even fourth operation is then required, following the lines indicated with laying open of the fistulous track freely on to the surface. Following each operation the abscess closes from the top, healing at the level of the skin taking place.

In the **complete** variety the same procedure is followed, except that in this case the original incisions radiate from the fistulous track. In addition the opening of the fistula through the levator ani may be slightly enlarged by a small incision in the direction of its fibres.

In the bilateral type the operation described must be carried out in both ischio-rectal fossæ. Any subsphincteric or subcutaneous extensions must of course be dealt with.

After-Treatment.—It is necessary to keep the bowels confined for three or four days after the operation; to procure this it is essential to empty the bowel completely before operation. The patient is therefore given on the evening before admission ʒi.-ii. of confection of senna (pulv. rad. jalap., pulv. folia sennæ, sulph. sub., āā gr. iii., theriaca nigra ad ʒi.), and on the following morning mist. alba. During the day a very light diet is allowed, and in the evening an enema is given. No further treatment is usually required on the morning of operation, but where the bowel has been excessively loaded a wash-out may be given.

All fistulæ are plugged, as has been noted, with wool soaked in 1 in 500 perchloride of mercury, and this is removed in about forty-eight hours. The wound may then be syringed frequently with hydrogen peroxide or eusol or perchloride of mercury, very light packing only being subsequently introduced into its cavity. During the early hours after operation pain is controlled with morphia, and in addition a mixture containing tinct. catechu and tinct. opii is given to constipate the bowels.

On the evening of the third day a purgative is given, followed by saline on the next morning, in order to produce a soft and easily evacuated stool, the bowels then being kept regularly opened with a nightly aperient.

The presence of tuberculous disease locally and in the lungs must be carefully considered and taken into consideration in advising operation. If the pulmonary trouble is early, there is no necessity for delaying operation; the patient will derive much more benefit

from sanatorium treatment if his fistula has been put on the way to recovery. In the later stages, however, it may be advisable to leave the fistula alone or only to relieve urgent symptoms.

Fissure of the Anus.—This painful complaint consists of a small crack or ulcer at the anal margin. Usually single and posterior, it is always associated with a deposition of fibrous tissue underneath the pile-bearing area known as the pecten band. This disposition is the result of congestion in the submucosa caused by chronic constipation, the presence of hæmorrhoids, a polyp or some other pathological abnormality. The mucosa, which normally during the act of defæcation is partially everted, now does not slide so readily on the underlying tissues and becomes torn by hard fæces. Owing to the fact that the pressure of these is directed backwards, the fissure is usually found in the mid-line posteriorly. Occasionally the fæces catch in an enlarged anal valve, which then is torn down, producing a fissure. Fissure is occasionally syphilitic or tuberculous.

The skin at the lower end of a fissure becomes œdematous and forms a tag, 'the sentinel pile.' In the chronic fissure the edges become hard and indurated, and the fibres of the pecten band may be seen in its base.

The **Symptoms** of this condition are very distressing, consisting of burning pain during and after defæcation, which often lasts for hours. The pain is usually associated with tenesmus, and may radiate down the thighs or up the back, and not uncommonly to the left sacro-iliac joint; it may be so severe as to lead the patient to refrain from defæcation for prolonged periods. The fæces may be streaked with blood or pus. On examining the part, the sphincter is found to be contracted spasmodically, and the entrance of a finger is forcibly resisted.

Treatment in the earlier stages is undertaken by regulating the action of the bowels by suitable laxatives, by the use of cocaine suppositories prior to defæcation, and by improving the general health. Sometimes the application of a silver nitrate stick, combined with the ung. hydrargyri subchlor., is most effective in giving relief. Five c.c. of an oil-soluble local anæsthetic solution such as A.B.A. or proctocaine may be injected into the tissues around and behind the sphincter. The anæsthesia produced and the relief of spasm may be sufficient in an early case to start healing. Local applications of ichthyol may also be made.

Operation should be performed if the fissure is chronic, with indurated edges, if there is a small polyp at the upper end and a large tag at the base, or if internal piles or a fistula are present. Operation consists in passing a finger into the rectum, everting the mucosa, and dividing the pecten band through the fissure. The glistening fibres of this band are easily distinguishable from the brown fibres of the external sphincter muscle. The wound is then lightly packed with a pledget of wool soaked in 1 in 500 perchloride of mercury.

About 80 per cent. of cases of pruritus ani are associated with some pathological condition in the anus or anal canal, such as piles, the presence of a polyp or threadworms, or the presence of the pecten band of fibrous tissue. Removal of this exciting cause is essential,

together with any other treatment. This latter consists in local applications of such ointments as zinc oxide ℥iii., lin. camph. ℥ii., vaseline ad ℥ii., or Whitfield's ointment. Sometimes application of a 20 per cent. solution of phenol in glycerine is of benefit, and injections of B.A.B.A. around the anus may also be tried.

Pruritus Ani is a condition characterized by intense and incessant itching of the anus and its surrounding skin. At first noticed mainly at night, and interfering with sleep, it may in time persist both day and night, interfering with the patient's work, and wearing him out through want of sleep. Scratching becomes a necessity, and yet aggravates the condition. It may be due to parasites, such as thread-worms, or to some ulcerative condition of the anal canal, just at the muco-cutaneous junction, or it may rise from some neurosis. The skin looks red and excoriated, and is usually swollen and thrown into œdematous folds radiating from the anus.

Treatment.—Parasites must be destroyed, and ulcers of the anal canal carefully looked for and cauterized. For cases which persist in spite of such measures, Sir Charles Ball devised an operation which has proved of value, and consists in dividing the terminations of all the sensory nerves to the part. Two semi-elliptical incisions are made around the anus, leaving a narrow pedicle in front and behind; the wounds are deepened to expose the sphincter, and the flaps raised from the muscle inwards around the anal margin and up to the muco-cutaneous junction. The pedicles in front and behind are undercut, and the outer margins of the incisions also to an extent corresponding to the area of irritation; the flaps are then replaced and sutured. The immediate result of such an operation is complete anæsthesia of the anus; normal sensation returns after a time, but without pruritus.

Hæmorrhoids, or Piles, consist in a varicose condition of the veins surrounding the anus and lower inch or two of the rectum.

The character of the blood-supply of this portion of the bowel, and the conditions under which it is carried on, go far to explain the frequency of this affection. The circulation in the pelvic colon is similar to that in the intestine generally, the vessels being distributed transversely around the gut; but in the rectum they run in longitudinal series along the bowel, being connected by transverse branches, which form a plexus around and just above the anus. Their situation in the loose submucous tissue, where there is but little support, necessarily exposes them to great and sudden variations of pressure before and after defæcation. Their dependent position at the lowest part of the portal area, together with the absence of valves, and the fact that they constitute an important communication between the portal and general systems, and thus afford the chief means of escape from a block on the portal trunk—all these reasons may be looked on as **Predisposing Causes** of the condition. In addition to these, we must also mention a sedentary occupation, alcoholic excess, and chronic constipation, which, by leading to congestion of the liver, are frequent precursors of piles. They are exceedingly common in young people, especially in men about twenty years of age forced to lead a sedentary

life; up to middle age the tendency diminishes, but in elderly individuals many conditions, *e.g.* an enlarged prostate, favour their development. Simple stricture of the rectum or malignant disease may also interfere with the return of blood so as to lead to piles. Young women are remarkably exempt, owing probably to the regularity of the menstrual discharge; but uterine conditions, such as pregnancy, displacements, or tumours, are liable to be associated with them.

A varicose condition of the veins in the neighbourhood of the anus is often present without being recognized by the individual; but many different circumstances may bring the symptoms into prominence by causing an attack of thrombosis, such as the use of drastic purgatives, especially aloes, local exposure to damp and cold, as by sitting on a cold wet stone or in a draughty closet, or sudden congestion of the liver, as by alcoholic excess, or a chill.

The position of the piles in the anus is determined by the location of the superior hæmorrhoidal arteries. That on the right side divides into two branches, a right anterior and a right posterior, distributed to the corresponding segments of the anal canal. That on the left side continues down with its accompanying veins midway between the anterior and posterior points of the anal canal. Dilatation of the veins in the submucosa in these positions gives rise to the first or primary piles that form, namely the right anterior, the right posterior and the left lateral.

The right anterior branch gives off no secondary radicles, but the right posterior gives off two, a right lateral and a right posterior The former runs down in a position corresponding to the left lateral branch, only of course on the opposite side, while the latter runs in the submucosa in the mid-line posteriorly.

There are two secondary branches from the left superior hæmorrhoidal dilatation of the accompanying veins which will give rise to hæmorrhoids, these being the left anterior and the left posterior, and the former may itself give a branch passing down in the anus anteriorly.

Thus it will be seen that it is possible for eight piles to form, three primary and five secondary, although the anterior one is very rarely seen (Figs. 932 and 933).

At first these piles are confined to the anal canal, and are not extruded with defæcation. They are covered with the columnar mucosa of the bowel, on account of the delicacy of this and the fact that the hæmorrhoids are prominent during an action of the bowels owing to the straining and congestion associated with that. Ulceration with resulting bleeding is a common feature of this first stage of piles. As the piles enlarge, the irritation set up gives rise to a metaplasia of the columnar lining to the hæmorrhoid, which becomes thickened and replaced by squamous-celled epithelium. Consequently bleeding during the second stage is rare.

In the third or fourth stage of piles, however, where protrusion is occurring either with defæcation only or with any act of straining whatsoever, the constant trauma gives rise to ulceration in spite of the thickened epithelium, so that once more bleeding occurs.

The **Symptoms** of internal piles are often not very marked until hæmorrhage occurs, but there is usually a sense of weight or fulness

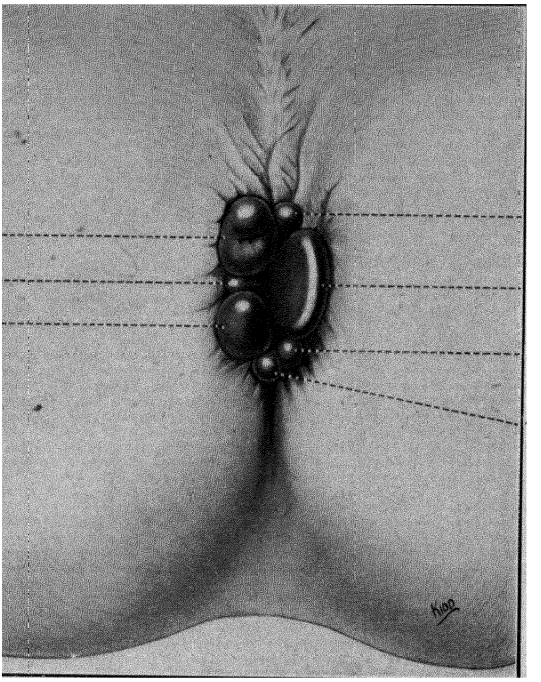

FIG 932.—INTERNAL PILES

1, Left anterior secondary, 2, left anterior primary, 3, left posterior secondary, 4, posterior secondary, 5, right posterior primary, 6, right lateral secondary, 7, right anterior primary.

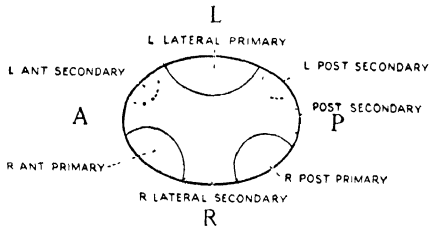

FIG 933.—SITUATION OF PRIMARY AND SECONDARY PILES

about the anus, with sometimes pain, which is increased before and after defæcation. The patient feels as if a foreign body were present,

and the mass not unfrequently protrudes, giving rise to pain and inconvenience, owing to the grip of the sphincter; they can, however, be easily replaced by the patient. Sooner or later hæmorrhage is almost certain to occur, coming on at first after defæcation, and only a few drops being lost. After a time, however, the flow increases, and may continue to such an extent as to cause marked anæmia. If the case remains untreated, the pain and inconvenience increase; a blood-stained mucous discharge from the rectum is noticed; reflex irritation of neighbouring organs is produced, and a condition of nerve prostration from pain and hæmorrhage may result. Where the piles are due to portal obstruction, as in cirrhosis of the liver, the bleeding may be beneficial, and must not always be checked. There is often an associated perianal irritation due to the skin being continually moistened by the rectal discharge.

Complications of Piles.—Thrombosis of a hæmorrhoid may occur. This is usually associated with an infection of the pile which may go on to develop into an abscess, this subsequently breaking and discharging into the lumen of the bowel. In other cases the abscess may burrow deeply to produce a fistula, and on rare occasions suppurative pylephlebitis or pyæmia may be added complications. Where severe infection is not present a thrombosed pile subsequently becomes organized into fibrous tissue and may give rise to one form of fibrous polyp of the rectum. *Strangulation* of the piles by the sphincter ani may follow protrusion where reposition is not effected, the mass becoming painful, tense, swollen, and livid in colour, inflammation running on to ulceration and sloughing follows, and a spontaneous cure may be effected.

The **Diagnosis** of piles from other swellings which occur in the neighbourhood is not difficult. The advantages of examining the patient in the right lateral position have already been referred to, and it is quite easy, after the tactile sensation of the finger has been educated by the examination of a number of patients, to palpate hæmorrhoids in the position described. They are felt as rather elongated velvety hillocks, separated by deep grooves from one another. From *prolapse* piles are recognized by their irregularity, the swelling not being of a rounded, smooth, annular variety, as in the former case; the two conditions are, however, often associated. From *polypus* piles are distinguished by being multiple rather than single, by being softer and more compressible, by their situation close to the anus, by the absence of a pedicle, and by the hæmorrhage being usually more marked. *Mucous tubercles* and *condylomata* are recognized by their general wart-like appearance, by their symmetry, owing to infection of one lip of the gluteal fold from the other, and by their situation at a little distance from the anus. The consistency, appearance, and history of an *epithelioma* should effectually prevent any error in diagnosis.

It is important also to remember that blood may be passed *per anum* from many other conditions besides piles. In the latter case the blood is of a bright red, florid colour, and often coats the fæces, whereas if it originates higher in the intestinal canal it is dark or tarry in colour

(*melæna*), and is more intimately mixed with the excreta. A visual and digital examination of the rectum should always be made in order to ascertain the exact cause of the bleeding.

The **Treatment** of internal piles is both general and local.

General Treatment consists in removing all possible sources of venous congestion, in regulating the bowels, and assisting the functions of the liver. Mild aperients, such as the confections of senna and sulphur, or castor oil, are better than more drastic drugs, and aloes should generally be avoided. At the same time the food is regulated, alcohol forbidden, and suitable exercise enjoined. When dependent on the pressure of a gravid uterus, as little as possible should be done beyond attending to the regular action of the bowels until the child is born, because with the relief of the pressure subsequent to delivery the condition improves greatly of its own accord.

Local Treatment consists in the application of a mercury ointment such as hyd. subchlor. ℥i., adeps. benz. ℥i., yellow vaseline ad ℥ii., and if there is associated pruritus ani it is advisable to use wood wool

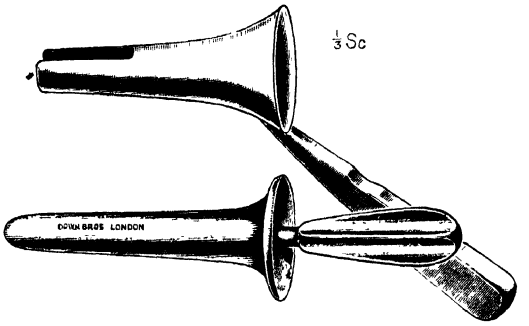

FIG. 934.—CLIFTON'S PROCTOSCOPE

to clean the anus rather than the customary toilet paper. All prolapsed piles should be replaced without delay to avoid the danger of strangulation.

When there is much bleeding or pain, or where protrusion occurs not only with defæcation, but in the course of normal exercise, **Operative Treatment** is necessary. Care must be taken before advising it to ascertain that no other serious disease of the rectum, such as cancer, is present, and that the piles are not dependent on such local conditions as enlargement of the prostate, or uterine fibroids, or on hepatic or cardiac disease; when an operation might be injudicious and harmful.

1. For those cases of piles where protrusion is slight or absent, good results are obtained by *injection treatment.* The patient is placed in the right lateral position and a proctoscope is introduced. Of these the best is Clifton's (Fig. 934). In this one segment of the tubular portion of the instrument is cut away so that the pile may be manipulated to protrude into the lumen of the proctoscope. For the injection 5 per cent. phenol in almond oil is used, and this is drawn

up into a 10-c.c. syringe fitted with a spread needle characterized by its having a shoulder placed about half an inch from its point. This shoulder serves to prevent the needle being plunged through the pile too deeply into the rectal wall (Fig. 935).

Some 10 c.c. of the oil are injected into the substance of the pile close to its base, the whole becoming swollen and turning white. Only one pile is injected at a time, and normally three injections are sufficient to cause thrombosis of the three primary piles. In selected cases this method is very successful, and its economic advantages are obvious.

2. *Operation.*—Although a number of different operations have been used in the treatment of piles, only one will be described, *viz.* that by ligature. A purge is given thirty-six hours before, and an enema saponis the evening before operation. A rectal wash-out with water may be given a few hours before the operation. The skin around the anus need not be shaved. While various forms of anæsthesia may be used, an

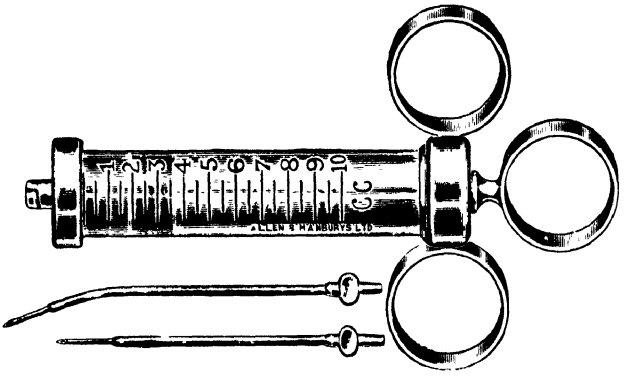

FIG. 935.—A USEFUL SYRINGE USED FOR INJECTING INTERNAL HÆMORRHOIDS.

intravenous sodium pentothal is most desirable, producing adequate relaxation.

If the anal orifice is tight, this is due to the presence of a band of fibrous tissue, the pecten band in the submucosa of the anal canal, and it is divided as described when considering the operation on fissure. There should never be any question of stretching the external sphincter. Efficient anæsthesia causes efficient relaxation of this muscle.

The skin of the anal margin is then seized with three Kocher's forceps at the left lateral, the right anterior, and the right posterior points of its circumference. Traction radially brings the piles into view, and they are clamped with three Miles' pile clamps, any secondary piles that are present being included in the clamp that includes the corresponding primary pile. A V-shaped snip with pile shears or scissors is then made through the muco-cutaneous junction at the anal margin corresponding to one pile. A ligature is then placed in this groove and carried above the pile over the tip of the clamp and tightened while the latter is released. The procedure is repeated with the two remaining piles. Thick silk is used for the ligature, as this is

less likely to slip than catgut. The ligatured piles are then replaced into the rectum and the ends of the ligatures cut long. The wound is dressed with wool soaked in 1 in 500 perchloride of mercury.

Careful after-treatment is required. Morphia should be given to relieve pain, and the bowels confined for three days. After the first motion the patient is allowed to go to the bath. A finger should be passed into the rectum as soon as the ligatures have sloughed off, which is about the twelfth day. The raw areas of mucosa tend to unite longitudinally, instead of transversely, producing a stricture, and this is prevented by digitally smoothing the mucosa every day for about three weeks. The patient is retained in hospital for about seventeen days, during the latter part of which time he is instructed how to do the finger exercise.

Post-operative retention of urine is a common inconvenience after operations in this region; subcutaneous injection of esnodil will often relieve it.

Perianal Hæmatoma, running around the anus under the skin of the anal margin, is a plexus of veins. One of these veins is very easily ruptured in acts of straining, whether it be at stool or in heavy muscular exercise. There is then formed under the skin a bluish swelling consisting of blood clot which is extremely painful. Under a little local anæsthesia, the skin over the clot should be cut away and the congealed blood evacuated. Local applications of wool soaked in 1 in 500 perchloride of mercury for a week complete the treatment. These perianal hæmatomas are sometimes wrongly referred to as external piles.

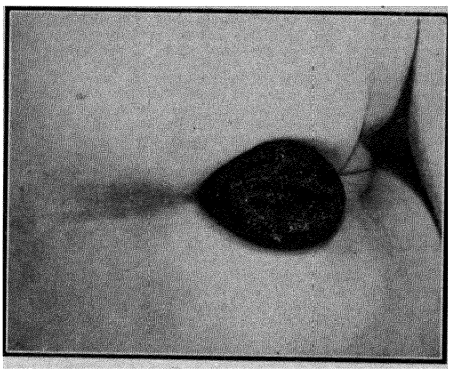

The patient is lying on her side.

Redundant Skin Tags.—Around the anus is sometimes a redundancy of skin forming tags which are often associated with pruritus ani. These tags cannot always be snipped away as part of the treatment of the irritation, and if associated with piles they are removed at the time of operation.

Rectal Prolapse.—A certain tendency to eversion of the mucous membrane of the bowel is a constant accompaniment of the act of defæcation; sometimes, however, this persists after the evacuation of the bowels is concluded, constituting a condition of prolapse. At first only the mucous membrane is protruded, constituting an *incomplete* prolapse (Fig. 936); if, however, the whole thickness of the bowel, mucous membrane, submucosa, and even the muscular and

serous coats, is involved, it gives rise to the *complete* variety (Fig. 937). The former condition (sometimes badly termed a prolapsus ani) is more commonly met with in adults, and the latter (the so-called prolapsus recti) in children; but it must be understood that the latter is always preceded by an incomplete stage, limited to the mucous membrane, and that in adults complete prolapse is occasionally observed.

Causes.—(1) Laxity of the sphincter may occur in weakly individuals and those who have been much exposed to the debilitating effects of residence in tropical climates, especially when chronic constipation or diarrhœa has caused the evacuation of the bowels to be accompanied by straining. In children the malnutrition following measles and whooping-cough may predispose, whilst the loss of fat from the perirectal cellular tissue may assist. (2) Conditions which have led to chronic tenesmus or violent expulsive efforts, *e.g.* piles, chronic constipation, diarrhœa, rectal irritation, as from polypus or worms in children, or diseases of neighbouring organs, such as vesical calculus, stricture, or enlarged prostate, may also determine prolapse.

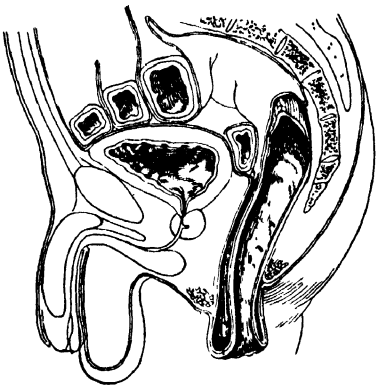

FIG 937.—LONGITUDINAL SECTION OF COMPLETE PROLAPSUS RECTI

Symptoms and Diagnosis.—The anal orifice is occupied by a smooth rounded swelling, red or purplish in colour, covered by mucous membrane; this protrusion in the early stages can be easily replaced, but returns when the patient coughs or strains. When the swelling is of large size, reduction is increasingly difficult and painful from infiltration and fibrous overgrowth of the submucosa, and the exposed mucous membrane is very liable to become inflamed and ulcerated. Prolapse of the mucosa alone seldom exceeds a length of 2 inches, and may occur on one side only. If both sides are involved, there is an indentation anteriorly and posteriorly not present in complete prolapse or procidentia recti. When the whole thickness of the gut is protruded, the serous lining may accompany the tumour, but this is usually limited to the anterior surface, and into the sac thus formed small intestine or omentum may pass, and even become strangulated. The prolapse itself may also be constricted if allowed to remain for long unreduced; the mass is then livid, swollen, and intensely painful, and if left to itself may slough, and thus lead to a spontaneous cure, although severe septic symptoms may supervene, and even perforative peritonitis.

There should be but little difficulty in recognizing a prolapse; the only condition for which it can be mistaken is an intussusception protruding from the anus; in this, however, the finger or a probe can

be inserted into the rectum by the side of the protruding gut, which is impossible with a prolapse.

Treatment.—In the earlier stages, all that is needed is the removal, if possible, of the cause of the tenesmus, *e.g.* dilatation of a urethral stricture removal of a vesical calculus, or the regulation of the bowels so as to check either chronic diarrhœa or constipation. When piles are present, they should be treated as described above, and the prolapse will, as a rule, subsequently disappear. Thread-worms must be dealt with by suitable means (*q.v.*). Beyond this, cold or astringent injections may be employed; *e.g.* sulphate of iron (1 to 3 grains to 1 ounce), and it is advisable for the individual to acquire the habit of having the daily motion at bedtime, whilst children are made to defæcate lying on the side, one buttock being pulled up for the purpose. The prolapse is carefully washed, reduced by pressure with the fingers, and retained by strapping the nates together, particularly in children, or by applying some suitable pad and a T-bandage. Electric treatment to tone up the sphincter and levatores ani may be of assistance, and in children palliative treatment of this type is usually successful.

In some cases light cauterization of the mucous membrane has been advocated. This produces adhesions between the mucous membrane and the muscle coats.

In adults, however, **Operative Treatment** has frequently to be undertaken.

In those cases where there is a prolapse of the mucosa alone ligaturing of the latter in three segments, namely right anterior, right posterior, and left lateral, as in the operation for piles, is often successful. Subsequent to the operation the patient must be instructed to develop the external sphincter muscle by periodically tightening it at intervals during the day.

For those cases where the prolapse involves the whole of the rectal wall and sigmoid colon the operation of choice is that devised by Miles and Kurrow as recto-sigmoidectomy. In this the prolapsed bowel is cut away by an incision surrounding it just below the junction of the skin and the mucosa in order to avoid damage to the sphincter muscle. The incision first passes through the coats of the anterior rectal wall, and opens the peritoneum, it then divides the prolapsed colon, after the vessels in its mesentery have been secured, and finally the posterior rectal wall is severed. The peritoneum on the anterior walls of the colon and rectum is united, and the layers of the walls of the colon are sutured to the corresponding layers of the small length of rectal wall that remains. The operation gives excellent results.

The alternative operations are those directed towards fixation of the rectum (*rectopexy*) either backwards to the posterior pelvic wall or from above. Various operations of this type have been described, but the simplest, and probably the best, consists in opening up the post-rectal space through a transverse incision placed midway between the anal margin and the tip of the coccyx. The external sphincter is detached from the bone, and the post-rectal space is then easily reached and the bowel pushed forwards. The wound is packed with gauze, which is only removed gradually so as to ensure healing by granulation.

Before these operations are performed, and certainly in the milder cases, high submucous rectal injections of 5 per cent. carbolic oil may be tried in an attempt to fix the mucous membrane. This may be allied with sphincteric exercises or plastic operations to tighten the external sphincter.

Tuberculous Disease of the Rectum occurs in the form of ulcers, which are usually multiple, and perhaps very extensive. Infection may be due to the swallowing of infected sputum, but is more probably of hæmatogenous origin. It starts in the submucosa, and the ulcers which follow have the usual features, with undermined edges and prominent granulations. There is usually a marked tendency to the production of fistulæ by extension of the process outwards. The symptoms are those of rectal irritability, pain on defæcation, and discharge of muco-pus and perhaps blood. **General Treatment** of the sanatorium type is necessary, and locally the fistula is dealt with as described. In the worst cases colostomy may be required in order to put the bowel at rest.

Syphilitic Disease of the Rectum and Anus.—The rectum and anus are attacked by syphilitic disease in a variety of ways, the most prominent being as follows:

(*a*) The initial lesion of primary chancre is occasionally met with in the neighbourhood of the anus.

(*b*) In the secondary stage mucous tubercles or condylomata are frequently seen, being placed either at the anal margin, or symmetrically on either side of the gluteal fold, the sores on one side having evidently infected the other. They are of the usual type, and are treated by dusting with powdered calomel and keeping a piece of dressing between the lips of the fold.

(*c*) Tertiary syphilitic lesions of the rectum and anus are occasionally found, but at the present time are undoubtedly uncommon. Gummatous infiltration of the rectal mucosa may be followed by ulceration, and cases have occurred in which the rectum, vagina and external genitalia have all been involved. Stenosis following syphilis may result in a rectal stricture.

Gummata in this region, particularly with ulceration, are likely to be mistaken for malignant disease. They are stated to be multiple rather than single, and the history, presence of a positive Wassermann reaction, and the result of a biopsy should enable the diagnosis to be made.

Treatment.—The usual treatment for syphilis should be adopted with due attention to any tendency towards stricture formation. In severe cases colostomy may be required.

Fibrous Stricture of the Rectum is usually met with in women over forty years of age, and is most often situated 2 or 3 inches from the anus, or as high as its junction with the sigmoid flexure. In this position it is generally due to the cicatrization and contraction of ulcers following prolonged diarrhœa and dysentery, although occasionally it follows tuberculous or syphilitic disease. Any form of chronic proctitis, *e.g.* gonorrhœa, may also lead to it. It occurs sometimes as a sequela of pelvic cellulitis and suppuration, from the contraction

of fibrous bands which may bind the rectum backwards to the sacral wall, or may merely constrict it. Repeated attacks of inflamed piles may also lead to stenosis at or just above the anus. A stricture sometimes results from traumatism, or follows operations involving the whole, or at any rate the greater portion, of the circumference of the bowel. It may in addition be associated with a fistula, especially if the latter has existed for long, and is then due to a chronic inflammatory fibrosis lighted up by the persistent irritation of the bowel; the inner opening is then found in the substance of the stricture. The use of radium in the treatment of anal and cervical carcinoma occasionally produces an anal or rectal stricture. Lymphogranuloma inguinale, a rare venereal disease, believed to be due to a filter-passing virus with a predilection for the lymphatic system, may in women produce a rectal stricture by the fibrosis which follows the involvement of the pelvic lymph spaces around the rectum. Pressure of the fœtal head in prolonged labour is another possible cause. Lastly, a congenital stricture may result from the persistence of part of the proctodeal membrane.

The earliest **Symptoms** of stricture are often alternating attacks of diarrhœa and constipation, in which, of course, the constipation is primary, and the diarrhœa due to a catarrhal enteritis arising from the irritation of the retained fæces. Gradually the difficulty in passing motions becomes more and more marked until no relief is obtained apart from medicine; the fæces themselves become narrowed, flattened, and elongated, something like pipe-stems, or small masses like shrimps may alone succeed in passing. This is associated with pain and uneasiness referred to the lower bowel, a certain amount of blood and mucus may be mixed with the excreta, and sooner or later marked dyspepsia and abdominal distension supervene. In untreated cases obstruction may result and lead to a fatal issue; or the mucous membrane of the bowel above the stricture becomes ulcerated, an abscess forms, and subsequently a fistula, through which a certain small amount of fæcal material passes. If several of these fistulæ are established, the patient may finally succumb to chronic septic poisoning and exhaustion.

An examination of the bowel with the finger may reveal a smooth, regular constriction of the gut as if a band had been tied round it, the fibrous mass and the aperture in it feeling something like an os uteri. In other cases, the bowel is stenosed for some distance, and its surface more or less ulcerated, whilst if due to pelvic cellulitis, it may be drawn up and fixed to the posterior pelvic wall. The gut above the contraction is hypertrophied and distended, whilst if filled with retained fæces, the mucous membrane may show signs of inflammation or even stercoral ulcers. The gut below the stricture is usually dilated (ballooned), partly from paralysis of its wall, and partly by invagination of the mass from above.

The **Treatment** in the early stages consists in keeping the bowels regular and the motions soft by means of paraffin and laxatives, or by enemata. The diet is regulated, so that there is no unnecessary débris. Locally, the stricture, if within reach, should be dilated by means of bougies passed in increasing sizes every two or three days;

the utmost gentleness must be used, in order to stretch the mucous membrane and not tear it. When situated low down, the stricture may be notched posteriorly, or slightly nicked in several places with a blunt-ended bistoury, and bougies then passed. As these strictures always tend to contract again, treatment is usually prolonged.

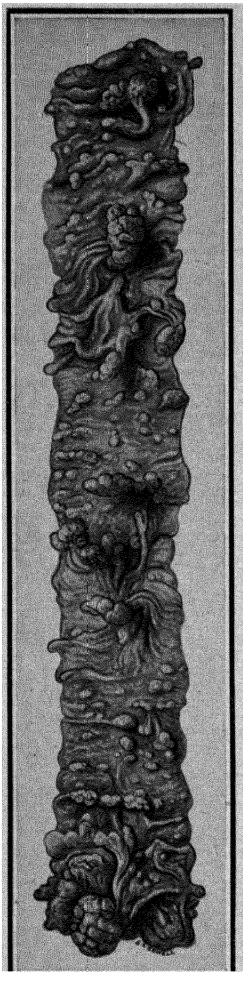

FIG. 938.—SPECIMEN SHOWING MULTIPLE POLYPI OF THE COLON (MR NORBURY'S CASE)

Colostomy will be required if ulceration and fistulæ are present or if the stricture is high and dilatation involves much risk.

Tumours of the Rectum.—Polypus Recti occurs most frequently in children, and consists usually of an adenoma of Lieberkuhn's follicles, but occasionally of simple fibrous tissue covered with mucous membrane. They are commonly found within easy reach of the anus, and present an appearance something like a small cherry with a long pedicle, pendulous and freely mobile. The **Symptoms** caused are irritability of the bowel and the passage of blood by the anus, which latter, when occurring in a child without symptoms of obstruction, is almost pathognomonic of polypus. It is sometimes associated with a fissure of the anus, and possibly with a pile. A natural cure can be effected by rupture of the attenuated pedicle, which is at first attended by a certain amount of hæmorrhage.

Treatment.—The polyp is manipulated to extend through the anus, and a silk ligature is tied tightly around its base. In the course of about ten days or so the polyp will slough off.

Polyposis Intestini or Multiple Adenomata.—This is a rare disease in which the colon and rectum are thickly studded with polypoid growths (Fig. 938). The disease occurs more commonly in men than in women, and between the ages of ten and forty. There is ample proof that polyposis intestini is an inheritable disease, and Dukes has published charts and thirteen family pedigrees which are most convincing on this point.* The disease is transmitted by both males and females, and the inheritance can be traced through several generations. The tragedy of these cases is that they develop cancer of the rectum or colon,

* Dukes, Cuthbert, *The Cancer Review*, 1930, vol. v., No 4, pp. 241-256.

usually in the early thirties or forties. The only form of radical treatment which offers any prospect of cure is colectomy.

Papilloma of the rectum is a rare disease, and gives rise to hæmorrhage from irritability of the bowel, or, if large, even to obstruction. This condition is not always limited to the rectum, but may extend through the greater portion of the intestine, and then proves fatal from hæmorrhage. In some cases it may be associated with a growth higher up in the bowel (Fig 939). **Treatment** consists in removal by ligature or wire snare, where practicable, or, alternatively, diathermy by means of Aylett's diathermy sigmoidoscope is used (Fig 940).



FIG 939.—CARCINOMA OF THE RECTO-SIGMOID JUNCTION WITH A VILLOUS PAPILLOMA OF THE RECTUM (MR NORBURY'S CASE.)

Sarcoma is another uncommon disease in the rectum. It occurs in the shape of a large fleshy tumour growing from the submucous tissue, and projecting into the lumen of the gut so as to cause obstruction. It is less painful than cancer, and usually occurs at an earlier age. The symptoms are much as in the latter disease, and the **treatment,** when feasible, is the same, *viz.* extirpation of the growth, but it will very probably recur.

Epithelioma of the Anus, *i.e.* of the skin covering the anal margin, occurs as a primary development similar to that on the lip, and is then of the squamous type. It presents the usual features, *viz.* an indurated nodular mass, which readily ulcerates, and runs the typical course of such a disease, infecting the inguinal glands. If large it should be treated by operative excision and colostomy, but where the growth is early good results are obtained by radium, and this has the great advantage of leaving the anal canal. The inguinal glands may also be treated by radium or excised. In those cases where the rectum is involved some form of excision of the rectum must be employed.

Carcinoma of the Rectum is one of the more common forms of cancer,

and, while it usually occurs in the 'cancer age,' it occasionally affects young adults.

It may start in three situations:

(*a*) In the upper part of the rectum near the recto-sigmoid junction. This, the most common site, is at the tip of the examining finger, and a growth here may easily be missed if a somewhat cursory examination is made of the anus and rectal ampulla.

(*b*) In the rectal ampulla.

(*c*) Just within the anus; this is an uncommon situation. The growth is histologically a columnar-celled adeno-carcinoma, and is usually found as an ulcer with raised, hard, everted edges. It is occasionally a large projecting tumour, colloid degeneration is not uncommon, and it may be the termination of multiple adenomatosis.



FIG 940.—AYLETT'S DIATHERMY SIGMOIDOSCOPE (VANN BROS.)

Apart from the latter condition small adenomata are frequent in the proximity of a carcinoma, and it is probable that many rectal cancers start as an adenoma.

The growth spreads by (*a*) direct invasion, (*b*) lymphatics, and (*c*) the portal blood-stream.

(*a*) At first confined to the mucosa, the growth invades the underlying muscle and gradually involves more of the circumference of the bowel. There is no definite relationship between the size of the growth in the rectum, the amount of circumference involved, and the extent to which it has penetrated the wall, and it is the last which is so important (Fig. 941). Stenosis and obstruction are more common in the upper part of the rectum, and this may be intensified by invagination of the growth. As the disease progresses, it invades surrounding parts, and thus the tumour may become adherent either to the pelvic walls or to the bladder, vagina, or prostate; sometimes

the iliac vessels or sciatic nerves are compressed, causing œdema or neuralgia respectively. Of course it must be understood that this invasion is in part inflammatory, and due to absorption of bacteria, etc., from the ulcerated surface, and this is always a grave addition to the case. Perirectal abscesses and fistulæ sometimes form, opening externally in the ischio-rectal fossæ, or perhaps internally into the bladder or vagina, and then the tumour begins to develop along the line of the fistula, and may actually form a mass of some size in the bladder.



FIG 941.—CARCINOMA OF THE RECTUM

The specimen was obtained by perineal excision and shows a small perforation above the growth.

(*b*) The lymphatics are seldom involved until the muscle coat of the bowel has been penetrated. First the small glands lying in close proximity to the growth are involved, then those along the superior hæmorrhoidal artery, and finally the lumbar glands. Glandular enlargement does not necessarily indicate invasion, but may be inflammatory.

(*c*) Secondary deposits carried by the portal blood-stream may occur on the liver.

Cuthbert Dukes has recently classified the pathological types of carcinoma of the rectum He has shown that the natural evolution of the disease is in its earliest stages limited to the mucous membrane and submucosa (Fig. 942). (*a*) As it progresses ulceration takes place on the surface and there is invasion of the muscle coats. (*b*) In both these stages local excision of the rectum will eradicate the disease When, however, the lymph nodes are affected (*c*), there is very little chance of curing the disease by surgical procedure.

The **Symptoms** of the disease are often so slight and the onset so insidious as to raise no suspicions of the existence of any growth until it has attained considerable size. The patient is usually an adult,

and more often male than female. At first there may be merely some slight constipation, requiring an increased amount of opening medicine. Then may come more definite attacks of constipation, alternating with diarrhœa, and the discharge of large quantities of mucus, often blood-stained. A sense of weight or dragging pain is noticed in the rectum, and the patient after defæcation feels as if there is still something to be passed. This sensation increases until true tenesmus and straining at stool are present, together with constant pain, which may radiate up the back and down the legs, causing sitting on any hard substance to be painful At first a blood-stained discharge may be seen on the fæces, which become flattened and pipe-like if stenosis is present, but later it passes independently of the motions. On examination, an ulcerating, crateriform mass is met with, which may be limited to one segment of the gut wall, and is then usually firm, and perhaps associated with stenosis, or it may surround the bowel, and feel soft and spongy readily breaking down under the finger, and bleeding freely. The

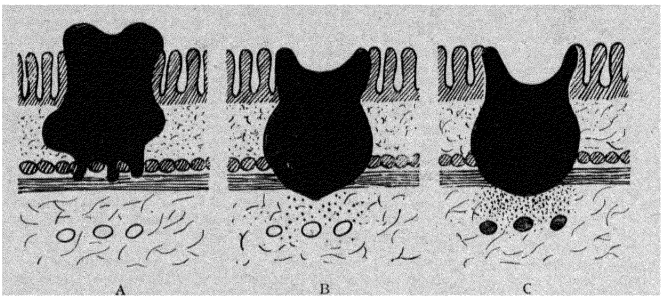

FIG 942.—DIAGRAM TO SHOW INVASION OF CARCINOMA OF THE RECTUM. (AFTER CUTHBERT DUKES)

bowel below the growth is usually 'ballooned.' This examination is generally painful, as also the process of defæcation, and sometimes the patient abstains from the latter for lengthened periods on account of the exquisite agony caused thereby. When the anterior wall is involved, the bladder is often fixed to the mass, and micturition becomes painful, moreover, every time the bladder is emptied, a discharge may occur from the bowel, and this may continue even after colostomy has been performed. Marked cachexia supervenes, the digestion becomes impaired, any meal causing pain and flatulent distension; natural sleep is impossible, and if a recto-vesical fistula forms, the patient's troubles are further aggravated by the passage of fæces and flatus by the urethra.

The case runs a more or less rapid course to the fatal issue, which in a patient fifty-five to sixty-five years of age ensues on an average about twenty-one months after the onset of symptoms, if no operation has been undertaken. Fæcal obstruction occurs in about 30 per cent. of the cases, being more marked in the chronic forms, and in those where the disease starts high up the bowel, on account of the peristalsis

causing invagination of the mass and occlusion of the tube; but if ulceration is excessive, or the disease situated low down, obstruction is less common, invagination being here impossible, and peristalsis being expended on the onward passage of the fæces. Exhaustion from hæmorrhage, pain, sleeplessness, or toxic absorption, accounts for most of the fatal results, and septic peritonitis following the perforation of stercoral ulcers above the growth occurs in a few instances. In young people under thirty years of age the outlook is so bad that operative treatment is probably not justified; in old people over eighty years of age the progress is often so slow that operation is unnecessary. In some cases where the growth is advancing to the point of causing obstruction, palliative diathermy to the growth is of value.

The **Diagnosis** is made on the result of a careful rectal examination and the passage of blood, or any alteration of the normal bowel habits in an elderly patient, symptoms which must never be neglected. 90 per cent. of rectal growths are palpable if care is taken, and a routine sigmoidoscopy in these cases will ensure that no growth at the pelvirectal junction is missed. Biopsy will assist in the diagnosis if there is any doubt. An antero-posterior X-ray of a barium enema may fail to reveal a carcinoma at the upper end of the rectum, since the lower end of the sigmoid overshadows this area.

The **Treatment** of cancer of the rectum consists in the radical measure of excision, the palliative operation of colostomy, or treatment by radium, with or without operation. In assessing the operability of a growth several factors are to be considered:

(*a*) **The Stage of the Growth.**—The mere size of the growth in the rectum is no indication of its operability. It should be mobile; fixation to the prostate or bladder, the side walls of the pelvis or the sacrum is generally regarded as a contra-indication to radical surgery. The posterior vaginal wall can, if involved, be removed with the growth. A final decision can only be made when the abdomen is opened. Secondary deposits in the liver or pelvic peritoneum necessarily render the growth inoperable, but enlargement of the glands in the mesorectum is not to be regarded as a bar to surgery, since the enlargement is frequently inflammatory.

(*b*) **The Site of the Growth.**—When the examining finger can be passed *above* a rectal carcinoma, the growth can be removed by the operation of perineal resection, an operation with a low mortality, whereas a high rectal carcinoma will require some form of combined abdominal and perineal operation. This is a more severe procedure with a higher mortality. Hence a high growth, even if otherwise suitable, may have to be regarded as inoperable in a patient of poor physique.

(*c*) **The Condition of the Patient.**—These operations are easier in women owing to the wider pelvis. In men there is the risk of damage to the urethra and bladder. Age must be considered in relation to the physique of the patient and the type of operation required. Obesity, cardiac and pulmonary disease are unfavourable factors, and chronic intestinal obstruction must be relieved by enemata, purges or bowel drainage.

Excision of the Rectum—(1) **Perineal Resection.** A permanent left iliac colostomy is performed at least ten days before the resection and the lower segment of bowel thoroughly washed out. In the male a catheter is tied in before the operation to guide the surgeon as to the position of the urethra. With the patient in the left lateral position, a purse-string suture is introduced around the anus and tied. The perineum is again purified, and a racquet incision is made from above

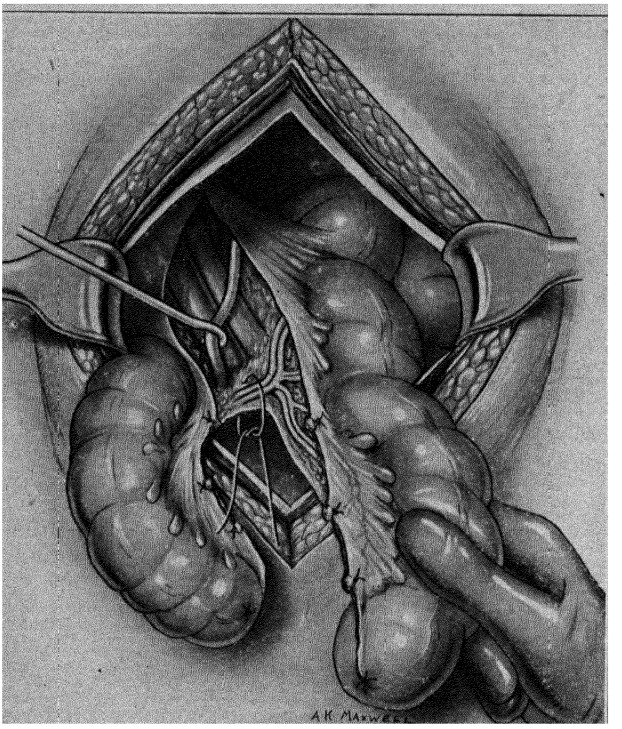

FIG 943.—LIGATURE OF THE INFERIOR MESENTERIC ARTERY (ABDOMINO-PERINEAL OPERATION)

The ureter is drawn aside as it crosses the bifurcation of the common iliac artery.

the sacro-coccygeal junction down to and encircling the anus. The coccyx is disarticulated; through this space a finger is inserted above the levator ani and the muscle divided close to the side wall of the pelvis on both sides. By careful dissection the rectum is separated anteriorly from the urethra and prostate or the vagina. The strong fascia extending forward from the anterior surface of the sacrum is divided, and the rectum stripped forwards from the sacrum. Lateral

bands of fibro-fatty tissue containing the middle hæmorrhoidal vessels are divided. The rectum and anus are now enclosed in a sterile glove and the anterior separation is continued till the peritoneum is exposed. It is opened and divided upwards on either side of the rectum. The mesorectum containing the superior hæmorrhoidal vessels is divided and ligatured as high as possible. The bowel is pulled down and divided between clamps. The upper cord is invaginated and the peritoneum sutured to its anterior and lateral surfaces. A large space is left in the perineum. The wound may be completely sutured save for a small drain, or the middle part left unsutured and the space

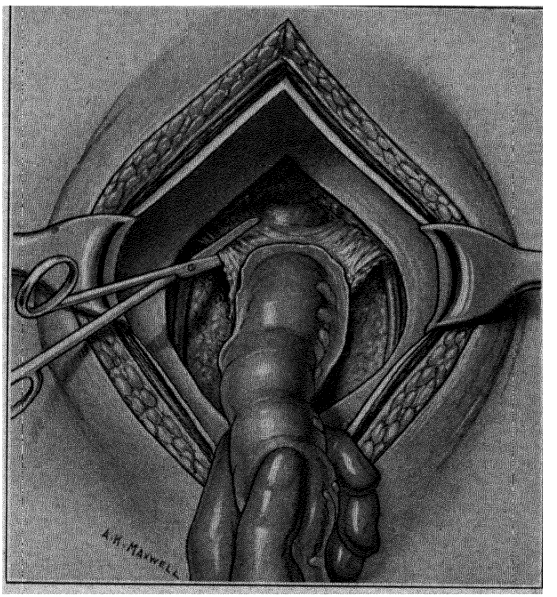

FIG 944.—DIVIDING THE LATERAL LIGAMENTS OF THE RECTUM IN THE ABDOMINO-PERINEAL OPERATION

packed with gauze inside a large piece of protective. In the male the catheter is left in for three days with strict asepsis; in the female a catheter should be passed three times daily till normal micturition is established. If packing has been used it is removed on the third day and the wound irrigated daily.

(2) **The Abdomino-Perineal Operation.**—If necessary this may have been preceded by a cæcostomy or colostomy. The patient is placed in the full Trendelenburg position and the abdomen opened through the right rectus. After ensuring the operability of the growth and the absence of secondaries, the small gut is packed off and the inferior

mesenteric artery divided between ligatures just below the level of the aortic bifurcation (Fig. 943). The peritoneum on either side of the rectum is incised downwards to the pelvic floor and the bowel and mesorectum stripped forwards from the hollow of the sacrum. The two peritoneal incisions are joined across Douglas' pouch, the rectum separated from the vagina or prostate, and the lateral bands containing the middle hæmorrhoidal vessels divided (Fig. 944). The sigmoid is now divided between clamps. The upper end is brought out to form a terminal colostomy through a small incision in the left iliac fossa, while the lower end is ligatured and covered with sterile protective. The lower bowel is pushed down into the hollow of the sacrum and the peritoneum united over it. The abdomen is closed, the patient placed in the left lateral position, and the operation is finished by the removal of the bowel by the perineal route (Figs. 945 and 946).

(3) **The Perineo-Abdominal Operation.**—In this method, after a preliminary laparotomy, the perineal operation is performed save that

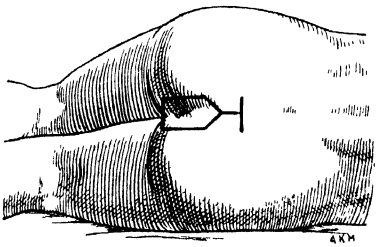

FIG 945.—OUTLINE OF INCISIONS MADE IN THE PERINEUM IN MILES' ABDOMINO-PERINEAL OPERATION.

the bowel and the meso-rectum are not divided. The perineal wound is now partly closed over the rectum, which is enclosed in a sterile glove. The patient is placed in the Trendelenburg position, the abdomen opened, and the rectum and lower sigmoid removed through the abdomen, leaving a colostomy, as in the abdomino-perineal.

In both 'combined' operations the procedure is a severe one, and restorative measures such as blood transfusion should be at hand. Apart from shock, sepsis, peritonitis and urinary infections account for the mortality.

The Choice of Operation.—It is not possible to dogmatize in this matter. A resection should remove an adequate margin of healthy bowel above a growth. The average length of bowel removed by a perineal resection is about 8 inches, and this operation is not suitable for a high rectal carcinoma. A 'combined' operation will remove 14 to 20 inches of rectum and sigmoid, and it is, therefore, the operation for a high rectal growth or where adenomata are present in the rectum and sigmoid above a carcinoma.

A 'combined' operation removes the lymphatic drainage of the rectum up to the level of the aortic bifurcation. Considerably less than this is removed by a perineal resection where the mesorectum is divided some 4 or 5 inches lower. If the lymph glands are not involved this wider removal of the lymphatic field has no advantage, but if they are involved (and 40 per cent. of rectal carcinomas have glandular metastases at the time of their resection), then it should give a better chance of cure, provided the growth has not yet reached the lumbar glands.

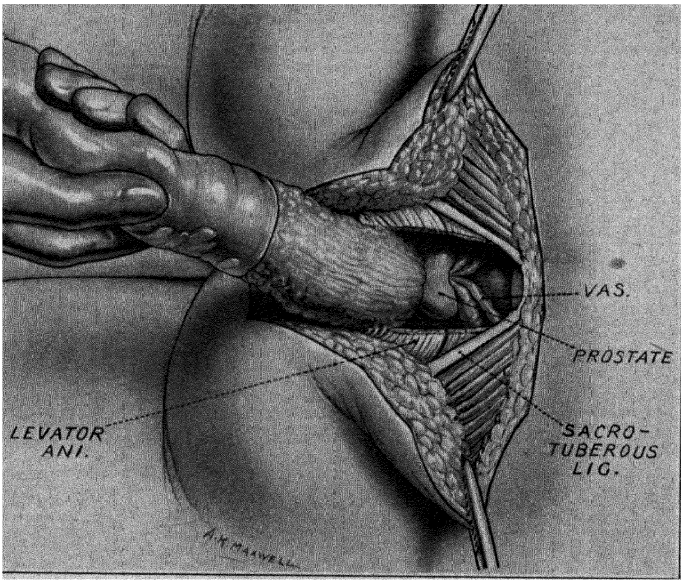

FIG. 946.—FINAL STAGE OF THE ABDOMINO-PERINEAL OPERATION

The pelvic colon and isolated upper part of the rectum are withdrawn from above downwards, from the cavity of the pelvis. Base of bladder, prostate and seminal vesicles exposed.

The mortality of the perineal operation is about 5 per cent., and that of a 'combined' operation probably not less than 15 per cent. To sum up, a *high* rectal growth requires some form of 'combined' operation.

If the examining finger can be passed *above the growth* perineal resection should be performed, particularly if the growth is early or the patient's physique is poor. If the growth is not early or if adenomata are present above it, a 'combined' operation may be performed, provided the patient is fit.

A number of other operations for rectal cancer have been performed, some aiming at the restoration of continuity in the rectum. They are rarely possible, and will not be described here.

Prognosis.—Somewhat more than half the cases of rectal cancer are inoperable when they seek advice; of those surviving the operation, some 60 per cent. are alive and free from recurrence in five years. The prognosis is obviously worse in those cases in which the glands are involved.

The Palliative Treatment of Rectal Cancer.—A left iliac colostomy should be performed, not only to prevent obstruction, but because it renders the patient more comfortable. Radium and X-rays are sometimes used in the treatment of an inoperable growth, but they are of doubtful value. As has been mentioned, palliative diathermy is often of benefit to the patient in lessening the constant discharge which is associated with any rectal growth.

CHAPTER XLI.

SURGICAL AFFECTIONS OF THE KIDNEYS.

General Remarks.—The kidneys are placed on either side of the middle line, and extend from the eleventh rib above to midway between the last rib and the iliac crest below, the right kidney being somewhat lower than the left, owing to the presence of the liver. The hilum is situated opposite the spinous process of the first lumbar vertebra, and the upper ends of the organs are nearer to the spine than the lower.

Exposure.—The kidneys may be approached by two chief routes, *viz.* the lumbar and the abdominal.

The **Lumbar** incision commences at a point corresponding to the outer border of the erector spinæ, and ½ inch below the last rib, extending downwards and outwards in the direction of the fibres of the external oblique towards the anterior superior iliac spine. The posterior portions of the abdominal muscles and the fascia lumborum are divided *seriatim*, and the fatty tissue surrounding the kidney is thus easily reached and opened. Variations of the incision must be made to suit the particular requirements of the case.

In the **Abdominal** operation the kidney is exposed from the front, usually through a free paramedian incision; the peritoneal cavity is opened or not, as may be thought necessary. If the peritoneum is opened, the colon is displaced inwards and held aside, as also the other intestines, by abdominal cloths; the peritoneum covering the posterior abdominal wall is incised to the outer side of the colon, and the organ thus reached. When, however, the kidney is enlarged, it may be unnecessary to open the peritoneal cavity, as the colon and other peritoneal contents are displaced inwards.

Examination of the Kidney.—1. **Manual examination** of the kidney is made with the patient on the back, with the legs raised, the head supported by a pillow, and the mouth open. The surgeon, kneeling or standing at the side of the couch, places one hand under the loin and presses it upwards, whilst the other is gently but firmly pressed backwards in the lumbar region, especially during expiratory movements. Unnatural mobility, enlargement or displacement downwards of the organ, will be thereby detected, as also irregularities in outline or modification of tension.

An **enlarged kidney** is recognized by the following general characters: A swelling is noticed in the loin, which is shaped more or less like the kidney, with its outer border rounded, and a notch being occasionally, though rarely, felt on the inner border. The flank is always dull on percussion, the note remaining unaltered whatever the patient's position, and intestine never finds its way behind the tumour. The passage of the colon in front of the kidney not unfrequently gives rise to a band

of resonance over its anterior surface; the bowel, however, soon gets pushed aside inwards as the enlargement increases. On the right side it is not unusual for the renal dulness to be continuous with that due to the liver; there is always distinct resonance below and to the inner side of the mass towards the pelvis, thereby distinguishing it from a pelvic swelling. The mass moves on respiration, though less distinctly than the liver or spleen.

On the left side it has to be distinguished from an enlarged spleen; the latter viscus hugs the anterior abdominal wall, and has no gut in front of it, whilst the loin is usually resonant.

2. A **radiographic examination** of the kidneys and ureters is often necessary in order to ascertain whether anything in the nature of a calculus is present (Plate XXXVIII.). The use of a soft tube will often enable the lower pole of a normal kidney to be detected; still more obvious does the same part of an abnormally enlarged organ appear, especially if the seat of chronic inflammatory trouble or of a malignant tumour.

There is now not much difficulty in making certain of the presence or absence of a *stone* in the kidney or ureter, although the permeability to the rays of a pure uric acid calculus still renders mistakes possible. A large stone of this character held in the hand in front of the screen casts no shadow deeper than the muscles of the thenar eminence. Oxalate calculi, or those formed of phosphates, cystine, or of a mixed composition, ought in all cases to be demonstrable, and their number, site, and position ascertainable.

The differential diagnosis of the shadows of calculi from those produced by other conditions which may appear on the plates has been rendered easier by the more perfect detail which can now be obtained in the radiograph. In most cases it is possible to show the outline of the kidney, as well as the stones contained in it, and one can thus eliminate the shadows produced by calcified mesenteric glands, bowel contents, or appendicular concretions. Gall-stones are occasionally visible, and this may lead to a mistake in diagnosis. Calcified caseous deposits in old-standing tuberculous kidneys also cast shadows on radiography, but they are recognized from calculi by their more diffuse outline and want of definition, together with the clinical history of the case. One would again emphasize here the necessity for the radiographer and clinician to work together, only coming to a decision after consultation.

The positive diagnosis of ureteral calculi is sometimes more difficult, as they have to be distinguished from phleboliths, calcified pelvic glands, appendicular concretions, bowel contents, calcified appendices epiploicæ, and calcified uterine fibroids, whether pedunculated or sessile. It may be necessary to pass an opaque bougie up the ureter and repeat the examination before a diagnosis can be made. Pelvic glands are nearly always circular and frequently multiple, although it is not uncommon to find a single calcified gland opposite and internal to the iliopectineal eminence on one or both sides. Calcified inguinal glands are easily recognized by their superficial position on stereoscopic examination. Bowel contents are excluded by repeating the examination after effective purgation, and, indeed, this is a course which should always be

followed except in cases which are absolutely characteristic. Calcified fibroids simulating ureteral or vesical calculi can generally be detected on clinical examination.

The preparation of the patient for the examination is of great importance, especially in one of heavy build. The intestine must be empty in order to get good results, and the patient should, if possible, be kept on light diet for some days previously. A course of purgation for two or three days, followed by a long-tube enema on the morning of the examination before the patient has had any food, is the ideal preparation.

A good deal of useful information can be obtained as to the physical condition of the ureter and of the calyces and pelvis of the kidney by the proceeding now known as pyelography, which consists in injecting through a ureteral catheter a solution of sodium bromide (20 per cent.) or of sodium iodide (15 per cent.) up the ureter, so as to fill the pelvis, and then taking a radiograph. A normal pyelogram is represented in Fig. 947, and it will be noted that the shadows of the calyces are concave or cup-shaped, owing to the projection into them of the pyramids. The pelvis of a normal kidney has a capacity of 5 to 8 c.c. of solution, but this is much increased in pathological conditions, such as hydronephrosis. When infection is present, terminal shadows of the calyces are usually convex or flat. With this process it is easy to detect kinks or other abnormalities in the shape of the ureter and its attachment to the pelvis, as also minor degrees of hydro- or pyo-nephrosis, and irregularities in the shape and size of the kidney itself. Doubtful shadows may also be shown to lie quite outside the renal or ureteric region by this means. Of course, it must only be undertaken by experts in the use of the ureteral catheter.

Now numerous radio-opaque drugs can be given intravenously which are excreted by the kidney in sufficient concentration to show the outline of the kidney, calyces, and pelvis, and are very useful when cystoscopy is not possible or when it is desired to compare both kidneys Pictures are usually taken two minutes, ten minutes, and thirty minutes after injection, and some indication of renal function is obtained by delay in excretion which may be noted. Perabrodil and uroselectan B are the two most satisfactory, being almost completely non-toxic, rapidly excreted, and giving good shadows; the dose of either is 20 c.c. of solution, which is easier to administer than other drugs requiring a 100 c.c. dose.

Examination of the Renal Functions.—No serious operation on the urinary organs ought ever to be undertaken in the absence of more or less satisfactory knowledge as to the functional capacity of the kidneys. When the surgeon is considering the question of removing one kidney, it is not sufficient merely to know that a second kidney exists; he must be assured that it is capable of 'carrying on' efficiently if left to itself. In conditions, moreover, of the lower urinary organs which may be associated with secondary changes in the kidneys, serious operations should not be undertaken unless the quality of the renal function has been estimated. Many a patient has lost his life after prostatectomy

from the reflex effect of the operation on damaged kidneys incapable of standing the strain of such a procedure.

The tests for the determination of renal efficiency are complicated, and at present cannot be relied on absolutely. Their very multiplicity suggests the uncertainty that still exists as to their value, and the differences of opinion as to their respective merits are considerable. It is only possible here to indicate the characters of those with the best reputation.

1. The **Amount and Quality of the Urinary Secretion** must be carefully noted in all cases of disease of the kidneys or of the urinary organs where it can be of any significance. The specific gravity should be regularly noted, and the amount of the output of urea; a persistent low specific gravity and a defective urea content are always danger signals. The amount of urine passed apart from a knowledge of its specific gravity is no guarantee of the efficiency of the renal secretion. The amount of urea output is little guarantee, apart from a knowledge of the



FIG 947.—PELVIS IN DIASTOLE, WITH MAJOR AND MINOR CALYCES WELL DEFINED



FIG 948.—PELVIS IN SYSTOLE, MINOR CALYCES NOT VISIBLE NARROWING OF COMMUNICATING CHANNELS AND CONTRACTION OF PELVIS

character of the food taken, moreover, it does not suggest or give any clue as to the capacity of the kidneys to deal with an emergency, nor does it show the amount of urea still existent in the blood.

2 The **Urea Concentration Test** is devised with a view to discover the capabilities of the kidneys to react to a stimulus. All fluid is withheld from the patient for six hours, and then a dose of urea (15 grammes in 100 c.c. of water) is administered. The volume of urine passed hourly for three hours is measured, and the percentage of the urea content, as compared with the dose given, carefully investigated. If the urea in the urine exceeds 2·5 per cent., the kidneys may be considered to be acting adequately; if the amount is between 2·5 and 2 per cent., the renal function is probably sufficient, but it is likely that some damage to the secretory apparatus is present, and it may be desirable to estimate, in addition, the amount of urea in the blood. If the urea content is below 2 per cent., the kidney function is prob-

ably unsatisfactory. Excessive excretion of urine (diuresis) somewhat vitiates these figures, and that must also be taken into account.

3. The **Estimation of Urea in the Blood,** especially if it can be compared with the output of urea in the urine, would at first sight appear to be a matter of great value. Inasmuch, however, as the amount is largely dependent on the diet of the patient, and gives no indication of the power of the kidney to react to a stimulus, its value as a test of renal efficiency has been rightly depreciated. The amount of blood urea normally in patients on a hospital diet varies from 20 mgrms. per cent. in young people to 50 mgrms. in older people; 70 mgrms. per cent. in an elderly patient would indicate renal insufficiency.

4. The **Elimination of Dyestuffs** has been used for some years as a means of determining the functional activity of the kidneys, and although one cannot be certain that any parallelism exists between such excretion and that of the products of nitrogenous metabolism, yet it has its value, and particularly in estimating the relative activity of the two kidneys, if the urine from each is collected by a ureteral catheter. (*a*) The *methylene blue test* was much used formerly, but has been displaced by other methods. However, for one who is not an expert, it may prove of value to determine whether or not a second kidney exists in view of a possible nephrectomy; 5 minims of a 10 per cent. solution are injected into the gluteus maximus, and within ten or fifteen minutes it should be possible to see blue jets of coloured urine escaping from the ureteral orifices by means of a cystoscope. The functional value of such a kidney is not determined thereby. (*b*) *Indigo carmine* has now largely taken the place of methylene blue, and may be introduced intravenously (20 c.c. of 0·4 per cent. solution). The colour should appear within three to six minutes, and the depth of the coloration is some guide as to the renal efficiency. Delay in appearance and feeble coloration are indications of imperfect renal function. It is difficult to form any judgment as to moderate degrees of impairment of function. (*c*) *Phenol-sulphonephthalein* is also employed in much the same way, but is rather more accurate. A draught of water is administered, and 0·006 gramme of phenol-sulphonephthalein is injected subcutaneously. The urine is collected for two hours, and rendered alkaline by the addition of caustic soda (25 per cent.), which produces a brilliant red colour. Each hourly specimen is made up to 1 litre with distilled water, and compared in a colorimeter with a standard solution of phenol-sulphonephthalein containing 0·003 gramme in a litre. The percentage of the dye excreted in each hour is thus estimable. The normal secretion is 40 to 50 per cent. for the first hour, and 20 to 25 per cent. for the second. A figure below 45 per cent. for the two hours indicates some degree of renal insufficiency.

In conclusion, it must be remembered that none of these tests can be relied on by themselves, and none or all of them combined can be used to the exclusion of the facts ascertained by clinical examination. The laboratory worker must be the assistant of, and not the dictator to, the clinician.

Diminution in or loss of the functional activity of the kidneys results in an accumulation of toxic products of varying characters in the blood,

which leads sooner or later to the development of a condition of **Uræmia,** which may have a gradual or sudden onset, and be represented by a multiplicity of varying symptoms. Headache, vomiting, and convulsions are probably the most characteristic features, but there are many other suggestive manifestations, such as delirium, various paralyses, asthmatic attacks, etc.

Congenital Affections of the Kidney.—Many different malformations and displacements are met with affecting this organ.

The chief **Malformations** are as follows: (1) Complete absence of one organ, a very rare condition. (2) Congenital atrophy of one kidney, it being represented by a mass of fatty tissue. In both cases the other kidney is correspondingly enlarged and hypertrophied. (3) The kidneys may be fused together, either forming one large organ in the median line and more or less normal in shape, or sometimes constituting the so-called **horseshoe kidney,** the convexity being directed downwards. The latter condition is not very uncommon, being present once in about 1,100 bodies examined; it is usually associated with an increased number of ureters or renal vessels. (4) Deep lobulation of the kidney, as in some animals, is occasionally seen, especially if the organ is displaced; this may be carried to such an extent as to divide it into two or more portions. (5) The ureter and pelvis may be double, this malformation affecting the pelvis alone, or extending as far as the bladder (6) The renal artery may arise from the aorta in two or more main branches.

The majority of these malformations are of very little clinical importance, except in the operation of nephrectomy, when they may necessitate some modification of the usual proceedings. They are apparently more than normally liable to infection.

Congenital Displacement of the Kidney occurs about once in every thousand individuals, the organ being either depressed, so as to lie over the sacro-iliac synchondrosis or sacral promontory, or raised above its normal position. The left kidney is more frequently affected in this way than the right, and, when lying in the iliac fossa, the descending colon is usually displaced inwards, so that the rectum starts to the right of the middle line. The adrenal bodies retain their normal position, and do not move with the kidney.

Cystic disease, sarcoma, and hydronephrosis may also occur congenitally, and will in turn be described below.

Movable and Floating Kidney.—The normal kidney is not a fixed organ, but moves up and down on respiration, although usually this movement cannot be detected on palpation. It is therefore necessary to define as precisely as possible what is meant clinically by the terms 'movable' and 'floating' kidney. Three stages of abnormal mobility may be described: (i.) A *palpable* kidney is one the lower half or more of which can be definitely felt on deep inspiration. (ii.) A *movable* kidney is one in which the examining hand can define the upper end of the organ, and can restrain it from returning to its old position during expiration. (iii.) A *floating* kidney is one which can be moved freely about the abdomen in all directions, and even across the middle line in some cases Formerly this last term was applied to a supposed

congenital lesion, in which the kidney was attached to the posterior abdominal wall by means of a mesentery; it is more than doubtful whether such a condition exists.

In the earlier stages the movements occur within the fatty capsule which surrounds the organ, but later on mild attacks of inflammation attach the fatty to the fibrous capsule, and the kidney with its associated fatty envelope moves behind the peritoneum. Two forms of movement are possible: (i.) An up-and-down or in-and-out movement in one plane (*cinder-sifting* movement), the kidney merely swinging on its pedicle; or (ii.) a movement of torsion may accompany this, either round a transverse axis when the lower end of the kidney becomes prominent, or round a vertical axis when the outer convex border swings forwards. In the latter case kinking of the ureter or renal vessels is very likely to ensue.

Movable kidney occurs more frequently in women than in men (10 to 1), and more often on the right than on the left side (12 or 13 to 1), partly because the renal vessels are longer on this side than on the other, and partly because the descending colon is more fixed than the ascending.

Causes.—The kidney is placed between the layers of the perinephric fascia, which in turn are derived from a splitting of the fascia transversalis. In children this perinephric capsule is attached closely to the kidney front and back without any intervening fat; but as development proceeds, fat is packed in around the kidney in increasing amount, and hence in stout subjects the perinephric capsule is considerably distended, and the kidney is firmly supported. In addition to this, however, the tension of the peritoneum, the maintenance of the intra-abdominal pressure, and the support of the muscular abdominal parietes, have much to do in keeping it in place. Anything that seriously modifies these three factors may lead to displacement and mobility of the organ. Parturition accounts for some cases—firstly, because of the sudden diminution of the intra-abdominal pressure; and, secondly, owing to the resulting pendulous and relaxed state of the abdominal muscles, especially if the patient too early resumes the erect posture, or undertakes physical work without efficient external support; hence it is more frequent among the poor than among the rich. It may also follow the removal of large abdominal tumours which stretch the abdominal walls, or rapid emaciation, whereby the perinephric fat is absorbed, tight-lacing or traumatic influences may also be responsible for some cases. It is frequently associated with that form of displacement downwards of the abdominal viscera which is known as Glénard's disease, or visceroptosis. Constipation is an important element in the production of movable kidney, and probably acts by the loaded cæcum dragging upon the anterior layers of the perinephric fascia, and thus displacing it forwards.

Symptoms.—A movable kidney is often discovered by accident, and may be entirely free from symptoms. In some cases the patient comes under observation because she has observed a movable lump in the abdomen, which on handling is painful, the pain being often associated with nausea and vomiting. In other cases, pain and vomiting bring the

patient under observation, the doctor discovering the movable kidney. The pain is referred to the back, or perhaps shoots along the ureter to the groin, testis, or labium majus. Vomiting is a significant sign, and the surgeon should never omit to examine the loins in cases of obstinate vomiting with no apparent cause. Periodical exacerbations of these symptoms, with a temporary diminution of the amount of urine, result from kinking of the ureter (*Dietl's crises*); sudden relief, followed by an increased flow of urine, possibly containing some muco-pus, indicates that the organ has returned to its normal situation. Repeated attacks of this type may result in pyelitis and hydronephrosis. On examining the abdomen, a movable tumour can often be observed with ease if the abdominal parietes are not loaded with fat, and on manipulation pain and vomiting may be induced. The adoption of the genu-pectoral position will sometimes enable a movable kidney to be more certainly felt, whilst a distinct loss of resistance is noticed external to the erector spinæ on the affected side.

The patient is usually of a neurotic type, but possibly this may result in part from the mobility of the organ, which necessarily involves a certain amount of traction upon the sympathetic centres in the abdomen. Evidence of the displacement of other abdominal viscera is often found, so that the detection of a movable kidney does not necessarily explain the whole case, or indicate operation. After many an operation for movable kidney the symptoms (pain, vomiting, etc.) have persisted, even though the organ remained anchored to the abdominal wall.

Treatment.—In the great majority of cases of movable kidney operation is not required, and, indeed, it is usually unwise to tell the patient that such a condition is present. If it is associated with marked debility, bodily or nervous, and perhaps with general enteroptosis, a rest-cure in bed for six weeks, with abdominal and general massage and an abundance of milk and fatty foods, will do much to steady the kidney and improve the general condition. The application of a carefully-fitted kidney support will then suffice to keep her comfortable. This may advisably consist of an air-cushion fitted into an abdominal belt; the cushion should be triangular in shape, its sides corresponding to the costal border, Poupart's ligament, and the linea semilunaris; it is put on in the recumbent posture, and for choice with the pelvis raised.

The indications for operation are: (1) Extreme mobility, so that the organ cannot be fixed by a support; (2) extreme tenderness, so that a support cannot be tolerated; (3) the recurrence of acute attacks of pain and vomiting (Dietl's crises); and (4) the supervention of hydronephrosis or pyelitis.

Nephrorrhaphy or *Nephropexy* is the name applied to the operation for fixing the kidney. It is obvious that a rounded body like the kidney with a smooth fibrous capsule is not easily fixed, and the more so since the renal parenchyma has great absorbent powers, so that sutures, even of silk, passed through its substance are readily disintegrated and absorbed; hence, although the kidney may seem to be efficiently immobilized at the completion of the operation, it readily becomes loose again. There are only two certain methods of fixing

the organ. (i.) The wound down to the kidney is left open and packed with gauze, so that healing occurs by granulation; the cure is certain, but tedious, and a lumbar hernia may follow. (ii.) The plan now usually adopted is to expose the organ through the loin. The perinephric fat is opened, and as much as possible of it removed. A new home is made for the organ a little higher than its former position, so that it shall lie under cover of the diaphragm. A considerable portion of the true fibrous capsule is now dissected up, and fixed by sutures to the deep aspect of the abdominal muscles, thereby steadying the organ. The patient should be kept in bed subsequently for six weeks, so as to allow of consolidation of the parts, and subsequently a binder or belt should be worn for a time.

Injuries of the Kidney are usually due to crushes of the body, as between the buffers of railway cars, or when a cart passes over the abdomen, or from blows or falls. Considerable hæmorrhage follows, both into the substance of the kidney or its pelvis (Fig. 949), and into the perinephric fatty tissue, and this even when the capsule has not been torn. The integrity of this structure is a point of great importance, since it limits to some extent the bleeding and prevents urinary extravasation, the kidney may be crushed to a pulp without any external hæmorrhage, and under these circumstances clots are likely to pass down the ureter, and may obstruct it and lead to its subsequent occlusion. When the anterior portion of the capsule is torn, the peritoneum may also be involved, especially in children, and then evidences of intraperitoneal bleeding may manifest themselves, and, indeed, if the kidney is extensively lacerated, fatal hæmorrhage may result, though this is unusual. Rupture of the posterior surface of the kidney opens up the perinephric cellular tissue, which becomes infiltrated with blood and urine, and suppuration is almost certain to follow, resulting in pyæmia, or at a later date in exhaustion from chronic septic poisoning. Not infrequently other severe injuries are present, such as fracture of the pelvis, spine, or skull, bruising or tearing of intestine or liver, and from these associated lesions serious phenomena may arise.

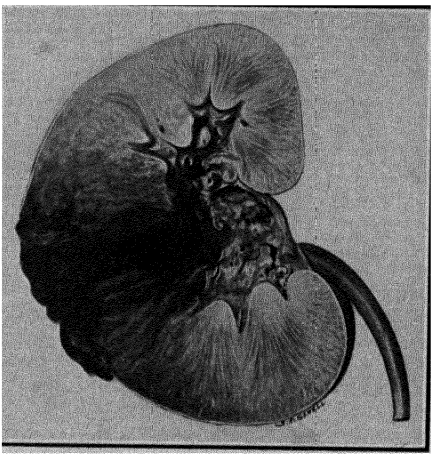

FIG. 949. RUPTURE OF KIDNEY (KING'S COLLEGE HOSPITAL MUSEUM).

The **Symptoms** consist in severe shock, followed by nausea, vomiting, pain in the loin, shooting down into the testis or thigh, localized

tenderness and perhaps swelling over the injured organ, and hæmaturia. The amount of blood lost in this way varies considerably; in the slighter cases the hæmaturia is of short duration, but in more extensive lesions it may be severe and so persistent as to threaten life. The passage of clots down the ureter gives rise to renal colic, and obstruction of that duct may lead to total suppression of the secretion on the affected side. The bladder may in some cases become greatly distended with clots, the blood coagulating after it has entered the viscus. Hæmorrhage into the perinephric tissues is indicated by the formation of a swelling in the loin, and laceration of the peritoneum is followed by distension of the abdomen, increasing anæmia from persisting hæmorrhage, and the onset of peritonitis. The development of a perinephritic abscess is recognized by fever, rigors, increased pain in the loin, and the usual phenomena of deep suppuration.

Treatment.—The patient must be kept in bed, with an icebag or Leiter's tubes applied to the loin; pain may be relieved by strapping the side or by applying a firm bandage. If the hæmorrhage persists and threatens the patient's life, an exploratory incision is required, and, if need be, removal of the organ, although it is sometimes possible to stitch up a limited rent, the sutures being passed deeply through the glandular tissue. Sometimes the blood does not escape externally, and then the rapid development of a swelling in the loin, with increasing anæmia and rapidity of pulse-rate, would indicate that operation is desirable. Distension of the bladder must be relieved, the clots being washed out through a large-eyed catheter. The occurrence of peritonitis or of a perinephritic abscess will call for suitable surgical measures, the injured viscus being dealt with according to its condition.

Rupture of the Ureter is a rare accident, usually due to direct violence, but occasionally happening during pelvic operations, such as removal of the uterus. When the result of a subcutaneous injury, it cannot be recognized at once, but extravasation of urine in the perinephric tissue takes place, and leads to the formation of a swelling; the urine, if aseptic, may remain unchanged, or suppuration may be caused. Sooner or later an incision is almost always required, and on exploring the cavity it may be possible to detect the rent in the ureter, but more frequently its situation cannot be found, and then a doubt will necessarily exist as to whether the lesion involves the ureter or the pelvis of the kidney. In either case a urinary fistula in the loin results, which may possibly close after a time; if the fistula persists, nephrectomy will be needed, unless the ureteral lesion can be repaired. Various methods have been employed to effect this, but the best results seem to have been obtained by invagination of the upper into the lower segment, which may be split longitudinally to increase the calibre. Two fine stitches are passed through the complete wall of the upper end, one on either side, and these are carried through the walls of the lower segment so as to make invagination possible.

Hydronephrosis is a condition characterized by distension of the pelvis and calyces with urine, as a result of some obstruction to its exit.

Ætiology.—(1) Congenital hydronephrosis is often bilateral, the obstruction in these cases being in the urethra, as with valves in the

prostatic urethra of male infants. When unilateral, stenosis of the ureter may be present, this occurring most commonly at its junction with the pelvis or at its entrance to the bladder; in some cases the ureter may be kinked over an abnormally low branch of the renal artery and obstructed by tough fibrous bands that accompany such vessels. Hydronephrosis may be seen in abnormal kidneys of horse-shoe type, or in case of double ureter, when the part of the kidney connected with one ureter only may be affected. The amount of distension in some of these cases may interfere with parturition until the abdomen has been tapped. Infants with bilateral congenital hydronephrosis that are not born dead do not often live for more than two years.

(2) Acquired hydronephrosis may be classified under the following headings: Obstruction (*a*) in the lumen of the ureter, most commonly by stone, more rarely by growth, such as villous papilloma of the renal pelvis, and possibly by blood-clot. (*b*) In the wall of the ureter by inflammatory swelling of the mucosa, by ureterocœle (ballooning of the intravesical portion of the ureter behind a congenitally stenosed orifice), by stricture resulting from healing of ulcerated area caused by a stone, from contraction of fibrous tissue in bilharziosis and other conditions,

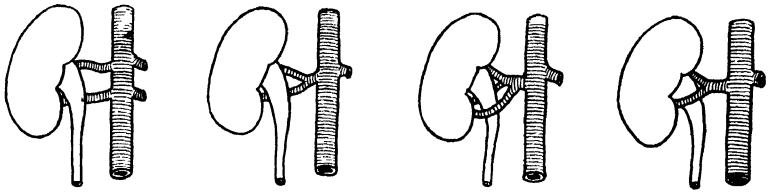

FIG 950.—DIAGRAM SHOWING THE VARIOUS WAYS IN WHICH THE RENAL ARTERY MAY ENTER THE KIDNEY

or by tumours. (*c*) Outside the ureter by pressure from cicatrices following pelvic cellulitis, from tumours and other swellings in the pelvis, among which must be remembered a bladder diverticulum, which may often distort one ureter near its entrance to the bladder. (*d*) By kinking of the ureter in cases of movable kidney and aberrant renal artery (Fig. 950). (*e*) In the urethra by stricture, prostatic enlargement, or penile carcinoma; in such cases the dilatation will be bilateral. (*f*) Of nervous origin; those cases of hydronephrosis for which no obvious cause can be found, and previously classified as 'idiopathic'; these occur in early adult life, and are now said to be due to inco-ordination of the neuromuscular mechanism, probably of 'sympathetic' origin.

The words 'open' and 'closed' are used according to the escape or not of urine from the hydronephrosis.

It must be clearly understood that a sudden and absolute block never leads to hydronephrosis. Should it occur as the result of impaction of a calculus in one of the ureters or of ligature of the ureter, as has occurred in hysterectomy, the secretion on that side is totally suppressed as soon as the tension within the pelvis and calyces is sufficiently high. Atrophy of the renal epithelium follows after a time,

but if the obstruction is relieved within two weeks of its incidence, the secretion of urine will probably be re-established, but not after compensatory hypertrophy of the other kidney has been established. Should, however, the obstruction be intermittent or incomplete, so that some of the urine escapes, thereby relieving the pressure, hydronephrosis develops. Sudden and complete occlusion of the urethra likewise results in dilatation of the bladder and rupture either of that viscus or of the urethra, whilst a gradually increasing obstruction is always likely to lead to hydronephrosis. Some absorption of fluid from the hydronephrosis occurs through the convoluted tubules and lymph vessels, but 'pyelo-venous' backflow only results after the trauma of excessive pressure, as may occur in careless pyelography.

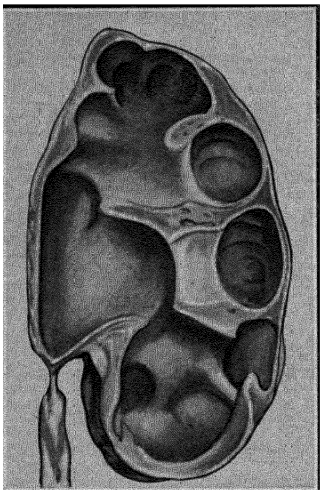

TO A STRICTURE AT THE UPPER END OF THE URETER

Pathological History.—The earliest result of obstruction is a slight flattening of the pyramids and clubbing of the calyces, which replaces the normal cupping. As dilatation proceeds two main types may result: (*a*) The renal type occurs in cases where the pelvis is contained mainly within the kidney and the calyces dilate, a series of large cavities arise with the kidney substance becoming gradually thinned out. Calculi may be developed in these cavities and grow to a large size, often branched (*b*) The pelvic type occurs where the pelvis is outside the kidney and can distend freely In early cases the kidney retains nearly its normal design, with the pelvis becoming globular, but with increase in size the kidney atrophies, leaving a large thin-walled cyst (Fig. 951).

The urine is pale and of low specific gravity. The ureter above the obstruction dilates (hydro-ureter), and in many cases there is dilatation of the ureter below the obstruction (cause unknown). At any stage septic phenomena may supervene, giving rise to pyonephrosis (p. 1452)

The **Clinical History** varies considerably with the method of onset and the cause of the trouble. Frequently all that happens is a painless enlargement of the affected organ; if both kidneys are involved, there may be at first some increase in the amount of urine secreted, which is pale, limpid, and of a low specific gravity, after a time the quantity diminishes, and finally anuria and uræmia follow, especially if septic changes supervene, as is so commonly the case. When only one kidney is affected, the excretion may remain normal in quantity and quality, owing to compensatory hypertrophy of its fellow. An

elastic swelling, fluctuant if of considerable size, is produced and presents all the physical signs of a renal tumour.

Symptoms are more frequently due to the causative agent rather than to the disease itself, pain from a renal stone, or bleeding from a growth. When due to a kink over a branch of the renal artery, there may be a history of occasional attacks of acute pain and swelling on the affected side, the swelling and pain disappearing after voiding a large quantity of pale urine; this is known as a Dietl's crisis.

The symptoms due to the disease itself are pain, which may be a dull ache due to the size of the swelling, or more acute in the stage when outflow is completely blocked. Vomiting may be due to the pain, or occur as a result of early uræmia in conjunction with dry tongue and thirst and other signs of early renal failure. True polyuria may occur and cause increased frequency of micturition, which may, however, be of reflex origin. Hæmaturia occurs in some cases for which no cause can be found.

Investigation.—After routine abdominal, rectal, and vaginal examination and urinalysis, with investigation of signs of early renal failure X-ray pictures should be taken; these may show stones or calcified abdominal glands. Cystoscopy will reveal the presence of an enlarged prostate, ureterocœle, or the orifice of a bladder diverticulum. Both ureters should be catheterized, the site and nature of any obstruction being noted, the rate of flow from the affected side will be very rapid, and it may be possible gently to aspirate many c.c. by a syringe attached to the catheter. The specimen collected from each ureter should be examined for organisms and pus cells, and the urea percentage of the two sides compared. Pyelography should be performed, and will reveal the degree of hydronephrosis, any filling defect due to growth, and confirm the level of ureteric obstruction. Pyeloscopy is not yet perfected, but is useful in cases of defective sympathetic innervation. A good concentration of dye is obtained by intravenous perabrodil and the simultaneous introduction of sodium iodide through a ureteric catheter into the pelvis under observation. The catheter is removed and the contractions of the calyces and pelvis are watched on the fluorescent screen, and the response of the contractions noted to the administration of subcutaneous injections of drugs. Spasm of the renal musculature may sometimes be relieved by the injection of ½ c.c. of pituitrin, and normal peristalsis established. Before instituting treatment, the integrity of the other kidney must be established.

The **Treatment** of hydronephrosis should in the first place be directed to the removal of the cause, if practicable, and where the obstruction exists in the prostate or urethra, no other treatment is feasible. In some cases of *congenital* hydronephrosis due to malformation of the upper end of the ureter, it is possible to transplant it and thereby relieve the obstruction; or the pinhole orifice of the ureter may be exposed within the pelvis, and divided longitudinally, with subsequent stitching open of the margins. This type of *ureteroplasty* is sometimes very successful.

Obstructing bands with bloodvessels should be divided between ligatures. Pyeloplasty, excision of a flap of redundant pelvis with the

suture line arranged so that the ureter is at the most dependent part, may be performed if the obstruction has been relieved. These plastic operations must only be performed if the urine of that kidney is sterile.

Stenosis of the lower end of the ureter may be treated by transplanting the end proximal to the obstruction into the bladder.

Renal sympathectomy is carried out through the usual lumbar incision and the vessels and pelvis stripped of their sympathetic nerve supply. This is occasionally indicated in early hydronephrosis due to 'sympathetic' overaction, often confirmed at pyeloscopy.

In the later stages, where suppuration is threatening or present, nephrectomy will probably be required.

In bilateral cases with renal failure, double nephrostomy is necessary, This may be permanent or temporary, as in some cases with improvement of the patient's condition the obstruction may be dealt with and the nephrostomy closed.

Pyogenic Infections of the Kidney and Ureter may develop from many distinct sources, and give rise to several allied, though distinguishable, clinical conditions. Thus (i.) the infective material most frequently reaches the kidney from the blood. We have already explained the influence of oral and other types of sepsis in causing blood contamination; bacteria can readily find their way from the capillary blood-stream in the glomeruli into the renal tubules, and light up an infective nephritis which quickly spreads to the pelvis. Similarly a pyæmic embolus may determine an infective lesion of the renal parenchyma, ending either in a single large localized abscess, or in many scattered foci of suppuration. In cases where a focus of disease pre-exists in the kidney, *e.g.* stone, tubercle, or cancer, a secondary pyococcal infection adds gravely to the severity of the symptoms. (ii.) When once the kidney substance is involved, the trouble is only too likely to spread to the pelvis, causing a suppurative *pyelitis* (or, inasmuch as the renal parenchyma is already invaded, a suppurative pyelonephritis); and thence the mischief spreads down the ureter, and may perhaps infect the lower urinary passages, constituting a condition of *descending pyelonephritis*. (iii.) A common method of origin consists in pyogenic organisms spreading upwards from the bladder to the ureter and kidney. This may arise from a primary cystitis, but is seen most frequently in the affection which used to be termed 'surgical kidney,' and follows in the train of many diseases accompanied by cystitis, *e.g.* stricture of the urethra, enlarged prostate, stone in the bladder, etc. It will be remembered that the ureter passes through the bladder in an oblique direction, and is guarded by strong sphincteric muscular fibres, and thereby the spread of infection upwards is rendered more difficult, except in some cases of rigid open ureter, as in tuberculosis, when it may be that secondary infection reaches the kidney by the lumen of the ureter. It may be (but has not been proved) that in cases of 'ascending pyelonephritis' the infection reaches the kidney by peri-ureteric lymphatics from the bladder, or even in some cases by the blood-stream, and is really hæmatogenous with the bladder as the primary focus. When the phenomena caused by this infection from below are limited to a suppurative condition, it is known as an

ascending pyelonephritis; but if to them is added an element of distension, due to the cause being of an obstructive type, then the distended suppurating kidney is known as a *pyonephrosis*. (iv.) Sometimes the infection reaches the urinary passages from neighbouring organs, as in disease of the rectum or even of the appendix; in the former the bacteria are disseminated by the lymphatics; in appendicitis or diverticulitis an abscess may open into the kidney or ureter, or the latter structure may be involved in the inflammatory deposit. In the female, infection may easily spread along the short urethra from the vulva.

The organisms usually present are staphylococci, streptococci or the *B. coli*, which, as will be seen later, is constantly associated with inflammation of the bladder. *B. proteus* and *B capsulatus mucosus* are more rarely found; the latter is almost invariably secondary to infection of the nose with this organism.

1. **Pyelitis** is the term applied to an inflammation involving the pelvis of the kidney, the calyces, and perhaps the ureter. The chief predisposing causes from which it arises are: (*a*) The presence of a calculus, or the passage of uric acid crystals in gouty individuals; (*b*) tuberculous disease, either starting primarily in the kidney or extending upwards from the bladder; (*c*) extension of septic inflammation from the bladder and urethra; (*d*) malignant disease of the kidney; (*e*) occasionally in floating or movable kidney; (*f*) the ingestion of irritating drugs, *e.g.* cantharides, turpentine, and even cubebs or copaiba; (*g*) the presence of foreign bodies, such as needles, bullets, and parasites, *e.g.* the *Bilharzia hæmatobia*; * (*h*) a pyæmic embolus; and (*i*) possibly cold. Any condition with urinary stasis will render greater the possibility of pyelitis; this may explain the frequency with which it occurs in pregnancy. In the milder cases and in the early stages it may be a simple catarrhal inflammation, but it is almost certain to become purulent if it lasts long.

Whatever the cause, the pathological phenomena are the same, consisting in the lining membrane becoming congested and thickened, and secreting a muco-purulent, or even purulent, discharge. Owing to the swelling of the mucous membrane, the entrance to the ureter is encroached on, and a certain amount of distension of the pelvis and calyces (hydronephrosis) follows. The renal parenchyma is always more or less involved in the process (pyelonephritis).

The **Symptoms** of pyelitis consist of pain and tenderness over the affected kidney, increased frequency of micturition, and the presence of *pus in acid urine*. Necessarily, where pyelitis follows chronic cystitis, the acid reaction is neutralized if the urine in the bladder has become alkaline. The highly acid urine often causes scalding at micturition. The general condition of the patient is much upset, the temperature is high (particularly in children), and rigors are not unusual.

* Infection with *Bilharzia hæmatobia* occurs most commonly in Egypt, and symptoms are produced by disposition of the ova in the venous radicles of the bladder. Cystitis is the result, and by a process of fibrosis the bladder and ureter may become seriously contracted. Patients reach temperate climes with chronic cystitis which gives a typical cystoscopic appearance of ground glass and particles of sand; ova are sometimes found in the urine or seen in the bladder wall As a result of continued irritation, papillomatosis or carcinoma may arise.

The tongue is dry and the pulse rapid. The urine is acid, hazy (due to bacilluria), and has a fishy odour; in the later stages there may be a heavy deposit of pus and mucus. At cystoscopy the ureteric orifice of the affected side will be red and œdematous, while efflux of turbid urine may be observed.

The **Treatment** of pyelitis is (*a*) to the disease itself, (*b*) to the predisposing cause.

(*a*) Rest in bed with fluid diet is important; the patient should be encouraged to drink freely of barley water, etc.; attention must be paid to the bowels. Alkalies (potassium citrate) and sedatives (tincture of hyoscyamus) should be administered in full doses six-hourly.

Many cases pass into a condition of chronic pyelitis from which acute exacerbations are liable, so it is important to persevere with treatment at the first attack.

After about fourteen days (with the temperature now rising only about 1 degree) urinary antiseptics may be administered, of which hexamine (gr. x. t.d.s.) is the most popular; with this alkalies must be discontinued, as hexamine acts only in an acid urine. Others are hexyl resorcinol, methylene blue, etc. An autogenous vaccine is of assistance, and should be given in resistant cases. Lavage of the renal pelvis, 0·5 per cent. argyrol being the antiseptic used, should not be used as routine, but is of help in cases of pyelitis of pregnancy, in which, however, the presence alone of an indwelling ureteric catheter for twenty-four hours to promote drainage is often productive of excellent results. Ketogenic diet treatment should be reserved for chronic cases when other treatment has failed; the diet, by limiting carbohydrates and increasing fat, produces a ketosis which certainly improves the patient, many patients, however, are unable to digest such a diet, which must be arranged by a competent dietetist. Recently mandelic acid treatment had replaced ketogenic diet, some new proprietary preparations (Mandelix, Neoket, etc) being easier and more pleasant to administer than the original tablets with which it was necessary to exhibit ammonium chloride. This treatment is based on the principles of the ketogenic diet, producing a highly acid urine in itself bactericidal, to which is added some empirical antiseptic action of the mandelic acid.

(*b*) The predisposing cause should be treated after the subsidence of the acute stage of pyelitis. X-ray is always important to exclude stone, which must be dealt with. Similarly urethral stricture, septic tonsils, and other predisposing causes must have appropriate treatment.

2. **Pyelonephritis,** or inflammation of the pelvis of the kidney, together with the renal parenchyma, is almost invariably suppurative in type, and either due to extension upwards from the lower urinary organs, or to local lesions of the pelvis or kidney.

In almost all cases of pyelitis a certain degree of renal congestion is present; but when the condition becomes confirmed, and especially when infective matter is present in the calyces, it is certain to light up a subacute interstitial nephritis. The kidney becomes swollen and

purple, with cloudy swelling of the epithelium. In the latter stages bacteria invade the pyramids and travel upwards along the lymphatics or renal tubules, giving rise to abscesses, either scattered through the connective tissue of the organ or within its tubules, in either case seriously damaging its excretory function. In both instances it is possible for many of these minute foci of pus to run together and form a large collection, which in time may become recognizable from outside; but more usually the patient dies of toxæmia or uræmia long before that stage is reached. When the affection ascends from the bladder it may commence suddenly and with acute symptoms, and then probably results from some surgical operation or simply from catheterism in a patient whose bladder is in a highly septic condition. The organisms find their way upwards along the ureters, and infect the pelvis.

Sometimes the trouble is primarily cortical and of hæmatogenous origin. The organisms are then generally staphylococci, and the patients children. A subcortical abscess is an early development, and this may spread either towards the surface of the organ and involve the perinephric tissue, or it may invade the pelvis.

A *carbuncle* of the kidney is similar, but tends to be localized to one pole of the kidney and resemble the processes of carbuncle formation elsewhere.

Clinical History.—In *acute* cases the symptoms probably commence with a severe rigor, associated with pain in the loins or back, headache, vomiting, great thirst, and probably some amount of drowsiness, perhaps passing into a condition of coma. They may have been preceded by signs of a pre-existing bladder infection, such as acute dysuria or strangury, for a few days. The rigor may be repeated, or the fever may remain high without exacerbations, but if uræmia is present or threatening, the temperature may be subnormal. The kidneys are felt to be enlarged and tender, and the urine is usually diminished in amount, and, indeed, may be suppressed entirely; if any passes, it is high-coloured and contains albumen and perhaps blood, with some amount of pus, which is probably derived largely from the lower portion of the urinary tract. The prognosis of the worst cases, which supervene on old bladder trouble, is nearly hopeless, the patient being almost certain to die of uræmia, especially as both kidneys are generally affected. In less acute cases, occurring most often in young people, secondary to a bacillary cystitis, the symptoms often improve in a few days and quiet down; but the urine is swarming with bacilli, and recurrence of the trouble is not uncommon. Abscess may sometimes supervene.

In the more *chronic* cases, the symptoms are those of pyrexia, at first only slight, but gradually increasing and taking on the hectic type. The kidney is slightly enlarged and tender; the urine contains epithelial cells from the pelvis or renal casts, and may be acid in the early stages, but is usually alkaline in the late. As the condition progresses the temperature rises; the patient wastes and is very sallow; appetite and digestive functions flag; slight delirium supervenes at night; and unless the cause can be removed or dealt with effectively,

death from uræmia is likely to follow. If, however, effective treatment is possible, recovery may follow, but the kidney is permanently damaged, and some degree of sclerosis follows.

Treatment.—In the *chronic* variety, the cause must first be dealt with, but the surgeon must not forget that an acute attack may be easily lighted up by injudicious instrumentation or operations. Hence it is often desirable to drain and wash out the bladder first, as by a suprapubic cystotomy, rather than at once to dilate or divide a stricture of the urethra, or to remove an enlarged prostate or calculus. At the same time the patient is kept in bed, and encouraged to drink plenty of bland fluids. An autogenous vaccine may be of slight help. A prolonged visit to the country or seaside, and freedom from exposure to wet and cold, are essential elements in the treatment. In cases where there is an abundant development of bacilli in the urine with no serious disease of the lower urinary organs, lavage of the renal pelvis after the passage of a ureteral catheter is a valuable procedure. Silver nitrate solution (1 in 15,000) may be employed, or collosol silver ($\frac{1}{2}$ or $\frac{1}{4}$ strength). This must never be undertaken by the inexperienced; only by experts. In the *acute* form the patient is kept warm in bed, and plenty of fluid, such as milk or barley-water, is given; stimulants are avoided, as also opium. Hot-air baths, wet packs, and the hypodermic injection of pilocarpine, will suffice to get the skin to act well, and watery purgatives, such as jalap and scammony, are needed for the bowels. The loins are fomented or cupped, but if the urinary secretion is not re-established, or if it is suppressed, or if the phenomena of suppuration supervene, incision of the kidney and drainage of the pelvis (*nephrostomy*) are essential. It is sometimes remarkable to observe how rapidly the symptoms improve after such a procedure, and how quickly the urinary secretion is re-established.

3. **Pyonephrosis** is the term applied to indicate the association of a chronic pyelonephritis with distension of the pelvis and ureter, as a result of obstruction of the passage of urine. It may be unilateral or bilateral, open or closed. When unilateral, it is most commonly due to the presence of a calculus, or of tuberculous disease, the obstruction being caused by the swelling of the ureteral mucous membrane, if the affection is secondary to obstruction in the lower urinary passages, it is usually bilateral. The lining membrane of the pelvis is inflamed, thickened, and perhaps ulcerated; decomposing urine and pus collect in the dilated pelvis and calyces, and a soft, friable, phosphatic calculus may develop, even in cases where the originating cause is not of a calculous nature. Obstruction to the outlet may lead to such an accumulation of pus as to constitute an abscess of the kidney, whilst a certain amount of perinephritis is always present, rendering the kidney fixed and adherent to neighbouring structures. If the obstruction is low, the ureter will be thickened with dilated lumen, which will contain pus.

The **Clinical Signs** are very similar to those of pyelonephritis, but to them are added those of an enlarged, fixed, tender, and painful kidney, and abundant pyuria, usually intermittent. The temperature is somewhat raised, especially at night, from the absorption of toxic products;

the patient becomes emaciated; the tongue is dry, the appetite diminished, and nausea and vomiting are sometimes present. The urine is generally scanty in amount, and if both kidneys are involved, the excretion gradually diminishes, leading to a fatal issue from uræmia, unless the patient dies previously from toxæmia or pyæmia. At cystoscopy a thick column of pus may be seen issuing from an open œdematous ureter.

Treatment.—Where both kidneys are involved as a result of some urethral or prostatic affection, no special treatment directed to the kidneys is feasible, except bilateral nephrostomy; but if the condition is unilateral, nephrostomy should be undertaken, and any removable cause dealt with, and later, if the other kidney is healthy, when the acute process has subsided, nephrectomy should be performed.

4. **Abscess of the Kidney** may follow any of the conditions already alluded to, in which bacteria gain access to the organ from below, the pus then collecting in the pelvis and dilated calyces. It also occurs in connection with pyæmia, and sometimes develops after the general infective fevers. It usually commences as an acute interstitial nephritis, where the abscesses are multiple and at first small, being located between the tubules or sometimes within them; the pyramids then have a streaky-white appearance, due to their infiltration with pus, and the abscesses form in the cortical substance at their base. Larger collections are caused by the amalgamation of several of the smaller. In pyæmia the abscesses are preceded by infarcts, which appear immediately beneath the capsule as wedge-shaped areas of a chocolate colour, which turns a yellowish-white as suppuration occurs. The kidney becomes enlarged and tender, and can usually be felt from outside, but fluctuation is rarely to be detected. The abscess may burst into the pelvis and discharge through the ureter, but when due to an ascending pyelonephritis from obstruction this is not likely to be the case. The inflammation is more liable to spread outwards through the kidney substance, and give rise to a suppurative perinephritis. The general symptoms produced are similar to those present in acute pyelonephritis. Treatment of an abscess of the kidney consists in nephrostomy for drainage purposes, or perhaps nephrectomy.

The more chronic varieties are probably tuberculous in origin, and may then attain considerable dimensions, all that is noted being the lumbar swelling, whilst pyuria is not necessarily present, owing to the ureter becoming blocked.

Perinephritis is usually recognized only when suppurative in nature; it may be primary, following boils, tonsillitis, etc., and is a blood-stream infection, or it may be secondary to neighbouring suppuration from kidney—most frequently a staphylococcal cortical infection—appendix, pleural cavity, ribs, spine, etc. It is usually behind the kidney, but may be found in any relation to it.

Symptoms.—In *acute perinephritis* signs of deep suppuration in the loin are produced, *viz.* an indurated painful swelling, associated with fever, and perhaps preceded by rigors. The body is held stiff and rigid, with an inclination towards the affected side. Fluctuation may sometimes be detected when pus has formed, but the abscess is often so

deeply placed that it is difficult to recognize at first; it is likely to point at the side of the erector spinæ, or may burrow forwards between the abdominal muscles, and find an exit on the anterior abdominal wall. Occasionally it bursts into the peritoneal or pleural cavities, or into the intestine. If it comes to the surface, it is preceded by congestion and œdema of the skin. Chronic perinephritis gives rise to no characteristic symptoms until an abscess forms which is large enough to be felt. If of the non-suppurative type, as occurs sometimes with tuberculosis or chronic staphylococcal abscess, much fibrous tissue may be laid down, forming a hard fixed swelling and rendering operative interference very difficult.

Treatment in the suppurating variety consists in giving exit to the pus through an incision at the outer border of the erector spinæ; the cavity is then carefully examined, and the cause of the suppuration, if possible, determined, and treated according to the requisites of the case.

Tuberculous Disease of the Kidney occurs in one of three forms:

(*a*) **Miliary Tuberculosis** arises in the course of acute general tuberculosis, when miliary tubercles will be found studding both organs. Treatment is impracticable.

(*b*) **Tuberculous Nephritis** is the term applied to a toxic condition of both kidneys, which show cloudy swelling as a result of extensive and usually obvious tuberculous infection elsewhere, *e.g.* lungs. Tuberculous bacilluria may be present, and also a considerable amount of albumen, but there will be no pus cells. Local treatment is of no avail, and it is accordingly important to distinguish this medical renal tuberculosis from surgical renal tuberculosis.

(*c*) **Primary Tuberculosis (Surgical Tuberculosis)** of the kidney is generally unilateral in the early stages (80 per cent.), but is bilateral in 60 per cent. of cases at death; it is more likely to be bilateral in children. The infection is by the blood-stream, and a tubercle is deposited at the apex of a pyramid which will proceed to **caseation** and **ulceration;** from this area there will be seen streaks of infected lymphatics to the overlying capsule, which will become thickened and adherent at this part, and fresh tubercles may form in the cortex from this lymphatic spread. Fibrosis at the apex of the calyx will lead to occlusion of that part of the kidney and to **Tuberculous Hydronephrosis;** but if secreting tissue has been destroyed in that segment, **Massive Caseous Tubercle** will result. **Tuberculous Perinephritis** from the infected capsule will cause adhesions and possibly abscess in the perinephric fat.

Simultaneously the infection will spread to the pelvis, ureter, and bladder; submucous tubercles occur, and by their production of tuberculous granulation tissue may block the ureter with caseous débris or by stricture from the contraction of fibrous tissue. The ureter may ultimately be converted into a hard thickened cord, which by contraction drags upon its outlet in the bladder and may even partially rotate the bladder (Fig. 952).

Symptoms are at first indefinite, and are more likely to be present from early spread of infection to the bladder.

The patient is usually a young adult, and rather more frequently a male than a female. He complains of increased frequency of micturition, and unilateral pain in the loin, neither of which conditions is improved by rest, remaining the same at night as in the day, and, indeed, sometimes being worse. There may be a true polyuria in early stages owing to diuresis. The pain is generally of an aching character, and more or less constant, although exacerbations may occur, taking on the type of mild renal colic, in consequence of the passage of fragments of disintegrated mucous membrane, or of caseous material. The urine is acid, and usually contains a certain proportion of pus, and the *B. tuberculosis* can usually be found after centrifugalizing a complete twenty-four-hour specimen. Hæmaturia varies in amount, and may be the first symptom to appear, or may not occur at all; the bleeding may come from the kidney or from a tuberculous ulcer in the bladder; this latter is capable of causing considerable hæmorrhage. Albuminuria is not so marked as in the tuberculous nephritis cases. Loss of weight, night sweats, and a nocturnal rise of temperature are present in the later stages. On examination the kidney may be slightly enlarged, with some tenderness, but it must be remembered that one kidney may be destroyed with hypertrophy of the other, and that the enlarged kidney is in fact the healthy kidney. A thickened ureter is occasionally palpable on abdominal, rectal, or vaginal examination.

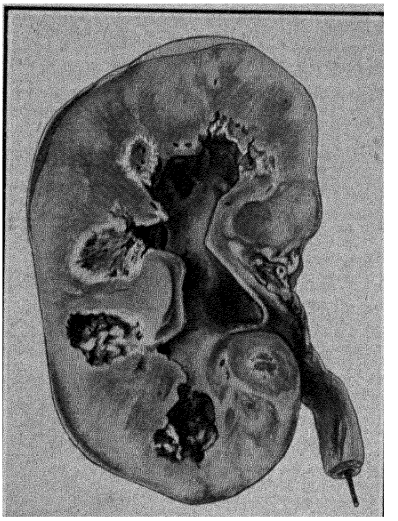

FIG 952.—TUBERCULOUS KIDNEY, SHOWING THICKENING OF MUCOUS MEMBRANE OF PELVIS AND URETER (FROM SPECIMEN IN KING'S COLLEGE HOSPITAL MUSEUM)

Diagnosis.—The age of the patient and his personal and family history may be of importance, and he should be carefully examined for evidences of tuberculous disease elsewhere, especially in the genital organs, particularly prostate and seminal vesicles. Pus in acid urine in which pyogenic bacteria are not found is most suggestive of tuberculosis, which will be established by finding of the acid-fast Koch's bacillus. Radiography will determine the presence or absence of a stone, but also of calcified caseous deposits. Cystoscopy may reveal the existence of tuberculous ulcers in the bladder close to the ureteral orifice in the earlier stages, or of a retracted ureter, when the latter has become transformed into a solid cord.

It is necessary to catheterize each ureter to determine whether the infection is unilateral or bilateral; in cases of doubt the urine from a suspected kidney may be injected into a guinea-pig, which will show evidence of tuberculosis in some eight or ten weeks in positive cases.

If severe, tuberculous cystitis renders recognition of the ureteric orifices difficult; these may be seen after intravenous injection of indigo-carmine and catheterized. In severe cases the condition of the bladder may be somewhat improved to permit of adequate ureteric catheterization by a short course of tuberculin injections. It should no longer be necessary to expose the ureters at the brim of the pelvis in difficult cases to obtain urine specimens, as the information given by intravenous pyelography will displace this severe investigation.

Treatment.—Nephrectomy is the only satisfactory treatment, to be performed while the disease is still unilateral, removing the ureter as far as the brim of the pelvis. This should be followed by routine anti-tuberculous treatment of the sanatorium type and the administration of tuberculin for a long period. In bilateral cases general treatment only is possible, belladonna being useful for the milder degrees of dysuria. Excision of the presacral nerve is a useful palliative for pain and frequency (of bilateral renal tubercle or of carcinoma of the bladder), allowing sleep at night and yet not causing any lack of control.

The tuberculous cystitis usually clears up gradually after the removal of the kidney, but sometimes infection is maintained from the stump of the ureter, which must then be removed at a second operation.

Renal Calculus.—All renal concretions are primarily excreted in a crystalline form from the renal tubules, but under ordinary circumstances are sufficiently small to find their way into the pelvis of the kidney, and thence along the ureter to the bladder. If, however, they are obstructed in their onward course, either on account of their size or shape, or some narrowing of the tubules, they may become lodged in the kidney substance or in one of the lower calyces, and by the gradual deposit of the same material increase in size until large enough to give rise to symptoms. Renal calculi are usually not of great bulk; occasionally, however, the whole of the pelvis and some of the calyces may be occupied by a concretion, which takes the shape of the cavity in which it lies (Plate XXVII.). When many calculi are present in the pelvis of a kidney they are usually faceted. Chemically they consist most commonly of oxalate of lime, though in some few cases they are composed of uric acid or urate of ammonium; when associated with suppurative pyelitis, a phosphatic element is often present.

The **Pathological Phenomena** connected with renal calculi vary with their size, shape, number, and position. If situated in the substance of the renal parenchyma, they may give rise to but little trouble, being more or less encapsuled in a cavity lined by granulation tissue or surrounded by a dense fibrous capsule. Sometimes ulceration of the wall and suppurative perinephritis may follow; the calculus may even find its way into the abscess cavity, and be discharged spontaneously or removed through the loin, a urinary fistula perhaps resulting. The

PLATE XXVII



Large branched Renal Calculus
(*King's College Hospital Museum*)

[*To face page* 1456

calculus may be gripped by the neck of one of the calyces, and thus immobilized; the calyx involved will then become dilated (localized hydronephrosis), and the kidney substance thinned over it. At times the whole pelvis is filled by a large branching calculus, extending into a number of calyces; there is then little mobility, but suppurative pyelonephritis follows, and the kidney substance is seriously damaged. When lying loosely within the pelvis of the kidney, a calculus sets up a suppurative pyelitis, and from the obstruction to the flow of urine, caused partly by the thickening of the mucous membrane and partly by the stone engaging the orifice of the ureter, produces dilatation of the pelvis of the kidney, and the phenomena of hydro- or pyo-nephrosis. If the calculus passes down the ureter, it gives rise to the symptoms of renal colic. When small and smooth, it usually reaches the bladder without much difficulty, and is then voided with the urine, or remains as a vesical calculus. Occasionally, owing to its size or irregular shape, it becomes impacted in the ureter, giving rise to acute obstruction and the cessation of the urinary secretion on that side, followed in time by disorganization. If the kidney thus affected is the only one available for excretory purposes, or if both ureters are similarly obstructed, the patient, if unrelieved, dies in a few days from suppression of urine (*calculus anuria*). In other cases the stone ulcerates through the wall of the ureter, leading to a retroperitoneal urinary abscess, or possibly to suppurative peritonitis. If the ureter is only partially obstructed by the calculus, the changes which take place in the kidney are more gradual, and result in hydro- or pyo-nephrosis.

The typical **Symptoms** arising from renal calculus are as follows: The patient complains of pain in the loin, more or less persistent, and often paroxysmal in nature, which is, however, usually increased on exercise or jolting, it is frequently referred to distant regions, but most commonly follows the course of the genito-crural nerve, giving rise to pain in front of the thigh, accompanied by retraction of the testicle; in the female it is experienced in the labium majus; sometimes it also extends down the back of the thigh. It is almost invariably associated with hæmaturia, and often with pyuria. Frequency of micturition is a prominent symptom, and if the pelvis is enlarged the kidney may be tender and distinctly palpable. If the calculus is lodged in the renal parenchyma, the urinary secretion may be but little influenced, although the characteristic pain is well marked; the patient also finds that at night he can only gain relief by lying on the affected side, and on manual examination the kidney, though somewhat tender, is not much enlarged. When the calculus lies in the pelvis or one of the calyces, typical symptoms are produced. On the other hand, it is an undoubted fact that stones even of large size may exist for years in the kidney without giving rise to any symptoms whatever.

The passage of the calculus down the ureter is accompanied by the symptoms known as **Renal Colic.** They consist of excruciating pain of a paroxysmal nature, which comes on suddenly and is referred both to the loin and along the course of the genito-crural nerve. It is always associated with vomiting and severe shock, the patient often lying on

the floor writhing in agony, with cold perspiration standing in beads on his forehead. The temperature is subnormal, and the pulse weak and rapid. Strangury is usually present, the patient suffering from frequent paroxysmal efforts to pass water, but only succeeding in voiding a small amount, and that generally blood-stained. After lasting for a variable period, the pain suddenly ceases, as a result of the passage of the calculus into the bladder, or of its slipping back into the pelvis of the kidney.

Impaction in the Ureter may occur either 2 inches below the pelvis of the kidney, or near the brim of the pelvis, or near the vesical orifice, sometimes even protruding through it. Generally only one stone is present, but occasionally more; the size is rarely greater than a coffee-bean and the shape is usually somewhat elongated, like a date-stone. In thin persons it has been detected on palpation through the abdominal wall, and when low down has been felt on rectal or vaginal examination. Persistent pain and hæmaturia extending over days or weeks should certainly suggest the presence of a ureteral calculus, and the more so if with each succeeding attack the pain and tenderness are located lower down. The result may be that the stone will ulcerate through into the retroperitoneal tissue, and be discharged in an abscess, or more frequently the kidney becomes disorganized, and perhaps the patient's life is destroyed through the resulting renal incompetence.

Occasionally the function of both kidneys is brought to an end—on the one side by the back pressure of urine due to the impaction of a small calculus; on the sound side, by reflex suppression of urine. In a case of this character operated on some years back all the symptoms were on the left sound side, and in the unavoidable absence of a radiograph the kidney and ureter on this side were first explored and found normal, the peritoneum was then opened, and an impacted stone detected in the right ureter, and through a second incision this was removed. The urinary secretion was at once recommenced.

Should the ureter of a solitary kidney be blocked by a stone, grave symptoms of **calculous anuria,** or suppression, will arise. The condition is ushered in by pain in the loin of the usual character, which often passes away in two or three days. The anuria is rarely complete at first, a few ounces of pale limpid urine being passed at intervals, whilst occasionally distinct polyuria is present. Sooner or later definite uræmic phenomena supervene, the most usual period is seven or eight days after the onset, but incomplete obstruction or a pre-existing condition of hydronephrosis may delay matters. The onset of uræmia is indicated by dry red or furred tongue, persistent vomiting, a slow, full pulse becoming irregular, contraction of the pupils, and muscular tremors. Coma and convulsions are rarely seen, and there is no dyspnœa; the temperature is subnormal.

The **Diagnosis** of renal calculus is often a matter of uncertainty in the absence of a history of the passage of gravel or of the occurrence of renal colic. It is most likely to be mistaken for tuberculous disease, the differential diagnosis between the two conditions has already been considered (p. 1454). The final determination of the presence or not of a renal or ureteral calculus is now made by radiography, which has

PLATE XXVIII.

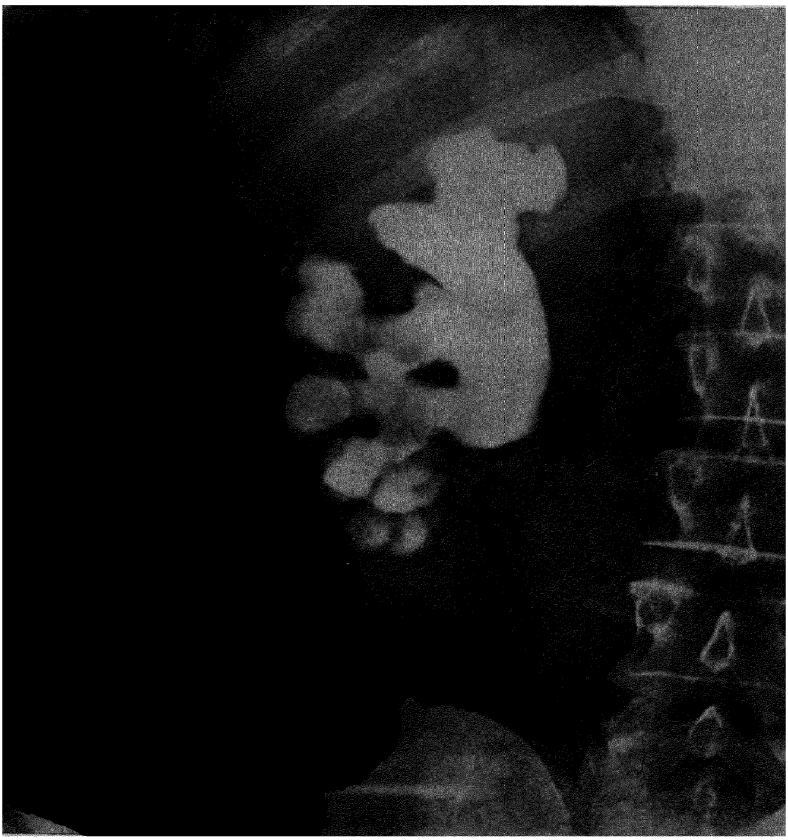

LARGE BRANCHING CALCULUS IN RIGHT KIDNEY

made such advances that it may be relied on with almost absolute certainty, except perhaps in the case of the small pure uric acid calculi.

Reference has already been made (p. 1457) to some of the conditions which must be observed if a reliable result is to be obtained. It is a good rule to follow that a secondary confirmatory examination should be made after an interval of two or three days in all cases where the diagnosis has not been established beyond all shadow of doubt. If a small stone has been located in the kidney, and operation has for some reason or other been deferred, it is always advisable that a confirmatory radiograph be taken immediately before the operation. Cases have been known where a stone had, during an interval, shifted its position from the kidney to within an inch or two of the lower end of the ureter without any symptom which could suggest the change of position.

Treatment.—Attacks of renal colic are treated by the use of hot hip-baths, warm drinks, and hypodermic injections of morphia and atropine; in the more severe cases chloroform must be administered.

In former days, when the presence of a calculus could only be suspected from the history of symptoms, the question of operation and when to undertake it was a subject of much discussion. Even at that time the late Sir Henry Morris wrote that an 'unsuspected renal calculus is a source of very real danger; and when its presence is disclosed, whether by accident or by the systematic examination of the urine, we should recommend its immediate removal, regardless of the fact that it is not causing pain, unless the general condition of the patient contra-indicates an operation.' At the present day, when radiography has placed in our hands a means of almost certain diagnosis, the same advice holds good: *whenever a stone is found, remove it,* unless special contra-indications exist (Plate XXVIII.). Particularly is this the case when a considerable amount of blood or pus is being passed in the urine, and the patient's temperature is raised. Moreover, pain in both kidneys is no contra-indication, since there is no objection to operating on the second kidney some little time after the first has been satisfactorily treated. After operation the nature of the stone should be determined by analysis and the patient placed on an appropriate diet, *i.e.* cases of oxalate stone to avoid strawberries, spinach, veal, etc. The patient should be instructed always to partake freely of bland fluids and his habits of life should be regulated.

Nephro-lithotomy is always undertaken through the loin. When exposed, the kidney is carefully freed from its connections and drawn up into the wound; in the majority of patients it can be brought out on the loin, and this is certainly a desirable manœuvre. The whole gland is then carefully palpated, as also the pelvis and upper part of the ureter, so as to locate, if possible, the stone. Should it be distinctly felt within the kidney substance, or should an area of thinned cortex exist, an incision is made over it through the renal parenchyma; free hæmorrhage follows, but this is readily controlled by inserting the finger into the wound, or by grasping the vessels in the hilum. Should the stone not be palpable, it may be possible to detect it by needling the organ, and, failing that, an incision is made through the convex border

of the kidney substance a little posterior to the mesial plane of the organ and at the junction of its inferior and middle thirds ('bloodless line' of Broedel). One of the lower calyces is opened by this means, and the interior of the pelvis is carefully and fully explored by finger and probe. It is unwise to incise the kidney to any extent, especially in searching for a small calculus; the hæmorrhage is always severe, and although checked by sutures, these may be dissolved in six or eight days, and secondary hæmorrhage may arise which may prove fatal. When the pelvis is much distended and the patient has previously passed a good deal of pus, careful precautions must be taken to protect the surrounding tissues from infection. Bleeding is usually controlled without difficulty by stitches passed through the kidney substance, to which in bad cases may be superadded pressure by sponge or a gauze plug in the wound. It is useless to attempt to place a ligature on a vessel divided in the renal parenchyma. Should bleeding persist, sutures of the mattress type should be introduced and tied firmly. It is wise to insert a drainage-tube down to the sutured wound in the kidney after it has been replaced. The abdominal parietes may then be closed in the usual way.

The incision was formerly made through the cortex in preference to opening directly into the pelvis; but the objection often stated that a pelvic incision heals with difficulty, and is liable to leave a fistula, is not true, and most surgeons now deliberately open the pelvis (**pyelotomy**) in order to extract stones if it is more convenient to get at them in this way. An incision large enough to introduce the gloved little finger may be made, and by this means the whole kidney can be explored bimanually. Accurate suturing with catgut is generally successful in securing immediate healing, but the sutures must not encroach on the mucous membrane. Stones are removed by dressing forceps or scoop, and care must be exercised to prevent any from falling back into the ureter. Large branched calculi are often held very tightly, and require an extensive incision and careful peeling off of the kidney substance The pelvic cavity need not be irrigated under ordinary circumstances, but when dilated and suppurating it is well to do so with a hot solution of 1 in 10,000 silver nitrate. Before closing the wound in the kidney or pelvis the ureter should be thoroughly examined; it is sometimes possible to introduce a ureteral sound through the open wound, but this is by no means easy in the renal operation, and it is then often wiser to make a tiny opening through the pelvic infundibulum, through which the sound is passed, and which is subsequently closed by a Lembert suture.

To explore and expose the ureter the incision should be prolonged downwards and forwards in a direction parallel with Poupart's ligament towards the inguinal canal. The peritoneum and its contents are pushed bodily inwards, and the ureter attached to the posterior peritoneal wall can be followed down to within a few inches of the bladder. For a stone impacted near the lower end of the ureter, **uretero-lithotomy** is performed with the patient in the Trendelenburg position. The operation may be trans- or retro-peritoneal.

1. The *trans-peritoneal* operation is conducted through an incision

in the middle line. The stone is located, and, if possible, coaxed by the finger out of the depths of the pelvis to a more accessible position. It is then cut down on through the peritoneum, and the stone removed. The incision is closed by a Lembert suture or two.

2. The *retroperitoneal* route is the most often used, the incision being usually mid-line, but without opening the peritoneum, which is gradually peeled off from the side of the pelvis on which the ureter is to be examined. An incision similar to that for tying the common iliac artery (Fig. 142, p. 351) may also be used. The peritoneum and its contents are displaced inwards, and the ureter is easily found running down on its posterior aspect. The stone is, if possible, displaced up from the pelvis and removed. Cases seem to do equally well whether the ureter is sutured or not, granting that the stone is small. The uncertainty of the local condition, which may be disclosed on operation, leads the authors to favour the retroperitoneal operation as the safer of the two procedures. All operations involving incisions in the renal pelvis or the ureter must include drainage of the peri-pelvic or peri-ureteric regions for seven days by rubber tubing.

When the kidney is totally disorganized, **nephrectomy** may be required, but such treatment is not always advisable, especially when sinuses have resulted from suppurative perinephritis. In such cases the renal tissue has often entirely disappeared, and disintegrating calculous material may occupy the pelvis, which is surrounded by a mass of dense fibro-cicatricial tissue, the removal of which is impracticable and even dangerous. All that should be attempted locally is the extraction of the stone and the purification of the cavity.

Purpura of the Kidney.—It is one of the rarer causes of hæmaturia, and in quite a number of cases is due to a streptococcal infection of the throat, teeth, or bowel. Fortunately, the exhibition of horse serum by the mouth usually has an immediate effect in checking the bleeding tendency, but nephrectomy may be required. In bilateral recurrent cases splenectomy should be considered.

Tumours of the Kidney.—The different forms of tumour which originate in the kidney may be classified as the **simple** and the **malignant.** Several cystic conditions also occur. The general features of an enlarged kidney have been already described (p. 1435).

The **simple** tumours of the kidney are:

1. **Diffuse Cystic Disease** (or, as it has been termed, adenoma of the kidney), which may be congenital or acquired. It is almost invariably bilateral. The kidney is enlarged and occupied by cysts, varying in size, but rarely exceeding that of a cherry; they are lined with epithelium which is generally flattened, and filled with a limpid fluid containing urea, and perhaps cholesterine. The cysts are very numerous, and project from the surface of the kidney as nodular elastic outgrowths.

The pelvis remains unaffected until the later stages of the disease (Fig. 953). Generally the whole kidney is involved, and may attain enormous dimensions, constituting large swellings, which can be easily felt, and with a distinctly nodulated surface; occasionally the growth is limited to one portion of the organ. The origin of this

condition is uncertain, but it is supposed to be due to the persistence of the mesonephros (or Wolffian body) in the substance of the true kidney (or metanephros), and its development into cysts. In the early stages no symptoms are produced, except perhaps a sense of dragging weight in the loins from the size of the tumours; but later on the secretion of urine is interfered with to such an extent as to produce renal incompetency and finally uræmia. Hæmaturia is sometimes the cause of drawing attention to the condition. The tendency of this affection to involve both kidneys prevents any hope of benefit from operation. Puncture of the cysts by relieving pressure on the renal substance may produce temporary amelioration.

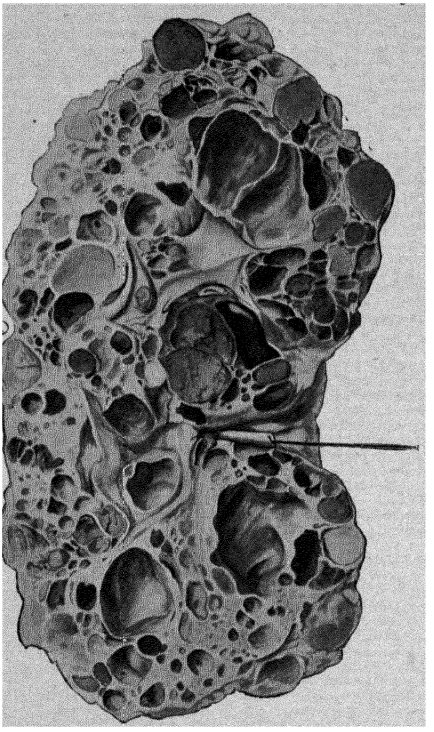

THE KIDNEY. (KING'S COLLEGE HOSPITAL MUSEUM)

A probe has been passed into the ureter

2. **Papilloma** of the renal pelvis is a rare condition, characterized by the development within its cavity of a villous mass, identical in structure with that met with in the bladder. It has usually been observed in elderly people, and the chief, if not the only, symptom is excessive hæmaturia. Although the growth is of an innocent nature, it is very near the border-line of malignancy, because implantation growths quite commonly occur after removal. Diagnosis is made by pyelography, which shows a filling defect of the renal pelvis. Nephrectomy is the only treatment of any permanent value.

3. **Angioma of the Renal Pelvis** is the rarest of the innocent growths of the renal pelvis, and gives rise to painless hæmaturia. Generally nephrectomy is required, but a few cases have been treated by local excision.

Malignant tumours of the kidney may be divided into:

1. The **Sarcomata of Infants** (embryoma), which are often congenital, but may be acquired within the first few years of life. They are encapsuled, the kidney substance being spread over them, and consist of round or spindle cells, the latter often showing a cross-striation,

PLATE XXIX

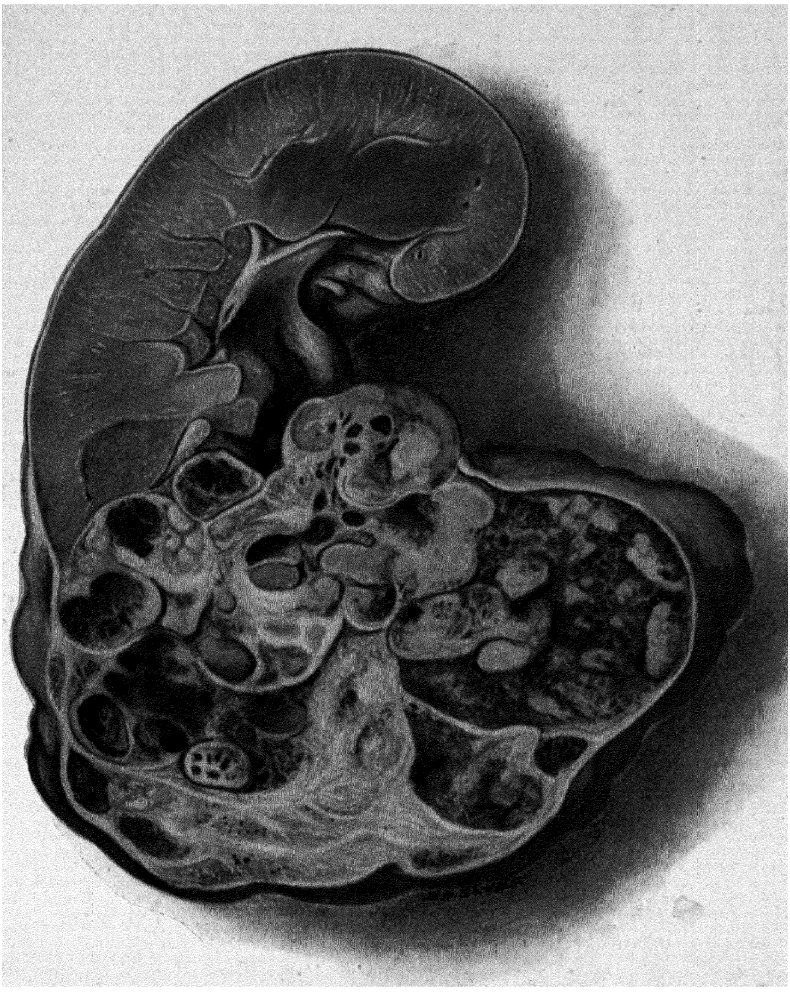

Hypernephroma of the Kidney
(Museum, Royal College of Surgeons)

resembling that of muscular fibres. Some pathologists regard these tumours as teratomata. They grow to a great size, and may affect both organs, with little pain or hæmaturia. Death results from general dissemination or from exhaustion, or may follow the detachment of a sarcomatous embolus, which travels upwards and blocks the pulmonary vessels. **Treatment** by nephrectomy has given most unsatisfactory results, the operative mortality having been high and recurrence within a short period almost invariable. The operation itself is not particularly difficult, but a large incision is required, and care must be taken to avoid displaced structures, such as the inferior vena cava.

2. The **Sarcomata of Adults** occur between the thirtieth and fiftieth years of life, and are of the spindle-celled variety, often originating from the capsule. Only one kidney is generally involved, giving rise to a rapidly-growing swelling, associated with hæmaturia and perhaps pain. Calculi are often found in the pelvis of such organs, and may be causative or consecutive. Secondary deposits form in the viscera; extension through and beyond the capsule is not uncommon, and death is usually due to exhaustion. The results of nephrectomy have not been very encouraging.

3. **Primary Carcinoma** is an uncommon form of tumour in the kidney. It presents the same clinical features as a sarcoma, except that there is rather more pain, and can only be recognized on microscopic examination. One symptom, however, requires special mention, since it is extremely suggestive of the presence of cancer, *viz.* the development of a varicocele. It is due to the pressure of enlarged and cancerous lymphatic glands upon the root of the spermatic vein, and hence, whenever an elderly person develops a varicocele, a careful examination of the kidney on the affected side should always be instituted.

4. The commonest tumours of the kidney, however, are the so-called **Hypernephromata** (75 to 80 per cent. of all renal tumours). They are looked on as growing from accessory and misplaced adrenals (*adrenal rests*), and develop primarily in the cortex as localized growths, gradually increasing in size and encroaching on the pelvis. This theory is not universally accepted, as some surgeons regard these tumours as true carcinomata of the renal tubules. They are of firm consistence, but show areas of necrosis and softening, and deep red patches due to hæmorrhage (Plate XXIX.); the section is more or less mottled, and some bright yellow areas are very evident. On microscopic examination their appearance closely resembles the zona fasciculata of the adrenal bodies, but this theory as to their origin is not universally accepted. They are malignant in type, being disseminated by the bloodvessels, and secondary growths are found in the lungs, liver, or bones.

Hypernephromata usually occur in adults between fifty and seventy years of age, and are of comparatively slow growth. They give rise to hæmaturia, but it is late in appearance, and less persistent than in other malignant growths of the kidney. Pain is often well marked and referred to the loin; it is of two main types—a persistent aching pain, which may be very severe and wearing, and a colicky pain, due to the passage of clots down the ureter. The renal enlargement is usually characteristic, but outgrowths from diffusion beyond the

capsule may render the swelling of irregular shape. **Treatment** consists in removal, if there is no evidence of secondary deposits in the lungs or elsewhere. The operation is by no means simple in cases that are at all advanced, as serious adhesions in various directions may be present and the bleeding may be severe.

Various **Cystic Conditions** of the kidney must be noted in addition to the general cystic disease already described.

(*a*) **Hydatid Disease** affects the kidney, as it may involve any other organ in the body. It starts either beneath the capsule or in the glandular substance. In the former case it is likely to form a rounded projection, which may be detected on palpation of the loin; in the latter it expands, or even destroys, the whole of the glandular tissue, and may burst into the renal pelvis, the cysts being passed along the ureter, accompanied by more or less colic. Suppuration may complicate matters, but, unless the cyst has ruptured into the renal pelvis, diagnosis is scarcely feasible apart from an exploratory incision. *Treatment* consists in cutting down on the kidney, and enucleating the mass, if possible. Failing this, drainage may be undertaken, but in bad cases nephrectomy is necessary.

(*b*) **Dermoid Cysts** have also been found.

(*c*) **Serous Cysts** are occasionally met with, arising possibly as a result of obstruction to some of the ducts, or due to lymphatic obstruction. Rounded swellings, simple or multiple, are produced, growing outwards from the cortex, and containing a thin fluid, with a small amount of albumen and saline substances in solution. They give rise to no symptoms except from their size, and rarely require treatment other than simple aspiration or drainage. If discovered at an operation, and of considerable size, they should be incised, and either dissected out, or the outer wall cut away, and the inner left continuous with the renal capsule.

(*d*) Not unfrequently a number of small cysts develop in connection with chronic granular nephritis, and they are of no clincal importance.

Nephrectomy, for total removal of the kidney, is performed for the following conditions. (*a*) For tuberculous disease, when unilateral; (*b*) for calculous pyonephrosis, when the renal parenchyma is disintegrated; (*c*) for hydronephrosis, when palliative measures or drainage have failed to give relief; (*d*) for malignant disease, (*e*) for traumatic lesions, such as disintegration or rupture, especially if complicated by laceration of the peritoneum; and (*f*) for some cases of ruptured ureter, and fistula from pelvis or ureter when attempts at closure have failed.

Before undertaking the excision of any kidney, however diseased, it is essential that the surgeon should satisfy himself as to the existence of another, and also, if possible, ascertain that it is capable of undertaking the increased duties which will subsequently fall upon it (p. 1437).

Nephrectomy may be undertaken through the abdomen or through the loin; but sundry combinations or modifications of these operations have been recommended by various authorities.

The *Abdominal Operation* is chiefly utilized when the organ is

much enlarged, on account of the readier access obtained, especially to the pedicle. The peritoneum must be carefully protected from septic contamination, when the pelvis and the upper part of the ureter are distended with decomposing pus. The colon and peritoneum are displaced inwards; the kidney is then freed from its adhesions to surrounding tissues, the surgeon endeavouring to keep outside its true capsule, but inside the layer of condensed perinephric tissue. Special precautions must be adopted in dealing with the deep aspect of the tumour, particularly on the right side, where it is occasionally adherent to the inferior vena cava. The mass is now lifted from its bed, and its pedicle, consisting of the ureter and renal vessels, isolated. These latter are secured separately by ligature and divided, a clamp being applied to the distal ends. The ureter is dealt with in the same way, small pieces of gauze being packed round so as to receive any secretion which may escape. The wound in the abdominal parietes is closed in the usual way, provision for drainage being made either through the loin or from the front. Considerable shock is often experienced from this operation.

Occasionally the perinephric adhesions are so firm and extensive that the only practicable plan of removing the organ is to enucleate it from within the capsule as far as the hilum; the capsule is then torn or cut through so as to expose the pelvis and renal vessels, which are secured.

The *Lumbar Method* can be employed when the kidney is not too greatly enlarged. The organ is exposed by the incision already described, enucleated from its surroundings, and the pedicle dealt with as in the abdominal operation.

Should it be desirable to include the ureter in the scope of the operation, the incision may be prolonged into the groin in the direction of the fibres of the external oblique, and the peritoneum and its contents pushed forwards; by this means it can be traced down almost to the bladder. It may be desirable, however, to delay the excision of the ureter to a later date, effecting it through an anterior incision as for a ureteral calculus (p. 1462)

CHAPTER XLII.

BLADDER AND PROSTATE.

Methods of Examining the Bladder.—When a patient presents himself complaining of increased frequency of micturition and other evidences suggestive of chronic disease of the bladder, a systematic examination of the individual and his urinary passages must always be instituted. The history of the case, the character of the symptoms, and the condition of the urine, are carefully gone into. An examination of the bladder should then be made. (1) The patient is laid on a couch, and the lower part of the abdomen uncovered. The hypogastrium is examined by inspection, palpation, and percussion, so as to ascertain whether or not the bladder is distended, or if any abnormal resistance can be felt, either from thickening of the wall or the presence of a tumour. (2) The finger is inserted into the rectum, or, in the female, into the vagina, so as to enable the condition of the posterior vesical wall to be investigated. Enlargement of the prostate or of the vesiculæ seminales can also be detected in this way. (3) A sound is then passed according to the method described at p. 1413, and the anterior of the viscus explored; by this means a calculus may be detected, and even sometimes a tumour, as also a rough and irregular condition of the mucous membrane. (4) The patient may then be asked to void urine, after which a rubber catheter may be introduced, and the amount, if any, of residual urine estimated. (5) As mentioned elsewhere, Bigelow's evacuator is useful, not only to wash out the bladder, but also to detect the presence of very small calculi which the sound may have missed. (6) Of recent years the chief means of examining the interior of the bladder is the *cystoscope*. This consists of a straight tube with a short end bent at an angle, in which an electric lamp is placed, the wires leading to it being carried within the tube. A small window covered with glass is situated close to the angle, and a prism is here inserted in such a manner that, when the surgeon looks through an eyepiece placed at the end of the instrument, he is able to see the portion of the vesical wall illuminated by the electric lamp. To use it the bladder must be previously washed out after some local anæsthetic (novocain) has been introduced into the urethra. In those cases where the bladder is very irritable a spinal anæsthetic is given. About 10 or 12 ounces of boric acid lotion or clear water should be present in the bladder, so as to prevent the vesical wall from being injured by the instrument, which always becomes hot after the lamp has been used for some time. Considerable practice is needed for any useful information to be gained by the aid of this instrument, but in skilled hands much may be learnt as to the condition of the mucous membrane (see Plate XXX.). Slight modifi-

tions of the instrument permit of the passage of a solid bougie or small catheter, which can be inserted into the ureteral orifice and up the ureter. (7) Finally, in cases where great irritability of the bladder exists in spite of treatment, and its presence cannot be explained, an exploratory suprapubic cystotomy is justifiable.

A *distended bladder* constitutes a rounded swelling, which projects above the symphysis pubis, and may even reach to the umbilicus in some cases. The swelling may be visible to the naked eye, and is dull on percussion, the dulness rising directly above the symphysis; it is quite immovable, and therein differs from many ovarian and uterine tumours. Bimanual examination *per vaginam* or *per rectum* should at once indicate its nature; and when at all doubtful, a catheter should be introduced.

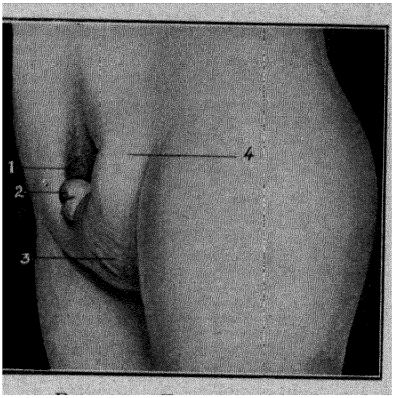

FIG 954.—ECTOPIA VESICÆ

1, Exposed mucous membrane of posterior wall of bladder, 2, glans penis drawn up to cover lower part of vesical mucosa and orifices of the ureters, 3, scrotum, 4, projection of pubic ramus

Congenital Affections of the Bladder.—1. **Ectopia Vesicæ, or Extroversion of the Bladder,** is the term employed to denote total absence of the anterior wall of the bladder and of the lower portion of the abdominal parietes, as a result of which the mucous membrane of the posterior vesical wall is exposed and rendered somewhat prominent by the pressure from behind of the abdominal contents (Fig. 954, 1). This surface is usually not much more than an inch in diameter in an infant, and is often irregular, and covered with papilliform processes, the orifices of the ureters are easily recognized below, urine being occasionally emitted from them in forcible jets. The condition is necessarily one of the greatest discomfort, not only from the constant dribbling of urine causing excoriation and eczema of the thighs and surrounding parts, but also from the pain and irritation due to friction of the clothes against the exposed mucous membrane. The symphysis pubis is always absent, and the horizontal ramus of the pubic arch terminates on either side in the inguinal region (4). The innominate bones are usually rotated outwards, and the sacrum is convex anteriorly from side to side instead of being concave. In consequence of this pelvic malformation, the patient's gait and powers of progression are considerably impaired. The penis (2) is cleft, and in a condition of complete epispadias; it is drawn upwards and backwards over the trigone, so that it requires pulling down to expose the ureteral orifices. The testes are often found in the inguinal canal, or, if in the scrotum, are accompanied by congenital herniæ. No umbilicus is present. The

condition is due to impaired development of the anterior wall of the allantois and the lower segment of the abdominal parietes. At birth the lower portion of the umbilical cord is expanded over the raw surface, constituting the anterior vesical wall. When the cord separates, the posterior vesical wall is necessarily exposed (Fig. 955).

The **Treatment** of this distressing malformation is most unsatisfactory, and hence in the majority of the cases the application of a urinal has been recommended, although the instruments hitherto devised are not particularly efficient. Although various *operative measures* have been practised in the past, the only one which requires mention is implantation of the ureters into the large bowel. The ureters are implanted into the sigmoid, one above the other. One ureter should be implanted at a time, and some months allowed to elapse between the operations. This method has given better results, both in this country and in America (Mayo clinic), than transplanting the whole trigone of the bladder with the ureters into the sigmoid. Turner* has recorded seventeen personal cases with four deaths directly due to the operation, which is very satisfactory considering its severity and delicacy.

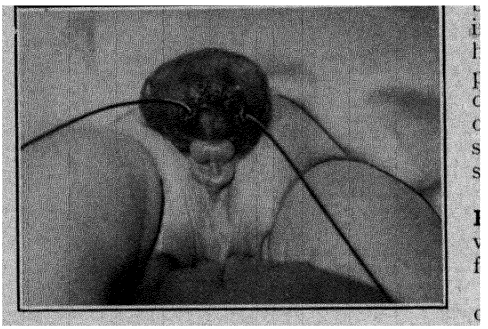

FIG 955.—ECTOPIA VESICÆ. Catheters are inserted into the ureters.

2. An **Umbilical Urinary Fistula** is sometimes met with as a result of imperfect closure of the urachus.

3. Occasionally in cases of malformation of the rectum the **Primitive Cloacal Condition** may in part persist (see p. 1402).

Traumatic Affections of the Bladder.—Rupture may be produced in several ways. (1) It may be due to direct violence applied to the lower part of the abdomen, especially when the viscus is distended. (2) It may complicate a fracture of the pelvis, either as a direct result of the violence, or from penetration of a spicule of bone from the os pubis. (3) The bladder may be opened by a penetrating wound. (4) Apart from traumatic lesions, rupture may occur from simple over-distension, especially if destructive ulceration of its walls is present, or it may follow ulceration of a saccule if it contains a phosphatic concretion.

Rupture of the bladder is divided into two main classes, according to whether or not the peritoneal cavity is opened. The peritoneum covers the upper and back part of the viscus, being reflected anteriorly along the urachus, laterally along the obliterated hypogastric arteries, and posteriorly on to the rectum.

Intraperitoneal Rupture involves the posterior superior portions of the viscus, and is the variety most frequently met with. The

* G. Grey Turner, *Brit. Journ. Surgery*, vol. XVII., No. 65, 1929, p. 114.

symptoms produced are severe shock, associated with hypogastric pain of a burning nature. The patient experiences a constant desire to micturate, but, as a rule, nothing is passed, except perhaps a little blood Peritonitis soon follows, running a rapidly fatal course, especially if efficient treatment is not adopted. On passing a catheter the bladder is usually found empty, or possibly a little blood-stained urine may be withdrawn; if, however, the instrument happens to be insinuated through the rupture into the peritoneal cavity, a considerable quantity of blood-stained urine can be drawn off, and the point of the catheter may be felt under the anterior abdominal wall. A useful diagnostic sign consists in injecting a measured amount of boric acid lotion into the bladder, and noting how much of it returns; when a rupture exists, some considerable discrepancy will probably be noted between the two quantities, this test cannot, however, always be relied on.

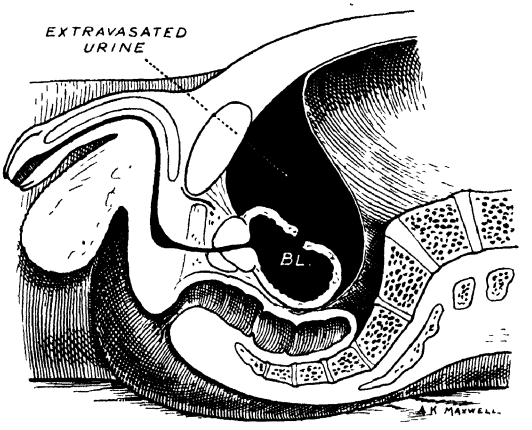

FIG. 956.—EXTRAPERITONEAL RUPTURE OF THE BLADDER

The **Treatment** of these cases consists in immediate laparotomy; the fluid within the peritoneal sac is aspirated or mopped up by swabs, and the wound in the bladder clearly demonstrated, preferably with the patient in the Trendelenburg position, which must not, however, be adopted until the urine and inflammatory effusion have been removed. The rent is carefully closed by means of a row of Lembert sutures, not involving the mucous membrane, which should always extend a little beyond each extremity of the wound. It is safer to drain the bladder by a rubber tube extraperitoneally than to rely on drainage by an indwelling catheter. The peritoneum should also be drained and the abdomen closed in the usual way.

Extraperitoneal Rupture of the bladder involves its anterior wall or base (Fig. 956). The urine finds its way into the pelvic cellular tissue, and gives rise to a most virulent form of suppurative pelvic cellulitis, which is usually fatal from toxæmia or pyæmia. Abscesses generally point either above the pelvic brim or in the perineum. The treatment consists in free incisions into the area of extravasation, and a large suprapubic tube should be introduced into the bladder, through which the urine can escape freely for a time. As soon as the tissues are sealed off by the development of granulations, the tube may be withdrawn. The prognosis largely depends on the condition of the

urine, whether healthy or contaminated with bacteria, and on the length of time it is allowed to remain in contact with the tissues.

Foreign Bodies introduced into the bladder from without are of various natures, such as portions of catheters, or bougies, pins, etc. They give rise to symptoms of chronic cystitis, and usually become encrusted with phosphatic deposit. They should be removed as early as possible with a lithotrite, but if of large size or thickly covered with phosphates, must be treated by suprapubic cystotomy.

Cystitis may be due to a great variety of causes, but is always in essence of bacterial origin. Many different forms of bacteria may be found, but those most usually present are ordinary pyococci and the *B. coli*. Neither of these has any power of decomposing urea and setting free ammonia; this change is generally brought about by the *Micrococcus ureæ*, which is probably identical with *Staphylococcus epidermidis albus*. The *B. coli* grows badly in alkaline media, and hence if present in a pure infection the urine remains acid, though stale and offensive to the smell. The *methods of invasion* of the bladder are diverse: (1) Bacteria may reach the viscus from above, either owing to a suppurative lesion of the kidney or its pelvis, or escaping into the urine from the blood. (2) They may travel up the urethra. This is a matter of no difficulty in the short and comparatively large urethra of a woman, and hence cystitis is frequently associated with vulvitis or is seen after labour. In girls a pure bacillary cystitis with acid urine is not uncommon, and is probably secondary to a vulvo-vaginitis, which arises from contamination of the vulva with the fæces where cleanliness is neglected. In the male sex, infection from the urethra is unusual unless urethritis has previously existed or some irritation, due to the passage of instruments. Even if they are carefully sterilized, mucus is liable to form and cling about the urethral wall, and along this bacteria can find their way. Naturally the introduction of an unsterilized dirty instrument may suffice to cause cystitis. (3) Bacteria can invade the bladder from surrounding organs, being transmitted by lymphatic dissemination. Thus an injury of the rectum may easily lead to cystitis.

The mere presence of bacteria in the bladder is, however, not sufficient as a rule to determine an attack of cystitis. Large quantities of pus are frequently discharged from the kidney through the bladder, and that over lengthy periods, and yet no inflammatory reaction follows. Some *local predisposing factor* must be added in order to excite their activity, and amongst the most favourable are the following: (i.) Congestion of the mucous membrane, determined by exposure to cold, this is peculiarly liable to occur in gouty individuals, and, indeed, there are people who 'take cold' in their bladders instead of developing a nasal or bronchial catarrh. (ii.) Injury, as by the presence of a foreign body, a calculus, or rough handling during an operation, may serve to render bacteria active and virulent. (iii.) One of the most important causes is retention of urine, from whatever cause it is due, *e.g.* enlarged prostate, stricture, etc. The bacteria develop and decompose the urine, rendering it offensive and ammoniacal, and the toxins and irritating bodies thereby produced affect the vesical mucosa. (iv.) The presence of irritants in the urine may determine cystitis, as

also pyelitis, *e.g.* after the absorption of cantharides. Other drugs may light up bacterial activity in some predisposed individuals, *e.g.* copaiba or cubebs. (v.) Loss of nervous control is a most important predisposing factor, and comes prominently into play in spinal injuries. The greatest difficulty is experienced in protecting such patients, and even effective purification of penis, hands, and catheter, and the application of a sterilized dressing to the organ, after a catheter has been used, may not suffice to prevent an outbreak of cystitis, which is due to infection from the kidney or rectum. In these cases the disease always runs a virulent course, and is likely to kill the patient by extension up the ureter.

Pathological Anatomy.—In acute cases the mucous membrane of the bladder becomes congested and thickened; the epithelium is shed; mucus is excreted, and is soon transformed into muco-pus, which may be extremely viscid, and develops in large quantities. Ulceration of the bladder wall may follow, or even sloughing; in the worst cases the whole of the mucous lining may necrose, and be cast off as a slough. Sometimes a membranous form of inflammation occurs, the patient frequently passing flakes of some size, which on examination are found to be chiefly composed of fibrin.

In chronic cases the mucous membrane is thickened and congested, the superficial veins dilated and even varicose, whilst ulceration is not uncommon. The continued repetition of the act of micturition leads to hypertrophy of the bladder wall, which becomes thickened and fasciculated, this effect is of course most marked when the cystitis is associated with obstruction to the outflow of urine. The mucous membrane may protrude outwards between the muscular fasciculi, giving rise to pouch-like saccules, in which phosphatic concretions are sometimes formed, and the retained urine undergoes decomposition. Perforative ulceration occasionally follows, originating a fatal peritonitis or pelvic cellulitis from extravasation of urine. The contracted state of the bladder and the overgrowth of its muscular substance lead to compression of the openings of the ureters, hydronephrosis being thus induced. A plug of viscid mucus often finds its way into the ureteral orifice, and by becoming infected with bacteria causes an extension of the infective mischief to the kidney.

The **Symptoms of Acute Cystitis** consist in pain referred to the perineum and hypogastrium, together with tenderness on pressure over the symphysis pubis. This is accompanied by extreme irritability of the bladder, frequent efforts of a painful and spasmodic nature being made to pass water (strangury); but little urine is voided at a time, for as soon as any amount has collected it is ejected forcibly. It generally contains blood and pus, and teems with bacteria. Some amount of fever is generally noted, as also vomiting, and tenesmus may be induced as a result of the proximity of the rectum to the inflamed bladder. The usual termination of the case is in resolution, but sometimes chronic irritability may persist. In rare instances the inflammation is of such a virulent nature as to cause death. The urine in these cases is often exceedingly foul, and the fatal issue is due to exhaustion, peritonitis, suppurative pyonephrosis, or even acute

toxæmia. In some patients, however, when the inflammation is concentrated at the neck of the bladder, retention, distension, and atony may ensue.

Treatment.—The patient should be kept in a warm atmosphere and preferably in bed, with fomentations applied to the lower part of the abdomen; hot hip-baths twice daily, maintained for some time, are very advantageous. The diet should be restricted to fluid, and the patient encouraged to partake freely of barley-water and other bland liquids. Alkalies and hyoscyamus may be administered, and morphia and belladonna suppositories are useful to allay the pain and irritability. As a rule, no instrument should be passed during the acute stage, unless retention is present; but if the urine becomes very foul, the bladder may be gently washed out. Urinary antiseptics, such as hexamine (5 to 10 grains three or four times a day), administered by the mouth, may do good; in the intervals between the doses acid phosphate of soda should also be given, but is usually better reserved for the subsiding stages of the attack.

Chronic Cystitis is much more common than the acute variety, and is usually associated with some irritation of the walls of the viscus, as from calculi, tumours, foreign bodies, tuberculous ulceration, or retention and decomposition of urine, especially if associated with obstruction to the outflow, as by a stricture or enlarged prostate. It may also follow acute cystitis.

The **Symptoms** are those of irritability of the bladder, the patient constantly desiring to pass water, and having to rise at night, perhaps several times, for this purpose. The urine becomes turbid, and, on standing, deposits a variable amount of mucus or muco-pus, mixed with epithelial cells, crystals of triple phosphate, and a granular sediment of phosphate of lime. It is usually alkaline (unless due to a pure infection with the *B. coli*), perhaps foul-smelling and ammoniacal, containing an abundance of micro-organisms. There is often but little pain, though when a calculus exists, or the neck of the bladder is ulcerated, this may become a prominent symptom. The patient's general health is not at first affected; but if the symptoms persist it soon becomes impaired—partly from the absorption of septic products from the bladder, and partly from the want of rest and sleep arising from nocturnal disturbance—and this may be so marked as to lead to fatal exhaustion. In other cases the inflammation may spread from the bladder along the ureters to the kidneys, and the phenomena of septic pyelonephritis manifest themselves.

The **Diagnosis** of chronic cystitis is readily made from the characteristic symptoms of irritation of the bladder and the condition of the urine; but considerable difficulty may be experienced in determining its cause In investigating a case, not only must the character of its onset be considered, but also the general history of the patient; a thorough examination of the lower urinary passages must always be instituted, and the urine examined microscopically and bacteriologically. The passage of a catheter or sound will generally detect any obstruction located in the urethra, whilst the bladder is also examined by the cystoscope and other methods described at p. 1468.

The **Treatment** of chronic cystitis is naturally directed towards its cause, if this can be discovered; thus, calculi or foreign bodies should be removed, and a stricture dilated. In most cases, even where the cause is not apparent, great benefit will be derived from washing out the bladder.

The bladder is irrigated by mild antiseptic lotions. Various solutions are employed for this purpose, but perhaps the most useful are weak Condy's fluid, sanitas (1 in 10), boric acid (20 grains to 1 ounce), or nitrate of silver ($\frac{1}{4}$ grain to 1 ounce), and they may be used alternately with advantage. Acetic acid $\frac{1}{2}$ per cent. is valuable in cases of foul alkaline cystitis, such as is associated with vesical diverticulum. The frequency with which the injections are made must vary with the severity of the symptoms; it is not often necessary to perform the operation more than once or twice a day. Of course, the most stringent precautions must be taken as to sterilization of the patient's penis, of the surgeon's hand, and of the instruments employed.

At the same time that this local treatment is being adopted, the patient's general habits of life must be regulated. The diet should be bland and unstimulating; alcohol is better avoided, but if essential for other reasons, well-diluted gin or whisky may be given. Tea and coffee should be prohibited, and milk should be given freely, together with barley-water and some mild alkaline water—such as that derived from Contrexéville. Hexamine, 10 grains three times a day, is the most useful urinary antiseptic, and to be effective the urine should be acidified by adequate doses of acid sodium phosphate; a more powerful acidifier of the urine is ammonium chloride, gr. xx. t.d.s. This should alternate with an alkaline mixture containing tincture of hyoscyamus and infusion of buchu.

Vaccine treatment should be employed if the *B. coli* is the active organism, and is of some help. The patient may remain apparently well, and yet the urine teems with bacteria, and occasional bouts of cystitis occur, which must be treated by alkaline drugs and by washing out the bladder either with Condy's fluid or with a very dilute solution of nitrate of silver.

In cases which do not improve and when the patient is becoming exhausted by toxic absorption, want of sleep, etc., it is essential to put the parts at rest and to secure rest for the patient by draining the bladder.

Suprapubic Cystotomy is a simple operation with no special risks and gives good results. The procedure adopted is as for suprapubic lithotomy. A rubber tube with two or three openings at the distal end is placed in the cavity, and the bladder wall stitched closely around; possibly one fine catgut stitch may secure it in position to the bladder wall so as to keep it from slipping out. The wound in the abdominal parietes, purified by alcohol, is closed around the tube (not too tight) by through-and-through silkworm-gut stitches, and a dressing is applied. A rubber tube sufficiently long to pass into a vessel containing water placed on a level lower than that of the bladder is united to the drainage-tube by a glass connection. As the urine is

secreted, it passes up the tube and soon overflows, establishing a syphon connection as soon as the air is expelled. Possibly a more satisfactory method is to employ suction drainage as suggested by Cathcart; the bladder drainage-tube is connected by a T-glass connection with a tube along which is kept running a stream of water; this by its negative pressure sucks out the urine from the bladder, which is thereby kept empty and at rest.

Diverticula of the bladder may be of congenital origin, and are usually observed either at the apex, and then probably due to imperfect closure of the allantoic sac, or at the base just above the trigone, and possibly in close relation to one of the ureteral orifices. This latter may be due to some abnormality in the division of the primitive cloaca into bladder and bowel. These conditions are usually observed in young males, and arise apart from any urinary obstruction. They are associated with irregularities in the action of micturition, and are likely to be recognized on cystoscopic examinations for the same The exact relation to ureters, etc., can be determined by radiography after an injection of sodium iodide, and possibly by the passage subsequently of a ureteral catheter. If the proceeding appears to be at all feasible, excision of the cyst can be undertaken, and is usually successful.

Quite distinct from these congenital diverticula are the acquired **Sacculi,** which develop in consequence of hypertrophy of the muscular fasciculi of the bladder wall in cases where there is some obstruction to the urinary overflow. In diverticula the whole bladder wall is represented in the earlier stages, mucous membrane and muscular fibres being found; in sacculi only the mucous membrane is protruded as a hernial pouch between the muscular bundles. These gradually increase in size, and are to be found most commonly on the upper part of the bladder. Urine stagnates in them and undergoes decomposition; the walls may become inflamed and even ulcerate or perforate, a calculus may lodge therein, and increasing by fresh deposits of the constituent salts, may finally project into the bladder cavity, being held in position by a narrow neck. Occasionally they become so large that they are drawn down into the sac of a hernia. Exact diagnosis is made by cystoscopy and radiography after an injection of sodium iodide, and removal is the ideal treatment; where this is not possible, enlargement of the opening into the bladder to allow adequate drainage may be tried, or invagination of the diverticulum.

Tuberculous Disease of the Bladder is almost invariably secondary, extending from the kidney, prostate, or testicle. It is much more common in men than in women, and is most frequently seen in young adults. It commences in the submucous tissue as a deposit of miliary tubercle (Plate XXX., Fig. 3), which caseates and suppurates, breaking down, and giving rise to ulcers with undermined edges; these are rarely of large size at first, are usually multiple, and situated in or near the trigone. The **Symptoms** are those of chronic cystitis and hæmaturia, the irritability of the viscus being very marked. The diagnosis is made by demonstrating the bacillus of tubercle in the urine, and by the

secreted, it passes up the tube and soon overflows, establishing a syphon connection as soon as the air is expelled. Possibly a more satisfactory method is to employ suction drainage as suggested by Cathcart; the bladder drainage-tube is connected by a T-glass connection with a tube along which is kept running a stream of water; this by its negative pressure sucks out the urine from the bladder, which is thereby kept empty and at rest.

Diverticula of the bladder may be of congenital origin, and are usually observed either at the apex, and then probably due to imperfect closure of the allantoic sac, or at the base just above the trigone, and possibly in close relation to one of the ureteral orifices. This latter may be due to some abnormality in the division of the primitive cloaca into bladder and bowel. These conditions are usually observed in young males, and arise apart from any urinary obstruction. They are associated with irregularities in the action of micturition, and are likely to be recognized on cystoscopic examinations for the same. The exact relation to ureters, etc., can be determined by radiography after an injection of sodium iodide, and possibly by the passage subsequently of a ureteral catheter. If the proceeding appears to be at all feasible, excision of the cyst can be undertaken, and is usually successful.

Quite distinct from these congenital diverticula are the acquired **Sacculi,** which develop in consequence of hypertrophy of the muscular fasciculi of the bladder wall in cases where there is some obstruction to the urinary overflow. In diverticula the whole bladder wall is represented in the earlier stages, mucous membrane and muscular fibres being found; in sacculi only the mucous membrane is protruded as a hernial pouch between the muscular bundles. These gradually increase in size, and are to be found most commonly on the upper part of the bladder. Urine stagnates in them and undergoes decomposition; the walls may become inflamed and even ulcerate or perforate; a calculus may lodge therein, and increasing by fresh deposits of the constituent salts, may finally project into the bladder cavity, being held in position by a narrow neck. Occasionally they become so large that they are drawn down into the sac of a hernia. Exact diagnosis is made by cystoscopy and radiography after an injection of sodium iodide, and removal is the ideal treatment; where this is not possible, enlargement of the opening into the bladder to allow adequate drainage may be tried, or invagination of the diverticulum.

Tuberculous Disease of the Bladder is almost invariably secondary, extending from the kidney, prostate, or testicle. It is much more common in men than in women, and is most frequently seen in young adults. It commences in the submucous tissue as a deposit of miliary tubercle (Plate XXX., Fig. 3), which caseates and suppurates, breaking down, and giving rise to ulcers with undermined edges; these are rarely of large size at first, are usually multiple, and situated in or near the trigone. The **Symptoms** are those of chronic cystitis and hæmaturia, the irritability of the viscus being very marked. The diagnosis is made by demonstrating the bacillus of tubercle in the urine, and by the

PLATE XXX

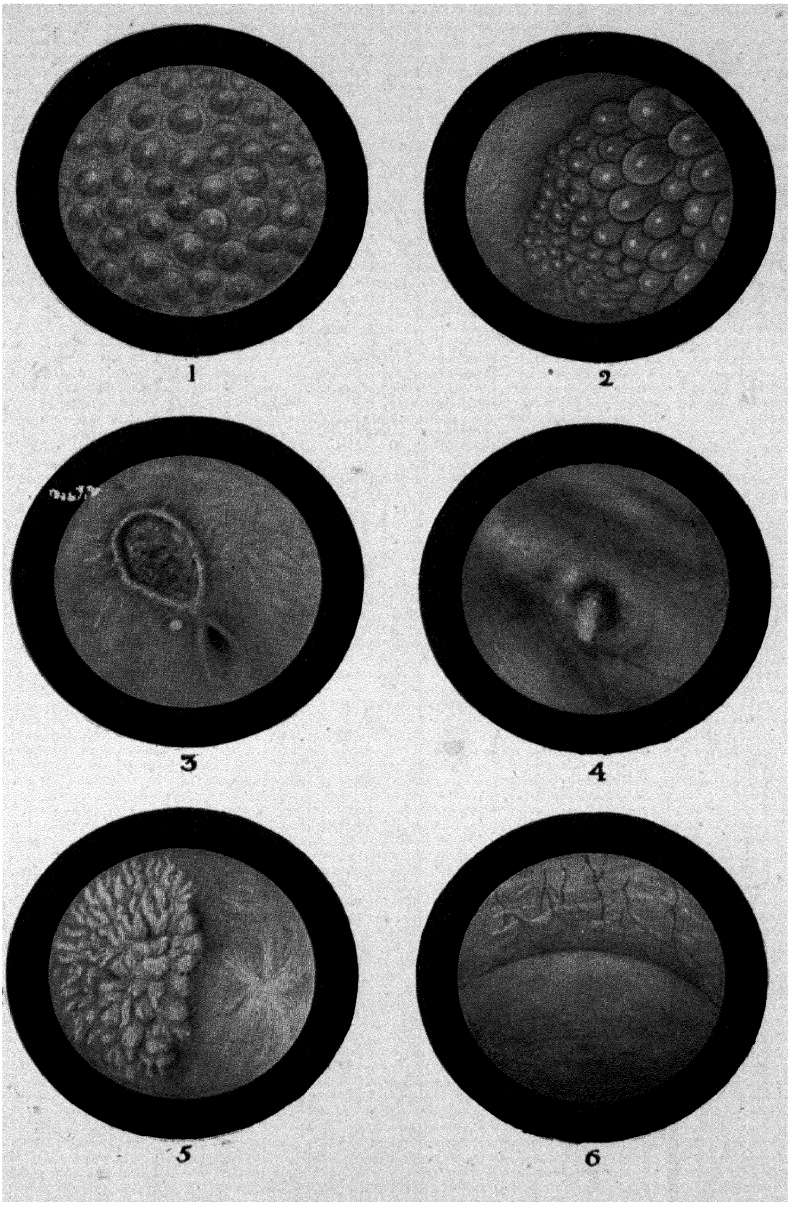

Cystoscopic Appearances of Pathological Conditions of the Bladder

cystoscope. The course of the case is unfavourable, the ulcers increasing in size, and death resulting from exhaustion, general infection, phthisis, or renal complication.

Treatment.—The case is usually treated for some time as one of chronic cystitis before its nature as a tuberculous affection is ascertained. In the milder cases it will suffice to attend to the general health and hygiene of the individual, and to wash out the bladder with some antiseptic two or three times a week, leaving a drachm or two of a 5 per cent. solution of iodoform in liquid paraffin within the viscus. Injections of tuberculin have been found decidedly valuable in this condition, and should be continued for over a year. In more advanced cases, where the patient's life is a misery owing to continual pain, the ureters may be transplanted from the bladder to the skin on the anterior abdominal wall, or more recently relief of pain and frequency has been obtained by division of the presacral nerve.

Very similar symptoms may be induced by the presence of a **Simple Ulcer of the Bladder,** which, according to Fenwick, occurs not unfrequently. It is usually single, and situated near the neck or trigone, giving rise to great irritability of the viscus and hæmaturia, although the urine remains clear. The diagnosis is best made by the cystoscope. Phosphatic deposits sometimes form over the ulcerated surface, and may suggest the existence of a stone. Treatment consists in washing out the bladder with lactic acid (½ to 3 per cent.), or in cauterizing the base of the sore through an operating cystoscope.

Tumours of the Bladder.—New growths from the vesical wall are not very uncommon; they may be simple or malignant.

Simple Tumours occur in the form of fibroma, myoma, and myxoma; but that most often seen is the **Papillomatous** or **Villous Tumour,** which appears as a soft flocculent mass, usually situated near the trigone, and close to the opening of one of the ureters (Fig. 957). The floating tufts or villous processes consist of an extremely delicate connective tissue, covered with a layer or two of epithelium similar to that lining the bladder and traversed by bloodvessels. Occasionally the growths have a narrow base and are pedunculated, but more frequently are sessile, and then the base is liable to be infiltrated, and a cancerous element is by no means uncommon. They may be single or may multiply rapidly, and spread all over the bladder by infection from the primary growth (Plate XXX., Fig. 5).

The **Symptoms** are those of recurrent hæmorrhage, the blood being of a bright red colour, followed later on by irritability of the bladder. At first the hæmorrhage is intermittent, considerable intervals occurring between the attacks; but subsequently it becomes more continuous. The irritability of the bladder is generally induced by chronic cystitis, and when the urine has undergone alkaline changes there is a copious exudation of ropy mucus, which, mixing with the urine, causes considerable difficulty in micturition, leading in some cases to strangury. The urine may also contain portions of the tumour which have been set free, and occasionally, if situated near the neck of the bladder, some of the fimbriated ends may be swept into the urethral orifice, and interfere with micturition. In the same way the opening of one or both

ureters may be encroached upon, leading to hydronephrosis. On examination of the bladder with a sound, nothing definite can be detected, unless the surface of the growth becomes encrusted with phosphates, and no abnormality is noticed on rectal examination. Occasionally a small portion of the growth may be caught in the eye of a catheter.

Prognosis.—A considerable element of uncertainty generally exists about these cases, since, although single growths with a well-defined pedicle are usually free from recurrence after removal, there is always a possibility of the implantation of living cells in the mucous membrane, giving rise to multiple growths, the removal of which may be impossible,

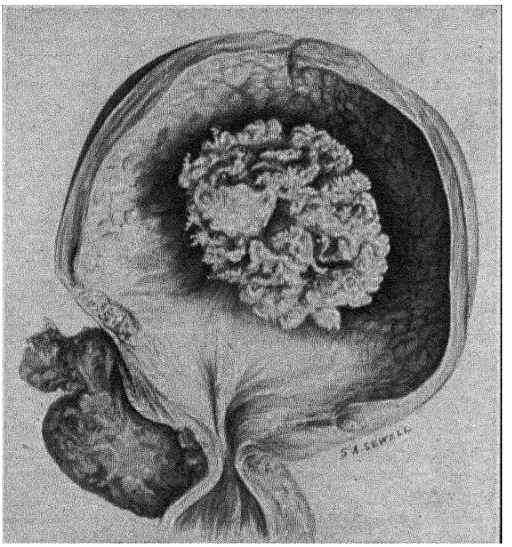

FIG. 957.—VILLOUS TUMOUR OF THE BLADDER. (FROM KING'S COLLEGE HOSPITAL MUSEUM)

and causing death from hæmorrhage or back pressure. Moreover, it is often impossible to be certain that the base of the tumour is free from malignancy.

Sarcoma of the bladder is an uncommon disease, more often seen in children than in adults. In the former it gives rise to multiple polypoid growths; in the latter it is often single and sessile. The tumour grows rapidly, and may attain considerable dimensions, spreading outside the bladder, and even invading the pelvic bones. Lymphatic glands may be implicated at an early date.

Cancer of the bladder is more common in men than in women, and may originate in the viscus, or may spread to it from the rectum or

neighbouring organs. In the former case, the growth is generally a squamous epithelioma, in the latter, its nature is, of course, similar to that of the primary disease, thus, when secondary to rectal cancer, the tumour is of a columnar type. Most frequently the affection commences in the posterior wall above the trigone extending forwards to the neck of the bladder. The growth is sometimes superficial, projecting into the vesical cavity as a soft spongy mass, which does not ulcerate early, or invade the muscular walls till late, but more frequently the neoplasm extends into and infiltrates the walls, whilst marked ulceration is also present (fig. 958), the raw surface often becoming coated in places with a phosphatic deposit. A cancerous

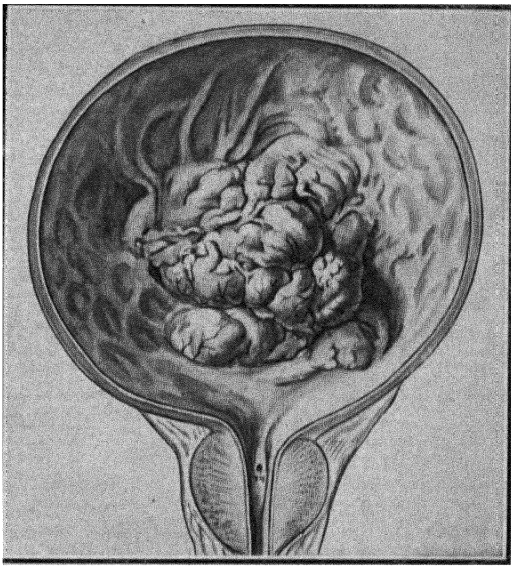

FIG 958.—CANCER OF THE BLADDER (FROM ROYAL COLLEGE OF SURGEONS MUSEUM.)

growth in the bladder is always more or less likely to become papillated, and, indeed, every type of transformation from the simple villous growth to the malignant form can be demonstrated.

The **Symptoms** vary somewhat in these two forms, although the conspicuous features of each are hæmaturia and irritability of the bladder. In the slowly growing superficial variety, the tumour often attains a considerable size before causing any trouble, beyond possibly some slight irritability of the bladder. A severe attack of hæmaturia, unaccompanied by pain, is usually the first symptom of importance, and may be induced by some injury which tears off a piece or fissures the growth. This painless hæmaturia closely simulates the early symptoms

of a simple villous tumour, but is more persistent, and yields less readily to treatment. After one or more of such prolonged attacks cystitis follows, and the subsequent history resembles that of the harder and more rapidly growing infiltrating tumours. In these latter, the symptoms of vesical irritability precede those of hæmaturia. Dysuria and severe pain referred to the bladder and perineum are complained of, and the urine early becomes alkaline and putrescent; shreds of the growth may also be found in the urine on microscopic examination. If the tumour involves the internal meatus, micturition may be considerably impaired; if the orifices of the ureters are obstructed, hydronephrosis results. On passing a sound, the tumour can be detected as an irregular mass projecting into the bladder, whilst the posterior vesical wall may be felt *per rectum* to be hard and resistant; its ulcerated surface may also be seen with the cystoscope.

The course of the case is similar to that of a somewhat rapidly growing carcinoma, leading to early and marked cachexia, increased by the sleeplessness resulting from the vesical irritation; secondary deposits are found in the viscera and lumbar glands, whilst perforation of the wall may occasionally follow, causing urinary extravasation, septic cellulitis, and death. Another most distressing complication is the establishment of a recto-vesical fistula, through which the urine makes its way into the rectum, thus intensifying the sufferings of the patient.

The **Diagnosis** of a vesical tumour can only be made with certainty by the cystoscope, and by discovering fragments of its substance in the urine. Whenever hæmorrhage is associated with marked vesical irritability, and cannot otherwise be explained, a tumour of the bladder may be suspected, and cystoscopy must be undertaken. In this viscus, as in others, the only hope of curing malignant disease lies in early operation, and if the practitioner waits until the diagnosis is assured by the symptoms, the patient's case is probably hopeless. Early cystoscopy is all-important.

In simple papilloma and the superficial type of epithelioma, hæmorrhage precedes the irritability; but whilst it is usually impossible to detect the villous growth either by examination with the sound or from the rectum, a fungating malignant growth may sometimes be recognized by the sound. In the infiltrating type of malignant disease, on the other hand, pain and dysuria always precede the bleeding for a considerable interval, whilst definite evidence of the existence of the growth can usually be made out, both by the sound and on rectal examination. A worn and exhausted appearance must not be looked on as necessarily the outcome of advanced cancerous cachexia, since the loss of rest and sleep due to chronic vesical irritability can of itself lead to a somewhat similar condition.

Treatment of Villous Tumours of the Bladder.—In the early stages, when the diagnosis of a tumour has not been confirmed, the hæmaturia may be treated with ordinary hæmostatic remedies, such as a mixture containing dilute sulphuric acid and ergot, or turpentine administered in capsules (10 minims three times a day).

When once a diagnosis has been established, active operative treat-

ment is essential. Two plans are available: (1) Destruction by **Diathermy.** In this plan special apparatus is required. A cystoscope for catheterizing the ureters is employed, but instead of the catheter, a flexible sound with a fine rounded metallic end which serves as an electrode is passed, the remainder being carefully insulated. The other terminal of the current is attached to a pad wetted with salt solution placed under the patient's back. The current employed is of high potential, gradually increased. The metallic terminal under the control of the eye is approached to one portion of the growth after another, and as it touches and makes contact with it, the growth turns white and shrivels up. This method of treatment is troublesome, but excellent, when available. (2) When diathermy is not available nor desirable, villous growth must be treated by *excision* through a suprapubic cystotomy. The sessile type is less effectively treated than the pedunculated, and, indeed, it is a question whether it is not always wiser to deal with such cases from the first by excision. Of course, the difficulty lies in recognizing the absence of a pedicle. After opening and exploring the bladder, a self-retaining retractor is introduced, and the interior illuminated by a forehead electric lamp, or by bulbs actually incorporated in the retractor. If more room is required, one of the rectus muscles may be cut across about 1½ inches above its insertion, and the viscus can thus be freely opened. The larger growths are removed by dividing the mucous membrane around them and cutting them away after ligaturing or cauterizing the base; the incision in the mucous membrane should be closed by fine catgut, if possible. Smaller growths may be destroyed by the galvano-cautery. The finger of an assistant in the rectum can press forward the posterior wall and give effective help. Where the growths are very extensive and complete removal almost impracticable, radium may be of considerable value, a suitable quantity in a metal filter can be placed in the terminal portion of a rubber catheter, and left in position for twelve or twenty-four hours, as may be thought desirable.

For **malignant disease** of the bladder, partial or complete cystectomy may be possible. **Partial Cystectomy** consists in removal of the whole thickness of the vesical wall involved by the growth, and according to its location this may involve opening the peritoneal cavity or not. The bladder is exposed as described above, and the peritoneum is detached up to and beyond the growth, which is cut away, the solution of continuity in the wall being made good by careful suturing with catgut. If the ureter is involved in this resection, it should be divided through a healthy spot and reimplanted in the bladder. **Complete Cystectomy** has been undertaken for extensive malignant disease, but it is more than doubtful whether it is ever justifiable, for the disease almost certainly involves both ureters, and this is practically always associated with changes in both kidneys, which render operative treatment most dangerous. The actual results of operations for cancer of the bladder are extremely disappointing.

When removal is impracticable, the growth may be treated with *radium*, either by the introduction of radon seeds through an operating cystoscope, or by the open cystostomy method. The latter is the

method of choice. The bladder is opened suprapubically and radium needles are introduced into and around the growth (Fig. 959). Small radium needles containing 0·6 mg. of radium, with threads attached, are passed through a small rubber tube into the bladder. A self-retaining catheter is also placed in the bladder and the suprapubic wound closed. The radium needles, together with the tube, are removed after a week. It must be remembered that radium treatment is contra-indicated whenever there is bilateral kidney infection.

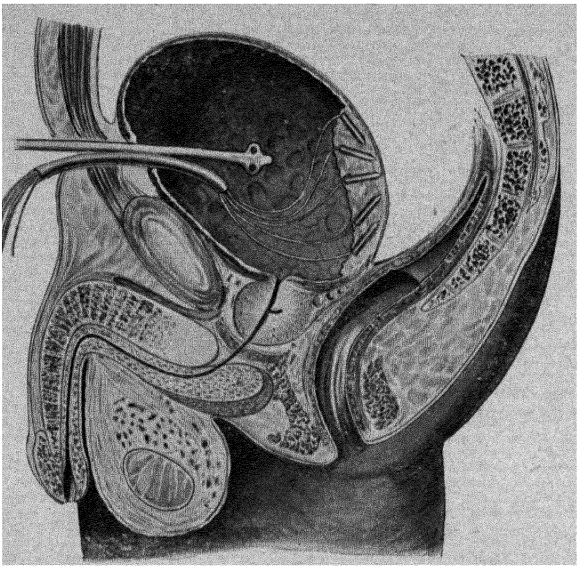

FIG. 959.—SUPRAPUBIC METHOD OF IRRADIATION FOR CARCINOMA OF THE BLADDER.

Stone in the Bladder.

Varieties.—A vesical calculus may be formed of almost any of the urinary deposits commonly met with, and each has its own special characteristics.

(*a*) The *uric acid* calculus is usually an oval, flattened body of considerable density, with a smooth or slightly nodular surface, and of a nut-brown colour. On section it is distinctly laminated, and it may be surrounded by a crust of phosphatic material.

(*b*) The *urate of ammonium* calculus is of very similar structure, but of a lighter colour, and the lamination is less distinct.

(*c*) The *oxalate of lime* or mulberry calculus is a rough, irregular body, sometimes evenly nodular, but not infrequently tuberculated, or even spiculated. It is extremely hard and dense, laminated, and of a dark red-brown colour, or sometimes black, owing to admixture with blood.

It is rarely of great size, on account of the irritation caused by its presence and its slowness of growth.

(*d*) A pure *phosphatic* calculus is very uncommon, but any stone or foreign body is certain to become coated with a phosphatic deposit when chronic cystitis has resulted in alkaline decomposition of the urine. Occasionally concretions of a similar nature form spontaneously in saccules of the bladder; these are white and chalky in appearance, friable in consistency, with no evidence, or but little, of lamination, and on removal are exceedingly offensive; they consist of a mixture of the triple ammonio-magnesic phosphate and phosphate of lime. Less commonly an excess of the triple phosphate is present; if in the proportion of two parts of the latter to one of phosphate of lime, a laminated and somewhat denser calculus is produced, which is sometimes termed a *fusible calculus*, owing to the fact that it fuses to a bead under the blowpipe flame. Occasionally a phosphate of lime calculus occurs in the upper urinary passages, *e.g.* the pelvis of the kidney, and has a crystalline appearance on drying.

(*e*) *Cystine* forms the base of a rare calculus which is of a yellowish-green colour and waxy appearance.

(*f*) *Xanthine*, or xanthic oxide, occurs very exceptionally as a calculus of a reddish colour.

An **encysted** calculus is one which develops in a saccule of the bladder. It may consist of any of the above substances, and is due to a small stone finding its way into a saccule and being arrested there. It grows by gradual accretion of new calculous material, and after a time projects into the vesical cavity. In such a calculus the large intravesical portion is separated from the encysted part by a narrow neck. Ulceration of the sac wall is not unlikely to follow, and extravasation of urine.

Structure of a Calculus.—A calculus usually consists of the following parts: (1) The *nucleus*, which may be formed by a portion of blood-clot, inspissated mucus, a renal calculus, or some foreign substance introduced from without. (2) The *body*, which consists of superposed layers of uric acid or oxalate of lime, or of whatever substance the stone is composed; not infrequently the composition of adjacent laminæ differs, leading to what is known as an *alternating calculus*. Each lamina consists of myriads of minute crystals held together by vesical mucus, with which a certain amount of phosphatic material is often mixed, whilst layers of pure phosphatic deposit may be interposed. (3) The *crust* consists of a variable amount of soft, friable phosphatic material, the quantity of which is the measure of the degree of chronic cystitis originated by the calculus; in some cases it is entirely absent.

The **Number** of calculi present in a bladder varies greatly. Sometimes there is only one; occasionally a considerable number, counted perhaps by hundreds, may exist; in such circumstances they are never of great size. Multiple calculi are not infrequently faceted as a result of mutual friction.

The **Causes** of vesical calculus must be looked for in some of those constitutional conditions already described as predisposing to lithiasis

or oxaluria. They are not uncommon in children during the first decade of life, especially amongst the lower classes. It diminishes in frequency from childhood to the age of twenty-five, and then gradually increases until it is relatively common in elderly men. The condition is comparatively rare in women, owing to the fact that the shortness and large size of the urethra allow small calculi to be much more readily passed. Possibly the character of the drinking-water, or the amount imbibed, is a matter of importance, as indicated by the fact that the occurrence of calculus is very unequally distributed in different parts of the same country; thus, in England it is most frequently met with in the Eastern Counties. It is also very common in India and Arabia, a fact which may possibly be explained by the large amount of fluid withdrawn from the body by perspiration, and by vitamin deficiency due to the highly starchy nature of the diet.

Symptoms.—The effects produced by vesical calculi vary in different individuals, according to the shape of the stone and the tolerance of the mucous membrane. In children and young adults, where the parts are very sensitive, even a smooth calculus gives rise to severe symptoms, but old men often tolerate a large stone without much inconvenience; *cæteris paribus*, an oxalate of lime calculus is always more irritating than one composed of uric acid. The classical symptoms of a vesical calculus may be preceded by a history of the patient having passed 'gravel' for a long time, or by an attack of renal colic, on the cessation of which the calculous symptoms commenced. Sometimes the vesical symptoms do not appear for some time after the passage of a stone into the bladder, presumably in consequence of its small size. They consist of pain in the perineum and neck of the bladder, which radiates to the back and down the thighs, but is especially noticed at the end of the penis immediately after micturition. The stone is then pressed down against the sensitive neck of the bladder by the contraction of its muscular walls. Increased frequency of micturition is also present, and perhaps hæmaturia of a vesical type, though this is not a prominent feature. All these phenomena are increased in severity by jolting, jumping, or any form of exercise, and hence are more marked during the day than at night. Occasionally the patient complains that the flow of urine suddenly ceases before the bladder has been completely emptied, and that some change in the position of the body is needed in order to allow him to complete the act. In addition to these characteristic symptoms, he may suffer from various phenomena secondary to the irritability of the bladder, and dependent on the straining induced by the calculus. Thus, tenesmus may be produced by sympathetic irritability of the rectum, especially in children, and a hernia be thereby caused, priapism, too, is not uncommon.

The symptoms are somewhat modified in *children*, leading to irritability of the bladder, as evidenced by wetting of their clothes and of their beds at night, and pulling at the prepuce and penis. These manifestations are very similar to those caused by a tight foreskin, with which condition, indeed, a stone is often associated.

The actual **Diagnosis** of vesical calculus can be made by sounding,

radiography, or cystoscopy. (1) In order to examine a patient by *sounding*, he is laid on a couch with the head low, and the buttocks raised on a pillow placed beneath them. The bladder should always contain a few ounces of fluid, so as to obliterate any folds produced by laxity of the mucous membrane, as well as to facilitate the introduction of the instrument. A sterilized sound of suitable size, warmed and lubricated by some antiseptic preparation, is then gently passed along the urethra, and the handle depressed between the separated legs so as to enable the point to enter the bladder. The handle, which should be cylindrical in shape and fluted, with the maker's name or some mark to indicate the direction of the beak, is then lightly grasped between the index-finger and thumb, and rotated from side to side, whilst at the same time the whole instrument is drawn forwards or backwards in the urethra. Each side of the bladder is thus carefully investigated, and, finally, if no stone is detected, the beak is turned directly downwards, so as to examine the pouch which often forms behind a slightly-enlarged prostate. The presence of a stone is recognized by a metallic click, which can be felt and even heard when the end of the instrument taps it. The character of the click is some guide to the size and density of the stone. The presence of two or more calculi is indicated by the surgeon being able to touch them on rotating the instrument alternately to each side of the middle line, or by seizing one stone with a lithotrite, and using it as a sound for the other. In doubtful cases, a still more delicate test than the sound is obtained by passing a medium-sized tube of a Bigelow's evacuator, and washing out the bladder. The calculi may by this means be sucked out even from sacculi, and be felt to rattle against the end of the instrument, when the pressure upon the indiarubber bulb is relaxed. When the calculi are multiple and of small size, they may be actually removed in this way by an examination which was only intended to be diagnostic in character. The surgeon must not forget that a hypertrophied bladder with projecting fasciculi may somewhat resemble a calculus, especially when coated with phosphatic material. In some rare instances a calculus may be so completely hidden in one of the saccules as to render its detection impossible by these means. An encysted calculus which projects into the bladder is recognized by being always found at the same place. (2) *X-ray* examination is conducted in the usual fashion, care being taken to see that the rectum is empty. The tube is placed over the patient's abdomen with the rays directed downwards and backwards, and the plate is behind. The calculus usually appears as a shadow immediately above the pubic rami (Fig. 960). (3) *Cystoscopy* is now used so constantly that it is needless to lay stress on its value. Indications as to the character and size of the stone can be thereby obtained, and saccules or other changes in the bladder wall observed.

Course of the Case.—A patient suffering from vesical calculus is certain, sooner or later, to develop symptoms of chronic cystitis, and septic changes in the urine are equally sure to follow. The bladder is hypertrophied, and if the stone is not removed the mucous membrane becomes ulcerated and the inflammation extends to the kidneys;

the patient's life is thus destroyed, partly by exhaustion, and partly by septic or uræmic poisoning.

Treatment.—At the present day only three plans are employed, *viz.* lithotrity, suprapubic cystotomy, and very uncommonly perineal cystotomy.

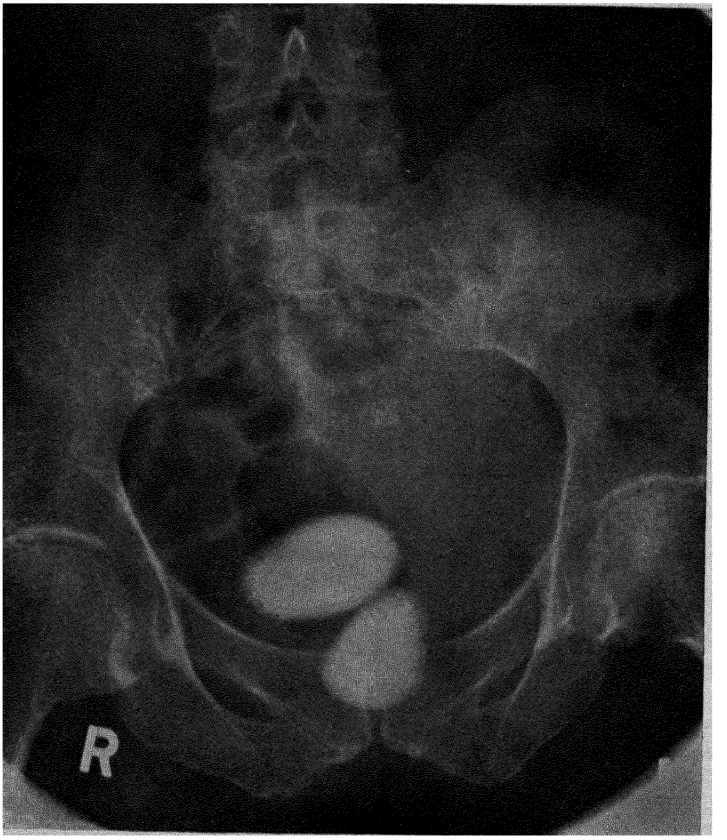

FIG. 960.—SKIAGRAM OF CALCULI IN URINARY BLADDER.

Lithotrity was formerly conducted in several stages, the stone being crushed, and the patient allowed to pass the débris subsequently; this process was repeated at intervals of a few days until the bladder was clear. Such a proceeding took a considerable time, and was exceedingly painful, irksome, and dangerous to the patient. The introduction of Bigelow's evacuator completely revolutionized this

operation, and enabled it to be completed at one sitting, constituting the proceeding sometimes termed *Lutholapaxy*.

Operation.—After anæsthesia has been induced the head is kept low, and a pillow placed beneath the buttocks, so as slightly to raise the pelvis. The bladder is carefully washed out with some bland antiseptic, such as a solution of boric acid, and about 6 ounces of lotion are left within it, in order not only to obliterate all folds of mucous membrane, but also to facilitate the seizure of the stone, and to prevent injury of the walls during the operation.

The lithotrite (Fig. 961) is then introduced. The male blade slides easily up and down in a groove in the stem of the female blade, and after the stone has been seized it is brought to the centre of the bladder, and the blades are forcibly pressed together by a screw action, brought into play by the mechanism in the handle, which can be put in and out of gear at will. It is absolutely essential that the instrument should be made of well-tempered steel, so as to prevent any risk of breaking during the operation. To introduce it some skill is needed, since the curved end is short, and consequently the handle must be well depressed between the legs, in order that the beak may pass under the pubic arch. The position of the stone is ascertained by rotating the instrument, and using it as a sound. To catch the stone, the lithotrite must be held vertically and pressed well back against the posterior wall of the bladder; on separating the blades, the stone by its weight falls between them. If fairly grasped, the blades when screwed up crush it into several fragments, each of which is subsequently dealt with in a similar fashion. If only the margin of the stone is gripped, the application of screw pressure may cause it to slip away, and the manœuvre must then be carefully repeated. When the surgeon is satisfied that the fragments are sufficiently small, the largest evacuator-tube that can be safely introduced is passed into the bladder. To effect this, it is sometimes necessary to incise the urethral orifice with a bistoury in a downward direction. The evacuator is attached to the tube, and the bladder thoroughly washed out by alternate pressure upon, and relaxation of, the rubber bottle (Fig. 962). By this means the fragments of the stone are collected in the glass receptacle which forms part of the apparatus. The washing is continued until no more fragments are heard or felt to rattle against the end of the tube. It may be necessary to reintroduce the lithotrite in order to crush some larger portions of the calculus still remaining; the old practice of withdrawing small fragments within the grasp of a lithotrite is to be condemned. It is scarcely necessary to resound the bladder after the efficient use of the evacuator. A certain amount of bleeding is indispensable from these manipulations, but it is not excessive in careful hands. Should, however, considerable

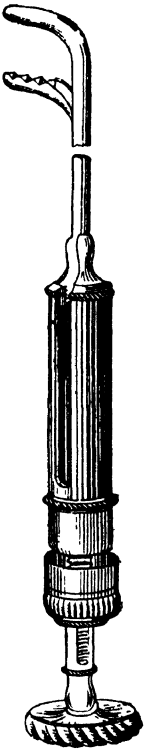

FIG 961.—LITHOTRITE.

bleeding follow, the bladder is likely to become subsequently distended with clots, necessitating the use of a large-eyed catheter for their removal.

After-Treatment.—The patient is placed in bed as soon as the operation is completed, and kept warm and quiet, and suitable measures must be taken to combat shock. The diet is restricted to fluids for a few days, and pain, if complained of, may be relieved by a little morphia. If all goes well, he may be allowed to get up at the end of a week.

Various **Sequelæ** may follow this operation. *Cystitis* results partly from mechanical causes, but more frequently from the previous septic state of the mucous membrane. The symptoms are usually subacute in character, and may pass away after a few days, but if of a serious type, considerable constitutional disturbance arises, and a large amount of viscid muco-pus is excreted, the urine becoming alkaline and

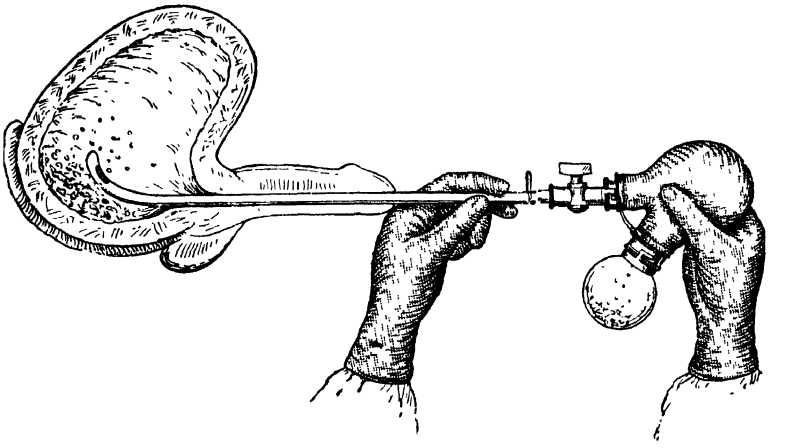

FIG 962.—EVACUATOR IN POSITION IN THE BLADDER.

ammoniacal. In such a case it is absolutely essential to wash out the bladder once or twice a day, as if left to itself the condition is very liable to spread up to the ureters, and may destroy the patient's life by suppurative pyelonephritis. *Atony of the bladder* is occasionally induced, either by the operation or by a consequent cystitis, and is especially common in elderly individuals. It must be treated by regular and aseptic catheterism. When the patient's kidneys are already affected prior to the operation, an acute ascending pyelonephritis (p. 1450) may be originated by it, perhaps leading to suppression of urine and death from uræmia.

Suprapubic Lithotomy, formerly looked on as a serious procedure with a high mortality, is now a very successful operation. The bladder is washed out, and 8 or 10 ounces of lotion are left within it; the patient is then placed in the Trendelenburg position, with the pelvis raised, the intestines being thus allowed to gravitate to the postero-superior

part of the abdomen. A median incision is made from the top of the symphysis upwards for 2 or 3 inches; the linea alba is divided, and the retropubic cellular tissue opened up. Air finds its way into the connective tissue behind the symphysis (cavum Retzii), and the peritoneum is thus pressed back.

The tense rounded outline of the bladder is readily detected with the finger, and picked up and steadied on either side by a pair of tissue forceps. An opening is then made into it in the middle line from below upwards, through which the index-finger is passed and the stone examined. Suitably curved lithotomy forceps are introduced, and the stone grasped and withdrawn. A careful examination is made to ascertain whether any more calculi are present, as also to investigate the size of the prostate, which if enlarged may sometimes be advisably removed at the same time. The after-treatment of the wound differs with the condition of the bladder; if it is infected, a drainage-tube is introduced, and the urine syphoned off, healing occurring by granulation in three to six weeks (see After-treatment of Prostatectomy, p. 1503). If the bladder is healthy and free from infection, it may be closed by catgut sutures, which only pass through the muscular and submucous coats. The external wound may be left open or closed, except at the spot where a drainage wick is passed down to the vesical wound, so as to allow exit to any urine which may accidentally leak into the wound. Often the patient can pass his water afterwards without difficulty, but if need be a catheter is passed at regular intervals, or is tied in.

Choice of Operation for Vesical Calculus.—At the present day lithotrity has been brought to such a standard of excellence that there is no doubt as to the general rule which should be followed, *viz.* that *unless some contra-indication is present, all cases of vesical calculus should be treated by lithotrity.*

The **Contra-indications to Lithotrity** are as follows: (1) *Conditions of the Stone.* If the calculus exceeds 1½ inches in diameter, it is not advisable to attempt lithotrity, on account of the damage which may be inflicted on the vesical wall. Moreover, some stones, especially those consisting of oxalate of lime, are so hard that no lithotrite can crush them. Phosphatic concretions, on the other hand, are so soft that a lithotrite becomes clogged, and crushing is impracticable. An encysted stone will also preclude lithotrity on account of its fixed position. There is no objection to dealing with multiple calculi by this means; if of small size, they may be removed by simply using the evacuator. (2) *Conditions of the Urethra.* The existence of an organic stricture, or an enlarged prostate, may render lithotrity impracticable from the impossibility of passing large enough instruments, whilst false passages may make it exceedingly difficult. Excessive irritability of the urethra, as evidenced by the occurrence of severe rigors after instrumentation, may also render the operation unadvisable. (3) *Conditions of the Bladder.* The existence of severe cystitis or the presence of sacculi, as indicated by the cystoscope, will usually suggest the performance of lithotomy; a contracted bladder, which will only hold a few ounces, materially increases the dangers and difficulties of lithotrity.

Suprapubic Lithotomy should be undertaken under the following conditions: (1) Where the stone is too large to be dealt with by crushing; (2) where the stone is encysted; (3) where a stricture or enlarged prostate is present, and it may then be feasible to remove the prostate at the same time.

Calculus in Boys is a common occurrence. It must be remembered that the bladder is rather an abdominal than a pelvic organ in children, and hence suprapubic lithotomy is particularly indicated, except in the hands of skilled lithotritists. It has been shown, however, that lithotrity can be safely practised, and many surgeons in the East, where stone is common, employ it as a routine procedure, granting that a No. 6 catheter can be passed, and that the stone is not too large to be grasped by a lithotrite. Specially constructed instruments are required for the purpose.

Calculus in the Female.—As already mentioned, vesical calculus is very rare amongst women, owing to the shortness and greater size of the urethra, so that small stones passing downwards from the kidneys are easily voided. Phosphatic concretions are not uncommon, and are due to the presence of a foreign body usually introduced by the patient. **Treatment.**—Litholapaxy is usually indicated, but for really large stones suprapubic cystotomy is the best procedure. It is never desirable to open the bladder through the anterior vaginal wall, so as to remove a stone, for fear of the persistence of a vesico-vaginal fistula.

Functional Derangements of the Bladder.

The act of micturition is a complicated proceeding, which for its effective performance requires the due co-ordination of several factors. When urine collects in the bladder, it is prevented from escaping at once by the tonic contraction of the sphincter vesicæ; in infants this is but little developed, and hence is readily overcome by the relatively strong detrusor in response to but slight intravesical pressure. As the child grows the sphincter becomes better developed, and is under more effective control; whilst at puberty the growth of the prostate adds to this, and therefore micturition loses its reflex character, and becomes entirely voluntary. Three chief elements enter into the act of urination, *viz.* (1) an appreciation of the stimuli set up in the bladder by its increasing distension, which depends on the sensory nerves having a free communication with the sensorium; (2) as a result of this stimulus, the sphincter vesicæ is voluntarily inhibited; and (3) the detrusor muscle is contracted, expulsion of the urine necessarily following. A voluntary contraction of the abdominal muscles is often employed to assist in this expulsive effort. Each of these muscular elements has its own central control: the sphincter in the inferior mesenteric and hypogastric plexuses, the detrusor in the lumbar enlargement of the spinal cord, and it is possible for one or both of them to be destroyed or weakened. Should the sphincteric control become weak, the activity of the detrusor may be relatively increased and the bladder contents are expelled too frequently (active incontinence). Should the sphincteric control be relatively increased, the expulsive efforts of the detrusor

will be hindered, and retention results. Necessarily, other causes than nervous enter into the production of these two conditions, and hence they must be considered separately.

Incontinence of Urine.—A patient is said to be suffering from incontinence when the urine escapes involuntarily, dribbling away either constantly or intermittently from the urethra.

1. **Active Incontinence (Enuresis)** is often present in young children, mostly boys, in whom, as already indicated, sphincteric control is not too well developed. It results from some condition of increased excitability of the urinary apparatus, and is looked on by some as of a choreic nature. The chief local sources of irritation are phimosis, ascarides in the rectum, a rectal polypus, or urine of high specific gravity, containing uric acid crystals in suspension. The affection is most obvious at night, and may only occur during sleep; it usually disappears when adult life is reached, if not cured before, but has been known to persist. **Treatment** of the nocturnal incontinence consists in the removal of all sources of irritation, such as a tight foreskin. Tonics, *e.g.* iron, arsenic, and quinine, may be administered, and tincture of belladonna should also be given in full doses. The boy must not be allowed to lie on his back, or to eat or drink late at night, but must be kept warm, and should be waked at regular intervals to pass water. All excitement of the sexual senses must also be avoided. During the day also the patient should be watched, and not allowed to run to the lavatory continually; the bladder must be trained to *hold* its contents. Parents and school-teachers should be instructed, and their co-operation secured, so as to train the child in habits of restraint. If this can be gained during the day, the nocturnal habit will cease.

2. **Passive Incontinence** is said to be present when the neck of the bladder is relaxed, so that as soon as any urine is secreted it flows out of the urethra—the bladder in this way never becoming distended. The cause of this condition is mainly mechanical, such as the holding open of the internal meatus by a pedunculated growth from the prostate or an impacted calculus. It sometimes occurs in women from over-distension of the urethra, as for removal of a calculus.

3. **False Incontinence,** or **Distension with Overflow,** may be the outcome of an attack of retention, naturally relieved, or is due to any condition in which the outflow of urine is impeded to such an extent as to lead to a certain quantity being left in the bladder after every act of micturition, although the patient imagines that the organ has been completely emptied. This so-called *residual urine* gradually increases in amount until the bladder becomes filled, and then some of it dribbles away involuntarily so as to wet the patient's clothes. In old-standing cases the bladder can be detected as a tense, rounded swelling in the hypogastrium. This condition is usually met with in patients with neglected stricture or enlargement of the prostate, and in the latter case the bladder may be so distended as to contain many pints of urine. Very much the same state of things obtains in paralysis due to spinal mischief. Treatment must be directed to keeping the bladder emptied by the regular use of a catheter, but it often remains in an atonic state for some time.

Retention of Urine.—When a person is unable to expel the contents of his bladder, so that it becomes distended, retention is said to be present. It results from a variety of conditions, which may be classified as follows:

1. *Mechanical obstruction* which may involve any part of the urethra or the neck of the bladder, the actual cause varying somewhat with the age and condition of the patient. Thus, in infants the most common cause of retention is the narrowed orifice of a tight phimosis; in children, an impacted calculus in the urethra or a ligature tied round the penis; in young men, gonorrhœa or one of its complications; in young women, foreign bodies in the urethra or bladder; in adult men, stricture, in adult women, uterine fibroids or some uterine condition compressing the bladder or urethra; and in old men, hypertrophy of the prostate.

2. *Nervous lesions* may be responsible for some cases. Anything that excites the sphincteric energy or diminishes the activity of the detrusor muscle may determine retention, and thus it may be brought about in many ways: (*a*) Spasm of the sphincter may result from mental perturbation or excitement, a person being unable to micturate in the presence of others. (*b*) Neurosis is a common cause, as in hysteria or shock; and a reflex neurosis is responsible for retention after injuries or operations, especially when the latter are somewhere in the neighbourhood of the genital organs, as for piles, hernia, varicocele, etc. (*c*) Organic disease of the nervous system produces retention, as in tabes, disseminated sclerosis, traumatic and neoplastic conditions of the cord, etc.

3. Inflammatory diseases of the bladder may be followed by difficulty in micturition as the result of fibrosis of the vesical wall, which is perhaps most frequently seen after gonorrhœal cystitis.

4. Retention is sometimes the outcome of habit or circumstances, as in clerks or school-teachers, and then when the opportunity to micturate occurs the act cannot be completed.

If left unrelieved, the urine accumulates and the bladder becomes distended. One of two conditions is certain to follow: (*a*) In cases of retention from stricture, or when a calculus is impacted in the urethra, the dilated urethra behind the seat of obstruction gives way, resulting in perineal *extravasation* of urine. If, however, the bladder wall has been weakened as the result of ulceration, or if it be sacculated, rupture of that viscus may occur, and pelvic extravasation may follow. (*b*) When the retention is not due to complete obstruction of the passages, the distension is in time followed by unconscious *overflow*, and relief is thereby obtained, although the bladder wall often becomes atonic.

The treatment of retention necessarily varies with the cause, as it is but a symptom.

Atony of the Bladder is the term applied to a condition in which the patient is unable to expel the contents, not on account of any true paralysis, but simply from loss of tone of the muscular wall. The causes are the same as for retention, and the condition may be determined by a single act of over-distension, or be the outcome of a more

chronic obstruction. Thus, owing to the oversight of a house-surgeon, it occurred in a patient who had been operated on for varicocele, and was left unrelieved for twenty-four hours. More commonly, however, it is met with in old people who are suffering from retention due to enlargement of the prostate, or in men who are the subjects of stricture of the urethra.

In the slighter cases all that is noticed is some hesitation or difficulty in commencing the act of micturition, whilst the flow itself is weak, the urine escaping with no force, and often dribbling away after the act is apparently completed. In bad cases a considerable amount of residual urine may be left in the bladder, the decomposition of which may lead to chronic cystitis. The **Treatment** should be directed to removing any source of obstruction which exists; regular catheterism two or three times a day will prevent any distension of the bladder, and the administration of strychnine, phosphoric acid, and other tonics will improve the expulsive power of the viscus. The passage of a constant current of electricity may also be employed two or three times a week to stimulate the muscular fibres; one electrode is inserted into the bladder, and the other placed over the hypogastrium.

Affections of the Prostate.

Acute Prostatitis arises most usually as a sequela of gonorrhœa, either in its acute or chronic stage, by direct extension backwards of the inflammatory process; it is also occasionally met with as a result of stricture arising from the irritation of retained and decomposing urine, or from the passage of instruments. It is said to be induced by the application of cold or damp to the perineum, as by sitting on cold stones or damp grass, but probably this has been preceded by bacterial invasion of the posterior part of the urethra. Suppuration follows in not a few cases, being due to the infection of the prostatic follicles with pyogenic organisms. Sometimes merely one or two superficial follicles are affected, causing what is termed a *follicular abscess*; occasionally the mischief extends much more widely, involving the whole of one lobe, or perhaps the whole organ, and constituting a *parenchymatous abscess*.

The **Symptoms** consist of deep-seated pain referred to the neck of the bladder, with perhaps a sense of weight and fulness about the perineum, and pain referred to the end of the penis. Micturition becomes frequent and painful, and defæcation may cause considerable distress. As the organ increases in size the pain becomes more and more severe, and all movements of the body, as also the act of sitting, are increasingly difficult. On rectal examination the organ can be felt enlarged, hot, and tender. Suppuration is likely to follow, and retention of urine may be thereby induced. A follicular abscess bursts into the urethra spontaneously, or is ruptured by the passage of a catheter for the relief of retention; the opening, however, is sometimes of a valvular nature, and only a small portion of the pus escapes. The process may then continue to spread, and the pus may find its way into the rectum, or come to the surface through the perineum. In either of the latter conditions a rectal or perineal fistula is liable to result. Considerable

constitutional disturbance and fever are usually associated with this affection, whether suppuration occurs or not. The formation of a parenchymatous abscess is always attended with much more acute symptoms, both general and local. The organ is larger and produces more rectal irritation; a considerable quantity of pus may form, and suppuration may extend beyond the capsule.

Treatment.—The patient should be kept in bed on a restricted diet and the bowels freely opened by saline purges, combined with small doses of antimony, and perhaps full doses of hyoscyamus. Hot hip-baths are also very valuable, and linseed-meal poultices may be placed on the perineum. Extreme pain should be relieved by the use of morphia suppositories, and if the urine needs to be drawn off, a soft rubber catheter of small size should be used. If an abscess forms, and is not opened by the passage of a catheter, or if the natural opening is of a valvular character, so that the cavity cannot completely empty itself, an incision must be made into it through the middle line of the perineum, being guided by a finger placed in the rectum; pus may not be reached until the knife has entered to a depth of about 2 inches. Urine will sometimes escape from this opening, and may continue to do so for some considerable time. If gonorrhœa is also present, suitable treatment must be adopted in order to check the discharge. When the abscess is pointing in the rectum, it may be wise to open it from that cavity; but every effort must be made to avoid this contingency, as a recto-urethral fistula may result.

Chronic Prostatitis is perhaps one of the most common causes of chronic gleet after gonorrhœa, and arises as a sequela of an acute attack; it may also be a result of stricture.

The **Symptoms** produced by it are a sense of weight and fulness about the perineum, combined with irritability of the bladder, and pain referred to the extremity of the penis at the end of micturition, owing to the bladder contracting upon the hyperæmic and sensitive organ. A glairy discharge of viscid material, similar in appearance to uncooked white of egg (*prostatorrhœa*), is often present, and fine threads of mucus are usually seen floating in the urine, being due to the formation of mucous casts of the prostatic ducts. On examination through the rectum, the organ can be felt enlarged and tender, and the vesiculæ are usually in the same condition. Chronic suppuration may follow, the abscess bursting into the urethra or rectum, or pointing in the perineum.

The **Diagnosis** from tuberculous disease can usually be made by careful attention to the history and physical signs.

Treatment consists in massage of the prostate from the rectum so as to empty the vesiculæ and prostatic follicles, and in effective irrigation with permanganate of potash solution, as for gonorrhœa (p. 138). Diathermy (p. 139) is useful, and the local application of organic salts of silver, *e.g.* argyrol, protargol, etc., is valuable; a small quantity is introduced into the prostatic urethra by a special porte-caustique. The passage of large solid bougies with a view to dilate the urethra and compress the prostatic follicles is also of use. The general routine treatment of gleet must be enforced (p. 138).

Tuberculous Disease of the Prostate is usually met with as a result of extension from similar disease in the epididymis, the seminal vesicles being also invaded; possibly, it may arise as a primary affection. In either case, it rapidly spreads to the bladder, and thence to the ureters and kidneys. The prostate is usually found to contain caseous masses which break down, leading to extensive ulceration, and sometimes the organ is riddled with ragged cavities. The symptoms are those of irritability of the neck of the bladder, combined with pain referred to the end of the penis, or mainly noticed in the back or perineum. Hæmaturia may occur, but pyuria is almost constant. The urine is feebly acid or neutral, and on examination of the pus tubercle bacilli may be detected. Rectal examination will demonstrate an irregular enlargement of the organ, and if the vesiculæ are invaded they also can be felt.

Treatment consists in the usual anti-tuberculous measures, and the injection of tuberculin may prove of some value. If the disease is not too extensive, benefit may be derived from removing the tuberculous tissue through a perineal incision.

Prostatic Calculi are infrequent, being usually met with in cases of chronic prostatitis, especially that resulting from stricture of the urethra or previous attacks of gonorrhœa. They are generally multiple, and of small size, consisting mainly of carbonate of lime. They develop primarily in the glandular crypts, and may remain embedded in a pouch or pocket of the organ, giving rise to but little inconvenience. When large and protruding from the gland into the urethra, great irritability of the neck of the bladder is induced, together with symptoms of obstruction to the flow of urine; on passing a catheter or sound a distinct click or grating may be noticed. Diagnosis can be effected in some instances by radiography, the calculi casting shadows usually a little below the brim of the pelvis. These stones cause a prostatitis often productive of a considerable urethral discharge, and when great difficulty of micturition or even acute retention occurs, this may lead to an erroneous diagnosis of a gonorrhœal stricture, unless careful attention is paid to the history and to the rectal examination, when the hardness is felt in the gland. It is sometimes possible to remove the calculi through the urethra, but more frequently a perineal incision is required.

Enlargement of the Prostate (or, as it used to be termed, *senile hypertrophy*) is a condition rarely seen under fifty years of age, characterized by a chronic persistent overgrowth of the organ, which results in interference with the act of micturition, and may finally destroy life by inducing secondary changes in the bladder and kidneys by prolonged backward pressure. As to causation but little is known. Recent experimental work in animals shows that a similar condition can be produced by the administration of œstrin, and it is possible that in man prostatic enlargement is the result of excessive œstrin production by the testis, or a deficiency of an anti-œstrin substance. It may attain a considerable size, perhaps constituting a tumour as large as one's fist and weighing 200 grammes, the average normal weight of the prostate being about 18 grammes. It may be of hard or soft consistence, and in the latter case is extremely vascular. The vascularity varies from time to time, and the patient is liable to sudden attacks of congestion,

which aggravate the symptoms. On section the organ may appear to be homogeneous and of the same texture throughout, but most commonly it consists of a number of firm rounded masses, sharply defined, and held together by a certain amount of connective tissue. Outside these is an ill-defined layer of stretched (and sometimes atrophied) muscular tissue, containing a few glandular elements, but continuous with the stroma, and constituting the true capsule of the organ. Still further out is the extrinsic sheath derived from the pelvic fascia (mainly recto-vesical); it consists of two layers, between which are the veins of the prostatic plexus.

Histologically, an enlarged prostate consists of an overgrowth of the glandular tissue, sometimes diffuse, more frequently in the form of multiple adenomata, set in a connective-tissue basis developed from the prostatic stroma of muscle fibres. Cystic changes are not usually observed in these adenomata. Occasionally a few fibro-myo-

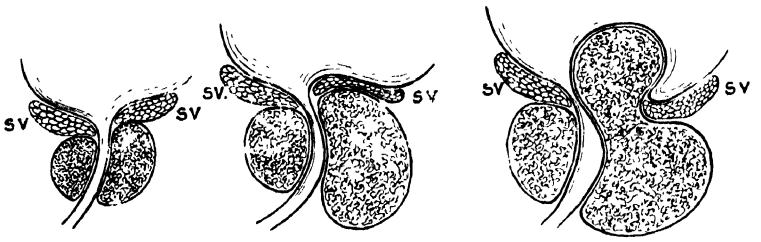

FIG 963 FIG. 964 FIG. 965

FIGS. 963-965.—DIAGRAMS TO ILLUSTRATE RELATION OF THE PROSTATE TO THE SPHINCTER VESICÆ (S.V.).

In Fig 963 the prostate is supposed to be of normal size, and the sphincter lies above it, in Fig. 964 the prostate is enlarged, but has no intravesical projection of 'middle lobe,' and hence the sphincter retains its normal relation; in Fig. 965, the most common type of prostatic enlargement, a well-marked intravesical projection or middle lobe exists, the sphincter being displaced backwards by this development

mata may develop, but they are decidedly uncommon. Malignant disease is liable to supervene in rather more than 10 per cent. of the cases, either in the periphery as a localized, firm, inelastic nodule closely attached to the capsule, or in the centre of a lobule.

The changes induced in connection with an enlarged prostate are numerous and important.

1. The prostatic sheath of pelvic fascia becomes thickened and condensed, thereby preventing any downward expansion of the organ, and directing its enlargement upwards.

2. The close connection between the capsule and the sheath, which is so marked a feature in the normal anatomy of the organ, is profoundly modified, so that it becomes easy to enucleate the gland in its entirety from its surroundings.

3. The relations to the bladder wall are also much altered. Normally, the sphincter (Fig. 963, S.V.) is interposed between the prostate and the vesical mucosa. As the gland enlarges, this relation may persist

(Fig. 964), and although the bladder base is raised up, the growth is extravesical, and the sphincter muscle is stretched over the enlargement. More frequently, however, the gland, as it enlarges, insinuates itself between the sphincter and internal meatus, constituting an intravesical projection (Fig. 965). This is generally most marked in the middle line behind, constituting the so-called 'middle lobe' (Fig. 966); but it may involve the whole gland, which projects into the bladder as a collar-like enlargement around the meatus, whilst sometimes one or both of the lateral lobes are chiefly affected in this manner. The gland also pushes backwards between the seminal vesicles, which in time are displaced from their connection with the back of the bladder, and constitute a posterior relation with the enlarged organ (Fig. 967). It is interesting to note that this overgrowth involves mainly, if not entirely, the upper part of the gland, and that the portion below the verumontanum is rarely affected, so that the openings of the ejaculatory ducts are not displaced backwards.

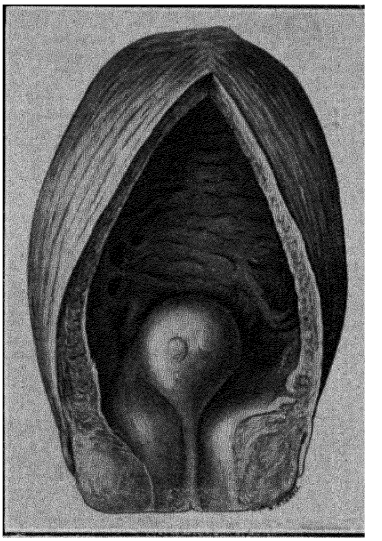

FIG 966.—ENLARGED PROSTATE WITH A LARGE INTRAVESICAL PORTION (FROM COLLEGE OF SURGEONS MUSEUM.)

4. The changes produced in the prostatic urethra and neck of the bladder vary considerably in different cases. The length of the urethra is always increased, perhaps by 2 or 3 inches, or even more. Some amount of obstruction to the outflow of urine is universal. In rare instances it may be due to an adenoma becoming pedunculated and projecting downwards into the urethra as a polypus. Occasionally the base of the middle lobe becomes narrowed, probably as the result of constriction by a band of longitudinal muscle fibres passing down on either side from the urethral orifice to the meatus; the middle lobe thereby becomes more or less pedunculated, and may be movable, constituting a ball-valve which determines retention, or else wedging open the internal meatus and causing incontinence. As a rule the outflow of urine is hindered by the 'prostatic bar,' caused by the projection of the middle lobe, which also hinders the entrance of a catheter. When both lateral lobes are enlarged symmetrically, the lumen of the urethra is diminished from side to side, being narrow or chink-like instead of triangular, but its vertical measurements are increased. Asymmetrical enlargements, of course, displace the urethra to one or other side.

5. The *effect* of an enlarged prostate *on the bladder* is important. The obstruction to the outflow of urine leads to increased expulsive efforts on its part, and consequently the wall becomes thickened and hypertrophied. This involves the muscular fibres, which stand out prominently as rounded fasciculi, and the mucous membrane may project outwards between them as hernial protrusions, constituting saccules in which urine may stagnate and decompose, and even phosphatic concretions form.

In almost every case the enlarged prostate projects more or less into the vesical cavity, either as a collar-like mass around the internal meatus, or as one or more rounded outgrowths. This is necessarily associated with a pouching backwards of the lowest part of the bladder (*prostatic pouch*), which, being below the level of the meatus, does not become emptied during the natural process of micturition, and in it *residual urine* is therefore able to collect and remain.

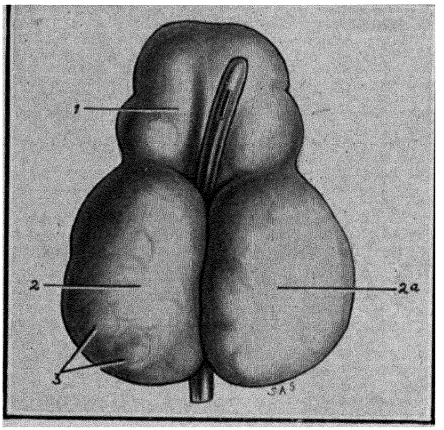

FIG 907.—ENLARGED PROSTATE AFTER REMOVAL BY SUPRAPUBIC OPERATION.

The catheter has been placed in the urethra 1, The so-called middle lobe, or intravesical projection behind the internal meatus; 2 and 2', the lateral lobes; 3, indicates some of the nodular adenomatous masses which constitute the bulk of the swelling

Cystitis will in time follow, caused either by infection from within or by the use of unsterilized instruments; the bladder wall becomes inflamed; ammoniacal decomposition of the urine follows, and phosphatic concretions not infrequently form, finally, renal complications ensue (due either to back pressure or to an ascending pyococcal infection), and these may determine a fatal issue.

The **Symptoms** vary somewhat with the nature and position of the enlargement. The patient at first finds some difficulty in micturition, especially at the commencement of the act, straining often hinders rather than assists. The stream is not necessarily smaller than formerly, but is projected with less force. Gradually irritability of the bladder ensues, and the patient has to pass water very frequently, a trouble especially noticed during the night. Some degree of pain and a sense of weight and fulness about the perineum are also experienced, and tenesmus, or even hernia, may be induced by the straining. Intermittent attacks of increased pain and difficulty in micturition occur from time to time, generally resulting from exposure to cold and wet, and presumably due to congestion of the prostate. After lasting for

a few days the more acute symptoms slowly disappear, if judiciously treated.

As the obstruction increases, a certain amount of residual urine remains within the bladder after each act of micturition, the vesical muscles in time losing power and becoming atonic. Well-marked distension and atony of the bladder ensue at length in neglected cases, the urine dribbling away and wetting the clothes. Decomposition of the retained fluid follows, accompanied by cystitis with increasing vesical irritation and muscular spasm; the urine becomes ammoniacal and contains muco-pus and phosphates; this process, if untreated, is certain to lead to hydronephrosis and pyelonephritis. The general health of the patient is slowly undermined by the constant irritation and want of sleep induced by these changes, as also by toxic absorption, and the final chapter may be ushered in by symptoms of uræmia from the mischief inflicted on the kidneys.

Occasionally the early symptoms may pass unnoticed for a considerable time, the patient imagining that the frequent calls to pass water are good signs rather than evidences of disease. In these cases the bladder may become over-distended, and the condition unsuspected, until, owing possibly to some exposure to cold or over-indulgence in alcohol, complete retention is induced, and then, to the surprise of the patient, an enormous amount of urine is withdrawn on the passage of a catheter. Priapism is sometimes a troublesome condition, and the effect of this on the moral sense may be very serious, even leading to acts of gross indecency.

The **Diagnosis** of enlarged prostate is made partly by a consideration of the symptoms complained of, but mainly by an examination of the organ from the rectum. The age of the patient, the increasing irritability of the bladder by night *and* day, the fact that straining hinders rather than helps the expulsive act, together with evidence of vesical distension—all these facts indicate that the seat of obstruction lies in the prostate. A rectal examination is then instituted, and bimanually a fair idea can be gained of the size and condition of the organ. The normal prostate is about the dimensions of a horse-chestnut; the enlarged organ constitutes a smooth rounded mass, varying in size, usually soft, and somewhat movable. The degree of obstruction to the urinary outflow cannot be gauged from the rectum, but is rather determined by the amount of residual urine. This is effected by asking the patient to empty his bladder and then passing a soft catheter; merely 2 or 3 ounces of urine may be withdrawn, but in bad cases anything up to 2 or 3 pints may escape. The actual degree and situation of the intravesical projection of the gland is seen at cystoscopy.

It must not be forgotten that an enlarged prostate may be associated with a stricture, the existence of which becomes evident on passing a bougie or catheter. The presence of a stone or stones in the bladder is indicated by severe cutting pain during micturition, as also by radiography. The secondary onset of cancer can only be guessed at in the early stages if the gland appears flat, hard, and fixed at one spot; if it commences in the centre of a lobule, it is unrecognizable. For the diagnosis from primary cancer of the prostate, see p. 1506.

Catheter Life.—To pass a catheter in a case of enlarged prostate is not always easy, owing to the fact that the middle lobe (Fig. 967) projects across the urethra, and bars the onward progress of an instrument of the ordinary shape. A rubber catheter should always be employed, if possible, and failing that a catheter coudé or bicoudé (Fig. 968), which consists of a soft, straight instrument of the usual French type, the end of which is bent or doubly bent at an angle, like an elbow, so as to enable it to ride over the obstruction. Only in difficult cases associated with acute retention should the surgeon resort to the silver prostatic catheter, which is longer and more curved than usual, and the handle of which requires to be well depressed between the thighs after the point has cleared the pubic arch. Whichever method is adopted, no force is required, since with a little skill the point of the instrument will pass round the obstruction and enter the bladder. Every precaution must be taken to ensure the sterilization of all instruments, and it should be remembered that as a rule large rather than small instruments will pass more easily.

During the first fortnight of catheter life the patient must be carefully guarded from cold and exposure. Not infrequently a certain amount of fever is produced, which either passes off in a few days, or

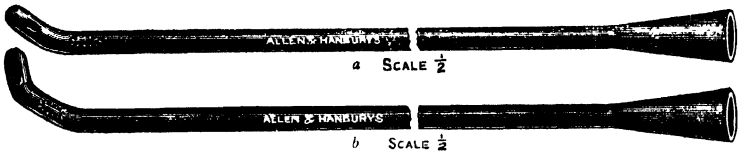

FIG. 968.—CATHETER COUDÉ (*a*) AND BICOUDÉ (*b*).

may increase, together with symptoms of chronic cystitis, running on to a fatal issue at the end of three or four weeks. This condition probably arises from septic causes, but possibly reflex nervous disturbance plays some part in its production. The only treatment required in the simpler cases is to keep the patient warm in bed, to limit his diet, to administer quinine and perhaps opium, and to keep the bowels well open.

During the continuance of catheter life, the patient must be warned to live quietly, and abstain from all excesses, especially as regards eating and drinking; sexual excitement should be avoided, and horse-exercise forbidden; precautions must also be taken to ensure protection from cold and damp. The administration of alkalies is desirable if the urine is highly acid, so as to diminish the irritability of the bladder.

Under such a régime, it is possible that the patient may live in comparative comfort perhaps for years, the progress of the affection being entirely checked in some instances. In others, the patient suffers from *intermittent attacks of congestion* of the prostate, with increased pain and irritability of the bladder, and augmented difficulty in micturition. These are usually brought about by exposure to wet or cold, or by injudicious indulgence in alcohol. Treatment consists in keeping the patient warm in bed, and, if convenient, placing

fluid aspirated. The prostate gland is enucleated, commencing anteriorly and to the left side of the gland, sweeping round posteriorly. This preserves a larger flap of mucous membrane on the floor than by tearing through the mucous membrane behind the middle lobe.

At the end of enucleation the mucous membrane of the prostatic urethra is divided by the finger over the gum elastic catheter; the patient is placed in Trendelenburg's position and illuminated bladder retractors introduced, with a lighted retractor in the prostatic cavity (Fig. 969). Any spurting vessel will be seen, secured by forceps and stitched; two ligatures are often needed, one each side of the prostatic rim, at about four and eight o'clock. A boomerang needle is now introduced deeply behind the inter-ureteric bar, pushed downwards and brought to the surface just short of the torn prostatic urethra;

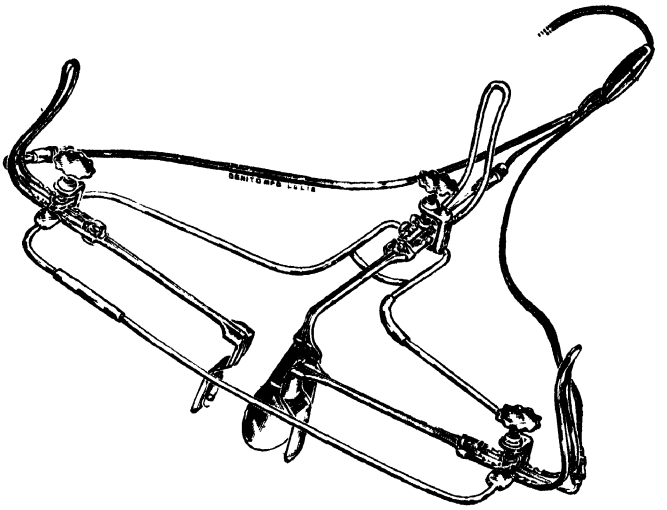

FIG. 969.—HARRIS'S ILLUMINATED BLADDER RETRACTOR.

this is threaded with catgut No. 2 and withdrawn. After tying this stitch it will be noted that the trigone area of the bladder has been drawn down so as largely to cover the prostatic bed. It is essential that this stitch be introduced in the mid-line, so as not to injure either ureter. A stitch is now introduced laterally, horizontally across the prostatic cavity, using the boomerang needle (Fig. 970). This is tied and a similar stitch introduced below this, well obliterating the prostatic cavity.

As a rubber catheter is needed for drainage, it is customary to withdraw the gum elastic catheter and introduce a No. 12 Mallecot on a stilette after the introduction of a trigonal suture and before placing the transverse stitches. The end of this catheter is cut off and a lateral eye is made and a silkworm-gut stitch passed through and brought out through the suprapubic wound. Hæmorrhage is now

usually adequately controlled. Occasionally a third transverse stitch may be needed.

The bladder can now be closed without drainage, but if there is any doubt as to the efficiency of the hæmostasis it is advisable to leave a small tube, the size of a No. 8 or No. 10 catheter, so that more adequate washouts can be given. The bladder is sewn up in the usual way and the layers of the abdominal wall. A small tube is required to drain the prevesical space, whether the bladder is completely closed or not. These tubes are fixed in the lower end of the incision, and the silkworm gut is brought out separately and tied over a rubber or glass tube, so as firmly to hold the catheter in position.

Freyer's Operation.—This consisted of a blind enucleation of the prostate gland, after which the bladder was not opened widely and any gross bleeding was controlled by packing.

Thomson-Walker Operation was a great advance, as here, after enucleation of the gland, automatic retractors were introduced, tags removed, and bleeding points secured; the shelf of the mucous membrane below the trigone was divided to prevent post-operative obstruction, and a hæmostatic stitch was introduced at the rim.



FIG 970.—HARRIS'S BOOMERANG NEEDLE

Harris Operation is described above, the advantages being greater hæmostasis and a shorter period, if any, of bladder drainage with consequent diminution in the risk of infection.

If preliminary suprapubic drainage has been established the operation is as indicated, except that the original track will need to be excised and the bladder mobilized from the symphysis pubis and other attachments to enable satisfactory suture at the conclusion.

After-Treatment.—The bladder must be irrigated at frequent intervals (half-hourly to start with) with small quantities of warm silver nitrate solution (1 : 10,000), whether the suprapubic drain is in position or not, to prevent these tubes of small lumen becoming blocked by clot. The bladder tube is usually removed in twenty-four hours, the prevesical in four days; the wound heals rapidly, and there seems to be no tendency to post-prostatectomy obstruction. The necessity for frequent irrigation in the first twenty-four hours has been emphasized. Morphia is useful to relieve the pain and spasm, and may be given as a suppository or hypodermically. While there is suprapubic drainage of urine Irvin's apparatus may be employed, consisting of a metal cup fitting closely over the wound, kept in place by elastic bands round the body, draining into tubes which carry away the

urine into a bottle between the legs. This keeps the patient dry and saves the expense of a dressing. The bladder is irrigated daily through the urethral catheter, which is usually left in position for about fourteen days. After it has been removed the patient usually is passing his urine naturally, but occasionally it is necessary, if a suprapubic leak occurs, for a rubber catheter to be introduced for a few days to allow the completion of healing.

Transurethral Operations.—In this country transurethral resection is most commonly carried out by the McCarthy resectotome (Fig. 971), although in America some form of the punch cautery is frequently used. Resection consists of the removal of pieces of prostatic tissue through a large endoscope by means of a wire loop electrode, using a cutting current under vision. This is rendered possible by the

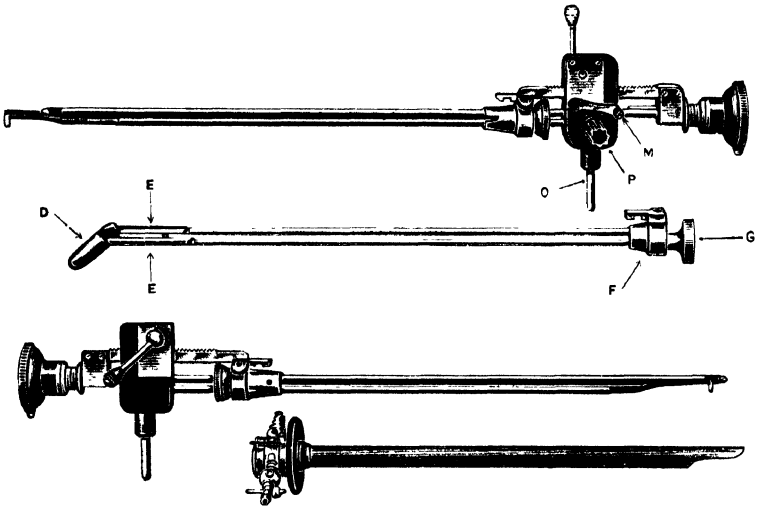

FIG 971.—MCCARTHY RESECTOTOME, SHOWING ITS COMPONENT PARTS

McCarthy visual system and improved irrigation. Sterile water must be used for this purpose with no electrolytes to disseminate the current. This should only be carried out by a surgeon extensively skilled in cystoscopic manipulations, as in inexperienced hands it may lead to perforation of the bladder into the peritoneal cavity or into the rectum.

By this means it is possible to gouge a channel through the prostate gland and allow satisfactory micturition to be re-established. It is of chief use in fibrous prostates where a small amount of tissue needs to be removed—there is little tendency to bleeding or for any large lateral lobe to fall together again. Secondly, as a palliative measure in carcinoma, which is justifiably preferable to a permanent suprapubic cystotomy. It also has considerable indication in simple enlargement of the prostate gland, when these patients, for any reason,

could not be subjected to the major operation of prostatectomy. The chief disadvantages of this procedure for simple enlargement are the occurrence of sepsis and the tendency to leave the patient with some chronic infection in the remaining prostate gland, for the remaining lateral lobe to continue growing, and for further operation to be necessary in three or four years' time.

Any bleeding at the time of operation is controlled by changing to a bulbous electrode and coagulating under vision with the diathermy current (Fig. 972).

If preliminary drainage has been established the operation is in no way altered and the urethral catheter will need to be reintroduced after about a week to allow closure of the suprapubic wound.

The **after-treatment** is much the same as for the Harris prostatectomy, the catheter being introduced at the conclusion of the operation and frequent irrigations being advisable. The catheter is usually removed on about the fifth day, the patient being allowed up in one week, provided no complications have occurred.

Suprapubic Cystotomy is frequently indicated, mainly as a preliminary to either prostatectomy or trans-urethral resection. Both these operations require satisfactory renal function tests before they can be embarked on with safety. The patient therefore with poor



FIG 972.—DIATHERMY ELECTRODE AND CUTTING LOOP ELECTRODE.

tests should have a temporary drainage established and have his urea concentration test and blood urea done at regular intervals until these are deemed worthy of further operative interference.

A permanent suprapubic cystotomy is now very rarely indicated for prostatic obstruction, except in certain cases of carcinoma where it is not possible to introduce the resectotome owing to the tortuous and lengthy rigid urethra, and in certain cases of benign enlargement where the renal function does not improve sufficiently for a resection to be carried out, or where the enlargement is so great that possibly four or five resections would be indicated to give an adequate channel.

In these cases a De Petzer or Mallecot catheter is introduced through a small suprapubic incision; this may be connected to a portable urinal worn in the trousers. Most patients, however, are happier when the tube is plugged with an ordinary wooden spiggot which can be released at regular intervals to allow the escape of urine. Regular bladder washouts will be needed to keep the bladder clean.

Steinach Operations.—Steinach I, the vaso-ligation originally introduced as a rejuvenating procedure, is now largely carried out in prostatic surgery, but merely with the idea of preventing the spread of infection to the epididymis. It may be done at the time of the temporary suprapubic drainage or in one-stage operations, at the conclusion of

a prostatectomy or trans-urethral resection. It certainly prevents epididymitis, a distressing complication, and has a distinct place in prostatic surgery.

Steinach 2, ligature of the vasa efferentia between the testis and the epididymis, again originally introduced as a rejuvenating operation, has been said to give beneficial effects in enlarged prostates; the reasons offered for this are (*a*) that by destruction of the spermogenic function an increase of male hormone is promoted which will cause the prostate gland to shrink, or (*b*) by interference with the sympathetic ganglion at the head of the epididymis an immediate reflex effect is produced.

Statistics at the present moment are unreliable, but there seems to be definite evidence that for early prostatic cases the development of the full syndrome may be averted, or at any rate postponed, although it is not possible at present to say for how long.

It may also be used to some advantage on very feeble patients who would not stand the proverbial 'haircut and shave' in two stages, as operation involves virtually no shock and can be done under local infiltration anæsthesia.

Cancer of the Prostate occurs in elderly men, but is more common than was formerly supposed; it is usually of a scirrhous type, though sometimes it is of a soft nature; in either form it early progresses beyond the limits of the capsule The symptoms produced are at first similar to those caused by simple enlargement of the prostate; but the progress of the case, though slow at first, is after a time much more rapid, the amount of pain and discomfort is much greater, and the pain is often referred to the back of the thighs and down the legs. Later on hæmaturia may occur. On rectal examination a hard mass is readily detected, fixed more or less to surrounding parts, and perhaps with outlying nodules distinct from the main mass; secondary deposits may be found in the lumbar and abdominal glands on palpating the abdomen. Occasionally phenomena referable to pressure on the abdominal vessels and nerves arise, and the symptoms of general cachexia early manifest themselves. Palliative treatment alone can be adopted in the majority of cases, operative measures to remove the whole organ, including the base of the bladder, have been practised, though with doubtful advantage. Radium, too, has not proved very successful, and, indeed, seems at times to favour local dissemination of the growth.

Transurethral resection has been mentioned, and undoubtedly affords a happier end to these unfortunate patients, although in some cases permanent suprapubic drainage will be necessary.

CHAPTER XLIII.

AFFECTIONS OF THE URETHRA AND PENIS.

Affections of the Urethra.

Congenital Malformations.—Total Absence, or **Occlusion,** of the urethra has been met with, the urine under such circumstances being sometimes retained, and leading to dilatation of the bladder, ureters, and kidneys, a condition rapidly fatal, even if the child be born alive. In a few cases the urachus remains patent, and a congenital urinary fistula is established at the umbilicus; in others the cloacal condition persists, the rectum communicating with the bladder.

Epispadias is a deformity in which the urethra is partially or wholly exposed along the upper surface of the penis. In rare instances the external meatus is situated just above the glans, which is cleft and deeply grooved superiorly. More commonly the urethra opens at the root of the penis, just in front of the symphysis, and in such patients the organ is always rudimentary and stunted. Complete epispadias is only present when associated with extroversion of the bladder (p. 1470). The incomplete form has been treated with success by the use of reversed flaps dissected up from the side of the penis For details of the operations on this and the following conditions, see textbooks on operative surgery.

Hypospadias, or defective development of the lower wall of the urethra, is a much more common malformation than the foregoing. Three varieties are described. In (*a*) *hypospadia glandis* the opening of the urethra corresponds to the position usually occupied by the frænum, and is thus directed downwards instead of forwards. The prepuce in these cases is always voluminous, and hangs like a hood over the glans, which is bent down over the orifice. (*b*) *Hypospadia penis* is characterized by the urethra opening somewhere along the under surface of the body of the penis, which is often small and stunted. Considerable discomfort may arise in the act of micturition, owing to the urethral orifice looking downwards; it is also sometimes so small as to require incision and dilatation. (*c*) Complete hypospadias, or *hypospadia perinealis,* is a somewhat complicated condition, in which the lower wall of the urethra is defective as far back as the perineum, the scrotum being cleft, and thus resembling the vulva (Fig. 973). The penis is always small, imperfectly developed, and bound down by adhesions between the scrotal segments, looking not unlike a hypertrophied clitoris, and late descent of the testes is common. Under these circumstances it is not surprising that the sex of the child has been mistaken, and not a few cases are on record where the boy has been educated as a female until the age of puberty.

In the incomplete varieties, where the deformity is slight and the urethral opening well in front of the scrotum, no interference is necessary; but where it encroaches on the scrotum, causing inconvenience and discomfort, and threatening to prevent effective sexual intercourse in the future, the restoration of the urethra may be attempted by the use of flaps obtained from either side, or from the redundant prepuce. In the complete form the penis must first be liberated from its adhesions and set free, the integument lining the scrotal cleft is then dissected up and turned inwards to form the posterior part of the urethra, and the lateral halves of the scrotum are brought together with sutures; the anterior portion of the urethra may then be dealt with, as for the incomplete variety.

Traumatic Laceration of the Urethra usually results from violence applied directly to the perineum, as by falling astride a stile, fence, or beam; it has also been caused by severe jolting in the saddle, or by a kick in the perineum. In fractures of the pelvis it may be produced by a spicule of bone puncturing the canal, and the membranous portion is that generally affected. The whole circumference of the urethra may be involved, the two segments being entirely disconnected, or only a portion may be ruptured, and that most frequently the floor (Fig. 974).

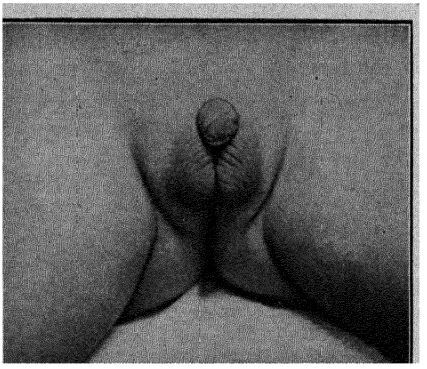

FIG 973 — COMPLETE HYPOSPADIAS WITH CLEFT SCROTUM

The **Symptoms** consist of pain in the perineum and shock, followed by great distension of the scrotum from hæmorrhage, and blood trickles from the urethral orifice. If the patient is able to restrain himself from passing water, and is successfully treated, no extravasation of urine results, since the lesion is below the sphincter vesicæ; if, however, he attempts to micturate, the urine finds its way into the perineal and scrotal tissues Whether the rupture is complete or not, an organic stricture of considerable density is almost certain to follow, and great difficulty is subsequently experienced in keeping it dilated.

Treatment.—In the slighter cases, where it is probable that the mucous membrane has alone been torn, and there is no perineal swelling, the patient should be kept quietly in bed, and no attempts made at instrumentation. If urinary infection of the wound occurs, and an abscess forms, it can be dealt with by incision at a later date.

When, however, it is thought that the urethra is partially or wholly divided, no temporizing measures, such as tying in a catheter, even if that be possible, should be adopted. An incision ought to be made at once into the perineum so as to expose the divided ends of the

urethra, which it is the surgeon's aim to unite. The blood-clot is removed, bleeding-points are secured, and if the ends of the urethra can be identified a soft catheter is introduced into the bladder, and they are sutured together around it with fine catgut. When the ends are much bruised, they should be excised so as to have clean, smooth surfaces to deal with. Under any circumstances, the catheter must be kept in for five or six days, and subsequently an instrument should be passed every day for some time. It is usually advisable to combine this with suprapubic bladder drainage to divert the urine from the damaged area; this also affords the opportunity for the retrograde passage of a catheter to identify the proximal end of the torn urethra.

If a catheter cannot be introduced, or if extravasation has occurred, free incisions must be made into the scrotum and perineum to give exit to the blood and urine, and to expose the seat of injury. A catheter is passed as far as possible, and its point felt for, cut down on, and guided into the bladder; a prolonged attempt under anæsthesia may be necessary to accomplish this, and even then it is useless to attempt to stitch up the urethra, as the sutures are certain to cut out. Occasionally, and especially if treatment has been delayed, the swelling of the parts is so great as to render the passage of a catheter impossible. The patient should then be drained suprapubicly, and an attempt made as soon as possible to repair the urethral injury.

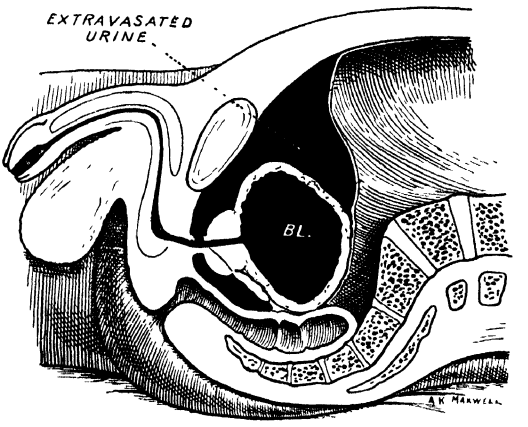

FIG 974.—EXTRAVASATION OF URINE DUE TO A RUPTURED URETHRA

Foreign Bodies are sometimes found in the urethra, usually consisting of a portion of a catheter, pipe-stem, or in children a piece of slate-pencil. Their presence gives rise to partial or complete obstruction to the flow of urine, followed by ulceration of the mucous membrane, the formation of a peri-urethral abscess, or even extravasation. They are readily detected on the passage of a sound or catheter, and may be removed by suitable forceps if situated near the orifice. Should this fail, the urethra may be incised and the body extracted; a troublesome urinary fistula is apt to follow this proceeding, even when the wound in the urethra has been carefully sutured.

A pin is sometimes introduced voluntarily into the urethra, and is not easily removed, since it has usually been pushed in head-foremost. The following manœuvre is necessary in order to remove it: The point

is made to penetrate the floor of the urethra and skin by a sharp push on the head from behind. The body is pulled out until the head catches against the mucous membrane, and then the direction of the pin can be changed, so that the head presents at or towards the meatus.

Impacted Calculus is a not infrequent cause of retention in children. It can usually be felt through the walls of the canal. The symptoms and treatment are much the same as for foreign bodies. When near the neck of the bladder, it should be pushed back into that viscus, if possible, and treated by lithotrity.

Simple Urethritis may arise from a variety of causes apart from gonorrhœa, *e.g.* the presence in the female of an irritating vaginal discharge, such as leucorrhœa, and possibly due to the *B. coli.* It also occurs after the passage of an instrument or of a calculus, and is occasionally excited in gouty individuals by highly acid urine, charged presumably with spiculated crystals of uric acid. The symptoms are much the same as those of gonorrhœa, but the discharge is thinner in character, and on microscopical examination no gonococci are detected. The treatment consists in the administration of alkalies and saline purgatives, all forms of alcohol being interdicted. In more severe cases oleo-balsams may be prescribed, and even mild injections.

Polypoid Tumours, similar in character to the caruncle met with in the urethra of women, have been observed at the orifice of the male urethra. They are red, vascular, and sometimes exceedingly painful, and are dealt with by excision, followed by the application of the galvano-cautery, so as to stop the bleeding, which is always copious. If of large size, the base may be ligatured and the growth cut away.

Epithelioma of the urethra is usually secondary to some other malignant development in the neighbourhood, *e.g.* of the prostate. Occasionally, however, it is primary, and then frequently the sequela of an old stricture. It constitutes a hard swelling of the urethra, which infiltrates surrounding parts, and there is usually some discharge of blood and pus from the meatus; micturition is consistently painful. The introduction of an instrument increases both the pain and bleeding; it generally passes easily, but the irregularity of the surface of the growth can be recognized. Examination by the urethroscope is desirable in such cases. Amputation of the whole penis is usually required.

Stricture of the Urethra.—By stricture of the urethra is meant a condition in which the onward passage of urine is hindered, owing to some change in the walls of the urethra, which prevents them from dilating. When at rest, the urethra is merely a potential canal, the walls of which are in complete apposition, and it is only converted into a tube when urine is passing along it. When, owing to some change in the structure of its walls, this functional dilatation is impracticable, the patient is said to suffer from stricture. Three forms of stricture are described, *viz.* the spasmodic, congestive, and organic.

Spasmodic and Congestive Strictures frequently co-exist, although either congestion or spasm may be the predominant feature in any particular case. Thus, in acute gonorrhœa the mucous membrane often becomes engorged and thickened to such an extent as to inter-

fere with the act of micturition. Spasm is the chief element under the following conditions: (1) When a patient suffering from slight organic stricture is exposed to wet or cold, especially after heavy drinking; (2) as a result of catheterism; and (3) from perineal irritation of the urethra, as by a blow or kick in this region, or from prolonged riding on a bicycle with a badly-fitting saddle, or on horseback. Temporary retention is the usual result of any of these conditions, and, as a rule, no *treatment* is required beyond placing the patient in a hot bath, and unloading the lower bowel by the use of a large warm enema. If such fails, catheterism will be necessary, and must be conducted with the greatest gentleness, owing to the congested and lacerable condition of the mucous membrane. Full-sized soft instruments should first be used, and will usually succeed; if not, a silver instrument must be substituted.

Organic Stricture is the term applied to an undilatable condition of the urethra, resulting from the development of cicatricial tissue within its walls.

The **Causes** of organic stricture are: (*a*) The long continuance of a urethral discharge following gonorrhœa, or the frequent recurrence of this affection. Chronic inflammations are always characterized by a tendency to sclerosis of the tissues involved, and the urethra is no exception to this rule, its walls under these circumstances becoming thickened, indurated, and contracted. (*b*) The cicatrization of a urethral chancre, or of an ulcer caused by the impaction of a stone, or the contraction produced by the healing of a urethral abscess, may also lead to stenosis. (*c*) The most intractable forms of stricture are those due to cicatrization after rupture or laceration of the urethral wall.

The usual **Situation** is within the bulb, *e.g.* just in front of the triangular ligament; but the orifice and body are not infrequently affected. It occurs in the membranous portion only as a result of traumatism, and never in the prostatic. To find more than two strictures in any particular case is unusual, although three or four have been met with.

Various terms are applied to a stricture according to the physical conditions present, thus, it is termed *annular*, if it involves the whole lumen of the urethra; *bridled*, if it affects only a portion of the circumference of the tube. A *ribbon-shaped* stricture is one in which a considerable extent of the wall is contracted, *i.e.* as if a ribbon has been tied around the urethra. It is termed *tortuous*, if the resulting passage is not straight; *indurated*, if the walls are very hard and thickened; and *resilient*, when the stricture, though readily dilated, rapidly recontracts. The terms *impassable* and *impermeable* are applied to strictures through which, on the one hand, a surgeon is unable to pass an instrument, or along which, on the other hand, urine cannot find its way; it is doubtful whether the latter condition ever occurs, whilst the number of impassable strictures met with by the surgeon diminishes with his experience and ability in passing instruments.

The **Symptoms** of urethral stricture vary according to the case. The patient generally complains of difficulty in the act of micturition, the stream becoming small, and perhaps forked or twisted. It takes a longer time than usual to empty the bladder, and even when apparently

successful a few drops of urine may trickle away, wetting the patient's clothes. Irritability of the viscus follows, leading to frequent attempts to pass water at short intervals during the day and night. The urine under these circumstances often becomes alkaline, and loaded with muco-pus and phosphates. As the obstruction increases, more and more residual urine is left in the bladder, which may in time form a tense, rounded, dull swelling in the hypogastrium. The quantity of urine trickling away also increases, so that the patient's garments are always wet, giving him an unpleasant urinous odour. A certain amount of gleety discharge is present, and if the individual takes an excess of alcohol, or is exposed to wet and cold, complete retention may ensue. Sometimes the onset of symptoms is so insidious that such an attack of retention is the first marked feature in the case.

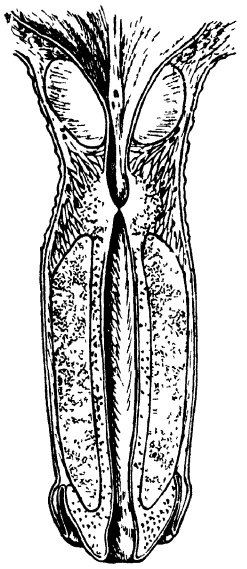

FIG. 975. — ANNULAR STRICTURE OF THE BULBOUS URETHRA

The **Pathological Conditions** arising from a stricture are best considered under the following five headings: (1) The *urethra anterior* to the stricture is usually in a perfectly normal state, although possibly the orifices of false passages may be seen. A few granulations are sometimes present, projecting at the commencement of the stricture. (2) The *stricture itself* is characterized by the development of fibro-cicatricial tissue immediately under the mucous membrane, and intimately adherent to it. It extends for a variable distance, and is often associated with a good deal of peri-urethral infiltration. (3) The *urethra behind the stricture* is dilated, and the mucous membrane velvety and friable; the orifices of the lacunæ and other glands are somewhat enlarged and more than usually evident, and ulceration may be present around them. In the later stages the inflammation may extend to the peri-urethral tissues owing to lymphatic absorption, or perhaps to the escape of a few drops of urine; a perineal abscess then results, leading subsequently to perineal fistulæ. When the obstruction becomes almost absolute, this portion of the urethra may give way, leading to extravasation of urine into the perineum and scrotum. (4) The *bladder* invariably manifests considerable changes in structure. At first the vesical wall undergoes a compensatory hypertrophy of its muscular elements and is thickened, in order to overcome the obstruction to the onward passage of urine (Fig. 975). The lattice-work arrangement of the muscular bands becomes coarse, thickened, and evident, causing the vesical wall to assume a fasciculated appearance. As the pressure increases, the mucous membrane protrudes between the muscular fasciculi, giving rise to sacculation; it is also thickened and congested as a result of chronic cystitis; the superficial veins become varicose, and hæmaturia may be caused

by their rupture; ulceration may also occur. The urine becomes alkaline and decomposes, containing muco-pus and phosphates. It is likely to stagnate in any sacculi which exist, and may then determine the formation of phosphatic concretions; or the walls of the sacculi ulcerate, and after a time perforation and extravasation of urine into the cellular tissue lead to a fatal issue. Occasionally the bladder, instead of being thickened, is dilated and atonic, with very thin walls. (5) Consequent on the changes in the bladder, the conditions already described as hydronephrosis, pyonephrosis, or pyelonephritis may develop, partly as the result of the backward pressure, and partly from the extension of inflammation along the ureter to the pelvis of the kidney and calyces.

Physical Examination.—The actual diagnosis of a stricture can only be confirmed by a careful physical examination of the urethra, which is usually made by the introduction of a full-sized catheter or a solid bougie, *e.g.* No. 9 or 10 (English), so as to ascertain where the obstruction is situated. If this cannot be passed, smaller instruments, and even filiform bougies, are inserted until one is found which will enter the bladder.

A great variety of catheters is in use; in selecting such an instrument care must be taken that it is suitably curved, that the 'eye' is suffi-



FIG. 976.—TIEMANN'S CATHETER.

ciently large and bevelled inwards, so that no projecting rim lacerates the urethral mucous membrane.

Catheters likely to be left and tied in should have more than one eye, so that if one becomes blocked a drain is still established through the other.

The great advantage of silver catheters is that they can easily be rendered aseptic and the point can be located and guided readily along the urethra.

Many varieties of flexible catheters are now extensively employed, as they give rise to less irritation than those made of metal and are less likely to traumatize the urethral mucous membrane. They are not readily directed through a stricture on account of this flexibility, and their use has been largely replaced by bougies for this condition.

The most advisable way of sterilizing gum elastic catheters is by keeping them in a box with formalin tablets. The catheters, however, must be washed through with weak boracic or sterile water to remove deposit of formalin from the interior and exterior of the catheter, as this substance readily sublimes and is very irritating. Alternatively, they may be allowed to soak for twenty minutes in a 1 : 2,000 sublimate solution.

The most popular rubber catheters are Marshall's or Tiemann's (Fig. 976), the latter being useful in prostatic cases, as it is made of particularly firm rubber, and its beak is coudé to engage the curve of the urethra.

Bougies or solid instruments are preferred by the majority of surgeons for examination and treatment of strictures. Lord Lister's are still popular, consisting of solid metal rods, curved like catheters, the bulbous ends of which are three sizes smaller than the shanks, thus enabling each instrument to prepare the way for the next.

If these fail to pass, a filiform bougie, made of gum elastic, is introduced. If this fails, several more are introduced simultaneously into the urethra, and each will block up a pit or even a false passage, so that ultimately one will find its way through the stricture. When this has been done a Harrison bougie can be screwed on to the connection at the end of the filiform bougie, which will then guide the passage of the larger instrument. If necessary a Phillips catheter, which is similar in design except that it has a lumen for the drainage of urine, can be used if a full bladder is present.

In order *to introduce a silver catheter or bougie*, the patient is laid on his back, the surgeon standing on his left side. The umbilicus should always be exposed, as also the upper parts of the thighs. The meatus and end of the penis are washed with a 1 in 2,000 solution of sublimate, as also the surgeon's hands. The catheter, which has been previously sterilized, warmed, and covered with sterilized or antiseptic oil or grease, is taken in the right hand and inserted into the urethra, with the handle directed over the left thigh and slightly downwards. The point of the instrument is guided as far as the perineum, and then the handle is carried round to the middle line of the body towards the umbilicus; it is gently raised to the vertical, the penis being held in the left hand, and finally depressed between the patient's thighs, the so-called *tour-de-maitre*. The catheter finds its way along the urethra into the bladder rather by its own weight than by any forcible action of the surgeon. The chief points at which difficulty may be experienced are: (*a*) The orifice, which may be small and contracted; (*b*) the lacuna magna, which is avoided by keeping the point of the instrument against the floor; and (*c*) the opening in the triangular ligament, which is best entered by keeping the point against the upper wall of the canal.

When a flexible instrument without a stilette is used, it is passed by pressing the point on with a little rotatory movement until the bladder is reached, withdrawing a little, and pushing on again, if any obstruction is met. In some instances, however, the use of a stilette is absolutely necessary.

The chief **Dangers** of catheterism are as follows:

1. A considerable degree of *shock* is sometimes experienced, especially in sensitive individuals, and if an instrument has not been passed before. It may be obviated to a large extent by first introducing about ½ drachm of the 5 per cent. solution of novocaine into the urethra.

2. *Hæmorrhage* may be induced by laceration or abrasion of the mucous membrane, even though no false passage has been made; it is best avoided by gentleness and the use of well-finished instruments. In spite of these precautions, when the mucous membrane is soft and congested, and in many cases of stricture, some bleeding cannot be avoided. It is rarely sufficient to call for special treatment, but if

very abundant may be arrested by the pressure of an instrument tied in or by injections of hazeline.

3. *False passages* are occasionally produced in the treatment of strictures. The point of the instrument is most likely to leave the canal at some spot in the floor, travelling for a variable distance, according to the force employed, under the mucous membrane, sometimes re-entering the dilated urethra behind the stricture, which it avoids altogether, or perforating the posterior wall of the bladder by tunnelling under the prostate, an accident which can only occur in unskilful hands. The occurrence of a false passage is indicated by the sudden onward movement of the instrument, combined with pain and hæmorrhage; the point is usually deflected from the middle line, as is plainly seen by the obliquity of the rings at the end of the shaft; no urine comes unless the urinary passages are opened behind the stricture. On rectal examination, the instrument can be felt out of the middle line, and nearer the rectum than is normal, and in some exceptional cases has even been found in it. A false passage is not necessarily a matter of great importance, but when extensive may lead to peri-urethral suppuration and extravasation of urine. If the urine is very offensive, grave infective troubles may arise, even threatening life. Thus in one case the unfortunate patient suffered subsequently from gangrene of the penis, necessitating its almost complete removal, in spite of the fact that a free incision was made through the perineum into the urethra, and the urine drained away.

4. Inflammatory phenomena may be lighted up in the prostate, and acute epididymitis induced by extension along the vas deferens; these are always due to infection.

5 **Urinary Fever,** or, as it is sometimes termed, urethral or catheter fever, is always liable to develop as a result of the introduction of instruments. It may occur as a solitary rigor even in individuals with healthy urinary organs, but is much more frequently observed in those with damaged kidneys. As to its causation, much discussion has arisen, but there can now be little doubt that it is essentially infective in origin. Possibly the instrument employed may be dirty, or the urethra itself contains infective material, especially in its deeper parts. It is quite sufficient for a slight abrasion to occur near the neck of the bladder, to allow of the absorption of bacteria, and then general phenomena show themselves at once. Possibly a passing febrile condition, with one or more rigors, will develop, with no more serious phenomena; but the trouble is liable to extend from the bladder to the kidneys, giving rise to pyelonephritis.

The *clinical manifestations* vary considerably, according to the character of the case and the type of infection. (*a*) The simplest form consists in the development of a single rigor, the temperature perhaps running up to 105° F.; the patient shivers and feels very ill, complaining of headache, but when the temperature falls he soon recovers, and within a few hours is all right again. (*b*) Sometimes the temperature does not fall to the normal after the initial rigor, but remains elevated a few degrees for a day or two, and there may even be a repetition of the rigor. The patient, however, recovers

perfectly, and no permanent harm is done. (*c*) In the more serious cases the symptoms of pyelonephritis supervene, and are very likely to prove fatal, the patient perhaps dying in seven or eight days. (*d*) General pyæmia may appear as a complication of the last condition. (*e*) In patients who are commencing the regular passage of catheters for enlarged prostate a series of phenomena develop which have been already alluded to (p. 1500), and though often mild, are of a similar nature. (*f*) Finally, suppression of urine may accompany any of the conditions alluded to above.

Treatment.—The greatest care must always be taken in order to avoid infection, and it is better to use soft instruments, if possible, rather than silver ones, as the latter give rise to more irritation than the former, and are more likely to abrade the mucous membrane.

For the single rigor following catheterism, the patient must be kept warm, plenty of hot diluent drinks given, and quinine (2 grains) administered. If the febrile symptoms continue, the skin and bowels are freely acted on, and a milk diet prescribed, although a certain amount of stimulant may be given if necessary; all operative measures must be avoided, unless it is essential to relieve obstruction. If suppression of urine ensue, the loins should be cupped in the hope of relieving renal congestion, and a free action of the bowels obtained by the use of watery purgatives. If the urinary secretion is not quickly re-established, *i.e.* in forty-eight hours, the surgeon should perform nephrostomy, *i.e.* opening and draining the renal pelvis, without delay, selecting for operation the kidney which appears to be most tender; it may be necessary to incise both kidneys. Uræmic symptoms may sometimes be relieved by copious and repeated intravenous injections of saline solution, which encourage diuresis and a watery diarrhœa.

The **Treatment of Passable Strictures** is conducted either by dilatation or by a cutting operation (internal or external urethrotomy).

Treatment by **Dilatation** is effected in various ways, according to the nature of the stricture and the urgency of the symptoms. Where the obstruction is not serious, and an instrument can be easily passed, *gradual dilatation* should always be employed; this consists in the use of instruments once or twice a week, steadily increasing in size until a No. 12 is reached. If the intervals are too short, the urethra may become irritated, spasm be induced, and the lumen of the canal temporarily diminished in size; by keeping the patient quiet for a few days on a bland diet, and the bowels freely open, the spasm disappears. In cases where time is an object, *rapid dilatation* may be undertaken by the passage of several sizes of bougie at one sitting; for this purpose Lister's instruments are particularly useful. Where only a very small catheter can be introduced, and that with difficulty, *continuous dilatation* may be adopted by keeping the patient in bed, and tying in a small instrument for forty-eight hours or more, at the expiration of which period a catheter several sizes larger can be substituted. This in turn may be tied in if the patient can bear it; but the presence of a catheter within the urethra for any length of time is not always tolerated, and may give rise at the end of two or three days to considerable constitutional disturbance and fever.

By whichever of these methods dilatation is accomplished, it is essential that either the surgeon or the patient should subsequently pass an instrument through the stricture, at first every week or two, and then at longer intervals, to overcome the tendency to recontraction which is ever present.

The **Treatment of Passable Stricture** by a **Cutting Operation** is conducted either by excision or by internal or external urethrotomy.

Excision is certainly the ideal treatment, the urethra being thereby restored to a normal condition. It has now been frequently undertaken, and with great success, in strictures of the deeper perineal portion of the urethra; it is not so satisfactory when the penile urethra is involved. Fully an inch of the tube may be excised, and the ends sutured together over a catheter. The corpus spongiosum must be detached from its surroundings to permit of this. Sutures are introduced in the upper wall first; then the catheter is placed in position, and the remainder of the stitches inserted.

Internal Urethrotomy is a valuable means of treatment when rightly employed, but in careless or inexperienced hands may be attended

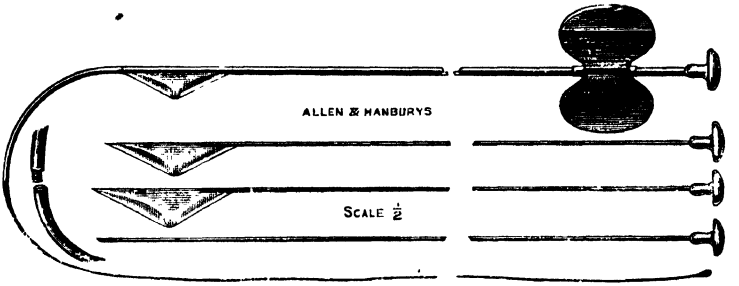

FIG. 977.—SIR JOHN THOMSON-WALKER'S URETHROTOME

with considerable danger. It should never be undertaken for impassable strictures, and therefore it is limited to strictures through which at least a filiform sound can be passed, and yet for various reasons ordinary dilatation is undesirable. Thus it may be required (*a*) in the treatment of very old and dense strictures, as also (*b*) for resilient strictures, and (*c*) when the urethra is so irritable that the passage of any instruments is associated with grave constitutional reaction. (*d*) Occasionally the patient cannot give the time to submit to ordinary treatment by dilatation, and in order to hasten matters internal urethrotomy may be desired.

The operation is usually performed from before backwards, and Thomson-Walker's urethrotome (Fig. 977) is usually employed. After irrigating the urethra, a special staff is introduced to which is attached terminally a fine filiform guide, which passes through the stricture and coils up in the bladder. Along a groove in the staff is inserted a steel rod carrying a triangular knife, sharp at each end, and with the apex blunt and expanded, so as not to injure the urethral wall during its passage. When the knife engages the face of the stricture its onward

progress is hindered, and then the surgeon drives it forward with a sharp push, thereby dividing the fibrous wall of the stricture; this is usually effected along the roof of the urethra. Several sizes of knife are available so as to vary the depth of the incision. A full-sized soft catheter is passed and tied in, being retained for two or three days; the patient is then permitted to micturate normally, and no instrument is passed for a fortnight. Hæmorrhage sometimes occurs as a sequela, and is not easy to control, ice to the perineum and pressure may be helpful, or calcium lactate may be given *per rectum*; in serious cases perineal section may have to be undertaken, and direct pressure applied.

External Urethrotomy, or **Syme's Operation,** is required under circumstances similar to those needing internal urethrotomy, but is chiefly employed when complications arise behind the stricture, such as a perineal abscess, perineal fistulæ, impaction of a calculus, or



FIG 978.—SYME'S SHOULDERED STAFF FOR EXTERNAL URETHROTOMY.

extravasation of urine. It is performed by passing a special shouldered staff (Syme's, Fig. 978), the distal end of which is small enough to traverse the stricture, and grooved in the middle line; the shaft of the instrument is of larger size, and ends abruptly, so that the shoulder rests against the face of the stricture; the groove extends on to the larger portion for about ¼ inch. The patient is then placed in the lithotomy position, and the surgeon, seated opposite the perineum, which is shaved and purified, incises it in the middle line, deepening his dissection carefully so as to reach the groove in the staff behind the stricture. The knife is then carried forwards to the anterior extremity of the groove, and inasmuch as it extends on to the shaft of the instrument, the stricture is completely divided. Any fistulæ which exist are laid open into the median wound. A full-sized soft catheter is then passed into the bladder, through either the penis or the perineum, according to circumstances, and retained in position for some days, the urine being syphoned off in the usual way; the perineal wound, after hæmorrhage has been stopped, is packed and allowed to heal by granulation. The catheter is removed early or late according to the amount of general disturbance caused thereby, and subsequently a full-sized instrument can be passed into the bladder daily.

The **Treatment of Impassable Stricture** varies according to whether or not the condition is complicated with retention of urine.

If *no retention is present,* it is possible that the inability to pass an instrument is due to some temporary spasm or congestion induced by errors of diet or drink, or perhaps by exposure to cold. Hence the patient should rest in bed for a few days, his bowels be well opened, the

diet regulated, and a mixture containing some alkaline purgative and tincture of henbane administered. Further attempts at instrumentation should then be made, if necessary, under an anæsthetic, and if the stricture still remains impassable, *Wheelhouse's operation* (Fig. 980) is indicated. This consists in incising the urethra in front of the constriction, tracing the passage backwards, and dividing it. A Wheelhouse's straight staff (Fig. 979) with a median groove and a blunt hook at the end is inserted down to the stricture, and the urethra opened just in front of it by cutting down on the groove. The staff is then



SCALE $\frac{1}{3}$

FIG. 979.—WHEELHOUSE'S STAFF

twisted round, the upper end of the incision drawn up by the projection of the hook, and the sides of the urethra held apart with artery forceps. The orifice of the stricture is thus exposed, and granulations may often be seen projecting from it. A fine probe-pointed director can generally be insinuated along the urethra through the stricture, which is then divided. A full-sized instrument is passed into the bladder and retained for a few days, and the wound is allowed to heal by granulation.

If *retention of urine is present* in a case of impassable stricture, no time must be lost. If seen at an early stage, and the symptoms are not urgent, the patient is given a hot bath, and the bowels are opened by a warm enema, whilst a moderate dose of opium or preferably a morphia suppository is administered. If the urine is not passed naturally in the bath, and the bladder is becoming distended, being felt in the lower part of the abdomen, then suprapubic cystotomy must be performed, and bougies or soft instruments passed from inside the bladder, if not at once, at any rate after a day or two. Dilatation then proceeds in the usual manner.

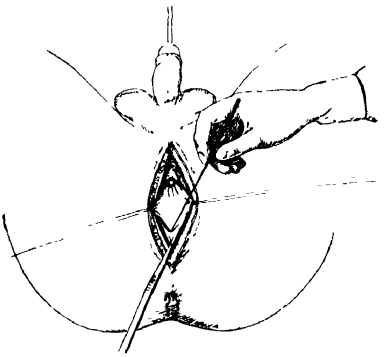

FIG 980 —WHEELHOUSE'S OPERATION FOR IMPASSABLE STRICTURE

The chief **complications** of stricture other than those already mentioned are peri-urethral abscess and extravasation of urine.

A **Peri-urethral Abscess** is due either to a limited extravasation of urine, or to the absorption of infective material through an ulcerated surface. It is indicated by the formation of a hard, brawny swelling in the perineum or above the scrotum, which is tender to the touch. As it approaches the surface, fluctuation can be detected, and the skin over it becomes congested and œdematous. Constitutional disturb-

ance and fever of an asthenic type are also present. Left to itself, it bursts and usually gives rise to a perineal sinus or fistula, discharging either pus or urine mixed with pus. One or many of these fistulæ may occur, and the openings are not limited to the perineum, but may also be found in the thighs or buttocks. In chronic cases, the scrotal or perineal tissues become infiltrated and of an almost cartilaginous consistency.

Diagnosis.—Every abscess in the scrotum or perineum is not necessarily associated with stricture, for simple irritation of the skin may lead to a superficial abscess; suppuration in the lacunæ, or Cowper's glands, may follow gonorrhœa, a prostatic or ischio-rectal abscess may point in the perineum; and the injury inflicted by the passage of instruments, or the existence of false passages, may lead to a similar result.

Treatment consists in letting out the pus through a free incision, and it is often advisable to take the opportunity of dealing radically with the stricture by section at the same time. Perineal fistulæ can rarely be cured without operation, since, although the stricture may be completely dilated, the discharge of urine and pus continues. In these circumstances Syme's or Wheelhouse's operation is the proper treatment.

Extravasation of Urine is a condition due to a solution of continuity of the urethral walls, allowing the urine to find its way into the perineal and scrotal tissues. It usually results from over-distension of the urethra behind a neglected stricture; during some violent effort at micturition, the patient experiences severe pain and a sensation as if something had given way in the perineum, followed by a feeling of relief. This, however, is of short duration, as it is soon succeeded by the local and constitutional effects of extravasation. Occasionally the onset of symptoms is more gradual, being preceded by a peri-urethral abscess, which bursts into the urethra; at each act of micturition the cavity becomes more and more distended with urine; finally the wall yields, resulting in diffuse extravasation. The same phenomena are produced in cases of traumatic laceration of the urethra if the patient attempts to empty his bladder.

The membranous urethra is almost always the site of the rupture, the urine finding its way subsequently through the anterior layer of the triangular ligament, and being guided towards the anterior abdominal wall by the arrangement of the fasciæ. The root of the penis, covered by its appropriate muscles, lies in an interfascial cul-de-sac, formed by the anterior layer of the triangular ligament above and the deep layer of the perineal fascia (or fascia of Colles) below; these two layers are continuous, passing round the transversus perinei muscles, and are both attached laterally to the ischio-pubic rami. Into this space the urine finds its way, after the anterior layer of the triangular ligament has yielded, and owing to the fact that its passage backwards and laterally is checked by the attachment of the fasciæ, it is necessarily forced forwards, infiltrating in order the perineum, scrotum, and body of the penis. If more extensive, it travels along the spermatic cords to the anterior abdominal parietes, its passage downwards into the

thighs being prevented by the attachment of the deep layer of the superficial fascia of the abdomen to the fascia lata just below Poupart's ligament. In the most severe cases the urine may even find its way as far as the axillæ.

The **Effects** of extravasation of urine following a stricture are always serious, inasmuch as it is almost certain to be foul and alkaline, and hence wherever it travels it gives rise to a grangrenous cellulitis. The parts at first become infiltrated and brawny, but soon necrosis of the cellular tissue occurs. The congested and œdematous skin turns to a dusky purple or black colour, and finally gives way or separates, allowing exit to a mixture of pus, urine, and decomposing slough of a most offensive and penetrating odour. The superficial loss of substance may be so extensive as to lay bare both testicles, and even the body of the penis, or part of the anterior abdominal wall. The inflammatory process is necessarily associated with severe constitutional disturbance, at first characterized by high fever and a quick, bounding pulse; but later on the temperature may become subnormal and the patient profoundly collapsed from toxæmia.

The **Treatment** consists in early and free incisions, so as to give exit to the urine and pus, and to prevent, if possible, the sloughing of the skin and subcutaneous tissues. Every part that the urine has infiltrated must be dealt with in this way, thus the perineum should be incised in the middle line, the scrotum is similarly divided, if need be, down to the urethra, the testicles being laid on either side, but, if possible, this should be avoided. The penis should be incised, when necessary, on either side of the urethra, and along the dorsal surface. It is often possible to expel a large portion of the urine, especially in the scrotum, by firmly squeezing the infiltrated tissues. A full-sized catheter must be passed into the bladder, and to effect this the urethra has often to be laid open and the stricture divided, perineal drainage is always preferable for these cases. The parts should be subsequently dressed with gauze soaked in flavine, eusol, or hypertonic saline solution. Frequent hip-baths may be employed, and a continuous sitz-bath is very valuable for a short time. As soon as the wounds become clean, they should be dressed in the ordinary way to allow them to granulate. The general health of the patient must of course be attended to, plenty of easily assimilated nourishment, stimulants, and quinine being administered.

Affections of the Penis.

Phimosis, when complete, is a condition in which the prepuce is so long, and the orifice so narrow, that it cannot be retracted behind the corona. It is usually **Congenital** in origin, and may exist to such a degree as to render micturition impossible. More frequently the opening is a very small one (pinhole prepuce), permitting micturition, but leading to irritability of the bladder from the obstruction. In such cases the prepuce is usually adherent to the glans, and considerable irritation is caused by the retention of the smegma secreted by Tyson's glands; this may collect and become so inspissated as to give rise to definite concretions. The child pulls at the foreskin, owing to the

itching produced, and thus a symptom of vesical calculus may be simulated. Attacks of balanitis are also frequent, and should the prepuce be withdrawn, paraphimosis is almost certain to follow. If allowed to remain untreated long enough, distension of the bladder, and even hydronephrosis, may supervene. This condition is often provocative of masturbation, and is certain to aggravate the symptoms of venereal disease; there is but little doubt that it acts as a predisposing cause to epithelioma of the penis. Phimosis also occurs as an **Acquired** condition, resulting from the cicatrization of venereal sores.

The **Treatment** of phimosis consists in circumcision. Other methods have been suggested, *e.g.* dilatation of the prepuce, and merely slitting it up, but they are not satisfactory.

Circumcision should always be performed on children with a long prepuce within the first year of life, since at that time the parts are but slightly developed, the operation is a trifling one, and but little inconvenience is subsequently experienced; the longer it is postponed, the more troublesome does it become. The best method of operating is as follows: The dorsal aspect of the prepuce is put on the stretch by grasping it on either side of the median line with a pair of catch forceps; a director is then introduced between it and the glans, and held exactly in the middle line, and the prepuce slit up with a curved pointed bistoury or scissors. The lateral halves are now separated from the glans, adhesions, if necessary, being broken down, so as to enable all retained smegma to be removed, and the corona glandis defined. The redundant preputial tissue, both skin and mucous membrane, is cut away on each side by scissors, special attention being directed to the removal of sufficient tissue on the under side to prevent the unsightly projection so liable to follow. In adults several arteries will require to be ligatured, especially that in the frænum, but in a child the hæmorrhage is trifling. Having carefully trimmed up the edges and snipped off ragged corners, so as to render the margins of the wound regular, catgut sutures are inserted to prevent any raw surface being left exposed; in children only a few are required, but possibly a considerable number in adults; a continuous suture should never be employed. The wound is dressed with strips of gauze, and around this a wisp of sterile wool, retained in adults by a narrow bandage. Considerable after-trouble is sometimes experienced from nocturnal erections, which may be so marked and prolonged as to tear through the stitches; to control this the patient's bowels should be freely opened, and he should be kept on a low and unstimulating diet, and bromide of potassium or other sedatives administered. The stitches are usually removed at the end of five days, and the parts are then dusted over with a mixture of powdered boric acid, zinc oxide, and starch, so as to reduce their sensitiveness.

When a phimosed prepuce is completely retracted, the patient often finds it impossible to replace it, thus giving rise to a condition known as **Paraphimosis.** It is due to the narrow orifice of the prepuce getting behind the corona, and is characterized by great œdema and congestion, not only of the exposed mucous membrane, but also of the glans itself. If left untreated, ulceration takes place along the line of constriction,

and the parts become fixed in their deformed position, the vessels sooner or later accommodating themselves to the new conditions, and the œdema slowly disappearing. In some cases sloughing of the glans may occur.

Treatment consists in forcible replacement of the prepuce. This is accomplished by grasping the penis between the first and second fingers of each hand, and compressing the glans penis with the thumbs so as to empty the vessels and diminish the amount of œdema present, and thus reduce its size (Fig. 981). At the same time the fingers draw the prepuce forwards, and thus finally reposition is effected. When the œdema of the prepuce is very marked, it should be punctured in several places to permit the escape of serum and diminish the tension, previous to reduction as just described. In more advanced cases reposition becomes impossible, and then the narrow constricting band caused by the orifice of the prepuce must be divided on the dorsal aspect. This will free the parts, which can be subsequently drawn forwards, and after the œdema has been reduced by applying lotio plumbi for a few days, circumcision may be advantageously undertaken.

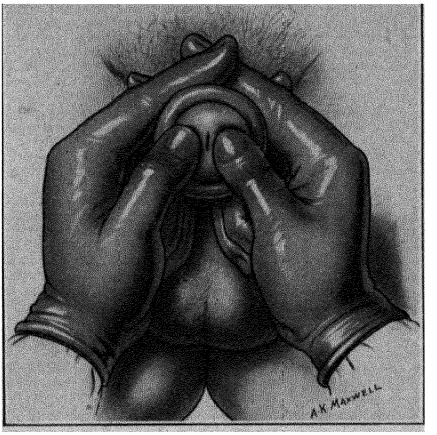

FIG 981.—REDUCTION OF PARAPHIMOSIS

Balanitis, or inflammation of the glans, may be simple in nature, arising from want of cleanliness in a person with a long foreskin, but is more frequently associated with gonorrhœa or soft chancres. The under-surface of the prepuce is often involved, and then the term **Balanoposthitis** is sometimes applied to it. A purulent discharge escapes from under the prepuce, which is often swollen and œdematous. Occasionally, when a considerable degree of phimosis exists, the under-surface of the prepuce may become ulcerated, and even perforated, allowing the glans to protrude through its upper surface.

Treatment.—In simple cases, all that is required is to cleanse the parts thoroughly by washing beneath the foreskin, and then to apply lead lotion on lint between the glans and the prepuce; but when there is much discharge, and the foreskin is long and swollen, or if perforation is threatening, the prepuce must be slit up, and after the parts have been restored to a healthy state the redundant tissues should be cut away by a modified circumcision.

For **Soft Chancre** and **Syphilis,** see pp. 142 and 148.

Herpes not uncommonly affects the prepuce and glans. It may result

from simple local irritation, more especially in gouty individuals, but is most frequently seen in patients who have suffered from syphilis, and is then likely to be somewhat intractable. It manifests itself as a crop of small vesicles on a hyperæmic base, which become abraded, leaving a number of small ulcers. It is preceded by neuralgic pain, and accompanied by much itching and irritation. The only treatment required is to keep the parts clean and dust them over with powdered oxide of zinc and starch. In the majority of cases the disease lasts from a week to ten days.

Warts (Fig. 982) often arise on the penis in the shape of red, vascular excrescences, usually pedunculated, and sometimes of considerable size. They are met with most frequently as a sequela of gonorrhœa, and must be carefully distinguished from mucous tubercles. They should be treated by snipping away with scissors, and cauterizing the base with a galvano-cautery. The X-rays are also useful in their removal when very extensive.

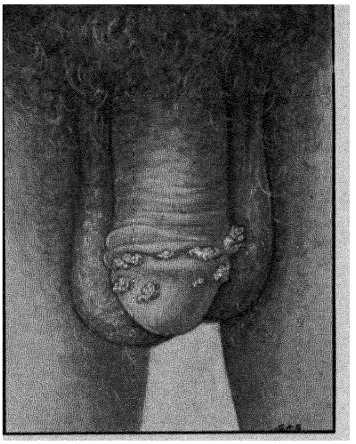

FIG. 982.—GONORRHŒAL WARTS

Horns are also occasionally seen arising from the body of the penis. They are of the usual sebaceous type, as described at p. 454, and should be excised.

Epithelioma of the penis rarely arises except in patients who are the subjects of congenital phimosis or possess long foreskins, and hence is said to be unknown amongst the Jews. It usually commences in the sulcus behind the corona glandis, and rapidly spreads to the surrounding parts, manifesting itself either as an irregular, papillated, wart-like outgrowth, or as a diffuse infiltration, ulcerating early, and leading to considerable destruction of tissue (Fig. 983). At first the prepuce becomes distended, producing a sanious discharge which contains epithelial cells as well as pus corpuscles, but later on both the prepuce and the body of the penis are invaded, and, owing to its great vascularity, the disease makes rapid progress. The inguinal glands are early affected, but when the body of the penis is involved the lumbar glands are also implicated

Treatment consists in amputation of the penis whenever the disease is sufficiently limited to lead to the hope that it can be eradicated. When confined to the distal end of the organ, the operation may possibly be performed through the body, but it is much more logical and more in accord with modern scientific dicta to remove the whole organ. The lymphatic field connected with the penis ought also to be cleared, as in any other case of cancer. This is not difficult to effect as regards the inguinal glands, but is impossible as regards the pelvic

or lumbar glands. Oblique incisions are made in either groin, and through these the glands, together with the vessels and fat surrounding them, are gathered up and turned down and in towards the root of the penis, where, if the amputation is to be total, they can be taken away together with the body of the penis in one portion, without division of the lymphatic trunks. Unfortunately, lymphatic œdema of the legs may develop after this procedure if it be thorough.

During the last few years radium has been used in the treatment of carcinoma of the penis, and has given excellent results. Suprapubic cystostomy is required before radium can be used. The primary growth in the penis is surrounded by small radium needles, which are left *in situ* for eight to ten days, the dosage being about 2,000 mg.-hours. The inguinal glands are treated by Columbia paste plaques, each containing about 30 mg. of radium. These plaques are applied to the groins eighteen hours each day for a period of twenty days, the dosage aimed at being 14,000 mg.-hours The suprapubic cystostomy is allowed to heal after the radium treatment is completed.

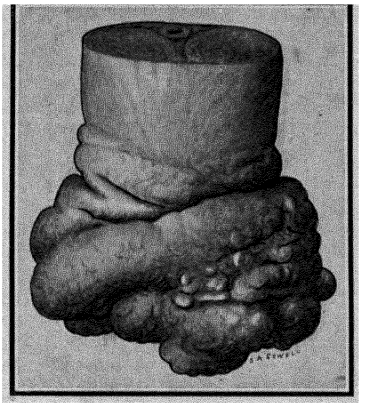

FIG 983.—EPITHELIOMA OF PENIS. (KING'S COLLEGE HOSPITAL MUSEUM.)

Amputation through the body of the penis is an operation of but little difficulty. The skin around the organ is divided by a circular incision, and retracted a little. The corpora cavernosa are then cut through, and the corpus spongiosum divided half an inch lower down. Bleeding is arrested by securing the divided vessels; five ligatures are usually required, *viz.* one for the artery to each corpus cavernosum, one for each dorsal artery, and one for the artery to the septum. The fibrous sheaths of the corpora cavernosa are then overstitched, so as to close the vascular spaces, and the urethra split on its inferior aspect for about a centimetre. The skin on the underside of the penis is similarly incised in a longitudinal fashion, and the urethral mucous membrane is stitched to it. The remainder of the incision is closed in the usual way.

Amputation of the whole penis is a more serious operation. The patient is placed in the lithotomy position, and the perineum, after being shaved and purified, incised freely in the middle line. The corpus spongiosum is traced backwards, and divided at such a level as to allow the mucous membrane lining the proximal portion of the urethra to be stitched to the skin at the posterior angle of the incision. The corpora cavernosa are freed from their connections, and separated at their origins from the ischio-pubic rami by the knife or suitable raspatories. An elliptical incision is then made round the root

of the penis, the dorsal vessels are divided and secured, and the suspensory ligament cut through. The penis can then be drawn forwards, and by a few final touches of the knife completely removed. All bleeding-points are ligatured, and the anterior wound closed by a continuous suture in the middle line, a drainage-tube being placed in the perineal portion for a few days. The results of this operation have, on the whole, been very satisfactory, and by the use of a suitable contrivance the patient need not assume the sitting posture in order to micturate. He will require to carry about with him a small metal funnel, bevelled to fit the perineum, and with a spout directed forwards. An excellent one was extemporized by a patient from the rose of a watering-can, the perforated top having been removed and the edges smoothed and bevelled.

CHAPTER XLIV.

AFFECTIONS OF THE TESTIS, CORD, SCROTUM, AND SEMINAL VESICLES.

Congenital Affections of the Testis.—It is scarcely necessary to state that the testicles are not developed in the scrotum, but from the posterior wall of the abdominal cavity, so that they lie at first behind the peritoneum close to the kidneys. The body of the gland arises from the so-called genital ridge, which is covered by columnar epithelial cells, and lies to the mesial side of the Wolffian body. The vasa efferentia are developed from the tubules of the latter structure, coming into relation at a later date with the seminal tubules; the vas deferens is formed by the Wolffian duct.

Occasionally the body of the testis is entirely absent, and a few cases are on record of absence or deficiency of the vas. Very rarely two testicles have been developed on one side, and have both found their way into the scrotum (*polyorchism*).

The passage of the testis from the abdominal cavity to the scrotum takes place at about the end of the eighth month of intra-uterine life. The gubernaculum testis assists in this process, but whether its function is to direct or to effect the descent is still somewhat doubtful. It consists of a band of involuntary muscular fibres which traverses the inguinal canal, and is attached above to the posterior peritoneal wall of the abdomen and possibly to the testis, and below to the abdominal wall, to the pubis, and to the bottom of the scrotum. The gubernaculum is supposed to exert traction on the testis and peritoneum, thereby determining the formation of the tunica vaginalis in the first place, and the descent of the testis slightly later.

Two chief forms of malposition of the testis are described, arising either from its incomplete or abnormal descent.

1. **Incomplete Descent or Retention of the Testis.**—The testis may remain in the abdominal cavity attached to the abdominal wall by a mesorchium (*retentio abdominalis*); more frequently it is found just within the internal abdominal ring (*retentio iliaca*); but most commonly it occupies the inguinal canal, or lies just outside of it (*retentio inguinalis*). The organ in the latter position is freely mobile, being readily pressed up towards the abdominal cavity. The cause of this condition must be looked for in some defective action of the gubernaculum. It is easily recognized by the absence of the testicle in the scrotum, and in the inguinal variety the organ can usually be detected as a small movable swelling about the size of a horse-bean. The scrotum on the affected side is imperfectly developed. In any of these varieties a late descent of the testis may occur, usually accompanied by a congenital hernia, possibly of an interstitial type.

2. **Malposition of the Testis.**—Two chief forms are described: (*a*) *Ectopia Perinealis.*—In this variety the testis finds its way into the perineum, slipping along the groove between the thigh and the scrotum. It may exist as a congenital condition, or may follow a late descent of the testicle, and always causes considerable inconvenience to the patient, especially on sitting or riding. (*b*) *Ectopia Cruralis.*—The testicle here lies on the inner side of Scarpa's triangle, in the region of the saphenous opening. It is said to escape along the crural canal, but more probably it passes down the inguinal canal as usual, and then finds its way over Poupart's ligament to this situation. When, as not uncommonly happens, a congenital hernia also exists, it may travel outwards to the anterior superior spine, being directed there by the arrangement of the fasciæ, as in a femoral hernia (extra-parietal interstitial hernia, p. 1342).

In cases of retained or misplaced testis the spermatogenic function of the organ is rarely developed, or at most merely for a year or two about the age of twenty. Pain is not unfrequently complained of, coming on in attacks which last for a short time and then disappear, probably due to slight injuries or torsion. Fibrosis of the testis follows in time, and total degeneration is the ultimate outcome. If only one organ is affected, but little harm follows; but if both are involved, the individual is probably sterile.

Complications of a Retained or Misplaced Testicle.—Any of the conditions to be described hereafter in this chapter may involve a retained or misplaced testicle, just as if it were in the scrotum, and give rise to considerable trouble, especially when the organ is lying in close proximity to the peritoneum. A testis misplaced or retained in the inguinal canal is much exposed to injury, and a subacute traumatic orchitis often occurs. It is stated that such organs are very prone to become the seat of malignant disease at a later period of life.

Treatment.—Most promising results are obtained by either endocrine or surgical measures between the ages of six and twelve, rather than leaving the patient to attain the age of puberty in the hopes that some further descent may occur. Endocrine treatment consists of giving injections of Pregnyl or some allied substance, which undoubtedly does encourage descent in about one-third of the cases. The usual dose is about 500 rat units given intramuscularly. It is said that in some cases this treatment tends to produce premature and precocious development. Injections are given twice weekly up to a dozen.

Operation—Orchidopexy.—The principle of all operations for orchidopexy is firstly to elongate the cord without damage to the spermatic vessels, by dividing fibrous and muscular bands and by straightening its tortuous path. The fixation of the testis to the bottom of the scrotum may be done by one of three methods.

Ombredanne's operation consists in making a small incision in the scrotal septum and passing the testis through to the opposite scrotal compartment.

Torek's operation consists of fixing the testis to the fascia lata of the thigh and sewing the skin of the scrotum to the edges of this

wound, which is separated by a second operation some three or four months later.

Thirdly, maintenance of the testicle in the scrotum by means of a twisted silver wire splint fixed above to the periosteum of the pubis and stitched to the tunica albuginea at the bottom end. This splint is removed in about fourteen days by making a small cut over its projecting lower end.

In any of these three operations the important part is care in dividing the coverings of the cord, paying particular attention to the spermatic vessels, and in cases of bilateral maldescent only one side should be done at a time.

Orchidectomy.—If the one testicle is fully descended into its scrotal compartment and at operation on the maldescended side difficulty is experienced in obtaining sufficient length of spermatic cord to allow reposition in the scrotum, orchidectomy would seem indicated, as sufficient internal and external secretion would be available from the healthy side.

In all these operations attention must be paid to any hernial sac which is frequently present, which must be dissected off the cord and its neck transfixed and tied off in the usual way.

Another condition met with congenitally is **Inversion** of the testis, the epididymis lying in front, and the body of the organ behind. It is of no clinical significance, except that in careless hands the testis may be injured in tapping a hydrocele.

Torsion of the Spermatic Cord results in acute strangulation of the testis. The cause still remains unknown, but several of the cases recorded have been associated with late descent of the testicle, and others have been attributed to twists and strains. The symptoms are tolerably characteristic: the patient complains of an acute sickening pain in the testis which persists until gangrene has supervened, and may then disappear; it is accompanied by a certain amount of pyrexia, and the appearance of a tumour, either in the inguinal region or in the scrotum. The testicle, slightly enlarged, is felt below, and above it a larger mass, consisting of the twisted cord and the congested and swollen epididymis. In some cases the latter swelling has been crepitant, owing to the development of gases due to its putrefaction. The condition is very likely to be mistaken for a strangulated hernia, which it closely resembles; but the presence of fever and the absence of abdominal distension and of fæcal vomiting are important distinctive signs; moreover, constipation, though often present, is never absolute. If the testis is situated in the scrotum, the cord and inguinal canal are found to be clear; but if in the canal, the affected side of the scrotum is empty. The only **Treatment** possible is exploration and removal of the inflamed or gangrenous testis and cord, unless the case is seen very early, when it may be feasible to untwist it.

Injuries of the Testis and Cord.—Contusion is a very common form of injury. It arises from blows, kicks, squeezes, and the like, and is always associated with immediate pain of a most sickening and intense character, which is not only experienced in the testicle, but also radiates along the cord towards the loins and back, and down the front of the

thigh. Severe shock accompanies the pain, and may be so profound as to lead to a fatal issue. A well-marked traumatic orchitis often follows, and this may in turn cause atrophy of the organ, although the same condition sometimes occurs without much evidence of inflammation as a result of thrombosis and occlusion of the spermatic vessels. A hæmatocele is also induced by a subcutaneous lesion of this nature. **Treatment** consists in keeping the patient in the recumbent posture with the scrotum well raised, and in applying fomentations or an icebag.

Penetrating Wounds or **Punctures** are uncommon except as a result of surgical treatment, *e.g.* tapping a hydrocele. A certain amount of hæmorrhage usually follows, whilst the immediate lesion is associated with severe testicular pain. If the wound becomes infected, the tubules are likely to protrude, and a hernia testis may result. All that is ordinarily required is to purify the parts and allow them to heal, sutures should not be inserted into the tunica albuginea if there is any doubt as to the wound being sterile. If the gland is totally disorganized, castration must be undertaken.

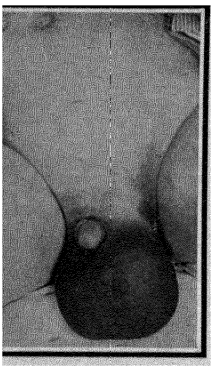

FIG 984.—HÆMATOCELE OF LEFT TUNICA VAGINALIS

Hæmatocele, or a localized collection of blood in the tunica vaginalis or cord, is a common result of injuries.

1. **Hæmatocele of the Tunica Vaginalis** arises from traumatism, such as a sudden blow or severe strain, and occasionally follows the tapping of a hydrocele if a superficial vessel has been ruptured or punctured, or if the body of the testis has been wounded; it may, however, be due to general oozing from dilated capillaries in the serous membrane owing to the sudden relief of tension. It also occurs more or less spontaneously in connection with malignant disease. The **History** generally given is that the patient was seized with a sudden sickening pain in the testicle, which became quickly enlarged without any evidence of inflammation; blood was extravasated at the same time into the scrotum, the integument becoming discoloured in a few days (Fig. 984). At first the swelling is smooth and fluctuating, exactly resembling a hydrocele, except in the absence of translucency; but owing to a deposit of fibrin on the walls, it soon becomes hard and firm, closely simulating a solid tumour. In slight cases the blood is entirely absorbed, but when the effusion is considerable the coagulum is likely to persist. On laying open such a swelling, the testicle is usually found in a healthy state, but the enlarged tunica is occupied by blood-stained fluid, surrounded by a mass of fibrinous coagulum, part of which is deposited in laminæ upon the walls, and part remains as shreddy masses projecting into its lumen. In very chronic cases the walls of the tunica become thick and indurated, and may even undergo calcareous changes. Suppuration is sometimes met with as a result of auto-infection. The

Diagnosis of a hæmatocele in the earlier stages is easily made; but when it has solidified it can only be suspected by the history, and by the exclusion of other sources of enlargement; an exploratory incision or puncture is often necessary to settle the diagnosis. **Treatment.**—When the patient is seen soon after the injury, he must be kept at rest, the parts elevated, and evaporating lotions applied, if the effusion is large, removal of a portion by aseptic tapping is helpful. In more chronic cases it may be necessary to lay the cavity open and remove its contents; but if the tunica has become thick and indurated, and the testis atrophied, castration may be advisable.

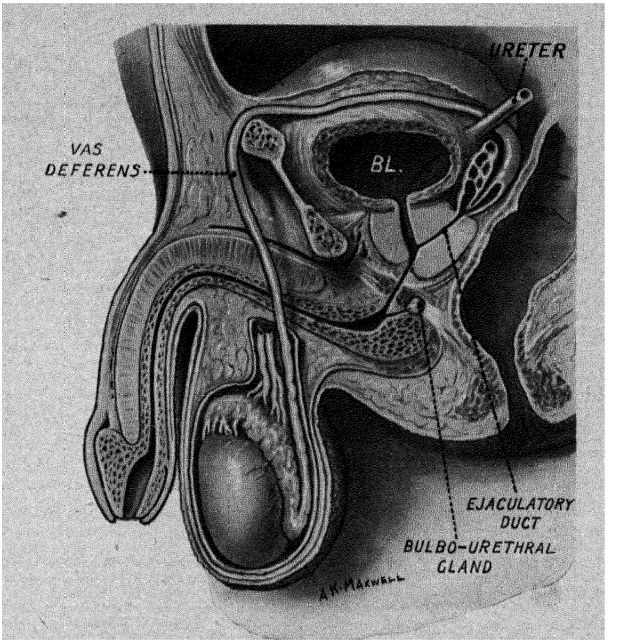

FIG 985.—THE ANATOMICAL COURSE OF THE VAS DEFERENS

2. **Hæmatocele of the Cord** is rarely seen. A swelling of considerable size rapidly forms, extending along the cord from the inguinal region to the scrotum, but the testis remains free and unimplicated. Such a condition may be mistaken for an omental hernia, but the tumour is more uniform in consistency, more rounded in outline, irreducible and without impulse; the history of an injury will assist the surgeon in making a correct diagnosis. **Treatment** in the early stages consists in the application of evaporating lotions, and later on, if the blood-clot is not absorbed, the cavity may be laid open and the coagulum removed.

Rupture of the Vas Deferens has resulted from sudden strain, but is a very rare accident. It may affect the intra-abdominal portion of the vas, and then gives rise to hæmorrhage from the urethra, together with some amount of fever and hypogastric pain, leading possibly to atrophy of the organ. Rupture of the extra-abdominal portion is followed by enlargement of the testis and perhaps scrotal hæmorrhage (Fig. 985). This was associated in a case under our observation with hæmorrhage from the urethra on attempting coitus shortly after the accident, and subsequently with severe pain and swelling of the testis produced by the same act, but atrophy did not follow. Attempts have been made to restore the continuity of a ruptured vas, but without much success; if this fails, and the condition occasions inconvenience, it is best treated by castration.

Inflammatory Affections of the Testis may be chiefly confined at their onset either to the body of the organ or to the epididymis; in the former case the term **Orchitis** is applied to it, in the latter **Epididymitis**; as the case progresses both portions are involved in the process; either condition may be acute or chronic.

Acute Orchitis most frequently results from injury, but it is also met with as a primary affection in gouty and rheumatic individuals, sometimes arising spontaneously; or it may follow mumps, typhoid, or other eruptive fevers, and it is always to some extent associated with epididymitis. In mumps it may precede the parotid lesion, or may even occur without it.

The testicle becomes considerably enlarged, exceedingly painful, and tender to the touch. The shape of the organ is more or less globular (Fig. 986), and the pain is of a peculiarly sickening character, extending upwards along the course of the cord towards the back and loins. The scrotal integuments become red and infiltrated, and, owing to the acuteness of the process, more or less adherent to the coverings of the gland. A plastic or serous effusion into the tunica vaginalis is sometimes present, giving rise to what is known as an 'acute hydrocele.' Some constitutional disturbance accompanies the process, the temperature being elevated two or three degrees, and vomiting and constipation are marked symptoms. It is unusual for suppuration to ensue, but an abscess occasionally forms, and then, after the pus has been let out, a hernia testis may follow. Atrophy is a more common sequela, especially in adults, being caused by constriction of the vessels and tubules, owing to organization of the inflammatory exudate.

Acute Epididymitis is almost always due to the extension of an inflammatory process from the urethra, the usual cause being gonorrhœa; it occasionally follows the passage of instruments or the lodgment of a calculus; or it may be secondary to affections of the prostate if pyococci are present. It is ushered in by pain in the inguinal region and perhaps in the hypogastrium along the course of the vas deferens, which soon extends to the scrotum. The testicle becomes enlarged, but its shape is that of an elongated oval, somewhat flattened laterally. The epididymis is readily felt as a crescentic swelling, partially overlapping the gland in all directions, and in its concavity the rounded outline of the anterior wall of the testis can usually be distinguished

(Fig. 986), or the tunica vaginalis distended with fluid. The scrotum is red, œdematous, and adherent to the testis, and the cord is infiltrated, enlarged, and tender. The same constitutional symptoms are met with as in orchitis. Suppuration is perhaps more common than after the latter affection, since the condition is usually due to a suppurating inflammation of the deeper parts of the urethra; but it is a rare complication. Atrophy of the testis is a not infrequent result in cases which are not efficiently treated, the plastic material exuded into the epididymis being organized into fibro-cicatricial tissue, and constricting the spermatic vessels; an acute attack of double epididymitis may in this way render the individual sterile.

The **Treatment** of both these conditions in the acute stage consists in keeping the patient in bed, with the scrotum supported on a small pillow. The part is assiduously fomented, except when the case is seen very early, and then an icebag or Leiter's coil is employed. Pain,

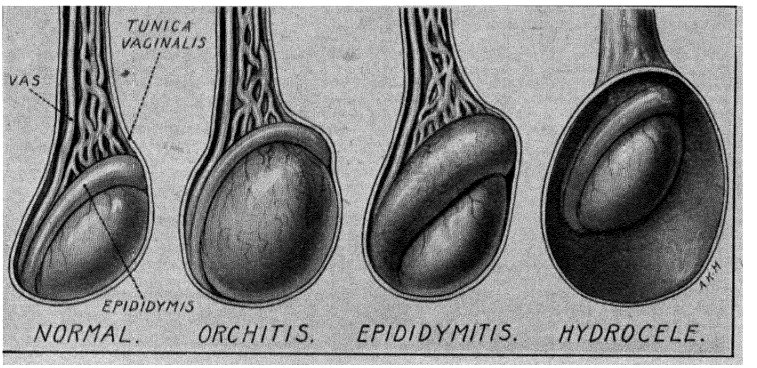

FIG 986.—DIAGRAMMATIC SECTIONS OF THE TESTICLE DEMONSTRATING VARIOUS PATHOLOGICAL CONDITIONS

if severe, may be mitigated by a hot sitz-bath, or by morphia suppositories. As regards general treatment, the patient, after a preliminary dose of calomel, is kept on a fluid, unstimulating diet, and alkaline purgatives are administered, with the addition of tincture of henbane or opium as a sedative; if the pulse is hard and the temperature high, vinum antimonialis in 10-minim doses is also beneficial. When the acute stage is passed, the organ usually remains enlarged, and for a time somewhat tender, it is then best treated by strapping with lead plaster, or with the emplastrum ammoniaci cum hydrargyro. This must be continued until all signs of thickening and induration have disappeared.

Subacute or **chronic** forms of inflammation are also met with affecting the testis or epididymis, either as a consequence of the above, or resulting primarily from blows or strains. The characteristic enlargement is readily detected, associated with a certain amount of tenderness. A useful diagnostic point between the chronic epididymitis

following gonorrhœa and that due to syphilis is that the former usually involves the globus minor, and the latter is almost limited to the globus major. The condition is best treated by strapping, and perhaps the administration of small doses of mercury and iodides may assist in the absorption of the inflammatory products. Chronic orchitis is very similar to the enlargement produced by syphilis, from which, indeed, it can only be distinguished by the Wassermann reaction being negative and the absence of a syphilitic history.

Tuberculous Disease of the Testis.—This affection is most commonly seen in young adults with a distinct tuberculous history, but it also occurs in otherwise healthy individuals. It may commence as a primary affection of the epididymis, or may be secondary to tuberculous disease elsewhere.

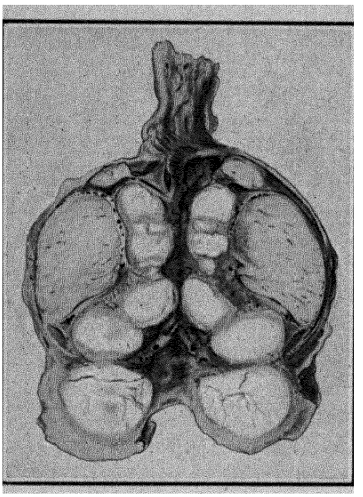

FIG 987.—TUBERCULOUS DISEASE OF TESTIS, MAINLY INVOLVING THE EPIDIDYMIS AND CORD (KING'S COLLEGE HOSPITAL MUSEUM)

Pathological Anatomy.—The process originates in the connective tissue of the epididymis, and runs its usual course, at first consisting merely of a deposit of miliary elements around the vessels, which by their coalescence and caseation lead to the formation of cheesy masses, and these at a later stage may emulsify and give rise to abscesses. It may be limited to any one part of the epididymis (most often the globus major), or may widely infiltrate its substance, causing a general enlargement (Fig. 987). In the latter case it early tends to spread, either into the body of the testis or along the vas deferens. The corpus Highmorianum becomes first involved by a similar deposit, and finally the intertubular connective tissue of the gland; this is always associated with overgrowth of the epithelium in the tubuli seminiferi, the cells after a time undergoing fatty degeneration, and perhaps to such an extent that, on microscopic section, the normal appearance of the organ has entirely disappeared. An abscess may form within it, and find its way to the surface by burrowing through the tunica albuginea, the visceral and parietal layers of the tunica vaginalis having previously become adherent. After the pus has escaped, a hernia testis is likely to develop. When the process extends upwards along the cord, the vas is mainly implicated, becoming perceptibly thickened, the other structures of the cord being but little affected. The disease spreads along the vas on the outside of the bladder to the vesiculæ seminales and prostate, and may even involve the base of the bladder, the ureters, and

kidneys. Lastly, general dissemination of tuberculous disease may occur, and it is a curious fact that meningeal mischief is not very uncommonly associated with genital tuberculosis.

Clinical Signs.—The disease is generally unilateral, although the other testicle often becomes involved at a somewhat later date. Its onset may be abrupt or gradual; in the former case the attack simulates an acute orchitis, but at the end of a few weeks, although the pain subsides, the swelling persists, being followed by the development of abscesses containing cheesy pus. In the more chronic cases, one or more firm and indurated nodules, which are free from tenderness, are felt in the epididymis, but more often the whole of this structure is found to be enlarged and thickened, forming a painless crescentic swelling, surrounding the posterior half of the body of the testis, from which it is usually separated by a deep groove or sulcus. The epididymis is nodular and craggy to the feel, and may be of unequal consistency, areas of softening being interposed between portions which are distinctly hard. The vas is early thickened, whilst the other structures of the cord are but little involved; the thickening is more or less nodular, and almost beaded in its consistency. The body of the testis may be involved and enlarged, the line of demarcation between it and the epididymis becoming indistinct. Testicular sensation remains as long as any normal glandular tissue exists, and effusion into the tunica vaginalis is not usual. When suppuration occurs, the pain increases, especially if the abscess is in the substance of the organ. As it finds its way to the surface, the skin becomes adherent to the testis, and is red and congested. Gradually fluctuation manifests itself, and the escape of the pus may be followed by a hernia testis. An abscess forming in connection with the epididymis is less painful, and may attain considerable dimensions before it bursts; it never gives rise to a hernia testis. Extension of the disease to the seminal vesicles causes no characteristic symptoms, and is only detected on rectal examination; when, however, the base of the bladder and prostate are affected, considerable dysuria and irritability of the bladder are induced.

The differential diagnosis is discussed at p. 1546.

Treatment.—If seen in the early stage, when the disease is limited, it is possible that sanatorium treatment will suffice, but if the lesion is at all extensive, operative measures should be undertaken.

When the whole epididymis is enlarged and solid, and the body of the testis more or less normal, *epididymectomy* will usually suffice. In this procedure the tuberculous mass is freed from the body of the organ, the spermatic vessels lying on the inner side are carefully guarded, and the vas is dissected out and cleared as high as possible. The presence of an abscess or sinus is no contra-indication, since it merely involves a somewhat freer removal of scrotal integument. Should foci exist in the body of the testis, they are likely to atrophy subsequently, or they can be scraped out at a later date. In this way the internal secretory function of the gland can be retained, although its use as a generative organ is lost—a retention the more important owing to the likelihood of the other testis being subsequently invaded. Even

if the vas is thickened at the external abdominal ring or the vesiculæ enlarged, it need not deter the surgeon from operating, since Nature will often deal effectively with what is left, if accessible portions are removed.

Castration is reserved for cases where the testis is disorganized, and its value as a secreting gland totally destroyed. Of course, the cord is also removed after division as high up as possible. Surgeons who believe that the epididymis infection is secondary to that of the seminal vesicle remove the epididymis, vas, and seminal vesicle through an inguinal incision, the approach to the last-named being extraperitoneal.

Syphilitic Disease of the Testicle.—The testicle may become affected either in the late secondary or in the tertiary stage; most commonly it results from the acquired variety, but occasionally is met with in the inherited.



FIG 988.—GUMMA OF TESTIS (COLLEGE OF SURGEONS MUSEUM)

Secondary Syphilitic Epididymitis is unusual. It occurs as a chronic enlargement of the epididymis, associated perhaps with a hydrocele, about six to twelve months after infection. The case is very similar to a simple chronic epididymitis, but the nodular thickening mainly involves the globus major, and is usually symmetrical. It quickly disappears on the commencement of treatment.

Tertiary Syphilitic Orchitis is observed at a much later period of the disease, even twenty or thirty years after infection. It is not unfrequently bilateral. **Pathologically,** it resembles the majority of tertiary manifestations in consisting of a diffuse infiltration accompanied by overgrowth of the connective tissue. If the process affects equally the whole organ, the ordinary syphilitic sarcocele or sclerosis of the testis results; if it is more localized in its distribution, the gummatous variety is said to be present (Fig. 988). The former affection is much more common than the latter.

In the tertiary syphilitic sarcocele the body of the testis is primarily involved, and becomes evenly enlarged and stony hard. It is globular in outline, frequently accompanied by a hydrocele, and the normal testicular sensation early disappears. The same process occasionally extends to the epididymis and cord. Suppuration is exceedingly rare. On section the characteristic appearance of a testicle has entirely vanished; the tunica albuginea is much thickened, and extending from it through the substance of the organ are bands of connective tissue representing the normal septa, in bad cases the gland substance is almost completely destroyed.

In the *gummatous* variety a similar condition involves the greater part of the organ, but in addition one or more gummatous foci are present. On section they appear as yellowish-white masses, fairly

well defined, and since the central portions are non-vascular, they undergo the usual degenerative changes, becoming soft and diffluent. If the gumma comes to the surface the skin may give way, and a deep syphilitic ulcer with a sloughy base like wet wash-leather results. Hernia testis very rarely follows such an occurrence. The clinical features of the gummatous variety are at first similar to those of the former, but after a time one portion of the organ becomes prominent and painful, and as this increases in size the central parts become soft and fluctuating, and finally yield, giving exit to the characteristic gummy contents. Under suitable treatment the swelling in each of these varieties may disappear entirely, leaving the testicle either of normal size or atrophied; but, as in tuberculous disease, its functional utility, if not entirely destroyed, is probably impaired considerably.

For the differential diagnosis, see p. 1546.

Treatment consists in the administration of iodide of potassium and mercury, whilst the hydrocele may be tapped, and the organ strapped or supported by a suspensory bandage. If a gummatous ulcer is produced, it may be possible to excise the greater portion of the characteristic slough at its base; but in all cases it should be dressed with lint or gauze steeped in lotio nigra or some other mercurial preparation. A strongly positive Wassermann reaction may justify treatment by salvarsan, but when the affection is of old standing, mercury must be employed.

Hernia Testis is the term applied to a protrusion of the substance of the gland, more or less infiltrated with granulation tissue, through an opening in the tunica albuginea and skin of the scrotum. It arises from various causes, such as a septic penetrating wound of the testis, acute suppurative orchitis, or from a chronic abscess, whether simple or tuberculous in nature. It is rarely produced by the breaking down of a gumma, owing to the extensive infiltration of the organ with fibro-cicatricial tissue, and necessarily it is never caused by suppuration in the epididymis. It is always preceded by a condition of increased pressure within the tunica albuginea, and consequently as soon as an aperture is formed in this membrane, its natural elasticity, allowing of its contraction, forces a portion of its contents out of the opening, this may even proceed to such an extent as to cause the whole of the substance of the gland to protrude, the tunica albuginea being practically turned inside out. A mass resembling granulation tissue is then seen to project through an opening in the scrotum; it is often somewhat pedunculated or mushroom-like in shape, possibly overhanging the margins of the skin. A considerable discharge of pus usually accompanies it. The condition must be distinguished from the fungating growth which occasionally results from malignant disease of the organ, when the protrusion consists of tumour substance, with no trace of testicular tissue.

The **Treatment** of hernia testis usually consists in extirpation of the organ, especially when it is affected by tuberculous disease. In simple cases healing of the wound may be obtained by keeping the part aseptic, and applying pressure by means of a pad of gauze. In other cases it may be possible to separate the protruding mass from

he surrounding skin, and, after paring the edges of the wound, to ›ring them together by sutures, and thus bury the gland substance, vhich, however, remains projecting from the opening in the tunica ılbuginea. Such proceedings are seldom very satisfactory.

Tumours of the Testicle.—These are invariably malignant. Their ·lassification is various and of little use; actually from the surgical ›oint of view there are two types: the radio-sensitive (or semi-ıoma) and the radio-resistant (or embryoma), both are types of teratoma.

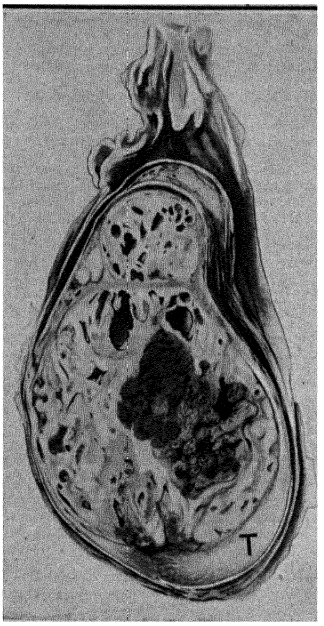

TESTICLE (EMBRYOMA TYPE)
There only remains a small portion of normal testis at the lower pole (T)

A teratoma producing a testicular dermoid is very rare.

Seminoma.—When the cut surface is inspected it presents a homogeneous appearance except for areas of degeneration which are common, there is some tendency to lobulation. At microscopy the cells are large with protoplasm and resemble the spermogenic cells.

Embryomas are somewhat slower in growth, but are less amenable to treatment, being radio-resistant. The cut surface of the growth varies in many cases, there may be numerous small cysts (fibro-cystic disease), areas of cartilage, and large cysts (Fig. 989). At microscopy, muscle may also be seen and gland structures, while the nature of the predominating cell may resemble a sarcoma or a carcinoma.

Clinical History.—These tumours appear between twenty-five and fifty years of age, a blow often attracting the patient's attention to the swelling; the part played by trauma as a cause is doubtful. Sometimes the testicle has gradually increased in size for two or three years and then rapid growth has ensued.

The glandular elements of the testicle are destroyed or compressed ıt the upper or lower poles of the swelling, and testicular sensation is ısually absent. The swelling feels heavy to the examining hand, but liagnosis from a hæmatocele may be impossible without exploration.

Dissemination occurs by the blood-stream with involvement of the ungs, and by the lymphatics of the lumbar glands, the spermatic cord ınd the abdomen must always be examined for lymphatic enlargement. 'f untreated, the overlying skin becomes adherent, ulceration and ungation soon following.

Treatment.—Orchidectomy with removal of the cord as far as the

internal abdominal ring remains still the least unsatisfactory treatment, as the distressing possibility of fungation is removed.

Deep X-ray therapy has some value in checking metastases in the lungs and abdominal glands, and this treatment should be combined with orchidectomy.

Radium is useless with the embryoma type, and although good local results are reported from its use with seminoma, the difficulty of satisfactorily irradiating the lymphatic area and lungs still remains.

Hydrocele.—Any collection of fluid, other than pus or blood, in the neighbourhood of the testis or cord is termed a hydrocele. The fluid usually consists of serum, but in some forms spermatozoa are also present, and in rare cases it may consist of chyle or a similar milky fluid (chylous hydrocele). Two chief varieties are described, according to whether the testis or the cord is involved.

I. In **Hydrocele of the Testis** the fluid is contained in the tunica vaginalis (vaginal hydrocele), or exists as a circumscribed swelling in its neighbourhood (encysted hydrocele).

1. A **Vaginal Hydrocele** is one in which there is an accumulation of fluid in the tunica vaginalis, and the following varieties may be differentiated:

(*a*) *Acute Hydrocele* occurs in coniunction with acute inflammation of the testis or epididymis. The effusion of fluid is never abundant, and is often only made out on careful examination; at first it consists of plasma, as in all acute inflammations of a serous membrane, and is therefore spontaneously coagulable. It may become chronic, or may disappear entirely, perhaps leaving a few adhesions.

(*b*) A *Congenital Hydrocele* occurs in cases in which the funicular process is still patent. The general signs of a vaginal hydrocele, as described below, are present, but the fluid can be returned by pressure into the abdominal cavity. It is rarely seen in others than infants, and may be treated by the application of evaporating lotion to the scrotum, whilst a light truss or woollen support is placed over the inguinal canal, as for congenital hernia; if it persists, it should be treated by operation.

(*c*) An *Infantile Hydrocele* is due to non-obliteration of the funicular process of peritoneum, except at its upper extremity. It presents the signs of an ordinary acquired hydrocele, the fluid, however, extending along the cord, even into the inguinal canal. Its treatment is the same as for an acquired hydrocele.

(*d*) A *Bilocular Hydrocele* is one in which there is an additional loculus within the abdominal cavity, communicating by a neck of variable size with the distended tunica vaginalis. It is due to a persistence of the intra-abdominal portion of the funicular process between the peritoneum and internal abdominal ring; this becomes distended with fluid, and burrows downwards in front and by the side of the bladder towards the pelvis. A similar condition occurs in the female, arising in the upper part of the canal of Nuck.

(*e*) *Acquired Vaginal Hydrocele* is the most common variety. **Causes.**—It may arise in middle-aged persons without any apparent cause, but is

usually associated with chronic orchitis. A hydrocele almost always accompanies a tertiary syphilitic enlargement of the organ, but is uncommon in tuberculous or malignant disease. The tunica is usually thickened and hyperæmic, and that covering the testis may be pitted and scarred. Here and there thick plaques of fibrous material are visible, which may sometimes become calcified, or even osseous.

Signs.—Vaginal hydrocele appears as a rounded pyriform swelling in the scrotum, which extends for a variable distance along the cord. Its tension differs with the amount of fluid present, and with the thickness of its walls; it is usually elastic, and with obvious fluctuation. The cord is felt distinctly above the rounded upper part of the tumour, and the testis is generally situated posteriorly, although it projects forwards into the cavity, and is thus not readily detected. On holding a light close to the scrotum the swelling is seen to be translucent, and the position of the testicle can also be demonstrated. In old-standing cases when the walls have become much thickened, translucency will be lost. Occasionally, when inflammation has existed, adhesions may form between the testis and the anterior wall, and irregularity in the shape of the swelling is thereby induced, or the cavity may be divided into compartments by fibrous bands or septa.

As a result of traumatism, subcutaneous rupture of a hydrocele has occurred, leading to increased swelling of the part, and perhaps œdema of scrotum and penis; the parts become bruised, but after a time the swelling diminishes, and perhaps a spontaneous cure follows.

It is scarcely necessary to mention that there is no impulse on coughing, and that the tumour is dull on percussion. When the distension is very great, its weight causes a dragging pain; the penis becomes buried in the swelling, and eczema of the scrotum may result from the urine trickling over it. The *fluid* in the sac is yellowish or straw-coloured; its specific gravity varies from 1015 to 1025, it contains a large amount of albumen, especially fibrinogen. In old-standing cases cholesterin may also be present.

The **Treatment** of vaginal hydrocele is palliative or radical. **Palliative** treatment consists in tapping the cavity and removing the fluid, the patient being subsequently directed to wear a suspensory bandage, and, where inflammation of the testis exists, to apply cooling lotions. For chronic orchitis strapping of the testis may be required.

In order *to tap a hydrocele*, the tumour must be firmly grasped in the palm of the left hand, and the skin over its anterior wall purified and made tense. A spot at the antero-inferior margin is then selected, as free from vessels as possible, and a fine sterilized trocar and cannula inserted almost directly upwards, so as to pass in front of the body of the testis (Fig. 990). The site selected for tapping must, of course, vary with the position of the testicle, which should be previously demonstrated. The fluid having been withdrawn, the cannula is removed and the puncture covered with wool and collodion. The condition usually recurs after a longer or shorter period, and the operation may then be repeated. If a dirty instrument is employed, inflammation, and even suppuration, may follow; if a blood-vessel or the body of the testis is punctured, a hæmatocele may result.

Radical treatment consists in injection of the cavity, or excision of the lining membrane. (I.) Injection has been revived, but is painful in the extreme, and the results are variable. Sodium morrhuate is the favourite reagent. (II.) *Open operation* is now generally adopted, and is particularly recommended in large and chronic cases. The hydrocele is cut down on through an incision in the upper part of the scrotum, and the tunica vaginalis isolated from the superjacent structures. The cavity is opened, and the parietal portion of the tunica snipped away with scissors close to the testicle. A number of vessels will need to be ligatured; a drainage-tube is inserted, and the wound closed in the ordinary way. The results of this practice are most satisfactory.



FIG. 990.—METHOD OF TAPPING A HYDROCELE



FIG 991.—ENCYSTED HYDROCELE OF EPIDIDYMIS (COLLEGE OF SURGEONS MUSEUM)

When the sac is not too large, and the tunica supple and uninfiltrated, it often suffices to turn it inside out, and stitch its edges to the back of the epididymis.

In infants hydrocele is by no means uncommon, and may be, but is not always, of the congenital type. The communication is sometimes very small, so that reduction is impracticable, although on lying up the cavity slowly empties; it is desirable to make certain as to this point before undertaking treatment. If the sac communicates with the peritoneal cavity, it may be treated as a hernia by truss pressure, or more satisfactorily by operation. If no communication exists, many cases get well spontaneously, but as a useful *placebo* the scrotum may

be painted over frequently with a lotion of chloride of ammonium (grs. x. ad ʒi. mixed with rectified spirit and water); in a few cases an open operation (incision with drainage or partial removal of the sac) will be required.

2. **Encysted Hydrocele** of the testis occurs in two main forms, according to whether it arises in connection with the epididymis or the body of the testis.

(*a*) *Encysted Hydrocele of the Epididymis* exists usually as a rounded globular swelling, tense and elastic in consistency, and translucent.

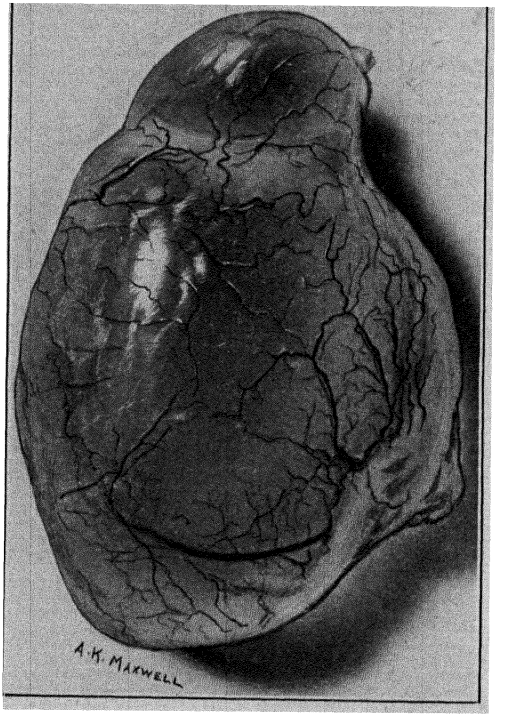

FIG. 992.—LARGE SPERMATOCELE REMOVED AT OPERATION

It is situated above the body of the testis, and close to the head of the epididymis (Fig. 991). As a rule, it does not attain a size greater than that of the body of the testis itself, so that it may appear as if a double testicle is present, the hydrocele is, of course, devoid of testicular sensation. Less frequently it may attain considerable dimensions, even projecting below and around the testicle, which, though enveloped by it, is quite distinct from it. The fluid contained within these cysts is usually milky and opalescent in appearance, owing to an admixture of

semen; under the microscope spermatozoa, either living or dead, can be demonstrated, on account of this it is sometimes termed a *spermatocele* (Fig. 992). The specific gravity is lower than that of ordinary hydrocele fluid, and there is but little albumen. The origin of these cysts has given rise to much discussion. They are of a very different nature from the ordinary vaginal hydrocele, or even from the encysted hydrocele of the cord, since the walls are not lined with endothelium, but with cuboidal or columnar epithelium. They are probably due either to a dilatation of one or more of the vasa efferentia testis, or more frequently to distension of some of the fœtal relics always found near the head of the epididymis, especially of those known as Kobelt's tubes (Fig. 93, p. 228). Smaller pedunculated cysts containing clear serum are sometimes met with in this region, arising from a distension of the hydatid of Morgagni (Fig. 993).

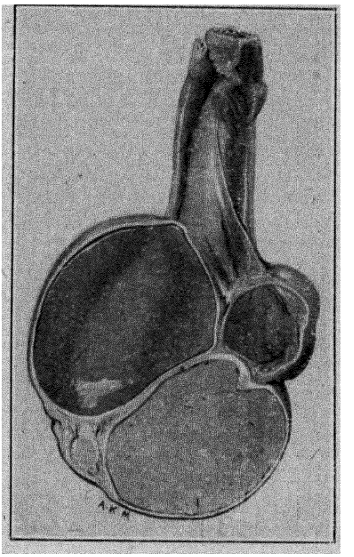

FIG. 993.—BILOCULAR SPERMATOCELE

Treatment is conducted along the same lines as for vaginal hydrocele, *viz.* by tapping as a palliative measure, and injection or excision in order to establish a radical cure.

(*b*) *Encysted Hydrocele of the Body of the Testis* is a condition rarely seen, consisting of a small collection of serous fluid beneath the visceral portion of the tunica vaginalis. It is probably due to dilatation of lymphatic spaces, and has no clinical significance.

II. **Hydrocele of the Cord** occurs, as already described, in connection with the congenital and infantile varieties of vaginal hydrocele. If limited to the cord, it exists in one of two forms, the encysted or the diffuse.

1. **Encysted Hydrocele of the Cord** arises from imperfect obliteration of the funicular process of peritoneum, the patent portion becoming distended with fluid and giving rise to a cavity lined with endothelium. It is usually detected as a rounded elastic swelling occupying the inguinal canal, moving freely up and down within it. The upper border is sharply limited, and in favourable cases translucency can be demonstrated. On fixing the testicle the cyst is no longer movable. The fluid contained within it is identical in nature with that in a vaginal hydrocele. In the female a similar condition arises from imperfect obliteration of the canal of Nuck, giving rise to what is known as a *hydrocele of the round ligament.* **Treatment** consists in removal of the fluid by tapping, or, if a more radical proceeding is necessary, by injection or excision.

2. **Diffuse Hydrocele of the Cord** is but rarely seen. It results from a diffuse œdema of its cellular tissue, and presents on examination a fusiform or sausage-shaped tumour, which extends along the cord for a variable distance.

The term **Chylous Hydrocele** is applied to a distension of the tunica vaginalis with chylous fluid, recognized by being milky in appearance, and under the microscope seen to consist of a fatty emulsion. Several modes of origin have been suggested, but none are very satisfactory. In one case under our care a series of dilated lymphatics filled with a similar fluid extended upwards from the testicle to the inguinal canal.

Varicocele.—A varicose condition of the pampiniform plexus is very commonly met with in young men, but seldom in those of advanced age, except when it has become chronic, or is due to malignant disease of the kidney. It usually occurs in individuals with a lax and pendulous scrotum, and is often associated with masturbation, which induces abnormal vascularity of the testis. The fact that it sometimes develops in quite young boys suggests, however, that there is some congenital condition associated with it. It may also be caused by the pressure of a truss applied for the relief of a hernia. It is almost invariably on the left side, and the reasons given for this are as follows. (*a*) The left testis usually hangs lower than the right, and hence the spermatic veins are longer and exposed to greater blood-pressure. (*b*) The left spermatic vein opens into the left renal vein at right angles, and no valve is present at the orifice, whilst that on the right side opens obliquely into the vena cava and is valved. (*c*) The presence of the sigmoid flexure on the left side of the body, and its distension by accumulated fæces as a result of constipation, may lead to pressure on the abdominal portion of the left spermatic vein.

A varicocele is characterized by the presence of a soft irregular swelling in the scrotum, which is somewhat pyramidal in shape, the main mass being below and slightly overlapping the testis and the apex above. It consists of dilated and tortuous veins, the outlines of which can often be seen through the skin (Fig. 994). They impart a sensation to the finger which has been likened to a collection of living worms in a bag, there is a distinct impulse on coughing. On assuming the recumbent posture the swelling almost disappears, owing to the vessels being emptied of their contained blood; if pressure is subsequently applied over the external abdominal ring, and the patient allowed to stand, the tumour reappears, filling from below upwards. A sensation of weight and pain usually accompanies a varicocele, and severe neuralgia of the testis may be induced. It is a frequent source of seminal emissions, and may result in testicular atrophy. Phlebitis is liable to follow an injury, and may lead to a spontaneous cure; if one of the dilated veins is ruptured, severe hæmorrhage ensues, causing a diffuse hæmatocele of the cord. In favourable cases the condition disappears spontaneously. For the diagnosis from omental hernia, see p. 1345.

The **Treatment** of slight cases of varicocele consists in supporting the testicle and scrotum by means of a well-fitting suspensory bandage; the patient is also instructed to bathe the parts with cold water night and

morning, and to take such measures as shall ensure a daily action of the bowels.

Radical Treatment by excision of the veins is advisable in neuralgic cases, where atrophy of the testis is threatening, or in order to fit the patient for admission into any of the public services. It is, however, much less employed than formerly. The operation is conducted as follows: An incision 1½ inches long is made in the direction of the cord, with its centre a little below the external abdominal ring. The coverings of the cord are divided longitudinally, so as to expose the spermatic veins at their upper end. Two main branches are usually found in this situation, but occasionally there is only one. These are cleaned and carefully isolated from the other structures of the cord, and a ligature is applied to them at the external abdominal ring. The vessels are now clamped with a pair of artery forceps below the ligature, and

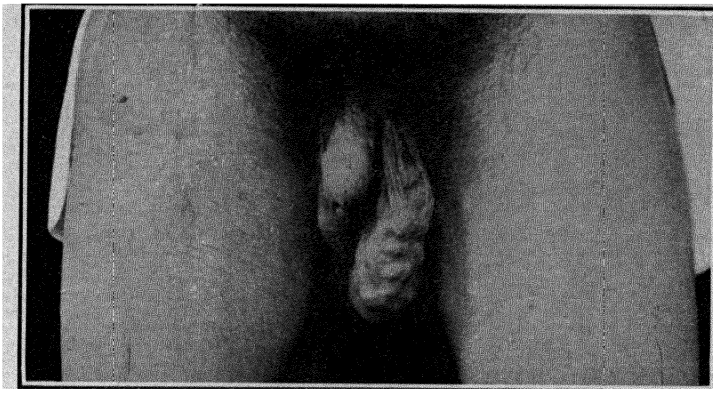

FIG 904.—LARGE VARICOCELE IN A PATIENT AGED 35 YEARS, WHO HAD USED NO SUPPORT FOR MANY YEARS

divided between it and the forceps. The lower end, grasped by the forceps, is stripped downwards, so as to free the pampiniform plexus from the other elements of the cord, and the dissection can be carried nearly as far as the epididymis by drawing the testicle up into the wound. The lower end of the veins is ligatured in one or two portions and divided. By this means the whole varicocele is removed. If the scrotum is pendulous and the testicle hangs low, it is advisable to raise it by introducing sutures through the divided ends of the veins above and below, and tying them together. The wound is closed without a drainage-tube, and dressed as usual. The patient is kept in the recumbent posture for a fortnight, until organization has occurred in the divided ends of the veins and a firm cicatrix has formed. The venous return after the operation is maintained by the vein or veins running with the artery to the vas in the posterior portion of the cord. Occasionally, if the removal of veins has been too complete, a hydrocele

develops subsequently, owing to the passive congestion of the testis. It is usually unnecessary to remove any scrotal integument, although it is often redundant; but after the wound is soundly healed the dartos may be stimulated daily by brushing the scrotum with a clothes-brush. Injection treatment with small doses of reagents used for varicose veins is satisfactory, after overcoming the difficulty of steadying these veins for the injection.

Neuralgia of the Testis is characterized by the organ becoming exquisitely tender and painful, although apparently healthy. It usually occurs in young adults of nervous temperament, or in middle-aged gouty men, and may be associated with a varicocele. The pain is usually paroxysmal in character, and very intractable. **Treatment** must be directed mainly to the general health, but local sedatives, *e.g.* belladonna and aconite, may be applied. It is also advisable that a suspensory bandage should be worn.

Atrophy of the Testis results from several causes: (i.) It may be due to a congenital arrest of development, as met with in displacement or late descent. (ii.) It is most frequently the consequence of inflammatory affections, either of the body or epididymis, owing to the cicatricial contraction caused thereby leading to compression of the vessels. It occasionally follows the orchitis of mumps, especially in adults, and is also due to syphilitic disease. (iii.) It arises from impaired nutrition, as after the division of the supplying arteries in operations for varicocele or hernia, or from compression of the cord by closing the inguinal canal too firmly in the operation for the radical cure of hernia. It appears, however, that division of the spermatic vessels in an adult will not suffice to determine atrophy, if the artery to the vas, with its accompanying veins and nerves, is preserved intact. A similar accident in a child will, however, suffice to prevent development of the organ. (iv.) Chronic congestion of the testis, as by a varicocele, may induce atrophy. If unilateral, it is of comparatively little importance; but where both organs are affected, sterility is sure to result, and the patient, if previously young and healthy, is likely to become depressed in spirits and melancholic.

General Diagnosis of Scrotal Tumours.—When a patient presents himself for examination with a swelling in the scrotum, the surgeon has to decide whether it is a hernia, a hydrocele, a hæmatocele, a varicocele, or a solid enlargement of the testis, and, if the latter, of what nature. The first point to which attention is directed is the condition of the cord immediately below the external ring. If this is of normal size and consistency, hernia and diffuse hydrocele of the cord are thereby excluded; the existence of a rounded tense swelling, movable within the canal, but becoming fixed on holding the testis, indicates that an encysted hydrocele of the cord is probably present. When, however, the cord is more or less masked, further examination speedily determines whether a hernia or a diffuse hydrocele or hæmatocele of the cord exists, since the former is often reducible, has an impulse on

coughing, and is rounded or nodular in outline, and the latter are sausage-shaped, always irreducible, and semi-fluctuating.

When the swelling is purely scrotal, inspection and manipulation will at once decide if it is a varicocele, by its characteristic feel, by its disappearance on assuming the recumbent posture, and filling again from below on standing up. If the swelling is rounded in outline, the next point to be determined is whether it is solid or fluid. If fluid, it is probably a hydrocele, or the early stage of a hæmatocele; the translucency of the former, and the sudden appearance and non-translucency of the latter, should suffice to demonstrate their nature. It is possible that the hydrocele is merely a secondary complication, and hence no final opinion should be given until it has been tapped, and the condition of the body of the testis investigated. If, however, a solid mass exists in the scrotum, it is either a hæmatocele in its later stages, or some form of enlargement of the testis, whether inflammatory, syphilitic, tuberculous, or neoplastic. A *hæmatocele* is possibly recognized by its history, and by there being a fluid centre to the swelling, surrounded by solidified tissue. *Chronic orchitis* and *syphilitic* enlargement of the testis are so much alike as to render diagnosis always uncertain in the absence of a distinct syphilitic history; but if the swelling is extremely hard, with a smooth and regular outline, without testicular sensation, limited to the body of the testis, and accompanied by a hydrocele, it is probably syphilitic. *Tuberculous* disease, on the other hand, occurs more frequently in younger individuals than does the syphilitic variety; the epididymis is usually first attacked, becoming nodulated, the cord is early implicated, hydrocele is rare, suppuration is frequent, and testicular sensation remains till the body of the testis is disorganized. *Tumours* always impart a distinct sense of weight to the hand, quite different from that noticed in tuberculous or syphilitic disease, if a simple tumour is present, it is rounded, slow in growth, and the cord is unaffected. Malignant disease is characterized by rapid growth, more severe pain, and early implication of the structures of the cord and of the lumbar lymphatic glands. The enlargement of both testes is in favour of tubercle or syphilis rather than of malignant disease. A certain small number of cases will remain where, in spite of every care, the nature of the mass is still a matter of doubt; in such the diagnosis cannot be established without puncture or an exploratory incision.

Whilst weighing carefully the local conditions, we must not omit thoroughly to investigate and appreciate the general history and condition of the patient, his age, appearance, previous habits and illnesses, etc., and his reaction to the Wassermann test. At the same time an examination of the internal organs should be made to ascertain, as far as possible, the existence or not of concurrent disease, *e.g.* tuberculous disease of the lungs, seminal vesicles or kidneys, or secondary malignant deposits.

Castration is required for many different conditions, which have been already described, *e.g.* for malposition, tuberculous disease, old-standing hæmatoceles, and simple or malignant tumours. The operation is conducted as follows: The pubes and perineum having been

previously shaved and purified, the surgeon, standing on the same side of the patient as the organ to be removed, makes an incision down to the testis. If large and adherent to the scrotal tissues, the incision must necessarily involve the scrotum, but if the testis can be displaced upwards, it is wise to avoid the scrotal integuments. It should always extend upwards as far as the external abdominal ring, so as to enable the structures of the cord to be divided high up, and in cases of tuberculous or malignant disease, the inguinal canal must be laid open so as to expose the internal ring. The testis or tumour is enucleated from its surroundings, and the cord isolated and divided as high as possible, after transfixing and securely ligaturing it. Some surgeons prefer to separate the tissues of the cord, and to take them up individually, but this is a matter of little importance. The stump should not be allowed to slip back into the canal until all bleeding has completely stopped. Bleeding-points in the scrotum are now secured by ligature, and these may be numerous; the wound is closed by sutures, a drainage-tube being inserted in the scrotum, and by choice coming to the surface at the upper end of the wound—that is, as far from the perineum as possible.

In the performance of double castration it is recommended to make two curved incisions from side to side, so as to include between them a crescentic portion of the scrotal integument, in order to reduce the subsequent redundancy of unnecessary tissue.

Affections of the Vesiculæ Seminales.

Acute Vesiculitis is not often met with, but sometimes arises, in association with prostatitis, as a complication of gonorrhœa It is characterized by deep-seated pain in the perineum, together with irritability of the neck of the bladder and increased frequency of micturition. Defæcation becomes painful, and on examination of the rectum the vesiculæ can be felt enlarged and tender. If suppuration ensues an abscess forms, which usually bursts into the rectum, but sometimes into the bladder or peritoneal cavity. As a rule, the condition disappears *pari passu* with the gonorrhœa, but when suppuration has supervened, it is advisable to open the abscess by a deep incision through the perineum, guided by a finger in the rectum.

Subacute or **Chronic Vesiculitis** is not uncommon, the latter condition being often associated with prostatitis, and one of the most frequent causes of gleet. Seminal emissions and priapism may be caused by it, and the enlarged organ can be felt through the rectum. A good deal of pain, often referred to the back, is experienced. The treatment is the same as for chronic prostatitis, although it is somewhat doubtful whether diathermy is of much use in these cases. Possibly vasotomy and the injection of silver salts through the open vas will be of some help.

Tuberculous Disease attacks the vesiculæ seminales as a result of extension from the testis along the vas, being almost always associated with similar disease of the prostate and base of the bladder. The organs can be felt enlarged, and if suppuration occurs, the abscess may

burst into the rectum or bladder, or possibly into both, a recto-vesical fistula being thereby developed. The vesiculæ can be reached without much difficulty through a curved incision in the perineum with its convexity forwards, displacing the rectum backwards and the bladder and prostate forwards. When exposed, complete excision is sometimes possible, or an opening is made into them, and the cheesy contents scooped out.

Affections of the Scrotum.

Injuries of the Scrotum.—Contusions and blows give rise to ecchymosis, which may be so extensive as to warrant the term *hæmatoma scroti* which has been applied to it.

Incised wounds may affect the skin and subcutaneous tissues, or may lay open the tunica vaginalis, with or without protrusion of the testicle. All that is needed in such cases is to render the wound aseptic, and to deal with it on general principles. Considerable destruction of scrotal tissue may be repaired by transplanting flaps from the inguinal region, or by grafting according to Thiersch's method.

Cellulitis of the Scrotum most commonly results from extravasation of urine, for which see p. 1520. It may occasionally arise from other causes, and leads to great constitutional disturbance, usually of an asthenic type, and often to considerable sloughing, the testes may be exposed when the sloughs come away, or may even be involved in the same process. As a general rule, repair is very active in the scrotum.

Œdema of the Scrotum is usually due to dropsy, being often associated with general anasarca and ascites. It may attain considerable dimensions. *Acute inflammatory œdema* of the scrotum is a term sometimes applied to erysipelas affecting this region, on account of the absence of the vivid red colour usually caused by that affection. Considerable œdema is always present, and gangrene of the skin may result. As soon as the gangrene becomes limited it should be excised, and the margins of the wound brought together by sutures, or allowed to heal by granulation.

Scrotal Fistulæ are usually due to the bursting of abscesses in connection with the urethra (p. 1519).

Sinuses of the Scrotum are often found in connection with tuberculous or syphilitic disease of the testicle.

Eczema of the Scrotum is a troublesome affection, giving rise to great pruritus and irritation. It results from the presence of pediculi, but the more chronic forms occur amongst workers in tar and paraffin, and also in chimney-sweeps, being due to the constant irritation of the corrugated scrotal integument by dirty clothes. It is associated with the presence of warty outgrowths, and not unfrequently runs on to **epithelioma,** originating the condition known as *chimney-sweep's* or *paraffin cancer.* The usual characteristics of such a new growth are present, and in some of the deeper cells particles of soot have been demonstrated. The inguinal glands are usually involved, but not till late, and the progress of the case is slow. The only treatment which can be adopted is complete removal, together with the inguinal glands.

CHAPTER XLV

AMPUTATIONS.

General Remarks.

THE surgeon who is about to remove a limb must always keep in mind that the operation to be performed has two ends in view: (1) To remove the offending member with as little shock and sacrifice as possible; and (2) to provide a stump suitable for the requirements of the maker of artificial limbs. Too often in the past this latter desideratum has been forgotten, but the huge experience recently acquired in connection with this subject has emphasized its need.

In a review of 1,000 cases of primary amputations of the leg recently dealt with in the British Isles some interesting figures are shown.

1. Approximately 90 per cent. of these amputations fall into two classes, *i.e.* above the knee or below the knee The remaining 10 per cent. are: disarticulation at the hip, Stokes', Gritti's, Stephen Smith's, disarticulation at the knee, Syme's, Chopart's; etc. From this it would appear that it is fairly common practice throughout the British Isles to amputate either above or below the knee, and that the other undesirable types of operation are not often performed.

2. Some 12 per cent. of the above-knee amputations are too long, *i.e.* over 10 inches, and 16½ per cent. of the below-knee amputations are too long, *i.e.* over 9 inches of stump.

3. The causes of the amputations were:

(*a*) Disease, 35 per cent.
(*b*) Accidents, 65 per cent.; and it is quite probable that the incidence of road accidents will gradually increase.

4. At the present time there are about 4,000 amputations performed in the British Isles every year.

I. The **Actual Removal** of a limb may be required as an immediate urgent necessity in order to save life from shock, hæmorrhage, or infection—or it may be undertaken more deliberately with a view to remove some more chronic condition The patient may be in a good condition of health, so that the surgeon need not hurry over the work, or he may be so seriously ill that every extra minute taken by the operation is dangerous. It is obvious, therefore, that methods must vary with the local and general condition of the patient.

A. When the limb is infiltrated with inflammatory products, the result of a grave infection, and still more if gas gangrene is threatening or present, and the patient's general condition is poor, the most rapid amputation possible must be undertaken. Moreover, it must permit

of suitable tissue-drainage, and be kept as low as possible, since a re-amputation may be required later on.

For this purpose short muscular flaps are cut from the front and back of the limb, the deeper parts are divided by a circular sweep of

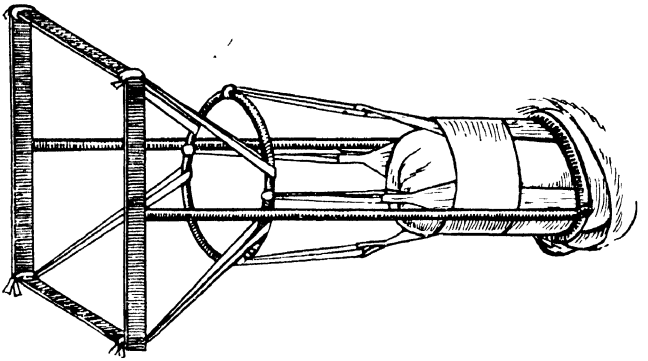

FIG. 995.—METHOD OF APPLYING EXTENSION TO AMPUTATION STUMP

the knife, and the division of the bone by the saw permits the removal of the limb. Bleeding-points are secured, and then the flaps are either loosely sutured together over a pad of gauze soaked in dichloramine-T or flavine, or may be stitched back out of the way for a time, so as to secure efficient tissue-drainage. To prevent undue retraction of the soft parts, an extension appliance similar to that represented at Fig. 995 may be employed. The guillotine operation so often used during the late war is most undesirable, and should never be undertaken.

B. When the amputation is undertaken deliberately for conditions which are not urgent, more consideration may be taken of the requirements of the artificial limb maker, and more stereotyped methods may be employed. All amputations are in the main merely modifications of three cardinal operations—the circular, the racquet-shaped, and the flap.

1. The **Circular Amputation** (Fig. 996) is now but little used, in it the skin and subcutaneous tissues are divided around the whole circumference of the limb by a circular sweep of the knife. These are then retracted or dissected back like a cuff, and the superficial muscles divided in a similar manner. The soft parts are again further retracted and the deeper muscles divided, allowing the

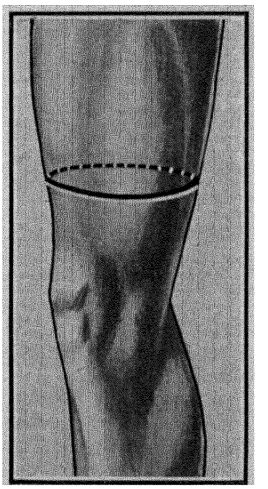

FIG. 996.—CIRCULAR AMPUTATION THROUGH THE THIGH

bone to be cleared and sawn through at a still higher level. The end of the bone is thus placed at the apex of a conical hollow and can be completely covered over; the vessels, moreover, are divided transversely. The stump is not very shapely, and after a time, owing to the shrinking of the soft parts, the cicatrix is likely to become attached to the bone. The arm is almost the only situation in which a pure circular operation is ever undertaken at the present day.

2. In the **Racquet-shaped Method** an oval incision is made around the limb with one end pointed, and if necessary prolonged upwards

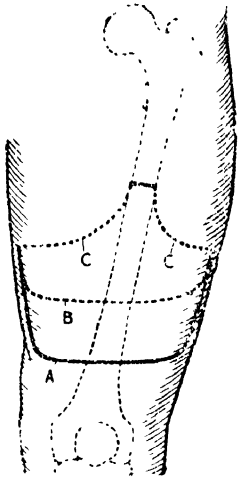

FIG 997.—AMPUTATION OF THE THIGH BY LISTER'S FLAP AND CIRCULAR METHOD

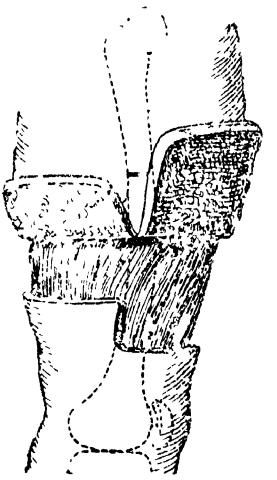

FIG 998.—LATERAL VIEW OF THE SAME OPERATION WITH THE SKIN FLAPS DISSECTED BACK

A indicates the anterior flap, B, the posterior, which is half the length of the anterior, C, the line of division of the muscles, which is performed by circular sweeps of the knife

to form, as it were, the handle of the racquet. This method is useful for removing fingers and toes, and is also employed at the hip and shoulder joints.

A somewhat similar operation is known as the **Elliptical** or **Oval Method**. In it an oval incision is made around the limb; the lower or distal portion is then dissected up so as to enable the amputation or disarticulation to be completed at a level a little below the proximal end. The free convex border of the flap is then turned over, and fitted into the concavity of the wound.

3. The **Flap Method** is that chiefly made use of at the present day in amputating through the shafts of the long bones. It was formerly performed by *transfixion* in order to save time; but the bulk of muscles included in the flaps, and the fact that the vessels and nerves are often

sliced, longitudinally render this an undesirable proceeding. Hence it has been discarded, and the flaps are now usually marked out superficially, and then raised by *dissection*. As a rule, they consist merely of skin, subcutaneous tissue, and deep fascia, a little muscle being perhaps included towards the base.

The best method of amputating in muscular parts, such as the thigh, is that known as the **Modified Flap and Circular** (Figs. 997 and 998), which was originally suggested by Lord Lister. In this two rectangular flaps with the corners rounded off are raised on opposite sides of the limb, the length of the anterior being two-thirds of the diameter of the limb at the point at which it is proposed to divide the bone, and the posterior flap half of the length of the anterior. These, consisting merely of skin and subcutaneous tissues, are dissected up, the muscles are then divided circularly, being retracted for another half-diameter. The advantages of the flap and circular methods are thus combined (Fig. 999).

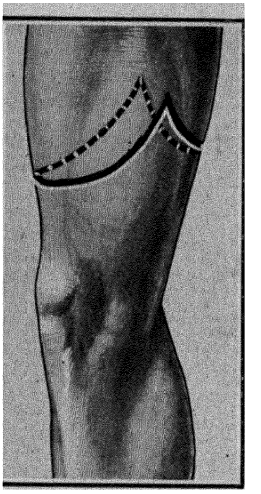

THROUGH THE THIGH BY UNEQUAL FLAPS

II. Since the **end results** of an amputation depend so greatly on the appliance that is afterwards supplied, it is necessary for the surgeon to have some knowledge of artificial limbs. A modern artificial limb is constructed with a view to giving maximum strength and comfort with minimum weight, and it has been found that a light metal alloy such as duralumin gives these requirements.

In practice, it is found that 90 per cent. of lower-limb amputation cases can be fitted with one of two types of limb, the one known as the 'above-knee type,' and the other as the 'below-knee type.'

(*a*) **The Above-Knee Type.**—Thighs or shins are pressed in one piece from thin sheet metal, and the old-fashioned bulky wooden sockets and lacing leather corsets are replaced by metal sockets, enamel finished, and carefully perforated to allow ventilation. Knee-joint mechanisms are built internally to give a smooth appearance, and are designed to control the swinging of the limb and produce a natural action.

The socket is shaped to take the greater part of the patient's weight on the tuberosity of the ischium, and a taper muscular stump is of great value in sharing the distribution of weight.

The limb is supported by a special form of pelvic band, which allows free movement of the stump in all directions. The old-fashioned chest and shoulder harness, which used to serve the double purpose of swinging the limb and holding it in place, is no longer necessary.

(*b*) **The Below-Knee Type.**—The shin is pressed in one piece from thin sheet metal, and supports a leather socket which is moulded from

a carefully rectified plaster cast of the stump. The ankle mechanism is self-contained, and the working clearance between foot and shin is imperceptible. Ball-bearing side steel joints attached to a soft thigh corset give support and freedom from lateral strain to the knee-joint.

From the prosthetic point of view the following are important:

1. **The Site of the Amputation.**—The stump should be long enough to give sufficient leverage yet short enough to allow room for an internal mechanical joint. The *level* of the amputation must be decided partly by the character and extent of the disease, partly by the requirements of the limb-maker. Whilst it is always requisite that the whole disease should be removed, it is also desirable to effect this with as little sacrifice as possible.

2. A **Sufficient Covering** is necessary in order to protect the end of the bone from injurious pressure. If the skin were not contractile, and if the muscles did not retract, it would suffice to provide two flaps, each equal to half the diameter of the limb at the point of section of the bone; but owing to the contractility and retraction of living tissues, it is essential to allow at least a diameter and a half, and sometimes two diameters; in non-muscular parts the former may suffice, but in fleshy parts, especially when amputating low down in the thigh, where the range of muscular contraction is much greater, the latter. It is usually a matter of some significance whence the flaps are derived; thus a *single* flap, *e.g.*, a long anterior or posterior, is not to be recommended owing to the difficulty of maintaining its nutrition. *Equal* flaps, antero-posterior or lateral, are used in parts like the arm, where the end of the stump will not be exposed to pressure; generally, however, one flap is cut longer than the other.

3. The soft parts covering the stump must be of a healthy character, soft, supple, and movable over the end of the bone, the medullary canal of which becomes closed by a layer of compact bony tissue. A comfortable sufficiency is required, but no excess, as pain and irritation are caused thereby, and increased difficulty is experienced in wearing an artificial limb. The end of the bone should, if possible, be covered by a suitable muscle pad, which serves to protect it from pressure, and over this the skin should move freely. It is, however, possible to wear an artificial limb over an adherent scar, but it is less satisfactory and liable to develop later trouble.

4. The position and character of the **cicatrix** are important. In the leg it should not be terminal, but lie to one or other side, preferably behind; in the arm a terminal scar is desirable. The scar itself should be as nearly linear as possible, although this may be impracticable; at any rate, it must be soundly healed before applying an artificial limb, not adherent to the bone, with no tendency to eczema or ulceration, and not unduly sensitive.

5. The stump must be free from tenderness and able to stand a certain amount of pressure. The nerves divided during the operation follow the rules natural to these structures and develop bulbous ends (Fig. 162, p. 385). If these bulbs become adherent to the end of the bone or to the scar, they are pulled on by every movement of the

stump, or are exposed to pressure, and hence become a source of constant pain and disability. The greatest care must be taken in amputations to divide all the main nerves high up.

6. The portion of the limb that remains must be carefully conserved. There is often a tendency for muscles to take advantage of the loss of the long lever provided by the limb in order to drag the short remaining portion into a bad position, *e.g.* the upper parts of the arm and leg are very liable to be abducted, this must be guarded against most carefully, so as to conserve adduction.

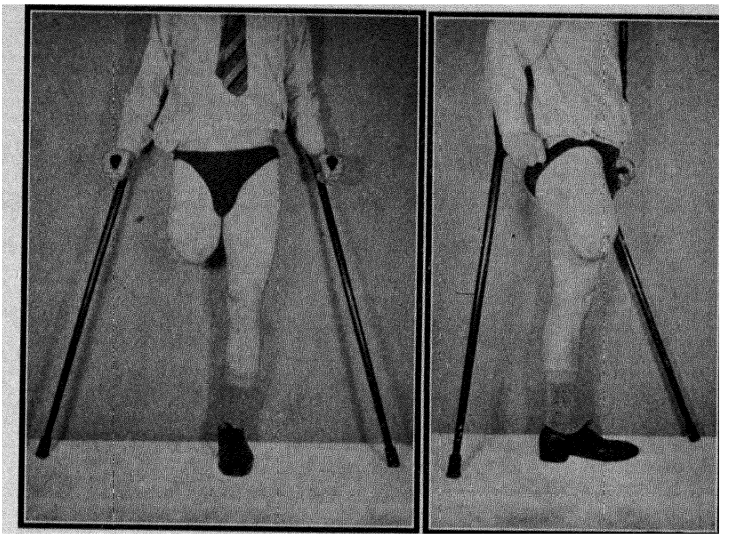

FIG 1000.—PRIMARY CASE OF AMPUTATION ABOVE THE KNEE OF IDEAL LENGTH

The stump is very œdematous, and almost the same size as the natural leg Binding and exercising, as described in the text, are necessary to prepare the stump for an artificial limb.

(By courtesy of Mr E R Desoutter)

The joint above the site of amputation must also be kept movable, and not allowed to become stiff; it is therefore wise to apply a splint for a time to keep the muscles quiet and prevent undesirable contraction. In a forearm amputation the elbow is likely to become flexed and extension may be lost, unless the limb is kept for a time on a splint in an extended position, and the elbow moved regularly. The same rule applies to an amputation below the knee.

7. *After the wound is healed the necessity for proper care of the stump can scarcely be over-emphasized* In the early stages after amputation, the greatest trouble the patient experiences with the fit of the artificial limb is caused by shrinkage and atrophy of the stump,

and it is therefore highly desirable to prepare the stump for the limb as soon as possible (see Fig. 1000). The time necessary for consolidation varies with each individual, for example, an elderly patient suffering from arterial disease will be weak, and it is advisable to wait four to six months before attempting to wear a limb, on the other hand, a youth who has lost his leg as a result of an accident will be strong physically, and with proper treatment will probably be ready for limb fitting about six to eight weeks after amputation. For a patient to be left, as so often happens, eight months or so after opera-

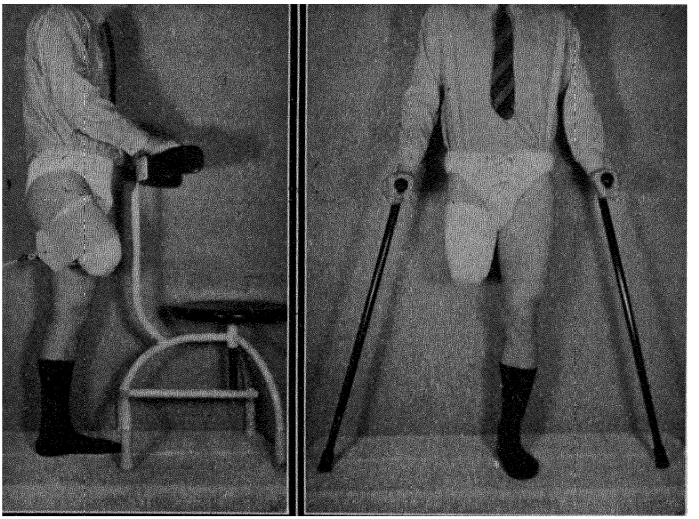

FIG. 1001 FIG. 1002.

FIG. 1001.—ELASTIC STUMP EXERCISER, WHICH SHOULD BE USED PROGRESSIVELY IMMEDIATELY THE STUMP IS HEALED

The movements should be extension, flexion and adduction

FIG 1002.—SHOWING THE CORRECT METHOD OF BINDING THE STUMP FROM ABOVE DOWNWARDS, ALL THE FLESH COMPRESSED AT THE BOTTOM OF THE STUMP

Comparison with Fig 1001 will show how much the stump is compressed by binding

(By courtesy of Mr E R Desoutter)

tion with no treatment whatever is both prejudicial to the end results and a waste of time. All cases should be exercised as soon as the wound is healed; the patient should perform active movements against resistance two or three times a day for twenty minutes; a convenient stump exerciser can be procured in which the resistance is provided by elastics, the strength of which can be increased progressively (see Fig. 1001). In this way the muscles are developed and superfluous flesh reduced. (It is possible to reduce a thigh stump 2 to 3 inches in circumference in four to six weeks by this means.) At the same

time mobility is retained and flexion and abduction are counteracted. A crepe or rubber bandage will help to ensure even shrinkage. It should be applied firmly *from above downwards* to prevent the formation of a roll of flesh at the top of the stump, and should be worn continuously (see Fig. 1002).

The use of a temporary pylon is a habit left from the late war when patients could not be fitted with limbs quickly enough, and is to be condemned. The small balancing point upsets the patient's equilibrium, and because there is no knee-joint the patient is forced to swing the pylon out to the side at every step, a habit it is almost impossible to cure when a permanent leg is fitted. A pylon should only be used when there is no prospect of fitting a permanent limb, or if locomotion is essential to the patient during the first few weeks. These cases should be fitted by an experienced limb-maker. The plaster pylon so often seen is most undesirable; usually constructed on wrong principles and ill fitting, it tends to develop a roll of flesh at the top of the stump, which gives much trouble to the limb-maker when a permanent limb is fitted.

Pathological Changes in Stumps.—*Infection of the stump* should not occur in amputations performed for disease or with unbroken skin; but in casualty work (civilian or military), where damaged or infected limbs have to be removed, infection cannot always be avoided. It may be limited to a localized suppuration, which merely requires the removal of a few stitches to effect drainage, and the packing of the cavity with gauze soaked in some suitable application, *e.g.* flavine, 1 in 1,000, or dichloramine-T in oil; as soon as infection has ceased and healthy reaction is secured, the flaps may be drawn together by strapping or closed by secondary suture. In the more severe cases it is necessary to open up the stump freely and at an early date, and not merely to introduce a drainage-tube through a small hole, thereby permitting the trouble to gather headway under the closed wound; when the infection has come to an end, secondary suture is available unless necrosis has occurred.

Necrosis of the end of the bone is not an unfrequent result of infection, especially if the periosteum has not been retracted before dividing the bone and subsequently brought together over the medullary canal to protect it. Rough handling during the later stages of the operation will predispose to its development, but practically it never appears apart from infection. A small annular sequestrum is usually all that separates, but should the inflammation spread up the medullary cavity (acute traumatic osteomyelitis), a more extensive destruction of bone tissue follows.

In the milder cases there is but little inflammatory reaction or pain, and all that appears is a sinus that will not heal. These cases should always be X-rayed, and sequestra will often be found. Operation for their removal should be undertaken at the earliest possible moment; they usually become loose in from two to three months. Prolonged retention means increasing sclerosis of tissues, and may necessitate a re-amputation.

Sloughing of the ends of the flaps occurs in debilitated individuals,

especially if thin skin flaps have been employed, or if their nutrition has been impaired by trauma, or if unhealthy tissue has been incorporated in their substance by amputating too close to the seat of disease or injury. The process is usually limited in extent, and rarely calls for treatment other than keeping the part dry and aseptic, the slough being then slowly absorbed. If infection is present, the consequences may be more serious, even necessitating re-amputation at a higher level.

A *conical stump* results either from the flaps being cut too short, or from the parts shrinking as a result of suppuration, or in young people from continued growth of the upper epiphyseal cartilage of the divided bone. In bad cases the bone may even project through the integument, and necrose; re-amputation is the only treatment.

A *painful stump* is usually due to the adhesion of a bulbous nerve-end to the cicatrix or bone, so that it is dragged upon at each movement of the limb. The pain is of a severe neuralgic nature, and is treated by excising the bulb, or by re-amputation. In other cases it is due to the projection of a *spur* from the divided end of the bone Fig. (1003), which presses on and irritates the tissues of the stump. These spurs are usually due to the want of a periosteal cuff to cover the divided end of the bone, or to imperfect protection of the soft tissues whilst dividing the bone with the saw; living bone cells are thus rubbed into the muscles, and ossification ensues.

Still another cause of pain in a stump is the persistence of inflammatory trouble in the bone which may be present as a subacute or chronic osteitis or osteomyelitis. The bone is enlarged and tender; necrosis may follow at a later date, and suitable treatment will be required, perhaps even a re-amputation.

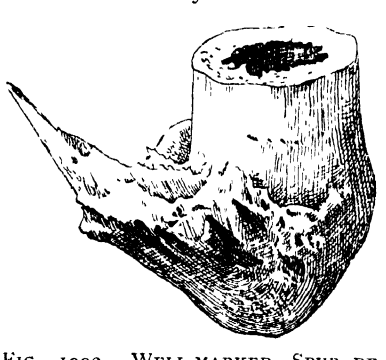

FIG 1003.—WELL-MARKED SPUR DEVELOPED AT THE LOWER END OF A DIVIDED FEMUR, NECESSITATING RE-AMPUTATION FOR PAIN.

It is obvious, therefore, that *in all cases of painful stump a radiograph is essential*, if a correct diagnosis of the cause is to be made.

A *spasmodic stump* sometimes occurs, being due either to irritation of the enlarged nerve-ends, or to some central cause. In the former instance, excision of the bulbs or re-amputation will cure the case; in the latter, the trouble will persist in spite of treatment, affecting fresh groups of muscles after re-amputation.

The *scar* itself may sometimes give trouble after healing has occurred. It may become dragged into a deep pucker in which eczema occurs. Ulceration may occur from local irritation or from general debility. In these circumstances, if suitable local or general treatment is unavailing, excision of the scar is required, especially if it is adherent to the end of the bone, or re-amputation.

General Technique of an Amputation.

A number of the more important elements in the operation have been already alluded to, but it is desirable to insist on them once again.

The greatest care must be taken to maintain *asepsis* whenever possible, since muscular and fascial planes are freely exposed, and possibly the medullary cavity of the bone opened; the dangers of infection under such circumstances are obvious. *Hæmorrhage* is prevented by previous exsanguination of the limb by elevating it for two or three minutes, as first suggested by Lord Lister, and then applying an elastic tourniquet. In the leg a piece of flat rubber tubing may be employed. In the arm, however, paralytic symptoms, usually involving the musculo-spiral nerve, have followed the use of such appliances, especially when made of solid rubber; a flat elastic bandage, carried several times around the limb, and secured by a knot or with a safety-pin, is all that is needed. The tourniquet must, of course, be first sterilized; it is also advisable to protect the skin over which it is placed by a few layers of sterile gauze. After the limb has been removed, the main vessels are at once ligatured, both artery and vein being separately tied. It is well to isolate and draw them down for a little distance, so as to make sure that they have not been buttonholed. Any other vessels which can be seen are tied before the tourniquet is removed. An assistant should for a time be ready to control the main trunk after releasing it from the tourniquet. In some cases it may be impracticable or undesirable to apply a tourniquet, and then the main vessels may be temporarily controlled by digital compression at some suitable spot whilst the amputation is completed. All bleeding-points are rapidly secured by pressure forceps and subsequently tied, and the main trunks isolated, and clamped or ligatured before division.

Attention has already been drawn to the necessity of not tapering the flaps, but of cutting them square, the corners alone being rounded. In dissecting them up, the deep fascia should be included with the flap, and the blade of the knife always turned towards the part which is to be removed, so that the under surface of the flap, and with it the nutrient vessels, shall not be scored. Whilst dividing the muscles, the flaps must be carefully guarded by the hands of assistants. Before dividing the bone, it is recommended that the periosteum should be retracted for some distance, so as more efficiently to provide for its nutrition and to cover the divided end subsequently; this plan should certainly be adopted for the humerus and femur. During the division of the bone the soft parts should be protected by a cloth so as to prevent bone dust being rubbed into the muscles and giving rise to myositis ossificans at a later date. Any irregular bony spicules left after sawing should be trimmed off with cutting pliers, and the periosteum is replaced and secured by deep sutures. Attention must next be directed to the main nerves and to any tendons which lie exposed in the wound, all such structures being cut short, the nerves as high as possible. The end of the bone should be covered by stitching the muscles together over it, and the little extra time expended in the introduction of these buried stitches will be well repaid in the improved shapeliness of the

stump. The skin wound is usually closed by a continuous suture, and provision made for drainage from one of the angles of the incision. The dressing is applied in such a way as to draw the flaps down over the end of the bone, and a splint is generally necessary in order to control the upper ends of the divided muscles and to keep them from spasmodic contractions.

The chief **complications** likely to arise in the subsequent course of the case are shock, reactionary hæmorrhage, and those which result from infection, these conditions and their treatment have been described elsewhere.

Re-amputations are not unfrequently required, especially in military work, where the primary operation has often been undertaken merely to save life, and sometimes with but little thought of subsequent prosthesis. Large open wounds result which take months to heal, and even then the stump is unsatisfactory and cannot bear pressure; so that a re-amputation as soon as it is safe is most desirable, and will save both time and pain. In other cases the wound is healed, but for various causes indicated above the stump is unsatisfactory, and an artificial limb cannot be worn; a secondary operation is therefore necessary.

In an *aseptic* case the operation is very simple. If the scar is healthy, it may be opened up, if the scar is adherent to the end of the bone, incisions are made to encircle it, and are prolonged on either side. These are gradually deepened by carrying the knife inwards to the bone from which the loosened soft parts are retracted. When the bone has been cleared at the desired level, it is divided for choice by a Gigli saw. Hæmostasis is effected, and the skin separated from the deeper tissues by undercutting all round; the muscles are drawn together over the end of the bone, and the skin margins united by sutures. It is essential that no tension be present. Naturally, modifications of the incisions have to be devised to meet any special peculiarities of the stump.

In cases *where the primary wound is unhealed*, a more difficult problem presents itself, but good results and primary healing are obtainable if certain precautions are adopted. In the first place, acute sepsis must be dealt with in the usual way, and no attempt made to re-amputate until the condition has quieted down.

In the operation the skin above the granulating area is most thoroughly cleansed, and the wound itself scrubbed with gauze swabs to provide mechanical disinfection, and then any antiseptic that the surgeon favours can be applied. The operation is conducted in the usual way, taking special care to provide a sufficiency of skin covering which is dissected up from the muscles. It is most desirable in these cases to have a periosteal cuff which can subsequently protect the medullary canal.

Bleeding vessels having been secured and nerves shortened, preparation is made to close the wound. Various plans are recommended, and herein lies the great difficulty of gaining a successful result. (1) Some surgeons draw the flaps lightly together over a gauze pack soaked in a solution of flavine, and do not attempt closure for a few days; absence of inflammatory reaction proves that complete closure

may be safely attempted. (2) Others prefer 'bipp' treatment. The wound is washed with absolute alcohol and dried, and then a sufficiency of 'Bipp' is rubbed into all the tissues, and closure is effected by deep and superficial sutures. (3) Other surgeons consider that it is useless to apply antiseptics, and pin their faith on deep sutures applied so as to coapt the parts without tension, thereby preventing the collection of blood in dead spaces between the flaps. The superficial stitches must also be free from tension. It is wise, however, to provide for drainage. Satisfactory healing usually follows, though it often does not occur without suppuration.

Special Amputations: Upper Extremity.

The end results are not so satisfactory on the whole as those obtained with lower extremity amputations, for it is impossible to replace the intricate movements of the fingers by any mechanical device.

Amputation of the Fingers is frequently required after machine accidents and similar injuries, or in necrosis following a whitlow. In these cases it is often impossible to follow any regular routine, the flaps being obtained from any portion of sound tissue present. The following, however, are the chief plans adopted:

Amputation of the Terminal Phalanx is usually conducted by opening the joint on the dorsal aspect, and cutting a palmar flap from the pulp of the finger (Fig. 1004).

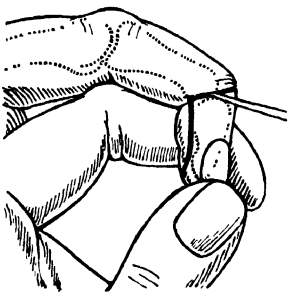

FIG 1004.—INCISIONS FOR AMPUTATION OF TERMINAL PHALANX OF FINGER

No useful result follows amputation through the first interphalangeal articulation, since the portion left is practically fixed and useless, no tendons being inserted to govern it. An operation which is sometimes advantageous consists in amputating through the middle of the second phalanx, so as to leave the insertion of the flexor sublimis tendon; the flaps for such an operation are derived from any part of the finger, and the bone is divided by cutting-pliers.

Removal of a finger **at the Metacarpo-phalangeal Joint** is an operation frequently necessary. It is best conducted by means of a racquet-shaped incision (Fig. 1005, A), which starts over the knuckle, extends between it and the next finger, curves round to the palmar aspect so as to be placed a little below the crease in the skin at the root of the finger (Fig. 1006, A), and returns in the same way to the back of the knuckle. This incision can be made with one sweep of the knife, but there is no real advantage in such a procedure. The articulation is then opened from behind; the structures on either side are successively divided, making them tense by rotation of the finger, and the flexor tendons finally cut across. Bleeding-points (usually one on each side) are secured, and the wound closed.

The question of removing the head of the metacarpal bone is one which must be decided by the occupation of the patient; if he is a working man, or needs strength of hand, it should be left, as its removal always causes weakness. In ladies and those where smallness and elegance of the hand are required rather than strength, it can be taken away by slightly prolonging the incision upwards, clearing the bone on either side, and applying cutting-pliers. The gap between the adjoining fingers can in this way be almost obliterated. It is especially advisable to do this in the case of the index-finger, since the head of the second metacarpal bone forms an unsightly projection, and is very exposed to injury. For this finger, Farabœuf's method (Figs. 1005, B, and 1006, B) is often used. When the finger is removed for a bad whitlow, it is often wise merely to disarticulate at the metacarpo-

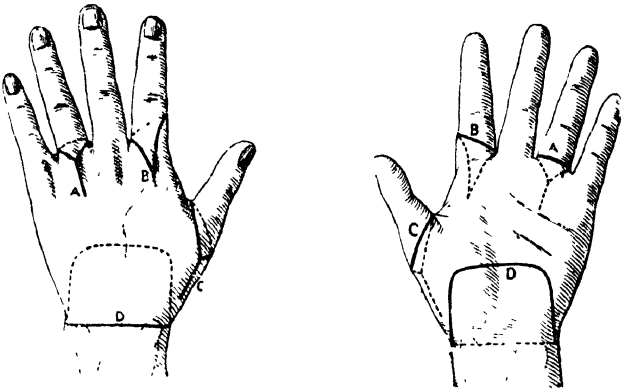

FIGS 1005 AND 1006.—DORSAL AND PALMAR VIEWS OF HAND, WITH INCISIONS FOR VARIOUS AMPUTATIONS

A, Incision for amputation of finger by racquet method, B, Farabœuf's method of amputation, as applied for index-finger, C, racquet-shaped incision for disarticulation of thumb at carpo-metacarpal joint, D, amputation through the wrist by a long palmar flap. In all of these the continuous black lines indicate the portions of the incisions visible from the dorsal or palmar aspects respectively, the interrupted lines, the portions that are hidden

phalangeal joint, and allow the septic trouble to quiet down and the wound to heal by granulation. At a later date a neat re-amputation, including, if need be, the removal of the head of the metacarpal, may be successfully undertaken.

Occasionally the four fingers and their attached metacarpal bones have to be removed *en bloc*. Short equal flaps may then be cut from the front and back of the hand, and the disarticulation effected. The stump that remains, although consisting of merely the carpus and thumb, is very serviceable.

Amputation of the Thumb should never be undertaken unless absolutely necessary, since its removal seriously impairs the functional utility of the hand; as large a portion must be saved as practicable, so as to assist the patient in grasping. The phalanges may be removed

by any method which enables the bone to be covered with the least possible sacrifice.

When it is also necessary to take away the metacarpal bone, one of the two following plans should be adopted:

1. *The racquet method* (Figs. 1005, C, and 1006, C). In this an incision commences in the intertendinous hollow known as the *tabatière*, and extends along the dorsum of the thumb to the head of the metacarpal bone, the oval portion sweeping round it at the level of the web when the thumb is abducted, and on the palmar aspect corresponding to the oblique crease at its root. The remainder of the operation resembles that for removal of a finger. Care must be taken not to wound the trunk of the radial artery as it passes through the base of the interosseous space; the blade of the knife is therefore kept closely applied to the bone.

2. By a *palmar flap*. In this the knife is first carried across the dorsal aspect of the thumb, from the centre of the web between it and the index-finger, to a point on the palmar surface of the wrist just above the thenar eminence. The knife is then rotated so that its cutting-edge looks outwards, and is made to transfix the ball of the thumb in front of the metacarpal bone, so as to emerge at the same spot in the centre of the web as that at which the dorsal incision commenced. A muscular flap with a well-rounded border is readily fashioned by cutting outwards. The remaining soft parts are then divided, and disarticulation is completed. It is a prettier and more showy operation than the former, but otherwise has no advantage.

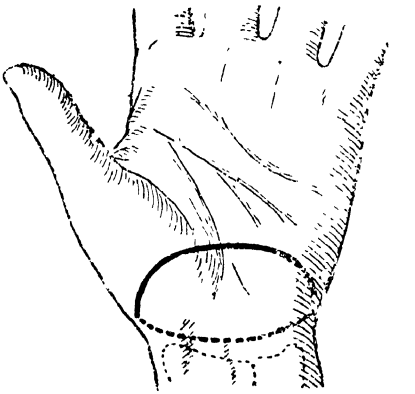

FIG. 1007.—AMPUTATION OF THE WRIST BY ELLIPTICAL METHOD

The dark line indicates the palmar flap, the dotted line the dorsal incision.

Amputations through the Wrist-joint are seldom performed except for injuries, and are unsatisfactory from the prosthetic point of view; the flaps must be derived as best they can from healthy tissues. Three chief methods are, however, described: (*a*) In the *elliptical* (Fig. 1007) the incision takes the form of an ellipse, the highest point being on the dorsum ½ inch below the level of the wrist-joint, and the lowest in the centre of the palm 2 inches below the former. On the ulnar side the incision passes between the pisiform bone and the base of the fifth metacarpal, and on the radial side it crosses the carpo-metacarpal articulation. After dividing the cellular tissue and dissecting up the palmar flap, the joint is opened from the posterior aspect, and the disarticulation completed. The convex end of the palmar flap is fitted into the concavity of the dorsum, and the cicatrix thus forms a curved line on the back of the stump. (*b*) A *long palmar flap* (Fig. 1006, D) is sometimes utilized, extending from just below either styloid

process down to about the middle of the metacarpal bones, the sides of this flap being parallel to each other. The dorsal incision crosses the carpus horizontally between the two extremities of the former wound (Fig. 1005, D). The palmar flap is then dissected up so as to include only skin and subcutaneous tissue, with perhaps a little muscular tissue from the thenar and hypothenar eminences. The wrist-joint is opened from the dorsum, and the amputation completed by the division of the flexor tendons. (*c*) In a few cases, amputation by an *external flap* may be desirable (Dubreuil's method). The incision commences at the junction of the middle and outer thirds of the back of the wrist, reaching down to the head of the metacarpal bone of the thumb, terminating at a point in the palm immediately opposite its commencement. This flap is dissected up and should contain a certain amount of muscular substance from the thenar eminence. The skin and subcutaneous tissues on the ulnar aspect are now divided by a circular sweep of the knife around the inner side of the limb. Disarticulation follows, and the external flap is carried inwards, and sutured so as to close the wound.

Amputation through the Forearm is usually conducted by means of a flap operation, the flaps being equal in length so as to secure a terminal scar. The muscles are divided circularly, and the bones should be thoroughly cleared before division. The junction of the lower and middle thirds is the most favourable situation. This will leave room for an artificial arm with wrist mechanism and a removable hand, in the place of which many different tools may be inserted. When the amputation must, perforce, be performed in the upper third, it is well to remove the upper ends of the flexors and extensors of the wrist and fingers and of the supinator longus from their attachments to the humerus, so as to leave as flat a stump as possible. The contraction of these muscles during flexion of the elbow causes the short stump to slip out of the socket of an artificial limb. The greatest care must be taken to divide the main nerves high, and subsequently to keep the elbow extended and supinated.

Disarticulation of the Elbow-joint is an operation which should not be undertaken; it has no advantages over one through the arm.

Amputation through the Arm may be carried out by any of the methods described, *e.g.* the flap, circular, or modified flap and circular, the choice in any particular instance being determined by the requirements of the case. The humerus should be divided about 6 or 7 inches from the tip of the acromion process to give the limb-maker a most useful stump; but even 1 or 1½ inches of bone will be useful, and the operation is much preferable to disarticulation of the shoulder-joint. Care should be taken to prevent an adduction contracture of the arm, which is very liable to follow, and lessens the subsequent utility of the part.

Disarticulation at the Shoulder-joint is now usually undertaken by an anterior racquet-shaped incision (Fig. 1008). The third part of the subclavian artery may be controlled by digital compression, the surgeon endeavouring to leave the division of the main vessels until the last stage of the proceedings; but it is perhaps better to clamp all the smaller vessels as soon as they are cut, and to isolate and tie the main trunks

before their division. A preliminary incision similar to that for excision of the shoulder is first made, extending downwards and outwards through the fibres of the deltoid, from the coracoid process. This passes directly down to the bone, and, if necessary, the joint is at once opened and examined prior to any further steps being taken. The surgeon, standing on the outer side of the limb, then carries his knife from the lower part of the incision downwards and inwards across the axillary folds around the limb to the point from which it first started, thus making the incision racquet-shaped. The skin is first dissected up all round for an inch or so, and then the muscles on the inner side, the deltoid in part, the pectoralis major, the coraco-brachialis and biceps, are divided on the slant, thereby exposing the main vessels and nerves. The vessels may now be secured and divided, and the nerves isolated, pulled down and cut short, or they may be left intact till later. The soft structures on the outer side of the vertical incision are next separated from the bone, and then the outer half of the capsule, together with the muscles inserted into the greater tuberosity of the humerus, and the long tendon of the biceps, are divided. The inner half of the capsule and the subscapularis are then cut through so as to free the head of the bone. By retracting the external flap and protruding the head from its socket, the posterior part of the capsule can be severed, and then the knife, travelling downwards between the humerus and the axillary vessels, is made to cut its way out, thus completing the disarticulation, the vessels and nerves, if not already dealt with, being divided as the last step in the proceedings. If the knife is kept close to the bone, the trunk of the posterior circumflex artery is not injured. Of course, an artificial limb after this operation has no functional value, but is merely ornamental.



FIG 1008.—AMPUTATION AT THE SHOULDER BY ANTERIOR RACQUET.



FIG 1009.—INCISIONS FOR THE INTERSCAPULO-THORACIC AMPUTATION

Occasionally it is necessary to remove the whole of the upper limb, together with the scapula and outer third of the clavicle, for new growths, usually of a sarcomatous nature, or for injury. This so-called **Interscapulo-thoracic Amputation** is best performed according to Berger's method. An incision is made along the clavicle, and the middle portion of this bone is then removed so as to enable the surgeon to divide between ligatures the subclavian artery and vein on a level with the lower border of the first rib. The anterior flap is then formed by an incision (Fig. 1009) reaching from the centre of the former and extending downwards and outwards over the shoulder, across the anterior fold of the axilla, and as far as the lower angle of the scapula.

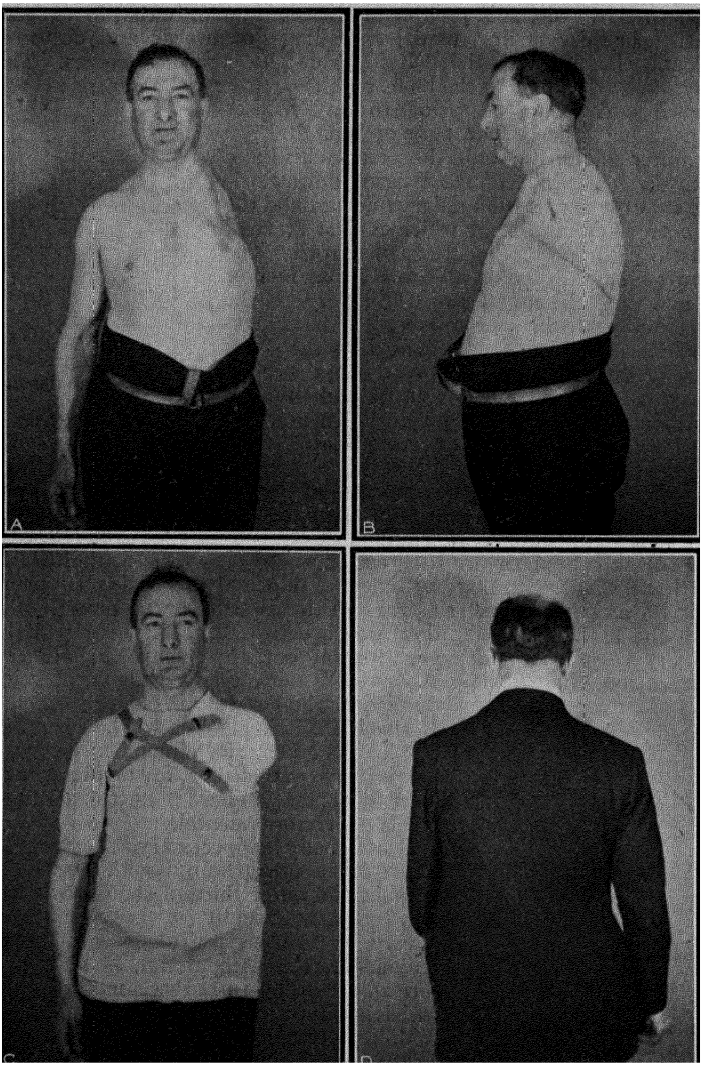

One of the results of this amputation is that the fitting of any appliance is extremely difficult, for there is very little left upon which to obtain a good grip. No form of artificial limb is practicable.

A, End result of amputation, B, side view, C, protective covering applied, D, the squaring of the shoulder by the use of a protective covering.

(By courtesy of Mr. E. R. Desoutter.)

The pectorales major and minor are divided along this line, thereby exposing the brachial plexus, the constituent nerves of which are severed on a level with the section of the vessels. The axillary space can now be opened up along the outer surface of the serratus magnus. The limb is then rotated inwards and adducted across the trunk, and the patient drawn well to the edge of the table so as to enable the posterior incision, which unites the outer ends of the two former, to be made. The flap thus marked out is dissected up, and the different muscles retaining the scapula in connection with the body are divided one after the other, including the trapezius, omo-hyoid, levator anguli scapulæ, rhomboids, and serratus magnus. These may be incised as near to the bone as is thought compatible with the total removal of the growth. Any remaining fibres are cut across, and the limb is thus detached. In cases of new growth there may be a large number of vessels, both arteries and veins, requiring ligature; but in a healthy limb removed for injury, none but the posterior scapular and suprascapular will give any trouble. Naturally, such an operation is accompanied by some amount of shock, but the results usually obtained have been very gratifying.

A limb-maker will supply a light protective covering which will square the shoulder and support the coat, though no form of limb is practical (see Fig. 1010).

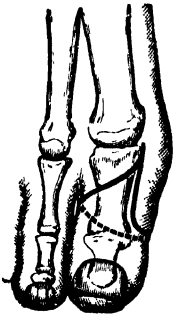

FIG 1011.—FARABŒUF'S AMPUTATION OF THE GREAT TOE (TREVES AND WAKELEY'S 'OPERATIVE SURGERY')

Amputations of the Lower Extremity.

Amputations of the Toes at the metatarso-phalangeal articulations are precisely similar to the analogous operations for the fingers. It must be remembered that the joint lies as far behind the web as the apex of the toe is in front of it, and hence the incision must start farther back than might be expected. A solitary toe should never be left, as it always becomes troublesome, owing to lateral displacement; this applies even to the big toe. The heads of the metatarsals should always be saved, if possible.

For the removal of the great toe from the metatarsal bone, *Farabœuf's operation* is the best. The incision (Fig. 1011) commences over the head of the latter bone, and well to the mesial side of the extensor tendon; it extends downwards nearly as far as the interphalangeal articulation, and then crosses the plantar surface of the toe so as to reach the centre of the web between it and the second toe; thence the knife is carried straight back to the commencement of the incision. These cuts are deepened, the tendons divided, the joint opened, and the toe removed. It will then be found that an internal flap remains, which can be brought across the head of the metatarsal bone, and covers it in so that the L-shaped cicatrix is not exposed to pressure.

Amputation of the great toe at the tarso-metatarsal articulation is conducted either by a racquet-shaped incision, or by dissecting up

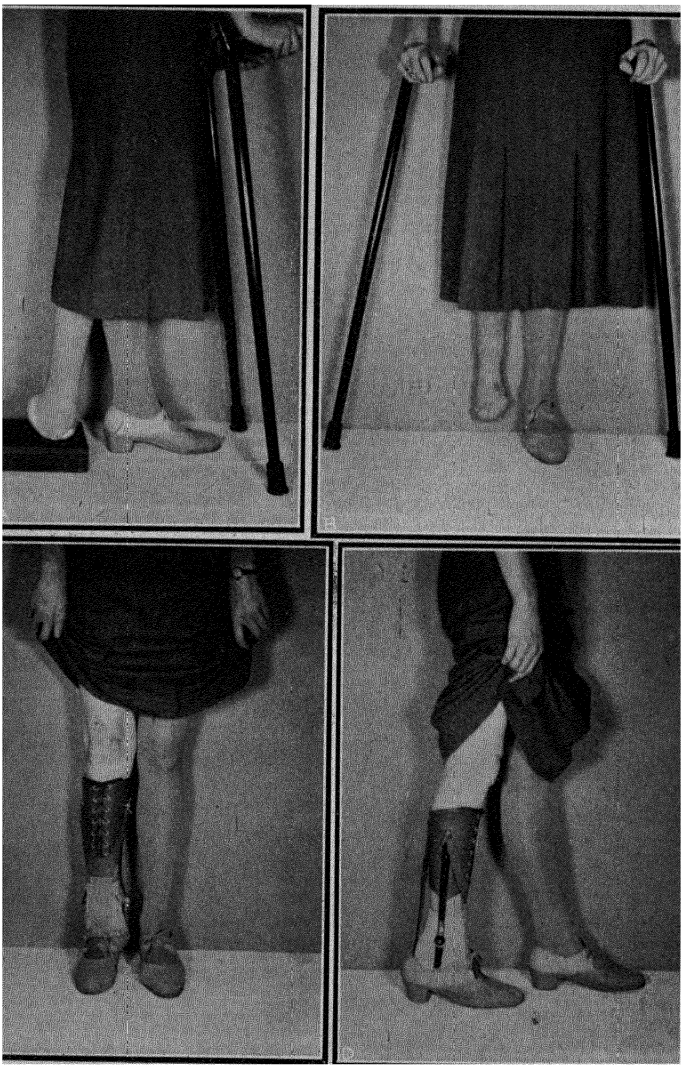

FIG. 1012. CHOPART'S AMPUTATION.

The tendo Achillis, having lost its antagonist, has contracted. There is also an equinus, and the stump is wider than the natural ankle. The type of appliance shown is most ungainly, and will cause painful sores to develop.

(By courtesy of Mr. E. R. Desoutter.)

a flap from the inner side. It is a bad operation, leaving a terribly mutilated foot, and should, if possible, never be undertaken.

Amputation of all the toes is occasionally required in bad cases of pes cavus. The operation is best conducted by cutting dorsal and plantar flaps, which, after removing the toes, are united over the heads of the metatarsal bones.

Amputations of the Foot used to be performed—

(*a*) At the tarso-metatarsal articulation by Lisfranc's or Hey's operation.

(*b*) At the mid-tarsal joint by Chopart's operation.

(*c*) At the sub-astragaloid joint.

But owing to the impossibility of fitting a satisfactory appliance to the stumps resulting from these operations, they should not be undertaken (see Fig. 1012).

Amputation of the Foot.—*Syme's amputation* consists of a disarticulation at the ankle-joint, together with removal of the two malleoli and the articular surface of the tibia. It is by far the best of all ampu-

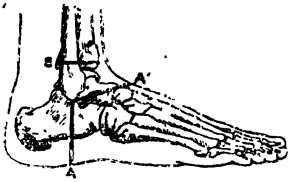

FIG. 1013.—LINES OF INCISION IN BONES AND SOFT PARTS IN SYME'S AMPUTATION.

A, A¹, Incisions for Syme's amputation; S, section of tibia and fibula

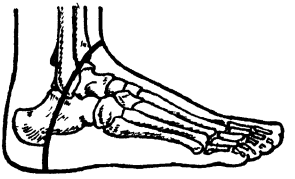

FIG. 1014.—ELLIPTICAL INCISION IN MODIFIED SYME'S OPERATION.

tations in the neighbourhood of the ankle. The patient lies on the back with the leg well elevated and projecting over the end of the table, the surgeon standing either below or a little to the right of the patient. Having exsanguinated the limb, the operation is, on the right foot, commenced by making an incision from the tip of the external malleolus down to the heel, and extending up to a point ½ inch below and behind the internal malleolus (Fig. 1013, A). On the left side the incision is made in the opposite direction. For this purpose a short-handled strong-bladed knife should be employed (an ankle knife). The incision is directed slightly backwards, otherwise a bucket-shaped heel flap is formed, in which discharges may collect. The knife is carried down to the bone at the first cut, and the surgeon then proceeds to dissect up the heel flap thus marked out by inserting his thumb into the wound, and partly peeling, partly cutting, the soft tissues from the back of the os calcis. This is sometimes a tedious and tiring proceeding, since it is most important to keep close to the bone for fear of dividing the nutrient vessels of the flap (external and internal calcanean). The dorsal incision (A¹) is then made, uniting the ends of the former wound, and carried slightly forwards so as to mark out a short convex flap. This is dissected up, and the ankle-joint opened, the line of the articulation being placed ½ inch above the tip of the internal malleolus. By

division of the lateral and posterior ligaments, of the tendo Achillis, and of the few remaining fibrous connections along the top of the os calcis, the foot is removed. The lower ends of the tibia and fibula are then cleared and sawn off (S), the ends of the dorsal flap being meanwhile held out of harm's way. The main vessels are tied, as also any other bleeding-points, the tendons and chief nerves are drawn down and cut short, and the wound closed by sutures, provision being made for drainage through one of the angles.

A much quicker and prettier method of performing this operation consists in making an elliptical incision (Fig. 1014) and opening the joint

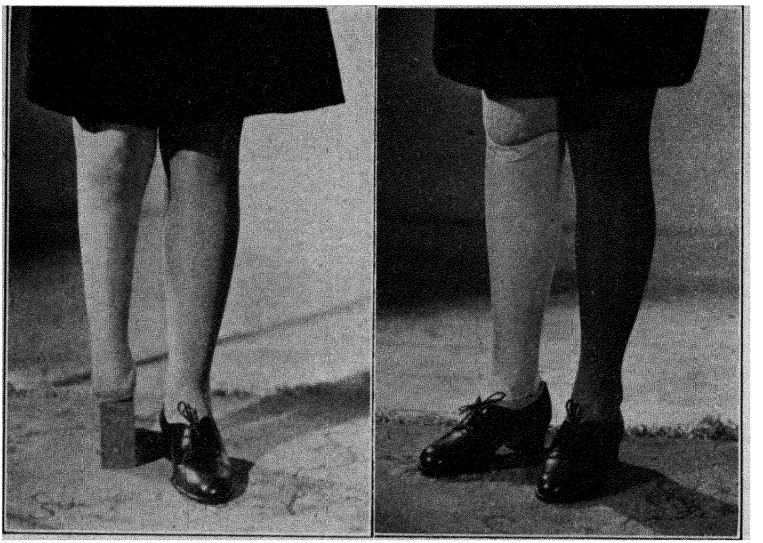

FIG. 1015.—SHOWING MODIFIED SYME'S AMPUTATION

Contrast the neat contour of the stump and the extra clearance between the end-bearing and the ground with Fig 1016 The light metal limb fitted, although slightly wider than the natural ankle, is quite neat

(By courtesy of Mr E R Desoutter.)

and disarticulating, whilst the os calcis is subsequently dissected out of the heel flap from above, keeping the knife close to the bone.

The modern practice is to cut the tibia and fibula about 1 inch above the articular surface of the tibia (Fig 1015) This is somewhat higher than the old-fashioned method (Fig 1016) and is desirable because.

(*a*) It leaves sufficient room for a mechanical ankle-joint in the artificial limb.

(*b*) There is less loose flesh and therefore less likelihood of the end-bearing pad loosening.

(*c*) The terminal increase in circumference of the stump is still great enough to be of value in holding the artificial limb in place, and is far less ungainly than when the bones are sectioned lower down.

Syme's amputation has been condemned, more particularly by surgeons who gained experience during the late war, when many operations were performed in unfavourable conditions. A good Syme's will give excellent results, with the advantages that the patient takes weight on skin already used to pressure, and there is very little shortening, so that he can, in emergency, walk on the bare stump. It is contra-indicated in cases where there is reason to suspect there may be circulatory trouble, and in bow-legged patients (Fig. 885), and is not on the whole recommended for women, because even the best appliance must be a little wider than the natural ankle.

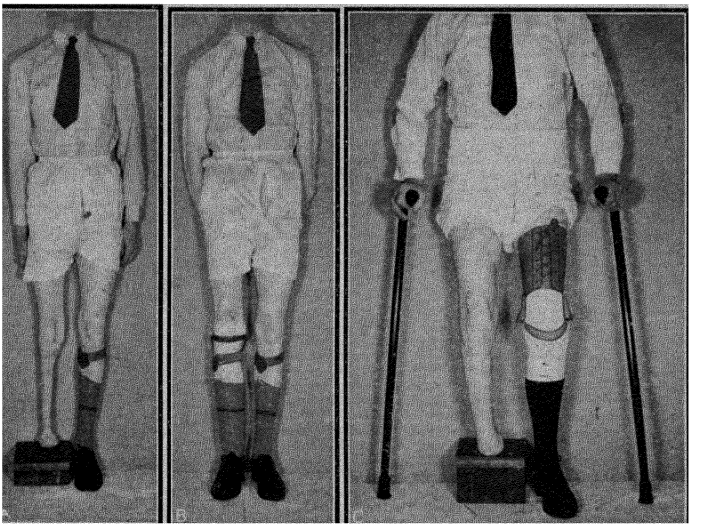

Fig. 1016. Fig. 1017.

FIG 1016.—ORTHODOX SYME'S AMPUTATION

Note the great increase in terminal circumference of this stump. The heel-pad is liable to loosen and become painful. The light metal limb fitted to this case is necessarily very much wider than the natural ankle.

FIG 1017.—SYME'S AMPUTATION ON A BOW-LEGGED PATIENT, DEMONSTRATING CLEARLY THE DIFFICULTY OF CONSTRUCTING AN ARTIFICIAL LIMB WITH CORRECT ALIGNMENT

(By courtesy of Mr. E. R. Desoutter.)

Amputations of the Leg should be undertaken, if possible, 7 inches for a man and 6 inches for a woman below the articular surface of the knee-joint. On a tall patient 1 inch longer than this is an advantage (Fig. 1018). A longer stump is not satisfactory because it does not allow of proper alignment of an artificial limb. In addition, there is frequently vascular trouble. Shorter stumps to a minimum of 2 inches of tibia, though not ideal, can give good enough results to make it well worth while saving the knee-joint (Fig. 1019). Almost any operation may be practised according to the needs of the case, but the most satisfactory is that by means of antero-internal and postero-external

flaps, the former being the longer so as to bring the scar well behind. After the first inch or two the flaps should be rapidly deepened so as to include all the muscles. In dividing the bones, care must be taken not to leave a sharp projecting edge on the front of the tibia. This is best prevented by partially sawing through the bone in an oblique direction from above downwards, and when this has reached a little beyond its centre, the saw is withdrawn, and a horizontal section made, cutting across the oblique incision in such a way as to remove a wedge of bone from the front of the tibia, which thus becomes suitably bevelled. The fibula should always be divided before completing section of the tibia, and should be about 1 inch shorter than the tibia,

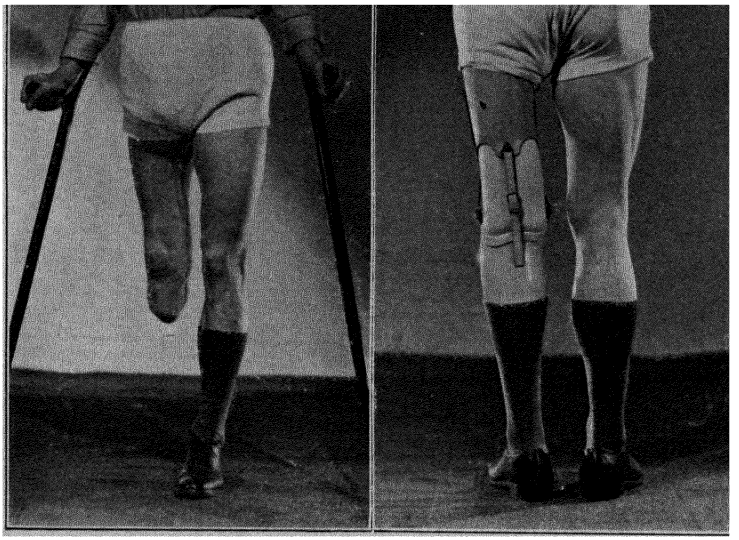

FIG 1018.—AMPUTATION BELOW THE KNEE, ALLOWING THE LIGHT METAL LIMB TO BE MADE TO MATCH THE NATURAL LEG,

(By courtesy of Mr E R Desoutter)

to leave a rounded end to the stump. With short stumps it is not advisable to remove the fibula completely, as is sometimes advocated, because this alters the shape of the stump from triangular to circular, and the triangular shape is extremely useful in helping to prevent an artificial limb from rotating. Also the scar left after the excision does not bear pressure. In cases where the fibula is very prominent, it is preferable to shave the head by means of a posterior circular incision, which will obviate the risk of an adherent scar.

Disarticulation through the Knee-joint and supra-condyloid amputation of the thigh (Carden's, Lister's, Gritti's, Stokes' are various methods) are seldom performed and are unsatisfactory because:

(1) They leave no room for an internal mechanical knee-joint.

(2) The bony end of the stump is greater in circumference than the fleshy part immediately above it, and in the case of disarticulation of the knee necessitates a limb with a leather lacing socket, which is heavy and hot

(3) The external mechanical knee-joint is wide and ungainly.

(4) The skin flaps are thin and of poor quality, and thus healing may not be satisfactory.

Amputation of the Thigh may be conducted by any of the general methods already described, but Lister's operation, modified flap and circular (Figs. 997 and 998), is the best.

The length of femur varies according to the height of the patient, but on an average 9 to 11 inches of stump, *measured from the perineum,*

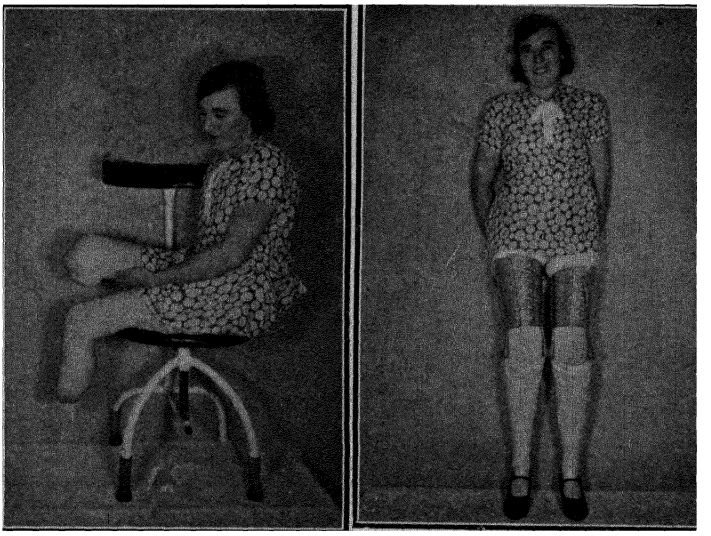

FIG 1019.—DOUBLE AMPUTATION BELOW THE KNEE

The right stump shows the minimum length to which it is possible to fit a below-knee type limb

(By courtesy of Mr E R Desoutter.)

is ideal (Fig. 1020). With longer stumps, not only do difficulties of circulation arise, but there is not room for a mechanical knee-joint, and the terminal increase in circumference of the lower end of the femur makes it impossible to fit a limb with a taper socket. Shorter stumps with as little as 3 to 4 inches of femur can be satisfactorily fitted with above-knee type limbs. Stumps with less femur than this have to be treated as cases which have been disarticulated through the hip, and are fitted with the 'tilting table' type of limb, but it must be emphasized that even 1 inch of bone is valuable when it comes to fitting this type of limb (Fig. 1022).

Disarticulation through the Hip-joint is always an operation of the

greatest gravity, and every precaution should be taken to minimize the immediate risks by preventing hæmorrhage and lessening shock. No part of the body should be unnecessarily exposed, moreover, the head is kept low, and although the operation must not be hurried over, no time is wasted.

Formerly several different methods of operating were described, but most of them are now discarded in favour of the *Anterior Racquet* operation (Fig. 1023). Of course, it is occasionally necessary for some other plan to be adopted, but the surgeon must use his own ingenuity in devising them to meet the requirements of the case. No

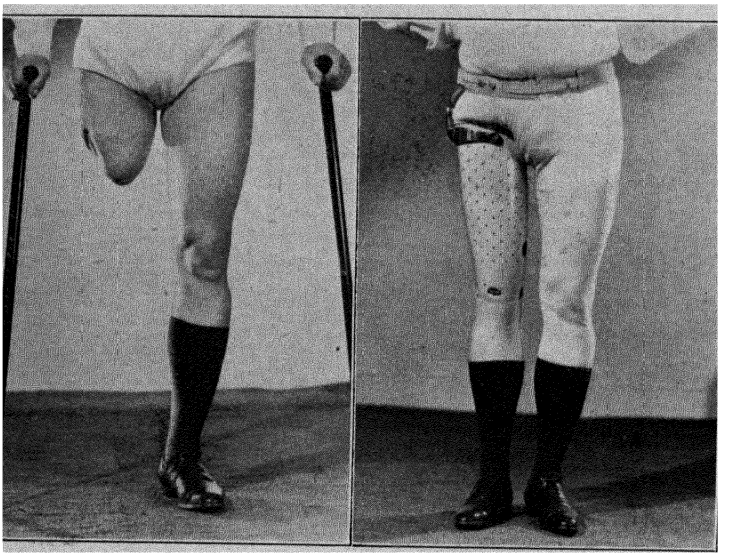

FIG 1020.—ABOVE-KNEE AMPUTATION OF IDEAL LENGTH AND CONTOUR
Note the taper shape of the stump, which is so valuable for the fitting and control of the artificial limb, also that the light metal artificial limb is suspended by a pelvic band only, with no chest or shoulder harness
(By courtesy of Mr. E R Desoutter)

special means need be employed for securing hæmostasis, as the main vessels are secured in the early stages of the operation, and all others are compressed by pressure forceps as they are divided.

The incision commences over the centre of Poupart's ligament, and is carried down along the course of the main vessels for about 3 inches. The common femoral sheath is exposed, and both artery and vein are secured by double ligature and divided. The incision is then completed, it sweeps over the inner side of the thigh 4 or 5 inches below the perineum to the back, and is brought up again to the front 3 or 4 inches below the great trochanter. The muscular structures in the outer flap are then cut through, and the external circumflex artery and other

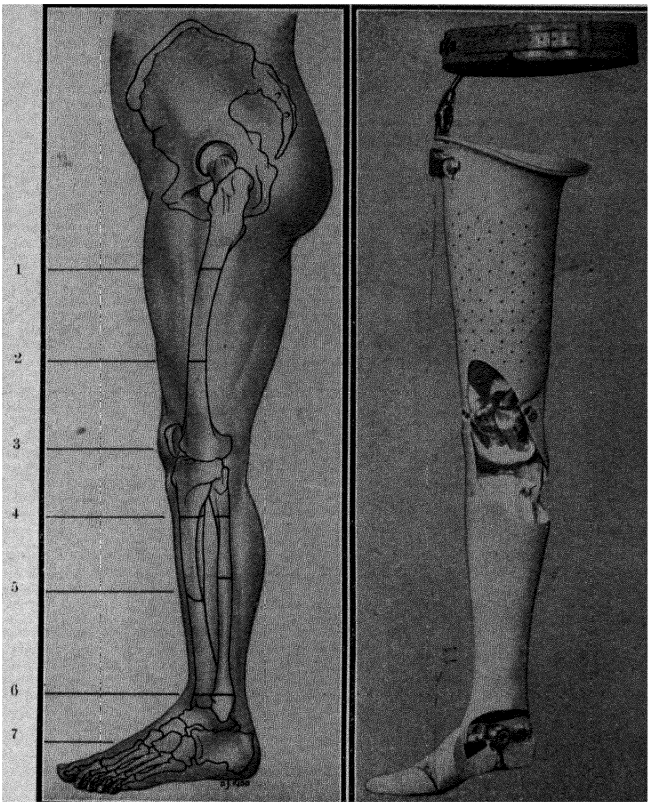

FIG. 1021.—AMPUTATION SITES OF THE LOWER EXTREMITY

An artificial leg (Desoutter) is shown for comparison, demonstrating in section the space required for the knee and ankle mechanism

1, Minimum of 3 to 4 inches of femur valuable for above-knee type limb, *but every inch of bone above this very valuable for through-hip type*, 2, stump of 9 to 11 inches, *measured from the perineum*, is the most satisfactory, 3, amputations at or immediately above knee undesirable for prosthesis, 4, tibia 2 inches long, the minimum which can be used for below-knee type limb—in this case the fibula must, of course, be of equal length, 5, tibia 7 inches long, with fibula 1 inch shorter, gives best results in below-knee cases; 6, modified Syme's—very satisfactory in selected cases, 7, all partial foot amputations undesirable for prosthesis

The sites of amputation indicated in the diagram are necessarily only approximate (see text)

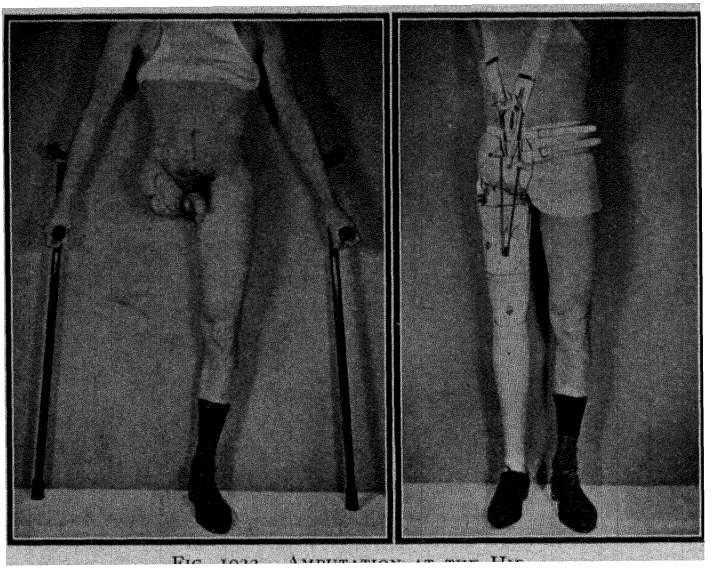

The shape of the stump shows clearly the value of saving even 1 or 2 inches of femur. The shape of the hip is retained, and provides a much better grip for the artificial limb than disarticulation.

(By courtesy of Mr E. R. Desoutter.)

bleeding vessels secured by pressure forceps *en route*. By rotating the limb inwards, the insertion of the gluteus maximus can be divided, as also the muscles attached to the great trochanter. The muscles in the inner flap are then similarly dealt with after rotating the limb outwards, the internal circumflex artery, etc., being secured. The capsular ligament is next divided transversely and the head of the bone disarticulated. Finally, the limb is rotated forcibly outwards, and all the soft parts at the back of the limb, including the sciatic vessel and nerves, are divided from within outwards with one sweep of the knife. The wound when sutured lies antero-posteriorly. After this operation an artificial limb of the 'tilting table' type can be fitted, and excellent results have been obtained (Fig. 1022).

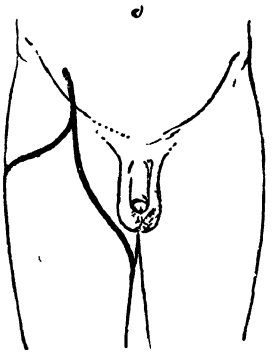

FIG. 1023.—AMPUTATION THROUGH HIP-JOINT BY ANTERIOR RACQUET INCISION.

At a glance the various sites for amputation may be visualized by looking at Fig. 1021.

CHAPTER XLVI.

ANÆSTHESIA.

By VERNON HALL, M R C.S , D.A.

THE art of anæsthesia is of comparatively recent origin. The first recorded use of nitrous oxide as an anæsthetic was in 1844; two years later Morton introduced ether for this purpose, and in 1847 Simpson of Edinburgh discovered the possibilities of chloroform. For nearly three-quarters of a century these agents practically monopolized the whole field, but during the last few years the subject has been revolutionized, and this revolution still continues.

The object of an anæsthetic is to enable various operative procedures to be carried out without pain to the patient, and this can be done in one of two ways: the patient can be rendered unconscious by the administration of a suitable agent, a process known as general anæsthesia; or the painful stimuli can be prevented from reaching the brain by the injection of drugs which temporarily block out the conductivity of the nerves while the patient remains conscious, a procedure known as local or regional anæsthesia, or, more correctly, analgesia.

General Anæsthesia.—In administering a general anæsthetic the anæsthetist is called upon to serve two persons—the surgeon and the patient. First in order of importance is the safety of the patient, and this implies a careful choice and administration of the anæsthetic agent, and also, in combination with the surgeon, the prevention of extreme shock. The second obligation is to keep the patient at such a stage of anæsthesia that the surgeon is enabled to carry out his operation in reasonable comfort. In addition the anæsthetist should make it his business to render the induction of anæsthesia as pleasant for the patient as is possible, and to reduce to the minimum the nausea and vomiting which are liable to accompany the recovery period. It cannot be too strongly emphasized, however, that safety must always take precedence of all other factors; this warning may seem unnecessary, but there is a tendency at the present time to take risks in order to make anæsthesia pleasant to the patient, and such practice cannot be too strongly condemned.

Stages and Signs of Anæsthesia.—For the purposes of description the course of anæsthesia is divided into several stages, but it must be borne in mind that the whole course is a gradual transition from consciousness to final respiratory arrest, and that it is not possible at any time to find a definite line of demarcation between one stage and the next. In the classification described here four stages are recognized, of which the third, that of surgical anæsthesia, is the

important one from the practical point of view, and this stage is subdivided into three planes, which take into account the needs of the surgeon during various operative procedures.

1. **Disordered Consciousness.**—Although still conscious, the patient's higher cerebral centres have become so affected that judgment is lost, and all faculties are disordered and unbalanced. Some senses may be abnormally acute, particularly that of hearing, and during this stage absolute silence must be maintained except for soothing and encouraging remarks to the patient. This condition is sometimes termed the stage of analgesia, as pain sensations are considerably dulled, and in the past it was used for some minor operations; nowadays its use is confined to obstetrics and to some phases of dentistry.

2. **Excitement.**—The patient loses grasp of his surroundings, and perhaps dreams he is elsewhere, and begins to shout and struggle. This is the most troublesome stage of induction, and considerable skill and experience are required to pass through it quickly, and to maintain a good airway and free respiration; if the concentration of anæsthetic vapour proceeds too slowly the period of struggling is prolonged, while a too-rapid increase will lead to breath-holding, swallowing, or vomiting.

3. **Surgical Anæsthesia.**—It is during this stage that all surgical operations are performed, as the patient is now completely unconscious and still. It can be subdivided into three phases:

Plane 1. Light Surgical Anæsthesia.—This is the degree of anæsthesia which is used for all operations in which muscular relaxation is not required—a large field including nearly all extra-abdominal operations. Considerable care has to be exercised while maintaining the plane, as any slight error of judgment may produce a lightening of anæsthesia sufficient to allow coughing or vomiting.

Plane 2. Medium Surgical Anæsthesia.—A moderate degree of muscular relaxation has now been established, sufficient to render possible some abdominal operations, such as appendicectomy or colostomy. It is the easiest plane to maintain, as it allows considerable latitude before a danger point is reached, and hence it is the plane that students should use for all their early attempts at giving anæsthetics.

Plane 3. Deep Surgical Anæsthesia.—In this plane the anæsthetic has been continued until all muscle tone has been lost, and respiration has become shallow by reason of commencing paralysis of the respiratory centre. It necessitates the absorption by the patient of large amounts of more or less toxic anæsthetic agent, and undoubtedly increases the liability to post-anæsthetic complications, and hence should be used only when the surgical procedure renders it essential, as, for example, in operations on the upper abdomen, such as gastrectomy, gastro-enterostomy, or cholecystectomy.

4. **Stage of Respiratory Arrest.**—This follows directly on Plane 3 if the dosage of anæsthetic is continued. The patient becomes pale and cyanosed, the blood-pressure falls, and after a period of time, the length of which depends on the patient and on the anæsthetic agent in use, the heart ceases to beat. This condition is produced

only by error on the part of the anæsthetist, and should it occur it calls for drastic action to avert calamity.

The Signs of Anæsthesia.—None of the signs of depth of anæsthesia can be considered to be absolutely reliable; all indications have to be watched closely, and allowance must be made for the marked individual variations which may occur. The most important signs are as follow:

Eye Signs.—Of the eye reflexes, the lid reflex and the conjunctival reflex are of little use, as both disappear at the beginning of surgical anæsthesia. The corneal reflex (elicited by lightly brushing the corneo-scleral junction and watching for a flicker of the lower lid) persists a little longer, and is present until light surgical anæsthesia is well established. It should not be used, however, as it is likely to result in abrasion of the cornea.

The degree of dilatation of the pupil is an indication of the degree of muscular relaxation, but unfortunately it is not always reliable, particularly in the young and old. Premedication with morphia in any form, or with hyoscine, alters the reaction of the pupil, and care should be taken not to rely on it in cases that have had these drugs.

Respiration.—This is by far the best guide, although even this is subject to marked individual variation, and is affected by pre-operative drugs. In all stages of surgical anæsthesia the respiration is regular and automatic, but alteration in volume and character occurs in the several planes.

Muscular Relaxation is a most important guide when dealing with abdominal cases. Provided that the premedication and the anæsthetic agent have been suitably chosen, the degree of relaxation demanded by the surgeon can be provided with safety.

As has already been emphasized, the signs of depth of anæsthesia vary considerably from case to case, but the following may be regarded as the most typical signs for each plane of anæsthesia:

Plane 1. Light Surgical Anæsthesia.—Respiration is smooth, regular and automatic in character, and the volume is slightly but definitely increased; expiration follows immediately on inspiration, and there is a marked pause at the end of expiration which may be slightly longer than the normal physiological pause. External stimuli, such as the surgical manipulation, are likely to cause alterations in the breathing at this stage. The pupils are small, and while a horizontal movement of the eyeball may be noticed in some cases, in others it is fixed in a slightly eccentric position. Muscular relaxation is slight.

Plane 2. Medium Surgical Anæsthesia.—The breathing is still automatic, but rather deeper than in the first plane; the pause at the end of expiration is slightly less marked, and there is no response to surgical stimuli. The pupils have become about half dilated, and the eyeball has become fixed in the central position. Muscular relaxation is fairly advanced.

Plane 3. Deep Surgical Anæsthesia.—The volume of respiration is decreased owing to the commencement of respiratory paralysis; in-

spiration is shortened and of a jerky, gasping character. There may be a slight pause between inspiration and expiration, whereas the pause at the end of expiration is much less marked. The accessory muscles of respiration come into play, and not unfrequently the chin is pulled downwards at each inspiration. The pupils are fully dilated, and muscular relaxation is complete.

While a full knowledge and understanding of these signs is essential, it must be remembered that the true art of anæsthesia lies in regulating the dosage according to the judgment acquired by experience, and in using the signs only as a check on that judgment.

The Airway.—The maintenance of a perfect airway throughout all stages of anæsthesia is of the utmost importance; even the slightest obstruction leads to uneasy anæsthesia, increases the surgical difficulties, and is harmful to the patient. There are three chief causes of obstruction to free respiration.

1. The accumulation of mucus in the air passages. This will not occur if adequate premedication with atropine (gr. $\frac{1}{100}$), or scopol-

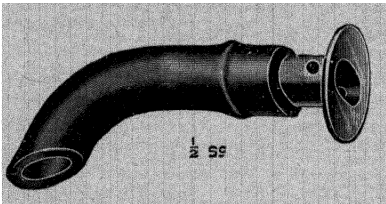

FIG. 1024.—PHILLIP'S AIRWAY.

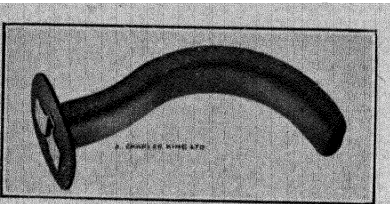

FIG. 1025.—GUEDEL AIRWAY.

amine (gr. $\frac{1}{150}$) has been administered a sufficient time before operation; three-quarters of an hour should be allowed for atropine, and one hour for scopolamine.

2. The most frequent cause of obstruction to the airway is the falling back of the base of the tongue on to the posterior pharyngeal wall; this is always liable to occur as soon as the muscles of the floor of the mouth are sufficiently relaxed by the action of the anæsthetic. It is essential that this obstruction should be overcome, and in some cases alteration of the position of the head, by tipping it well back or by turning it to one side, may suffice. Usually this is not enough, and then it will be necessary to hold the chin forward during the course of the operation; this is done by placing the fingers behind the angle of the jaw, and with a gentle but firm pressure lifting the floor of the mouth away from the back wall of the pharynx. If the operation is a long one this process is a tiring one and may give rise to bruising of the tissues, and it is better to use some form of artificial airway, such as shown in Figs. 1024 and 1025 well lubricated with vaseline, and passed over the base of the tongue, which is thereby kept forward without difficulty, and it is then only necessary to make sure that it remains in the correct position.

3. **Laryngeal Spasm** is a cause of obstruction which is less amenable to treatment. When the spasm is only partial it means that during

inspiration the vocal cords are tense and only partially open, so that the inspired air passes with difficulty, and a typical crowing sound is produced. The condition is often due to the irritation of too strong a vapour presented at an early stage, but even with the greatest care it cannot always be avoided. Once a spasm has been produced it is not easy to overcome it, and it is always liable to recur. A few breaths of air, followed by a much decreased concentration of anæsthetic vapour, may prove efficacious; should it succeed the concentration should be increased with great caution. In a fairly large number of cases the inhalation of four or five breaths of carbon dioxide, at the rate of about 500 c.c. per minute, will cause an immediate relaxation.

A complete laryngeal spasm, in which the glottis is absolutely closed, will sometimes occur, and will always be found when the patient is retching or vomiting. The only method of treatment is to cut off the anæsthetic supply, hold the chin well forward and wait; in due course the patient will have piled up a concentration of carbon dioxide which is sufficient to produce a stimulation of the respiratory centre strong enough to cause opening of the glottis. Preparation should be made to clear the mouth of vomited material, but should vomiting not take place, and it is necessary to continue the anæsthetic, this should be done with considerable caution.

Preparation of the Patient for Anæsthesia.—In emergency cases there may not be time to allow for really adequate preparation; sometimes food may have been taken recently and then, if it is at all possible, time should be allowed for the stomach to empty before the administration of an anæsthetic. In this connection it must be remembered that the excitement and shock of an accident may cause considerable delay in emptying.

Premedication.—Probably the most striking advance in anæsthesia in recent years is the great increase in the number of drugs which can be given as a preliminary to an anæsthetic. The object of all these drugs is to make the induction as pleasant as possible for the patient, to render the course of the anæsthetic smooth and trouble-free, and to enable the anæsthetist to use the minimum amount of the more toxic agents such as ether and chloroform.

Atropine.—A hypodermic injection of atropine can be considered almost essential before every general anæsthetic in order to decrease the secretion of mucus; without it the air passages of the patient may become so blocked that in some cases the administration is rendered virtually impossible. Atropine also reduces sweating, and hence helps to limit the amount of heat lost, and it may have some effect in diminishing the risk of vagal inhibition of the heart during induction with chloroform. The only drug which is as effective as atropine in limiting the secretion of mucus is scopolamine, and as this has also a sedative effect, it can be used with advantage before anæsthesia with gas and oxygen or with the intravenous agents. The correct dosage of atropine for adults is gr. $\frac{1}{100}$; children tolerate comparatively large doses, and any child over three years of age should be given gr. $\frac{1}{100}$, infants under six months should receive

gr. $\frac{1}{200}$, and from six months to three years gr. $\frac{1}{150}$. The injection must be given three-quarters of an hour before operation.

Morphia in doses of gr. $\frac{1}{6}$ to $\frac{1}{4}$ is sometimes used as a preoperative sedative. It helps to allay apprehension, and also reduces to a slight extent the amount of anæsthetic required, but it has a markedly depressing effect on respiration, and may render the production of a deep level of anæsthesia a much more difficult and hazardous task; hence its use is not desirable in cases in which a full muscular relaxation may be required.

Omnopon and Scopolamine.—Omnopon has a slightly greater soporific effect than morphia, and in combination with scopolamine it may produce drowsiness, or even sleep; more commonly it leads to a considerable degree of amnesia, and hence is a very suitable preliminary to operation under local or spinal anæsthesia. For this purpose the dose for adults is omnopon gr. $\frac{1}{3}$ and scopolamine gr. $\frac{1}{150}$, although for men of the strong muscular type the amount of omnopon may be increased to gr. $\frac{2}{3}$. This combination is also useful before gas and oxygen, and may be used almost as a routine before the intravenous anæsthetics. For this latter purpose it is wise not to exceed a dosage of omnopon gr. $\frac{1}{3}$ and scopolamine gr. $\frac{1}{150}$, and in old or feeble patients the scopolamine may be omitted.

Basal Hypnotics.—The above drugs serve the purpose of allaying apprehension and bringing the patient to the theatre in a more peaceful frame of mind, but they seldom produce sleep. There is now at the disposal of the anæsthetist a group of drugs which can be given to the patient in bed and which will enable him to be transferred to the operating-theatre while asleep; not only is this the ideal form of anæsthesia from the patient's point of view, but these agents are also more effective in reducing the amount of inhalation anæsthetic required. Although the surgical condition or the nature of the operation may contra-indicate the use of these basal hypnotics in certain cases, there still remain a very large percentage in which a suitable hypnotic can be chosen, and it must be emphasized that if the patient is to be given the full advantages of modern methods he should be asleep before the commencement of an inhalation anæsthetic whenever possible. The following are the basal hypnotics in common use:

Paraldehyde.—This is given as a rectal injection three-quarters of an hour before operation; the dose is calculated on the body weight of the patient—one drachm per stone—and the paraldehyde is made up as a 10 per cent. solution in normal saline. It has the advantage of being very safe, and is in frequent use for children, as it can be used for any child old enough to tolerate and retain a rectal injection. Its disadvantages are:

1. Its unpleasant smell, which is, however, more noticed by others than by the patient himself.

2. When used for adults the amount which has to be given may be rather excessive and is somewhat difficult to retain owing to its oily nature.

3. Its slow elimination, so that it leads to a prolonged post-operative sleep; hence it should be avoided when a long period with a rela-

tively inactive cough reflex, or with a depressed respiration, is undesirable.

Avertin (Tribromethyl Alcohol).—This is also for rectal administration. Although a full surgical anæsthesia can be obtained with it, any attempt to do so is to be strongly deprecated, as it entails marked risks of overdosage and respiratory depression. Used as a basal hypnotic it is very reliable, and essentially safe as long as care is taken in eliminating unsuitable cases. The contra-indications are suspected liver damage, advanced nephritis, and a low blood-pressure; also, if avertin is to be used for the very fat or for the cachectic patient, the dosage must be considerably reduced below the standard dose of 0·1 gm. per kilo of body weight. It gives rise to some respiratory depression, but this is neither so pronounced nor so prolonged as that produced by paraldehyde; any depression of the cough reflex which may be produced by avertin is so slight as to be negligible.

The Barbiturate Hypnotics.—Nembutal can be given intravenously, but in this field it has been almost entirely replaced by the newer drugs described below. For oral administration it is made up in gelatine capsules of 1½ gr., of which 2 or 3 may be given to an adult one hour before operation; this may be of use for an occasional case, but the results are too erratic for routine use. For the premedication of children it is a valuable agent; the standard dosage is 0·6 gr. per stone of body weight given mixed with jam or milk, and if the child is then left undisturbed in a darkened room, and the inhalation anæsthetic is started before he is moved, uniformly good results can be obtained.

Evipan Sodium is another derivative of barbituric acid for intravenous injection, it may be used as a sole anæsthetic for short cases, or as a means of procuring a pleasant induction. To obtain the best results preliminary medication with omnopon (gr. $\frac{1}{3}$) and scopolamine (gr. $\frac{1}{150}$) is desirable, this, with a full dose of evipan (up to 1 gm.) will give fifteen to twenty minutes' quiet anæsthesia, with a reasonable relaxation during the first half of this period. Evipan sodium is a white powder supplied in glass ampoules, and is readily soluble in 10 c.c. of distilled water; the intravenous injection is carried out slowly and the dose necessary to produce sleep is noted, as much again is then injected for full anæsthetic effect In some cases spasm of the jaw muscles may be pronounced, and it is advisable to use some form of mouth prop before beginning the administration. This form of induction is very pleasant, and the recovery is rapid and quite free from unpleasantness, although rowdiness occurs in a small percentage of cases. Consciousness is recovered in about half an hour, but it is two hours or so before it is safe to allow the patient to return home.

Pentothal is another intravenous anæsthetic of the barbiturate class. It is similar to evipan in action, but is a much more potent drug and is capable of producing a deeper and more lasting effect; thus ½ gm. of the drug (10 c.c.) will give about twenty to forty minutes' anæsthesia, provided that premedication with omnopon and scopolamine has been supplied, and during the first two-thirds of this

period an almost full muscular relaxation is obtained. It can be used as a single-dose anæsthetic, either for short cases or for induction, or it can be used continuously—that is, in repeated fractional doses—for longer cases. Whichever technique is employed the initial dose may be given in the following manner: ½ gm. (10 c.c.) or 1 gm. (20 c.c.) of pentothal is dissolved in distilled water in a syringe, the vein puncture is made, and 2 or 3 c.c. are injected at a slow rate of about five seconds per c.c. A pause of at least half a minute follows to observe the result, and then the injection is continued slowly and cautiously about 2 c.c. at a time, with a slight pause between every dose, during which the respiration is watched closely, and the injection is stopped as soon as the respiration has reached a certain level of depression; this point can only be judged by experience. If the pentothal is to be continued throughout, a drip saline is attached to the needle, and further injections can be made by piercing the rubber tube of the saline apparatus or by the three-way flow apparatus of Jarman and Abel. In cases in which an inhalation anæsthetic is to be combined with pentothal, this should be started immediately after intravenous injection, and it will follow a normal course except that much less anæsthetic will be needed. An initial dose of pentothal, followed by gas and oxygen, provides an anæsthetic which can be continued smoothly and easily for long periods, and allows for a deeper plane than will gas and oxygen alone; this combination has a wide field of application, and the absence of after-effects renders it a most satisfactory anæsthetic from the patient's point of view, while the gas and oxygen prevent that fall in blood-pressure which is sometimes troublesome with pentothal alone. It should always be borne in mind, however, that pentothal is a very powerful agent, and deserves respectful treatment; if a patient is a bad risk either by reason of shock or toxæmia, that risk is much greater with pentothal than with the more ordinary agents. Other contra-indications to its use are a low blood-pressure, liver disease, respiratory obstruction from tumours or inflammation in the neck or chest, or cardiac lesions sufficiently marked to cause dyspnœa on moderate exertion; also pentothal should never be given to a patient receiving drugs of the sulphonil-amide group, owing to the presence of a sulphur group in both drugs and the consequent risk of liver failure.

After-Treatment.—The patient should be put back to bed with as little disturbance as possible, and with the head turned to one side so as to allow the escape of any mucus or vomit, and a nurse should be in constant attention until consciousness has returned. Following operations in the mouth, nose, or throat the patient should lie on one side during this period in order to lessen the risk of inhalation of blood. If an airway has been used, it should be left in position until it is quite certain that a free airway can be maintained without it. The use of a tongue clip should never be necessary; it is a barbarous implement and is capable of causing considerable damage; if there should be difficulty in preventing the tongue from falling back, it can be overcome by the use of a metal tongue spatula, which is more effective and much less likely to produce trauma. The bed in which he is

placed should have been warmed, but hot-water bottles *must* be removed; every year a certain number of patients are burnt owing to the neglect of this elementary precaution. The need for saline, or for sedative or stimulant drugs should be discussed with the surgeon, and ordered in writing before the patient leaves the theatre.

Post-operative vomiting is due to a variety of causes. Some persons are more prone to vomiting than others, such, for example, as suffer from car or train sickness, and these are undoubtedly more liable to get excessive post-anæsthetic vomiting. The more toxic anæsthetics such as ether and chloroform will produce more sickness, firstly because these agents will become absorbed in mucus which drifts into the stomach and sets up a mild gastritis, and secondly because large amounts of such anæsthetics give rise to a ketosis. Excessive manipulation of intestine is an added factor, and hence the surgeon must share the responsibility for vomiting after abdominal operations; other surgical causes are the presence of blood in the stomach after nose and throat operations, and in some patients the presence of radium in the body. Much can be done to avoid this distressing complication by careful selection of anæsthetic agents, and by the use of minimum amounts of the more toxic ones; by making the induction as smooth as possible so that swallowing and retching do not occur; by avoiding starving and purgation before operation; and by pre-anæsthetic administration of glucose or barley sugar so as to keep up the carbohydrate reserve in the body and lessen the likelihood of ketosis.

If vomiting occurs the patient should be given copious drinks of warm water containing sodium bicarbonate, as this serves to wash out the stomach. Other measures worthy of trial are the administration of a few minims of tincture of iodine in water, drinks of champagne or black coffee, or the sucking of slices of pineapple. If ketosis has been produced the administration of 10 units of insulin with 20 gm. of glucose may prove very effective. Should vomiting continue in spite of these measures the possibility of a surgical cause should be considered.

Delayed chloroform poisoning is a condition very rarely seen nowadays, owing to the infrequent use of chloroform; it presents a clinical picture of pernicious vomiting and jaundice, very similar to that of acute yellow atrophy of the liver, and the post-mortem findings are practically identical; treatment is merely symptomatic, and the condition is always fatal. Every chloroform anæsthesia gives rise to certain marked liver changes which persist for several weeks, so that this agent should never be used for any case requiring two or more anæsthetics at short intervals; nor should it be administered if there is any doubt as to the efficiency of the liver function. Care should be taken to avoid the use of chloroform with any other agent, such as avertin or pentothal, which may have an effect on the liver, and it should be remembered that during pregnancy the liver is particularly liable to be affected by chloroform.

Nitrous Oxide (N_2O).—This gas forms the basis of a very large percentage of all anæsthetics given to-day. It can claim to be the

safest of all anæsthetics, as the only danger in the administration of nitrous oxide lies in asphyxia, and this can be produced only by gross misuse; moreover, it has no effect on the general metabolism of the body, and as it is excreted through the lungs elimination is very rapid Its only disadvantage lies in the fact that it is capable of producing only a light plane of anæsthesia, and hence this gas by itself is not sufficient for major abdominal surgery. It can be used with air for short operations such as the incision of abscesses, dental extractions, etc., but if a prolonged anæsthesia is required the gas must be given in combination with oxygen so that the inert nitrogen in the air may be replaced by nitrous oxide. It may also be used to reinforce, or may be reinforced by, any of the other anæsthetic agents.

Gas-and-Air Anæsthesia.—For this purpose the cylinder of nitrous oxide is connected by tubing to a rubber Cattlin's bag, which is in turn joined to the facepiece by a metal joint in which is incorporated a three-way valve. By manipulating this valve the patient can be made to inspire air, while gas is retained in the bag; or the patient can inspire gas from the bag and expire into the surrounding air; or finally the patient inspires from the bag and expires into it, a process known as rebreathing. Induction with nitrous oxide is started by applying the facepiece to the patient's face with the valve in the open position so that the patient gets a few breaths of air, the valve is then slowly pushed across until the 'valve's' position is reached and pure gas is inhaled. Respiration continues thus until fairly marked cyanosis is produced, and then the valve is opened to allow for one or two breaths of air; the anæsthetic can then be continued, either by giving one breath of air every five or six breaths of gas, or by putting the valve in such a position as to allow the continued entrance of a small trace of air. The period of time during which such an anæsthesia can be produced is limited, its length depending upon the skill of the administrator and the personal variation of the patient. This method can be used for short dental extractions, the facepiece being removed when a full anæsthesia has been produced, to allow the operator access to the mouth, but for longer dental work the facepiece is replaced by a small nasal inhaler and the patient is instructed to breathe only through his nose; if nasal breathing is once established it will continue throughout unconsciousness, particularly if the gas is delivered under a positive pressure sufficient to keep the soft palate forward and so occlude the oral airway. The advantage of the nasal method is that the gas can be continued during the extraction, thus allowing for a more careful and deliberate removal of the teeth than is possible under the ordinary 'straight' gas. Another important use of gas-and-air anæsthesia, or more correctly in this case analgesia, is in midwifery. For this purpose a special apparatus is required; there are several types available, but the original and most common is the Minnitt apparatus. In this machine gas is delivered into a small bag by means of a special reducing valve which automatically cuts off the supply as soon as the bag is full; when the amount in the bag is reduced by inhalation the valve allows more gas to enter, so that the supply is controlled entirely by the patient's respiration. At the

same time each inhalation draws into the mask sufficient air to render the mixture breathed by the patient approximately 45 per cent of nitrous oxide and 55 per cent air. When the patient feels the beginning of pain she applies the facepiece while keeping her finger over a special air inlet hole, and breathes in this mixture; should she become quite unconscious she can no longer arrest the air supply, and the mask



FIG. 1026.—MINNITT GAS-AIR APPARATUS (HOSPITAL PATTERN).

falls from its position, thus automatically cutting off the supply of gas; hence overdosage or asphyxia is quite impossible. In most cases full anæsthesia is not obtained, but with a patient who co-operates well a very fair degree of analgesia can be produced, the advantage of this apparatus is that it can be worked by a qualified midwife or by the patient herself, and the presence of an anæsthetist is not required, although to make labour as painless as possible a full gas-and-oxygen anæsthetic should be given during the second half of the second stage.

Gas-and-Oxygen Anæsthesia.—When oxygen is combined with nitrous oxide a light surgical anæsthesia can be provided for any length of time which may be required by the surgeon. In order to obtain uniformly good results it is necessary for the anæsthetist to be able to adjust very accurately the proportions of each gas; there are several machines available at the present time which enable this to be done, and it is not possible here to describe each in detail. They can, however, be classified in two main groups: the continuous-flow apparatus and the intermittent-flow apparatus. In the latter type the flow of gas is cut off while the pressure in the bag remains high—that is, while the patient expires—and is restarted as soon as the pressure falls with inspiration In the continuous-flow type the stream of gases continues unchanged during both phases of respiration.

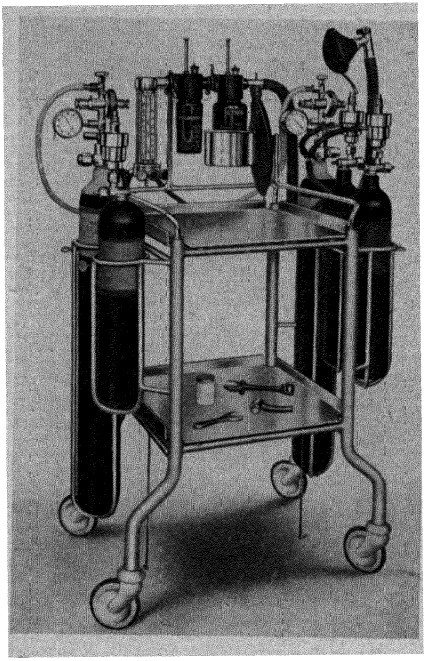

FIG 1027.—BOYLE'S GAS-OXYGEN-ETHER APPARATUS

The Boyle Apparatus.—This is the standard example of the continuous-flow machine, and has the advantage of being simple in operation, and also of being able to supply not only gas and oxygen but also ether and chloroform vapour in any amount that may be necessary; thus it can be used for any kind of anæsthetic and for any type of surgical operation. It consists of a flow-meter for measuring the relative amounts of each gas, and in the older types this flow-meter was a bottle containing water into which passed metal tubes with side-holes, and the quantity of gas passing was measured by the number of holes through which the gas bubbled. This rather inaccurate 'water-sight flow-meter' is now usually replaced by one of the many dry types in which the amounts of gas are fairly accurately recorded in litres per minute by means of bobbins rising and falling

in a glass tube. The rest of the apparatus consists of two bottles, a small one for chloroform and a larger one for ether: at the top of each bottle is a tap by turning which the mixture of gases can be made to pass through the appropriate bottle. The gases pass through a U-tube over the top of which a plunger is fitted, and by suitable adjustment of this the anæsthetist can allow them to blow through the bottle, to pass across the top of the ether or chloroform, or to bubble through the liquid itself if a really large dose is required. The emerging mixture is then carried by means of a wide-bore unkinkable tube to the facepiece, on the top of which is a spring-loaded expiratory valve which allows for the adjustment of the rebreathing into the

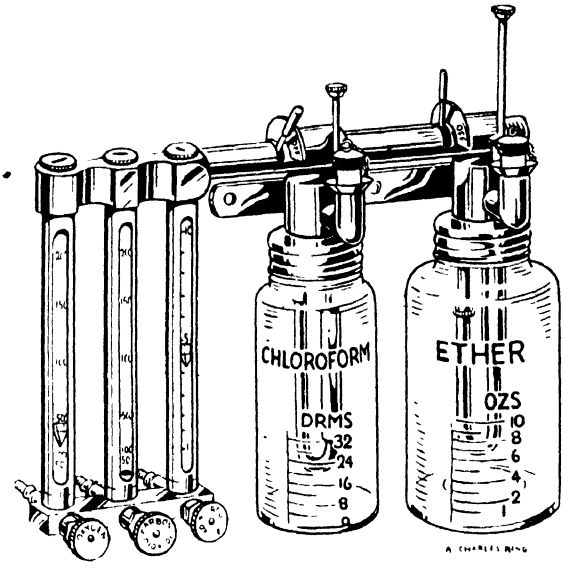

FIG. 1028.—DETAILS OF BOYLE'S APPARATUS, WITH MODERN TYPE FLOW-METER (ROTAMETER)

small bag attached to the side of the tube. This wide-bore tube, bag and expiratory valve constitute the 'Magill attachment,' which is more efficient and easier to manage than the old arrangement of having a tube leading to a large bag close to the patient's face.

Intermittent Flow Machines—The Walton Apparatus.—In this apparatus gas and oxygen are supplied into separate bags by means of special reducing valves which allow the gases to pass only when the pressure is reduced by inhalation, as was described in the Minnitt apparatus. Both bags are gently compressed by a steel spring in order to keep up a constant slight pressure, and they feed the gases into a single mixing valve, arranged so that, by the manipulation of a single handle varying percentages of oxygen from 0 to 100 per

cent. can be supplied to the patient at will. A separate rebreathing bag and an ether bottle in which the ether is vaporized through a gauze wick can be thrown into circuit if required, and a foot pedal provides for increased pressure of gases if that should be necessary. This machine is a popular and very effective one for dental gases and for administering gas and oxygen during labour, but is less suited to the purposes of anæsthesia for major surgical operations.

The McKesson Apparatus.—The main principles of this are similar to the Walton described above, but here the bags are enclosed in metal containers, and the pressure under which nitrous oxide is delivered can be accurately controlled and read off by means of a special dial There is also a separate control for oxygen percentages, and an emergency oxygen button by pressure on which the patient's lungs can be flooded with oxygen even against considerable resistance. A rebreathing bag and ether bottle are provided for use if required. As a pure gas and oxygen machine this is extremely efficient, but more skill and practice are required in order to get the best results.



FIG. 1029.—WALTON GAS-AND-OXYGEN APPARATUS

Method of Using the Boyle Apparatus.—Whether the anæsthetic given is to be gas and oxygen only, or whether any volatile anæsthetic is to be used in addition, the same method can be used for induction. The gas is turned on at a rate of about five or six litres per minute, and the facepiece is held away from the patient's face; if the patient is conscious he should be instructed to shut his eyes and to breathe quite gently and naturally. The mask is then quietly lowered until it begins to make contact with the face, the patient meanwhile being encouraged with soothing remarks or with a gentle stroking of the brow; there is a tendency with the inexperienced to interfere with the patient at this stage, either by trying to open the eyes, or by putting fingers under the chin in an effort to hold it up; both these procedures are unnecessary and should be avoided, as they are very disconcerting

to the patient. It must also be borne in mind that hearing is very acute during the induction of anæsthesia, and absolute quiet is essential until the patient is completely unconscious. After a few moments the patient becomes "muzzy," and then a gentle but firm contact must be made between the mask and the face; a good deal of the trouble that the beginner finds in gas induction lies in allowing air to leak in round the sides of the facepiece and dilute the nitrous oxide. At the same time any effort to press the mask into position, or any effort on the part of nurses or assistants to hold the arms or head, is likely to be resented, and is a frequent cause of struggling. After a certain length of time a slight cyanosis becomes apparent, and this may be accompanied by stertor; as soon as this cyanosis appears a small amount of oxygen should be added to the mixture; this should be about 500 c.c. to 1 litre a minute, and the expiratory valve can then be screwed down so as to allow the rebreathing bag to become just tight at expiration. The result of the addition of oxygen is watched for a few breaths: if it is insufficient the colour does not improve, or may become worse, and the stertorous breathing continues; if the amount is too great a pink colour is produced and movement may occur. If the amount added is correct the patient's colour improves so as to produce a barely perceptible cyanosis, and the respiration takes on a quiet, steady rhythm; this colour and rhythm must be kept, and to do this it will often be necessary to vary the percentage of oxygen in the mixture from time to time. To obtain the best results from gas and oxygen three important points should be borne in mind: a long induction (preferably ten minutes or more) is necessary before the operation is started; the oxygen percentage should be varied only fractionally, and any sudden large alterations are to be avoided; lastly, the inexperienced usually gets into trouble by giving too little oxygen rather than by giving too much, as sub-oxygenation leads to muscular rigidity, obstruction to the airway and perhaps vomiting.

Ether.—Although the general tendency is to replace ether by other agents which are less toxic and more rapidly eliminated from the system, at the moment ether still forms the basis of a very large number of all anæsthetics given in this country. The reason for this is that it fulfils the first and most important requirement of an anæsthetic—if given with reasonable care and skill it is essentially safe. This safety lies in the fact that in moderate doses it is both a respiratory and circulatory stimulant, and is also due to its being a slow-acting anæsthetic, so that in most cases the signs of overdosage are apparent some time before the condition of the patient has become really dangerous. Ether has the disadvantage of being strongly irritant to the bronchial mucous membrane, and hence it is very unpleasant to breathe and liable to give rise to coughing and breath-holding; for this reason it is not suitable for the initial stage of induction. The usual procedure is to use gas, ethyl chloride or other agents for this purpose, and to add ether only when unconsciousness has been produced, and even then it has to be introduced very slowly and carefully, so that by increasing the concentration of ether vapour

gradually the mucous membrane may become acclimatized to its pungency. During the stages of light and medium anæsthesia ether acts as a stimulant of respiration, so that both the rate and depth of the breathing are increased; during these stages, also, the blood-pressure is raised in spite of some degree of vaso-dilatation, and these two factors combine to give rise to increased bleeding, which may be a disadvantage from the surgical standpoint. With deep anæsthesia the blood-pressure falls and respiration becomes depressed. During the early stage, particularly in children, an erythema over the neck and chest is seen on occasion, probably as a result of the vaso-dilatation; this is commonly called an 'ether rash,' and is unimportant as it has no harmful effect and is quite transitory.

The irritant effect of ether on the mucous membranes has been blamed in the past for the occurrence of post-anæsthetic chest complications such as bronchitis and pneumonia; it is generally considered nowadays that this action has been overrated, as the incidence of such complications is almost as high after chloroform, spinal or local anæsthesia. Ether should, however, be avoided whenever possible in cases that already have some pathological condition in the chest; for cases of pulmonary tuberculosis it is contra-indicated, while for the patient with bronchitis or emphysema it should be used as sparingly as possible. It should not be forgotten, however, that the typical fat, emphysematous patient is probably possessed of a poor cardiac muscle and is seldom a suitable case for chloroform; a post-anæsthetic bronchitis will probably respond to treatment, but there is very little that can be done for a primary cardiac failure during or immediately following operation.

Ether Convulsions.—Two types can be recognized. The first is a clonic movement, usually confined to the legs, which occurs not unfrequently during light anæsthesia before muscular relaxation has been established; it passes off as anæsthesia progresses and is quite free from danger. The second type is much more serious, and is the condition to which the term 'ether convulsions' is usually applied. It always starts during deep anæsthesia, and nearly always in the patient already suffering from a fairly serious toxæmia and having a high temperature. This condition invariably begins with twitching of the muscles round the mouth; this twitching spreads rapidly until practically every muscle in the body is in violent clonic movement, including the intercostal muscles, with the result that the patient becomes cyanosed owing to lack of proper respiration. The convulsion continues for any period up to ten or fifteen minutes and then stops with dramatic suddenness. This violent muscular effort gives rise to profound shock if it lasts for more than a minute or so, and death, which is an only too common sequel to prolonged ether convulsions, is probably due to shock. Many theories have been advanced as to the causation of this condition; oxidation products in the ether, heat-stroke, and cerebral congestion have all been suggested, but none has as yet been proved. As regards treatment the most important thing is to recognize the onset early, before the convulsions become general; if the ether is stopped as soon as the

typical twitching of the mouth is seen in most cases the clonic movements will not become severe and will not last long enough to produce very bad shock. In all cases the ether must be discontinued, and oxygen, together with about 5 per cent. carbon dioxide, administered. Raising the head and compressing the carotid arteries has sometimes proved successful, while the intravenous injection of morphia, luminal, or evipan have all been used with good results by different observers, although care should always be taken to allow for the shocked state of the patient when using such intravenous therapy. It seems probable that more deaths have resulted from the various forms of treatment applied for this condition than have been occasioned by the condition itself; the original cure consisted in stopping the ether and administering chloroform instead, with the result that the mortality rate was practically 100 per cent., whereas since this method of treatment has been abandoned the mortality rate has fallen to round about 20 per cent. Every effort should be made to see that the new ' cures ' do not prove so lethal.

Explosions.—Ether vapour is highly inflammable, and therefore is contra-indicated when any form of cautery or diathermy is to be used; nor should it be administered for bronchoscopy, as explosions have occurred because of faulty connections and consequent shorting in the bronchoscope. The method of inducing with ether and continuing with chloroform for such operations cannot be considered to be a safe one. While the mixture of ether and oxygen is the most highly explosive, the addition of nitrous oxide does not decrease the risk. The liability to explosion is much greater in the modern theatre with its artificially dried atmosphere than the older ones where moisture vapour is nearly always present. Explosions have occurred as the result of sparking from static charges set up in trolleys by the friction of blankets, etc.; these can be prevented if all rubber-tyred trolleys are earthed to the floor by a short length of metal chain.

Methods of Ether Administration—Closed Ether.—This term is usually used to embrace all methods of administration in which rebreathing takes place, whether that rebreathing be total, as with the intermittent-flow type of machine and with the carbon dioxide absorption circuit, or only partial, as is the case with the continuous-flow machine. It is undoubtedly the best way of giving ether, as it allows for a much easier control of the depth of anæsthesia than is possible with the open method, and greatly reduces wastage of ether.

In the case of the Boyle apparatus, the ether bottle is turned off and the plunger is pulled well above the level of the liquid, and then induction is started exactly as for gas-and-oxygen anæsthesia with several breaths of pure gas; immediately before that stage is reached at which oxygen becomes necessary, the lever of the ether bottle is turned on for a brief period so that a very small dose of ether vapour is added to the gas. The necessary flow of oxygen is then started, and another small dose of ether is again introduced; by slowly pushing down the plunger and by leaving the tap in the ' on ' position for a little longer each time, the concentration of ether vapour is gradually increased. After each dose of ether is given a pause of two or three

breaths should be made in order to watch the effect on the patient; so long as this is slight, such as an increase in rate or depth of respiration, the concentration may be increased for the next dose, but if breath-holding, swallowing or coughing should occur it is essential that time should be allowed for the respiration to return to normal before a further dose is added. There is a correct rate of progress for each individual patient, and this can be ascertained only by careful observation of results, if the ether concentration is increased too rapidly coughing and subsequent congestion are produced, while if the rate is too slow there may be a prolongation of the excitement period, and both these complications are to be avoided. After the first few minutes most patients become much more tolerant of ether vapour, and the dosage can be pushed faster until the required level of anæsthesia is attained, when the dose can be reduced considerably in order to maintain this level. A very similar method of induction can be used for any of the other machines, although varying ways of vaporizing the ether are encountered, and this will necessitate some small alteration in the technique.

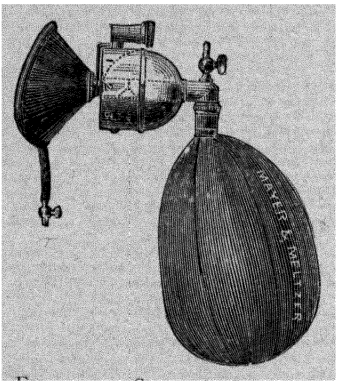

FIG. 1030.—CLOVER'S INHALER

Another method of giving closed ether is by means of Clover's inhaler. Although this piece of apparatus was produced many years ago it still remains an excellent method of induction, particularly if the anæsthetic is to be continued with open ether. Clover's inhaler consists of a spherical ether reservoir lying between the facepiece and the rebreathing bag; this ether chamber can be rotated on the central tube, and as this is done an arrangement of slots allows a slowly increasing proportion of the patient's breath to pass over the surface of the ether. Induction is begun with the bag full of gas, and ether is introduced in very much the same way as described above, except that the ether chamber is turned a small fraction of a turn every two or three breaths, instead of the tap of the ether bottle being turned on. As no allowance is made for the supply of oxygen, the facepiece has to be lifted every few breaths in order to keep the patient's colour good.

Open Ether.—This method of administration has the advantage of being the safest possible way of giving ether, and also of requiring only the simplest of equipment. On the other hand, it is very extravagant with ether, as much of the agent does not reach the patient but evaporates into the surrounding air to the discomfort of those working in the theatre, also the anæsthetic is much less controllable than is the case with closed methods, owing to the fact that it is difficult to maintain a high concentration of ether vapour in the inhaled air. It will also be found that the rapid evaporation that takes place gives rise to a very marked loss of heat, so that the patient

inspires very cold air; this may have some influence on the production of chest complications, and it certainly hastens the onset of shock by reason of the rapid loss of body heat. The apparatus required is a bottle, preferably of the flat medicine-bottle type, fitted with a Bellamy-Gardner dropper; also an open wire mask, of which there are several types in common use, and which is covered with at least eight to ten thicknesses of gauze, so as to form an absorbent pad which will retain a fair quantity of ether and limit evaporation as far as possible. Many anæsthetists place above and below this wire mask a gamgee mask consisting of a square of gamgee tissue with a hole cut in the middle; the purpose of this is to aid in the concentration of the vapour, and to prevent any excess of liquid ether running over the patient's face. If it is decided to start the anæsthetic by the open method, the mask is applied to the patient's face and a few drops of ether are allowed to fall on it; a short period is allowed for the patient to become used to this and then the process is repeated, and so on, each dose of ether being slightly larger than the last. There is nothing to be said in favour of this as a means of induction, the pungent vapour is extremely unpleasant, and the whole process is so slow that only individuals with very pronounced self-control will submit to it. In every case some other agent should be used for induction, and the change-over to the open mask should be made only when a medium surgical anæsthesia has been established. It may sometimes be necessary, in spite of a good airway and the adequate amount of air provided by this method, to run a small stream of oxygen under the mask or into the mouth, so as to keep a pink colour throughout a long anæsthesia; this may be done by pinning the rubber tube carrying the oxygen supply on to the under-surface of the gauze of the mask, or by attaching a piece of malleable lead tube and hanging this in the corner of the mouth. Continuation of an open-mask anæsthetic can be provided by pouring liquid ether on to the gauze from time to time according to the needs of the patient; or a useful variation is to bubble oxygen, or gas and oxygen, through ether in a Boyle's machine, and to carry the resulting mixture under the gauze mask by means of a rubber tube. This has the advantage of providing a steady level of anæsthesia, and is of value when the operation is prolonged. Many artificial airways are provided with a special tube which can be attached to an oxygen cylinder, and this tube can also be utilized for the anæsthetic.



FIG. 1031. MAGILL'S ATTACHMENT FOR CONTINUOUS-FLOW APPARATUS

Rectal Ether.—It is possible to give ether *per rectum* as a basal anæsthetic, and before the discovery of avertin it was used frequently in cases in which the minimum of inhalation anæsthetic was desired. About 2 ounces of ether was mixed thoroughly with 5 or 6 ounces of olive oil and injected into the rectum; the results on the whole were reasonably good if somewhat erratic. The mixture was rather irritating to the rectal mucous membrane, and not easy for the patient to retain, and it has been almost completely replaced by the more modern agents.

Chloroform ($CHCl_3$).—The relative merits of ether and chloroform have given rise to much controversy in the past. On the whole, chloroform has slowly lost the battle, and although it still retains a definite field, this is a limited one, and the modern teaching, and undoubtedly the correct one, is that it should be used only when no other agent can be found that answers all requirements. Thus in some cases in which the diathermy is being used in the neighbourhood of the mouth or throat, for an occasional bronchoscopy, or for some chest surgery, it may be found to be the ideal anæsthetic. The advantages of chloroform are that it is the easiest anæsthetic to give, as a smooth anæsthesia can be maintained at almost any depth, without the same risk of coughing as with ether; it requires only the simplest apparatus, namely a drop bottle and a mask, and unlike ether it can be used for induction as well as for the continuation of anæsthesia; also, being non-inflammable, it can be administered as well in front of the kitchen fire as in the theatre. Its disadvantages are: it is simple to give, and hence is the agent frequently chosen by the unskilled, for whom it is the most unsuitable anæsthetic; it is a very potent anæsthetic and the risk of overdosage is considerable except in the hands of the most experienced; death can occur suddenly and without warning in the early stages of a chloroform anæsthesia, it has a well-marked depressing effect on both respiration and circulation; the signs of the various stages are much less obvious than with ether.

The only safe method of giving chloroform is the open one, using a wire mask covered with a single layer of lint. This is held a few inches from the face and one or two drops are allowed to fall on it; the mask is approximated slowly to the patient's face, and a few more drops are added; the procedure is repeated with a gradually increasing dosage of chloroform, until the desired plane of anæsthesia has been reached, and then a few drops from time to time should be sufficient to keep this plane. When giving chloroform it is of the utmost importance that the airway should be kept perfect all the time, and that the colour of the patient remains quite pink. Chloroform exerts a marked toxic effect on the cardiac muscle, and in the presence of sub-oxygenation this effect is greatly increased. Sudden cardiac failure can occur during the induction stage with chloroform, probably due to ventricular fibrillation; the exact mechanism of this is obscure, but there seems reason to believe that an increased secretion of adrenalin produced by fear or struggling plays an important part. Chloroform vapour can be given in a manner similar to that used for ether, by blowing air or oxygen through the liquid; this was originally

done by means of Junker's inhaler, a small bottle having a metal tube passing just below the surface of the chloroform; the vapour which resulted from the passage of air through the liquid was collected by a second tube, the inlet of which was immediately below the screw cap. Great care had to be taken to connect these tubes correctly, as if they were put on the wrong way a stream of liquid chloroform was forced into the patient's throat; a number of fatalities have been caused by this mistake. Nowadays practically every Junker's inhaler is fitted with a special valve which renders this error impossible, but nevertheless the apparatus should always be tested under a full stream of oxygen before it is attached to the patient.

The Use of Chloroform in Midwifery.—Until the popularization during the last year or so of the Minnitt gas-and-air machine, nearly every woman who had any sort of anæsthetic during labour was given chloroform. It has many advantages for this purpose, as it is easy to transport, and it produces a marked analgesic effect very quickly and in very small amounts; moreover, the hypertrophied heart of the pregnant woman is tolerant of chloroform, so that the risk of cardiac failure is greatly decreased. It has, however, two rather serious disadvantages: a slight increase in dose will completely inhibit the action of the uterus, and the unstable state of the liver in pregnancy renders it much more liable to delayed chloroform poisoning. In spite of this it is probably the best alternative to gas and oxygen, or gas and air, in outlying districts where these more ideal methods are impossible. Experiments have been carried out in the use of capsules, containing three minims of chloroform, which can be broken on to a mask by the midwife in charge of the case, although this procedure is free from risk, the results obtained so far have not been entirely satisfactory.

Anæsthetic Mixtures.—Many mixtures have been popular in the past, all for use as open anæsthetics, but with the introduction of so many new agents, and the decline of the 'open' method, the need for them has almost entirely passed. A mixture of alcohol 1 part, chloroform 2 parts, and ether 3 parts, commonly known as 'A.C.E. mixture,' was very widely used, as was also the 'C. and E. mixture,' which consisted of chloroform 2 parts and ether 3 parts. Many anæsthetists had their own special mixtures in which 1 part of chloroform was included in 8, 10, or even as much as 20 parts of ether. The difficulty with all these lay in the fact that the more volatile ether tended to evaporate first, leaving a mixture consisting of a rapidly increasing proportion of chloroform.

Ethyl Chloride (C_2H_5Cl).—This is a very volatile liquid which is capable of producing a full anæsthesia with extreme rapidity. It is also a strong cardiac depressant, and this fact, together with its rapid rate of evaporation, renders it unsuitable for prolonged anæsthesia, although it is of considerable value for short operations where only one or two minutes' unconsciousness is required, or for induction, particularly in children. It may be used in a closed system which consists of a facepiece and a bag having a special valve fitting into which the nozzle of the ethyl spray can be inserted; 2 to 5 c.c.,

according to age, are injected into the bag, and the mask is applied to the child's face so as to catch an expiration and distend the bag; two or three breaths will suffice to produce unconsciousness, and a further four or five will give a fairly complete anæsthesia, with a partially dilated pupil and stertorous breathing. Should the anæsthesia produced not last a sufficient time to enable the operation to be completed, a further small dose may be given, but more than two doses should never be given. Some anæsthetists fill the bag with oxygen before introducing the ethyl chloride, and there is much to be said for this technique, as by reducing the percentage of carbon dioxide breathed by the child and lessening the depth of respiration, it slightly slows down the action of the anæsthetic. Given by the closed method, ethyl chloride is a very powerful and rapidly acting agent, and cannot be recommended for the inexpert; the open mask administration is undoubtedly safer, and at the same time gives uniformly good results. An ordinary gauze mask is used as for ether, and 2 to 4 c.c. are sprayed on to it, the exact amount depending on age; the mask is then lowered gently over the child's face, and after two or three breaths consciousness will have been lost; a further 2 or 3 c.c. will probably be required to obtain a full anæsthesia. A very similar routine may be followed when ethyl chloride is used for induction in adults. It cannot be considered an ideal way of producing anæsthesia, as it has a decidedly unpleasant smell, and is apt to give rise to a feeling of suffocation, but its merit lies in its speed, and this accounts for its popularity with the occasional anæsthetist, who finds that his patients prefer the rapid execution of ethyl chloride to the slow torture he is liable to produce with other agents. For short operations in children, particularly for dental extractions, incision of abscesses, etc., it is a very good anæsthetic, as the very young are bad subjects for gas owing to the ease with which an excessive cyanosis may occur and the rapidity with which they recover from the effect of gas; ethyl chloride gives that extra minute which is so important, while the after-effects are slight.

Ethylene (C_2H_4).—This gas has been used to a considerable extent in America. It is similar in action to nitrous oxide, except that the induction time with ethylene is shorter and a better muscular relaxation can be obtained, and it can be used with a slightly higher percentage of oxygen. The disadvantages are that it not unfrequently leads to distressing post-operative nausea, and that its smell is so unpleasant as to render work in a theatre almost impossible unless a special exhaust mechanism is used; moreover, it is highly explosive. Owing to these defects and to the introduction of cyclopropane, it appears to be going out of use.

Acetylene can also be used as an anæsthetic. It has an action very similar to that of ethylene, and almost identical disadvantages.

Cyclopropane (C_3H_6).—This gas has not yet fully graduated out of the experimental stage; there seems to be little doubt that it is a very valuable agent, and will occupy a definite place among the accepted anæsthetics, but the exact limits of its field have yet to be determined. It has a slight but not too unpleasant smell, and is non-irritating to

the lungs; moreover, it is a powerful anæsthetic capable of producing a full anæsthesia in the presence of a very high percentage of oxygen; thus about 15 per cent. of cyclopropane in oxygen is able to produce a fair degree of relaxation. Its disadvantages lie firstly in its expense, as the cost is just over two shillings per gallon, this makes the use of a carbon-dioxide absorption circuit essential, and with this the cost is not excessive. It appears to have some deleterious effect on the cardiac muscle when used in high concentrations, with the result that bradycardia or arrhythmias may occur, the exact significance of these is not fully understood as yet, but it seems possible that the perfection of the technique of administration may eliminate them. It is also extremely explosive, so that it should never be used with the cautery or any form of electrical apparatus. The marked respiratory depression produced by cyclopropane renders the use of any premedication undesirable, and also makes the signs of depth of anæsthesia somewhat difficult to follow, and it is very easy to push the patient to a stage of respiratory arrest; hence it is not an anæsthetic for the inexpert.



The rapid recovery from cyclopropane, and the fact that it may be given to patients suffering from any chest condition without fear of making that condition worse, are attributes of the greatest value, and there is little doubt that it will occupy an important position among the anæsthetics of the future

Carbon Dioxide (CO_2).—Although not an anæsthetic, carbon dioxide is of such use to the anæsthetist that it deserves mention. It is a very strong respiratory stimulant, and may be of great service when an overdose of anæsthetic has led to a respiratory failure. It may also be used in moderation to shorten the induction period or to overcome a spasm of the vocal chords; many anæsthetists give a few breaths as a routine before attempting to pass an endotracheal catheter, as it makes the vocal chords open to their fullest extent and renders this manipulation much easier. The administration of 5 or $7\frac{1}{2}$ per cent. CO_2 in oxygen post-operatively will produce hyperventilation of the lungs and assist in the rapid elimination of ether. Carbon dioxide should never be given excessively for any purpose; if a few

breaths of 5 or 10 per cent. do not give the desired result it is unlikely that an increased dosage will be of any value; moreover, the respiratory centre soon tires if stimulated to excess, and difficulty in establishing a good respiratory exchange may result.

Carbon Dioxide Absorption.—The greatest fault of the partial rebreathing method of administration lies in the fact that the patient's expired air, containing a relatively high percentage of carbon dioxide (about 4 per cent.), is returned into the bag and thence rebreathed. This causes an increased depth and rate of respirations which, although useful during induction, are unnecessary and may be troublesome for the surgeon when anæsthesia is fully established. Moreover, a certain amount of heat and moisture is lost to the patient in each expiration. In order to overcome these difficulties it is possible to include in the circuit a canister containing soda lime (sodium calcium hydrate), which serves to absorb most of the carbon dioxide. As the anæsthetic gases are returned from the lungs unchanged they can be used over and over again, and it is necessary only to add a small supply of oxygen, known as the basal flow, to suffice for the patient's metabolism. This represents a considerable economy in anæsthetic agents, in fact it is essential when expensive gases such as cyclopropane are in use, and preserves to the patient the heat and moisture which are ordinarily lost; moreover, it reduces the amplitude of respiratory movement very considerably, a fact appreciated by the surgeon. There are several efficient absorbers obtainable, of which the simplest is that designed by Waters, in which the canister is attached to the facepiece without the intervention of valves, so that both phases of respiration pass through the soda lime; more complicated pieces of apparatus are the Frankis Evans, and the MacKesson absorbers which allow for variation in the degree of absorption according to the needs of the patient.

Endotracheal Anæsthesia.—By this is meant the administration of an anæsthetic by means of a tube passing through the vocal cords and into the trachea. This manœuvre obviates the risk of obstruction to the airway either at the back of the tongue or by approximation of the cords, and so not only can the anæsthetic be given safely and easily when the surgeon is working in the neighbourhood of the head or neck, but also a smoother, quieter respiration can be established, and the level of the anæsthetic can be very easily controlled. There are two routes by which an endotracheal tube can be inserted, oral and nasal.

Oral Intubation.—This procedure is carried out with the help of a direct vision laryngoscope, of which instrument there are many types available, but one of the simplest and most effective is that designed by Magill in which a dry battery and rheostat are contained in the handle. Anæsthesia is induced by any suitable method, and continued until a fairly good degree of muscular relaxation has been established, this degree depending largely on the skill of the anæsthetist; the student should make his first few efforts under a very full anæsthesia. The laryngoscope is held in the left hand and passed back between the tongue and the palate until the posterior pharyngeal wall comes into view; the right hand is used to keep the lips and teeth

apart and to prevent them being damaged, and also to assist the instrument forward if necessary. A slight turn of the wrist directs the point of the spatula slightly forward, and the downward movement is continued until the epiglottis is seen. The tip only of the epiglottis is picked up by the tip of the laryngoscope, and the whole instrument is lifted forward and the point turned slightly in the same direction until the larynx is exposed; if the laryngoscope is inserted too far under the epiglottis the whole larynx is lifted forward and becomes invisible. Great care must be exercised in this manœuvre not to press on the incisor teeth, as it is easy to damage these. When a clear view of the cords has been obtained, and not before, an endotracheal tube lightly smeared with lubricant can be passed between them (Fig. 1034). The older types of endotracheal catheter consisted of a semi-rigid, thin tube of the gum-elastic type, which served to convey the anæsthetic vapour, while the expired air passed out round the tube; the type which is more popular to-day is the Magill catheter, and is a much

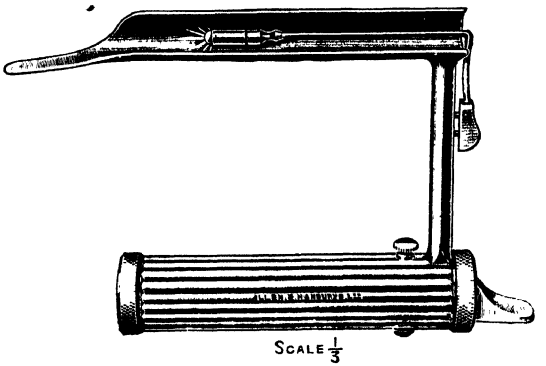

FIG. 1033.



FIG 1034.

FIGS 1033 AND 1034.—MAGILL LARYNGOSCOPE AND RUBBER ENDOTRACHEAL TUBE.

larger soft rubber tube with a bevelled end, and this fills up a considerable part of the glottis so that both inspiration and expiration are carried out through it. When the tube is in place it may be strapped on to the patient's face and connected to the apparatus delivering the anæsthetic vapour. Unless the patient is very deeply anæsthetized there will probably be some coughing either when the tube is inserted or when the ether vapour is turned on; this will cease as soon as the larynx and trachea become acclimatized to the irritation of the tube or of the ether, as the case may be. It should be emphasized that if the cords are closed when the laryngoscope has been introduced, no attempt should be made to push the tube through, as the mucous membrane of the cords is delicate and easily damaged.

Nasal Intubation.—If a well-lubricated rubber tube, having a certain amount of curve, is passed through the nose, it impinges on the posterior pharyngeal wall, and in many cases will pass forward into the larynx; it is this fact that is utilized in nasal intubation. The tube used is the ordinary Magill catheter of as large a size as can be passed through the nostril; the passage through the nose will be aided if the mucous membrane is sprayed with 10 per cent. cocaine, as this will cause it to shrink and lessen the risk of trauma. The tube should never be forced if it does not go easily, but it should be removed and the other nostril attempted. As the tube is being gently pushed on past the back of the tongue the anæsthetist listens for the sound of respiration in the tube, and this will be more easily heard if the other nostril and the mouth are held closed with the other hand. As the end of the tube approaches the glottis the sound becomes louder; if the glottis is missed and the tube passes into the œsophagus the noise of respiration stops suddenly and the tube must be withdrawn until it is again audible. Should the larynx not be found first time, it can be searched for by rotating the tube a little in either direction so as to direct the point from side to side of the pharynx. In those cases in which it is found impossible to get the catheter into the trachea—and the number of these will depend on the skill of the anæsthetist—a laryngoscope can be introduced and the tube picked up in the mouth and guided through the larynx by means of the special Magill forceps. Nasal intubation is useful for mouth and throat operations since the tube is well out of the way of the surgeon, and the rest of the pharynx can be packed off with gauze so as to decrease the risk of blood getting into the respiratory tract. The other great advantage of nasal intubation lies in the fact that it can, in expert hands, be accomplished under a much lighter plane of anæsthesia than can oral intubation. Every student of anæsthetics, however, must make himself completely competent with the oral route before he attempts the 'blind' method.

Local Anæsthesia.—This term is generally used to embrace all the methods by which an operation can be rendered painless while the patient remains conscious. In true local anæsthesia the area immediately surrounding the site of operation is rendered insensitive by the injection of a solution which will anæsthetize the small nerves and nerve endings to that area. In regional anæsthesia the main nerve trunks carrying sensory impulses from the operation area are blocked by the anæsthetic solution at some distance from that area. Spinal anæsthesia consists in carrying regional anæsthesia one stage further and anæsthetizing the sensory nerve roots as they leave the spinal cord.

Freezing is the simplest form of local anæsthesia, although it is probable that few patients who have suffered from this method would consider that it deserves to be called anæsthesia. It may be used for opening small abscesses when gas is unobtainable or undesirable, and consists in spraying the area for incision with ethyl chloride from a special 'local' container which allows for a very fine jet of liquid. After spraying for a few seconds the part becomes

frozen and white; this hard crust can then be incised without pain to the patient. Unfortunately the freezing process is unpleasant and the later thawing is extremely painful; moreover, only too frequently the effort required to penetrate the frozen skin carries the knife deeper than was intended and the patient jumps and pulls the hand or foot away. Under such conditions careful surgery is difficult.

Local Infiltration.—For this purpose the most usual agent is novocaine at a strength of from ½ to 2 per cent. If large amounts are to be used a strength of ½ per cent. is to be preferred, as stronger solutions may lead to toxic effects. The novocaine is nearly always mixed with a few minims of adrenalin in order to constrict the small vessels and prolong the effect of the anæsthetic solution. A fairly large syringe is required and two or three needles of varying sizes which can be attached to the syringe by a bayonet fitting, or, when large areas are to be infiltrated, a self-filling syringe can be used with advantage; this has a thin rubber tube leading to the novocaine solution, and possesses a two-way valve by means of which the barrel is automatically refilled as the plunger is withdrawn. The usual routine is to fit a small needle to the syringe and to inject a little novocaine so as to form a small subcutaneous wheal, or for large incisions several wheals. Through these original injections larger needles can be introduced with very little discomfort to the patient, and the solution can be spread over as large an area as may be necessary. For abdominal surgery it may be necessary to inject each layer in turn to obtain full anæsthesia and good relaxation of the muscles.

Cocaine has been used for local infiltration, and although the anæsthetic results are excellent it is very toxic, particularly in the large amounts necessary for major operations, and for this purpose its use is contra-indicated. It is still used for local anæsthesia for nose and throat or eye operation, as it gives very good results when applied to unbroken mucous membrane; for nasal work gauze packs of 10 per cent. cocaine with a small amount of adrenalin are used, while in the throat, painting or spraying with the same strength of cocaine is the usual method. A very large percentage of eye operations are performed under the effect of one or two minims of 4 per cent. cocaine dropped into the eye.

Spinal Anæsthesia.—Probably no other branch of the subject gives rise to such diverse views as does that of spinal analgesia; there appears to be little reason for this divergence of opinion, as spinal analgesia would seem to have a fairly definite and clear-cut field. To avoid the use of spinals altogether is to eliminate an anæsthetic agent of undoubted value, while to use them as a routine seems to indicate that the anæsthetist turns a blind eye to their disadvantages.

A spinal anæsthetic provides the greatest possible muscular relaxation, and by reason of cutting off reflex nervous impulses is said to reduce shock in big operations; in addition to these factors the amount of bleeding is markedly reduced owing to the vaso-constriction effect of a spinal, and intestinal peristalsis is stimulated, instead of being inhibited as it is with a general anæsthetic. These points render a spinal worthy of consideration for extensive abdominal operations

such as gastrectomy, excision of the rectum, and also for intestinal obstruction, although, of course, other factors have always to be taken into consideration. For abdominal operation on patients suffering from diabetes or pulmonary tuberculosis it is usually the anæsthetic of choice. Such procedures as electro-resection of the prostate may be almost impossible if bleeding is excessive, and here a spinal is of the greatest use. It was thought at one time that the risk of chest complications was very much reduced by the use of spinal analgesia, but statistics do not support this theory, as the incidence of such complications appears to be very much the same whatever form of anæsthesia is used.

One of the greatest difficulties of spinal analgesia lies in the drop in blood-pressure that is produced, in some cases this may be negligible, but in others it is considerable; hence a spinal should never be given to a patient whose blood-pressure is low, or who is suffering from severe shock; the limit should be approximately 100 mm. of Hg for the adult of about twenty to thirty years of age, and correspondingly higher as age increases. The patient with an abnormally high blood-pressure should also be treated with care as a considerable drop may be encountered, and such cases do not tolerate a falling pressure at all well, whereas the slight rise produced by a general anæsthetic is usually harmless. For children such form of anæsthesia is unsuitable from all standpoints and should not be used.

Complications.—Of the complications peculiar to spinal analgesia the commonest is headache; careful after-treatment, by not allowing the patient to sit up too soon after a light spinal, and the use of a thin needle for lumbar puncture so as to eliminate the risk of leakage of cerebro-spinal fluid, will reduce the incidence of this troublesome symptom, but even with the greatest care a certain percentage of headaches will occur. Usually these are short-lived, but on occasions the patient may suffer from an intractable headache lasting for several days and very resistant to the ordinary remedies, although some relief can be given by an intravenous hypertonic saline (30 c.c. of a 15 per cent. solution of sodium chloride) or by an enema of 3 ounces of magnesium sulphate in 6 ounces of water Ocular palsies, in particular a sixth-nerve palsy with accompanying strabismus, are not uncommon, but they tend to clear up spontaneously in three weeks or so. Cauda equina lesions, of a severity varying from slight loss of sensation in the sacral area with retention of urine to a more complete paralysis of the legs with loss of tendon jerks, incontinence of fæces, etc., occur in a few cases. Again, these are usually transitory, although permanent paralyses have been recorded.

The Technique of Spinal Anæsthesia.—Two main types of anæsthetic solution can be used, called heavy or light according to whether the specific gravity is greater or less than that of the cerebro-spinal fluid, which is between about 1·004 and 1·010, and the technique of administration will vary according to which solution is being used. With the light solution the head must be kept lowered for a certain period, a disadvantage in patients suffering from chronic bronchitis, or in cases which have pus in the abdomen so that the rapid adoption

of the Fowler position is desirable. With the heavy solution the anti-Trendelenburg position must be used, and here it is difficult to counteract any fall of blood-pressure which may occur; also such complications as post-spinal palsies seem to be much more common after the use of heavy solutions.

The lumbar puncture is done either with the patient sitting up and bending forward as far as possible, or with him lying on one side with the knees drawn up towards the chin. The former position may be used with advantage when the puncture is difficult, but whichever posture is assumed the important thing is to produce the fullest possible flexion of the spine. The line joining the highest points of the iliac crests is taken as crossing the fourth lumbar spine, and the puncture can be made in the space between either the third and fourth or the second and third lumbar vertebræ. A small injection of novocaine may be made at the chosen spot, and then the lumbar puncture needle, which should be thin and of not more than 1·2 mm. bore, is inserted at right angles to both planes of the back. The needle passes in easily until it reaches the dura, when the characteristic feeling of resistance is encountered; as soon as this resistance is passed the stylet is withdrawn and a steady drip of cerebro-spinal fluid should ensue. This should be quite clear, but a slight stain of blood which clears up after a few drops is no contra-indication to the injection of the anæsthetic; in the presence of persistent blood-staining or in the absence of cerebro-spinal fluid no attempt should be made to introduce the anæsthetic solution.

Absolute sterility of the anæsthetist's hands and of the needle and syringes is essential. It must be remembered also that traces of alkali, such as soda or even soap, are liable to spoil the effect of some of the anæsthetic solutions and are to be avoided.

Spinal Anæsthetic Solutions—Stovaine.—Although less popular than in the past, owing to the introduction of newer substances, stovaine is still used to a fairly large extent. It can be used as either light or heavy solution, up to a maximum dose of 0·8 c.c., but there appears to be some doubt as to the exact specific gravity of the light solution. It is a somewhat toxic substance and tends to give a rather big fall in blood-pressure.

Novocaine.—Many preparations containing novocaine as the active principle are in common use under such various trade names as spinocaine, duracaine, gravocaine, and planocaine; of these spinocaine and planocaine are light, gravocaine is a heavy solution, and duracaine can be obtained as either. They are all very good anæsthetics, and have the advantage of giving the minimum fall in blood-pressure, but in all cases the length of action is somewhat short, usually not more than three-quarters of an hour and often less, and moreover it is sometimes difficult to produce a high spinal effect with them. For short operations below the level of the umbilicus they give excellent results.

Percaine is a derivative of quinoline, and is a very non-toxic substance, which will work in very dilute concentrations; thus 1 in 1,500 is the usual strength, and at this dilution it is really lighter

than any normal cerebro-spinal fluid. It gives an extremely good anæsthesia over a period of about two hours, without dropping the blood-pressure too much. The technique of giving percaine is slightly more complicated than in the case of the before-mentioned solutions, and there are several in common use, but that invented by Howard Jones, who was responsible for the pioneer work on this drug, has the merit of being both simple and effective; it is as follows:

When the lumbar puncture has been made, a syringe containing 20 c.c. of percaine is attached to the needle; great care must be taken with this manœuvre, as it is easy to push the point through the dura and give the injection extra-thecally, and as no resistance to the injection is felt it is impossible to know when this has occurred. The injection is then carried out slowly and gently, the amount to be injected depending upon the level to which anæsthesia is required, and slightly upon the actual height of the patient, or more correctly upon the length of his spinal column. Twelve c.c. will give anæsthesia up to the umbilicus, while for gastric operations about 14 to 16 c.c. are necessary. The needle is withdrawn and a small dressing can be applied to the site of the puncture; the patient is then turned on to his face for a period of five minutes, with the table flat. The reason for this is twofold: firstly to enable the solution to reach the posterior roots, which may otherwise be missed owing to the lightness of the solution and leave an imperfect analgesia; and secondly to allow the percaine to float up to the dorsal region, where it is required.

At the end of five minutes the patient is turned over on to his back and the table tilted into about 15 degrees of Trendelenburg, when the operation may be started. There are many other techniques for giving percaine, but this has the advantage of simplicity, and it must be borne in mind that whatever method is adopted it must be carried out with scrupulous attention to detail, therein lies the secret of success.

The level to which anæsthesia is complete will depend on the following main factors: (*a*) the amount of solution injected, (*b*) the force with which it is injected, (*c*) the position of the patient during the ten or fifteen minutes following injection. It can easily be understood that if the injection is made forcibly there will be a swirling effect which tends to carry the solution further up the canal. With regard to the amount of solution injected, some anæsthetists withdraw a few c.c. of cerebro-spinal fluid and mix it with the anæsthetic; this has the effect of diluting the solution and at the same time increasing the amount injected, so that although a higher level of anæsthesia may be obtained it is not always so satisfactory in quality.

When using the other light spinal anæsthetics the same method may be used, except that turning on the face is not necessary. With the heavy solutions, of course, a slight anti-Trendelenburg position is necessary. All cases having spinal anæsthetics should at the same time as the anæsthetic be given an injection of gr. $\frac{1}{4}$ of ephedrine, as this has some effect in preventing a fall in blood-pressure.

Splanchnic Anæsthesia.—This method is now used extensively for gastric surgery. A full field block is established and two fingers are

inserted into the abdominal cavity, over the lesser curvature of the stomach, until the aorta is felt; this is gently retracted to the left, and the tips of the fingers are rested upon the first lumbar vertebra. A long needle is carefully guided down between these fingers until the point reaches this vertebra; it is then withdrawn about half a centimetre, and 60 c.c. of ½ per cent. novocaine are injected into the surrounding loose tissues in which lies the splanchnic plexus. This method of anæsthesia produces an excellent surgical field, although it may cause a marked fall in blood-pressure, and strangely enough does not eliminate the risk of post-operative pulmonary complications.

Premedication for Local Anæsthesia.—It should firstly be noted that both local and spinal analgesia expose the patient to a considerable nervous strain; if the mental make-up is at all unstable or difficult, such forms of anæsthesia are better avoided, while even the most phlegmatic person needs a fairly full premedication. For the really robust male this should take the form of omnopon gr. ⅔, and scopolamine gr. $\frac{1}{150}$, given an hour before operation, in the case of women, or of men of a slighter build, omnopon gr. ⅓ and scopolamine gr. $\frac{1}{150}$ is to be preferred; in either case the condition of the patient should be observed about twenty minutes prior to operation, and if the necessary drowsiness is not evident a further injection of morphia gr. ⅙ should be given. When dealing with persons over the age of sixty, considerable care should be exercised, as they are very susceptible to these drugs; in such cases omnopon gr. ⅓ will prove adequate. The same care should, of course, be exercised when operating on very ill or feeble persons of any age.

Pulmonary Complications.—Throughout this chapter frequent reference has been made to the lung complications which are liable to follow anæsthesia; while this subject is too large to be dealt with in full, the following brief summary may be of value. There are three main types of such chest conditions:

1. **Aspiration Broncho-pneumonia.**—This is a condition of septic broncho-pneumonia due to the aspiration of infected material, usually vomit. It should never occur, as it is due to carelessness on the part of the anæsthetist or lack of proper preparation of the patient. The symptoms include a rapid rise of temperature within the first twelve hours, marked cyanosis, and fast, difficult breathing; the treatment is on usual medical lines, but the result is almost invariably fatal.

2. **Bronchitis.**—This is a not uncommon sequela of an ether anæsthesia in a patient who already has some chronic bronchitis; the disease exacerbates in exactly the same way as it does when such a patient catches a cold. Treatment is as described in medical textbooks for acute bronchitis, and the results are usually good, although continual coughing throws a strain on the abdominal wound, and in case of operations for hernia it may produce a recurrence.

3. **Pulmonary Collapse.**—This is by far the most common type of chest complication met with after operation; the great majority of cases occur after operations on the abdomen, and the incidence is particularly high following surgery of the upper abdomen. Sometimes collapse only is present, but only too frequently infection of the

collapsed area follows to give rise to a clinical picture identical with that of lobar pneumonia. It is probable that there are many factors which help to produce this condition, and the incidence is practically the same whether general, local, or spinal anæsthesia has been employed. One very important cause is the prolonged respiratory depression accompanying the deep level of anæsthesia necessary for surgery of the upper abdomen; moreover, on regaining consciousness after such an operation the patient has a painful wound which discourages any effort at deep respiration, so that the bases of the lungs may remain collapsed for a considerable period; secretion accumulates in this area, and infection may very easily follow. In other cases an area of collapse may be produced by a plug of tough mucus sticking in one of the smaller bronchi; this condition has frequently been demonstrated and cured by means of the bronchoscope. Several other factors play their part in the production of post-operative pneumonia, such, for example, as the rapid loss of body heat which may occur when the patient leaves the hot atmosphere of the theatre and is returned to a draughty ward, the presence of infection in the wards, or the presence of pathogenic organisms in the naso-pharynx of the patient himself. Although there is no golden rule for the prevention of chest complications, a good deal can be accomplished by scrupulous attention to such details as the following:

1. A level of anæsthesia sufficient to produce respiratory depression should be maintained only for as long as the surgical procedure demands.

2. The patient must be kept warm during his passage from the theatre and for some hours after his arrival in the ward.

3. After an abdominal operation the patient should be sat up in bed as soon as possible, and encouraged to take deep breaths frequently; some surgeons give their patients a course of breathing exercises before operation in order to encourage them to use their diaphragm effectively.

4. Drugs which have a depressing effect on the respiratory centre are better avoided before upper abdominal operations; post-operatively they should be used sparingly.

5. Atropine renders the mucus thick and difficult to cough up, and should not be used after an anæsthetic; pre-operatively a small dose is essential whenever ether is to be used, but there seems to be little advantage in exceeding the routine dose of gr. $\frac{1}{100}$.

6. The use of carbogen (oxygen containing 5 or $7\frac{1}{2}$ per cent. carbon dioxide) for short periods as the patient is coming round tends to increase the lung expansion, recently some doubt has been cast on the wisdom of using carbogen, as it is claimed that plugs of mucus may be driven further down the bronchial tree, but at present there seems little reason to suppose that it can do harm, and it undoubtedly helps in some cases.

7. Coughing, combined with alteration in position, should be encouraged in all patients of the 'chesty' type; the administration of a mild expectorant mixture will help in this, and makes coughing less painful.

CHAPTER XLVII.

SURGERY OF THE FEMALE GENITAL ORGANS.

By EARDLEY HOLLAND, M.D., F.R.C.P., F.R.C.S., F.C.O G.

IN this account no attempt is made to present the whole subject of gynæcology, which extends into the domain of medicine as well as that of surgery, and embraces also the many disturbances which may occur in the sexual and reproductive life of women. All that will be attempted is a concise presentation of the pathology and treatment of the more important surgical diseases, *i.e.* the injuries, infections, deformities, and new growths of the female genital organs, especial regard being paid to those which may be met with in the course of general surgical work.

The female genital organs comprise: (1) The external genitalia, which include the *labia majora* and *minora*, the *clitoris*, *urinary meatus*, *hymen*, and the *glands of Bartholin*; collectively these structures form the *vulva*. (2) The internal generative organs, which include the *vagina*, *uterus*, *Fallopian tubes*, and *ovaries*. (3) The adjacent *musculo-fascial* and *connective tissues* of the pelvis, the pelvic peritoneum, and also various embryonic remnants (Wolffian) which lie in the broad ligament.

Diseases of the External Genitalia.

Vulvitis.—Vulvitis, or inflammation of the vulva as a whole, is commonly due to gonorrhœa, uncleanliness, or irritating discharges coming from the cervix or vagina; the streptococcus or other pyogenic organisms may also be the infecting agent. The inflamed vulva is covered with a purulent discharge, and the surface is seen to be swollen and reddened. The *symptoms* are a sense of fulness and burning and itching, and the presence of a profuse discharge. In gonorrhœa and other septic infections the infection may spread upwards to the uterus, Fallopian tubes, and peritoneum; Bartholin's glands may become acutely inflamed and form localized abscesses. The *treatment* of acute vulvitis consists in rest in bed, and in keeping the vulva cleansed with a mild antiseptic lotion, followed by drying of the vulva and painting with a strong non-irritating antiseptic, such as a 2 per cent. solution of acriflavine. If an abscess forms, it should be freely opened and drained. The treatment of gonorrhœa has been dealt with in a preceding section.

There are several special types of vulvitis, the incidence of each of which is comparatively rare. **Gangrenous vulvitis** may occur as a complication of the puerperium or of venereal disease, or of the acute infectious fevers, especially of measles in children; in the latter the

condition may form a local gangrenous area known as **noma,** in which the labium becomes swollen and black and extensive sloughing quickly follows. **Membranous vulvitis** is the result of superficial necrosis, associated with streptococcal infection or implantation of the Klebs-Loeffler bacillus on the vulva; a bacteriological examination should be made before treatment is undertaken, in order to ascertain whether the diphtheritic bacillus can be found, in which case anti-diphtheritic serum should be given without delay. Other rare forms are **erysipelatous vulvitis** and **herpetic vulvitis.**

Leucoplakia vulvæ is a chronic inflammatory disease of the vulva of unknown origin, beginning with hyperæmia and superficial cell proliferation The vestibule and urethral orifice are not affected, but the process may extend to the perineum and anus. The affected area becomes thickened, and acquires an opaque, white colour; in the later stages cracks and ulcers may occur, which may bleed when touched. In many cases carcinoma supervenes, though in others the tissues retract, the labium minora and the clitoris almost disappear, and the rest of the vulva appears smooth, white, and shiny. The chief symptom is intolerable itching, and the patient cannot refrain from scratching. In the earlier stages soothing ointments or lotions should be applied to the affected parts, but if the condition is progressive, the whole vulva should be excised, not only because this is the only means of ending the intolerable itching, but also because of the risk of the development of malignant disease

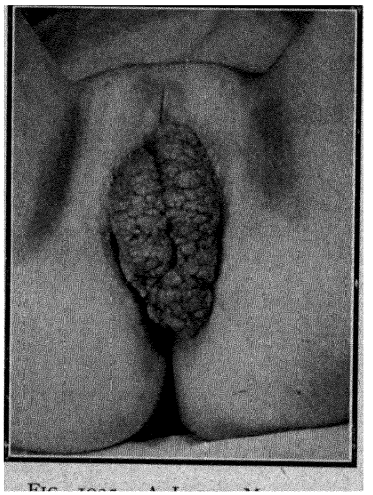

FIG 1035.—A LARGE MASS OF GONOCOCCAL WARTS

New growths of the vulva may be innocent or malignant. Both are comparatively rare. Innocent tumours consist of *fibroma, adenomyoma,* or *lipoma,* all of which are most commonly situated on the *labia majora.* They should be treated by local excision. **Papilloma of the vulva** commonly occurs in the form of multiple warts associated with uncleanliness or gonorrhœa (Fig 1035). The commonest vulval cyst is *Bartholin's cyst,* due to occlusion of the duct of the gland. The cyst forms a prominent swelling in the posterior third of the labium majus, and contains mucoid fluid. The cyst should be completely dissected out, care being taken to include the whole of the gland and duct, as otherwise a cyst may re-form.

Carcinoma of the vulva is nearly always a squamous epithelioma, but an adenoma-carcinoma occasionally arises from the epithelium of Bartholin's gland or duct. The commonest sites of origin are the

labium majus and clitoris (Fig. 1036); much less commonly the tumour begins in the urethra. Growth is usually rapid, and lymphatic spread into the inguinal glands occurs early. In a large percentage of cases the growth is preceded by leucoplakia. The first symptom is pruritus (itching), and later there is a blood-stained discharge from the ulcerated surface. *Treatment* consists in wide excision of the vulva, together with the inguinal glands in one block of tissue. Alternatively, radium needles may be implanted beneath and around the growth, and the lymphatic areas treated with the deep X-rays, or with radium 'beam-therapy.'

Sarcoma of the vulva is much rarer than carcinoma; melanotic sarcoma is commoner than the non-pigmented variety Treatment consists in wide excision, together with the inguinal glands

Urethral Caruncle.—This common and very painful little tumour occurs at the posterior margin of the urethral orifice, either diffusely distributed or as a polypus. It is usually about the size of a pea, is excessively tender to touch, and gives rise to dyspareunia and pain on walking or other movement and on micturition. It may also give rise to slight bleeding. In some cases a urethral caruncle is composed of granulation tissue covered with squamous epithelium, and results from a chronic inflammation of the terminal portion of the urethra; in other cases it is an adenoma and arises from the urethral glands. Urethral caruncles should be treated by complete excision, which must include the subjacent area of the urethral mucous membrane. Incompletely excised caruncles are liable to recur, but recurring caruncles should always be examined for malignancy.

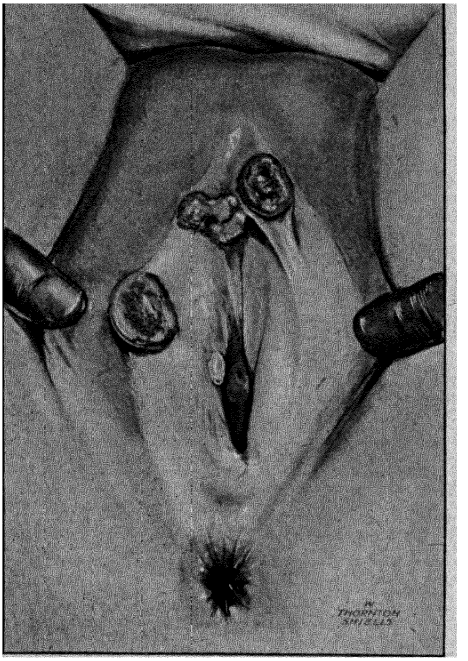

FIG. 1036.—CARCINOMA OF VULVA, WITH LEUCOPLAKIA.
An unusual case, with three separate areas of growth

Primary carcinoma of the urethra is extremely rare.

Prolapse of the urethral mucous membrane is liable to be confused with urethral caruncle. It may either arise acutely, following some

straining effort, in which case the prolapsed mass may become purple or black in colour owing to strangulation; or, more commonly, the condition is chronic and implicates usually the floor of the urethra only. *Treatment* consists in excising the prolapsed tissue, and in neatly re-forming the urethral orifice.

New Growths of the Uterus.

Fibromyomata, or **uterine fibroids,** are amongst the most common tumours found in the body, and are found especially in women between the ages of thirty-five and fifty. They are solid tumours, composed of a mixture of fibrous and unstriped muscle tissue, the relative proportions of which vary in different cases; a high proportion of muscle results in the formation of a relatively soft tumour, whereas fibrous growths are densely hard and are particularly found in elderly patients. Typically they are spherical in shape, and can be shelled out of the wall of the uterus in which they grow. They have a poor blood-supply, and lie in a capsule formed by the adjacent compressed tissues of the uterine wall. They may be single or multiple, and may vary in size from a small, seed-like structure to an enormous tumour which may fill the abdominal cavity. When sectioned with a knife, the distinction between the two elements of which the tumour is composed can be detected; the paler connective tissue surrounds the darker bundles of muscle, which become retracted and give the surface a definite but irregular pattern (Fig. 1037). About 96 per cent. of fibroids occur in the body of the uterus, and only 4 per cent. in the cervix. According to the position which they occupy (Fig. 1037) they are known as (i.) interstitial or intramural, in which case they are completely surrounded by the muscular tissue of the uterine wall; (ii.) subperitoneal, in which case they project beneath the peritoneum, being covered at their site of projection by the peritoneum only; and (iii.) submucous, in which case the part which lies next to the uterine cavity is covered by endometrium only. Both subperitoneal and submucous tumours may project still farther (Fig. 1038), escaping alto-

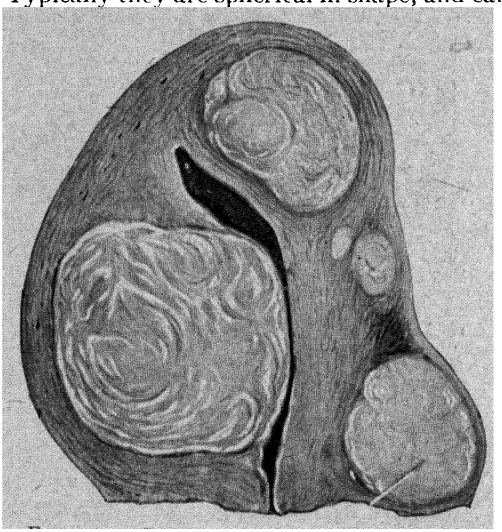

FIG. 1037.—SECTION THROUGH UTERUS REMOVED BY PARTIAL HYSTERECTOMY.

Note different positions of tumours in uterine wall

gether from the uterine tissue and becoming attached to it by a thin pedicle; they are then known as polypoid tumours or fibroid polypi. Tumours growing from the lateral wall of the uterus often burrow between the layers of the broad ligament, and, if they grow to any size, strip the peritoneum from the pelvic walls and establish retroperitoneal relationships. Thus they may drag the peritoneum off the pelvic colon, and may even burrow and split apart the layers of the mesentery of the sigmoid, or of the ascending or descending colon. A subperitoneal, pedunculated tumour may undergo torsion, with consequent impairment of the blood-supply and necrosis. Owing to their comparatively poor blood-supply, all fibromyomata are subject to various degenerative changes: **Atrophy** may occur after the menopause; **hyaline degeneration** consists of partial necrosis, resulting in areas of softening; in **fatty degeneration** scattered deposits of fat are found throughout the tumour, in **calcareous degeneration** lime salts are deposited in the tumour, and in an advanced form the whole tumour may become converted into a petrified mass. **Cystic degeneration** is comparatively common, and consists in the formation of irregular cystic spaces bounded by ragged walls and filled with a viscid fluid; the cysts arise from liquefaction of areas of hyaline degeneration. **Necrobiosis,** or **red degeneration,** is a peculiar change, usually the result of thrombosis of the capsular veins, and is especially liable to occur during pregnancy. On section a necrobiotic fibroid presents a striking alteration in colour, varying from pink to deep red. The clinical manifestations are pain and tenderness in the tumour and a rise of temperature. The condition usually subsides spontaneously, but occasionally calls for operative interference. **Septic infection of fibroid tumours** sometimes occurs during the puerperium from extension of infection from the uterine cavity. **Sarcomatous degeneration** occurs in about one half per cent. of all fibroids, it leads to rapid growth, but is usually unsuspected, and is discovered only after the removal of a supposedly innocent tumour. Fibroids do not undergo carcinomatous degeneration, but carcinoma both of the cervix and of the body of the uterus may, of course, occur in association with uterine fibroids.

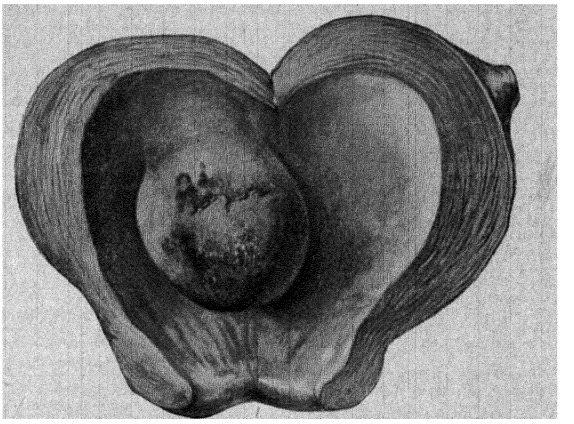

FIG 1038 – SUBMUCOUS FIBROID PROJECTING INTO UTERINE CAVITY.

The *symptoms* of uterine fibroids vary much in different cases. Even

when of large size they may cause no subjective symptoms. On the other hand, the symptoms to which they may give rise are many and various, and their occurrence is chiefly dependent upon: (1) The extent to which the tumours approach the uterine cavity, or project into it (submucous fibroids) or enlarge it. (2) Whether the tumours grow in such positions as to cause mechanical effects on the surrounding organs (large fibroids growing from the cervix or in the broad ligament, or from the posterior wall of the uterus, causing retroflexion). (3) The occurrence of certain forms of degeneration. (4) Interference with the reproductive function. (5) Rare complications, such as septic infection and torsion of the tumour. The commonest symptom is uterine hæmorrhage of the form known as **menorrhagia**, or an increased loss at the menstrual periods. The commonest mechanical effect is retention of urine, which is liable to occur with large cervical or broad ligament fibroids, or with posterior fundal fibroids which cause retroversion of the uterus.

Treatment.—The treatment of fibroids is surgical. It is not necessary to treat all fibroids merely because they have been diagnosed; the indications for operation are the size of the tumour and the occurrence of symptoms. Even if a large tumour is accompanied by no symptoms, it should be removed, as it is very liable to cause trouble sooner or later. A fibroid which reaches half-way up the umbilicus may be called 'large.' The symptoms that call for treatment are: (1) Bleeding, (2) pain and pressure symptoms, (3) evidence of rapid growth. Operative treatment for fibroids is either enucleation of the tumour (**myomectomy**) or removal of the uterus (**hysterectomy**). A fibroid polypus or a small accessible submucous fibroid may be removed by vaginal myomectomy after dilatation of the cervix, or after splitting the cervix along its anterior wall and reflecting the bladder (**anterior vaginal hysterotomy**). Abdominal myomectomy and hysterectomy are the operations of choice for most cases. The advantage of myomectomy is that it preserves the uterus as a child-bearing organ, and it is therefore indicated in women of child-bearing age; and as it is a more difficult operation and has a rather more unfavourable prognosis than hysterectomy, it should be reserved for such cases. The number of tumours is within limits no contra-indication to myomectomy, although the operation is naturally simpler if it entails the removal of one or of a few tumours only. In women past the child-bearing age, or in cases in which it is not desired to preserve the reproductive function, the operation of choice is that of removing the uterus, together with the fibroids, by abdominal hysterectomy, which may be either partial or complete. In *partial or subtotal hysterectomy* the body of the uterus with the fibroids is removed, but the cervix is left. In *complete or total hysterectomy* the body and cervix are both removed. Complete hysterectomy is the severer operation of the two, and is employed only in those cases in which the cervix is lacerated or eroded or inflamed; the reason for this selection is that in such cases carcinoma of the remaining cervical stump is more liable to develop than when the cervix is healthy, and many cases have now been reported of cervical carcinoma arising subsequent to subtotal hysterectomy.

The Operation of Abdominal Myomectomy.—The patient is prepared

as for any other abdominal operation, and, in addition, the pubic area is carefully shaved and thoroughly purified. A median incision of suitable length is made between the pubis and umbilicus, and the patient is placed in the Trendelenburg position. The uterus is then drawn up into or through the abdominal wound, and the abdominal cavity packed off from it with sterile cloths wrung out in saline solution. As the hæmorrhage may be troublesome, the blood-supply of the uterus is temporarily controlled; the uterine arteries are compressed by encircling the cervix with a special clamp devised by Bonney, and by compressing the ovarian arteries with light rubber-covered clamps as they run in the infundibulo-pelvic ligaments. An incision is then made over the prominent part of the tumour, keeping as closely as possible to the mid-line of the uterus, and the tumour is enucleated from its bed; several tumours may be successively enucleated in this way. The resulting cavities, after cutting away such redundant parts of the uterine wall as may be necessary, are then closed with through-and-through mattress sutures of linen thread, and the peritoneal edges finally united by a running suture of catgut. It is important to stop all oozing from the cut surface, owing to the danger, especially if the incisions lie on the posterior wall of the uterus, of adhesions forming to the intestines. If the incisions lie in the anterior wall, the uterus should be suspended by attaching the fundus to the anterior abdominal wall. The uterine cavity may be intentionally or inadvertently opened during the enucleation of the tumours, but this is not a disadvantage unless the uterus is the seat of a septic infection, which would be a contra-indication for the operation.

The Operation of Abdominal Hysterectomy.—In this operation there are four main sets of vessels to be secured, the ovarian and the uterine on each side; beginning on one side, a clamp is first placed along the upper half of the broad ligament close to the uterus, another clamp is then placed on the round ligament, and a third is placed over the Fallopian tube between the first clamp and the ovary; the round ligament and the upper part of the broad ligament are then successively divided. If it is intended to remove the ovaries also, the third clamp is placed on the infundibulo-pelvic ligament in order to secure the ovarian vessels. The same procedure is carried out on the other side, and the pedicles are secured by ligatures and the clamps removed. The peritoneum of the utero-vesical pouch running between the distal cut ends of the round ligaments is divided transversely by scissors, and the bladder gently pushed down off the anterior surface of the uterus and cervix. The uterine arteries, as they run up the sides of the uterus, are then secured by clamping them against the sides of the cervix about the level of the internal os, and the uterus is amputated above the clamps. A needle carrying a suture is then passed through the lateral wall of the cervix, and the arteries are firmly secured as the clamps are gradually released. The anterior and posterior edges of the divided cervix are next approximated by interrupted sutures of catgut, after which the raw surface left by the divided broad ligament is closed, and all vascular pedicles are buried, by approximating the divided margins of the pelvic peritoneum.

If it is decided to perform a complete hysterectomy, the vagina must have been prepared beforehand by thorough cleansing and by swabbing with an antiseptic solution such as 2 per cent. acriflavine. The operation proceeds as described above down to the clamping of the uterine arteries, after which the paracervical tissue is divided farther downwards on each side, keeping as close to the cervix as possible in order to avoid injuring the ureters, and having taken the precaution of pushing the bladder completely off the cervix. The vagina is then opened and snipped all round the cervix in order to remove the uterus. All vascular pedicles are secured by ligatures, and the divided edges of the vagina are sutured together, after which the edges of the pelvic peritoneum are united and all pedicles buried in order to leave no raw surfaces on the pelvic floor.

An **adenomyoma** of the uterus is a growth which combines the structure of a fibromyoma with that of an adenoma; it occurs in two forms: (1) diffuse, (2) circumscribed. The diffuse form, which is much the commoner, causes a general thickening of the uterine wall, usually the posterior; though presenting the usual features of a fibromyoma, it is distinguished by the gradual manner in which it merges into the surrounding uterine tissues. Microscopically, gland spaces resembling endometrium are scattered diffusely throughout the substance of the tumour. An adenomyoma presents the same symptoms as a fibromyoma, and the treatment is the same.

Uterine Polypi.—The following types of polypi are found. (1) Adenomatous or mucous, (2) fibroid, (3) placental, (4) malignant. **Mucous polypi** are very common, appearing as small bright red swellings hanging from the cervix or appearing at the os externum; they occur less commonly in the body of the uterus. In both situations they may give rise to irregular bleeding. A mucous polypus of the cervix is removed by grasping it in a pair of forceps and twisting it off. Small intra-uterine polypi are removed, after dilatation of the cervix, with a ring forceps or a large curette. A **placental polypus** arises from the retention of a placental fragment, from which a large polypoid swelling may develop by the deposit of fibrin over the surface. It gives rise to profuse hæmorrhage, and should be removed after dilatation of the cervix.

Chronic metritis or **fibrosis uteri,** although not a new growth, may be conveniently considered here. It may arise as the sequel of an acute infection of the uterus, but more commonly is the result of puerperal subinvolution. The condition is characterized by a general enlargement in the whole uterus, with a thickening of its wall, in which fibrous tissue predominates. If the condition is due to chronic subinvolution, the microscope will reveal an imperfect disappearance of the new bloodvessels, and especially of their elastic tissue, which had formed during the pregnant state. The chief symptom, which is usually delayed until near the time of the menopause, is menorrhagia, which, if unrelieved, may make the patient severely anæmic. *Treatment* may be by hysterectomy or, preferably, by inducing an artificial menopause by inserting a suitable quantity of radium into the uterine cavity.

Carcinoma of the Uterus.—The uterus and the breast are the two

commonest sites of cancer in the female sex, the liability of the two being about equal. Cancer may occur either in the cervix or the body of the uterus, the former site being about ten times more frequent than the latter.

Carcinoma of the Cervix.—Parous women are more liable to carcinoma in this situation than nulliparæ in the proportion of about 12 to 1; laceration of the cervix and the inflammatory erosions dependent thereon are probably the chief predisposing factors. The majority of cases occur between forty and fifty. The growth may begin (1) on the vaginal portion of the cervix, in which case it is a squamous epithelioma, and appears either as a warty excrescence or as an ulcer; and (2) in the cervical canal, in which case it is an adeno-carcinoma, and forms an ulcerated cavity in the substance of the cervix. Squamous epithelioma is far the commoner variety. In both cases spread of the growth, both by local and by lymphatic invasion, is usually rapid, and the vagina, parametrium, and bladder are all in time invaded; the ureter may likewise be infiltrated and obstructed, and hydronephrosis, septic infection of the kidney, and uræmia may all result. The iliac lymphatic glands are the first to be infected, and the lymphatic path passes along the base of the broad ligament.

The *earliest symptom* is irregular hæmorrhage; every case of irregular hæmorrhage, especially when it occurs after the menopause, should without delay be investigated for uterine cancer. The second symptom to appear is offensive discharge, which signifies that the growth is already fairly advanced and has become necrotic. Pain occurs comparatively late, and always signifies that the disease has become widespread in the pelvic cavity. In early cases, on vaginal examination, an induration or ulceration, or a wart-like elevation, may be felt on the vaginal portion of the cervix. The tissue is friable, and breaks down if scraped with the finger-nail or with a probe. In doubtful cases a portion of the suspicious part of the cervix should be removed for microscopical examination. In cancer which begins in the cervical canal there are no external appearances of the disease until it has ulcerated through the cervix; but the cervix is bulky, and the passage into the canal of a probe or small curette causes hæmorrhage and reveals other evidences of the disease. The extent of the disease should always be estimated by vaginal and rectal examination. If the cervix is freely movable and the bases of the broad ligaments are not indurated, the growth is in the operable stage, whereas if the cervix is fixed, the vaginal walls invaded, and infiltration of the parametrium can be detected, the disease is usually beyond the scope of radical operation.

Carcinoma of the body is much less frequent than that of the cervix. In this situation the disease arises in parous and nulliparous women with equal frequency, and the age incidence is higher than that of cancer of the cervix, the disease rarely occurring before the menopause (Fig. 1039). The outstanding symptom is irregular uterine hæmorrhage, which, if it occurs after the menopause, should always be regarded seriously. Later symptoms are pain, which appears much earlier than in cervical cancer, and foul discharge. It cannot be too strongly urged that the appearance of any hæmorrhagic discharge near the time of the

menopause should always determine a careful local examination of the pelvic viscera; it is an unfortunate fact that the majority of cases of cancer of the uterus, especially of the cervix, remain undiagnosed until the disease has reached the inoperable stage.

Treatment of carcinoma of the cervix has altered a good deal during the past few years. Until recently all cases in which there seemed a reasonable chance of removing the whole growth with its lymphatic extensions, *i.e.* the 'operable' cases, were treated by the operation of extended abdominal hysterectomy devised by Wertheim. In this operation the whole uterus, together with the upper end of the vagina and as much of the parametrium and iliac lymph glands as possible, is removed by the abdominal route The operation is a severe one,

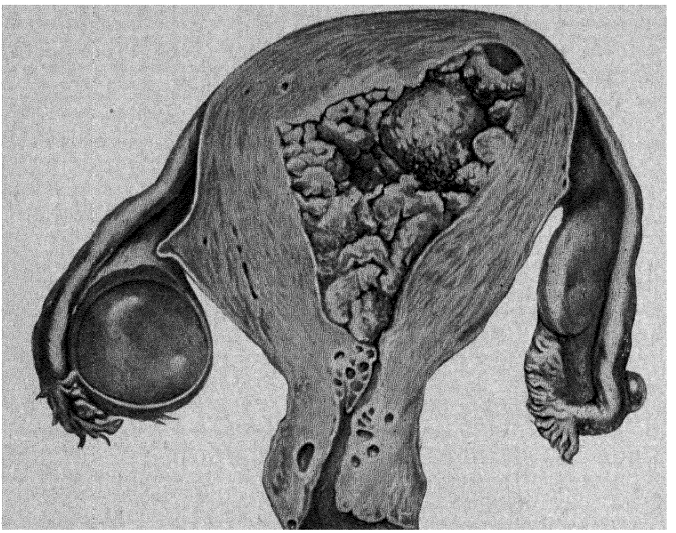

FIG 1039.—SECTION THROUGH UTERUS REMOVED BY TOTAL HYSTERECTOMY, SHOWING DEEP INVASION OF WALL AT RIGHT CORNU

with a primary mortality of about 10 per cent., and the prospects of freedom from recurrence for a period of five years amongst the survivors does not amount to more than about 30 per cent. There is an increasing tendency nowadays to discard operation in favour of treatment by radium for all cases, including the early ones. The great advantage of radium treatment is that it is accompanied by a primary mortality (from septic infection) of less than 1 per cent.; the percentage of five-year cures is also rather higher than that claimed by operation. The technique of radium treatment commonly used is that devised by Forsell and Heyman of Stockholm. Three applications are made, the second being a week after the first, and the third being three weeks after the second. Each application consists of 50 mgms. of radium

element inserted into the uterus and 50 mgms. disposed in the vaginal vault, the screenage being equivalent to 3 mm. of lead. The radium is allowed to act for a period of twenty to twenty-four hours. Opinion is still divided about the respective merits of operation and radium in early cases. For inoperable cases there is no doubt that radium is a remarkable palliative, relieving hæmorrhage, foul discharge, and pain in a wonderful manner, and prolonging life.

Finally, a word must be added to emphasize the fact that the predisposition afforded to this disease by a torn and inflamed cervix suggests the possibility of prevention by attending to such lesions, and not allowing them to persist indefinitely without treatment.

In **carcinoma of the body** the importance of early diagnosis cannot be over-emphasized, the interior of the uterus being explored with a curette in all cases of suspicious bleeding. The *treatment* is removal of the uterus by pan-hysterectomy. Treatment by radium or X-rays may be attempted when the disease has passed the operable stage.

Sarcoma of the uterus is not common. It may arise as a primary growth, or as a sarcomatous change in a fibro-myoma. The latter is rare, far less than 1 per cent. of fibro-myomata showing sarcomatous metaplasia. In most cases it occurs as a solid, firm tumour, consisting of spindle cells, but more vascular than and not quite so hard as the majority of fibroids; in others it is of a softer consistency, and may be associated with myxomatous degeneration. It almost always involves the body of the organ, the cervix being unaffected; and it may either attack the mucous membrane primarily as a diffuse infiltration, or constitute a more localized growth in the muscular tissue. Secondary deposits occur in the vagina and elsewhere, and the growth runs a rapid course. The symptoms are uterine hæmorrhage and a discharge which may be offensive and contain débris of the growth. *Treatment* consists in pan-hysterectomy.

Chorion-epithelioma, or **chorionic cancer,** is a rare tumour of the uterus, and is composed of malignant cells derived from the chorionic epithelium; a preceding pregnancy is therefore the invariable source of the condition. The pregnancy may have ended in an ordinary labour or abortion, but in the majority of cases the preceding condition is that of **hydatidiform mole,** a portion of which has remained behind after the expulsion of the main mass. Rarely the tumour may occur in the Fallopian tube after a tubal pregnancy. The tumour forms solid nodules of a purple or red colour mottled with pale areas, these appearances being due to the fact that the tumour elements are often surrounded by blood-clot originating from the erosion of vessels of the uterine walls by the malignant cells. The tumour cells resemble the normal cells of the chorionic epithelium, and appear as irregular masses of the discrete cells of Langhan's layer and of the multinucleated plasmodium of the syncytial layer. The tumour possesses no stroma, and therefore no blood-supply of its own; this explains the tendency of the cells to travel into and along the bloodvessels of the uterine wall and the early formation of distant metastatic deposits. The chief *symptom* is constant or repeated uterine hæmorrhage following abortion,

labour, or hydatid mole. The uterus is as a rule moderately enlarged, but often presents no alteration in size. In some cases the earliest symptom has been hæmoptysis or hemiplegia, from early embolic deposits in the lung or brain. If the case is operable, the complete removal of the uterus and appendages should be carried out. This tumour can be regarded as the most malignant tumour known, and the percentage of cures by operation is extremely small.

Tumours of the Ovary and Broad Ligament.

Many different forms of new growth originate from the ovary, and from the embryonic rudiments in the broad ligament. The following classification may be adopted:

A. **Unilocular cysts :**
   (1) From embryonic rudiments (Wolffian): (*a*) from hilum of ovary, (*b*) from epoophoron; (*c*) from paroophoron. All these have intracystic papillæ ('papilliferous cysts') and all may be carcinomatous.
   (2) Follicular cysts, including lutein cysts.

B. **Multilocular cysts :** the pseudo-mucinous cystadenoma.

C. **Dermoid cysts** (teratomatous cysts).

The **multilocular pseudo-mucinous cystadenoma** is the commonest variety of ovarian cyst, and comprises 80 per cent. of ovarian tumours; it is innocent, and may attain an enormous size. It has a fibrous capsule covered by cells of the germinal epithelium, and is made up of a series of loculi of different sizes separated from each other by septa. There is often a loculus of preponderating size, accompanied by many small loculi of varying size interspersed with semi-solid portions. The tumour is of a characteristic pearly-blue colour with a glistening surface. Each loculus is lined by high 'palisade' columnar epithelial cells, many of which are of the goblet variety, the nuclei being at the base of the cells. The cells secrete pseudo-mucin, a glycerine-like fluid which resembles mucin, but which differs from it in important respects.

Cysts arising from the epoöphoron or from the hilum of the ovary arise from Wolffian tubules. They are unilocular and usually contain intracystic papillæ, which may be in the form either of fibromata or of adenomata, in consequence, these cysts are known as 'papilliferous cysts' (Fig. 1040). They are frequently bilateral, and never attain to the large size of a multilocular cystadenoma. The walls of the cyst are thin and the fluid it contains is watery in consistence. They are often malignant, the type of malignancy being usually more local than general. The intracystic papillæ may burst through the cyst wall by a process of erosion and give rise to secondary deposits on the abdominal viscera and peritoneum, and this is always accompanied by a large accumulation of ascitic fluid. It is important to realize that these secondary deposits often have only a local malignancy, and may disappear after removal of the original tumour; in other cases these cysts assume a definitely carcinomatous character, and spread and infiltrate rapidly. It is not always possible to distinguish clinically between a

papilliferous cyst and an ordinary cystadenoma. It is therefore advisable, after opening the abdomen, to remove all ovarian tumours entirely without tapping them in order to avoid infecting the peritoneal cavity with tumour cells by the escape of the cyst contents.

Ovarian Dermoids (Teratomatous Cysts).—These tumours constitute about 10 per cent. of all ovarian tumours. They are usually unilocular and are sometimes found in combination with a cyst-adenoma. They are met with at all ages, from the early months of life up to extreme old age. They are frequently bilateral. They grow slowly, and seldom attain a large size. The cyst is filled with sebaceous secretion which is fluid at the body temperature, but which coagulates to a solid consistence after the cyst is removed and has cooled. At one area on the inner wall of the cyst is a projection covered with skin, which is liberally supplied with sebaceous glands and hair (Fig. 1041); beneath the skin is a mass of tissue which contains structures developed from all three primary embryonic layers, such as teeth, bone, cartilage, thyroid gland, muscle, intestinal epithelium, and neuroglia. The sebaceous contents originate from the skin area of the cyst, which is thus really in the nature of a sebaceous or retention cyst.

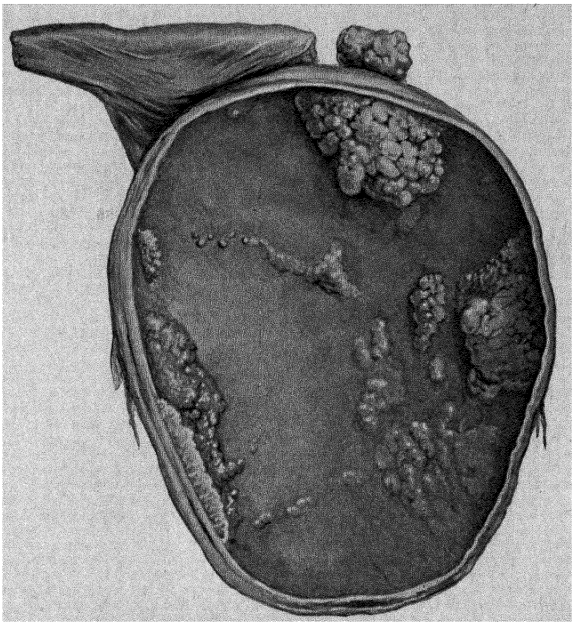

FIG. 1040.—PAPILLIFEROUS EPOOPHORIC CYST
Note intracystic and surface growths.

An **ovarian fibroma** is a hard pedunculated tumour; it is uncommon, and forms less than 2 per cent. of all ovarian tumours. It is often accompanied by ascites, and is prone to undergo cystic degeneration.

Carcinoma of the ovary may occur either as a primary growth of the ovary or secondary to a growth elsewhere, most commonly of the intestinal tract or breast. The tumour may be solid or cystic, and is usually bilateral. About 5 per cent. of all ovarian tumours are carcinomatous. The common cystadenoma may undergo carcinomatous change, and the papilliferous tumours of the ovary are, as has been

Diagnosis.—Ovarian cysts must be diagnosed from pregnancy, soft or cystic fibromyoma of the uterus, mesenteric cysts, pancreatic cysts, hydronephrosis, ascites, and distended bladder. The passage of a catheter and careful exclusion of the symptoms and physical signs of pregnancy are essential to avoid mistakes in diagnosis. In cases of doubtful diagnosis an X-ray examination of the tumour is essential, in order to reveal or exclude the presence of a fœtus.

Complications of Ovarian Tumours.—Torsion of the pedicle is a common complication, and all ovarian tumours, both cystic and solid, which are of moderate size and are not adherent, are liable to torsion. The effects of torsion depend on the degree of constriction of the blood-vessels in the pedicle. If torsion arises slowly and gradually, the thin-walled veins are occluded first, and this results in intense venous engorgement of the tumour and hæmorrhage into the cyst cavity and cyst wall, or into the peritoneal cavity. If both the arteries and the veins are occluded, necrosis of the tumour, with subsequent infection, will occur. Incomplete torsion, leading to a temporary effect, with subsequent readjustment of the circulation in the pedicle, is common. The symptoms are therefore variable, and usually consist of recurrent attacks of lower abdominal pain with tenderness of the tumour. In cases of acute or complete torsion the symptoms are very acute, and consist of agonizing pain, shock, and a degree of collapse which varies with the amount of internal hæmorrhage; the clinical state is, in fact, often that of an ' acute abdomen,' and at operation an ovarian tumour with twisted pedicle may be unexpectedly found.

Rupture of an ovarian cyst may occur spontaneously or as the result of external violence; the former is commoner, and is usually determined by necrotic changes in the cyst wall. The sudden escape of the cyst contents is accompanied by pain and shock, and internal hæmorrhage also may occur from tearing of vessels.

Suppuration of an ovarian cyst is a rare and serious complication; the infection usually originates from adherent bowel or from an inflamed appendix, and the *Bacillus coli* is the organism most usually found in the pus. The signs are those of localized peritonitis with the presence of a tumour, and the symptoms are those of severe septic absorption.

Treatment.—Early removal by the abdominal route is clearly indicated for all ovarian tumours as soon as they are diagnosed. The earlier they are removed, the safer for the patient, as at any moment dangerous complications may arise, and there is, moreover, always a possibility that the tumour may be or may become malignant. Even in cases diagnosed as malignant, an exploratory operation should be undertaken, for in certain of the papilliferous cysts the malignancy is of an essentially local nature, and removal of the main tumour may be followed by the disappearance of peritoneal implantations.

The operation of choice for removing ovarian tumours is **ovariotomy.** It is a very safe operation, and in uncomplicated cases is one of the safest in surgery.

Operation.—The patient is prepared in the usual way for abdominal operations. The Trendelenburg position may be adopted if it enables the pedicle of the cyst to be dealt with more easily. After opening the

peritoneal cavity the tumour should, if possible, be delivered through the incision without tapping it, bearing in mind the possibility of malignancy. If adhesions are present they must be liberated. If it is considered desirable to reduce the cyst by tapping before removal, great care must be taken to avoid escape of any of the cyst contents into the peritoneal cavity, or abdominal incision, by packing carefully all round with sterile gauze before introducing the trocar, which should be attached to a suction-pump. After the tumour has been delivered the pedicle is clamped with as many forceps as may be necessary, and the pedicle is then divided distally to the clamps. If the pedicle is very thin, it may be tied *en masse*, but it is preferable to secure separately the two chief sets of vessels, namely, the ovarian vessels in the infundibulo-pelvic fold, and the anastomotic branches of the uterine vessels close to the uterine cornu. After the vessels have been securely tied and bleeding points have been secured all raw surfaces are buried, in order to avoid the subsequent formation of adhesions, by sewing together the peritoneal edges of the pedicle. The other ovary is then examined and dealt with according to circumstances, after which the abdominal incision is closed.

Broad ligament cysts, which have no pedicle, are removed by incising the peritoneum of the broad ligament down to the cyst wall and enucleating the cyst from its bed; before incising the broad ligament, the ovarian vessels in the infundibulo-pelvic fold and the anastomotic branches of the uterine vessels should be clamped and tied, after which a bloodless enucleation can usually be completed. The opening in the broad ligament is then closed.

Endometrioma of the Ovary ('Tarry-blood Cyst').—These cysts, often bilateral, are filled with dark altered blood which has been likened to chocolate syrup or tar. They seldom have a diameter of more than 2 inches, and are usually densely adherent to the surrounding pelvic structures. The presence in the wall of the cyst of aberrant endometrium is the characteristic pathological feature, and the cyst formation is due to the gradual accumulation of menstrual blood derived from this misplaced tissue. Endometrioma of the ovary rarely occurs before thirty or after forty-five years of age. Severe dysmenorrhœa is one of the chief symptoms, and attacks of severe abdominal pain, having no relation to menstruation, occur in a large number of cases

Infections of the Female Genital Tract.

Infections of the female genital tract give rise to a series of inflammatory lesions which are best considered as a whole, rather than as affections of the individual organs. In the acute stage of an infection the organs and tissues of the pelvis are always affected collectively. In the chronic stage the lesion of one organ becomes predominant, but the other pelvic structures also participate to a greater or less extent, a chronic pyosalpinx, for example, being always combined with chronic inflammation of the adjacent peritoneum and of the ovaries. The circumstances under which infections may arise are: (1) Gonorrhœa (2) post-partum or post-abortum (usually streptococcal) infections,

(3) post-operative infection, (4) acute appendicitis, (5) tuberculous infection. The path of infection is usually an ascending one, gonorrhœa and puerperal infection (postpartum or postabortum) claiming between them about 90 per cent. of all cases.

Acute Pelvic Inflammation.—The great majority of cases are due to an ascending infection, which reaches the Fallopian tubes and results in **acute salpingitis.** Inflammation of the tube causes no symptoms until the infection has reached the peritoneum, and the symptoms of an acute attack are therefore entirely those of acute pelvic peritonitis. The severity of the symptoms varies widely in different cases. In the most acute, usually streptococcal and puerperal, the symptoms are often indistinguishable from those of other forms of 'acute abdomen,' and no localizing signs may be discoverable in the pelvis; in gonorrhœal cases the onset is less severe. The initial symptom is sudden acute

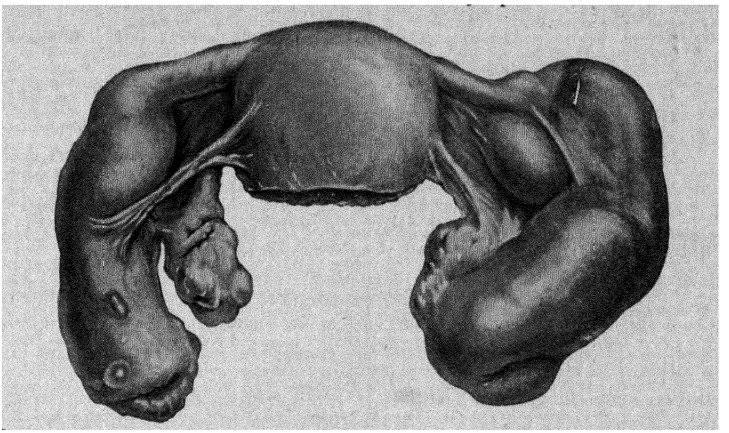

FIG 1042.—TUBES, OVARIES, AND BODY OF UTERUS REMOVED FOR PURULENT PELVIC INFLAMMATION.

Right tube is a pyosalpinx, left tube communicated with an intraperitoneal pelvic abscess.

pain located in the lower abdomen, accompanied by fever and rapid pulse. The patient lies on her back with the knees drawn up, and the lower abdomen is tender and rigid. Vaginal examination at the onset of the attack seldom reveals any physical signs in the pelvis, except tenderness on palpation through the vaginal vault. Tender lateral or postero-lateral swellings, representing the inflamed tubes and ovaries, soon appear and, increasing quickly in size, may become large enough to rise well above the pelvic brim.

An attack of **acute pelvic inflammation** pursues one of four courses: (1) Infection may spread upwards and result in general peritonitis; this is almost unknown in gonococcal infection, but in streptococcal, especially puerperal, infection its liability is great. (2) An abscess may form either in the Fallopian tube (**acute pyosalpinx**), in the ovary (**ovarian abscess**), or in the pelvic cavity (**pelvic abscess**). (3) The

attack may subside in a few days and leave few or no pelvic physical signs, but the tubes seldom escape permanent damage in the form of kinks, adhesions, and sealing of the abdominal ostia. (4) The acute attack may pass into the chronic stage.

Chronic pelvic inflammation is associated with the formation of such lesions as **chronic pyosalpinx** (chronic abscess of the tube), **chronic salpingo-oöphoritis** (in which the thickened tube is fused with the ovary into a conglomerate mass surrounded by adhesions) (Fig. 1042), or **hydrosalpinx.** The uterus is usually retroflexed and fixed by adhesions. All these conditions result in chronic ill-health, accompanied by pelvic pain, dysmenorrhœa, menorrhagia, and sterility. A chronic pyosalpinx is usually bilateral, forming swellings, usually of unequal size, lying in the postero-lateral regions of the pelvis; the swelling is tender, and can easily be felt on vaginal and rectal examination. A **hydrosalpinx** is a tube distended with clear fluid; it results from a mild infection of the tube, which does not proceed to pus formation, and in which the abdominal ostium becomes closed at an early stage.

Treatment.—All cases of acute salpingitis, whether in the initial stage or during a recurrent attack, are to be treated in the first place by expectant or palliative measures. The patient must be kept in bed, the diet limited to fluids, the bowels kept open, and simple measures for the relief of pain adopted, such as sedative drugs and the application of hot fomentations to the abdomen. The patient should be nursed in the Fowler position, in order to assist the infection to remain localized in the pelvis. If, however, there arises evidence of general peritonitis, or of the formation of pus, the treatment necessarily becomes surgical.

In the *chronic stage* of pelvic infection, it is often a matter of difficulty to decide whether medical or surgical treatment should be adopted. Chronic pyosalpinx is best dealt with by removing the affected tube or tubes by the abdominal route. When the disease is bilateral the ovaries and uterus are probably infected as well, and a radical operation, including complete removal of the tubes and ovaries and of the uterus, is usually the best operation. In *non-suppurative* cases, when an operation is decided upon to relieve pain and other symptoms, or because of recurrent attacks of subacute infection, less radical procedures should be adopted, and the ovaries and uterus should, if possible, be preserved.

A **pelvic abscess** must be evacuated as soon as it is recognized, and this is best done through the posterior fornix by the operation known as **posterior colpotomy.**

Tuberculosis of the Tube.—The symptoms of tuberculous salpingitis are not distinctive. A tubal swelling or an attack of salpingitis occurring in a young virgin may be suspected of being of tuberculous origin. The usual symptoms are tenderness and pain, the attack being subacute rather than acute, and not accompanied by the same severe symptoms as in the pyogenic forms of salpingitis. Tuberculous salpingitis is often accompanied by tuberculous peritonitis.

Parametritis, or **pelvic cellulitis,** is inflammation of the pelvic cellular tissue, and is generally due to septic infection following childbirth, the path of infection usually being through a tear of the cervix. It

may also occur secondarily to acute salpingitis. The majority of cases occur in the puerperium, and usually make their appearance during the second week after labour. The *symptoms* are those of any acute infection, namely, a rise of pulse and temperature, and often an initial rigor. On vaginal examination in the early stages a feeling of fulness is felt at the base of the broad ligament on the affected side, and a few days later a hard, thick, diffuse swelling, displacing the uterus to one side, makes its appearance. After running a more or less long course the inflammation gradually subsides, but in a certain number of cases pus forms, resulting in a **parametric abscess.** The abscess is, of course, extraperitoneal, and usually points above Poupart's ligament near the anterior superior spine. In other cases the abscess points towards the rectum or bladder, and may rupture into one or other viscus. Among other unusual situations for the pointing of such an abscess are Scarpa's triangle, the buttock, and the ischio-rectal fossa. When it is certain that pus has formed, the abscess must be opened and drained. This may be done through the skin above Poupart's ligament, or through the vaginal fornix, according to circumstances.

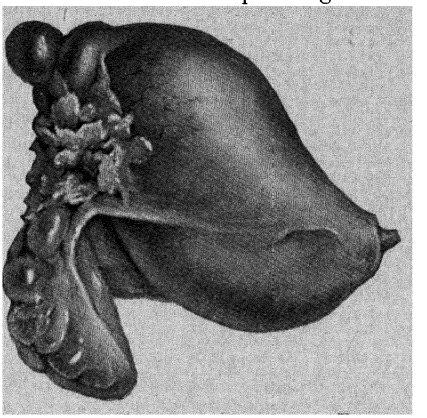

FIG. 1043.—PREGNANT FALLOPIAN TUBE, OUTER HALF.

Tube distended with blood, ovary seen below.

Extra-uterine Pregnancy.

It is very seldom that extra-uterine pregnancy occurs in any other site than the Fallopian tube, about 120 cases of **ovarian pregnancy** have been reported, but the occurrence of **primary abdominal pregnancy** is not generally accepted. The cause of tubal pregnancy is often a former salpingitis, the kinks and adhesions resulting from which delay or arrest the fertilized ovum during its passage towards the uterus. The fertilized ovum may become implanted, in order of frequency, in the ampulla, isthmus, fimbriated extremity, or in the interstitial portion of the tube. The ovum penetrates the mucosa and embeds itself in the muscular wall; in the absence of decidual formation the trophoblast quickly erodes the wall of the tube and opens bloodvessels. If the erosion is towards the peritoneal coat, **rupture of the tube** occurs with free hæmorrhage into the peritoneal cavity. If the eroding process is chiefly in the direction of the mucosa, the tube becomes distended with blood (**hæmatosalpinx**) (Fig. 1043), but does not rupture; the hæmorrhage is restrained by the wall of the tube, and the amount of blood lost is much less than in tubal rupture. In such cases blood usually escapes through the abdominal ostium and gravitates into the

pelvic cavity, where it becomes enclosed by adhesions between the sur rounding structures and forms a **pelvic hæmatocele;** the ovum becom converted into a **tubal mole,** which the tube attempts to expel by mear of painful muscular contractions. The process of **tubal abortion** i however, seldom completed, and blood continues to escape and th pelvic hæmatocele to grow in volume. Both tubal abortion and tub rupture give rise to characteristic signs and symptoms. Both processe occur very early, usually when the ovum is of the age of three or fou weeks; hence the period of amenorrhœa experienced by the patien seldom exceeds five or six weeks, and the symptoms often appear withi the limit of a normal menstrual interval.

Rupture of the Tube.—The symptoms are usually preceded by period of amenorrhœa, which seldom exceeds six weeks from the dat of the last menstruation. The first symptom is a sudden agonizin attack of lower abdominal pain; the patient feels faint and has th symptoms and appearance of internal hæmorrhage, but death fror hæmorrhage is rare. Slight uterine hæmorrhage soon appears, due t separation of the uterine decidua. On physical examination the pallc and small rapid pulse denote internal hæmorrhage; the abdomen is fu and immobile, is tender on palpation below the umbilicus, and ther are signs of free fluid. On vaginal examination the ruptured tube i usually impalpable, but there is great tenderness on vaginal palpatio on the affected side. Rupture usually occurs into the peritoneal cavity but occasionally the tube may rupture between the layers of the broa ligament. In the latter case the loss of blood is not so great as in th intraperitoneal variety; a large hæmatoma forms in the broad ligament and may become palpable well above the pelvic brim.

Tubal Abortion.—The symptoms of tubal abortion are much les severe than those of tubal rupture. After a short period of amenor rhœa the patient is seized with a severe attack of pain on one or othe side of the lower abdomen, and she feels faint. The attacks of pain ar repeated, and uterine bleeding, usually slight, and often accompanie by the passage of a decidual cast, soon makes its appearance. O examination a pelvic swelling is always felt, but the exact physica signs are variable, depending on the size of the tubal swelling and of th pelvic hæmatocele respectively. If the bleeding is confined to th tube (hæmatosalpinx), an ovoid swelling extending across the pelvi or lying in Douglas's pouch can be felt; but if there is a large hæmatocel the distended tube is masked, and can seldom be felt as a separat swelling. A pelvic hæmatocele usually forms a doughy mass in th pouch of Douglas, bulging forward the upper part of the posterio vaginal wall and displacing the uterus upwards and forwards.

The ovum is almost invariably destroyed at the time of rupture o abortion, but in rare cases it may continue to live and gain new attach ments within the broad ligament or in the peritoneal cavity, an pregnancy may continue even to the full development. Such cases o **full-time extra-uterine pregnancy** are of great rarity. The child i usually dead, and is deformed from pressure.

Treatment of Extra-uterine Pregnancy.—As soon as the condition i diagnosed, immediate operation should be undertaken. The abdome

is opened, the affected tube identified and removed, and the blood-clot cleared out of the pelvic cavity. It is usually possible, and always advisable, to preserve the ovary on the affected side. The danger of delaying operation is that fresh and possibly fatal hæmorrhage may occur. A pelvic hæmatocele which has become infected should be drained through an opening in the posterior vaginal fornix (posterior colpotomy). In cases of severe intraperitoneal hæmorrhage, intravenous saline infusion or blood transfusion may be required.

Displacements of the Uterus and Vaginal Walls.

Prolapse.—The various forms of downward displacement of the uterus and vagina are best grouped under the comprehensive term **prolapse.** Prolapse is a hernial protrusion of the pelvic viscera through the vaginal orifice, and the chief primary lesion which initiates the process is weakening of the fibro-muscular attachments between the viscera and the fixed pelvic structures; when such weakening exists, the ordinary intra-abdominal pressure suffices to produce prolapse, which tends progressively to increase and is always aggravated by muscular effort. Prolapse is, perhaps, the commonest gynæcological condition met with in practice, and its subjects are nearly always parous women in whom the attachments of the uterus and vagina have been overstretched or torn during labour. As, however, the condition sometimes occurs in nulliparous women, it must be supposed that a primary weakness of these attachments sometimes exists. A patient is best examined for prolapse lying on her back with the legs widely separated and the knees bent; when she is made to strain down or cough, the prolapse will become evident at the vaginal orifice or will be increased.

Clinically, four types of prolapse may be observed, and they may occur either singly or in combination.

1. **Cystocele.**—The vaginal orifice is wide, and part of the vaginal wall is exposed; when the patient strains down, the anterior wall bulges outside the orifice in the form of a round smooth swelling 'like an egg.' The bulging pouch of the vagina contains more or less of bladder or urethra, as may be demonstrated by passing a bladder sound. As a rule there is no accompanying descent of the uterus.

2. **Classical Prolapse or Prolapsus Uteri.**—This is the commonest form, and three stages may be described. In the first stage, the anterior vaginal wall bulges as in cystocele, and at the same time the uterus descends and becomes retroverted. In a later stage, the anterior vaginal wall is completely everted, the cervix appears at the vaginal orifice, and about half the posterior vaginal wall is inverted from above downwards. The final stage is known as **complete prolapsus uteri,** or **procidentia;** the vagina is turned completely inside out, and hangs outside the vulva with the cervix at the apex of the protruding mass, within which lie the uterus, bladder, and urethra.

3. **Rectocele.**—When the patient strains, the posterior vaginal wall bulges outside the vaginal orifice in the form of a swelling which contains a pouch of rectum, as is easily demonstrated by rectal examination; the anterior vaginal wall and uterus maintain their normal position.

4. **Inversion of the Vagina from above Downwards.**—When the patient strains, the cervix appears outside the vaginal orifice; the vaginal wall descends with the cervix, the vagina being inverted from above downwards, but there is no cystocele or rectocele.

All these types of prolapse may occur singly or in combination; thus rectocele and cystocele are often combined, and either or both may be associated with classical prolapse or with inversion of the vagina from above downwards.

A patient with prolapse complains of 'something protruding,' and of discomfort on walking or standing. In long-standing cases the everted vagina becomes rubbed, and ulceration and infection may follow. With large cystoceles the bladder is not completely emptied, and residual urine collects and decomposes, with cystitis and sometimes infection of the kidney as sequels.

Treatment.—Palliative treatment consists in inserting a vaginal ring pessary. This form of treatment does not cure the condition, but merely relieves symptoms by affording a temporary support in the manner that a truss controls a hernia. A pessary acts as a foreign body in the vagina, acting as a constant irritant, keeping the walls on the stretch, requiring to be changed at regular intervals, and condemning the patient to much discomfort and inconvenience for the rest of her life. Unless the age or general condition of the patient contra-indicates it, all forms of prolapse should be submitted to operative treatment, which entails very small risk and is almost invariably successful.

The operation which is nowadays performed is a combined vaginal and perineal plastic operation, which aims partly at tightening the relaxed fascial supports and restoring the cervix and bladder to their normal level, partly at reducing the area of the stretched vaginal walls, and partly at narrowing and building up the distended vaginal orifice and perineum.

For cystocele the operation of **anterior colporrhaphy** is performed, for rectocele the operations of **posterior colporrhaphy** and **perineorrhaphy,** and for the combined forms of prolapse all three operations in combination; in cases of elongation of the cervix, amputation of the cervix is carried out in addition.

Backward Displacement of the Uterus.—The normal position of the uterus is one of anteversion and anteflexion, the long axis of the uterus inclining forwards with an obtuse anterior angle between the cervix and the body; it must be clearly borne in mind, however, that the uterus is not fixed in this position, but is free to move in all directions.

A **retroversion** is a rotation of the whole uterus on a transverse axis passing through the cervix, so that the long axis is inclined backwards instead of forwards. A **retroflexion** is a bending backwards of the body of the uterus on the cervix, and is invariably accompanied by retroversion. Retroversion is frequently a normal condition, and is estimated to be present in about 20 per cent. of healthy women; it causes no symptoms, and does not interfere with normal uterine function. Retroflexion is extremely common in women who have borne children, and is not uncommon in nulliparæ. It most commonly arises during the early days of the puerperium, owing to the relaxed

state of the uterine attachments at that time; the uterus in this position cannot complete its normal puerperal involution, and remains in the state of 'chronic subinvolution.' In other cases retroflexion arises as the result of pelvic inflammation, being dragged backwards by the weight of the inflamed appendages. Many cases are congenital in origin.

Diagnosis.—On vaginal examination the cervix is found pointing downwards and forwards, and the body of the uterus is felt through the posterior fornix; on bimanual examination the diagnosis is confirmed by failure to palpate the body of the uterus through the anterior fornix.

Symptoms.—It is generally accepted that a *healthy* retroflexed uterus seldom causes symptoms. There are, however, three symptoms or signs which are occasionally the direct effects of retroflexion of the uterus—namely, dyspareunia, sterility, and abortion.

Treatment.—In cases in which retroflexion of the uterus gives rise to symptoms, the uterus may be replaced by manipulation and kept in the normal forward position by the insertion of a Hodges's pessary. A pessary acts only as a temporary support, and never permanently cures the displacement. A permanent cure can be obtained only by submitting the patient to the operation of **ventral suspension,** in which the uterus, either directly, or indirectly through the round ligaments, is sutured to the abdominal wall just above the level of the symphysis pubis.

Malformations.

Errors of development of the uterus from variation in the process of fusion of the Mullerian ducts are not uncommon, but malformations of the other organs, apart from stenosis of the lower end of the vagina, are rare. Congenital absence of the ovaries, except in association with some such gross fœtal monstrosity as acardia, never occurs. A number of cases have been recorded in which an ovary has been arrested at some point along its line of normal descent through the abdomen, and an ovary may sometimes be found in the sac of a congenital or acquired hernia.

Malformations of the Fallopian tube are unfrequent; the most usual are the presence of supernumerary ostia and congenital diverticula, the latter having an important bearing on the ætiology of extra-uterine pregnancy.

Malformations of the Uterus.—Congenital absence of the uterus is extremely rare; even in cases of so-called 'absence of the uterus' a small nodule of fibro-muscular tissue can usually be found. The **uterus fœtalis** represents the proportions of the uterus as usually seen at birth, the whole organ being very small and the cervix forming two-thirds of the whole; menstruation is generally absent. The **uterus pubescens** represents the persistence in adult life of the organ as found at puberty; its length may be normal, but it is often narrow and may be acutely anteflexed; the condition is usually associated with scanty menstruation, dysmenorrhœa, and sterility. Another class of uterine malformation is due to defective development and fusion of the Müllerian ducts, and the defects vary from the presence of two complete uteri (**uterus**

didelphys, or 'double uterus') to a depression in the fundus which denotes the slightest degree of imperfect fusion. An important form clinically is the **uterus bicornis with a rudimentary horn,** in which the latter is, as a rule, attached to the single cervix by a band of fibro-muscular tissue. Dysmenorrhœa is a common symptom, and there may be retention of menstrual fluid (**hæmatometra**) in the rudimentary horn. Pregnancy may also occur in such a horn, leading to the symptoms of extra-uterine pregnancy. In all the above malformations the cervix and vagina may be single or double.

Absence of the vagina occasionally occurs, in which case the uterus, though present, is usually rudimentary; should the uterus be functional, the condition of **hæmatometra** (retention of menstrual fluid in the uterus) will, of course, result.

Localized atresia is a common defect of the vagina, and the obstruction is usually due to the persistence of a membrane at the vaginal orifice—the so-called '**imperforate hymen.**' The obstructing membrane, after the establishment of menstruation, obstructs the flow of menstrual fluid, which distends the vagina and gives rise to the condition known as **hæmatocolpos;** if the condition is allowed to persist unrelieved, the uterus and Fallopian tubes may in turn become distended (**hæmatometra** and **hæmatosalpinx**). The symptoms are absence of menstruation, colicky pains in the lower abdomen, and sometimes retention of urine from pressure on the urethra. The condition must be relieved by incision of the membrane and liberation of the accumulated fluid, which is dark red and viscid.

Malformations of the vulva are usually associated with the various types of pseudo-hermaphroditism.

Injuries of the Female Genitalia.

The female genitalia are in such a well-protected situation that injuries other than those due to parturition are rare. **Injuries to the external genitalia** may occur from direct violence, such as a fall astride some object or from intentional kicks or blows; the hymen and vaginal orifice may be severely torn in the newly-married, resulting in hæmorrhage, which may require surgical attention, and cases of rupture of the vaginal vault from the same cause have been reported. The parts are richly supplied with bloodvessels, particularly veins, and slight injury may cause severe hæmorrhage, either external from an open wound, or subcutaneous in the form of a large hæmatoma; in the pregnant state especially, or if large varicose veins are present in the labia, the likelihood of severe hæmorrhage is greater. If a hæmatoma forms, the labium becomes greatly swollen and discoloured, firm to the touch, and extremely tender and painful; suppuration may follow, especially if the injury is associated with a superficial wound. A very large hæmatoma occasionally arises spontaneously during the second stage of labour, tracking up the side of the vagina and hindering parturition. Occasionally a fall on a stick or paling may result in **laceration of the recto-vaginal septum.**

Treatment.—Open hæmorrhage from injuries to vessels should be

stopped by ligature or by packing, or by ligature of the tissue *en masse*, as indicated by the nature of the wound. Wounds should be cleansed by antiseptic solutions and subjected to primary suture, if possible. After treatment of the wound the patient should be kept in bed with the hips elevated. A hæmatoma should be treated conservatively in the first place; but if suppuration occurs, incision and drainage will be required. If a large spontaneous hæmatoma forms during labour and obstructs the exit of the child, the swelling must be incised and the clot turned out.

Injuries resulting from Childbirth.—Slight injuries in the form of laceration of the vagina and perineum are extremely common, and as a rule heal without complications as the result of immediate suture. Severe injuries are nowadays met with much less commonly than in the past, thanks to the improved standard of obstetrical practice. The injuries to be considered here mostly represent the failures in the primary healing process. They may be considered as follows: (1) Unhealed lacerations of the perineum, incomplete and complete; (2) unhealed lacerations of the cervix; (3) vesico-vaginal fistulæ; (4) recto-vaginal fistulæ.

Lacerations of the perineum are the commonest injuries of the birth canal, and are divided into complete and incomplete. In **complete laceration** the sphincter of the anus is torn through, and sometimes the rectum itself is laid open for a considerable distance. The symptoms of an unhealed incomplete laceration are not very pronounced, and consist in discomfort and a sense of weakness in that region, and there is a predisposition to vaginal prolapse. The symptoms of a complete tear are, of course, much more noticeable to the patient and demand relief by operation; flatus and fæcal matter escape involuntarily, especially if the motions are loose, and life is thereby rendered a misery.

Treatment.—The treatment of perineal lacerations consists in their repair by the operation of **perineorrhaphy.** The first step in the operation is to excise the superficial scar covering the surface of the laceration, after which the vaginal mucous membrane, the deeper tissues, and the perineal skin are united by sutures, so as to restore the parts to their original condition. In complete lacerations, the first important steps of the operation are the freshening and suturing of the edges of the tear in the rectum and the union of the torn ends of the sphincter ani.

Lacerations of the cervix, if accompanied by **chronic cervicitis** and **erosion,** give rise to muco-purulent vaginal discharge; they also predispose to cancer of the cervix. Treatment consists in repair of the laceration by the plastic operation of **trachelorrhaphy,** or in amputation of the affected part and plastic reconstruction of the cervix.

Vesico-vaginal fistulæ are repaired by an operation the principle of which is excising the edges of the fistula and suturing the openings in the bladder and vagina in separate layers.

Recto-vaginal fistulæ are usually associated with complete laceration of the perineum, and are dealt with by the operation above described for repairing that injury, especial attention being paid to freshening and uniting the edges of the torn rectal wall.

CHAPTER XLVIII.

SURGICAL AFFECTIONS OF THE EAR.

By V. E. NEGUS, M.S., F.R.C.S.

THE **Examination of the Ear** is carried out by inspecting the external auditory meatus and membrana tympani through a speculum; by testing the power of hearing; and by ascertaining whether or not the Eustachian tube is permeable, and the effect on the hearing of inflation through this channel.

1. **Visual Inspection** by means of a speculum and frontal mirror. In introducing the speculum the auricle is held between the third and fourth fingers of the operator (the left hand being used for the right ear, and *vice versa*) and drawn backwards, upwards, and outwards so as to straighten the cartilaginous portions of the meatus. The speculum held by the operator's thumb and first finger is then gently inserted and held in position. The reflected light illuminates the tympanic membrane, unless the presence of wax, epithelial débris, or pus obstructs the view, when they must be removed by cotton-wool mops or by



FIG 1044.—EUSTACHIAN CATHETER

syringing. It may be impossible to insert the speculum because of dermatitis or furunculosis. The following points are to be noted in the normal membrana tympani (Fig. 1045) The projection of the short process and handle of the malleus which runs from the centre upwards and forwards, behind this the processus gracilis of the incus and the tendon of the stapedius, and at the upper border Shrapnell's membrane (Fig. 1047). The motility of the membrane should be determined by the use of Seigel's pneumatic speculum, as also its colour, whilst the presence of perforations, polypi, or adhesions should be noted.

2. The **Investigation of the Hearing** is carried out by testing the greatest distance at which the patient can hear the ordinary conversational voice, the whispered voice, or the tick of a watch. Accurate measurements can be made with an audiometer.

Discovery of the cause of deafness is assisted by **Rinne's Tuning-Fork Test.** A tuning-fork of 256 double vibrations is placed in contact with the mastoid process, and retained there until the patient can

hear it no longer. If now it is placed opposite the external auditory meatus, the sound should again be heard if the middle ear is normal, but not if disease of the external meatus or middle ear is present. It may be necessary to employ forks of lower vibration rate for this test if the deafness is slight, of 128, 64, or 32 double vibrations per second. **Weber's Test** consists in placing a vibrating tuning-fork in

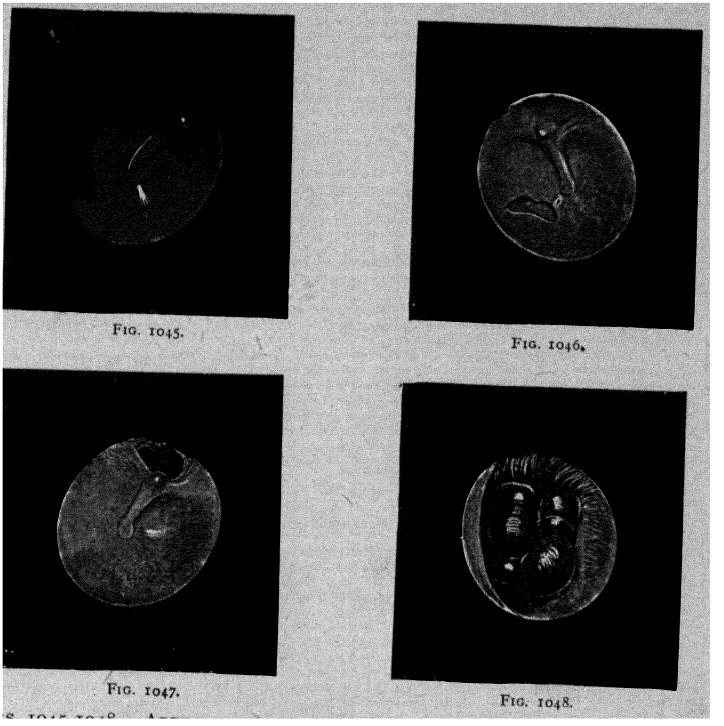

FIG. 1045. FIG. 1046.

FIG. 1047. FIG. 1048.

FIGS. 1045-1048.—APPEARANCE OF THE MEMBRANE IN VARIOUS CIRCUMSTANCES ON EXAMINATION THROUGH A SPECULUM

Fig. 1045.—Normal membrane (right side)
Fig. 1046.—Perforation below and in front of head of malleus (left ear) in acute otitis suppurativa
Fig. 1047.—Perforation through Shrapnell's membrane in chronic otorrhœa.
Fig. 1048.—Polypi protruding through perforation in membrane.

the middle line of the forehead. In cases of pure middle-ear disease, the sound will appear to be louder in the affected ear than on the healthy side.

3. Perception of high tones is tested with a monochord or with Galton's whistle. Lack of appreciation of high pitches indicates involvement of the cochlea or auditory nerve.

considerable deformity will result from its organization. **Eczema** and diffuse dermatitis are met with in the external ear; there may be obstruction from accumulation of epithelial scales and excoriation of the skin lining the meatus. **Boils** or **furuncles** form in the follicles of the hairs guarding the external auditory meatus. They cause great pain, and may produce deafness through obstruction. If the local inflammation spreads, there is swelling behind the ear, causing prominence of the auricle, making the diagnosis from mastoid abscess difficult. If the auditory meatus be in the slightest degree patent, or if a small speculum can be introduced, hearing and tuning-fork tests will be found almost or quite normal in uncomplicated cases of furunculosis; when acute otitis media, with or without mastoiditis, is present, there is marked deafness. It is unwise to incise boils in this region, as cellulitis of the deeper tissues may be produced thereby. **Epithelioma** may attack the auricle or auditory meatus, and may involve the middle ear.

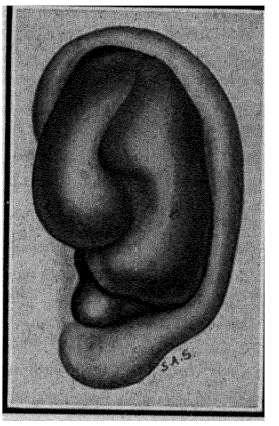

FIG 1050 — HÆMATOMA AURIS

Plugs of Cerumen (wax), which become dark and indurated, not unfrequently block the meatus, leading to more or less complete deafness; this may come on suddenly after bathing, owing to the rapid swelling of the plug. If they encroach on the membrana tympani, subjective symptoms of giddiness and rushing noises in the ear may also be caused. On examination with a speculum their presence is readily detected *Treatment* consists in washing them away, after previously softening with a solution of sodium bicarbonate. A large syringe with a fine nozzle should be used, and a stream of warm normal saline solution injected along the floor or roof of the eatus; as it returns, the softened masses wax are washed away. **Foreign bodies** in the meatus, such as ittons or beads, are similarly removed, if possible, by syringing, this fails, a fine pair of forceps or a fine hook may be employed it due care must be taken of the delicate structures behind. Where her plans fail, the auricle must be turned forwards and the meatus ened from behind. **Exostoses** occasionally form in the bony walls the meatus; they may cause deafness by obstruction, and then cal r a modified mastoid operation. The proximity of the facial nerve ust be remembered, and the operation should never be lightly ndertaken.

Affections of the Middle Ear.

Traumatic Rupture of the Tympanic Membrane is due to direct or indirect violence; the former includes the introduction of foreign bodies, or the ill-advised efforts of friends or even of medical prac-

4 **Inflation of the Tympanic Cavity** is required both as a test of the permeability of the Eustachian tube and also as a means of treatment in various conditions. The methods of effecting it are as follows

Valsalva's Method consists in closing the lips, holding the nose, and expiring forcibly; the air is thereby driven up the Eustachian tubes if they are patent.

In **Politzer's Method** an indiarubber bag with a teat-like end is introduced into one nostril so as to occupy it completely. The other nostril is closed by the surgeon's finger. The patient is instructed to take a sip of water and to hold it in the mouth with closed lips until told to swallow As he swallows the bag is forcibly compressed, and air is thereby driven up the tubes. An auscultating tube may pass from the patient's meatus to the surgeon's ear, and various sounds—whistling, bubbling, etc.—may be detected, according to the character of the lesion.

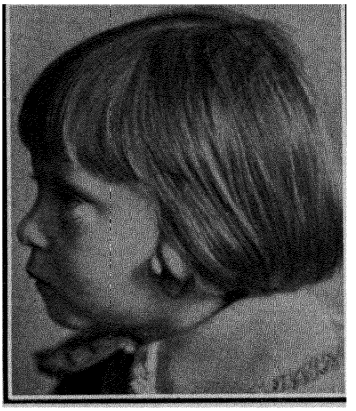

FIG. 1049.—ACCESSORY AURICLES IN A CHILD

The **Eustachian Catheter** (Fig. 1044) can be passed into the Eustachian tube, and the degree of inflation more accurately controlled The instrument, carefully sterilized, is passed with the beak downwards along the inferior meatus of the nose until the posterior pharyngeal wall is reached. 'As soon as its tip touches the posterior wall of the naso-pharynx, the *anterior end* of the instrument is slightly raised, and is withdrawn for about half to three-quarters of an inch until the beak is felt to be in contact with the posterior end of the hard palate. The catheter is then rotated through a quarter of a circle until the beak points directly outwards. It is then pushed a little onwards, and is usually felt to slip easily into the opening of the Eustachian tube' (Lambert Lack).

External Ear.—The pinna may be **congenitally absent,** and even the external meatus closed, a malformation often associated with macrostoma. The external deformity may be rectified by a plastic operation, but usually nothing can be done for the lack of hearing, and the surgeon must not be tempted to try to dig out the concealed membrana tympani. **Accessory auricles** may be present (Fig. 1049), consisting merely of fibro-cartilage covered with fat and skin. **Large and prominent ears** constitute a very unsightly deformity, for which operative interference is occasionally required. **Hæmatoma** of the ear is usually due to injury, and appears especially amongst the insane. The auricle becomes swollen and enlarged, and of a bluish-red colour (Fig. 1050); unless the swelling is punctured and the blood let out,

titioners to remove the same. Indirect violence can cause rupture of the membrane by the sudden compression of the air in the external meatus, *e.g.* by boxing the ear, by loud noises as from explosions or big-gun practice, or from diving. Rupture of the membrane also occurs in some fractures of the middle fossa of the skull. The patient complains of pain and deafness, and blood escapes from the meatus, but not in any great amount. On involuntary inflation of the middle ear air can be heard to escape through the opening, perhaps with a whistling sound. As a general rule, these cases do well, the wound cicatrizing, and the hearing being fully restored; but the surgeon must at first give a guarded opinion, as there may be some deeper lesion which does not immediately become apparent. The greatest care must be taken to sterilize the meatus by filling it with 1 in 20 carbolic lotion or biniodide of mercury in alcohol, which is allowed to soak in. A strip of gauze is then gently inserted into the meatus, and an external dressing applied.

Otitis Media.—Inflammation of the middle ear is an exceedingly common affection, and constitutes the great bulk of all ear diseases. It must be remembered that the tympanic cavity is lined by a mucous membrane which is in direct communication through the Eustachian tube with that of the naso-pharynx; and hence the *cause* is almost invariably an extension of inflammation along the Eustachian tube. The organisms usually present are the hæmolytic streptococcus and more rarely pneumococcus; ordinary pyogenic cocci may be found as secondary infections. The inflammation may be catarrhal or suppurative, acute or chronic.

Acute Inflammation of the Middle Ear is very common in children, being secondary to lesions of the naso-pharynx, such as an ordinary cold, scarlet fever, measles, etc., particularly if adenoids are present. It is ushered in by severe pain in the ear of a boring, persistent character, together with deafness and some degree of fever. The pain increases as the secretion accumulates, and particularly if the Eustachian tube become closed, in consequence of the inflammatory hyperæmia of its lining wall, the tympanic membrane bulges outwards into the meatus and finally ruptures (Fig. 1046), the pain being at once relieved. The discharge is mucous or purulent from the first; in the former instance, if infection from the meatus is guarded against, the inflammation may subside, the perforation heal, and no ill result follow. In many instances, however, especially when the child is suffering from measles, or if his resisting powers to microbic invasion are low, the catarrhal otitis media is transformed into a suppurative lesion, which may persist as a *chronic otorrhœa* for a lengthy period.

Treatment.—In the first place, the possibility of infection from the external meatus must be guarded against by thorough purification; the external ear is well cleansed, and the meatus is filled with 1 in 20 carbolic lotion, which is allowed to soak in and act for some minutes, or the meatus may be filled with biniodide of mercury in spirit. An antiseptic dressing is then placed within and over it. The child is kept in a warm room, and his general condition attended to by suitable diet, diaphoretic medicine, and a smart purge. Carbolic acid (5 per

it.) in glycerine, or drops of otalgan instilled into the meatus, help relieve pain, and in adults it may be possible to cocainize the orifice the Eustachian tube in the pharynx, thereby relieving the hyperia and opening up the tube, thus giving an exit to the retained charge. Pain is often relieved by fomenting the ear or by the plication of heat, as in the form of a hot-water bottle or a poultice antiphlogistine.

When the membrane is seen (by speculum) to be bulging, it is wise incise it (*myringotomy*), as a clean cut heals better than a ragged rforation. The external ear and auditory meatus must be thoroughly rified with 5 per cent. phenol lotion or biniodide of mercury in rit before operation. General anæsthesia is required, and the ision is usually made just behind the handle of the malleus from low upwards. An antiseptic dressing is kept over the meatus til healing has occurred. Cultures should be taken and if, as is ially the case, hæmolytic streptococci are the causative organisms, e of the sulphonamide preparations should be given forthwith. pneumococci are present M. and B. 693 should be prescribed.

Inflammation may extend into the mastoid cells, giving rise to the idition known as **mastoiditis.** This complication makes itself ident in individuals with a cellular type of mastoid process; they istitute 80 per cent. of the total, the remainder having a dense or bloetic type of bone.

The mastoid process is a triangular mass of bone lying behind the ditory meatus; it contains a greater or less number of cells lined th mucous membrane which communicate with the antrum, which elf communicates with the posterior part of the tympanic cavity tic) by means of the aditus. At birth and in early years the antrum solitary, but later the process begins to develop and may be of o types: (*a*) the *cellular*, in which the whole bone becomes more less hollowed out into a spongy mass of cells, which may extend wards into the temporal plate, backwards over the lateral sinus, wnwards to the tip of the mastoid process, forwards above the ditory meatus (zygomatic cells), inwards and forwards under cover the facial nerve, or inwards towards the tip of the petrous bone; the *acellular* type, in which but few cells appear, the antrum naining small, and the bone itself of ivory consistency. As a rule, e cells lie below and superficial to the antrum, which is more deeply ated in the adult than in the child; the aditus also is relatively ger in the child than in an adult. The cellular mastoid is that in hich serious trouble develops in the course of catarrhal or exanthetous infections.

When purulent otitis media is associated with acute inflammatory anges in the mastoid air cells, severe local and general symptoms ay result, particularly if the aditus becomes blocked. The patient mplains of intense pain in or behind the ear, with tenderness on essure, periosteal thickening, and perhaps redness and œdema over e mastoid process. The discharge from the ear often ceases for a ne at the commencement of these symptoms, but reappears later. the case progresses, the febrile symptoms accompanying the initial

attack of otitis media may persist or may reappear after a short intermission. An abscess may form under the periosteum covering the mastoid process, with or without caries or necrosis of the outer table of the bone; in children, where this bony lamella is thin, it is not unfrequently absorbed, and on incising the abscess granulations, springing from the interior of the bone, may be seen. When such an abscess has developed, the auricle is characteristically displaced downwards and outwards. Sometimes the suppuration extends through the bone cells, and may encroach on the inner aspect rather than the outer, and hence is likely to lay bare the dura mater and expose the lateral sinus; in such circumstances intracranial complications are possible. Occasionally a few thin-walled cells occupy the tip of the mastoid, and these may perforate downwards into the digastric fossa; and thus an abscess may form near the attachment of the sterno-

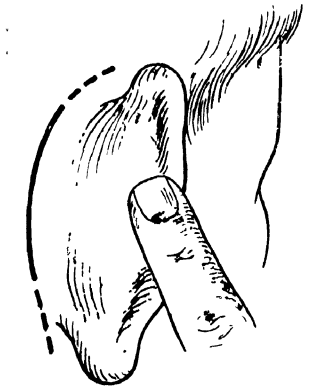

FIG. 1051.—INCISION FOR MASTOID OPERATIONS, SHOWING EXTENSIONS UPWARD AND DOWNWARD TO SUIT CIRCUMSTANCES.

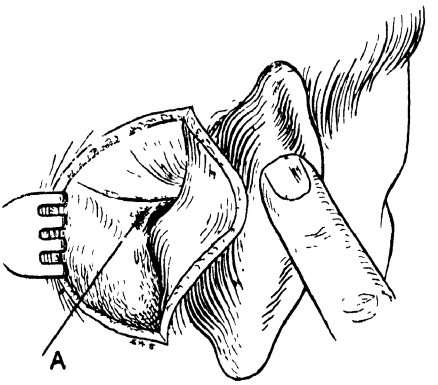

FIG 1052.—POSITION OF THE ANTRUM (A) DEEP TO THE DEPRESSED AREA CONSTITUTING MACEWEN'S TRIANGLE

mastoid, and track into the muscle itself or into the neck; this is known as *Bezold's abscess*.

Sometimes the trouble is of milder onset, and may be tuberculous in nature.

Treatment.—In the early acute stage warmth may be applied to the ear and the patient kept quietly in bed, whilst the diet is regulated and a suitable purgative administered. Sulphonamide, in some form, will probably be required if the temperature is raised; cultures are of course required to determine the type of organism, as mentioned above. It is important not to be precipitate with surgical intervention, unless some complicating factors arise. An operation may be necessary, but the best results are obtained if it is postponed until the end of the second week from the commencement of the attack of acute otitis. If, at the end of this time, there is still pyrexia, with tenderness over the tip of the mastoid and aural discharge, then it is advisable

)pen the mastoid antrum and air cells, through skin and periosteum, hout interfering with the tympanic structures, which in acute cases capable of effective repair (*Schwartze's operation*). A curved in- on is made immediately behind the ear, which is drawn well for- ds (Fig. 1051), and after separating the periosteum from the bone ouge is applied on a level with the roof of the external auditory itus, and about ½ inch behind its centre (Fig. 1052). A small iple in the bone can often be felt at the required spot, which can) be found by taking the point of junction of two lines drawn as gents to the roof and posterior wall of the bony meatus respectively. : direction taken by the gouge should be slightly downwards, vards, and inwards. In an adult the mastoid antrum is reached ut three-fifths of an inch from the surface of the bone. The geon recognizes that he has opened the cavity by the probe, or the loss of resistance and escape of offensive pus. The opening is irged by the use of the gouge and spoons, so as to remove all ased bone and open all the air cells, and the cavity is then syringed . Every cell must be freely laid open into the wound, as otherwise infection will continue to spread through the bone, and cause her trouble; all edges must be left sloping, with no overhanging . It may be necessary to remove the tip of the mastoid process, ells extend into it. The wound is packed with iodoform gauze, , after a lapse of four or five days after the operation, should be ssed on alternate days, or daily if discharge is profuse. A Bezold's foration must be enlarged, and possibly an incision in the neck y be prevented if the case is treated early.

he factors that may persuade the surgeon to operate earlier than r a lapse of fourteen days are: (*a*) the presence of a subperiosteal ubcutaneous abscess in the neighbourhood of the mastoid antrum ir cells, (*b*) thrombosis of the lateral sinus, (*c*) paresis or paralysis he facial nerve, or (*d*) brain abscess.

hronic Otorrhœa is a common sequela of an acute attack. The nbrane is perforated, and the discharge varies in amount and racter. In uncomplicated cases, treatment consists of: (1) Im- vement of the general health, as by the administration of tonics, dence in fresh country air, and avoidance of chills. (2) Attention he naso-pharyngeal condition, so as to ensure a healthy condition the Eustachian tube, by which discharges may escape Steam alations or oily sprays may be ordered, and adenoids and enlarged sils may require removal. Any sinus infection must be treated. The middle ear must be kept free from any accumulation of dis- rge which might undergo decomposition. When the purulent etion is abundant, the meatus should be mopped out or be syringed h sterile salt solution or weak boric acid solution. If the discharge offensive, or difficult to dislodge, the occasional use of drops of oxide of hydrogen (10-volume strength) will be found useful before nging. If the discharge is slight, the meatus may be insufflated h boric acid powder containing 0·75 per cent. of iodine, and syringing ided. Drops of alcohol (S.V.R.) are of use, if instilled twice daily. unfrequently, however, a persistent discharge from the ear is

due to some of the complications mentioned below, and further operative treatment may be required.

The **Surgical Complications of Otitis Media** are often serious, and call for prompt treatment; they may be classified under four headings —those affecting the external, middle, and internal ear, and those involving the intracranial contents.

The **complications of otitis media** affecting the external ear are comparatively unimportant. (*a*) **Dermatitis** of the meatus is frequently seen, and merely needs the parts to be kept dry and clean, and a little boric acid powder insufflated; it readily disappears when the discharge ceases, but is not unfrequently associated with enlargement and suppuration of the cervical glands. (*b*) **Boils** arise from pyococcal infection of the sebaceous glands or hair follicles in the meatus, and are exceedingly painful, owing to the denseness of the tissues involved. They should be fomented. A pledget of wool soaked in 5 per cent. chinosol and 2½ per cent. phenol in glycerine may be inserted and left from fifteen to twenty minutes, followed by drops of unguentum hydrarg. nit. dil. (℥i.) in ol. amygdalæ (℥i.). Incision should be avoided if possible, because of the danger of causing diffuse cellulitis. (*c*) Inflammation may occasionally spread to the tympanic plate of the temporal bone, leading to subperiosteal abscess and necrosis, or it may extend into the temporo-maxillary articulation, giving rise to suppurative arthritis.

The **complications of otitis media** in the middle ear are often of a grave nature, and may produce deafness, or endanger life.

(*a*) The **ossicles** become ankylosed, or may become carious, the hearing being impaired in either case, but not necessarily destroyed.

(*b*) The inflammation may extend to the bony walls of the tympanic cavity, giving rise to a limited **caries** or **necrosis of the temporal bone.** This may be associated with suppuration within the skull, and any of the intracranial complications mentioned below. The roof of the tympanic cavity (*tegmen tympani*), which is very thin, is especially liable to be affected in this way.

(*c*) **Polypi** may develop in chronic cases, they consist essentially of granulation tissue protruding through the opening in the membrane (Fig. 1048), thereby hindering the escape of the discharge. They may be removed by the snare or curette, and the base touched with a saturated solution of chromic acid, only, however, in cases where a fistula in the underlying bone has been excluded; the ear is subsequently dressed antiseptically.

(*d*) **Cholesteatomata** result from ingrowth of epidermal cells into the tympanic cavity through a perforation in cases of chronic otitis media of some years' duration. Squamous cells are cast off and mix with bacteria and secretions to form a mass which, by gradual absorption of moisture and increase in size, may destroy parts of the bony walls, sometimes causing intracranial complications.

(*e*) **Facial Paralysis** not uncommonly arises in chronic cases from caries of the bony walls surrounding the aqueductus Fallopii, causing inflammatory changes around the facial nerve in the canal. Inflammatory spread into the sheath of the nerve may occur also in

acute cases, with paresis or paralysis of the facial muscles. It must be remembered that the bony canal lies immediately behind the tympanic cavity, and to the inner side of the passage from the attic to the mastoid antrum (*aditus ad antrum*). More especially in cases of tuberculous nature, the nerve may be actually exposed as a result of necrosis or absorption of the bony wall of the aqueduct, and this may lead to direct infection, or even destruction of the nerve itself.

Treatment.—In some chronic cases, where discharge is kept up by infection of the mastoid antrum, or where complications, such as cholesteatoma or caries of ossicles, are present, a more extensive proceeding known as the *radical mastoid operation* is required. The cartilaginous meatus is detached posteriorly from the bony margins, and the antrum is opened and the whole of the osseous tissue intervening between it and the meatus and tympanic cavity in front is gouged away. In the region of the ridge of bone over the facial nerve the bone superficial to Hugh Jones's line—an imaginary line drawn from the most prominent part of the external canal to the lowermost part of the bony external auditory meatus—may be removed with safety. The facial nerve lies deep to this level. The remains of the membrane and the ossicles are removed if grossly diseased, and the cavity curetted (Fig. 1053). The deep portion of the posterior wall of the cartilaginous meatus is incised above and below, and the flap so formed is stitched to the posterior edge of the wound, the meatus thus leading to the cavity in the bone, which can in this way be cleansed more efficiently. Thiersch-grafting is sometimes employed to secure more rapid epidermatization of the wound in the bone.

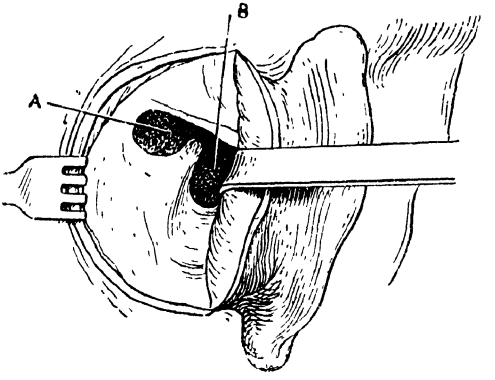

FIG 1053.—RADICAL MASTOID OPERATION

The antrum (A) has been thoroughly opened up, and the bridge of bone covering the aditus removed, thus bringing the antrum into free communication with the tympanic cavity (B), which is curetted and the ossicles removed.

Involvement of the Internal Ear or **Labyrinthitis** may be localized or diffuse, and results from the spread of infection inwards, either through the wall of the external semicircular canal, or through the fenestra rotundum or ovale; in the former case the posterior or vestibular portion is involved, in the latter the cochlea. The condition may arise both in acute and chronic cases. Invasion of the semicircular canals is evidenced by vertigo, a tendency to fall towards the affected side, nystagmus and vomiting; pain and fever are present in the more acute forms. Involvement of the cochlea results in

tinnitus and absolute deafness. As the perilymph and endolymph systems of the semicircular canals, ventricle, saccule and cochlea are in direct communication, inflammation in one region rapidly involves the other subdivisions. Infection of the meninges often arises by spread of inflammation along the internal auditory meatus.

The **intracranial complications** of otitis media are relatively more common in the acellular type of mastoid, inasmuch as it is almost impossible for the inflammation to extend towards the surface, and therefore it is liable to progress deeply.

(*a*) **Extradural Abscess.**—For general phenomena connected with this condition, see p. 900. Accumulations of pus occur most commonly along the summit of the petrous portion of the temporal bone, more commonly in chronic cases. The patient complains of pain and headache, extending over the affected side of the head, which gradually increase and are followed by drowsiness, lapsing into coma. The complication may arise after years of chronic otorrhœa, and is sometimes associated with sudden cessation of discharge. The temperature is raised, but rigors, even if present at first, are by no means a constant feature of the case. The pulse is of the usual febrile type, *viz.* quick, full, and bounding. There is no pain in the neck along the course of the jugular vein, but retraction of the head occurs if basal meningitis appears, and vomiting is a marked symptom. Optic neuritis may be observed in consequence of the inflammation extending to the membranes at the base of the brain. There may be some tenderness on pressure over the temporal region, and possibly œdema.

The **Diagnosis** from *cerebral abscess* is sometimes a matter of considerable difficulty The symptoms, however, set in somewhat more acutely, whilst the temperature is raised, and the signs of irritation of the membranes suggest that the lesion is extradural, and not cerebral in origin. The pulse is fast, and not slow, and focal symptoms are less likely to develop.

The **Treatment** consists in enlarging the opening made in the bone for treatment of the mastoid trouble, so as to ensure efficient drainage. As much bone is removed as will ensure thorough exposure of all affected dura, characterized by overlying pus or the presence of granulations.

(*b*) **Meningitis** may be localized or diffuse; it is generally an early complication of acute otitis media. The former is due to extension of infection from the middle-ear tract, generally through caries of the tegmen tympani or antri; the meninges adhere together, and spread of infection is thereby prevented. The diffuse variety is always infective in nature, and secondary to some suppurative affection in the neighbourhood, or to thrombosis of the lateral sinus. The route of entry is sometimes through small veins; spread from the internal ear may travel through the internal auditory meatus to the cisterna pontis or basalis. (For symptoms, see p. 902.) Occasionally a simple serous effusion occurs within the meninges, leading to increased pressure and consequent drowsiness. The condition is of extremely serious import. It is characterized by restlessness, stiffness of the

neck, or retraction of the head, possibly associated with Koenig's sign and also with changes in the cerebro-spinal fluid.

Treatment in the early acute stages is by sulphonamide therapy and not by operation.

(*c*) **Thrombosis of the Lateral Sinus** arises from direct extension of the inflammatory process from the middle ear through the mastoid bone, or it may be set up by an infective thrombosis of the mastoid emissary vein spreading to the sinus in the course of an acute attack. A clot forms within the sinus, possibly at first on one wall without completely stopping the blood-stream (mural thrombus); this, gradually increasing in size, leads finally to occlusion of its lumen. Infection with pyogenic organisms determines disintegration of the clot; infected emboli are detached, and thus pyæmic symptoms originated. In well-marked cases the thrombus extends back as far as the torcular Herophili, and downwards along the jugular vein.

The most marked **Symptom** of the case is a sudden rise of temperature, which is usually remittent, associated with rigors, vomiting, and localized pain in the head, perhaps most marked over the point of emergence of the emissary vein at the posterior border of the mastoid process. The pulse is rapid, feeble and easily compressible, and in the later stages the patient is drowsy and dull, probably from serous exudation within the meninges. Optic neuritis may or may not exist, being often preceded by photophobia. If the thrombus extends into the neck, a firm, tender, elongated swelling is felt in the region of the jugular vein. The cervical lymphatic glands become enlarged, stiffness of the muscles at the back of the neck is an evidence of associated basal meningitis, as also is optic neuritis Suppuration may occur outside the sinus, or around the vein in the neck, which becomes swollen, red, and œdematous.

In well-marked cases the **Diagnosis** is easily made, but in the early stages, and especially in children, it is often a matter of some difficulty. The abrupt onset, the oscillating temperature, the recurrent rigors, the pain in the neck, and the deep tenderness on pressure over the course of the lateral sinus or jugular vein, are the most trustworthy signs of this affection.

Treatment.—An incision is first made along the anterior border of the sterno-mastoid, through which the jugular vein is tied, so as to prevent the escape of any more emboli into the general circulation. In cases where the thrombus has extended into the jugular, the ligature must, of course, be placed on its proximal aspect, and this may involve exposing the vein in the lowest part of the neck, and placing the ligature close to the innominate. A mastoid operation is performed, and by extending its scope backwards the sinus can be exposed. A puncture with a fine needle readily determines whether the sinus contains fluid blood or thrombus, but would not detect a mural thrombus. If, therefore, there is any evidence of inflammation or pus around it, the sinus should be opened. The lateral sinus is now freely incised, and the infected thrombus partly scraped, partly washed away, the opening in the bone being increased in size, if necessary. It is desirable, but not essential in the simpler cases, to remove com-

pletely the lower part of the thrombus; if this is attempted, the jugular must be opened above the ligature, and the clot syringed or scraped away. Bleeding occurs from the posterior part of the upper opening as soon as all the coagulum is removed, but is easily controlled by plugging the sinus with a small piece of aseptic gauze. The wound in the neck should be lightly packed and not closed, since infection and suppuration are almost certain to follow. The upper wound is also packed in the same way, and allowed to granulate.

(*d*) **Abscess** in the cerebrum or cerebellum, a complication not unfrequently met with, has been already discussed (p. 902).

General Treatment.—In all cases where complications arise from acute otitis media or mastoiditis, it is necessary to determine the type of causative organism; if, as is usually the case, hæmolytic streptococci or pneumococci are present, sulphonamide thereby must be instituted, if not already commenced.

By this form of treatment cases of varying type, including some with meningitis, which would otherwise be fatal, may be saved.

CHAPTER XLIX.

SURGICAL AFFECTIONS OF THE EYE.

By N. BISHOP HARMAN, M.A., M.B.(Cantab.), F.R.C.S.

The separation of affections of the eye into medical and surgical groups is a separation of convenience and not of ætiology, and in this chapter only those will be considered which arise from injuries or superficial infections, or for which surgical treatment is necessary.

Injuries to the eyes are common in every walk of life, and particularly in industry, and as they are frequently the subject of arbitrations or lawsuits for compensation, the surgeon should always record carefully in writing, with sketches, his observations of any case of injury at each time of seeing it. The first examination should be systematic and thorough, including the vision and condition of each eye. When a man is injured his first desire is to know that his sight will be saved, and his answers are likely to be correct; later, the prospects of indemnification may bias his replies. Make an examination of the fundus reflexes with the retinoscope; determine the character of refraction, then test the vision subjectively; record the visual acuity as determined by the patient's ability to read the letters of the distance test card. Begin the reading with both eyes open, and slip a +6D cylinder before the good eye, and a +0·25 cylinder before the damaged eye, both cylinders with the axes vertical. What is seen is seen with the injured eye. With this test the patient does not know that the eyes are being used separately.

Foreign Bodies.—The entry of a foreign body into the eye is an extremely common accident; hence the need for guards to machinery, and of suitable goggles in dangerous trades. The lower lid is easily pulled down and the fornix inspected. The upper lid is difficult, less easy to evert, and since the upper fornix is the more likely to harbour foreign bodies it is the more important to examine it. Instruments should not be used; they frighten children. The eyelashes should not be used to pull over the lid; young ladies object to their loss. To the practised hand everting the lid is a neat performance. It is done with the worker's thumb and index finger, and *the patient's lower lid.* Stand facing the patient, use the right hand for the left eye, and the left hand for the right eye. Tell the patient to look down. Place the inner edge of the thumb parallel with the lower lid and on its outer half, just below the lashes. Place the index finger lightly on the upper lid just above the lashes, and gently push up the skin; this will cause the edge of the lid to lift from the globe and pout a little. Now with the thumb in position, slip the lower lid under the upper lid, and the thumb, following the lower lid, will get under the upper lid, which can then be held firmly between thumb and finger

and everted, even against a vigorous orbicular spasm. The secret of the trick is to make the *lower lid* do the work of raising the upper; it acts as a wedge to separate the upper lid from the globe and allow the thumb to follow through. The inspection of the cornea is less easy, especially in brown-eyed subjects, but for this purpose the

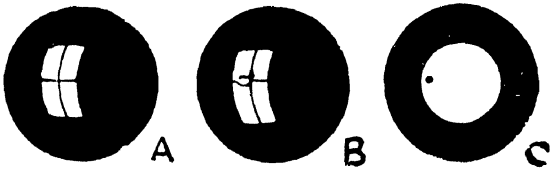

FIG 1054.

A Shows the perfect reflection of the window upon the surface of a normal cornea. B shows the reflection broken at one part by reason of a foreign body on the surface of the cornea. C, The foreign body is seen as a black speck against the fundus reflex obtained with the ophthalmoscope.

reflection of the window or other light on the cornea (Fig. 1054) may be used, the eye should be moved so that each portion of the cornea is employed methodically as a reflector. If there is a foreign body on the surface, its presence and site will be seen without difficulty by the broken reflex. The removal of the foreign body is usually effected



FIG. 1055. HARMAN'S 'NIBLICK-SHAPED' SPUD FOR REMOVING SURFACE FOREIGN BODIES.

The end (shaped like a golf niblick) is pressed vertically on the cornea beside the foreign body; thereon a forward movement lifts the object without disturbing the epithelium.

without difficulty with a spud after the instillation of cocaine. The choice of a spud is of some moment, for the foreign body must be removed with the least possible disturbance of the corneal epithelium. If the accident is recent my 'niblick shaped' spud (Fig. 1055) may be used, the end is pressed on to the cornea beside the foreign body



FIG. 1056. SPUD FOR REMOVING FOREIGN BODIES FROM CORNEA.

The blade is shown flat and in profile.

so as to depress the surface; then a forward movement will lift it off the cornea without scraping the epithelium. If the foreign body is embedded within the epithelium, a chisel-shaped spud (Fig. 1056) should be dipped into the epithelium beneath the foreign body, and thus, with some cells, should be lifted off. If the foreign body is fixed in the substance of the cornea, a needle must be used that will

prick into the tissue beneath the foreign body and push it out, but this last manœuvre should not be used except when it is imperative, for it damages the tissues and may open up the corneal spaces to infection. Every foreign body involves a certain element of risk from this source, and therefore irrigation should follow its removal. With older men there is not unfrequently some sepsis of the lachrymal sac, and a foreign body in such a subject is likely to be followed by infection, resulting in hypopyon ulcer and damage to the sight. For this reason pressure should always be made over the site of the lachrymal sac after the removal of the foreign body, and if there is the least suspicion of regurgitation the sac should be syringed out and examined daily. If the sac is manifestly septic, the puncta should be sealed up by the application of the actual cautery, and the sac laid open and drained or else excised.

A complaint of grit in the eye may be the initial sign of an attack of conjunctivitis; it is then accompanied by general suffusion of the conjunctiva. Occasionally an eyelash becomes fixed in one of the puncta, and sets up a local irritation. In summer, the wing cases of beetles may adhere to the cornea and set up a lesion simulating a phlyctenule. Careful examination with a corneal loupe will determine the nature of the lesion.



FIG. 1057.—BOWMAN'S NEEDLE WITH STOP ON SHANK

Penetrating wounds of the cornea are usually produced by chips of metal flying from a rotating machine. The foreign body may project into the anterior chamber, or its track may be seen in iris or lens. If it is projecting through the cornea into the anterior chamber, it should be pushed back by pressure made upon it from within the eye by means of a broad needle inserted through the margin of the cornea into the anterior chamber. If there is reason to suspect that the foreign body is more deeply placed, the pupil should be dilated, and the media and fundus thoroughly explored with the ophthalmoscope. Recourse may also be made to radiography; narrow metal strips should be strapped on the lids and temple, and skiagraphs of the head taken from front and side. If a dense foreign body is present, its shadow can be seen and its position determined by its relation to the shadows of the metal strips. The position of the fragment will determine its treatment. Iron and steel may be removed by the use of an electro-magnet introduced through a wound in the sclera, and sometimes with complete success, but unfortunately in most cases inflammation supervenes, and vision is much impaired.

When a piece of iron or steel remains embedded in the eye, it becomes firmly encased in fibrous tissue. Chemical action set up by the presence of the metal causes changes known as siderosis, vitreous degeneration and opacities, gross pigmentation of the choroid, and optic atrophy. If iritis should supervene, or the eye is blind, it should be excised without delay for fear of sympathetic disease.

Burns and Scalds, when they affect the eyeball, are usually severe in their reaction, causing intense engorgement of the conjunctiva and much swelling of the lids. Examination of the eye is difficult, but the cornea must be examined; if it appears whitened and dim on separating the lids, serious damage may be expected. Whatever the nature of the accident, whether it be due to steam, flame, lime, or chemicals, the eye should never be washed with water, but some heavy neutral oil, such as olive oil, cod-liver oil, should at once be instilled. Pure cocaine, dissolved in castor oil, may be used to relieve pain. Particles of lime or any other foreign bodies must be picked out. Continuous cold applications to the lids will give much relief, and reduce the risks of inflammation. Each day the lids must be gently separated, and if the conjunctiva has been damaged, a glass rod must be passed between the lids and globe to prevent as far as possible the formation of adhesions between the raw surfaces, and subsequent symblepharon. If such adhesions should develop, they are likely to invert the edge of the lid against the cornea, and then operation is required when the eye is quiet. The adhesion is severed down to healthy tissue, and a graft of mucous membrane from the patient's mouth, or of frog's skin, is wrapped round a suitably shaped piece of lead foil, and slipped deeply into the wound. The eye is then bandaged over this and left undisturbed for a week. Shrinkages of the conjunctiva are frequent and difficult to deal with.

Contusions of the Eye.—In most cases of 'black eye' the eye itself is undamaged. If the eyeball is struck, a variety of injuries may result. Traumatic mydriasis is common, the pupil being dilated, and the reaction to light poor or absent; the power of accommodation may also be lost. The lens may be concussed, with resulting opacities, or it may be dislocated. Vision may be impaired from concussion of the retina without perceptible injury, and recovery may follow. Should the macula be damaged, or the retina torn, vision is seriously impaired.

Rupture of the eye with escape of the lens and some of the vitreous may result from a blow. The rupture is nearly always at the thinnest part of the sclerotic, *i.e.* just behind the cornea. The tension of the eyeball is lost, and the anterior chamber may be full of blood. The only treatment lies in excision, for the eye will be blind, and sympathetic disease has been known to follow.

Penetrating Wounds of the Eye.—Wounds of the *conjunctiva* heal rapidly after cleansing with a mild antiseptic lotion. It is unnecessary to suture them unless they are large. Penetration of the *cornea* is serious, since the iris is liable to prolapse and vision to be impaired. If the wound is quite fresh, the iris may be replaced by a repositor, atropine being instilled freely so as to dilate the pupil to a maximum. Wounds of the *sclerotic*, if small, heal readily; they should be freely irrigated. Wounds within a quarter of an inch of the corneal margin are likely to involve the ciliary body, and may be followed by cyclitis, especially if the *ciliary* body is prolapsed or incarcerated in the wound. Inflammatory changes following such wounds are very likely to be followed by sympathetic disease, and, therefore, if after such an injury the sight is found to be lost, or nearly so, *e.g.* if only

perception of light is retained, immediate excision should be performed. If, however, there is but little impairment of sight, the character of the treatment requires most careful consideration. Excision should be undertaken even if the wound of the ciliary region is small, when severe iritis follows, and it should be urged if the lens is injured, or if there is reason to suspect the presence of a foreign body.

Sympathetic Disease.—The danger of an injury to one eye is not always confined to that eye. The other eye may become affected by sympathetic irritation or sympathetic inflammation. The affection rarely begins before three or four weeks after the date of the injury, and it may be delayed for months or years. A badly damaged eye is therefore a constant menace, and children are particularly susceptible.

Sympathetic Irritation shows itself by attacks, usually repeated, of photophobia, congestion and watering of the eye, failure of accommodation, neuralgic pains in the head, and floating bodies seen in the field of vision. Excision of the injured or exciting eye will, as a rule, stop the trouble.

Sympathetic Inflammation is a terrible disease. It is essentially a fibrinous iridocyclitis. Tough adhesions are formed, fixing the iris to the lens, which becomes opaque, and the vitreous and retina are involved, so that the eye becomes hopelessly blind. The cause of the disease is not definitely known, but it has been attributed to transmission of bacteria through the circulation, to a lymphangitis travelling from one eye to the other along the optic nerve sheath, or to a spreading neuritis by way of the ciliary nerves. A recent theory has suggested that it is an anaphylactic condition due to the absorption of uveal tissue, thereby sensitizing the body to uveal tissue, and rendering the uveal tract of both injured and uninjured eyes liable to attacks of inflammation. The latest theory is that it is of protozoal origin, for blood-counts in some cases show an excess of large mononuclear leucocytes (24 per cent. against a normal 2 to 5 per cent.), similar counts occur in malaria and syphilis, which are protozoal diseases. This last theory would suggest the use of salvarsan or its equivalents, and in some cases marked improvement has followed such treatment.

The attack is ushered in by the deep circumcorneal vessels of the uninjured eye becoming engorged, and by the appearance of numberless white spots of lymph, deposited from the aqueous on the back of the cornea, *Keratitis punctata* (Fig. 1065). They can be seen either by examining the cornea by focal light and the use of the loupe, or with the slit-lamp and microscope, or by direct ophthalmoscopic examination with a +20D lens, when the deposits show up as minute black spots against the red fundus reflex. Attacks of sympathetic irritation that are followed by the appearance of these spots are a danger signal of the gravest order. If no remission of the symptoms is obtained, it is almost certain that the disease will progress to the total destruction of the sight of both eyes.

Treatment.—There must be complete rest in a dark room. Mercurial inunctions should be given, with massive doses of salicylate of soda—*i.e.* 1 grain for each pound of the body weight per diem. If the blood-count shows excess of mononuclear cells, a course of salvarsan

should be given. Locally, fomentations are employed continuously, and atropine 2 per cent. thrice daily; each night for a week, two or three leeches should be applied to the temple. Atropine is useless when there are old and tough adhesions; it is then an irritant.

In the earliest stage of the disease, the exciting eye should be excised immediately; but if the disease has advanced seriously so that there is little sight in the sympathizing eye, it is perhaps wiser not to remove the exciting eye, since ultimately it may retain the better vision of the two. When the disease has subsided, if any useful vision is retained, it is wise to leave the eyes alone. If after a long period of quiescence it is judged that some improvement of vision might result from the performance of an optical iridectomy, with the extraction of the lens if opaque, this proceeding is justifiable, but there is always risk that the massive lymph deposits will again shrink and close the aperture.

Excision of the Eyeball.—This operation is most frequently needed for badly damaged eyes, but sometimes for blind and painful eyes, and more rarely for malignant tumours. A general anæsthetic is indicated. Local anæsthesia by deep injection into the orbit is used by some Continental surgeons, but is not recommended.

The operator stands behind the patient's head. The lid-speculum is inserted. The conjunctiva is picked up with fixation forceps, and cut round the limbus as close to the cornea as possible. The cut edge of the conjunctiva is held firmly, and then with curved squint scissors the underlying tissues are divided deeply around the globe as though trying to reach its equator. This manœuvre is designed to detach Tenon's capsule from the globe, and unless it is carried out effectively, it is not possible to secure the tendons of the recti muscles, which must be severed as the next step. When Tenon's capsule has been opened, the squint hook, with the point pressing against the globe, is slipped round the equator; the hook comes up against the various recti tendons. Each of the four tendons is divided close to the globe, save the internal, which should be left a few millimetres long so as to provide a hold for the next step. The eye is now loose, and pressure downwards of the unlocked speculum will cause the globe to pop up out of the orbit. Grip the tag of the internal rectus tendon with the forceps, and turn the eye towards the outer canthus; then take a pair of strong curved scissors in the other hand, slip them down between the globe and the inner canthus for a couple of inches, until the optic nerve can be felt. Open the scissors so as to include the nerve within their blades, and cut firmly. The eye can then be lifted out, and the dragging bands of the oblique muscles cut close to the globe. Hot water poured into the cavity acts as a hæmostatic, and the conjunctiva is drawn together so as to cover any tags. Several pads of gauze are placed over the closed eyelids and bandaged firmly. The patient may be allowed up in a few days, and an artificial eye may be introduced within a month of the operation; it should be on the small side, so that the lids may wipe it completely with each blink. It is well to have two shells, and to wear them in turn, so as to prevent irritation of the socket.

Chalazion.—This small tumour is due to disorder of a Meibomian gland. These glands are set in the margin of the eyelids. They are

the grease glands of the lids. They lubricate the margins, prevent tears running on the face (except when in excess), and prevent soreness from blinking. The glands are long and tortuous. The chalazion is due to microbic infection. A granuloma is produced within the gland, and later this breaks down, producing a cyst-like gelatinous mass of cells. The chalazion is then said to be ripe. When in this state the appearance of the lump on the inside of the lid is characteristic. There is a dusky patch encircled with a rim of red. The dusky patch will be found, on touching it with a small probe, to be soft. Many attacks of this order will subside after the use of frequent hot bathing to the eye, or fomentations. Gentle massage may secure the discharge of the offending cells from the gland. But if these measures fail, then the mass must be evacuated by surgical means.

A few drops of cocaine and adrenalin should be instilled. After five minutes the operation may be done. The lid should be everted and held in a suitable forceps so as to prevent bleeding from the marginal artery. There is no more suitable forceps for this purpose than Graddy's expression forceps (Fig. 1058). They are better than those with complete rings and plates on the skin blade. Forceps with ratchets or clamps may be dangerous, since the lid may be gripped too severely.



FIG. 1058.—GRADDY'S TRACHOMA FORCEPS AND SHARP SPOON.

The incision should be made with a fine, very sharp knife, and be vertical to the lid margin. It must never be parallel with the margin, for this will mean that other glands are cut. The next step is to scrape out the interior with a small sharp spoon (Fig. 1058). This is the painful part of the procedure, for the cocaine does not penetrate deeply. To diminish pain and make the scraping more effective, it is well to dip the spoon into some liquid pure carbolic. The spoon with its droplet of carbolic is then slipped between the lips of the wound deep into the mass of cells. It should be held there for a minute. The carbolic will effectively anæsthetize the interior. It can then be scraped out by quickly rotating the handle of the spoon between thumb and fingers. This is far better than attempting a direct scraping of the walls. The cell mass will be extruded, and may be wiped away. Care should be taken to see that none of the granulations is left between the lips of the wound. If the chazalion has been well scraped in this fashion there will be no subsequent bleeding. The conjunctival sac may be wiped clean with lint, the midriatic effect of the cocaine neutralized with a drop of eserine, and the patient may go home without a bandage. He should be told to bathe the eye frequently with hot water, and to use some astringent drops, such as zinc sulphate.

A chalazion is not a stye. A stye is a pustule on the outer edge of the lid margin in a sebaceous gland attached to a hair follicle. It can be emptied in many cases by pulling out the eyelash. Hot fomentation will promote evacuation. Occasionally it is necessary to pierce the centre with a small sharp knife. It is never necessary to scrape it out.

Conjunctivitis.—The conjunctiva is a delicate mucous membrane which lines the inner surface of the eyelids and the front part of the eyeball, thereby securing free mobility of both. At the lid margins it is studded with grease glands. It is kept moist partly by the secretions of the mucin from the epithelium, but mainly by the tears that flow from the ducts of the lachrymal gland over the front of the eye to the inner canthus, where they normally pass down through the lachrymal puncta into the sac, and so down the duct into the nose. The mucous membrane on the under surface of the upper tarsal plate is not everywhere quite smooth, as it has there many folds and crypts which were formerly described as Henle's glands, numerous lymph follicles also are embedded in the submucosa. The epithelial layer of the membrane is continuous with that covering the cornea, which, indeed, is of true conjunctival origin.



FIG 1059.—ANGULAR CONJUNCTIVITIS, BOTH EYES AFFECTED.

The Morax-Axenfeld bacillus was cultivated from the discharge on two occasions at the interval of one month. The fan-shaped areas of sodden skin at each canthus are characteristic.

Inflammation of the membrane (conjunctivitis) is marked by the four signs of that condition, *viz.* redness from the distension of the vessels, which, since they are little supported, are apt to bleed; heat, from the hyperæmia; swelling, that may be a slight œdema or an intense chemosis, rendering the lids and globe immobile, and therewith the skin of the lids will be glossy; and pain, which is described as like 'grit in the eyes,' even to a severity as though 'broken glass were rolling under the lids.' Lachrymation is marked; the Meibomian glands pour out a frothy secretion, and the mucous cells are over-active; leucocytes escape, and thus a secretion is produced, consisting of tears, mucus, and pus cells, and in severe cases it may be stained with blood. The discharge clings to the lid lashes and tends to seal the lids. There is always disturbance of vision, much or little according to the severity of the attack.

Conjunctivitis may arise from a variety of causes. Mild attacks follow exposure to wind, dust, smoke-fumes, or heat. Reflex irritation due to septic teeth, nasal douches, gastritis, or the taking of stimulating foods will produce similar symptoms. Exposure to bright light, such as the arc-lamp, ultra-violet rays, or snow-fields, will cause smart attacks characteristic of 'snow blindness.' Drugs are frequently excreted by the mucous membrane, and, if irritating, will produce conjunctivitis, *e.g.* arsenic. Tired eyes, from late hours or errors of

refraction, cause mild attacks, and these, if repeated, may become chronic.

Epidemic conjunctivitis is common amongst children and unwashen people, and prevalent in the dry dusty months of March to May. Two varieties are described: (1) *Angular* conjunctivitis (Fig. 1059), which is a mild but chronic condition causing redness of the mucosa and of the corners of the eyelids. There is excessive blinking, and the secretion is frothy like beaten white of egg It is due to infection with the Morax-Axenfeld bacillus (Fig. 1060). (2) *Muco-purulent* conjunctivitis, which is a highly contagious form of catarrh. If one member of a household is attacked, all are likely to catch it, unless toilet arrangements are satisfactory. It is the common 'pink eye' of schools. The eyes are red, and there are minute hæmorrhages, there is discharge of muco-purulent fluid. The lymph follicles are swollen and visible to the naked eye, especially in the lower fornix, and sometimes the pre-auricular gland is enlarged. The infective organism is the Koch-Weeks bacillus (Fig. 1062), a minute organism very like the bacillus of influenza.



FIG 1060.—FILM PREPARATION OF THE SECRETION, SHOWING THE MORAX-AXENFELD BACILLUS (×1,000)



FIG 1061.—OPHTHALMIA NEONATORUM

Swelling, redness, and excoriation of lids, discharge of thick yellow pus. Sixth day after birth, disease began third day.

The attacks may be very severe, and in hot countries are liable to be associated with corneal ulceration.

Since there are many causes of conjunctivitis, **Treatment** must be varied. The first step is discovery of the cause, especially of those mild

attacks which are not of microbic origin. The treatment of **angular** conjunctivitis is easy; zinc sulphate is a specific which may be used freely, either in ¼ to ½ per cent. strength as an eye-lotion, or better dropped into the lower eyelids with a pipette.

For an acute attack of **muco-purulent** conjunctivitis, the mucosa should be cleaned by one painting with some silver preparation, either a ½ or 1 per cent. silver nitrate solution, or one of the colloidal preparations. This is followed by free ablution and the use of drops of zinc chloride (⅛ per cent.) during the acute stage, and zinc sulphate (½ per cent.) during the convalescent stage. It is important to continue the use of the astringent drops for at least one week after the conjunctiva appears perfectly normal, since organisms may be lurking in the crypts and cause a relapse.

Acute Purulent Conjunctivitis is a very serious disorder. The cases that will attract most attention are those occurring in new-born infants,



FIG 1062.—FILM PREPARATION OF DISCHARGE FROM A CASE OF MUCO-PURULENT CATARRH, SHOWING THE KOCH-WEEKS BACILLUS (×1,000.)

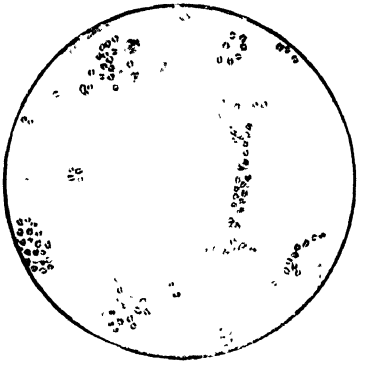

FIG. 1063.—FILM PREPARATION FROM A CASE OF OPHTHALMIA NEONATORUM, SHOWING THE MICROCOCCUS OF NEISSER (×1,000)

Ophthalmia neonatorum, which is due in 80 per cent. of the cases to a gonococcal infection of the eyes of the infant during birth (Fig. 1063). The inflammation begins usually on the third day. The lids are red and swollen, and their edges are stuck together by discharge (Fig. 1061). When they are opened, yellowish pus and sanious fluid escape, and on everting the lids the conjunctiva is seen to be extremely congested and velvety. There is grave risk of corneal ulceration and sloughing, and consequently of incurable blindness; 20 per cent. of the blindness found in school-children is due to this cause. About one child in every hundred born in England contracts the disease, and of every 2,000 born one suffers from some damage to the eyes. Even when the disease is treated successfully, and no corneal ulceration ensues, it is found that the children suffer in later years from nystagmus, as a result of the closure of the eyes and lack of the stimulus of light during the first few weeks of life. Prevention is therefore urgently necessary, and

much has been done of late years to reduce the incidence of the disease: (1) by antenatal measures for the discovery and treatment of vaginal disease in expectant mothers; and (2) by making the disease notifiable.

Preventive measures are also applied to the baby. Directly its head is born, the eyelids are wiped free from mucus with clean cotton-wool, a fresh piece for each eye, and as soon as the mother is settled, the eyes of the infant are washed with soap and water and then freely irrigated with boracic lotion or Condy solution (2 per cent.). The water for the first bath of the child must not get into the eyes; separate water and a clean towel must be used for the face. At no time during the lying-in period may the mother's sponges, napkins, etc., be used for the infant. If at delivery there is any suspicion of a purulent vaginal discharge from the mother, the eyes of the child must be cleansed as directed, and afterwards a drop of silver nitrate (1 per cent.) is instilled between the lids (Crede's method). The eyes must be examined and washed at the end of eight hours, and if there is any discharge the silver drop may be repeated. In case of doubt, a bacteriological examination of the discharge should be made without delay.

The treatment of ophthalmia neonatorum demands efficient and continuous nursing, for the oft-repeated cleansing of the eyes from the discharge is essential. The eyes must never be bandaged, and discharge should be wiped away as soon as it appears. The eyes should be freely irrigated at least six times a day with an abundance of boric lotion, but no pressure may be used, and no instrument (save a retractor by the surgeon during examination) may be thrust between the lids After each cleansing the skin of the lids should be dried with cotton-wool, and greased with vaseline to prevent sticking and excoriation. Once a day, after the conjunctiva has been cleansed, the surgeon himself should evert the lids, and carefully swab the whole mucosa, avoiding the cornea, with a solution of silver nitrate (1 per cent.) in glycerine and water (1 : 7), or with one of the colloidal preparations of silver. If the cornea becomes hazy, or an ulcer appears, the treatment is continued, but atropine drops (1 per cent.) are instilled after each douche.

The discharge is eminently contagious, and it is therefore imperative that the patient should be isolated. Great care must also be taken by the nurse and doctor not to infect their own eyes with splashes during the treatment, or by their fingers. They should always use rubber gloves, and goggles should be worn, if an accident should happen, the eye should be immediately irrigated and painted with a 1 per cent. solution of silver nitrate.

Gonorrhœal conjunctivitis *in adults* is a very occasional complication of a urethral discharge. The inflammation is intense, and the risks to sight are great. Similar treatment should be adopted as for ophthalmia neonatorum, but a gonococcal vaccine may also be advantageous. When only one eye is affected, the other eye must be carefully protected from risks of contamination. A watch-glass should be fixed over the eye by strapping, with a wick of cotton-wool between the skin of the outer canthus to provide ventilation. The nurses and doctor treating these patients must exercise the same care of their own eyes as in treatment of infected infants.

Trachoma is a disease which in its features is the very antithesis of purulent conjunctivitis, and yet it is very destructive and the cause of much blindness in countries where it is rife, as in Egypt and the Far East; MacCallan found it in 51 per cent. of the school-children of Egypt, hence the name of 'Egyptian ophthalmia.' It is seen chiefly among poor, dirty, and overcrowded peoples. It is very chronic, lasting one or more years in its active form. The presence of the disease may be unsuspected for some time, unless the lids be everted. Usually there is a little photophobia, with lachrymation. There is slight ptosis, and the lid-margins are thick and purplish. On everting the lids the upper tarsal mucosa is found most affected, the papillæ are exaggerated so as to look like plush pile (Fig. 1064), and the lymph follicles are enlarged and prominent so as to suggest sago grains or frog's spawn (granular lids). The discharge is intermittent and rarely great in quantity, but is contagious. As a result of the irritation of the rough mucosa, pannus appears in the upper part of the cornea, and soft tissue forms between



FIG 1064.—TRACHOMA, LIDS EVERTED
There is gross hypertrophy of the lymph follicles and papillæ, producing a cauliflower-like exuberance

the epithelium and Bowman's membrane, and new vessels grow in from above. Many organisms are found in the discharges, but despite much research the primary cause of the disease has not been determined.

Treatment.—No treatment is known that will produce a rapid cure, and attempts to effect this by too vigorous cauterization or scraping away the granulation usually lead to excessive scarring and entropion. Much good may be done by improving the patient's general health, and the methodical use of astringents to the everted eyelids for a period of many months. In the discharging stages the lids should be painted daily with a 1 per cent. solution of silver nitrate. In the chronic velvety stage the application of solid copper sulphate to the everted eyelids twice a week is the most effective treatment, but it is intensely painful. Equally effective, but less painful, is the use once or twice a week of carbon dioxide snow. A suitably shaped candle of snow is pressed firmly upon the part for from fifteen to twenty-five seconds; the tissue is whitened with the cold, and reaction follows. The application is

painless, but there is throbbing as the part thaws. The object of both these forms of treatment is to cause a reaction, thus setting up leucocytosis, and a subsequent fine interstitial scarring which contracts and destroys the trachomatous process.

At intervals of two months these treatments should be stopped, so that the effect may be seen. During the whole time of treatment an astringent lotion, such as zinc sulphate ½ to 1 per cent., should be used two or three times a day. If it is possible, the patient should be isolated so as to prevent the disease spreading to others.

Pannus, or vascularization of the cornea, is best relieved by treating the lids, but when ulceration is present, atropine may be required. In old-standing pannus with reduction of vision much improvement of sight may be obtained by the operation of peritomy. The conjunctiva is dissected from around the cornea so as to destroy the vessels passing from it into the cornea. The wound soon heals, and if necessary the operation may be repeated. In severe cases, when the patient is almost blind, the scarring may sometimes be reduced by the intervention of an acute conjunctivitis. In former days a gonorrhœal infection was

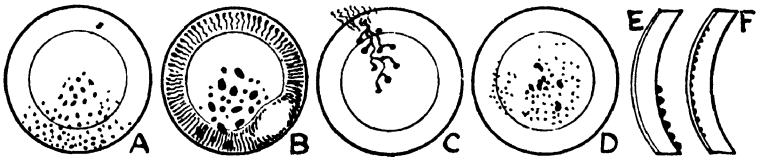

FIG 1065.—SPOTS IN OR ON THE CORNEA

A, Keratitis punctata small precipitates on back of cornea in iridocyclitis. B, Keratitis punctata large 'mutton-fat' precipitates in iridocyclitis with granuloma of iris C, Dendritic ulcer in surface epithelium D, Guttate keratitis spots of hyaline degeneration in Bowman's membrane. E, Section of cornea to show keratitis punctata (see A and B) F, Section of cornea to show guttate keratitis (see D)

used for this purpose, but now a more readily controlled affection can be induced by the use of an infusion of jequirity. Scarring of the lids and painful deformities of the margins and lashes require operation for their relief.

Phlyctenular Conjunctivitis, or **Keratitis,** is a disease common amongst poor and young children. Cases are rare in the first year of life, but are frequent between the ages of four to six years, when the milk teeth are decaying. It is accompanied by intense photophobia and blepharospasm, so that it may be necessary to use a retractor to examine the eye (and this is imperative). The child should be rolled in a blanket to secure its limbs. As soon as the lids are opened, tears spurt out. One or more small whitish elevations will be seen about the limbus, heading a leash of enlarged surface vessels. The bleb usually breaks down into an ulcer, spreading towards the centre of the cornea. The affection is probably herpetiform, since 70 per cent. of the initial lesions in a London children's hospital occurred within the temporo-malar quadrant of the cornea, a part supplied by the orbital branch of the second division of the fifth cranial nerve, *i.e.* in direct connection with the nerve-supply of

the teeth. The affected children are nearly always ill-fed, and there are commonly nasal discharges and septic mouths. The disease is rare in Jewish children, who consume much fatty food. **Treatment** consists of cleaning, feeding, and medication. Teeth and tonsils must be attended to; good food, with plenty of fat and cod-liver oil, is essential; natural or artificial sunshine is most beneficial. For the eyes, the use of ointment of atropine and yellow oxide of mercury (1 per cent. of each), applied between the eyelids thrice daily, is most effective. The vaseline base of the ointment forms a warm, soothing covering, the atropine quiets the ciliary muscle and iris, and the mercurial is a stimulus to repair.

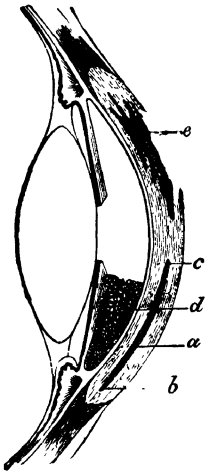

FIG 1066.

a, *b*, *c*, Pus in the substance of the cornea (onyx); *e*, deep infiltrating ulcer with undetermined edges, *d*, pus in the anterior chamber (hypopyon) —a more common condition than onyx

Corneal Ulcers in Adults are not very uncommon and are of two types: (1) The *Dendritic* variety is a superficial ulcer which tends to spread in tree-like formation from the corneal margin as a fine greyish line with considerable irritation (Fig. 1065, C). When fluorescin is instilled into the conjunctival sac, the ulcer shows up brightly green with characteristic branching and buds It is best treated by the application of pheno-camphor, equal parts of pure carbolic acid and camphor. A wooden match should be pointed and the end soaked in the fluid; the wet point should be stubbed into every stained area under cocaine. Atropine ointment is then applied. A second application may be necessary. (2) *Serpiginous* or *hypopyon* ulcer is a very severe disease, and causes much damage to sight. It usually occurs in elderly people of feeble habit, and follows some small abrasion, which gradually spreads in depth and extent It is accompanied by iritis with profuse outpouring of purulent lymph, forming a yellow deposit in the lower part of the chamber (Fig. 1066, *d*). The ulcer is of bacterial (often pneumococcal) origin, and is sometimes associated with infection of the lachrymal sac.

Treatment.—The ulcer should be cauterized with pheno-camphor, and atropine ointment applied, followed by hourly fomentations. Leeches to the temple will relieve the pain. If the ulcer spreads, despite the use of pheno-camphor, it may be necessary to apply the actual cautery at dull red heat around the spreading edge, so as to destroy the undermined margin; the base of the ulcer need not be touched. Further, it may be necessary to empty the pus from the anterior chamber. A fine Graefe cataract knife is passed through the cornea so as completely to divide the ulcer, both ends of the section being in healthy tissue. Usually it is convenient to let the knife enter the cornea at VI on the clock-face and come out at the pivot of the clock hands, making a vertical cut. One side of the cut cornea is then depressed, so as to permit the clinging pus to be

pulled out with fine forceps. Even after the ulcer has healed, a large scar will remain; and it may be necessary to perform iridectomy at a later date to reopen the pupil.

Lachrymal Diseases.—The tear glands are tucked beneath the upper roof of the orbit just above the outer canthus. The tears wash over the globe, and with each blink of the eyelids are partly sucked and partly squeezed into the sac, and so down the duct into the nose. If the puncta do not touch the globe, their action is partly lost, and overflow of tears or epiphora is thereby caused. In old people with shrinkage of the lids this trouble is common. Massage with lanoline will sometimes render the skin supple and relieve the trouble; but it may be necessary to operate. A coarse silk suture is armed with a curved needle at each end, and each needle is passed within the eyelid to come out on the cheek, where the silk is tied over a well-greased roll of lint. The traction of the silk loop suffices to turn the lid inwards and approximate the punctum to the outer conjunctiva, and the mild

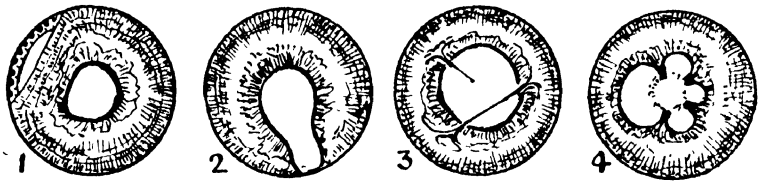

FIG. 1067.—IRREGULARITIES OF THE IRIS.

1, Iridodialysis: the ciliary processes and lens border and ligament are exposed 2, Congenital coloboma of right eye 3, Persistent pupillary membrane 4, Results of iritis: posterior synechiæ, uveal pigment on lens capsule; the pupil is dilated as much as possible by atropine

irritation and the lines of scarring which result keep the lid in its new position.

Obstruction of the nasal duct is common; it follows nasal disease and accidental injuries. The obstruction causes the tear sac to become distended, constituting a mucocele; pressure over the sac brings about regurgitation of its contents, which at first are mucous. Invasion with organisms follows, and the retained fluid becomes purulent. Acute attacks of inflammation or dacryocystitis follow, and the sac must then be incised and drained, just as though it were an abscess. If the obstruction of the duct is complete, it is wise to excise the sac, and this becomes imperative in subjects who are exposed to dust and dirt in their work, and thereby run a risk of developing a hypopyon ulcer. The operation is one of some delicacy, requiring a precise recognition of the site of the sac.

Acute Iritis is in most cases due to internal infection, but may also be caused by an injury. The iris is a richly vascular, muscular, and spongy curtain, which, when inflamed, is swollen with blood and lymph, and its power of movement is diminished; hence the pupil is sluggish, the colour is altered, and its surface becomes gummy and tends to stick to the lens capsule upon which it rests. Diagnosis and treatment are

urgent, otherwise the iris will become fixed to the lens by posterior synechiæ, and in severe cases the pupil will be blocked and the sight lost. Treatment is general and local. General treatment consists in dealing in an appropriate manner with the cause; thus if the iritis is due to syphilis, it is obviously insufficient to treat the ocular condition alone. But whatever the cause, local treatment is urgent, and it is always the same, *viz.* immediate instillation of atropine of sufficient strength to dilate the pupil and tear apart the adhesions. Weak solutions of atropine, *e.g.* ½ per cent., are useless; the solution should be at least 1 or 2 per cent. in strength, and may advisably be conjoined with equal strengths of cocaine, which assists its action. The atropine may be in watery solution, or in oil or in ointment; the last is best, as there is less risk of the drug getting on the skin and setting up atropine irritation. Continuous fomentations are also needed. At the outset of the treatment much benefit may accrue from the application of two, three, or even four leeches to the temple near to the external canthus; this usage will reduce pain and inflammation, and assist the action of the atropine. General medical measures, such as emptying the bowels and the drinking of plenty of bland fluid, are advantageous.

Acute Glaucoma is a disease caused by a disturbance of the balance normally existent between the supply of fluid provided for the nourishment of the eye and its escape from the eyeball. This nutrient and circulating fluid is derived from the vessels of the ciliary body, either by transfusion or secretion, or perhaps both; it passes from the posterior chamber of the eye into the anterior chamber, and escapes through the fine spaces in the extreme angle of the anterior chamber, between the cornea and the root of the iris. If the fluid is in excess and cannot escape, or if the fluid is denser than usual, and so passes less easily through the filtration angle, the tension of the eyeball increases by reason of its excess contents. Equally, if there is loss of penetrability of the filtration angle, the same condition will result. Disease will change the quantity and quality of the eye fluid, and so render filtration difficult. There is great liability to glaucoma in subjects with small corneæ, for it is evident that with a cornea of narrow diameter the filtration area in the rim of the cornea will be much smaller than normal. Also the filtration spaces get furred up with age, and there is a tendency for the large lens of age to push the root of the iris forward so as to overlie and perhaps block the filtration spaces. Glaucoma is therefore usually seen in elderly patients; in young people it is generally due to some gross anatomical abnormality. Usual premonitory signs of *acute glaucoma* consist in a rapid increase of difficulty in reading, redness of the eye, pain and dimness of vision, and haloes or coloured rings seen about a distant light. With the onset of an acute attack there may be sudden reduction or loss of sight, with intense pain over the head, combined with nausea or even vomiting. Such symptoms have frequently been mistaken for 'merely' a severe attack of neuralgia, or even an 'acute abdomen'; it is therefore essential that the eye itself should be examined regularly when there are suspicious pains about the brows together with nausea.

The eyeball becomes congested, and the conjunctiva and the lids

may be swollen. The cornea is anæsthetic to the touch of cotton-wool, and is steamy in aspect, so that the iris may not be clearly seen. The anterior chamber is shallow, the pupil moderately dilated and fixed, perhaps oval, and there is little or no reaction to light. The lens looks greenish. If the fundus of the eye can be seen, there is depression or cupping of the disc. The tension of the eye is raised. This is tested by gentle palpation with the finger-tips, just as in feeling for fluctuation in a suspected abscess.

Treatment is urgent. Palliative, or sometimes preparatory, treatment consists in the instillation of eserine drops (1 per cent.) into the conjunctiva every hour. Fomentations should be employed continuously, and leeches should be applied to the temple and allowed to suck to the full. Even though these measures result in a reduction of the symptoms, as they often will, it is not safe to leave the case at this point. Operation is essential in order to ensure a subsequent free escape of the fluids from the eye, and this is best attained by removing some part of the root of the iris by an iridectomy sufficiently wide and well placed to free the filtration angle; this operation in glaucoma demands much experience and skill.

The general surgeon faced with such a case may in emergency relieve the tension of an apparently hopeless eye by a short and speedy operation known as *sclerotomy*. It is an emergency procedure of much value, and is frequently adopted by ophthalmic surgeons preparatory to iridectomy. An anæsthetic is not essential, though cocaine and adrenalin may be of service. The patient is told to look well downwards; the surgeon stands behind the patient's head, and plunges a narrow Graefe's cataract knife deeply into the eye so as to evacuate the excess fluids which well up beneath the conjunctiva. The knife is plunged into the eye within the triangle formed by the ciliary body, the tendons of the superior rectus and of the external rectus. The back of the knife must be held towards the cornea, so that a jerk of the eye cannot do harm There is only the momentary pain of the stab, and the relief is great.

Differential Diagnosis.—To the beginner the distinction between conjunctivitis, iritis, and glaucoma will be difficult, as in all there are disturbance of vision, pain, and redness of the eyes; but there are certain sure distinctions. Conjunctivitis is most common in the young, iritis in young adults, and glaucoma in elders. The chief distinction, however, is the *character of the pupil.* If there is a mobile pupil, the likelihood is that the redness is due to conjunctivitis. If the pupil is small and irregular, the cause is probably iritis. If the pupil is enlarged, slightly oval, and immobile, glaucoma is present. If examination with a magnifying glass does not make clear in which of these categories a particular pupil is to be placed, it is well to use one drop of a 2 per cent. solution of cocaine, or of a 1 per cent. solution of homatropine, and watch the effect on the pupil. If the pupil dilates evenly and well, it is not iritis, if the pupil dilates with almost alarming rapidity, there is likely to be glaucoma, and then the mydriatic should be immediately neutralized with eserine. For this test atropine may never be used, for it cannot be neutralized with eserine. An examination by the fingers of the tension of the eyeball should be made in all suspicious cases, and

every medical student ought to train himself to be able to recognize changes in tension of the eyeball. This is the surest test in distinguishing glaucoma from other conditions.

For one acute attack of iritis the practitioner will see half a dozen mild attacks, or chronic cases. For one of acute glaucoma, he may see a score of chronic cases. In these insidious cases the diagnosis is still more difficult. The use of the mydriatic will discover those of iritis; the use of the perimeter will discover those of glaucoma. Attacks of dimness of vision associated with increasing size in the blind spot with a restriction of the peripheral field of vision, and 'cupping' extending over the whole area of the optic disc, so as to suggest an excavation, are characteristic signs of *chronic glaucoma*. The medical and operative treatment of chronic glaucoma requires much thought and care, and both are still the subject of much discussion, and some uncertainty. The prolonged use of eserine is beneficial in some cases, but it does not check the progress of the disease. Operation, by providing a new means of escape for the ocular fluids through a vent, cut with a trephine, at the junction of the cornea and sclera, is undoubtedly successful in very many cases, but not in all.

Squint is a disturbance of the natural balance between the two eyes, so that when one is looking at an object under observation the other is directed elsewhere. There are two main causes of this disturbance: (1) paralysis, (2) some derangement of the function of binocular vision, usually in children.

The paralytic form may be due to injury which by fracture of the orbit may involve a muscle or nerve, or by displacement of bones shift the origin of a muscle, or to disease which may destroy a nerve nucleus or nerve trunk. In all these cases there is diplopia, or double vision; but if the cause is a fracture with displacement of the origin of the muscle, the ocular movements persist, if the nerve root or trunk is involved, loss of movement results owing to the paralysis of the muscle. These cases are difficult to treat. When there is paresis, the simplest means of securing the comfort of the patient and ridding him of the danger of double vision is obtained by wearing spectacles in which the glass before the paretic eye is finely ground so as to prevent detailed vision. When the defect is due to a displacement of a muscle origin, the use of prisms may give relief, or readjustment may be secured by operation.

The commonest form of squint is that seen in *children*. The determining cause is the absence or suppression of the desire for binocular vision. This faculty varies greatly. In some it is so powerful that odd eyes, defective muscles, and gross inequality of vision will not prevail over the desire for fusion of the images of the two eyes, and this will be maintained even though the strain causes severe headache. In others there may be eyes which are equal, of normal focus and standard visual acuity, and yet there has been such a lack of development of the brain control of the eyes that there is complete absence of co-ordination; one may be fixed on an object, and the other turned in another direction. Between these extremes there is every grade of disability, and with that the liability to failure of the brain control when conditions of health are unfavourable. So it happens that commonly the onset of a squint

is determined by an accidental injury, or some illness. The liability to fail was always there, owing to the poor brain control of the eyes, a difficulty increased where there are also errors of refraction or of muscle balance. In children symptoms of double vision at the onset of a squint are very rare, though they do occur. The reason for this difference between children and adult squinters arises from the effect of habit. In children the habit of binocular vision is new and easily lost; in adults, when once fixed, it cannot be lost.

The treatment of squint in children is long and demands much patience. First, it is necessary to ascertain the refraction of the eyes and to correct any irregularity to the full. Next, it is necessary to recover the vision of the squinting eye, which is commonly reduced from disuse. The good eye should be covered completely for several hours a day for a period of weeks or months, to compel the use of the squinting eye. Then attempts should be made to get the eyes to work together, to see the images presented to each of them through instruments which act as variable stereoscopes. Finally, it may be necessary to reduce the deformity by operation. Operation has two aims. In young squinters the aim is to put the eyes in such a position of parallelism that they can work together if there be any recoverable binocular vision, and it is obvious that, if this aim is to be attained, the earlier an operation is performed the greater the prospect of success. In older children, operation is performed for cosmetic reasons; a squinting eye is a serious handicap to the prospects of the child, so this handicap must be removed.

In former days operative procedure consisted of tenotomy of a muscle. The practice is unsatisfactory, for undesirable effects follow. Nowadays operations of considerable delicacy are performed which adjust the balance between the opposed muscles: one is shortened or advanced, the other is lengthened by controlled sections. It is important to remember that the successful performance of a squint operation does not render glasses unnecessary.

Cataract.—Cataract is a name given to an opacity within the crystalline lens of the eye of sufficient density to obscure vision. The lenses of very many persons have small opacities or flaws in them, which it is unwise and incorrect to term a cataract. Three varieties will be described: (i.) Some few are *traumatic* in origin. The lens may be injured by a foreign body, or wound, resulting in an opacity of greater or lesser extent, according to the injury, or the lens may become completely white. Note has been made of these effects under the section on injuries (p. 1650). (ii.) Some *children* are found to have cataract in their early years. A few even are born with opaque lenses, and then there is usually bad vision even when the cataract is successfully removed by operation, for it is associated with defective development of the eye itself, as is evidenced by nystagmus, *i.e.* constant movement of the eyes due to poor fixation, from lack of development of the macula. Other children have suffered from grave illness in their early years, such as convulsions, and just as these illnesses affect the growing enamel of the teeth, causing them to be rough and pitted, so the growth of the lens is affected. One or more layers are imperfect, so that instead

of a lens clear and transparent throughout, there are found layers of more or less opaque tissue which obscure vision. The cataract typical of this state is known as *lamellar*, since the opaque substance forms a layer within the body of the lens (Fig. 1068). It is something like the familiar glass alley-marble of boyhood days, which showed a layer of coloured or white glass within the clear glass of the marble.

Operation for infantile cataract will be determined by the size of the opacity. In congenital cataract this is often small, and then the best result may be obtained by an iridectomy cut so as to provide a clear hole alongside the opacity through which vision may be obtained. In lamellar cataract of larger size removal of the lens is necessary; it is soft in substance and therefore easily broken up. A needle is passed into the anterior chamber of the eye; the lens is cut across from side to side, and its depths opened up to the action of the aqueous humour. After a week the anterior chamber will be found to be full of the swollen fragments of the lens. The anterior chamber is then opened at its margin with a broad needle, and the lens matter evacuated by coaxing it along a grooved curette. Finally, it may be necessary to needle the posterior capsule of the lens. The loss of the lens must be made good by the use of cataract glasses; about +10D will be needed to be worn for distance vision, and +14D for near vision.



FIG 1068.—DOUBLE LAMELLAR CATARACT. (× 4.)
Focal light, pupil dilated fully

The cataract of *adults* is an age change. With increasing years there is loss of nutrition. One effect is seen in the whitening of the hair, or its loss. The lens grows from the same epiblastic source as the hair, and just as the shrinkage of the core of the hair causes the whitening of the hair, so shrinkage of the lens with age causes increase of density, and occasionally irregular shrinkages with consequent cracking of its tissue. These cracks become filled with fluid and show as white marks in the lens when viewed with focal illumination, or as black marks against the red of the fundus reflex when seen with the ophthalmoscope. Age changes may also affect the central or nuclear region when there is a gradual fogging of the lens; the change is very slow, and, since the outer layers of the lens remain healthy, operative measures must be delayed, or measures taken to 'ripen' the outer layers of the lens. The most common form of senile cataract begins in peripheral changes in the lens, with cracks or radiating striæ. When these become so advanced as to obscure vision, operation must be performed to regain sight.

The test for the maturity of a senile cataract is not difficult (Fig. 1069). The iris pupillary margin rests on the lens; if the underlying lens is completely white, *i.e.* cataractous, then there will be no shadow cast by the iris edge, for the iris and cataract will be in contact (B). If there is in the outer part of the lens some tissue not affected by the cataractous change, then the iris will cast a shadow, for there is separation between the iris and cataract (A). If a beam of light is thrown upon the pupil from one side, these effects will be clearly seen. Further, it is necessary to determine the integrity of the fundus of the eye upon which it is proposed to operate, for nothing is more disappointing than to discover after the successful removal of a cataract that the patient is unable to see details owing to disease of the retina. The field of vision must be tested by projecting a beam of light upon the eye from varying directions, and the patient should point correctly to the position of the light. Also a light which is capable of being changed quickly into two lights (say, a couple of matches held together) must be held before the patient, and the cataractous eye should be able to tell correctly when the light is single or double.

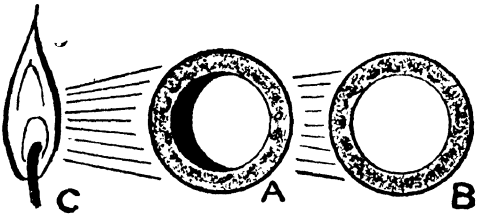

FIG. 1069.—THE TEST FOR MATURITY OF CATARACT

C, Candle A, An eye in which the opacity is separated from the iris by a layer of healthy lens fibres, so a deep shadow is cast by the iris B, The opacity is complete up to the capsule of the lens, so no shadow is cast; the cataract is mature

There are many methods of operating for cataract, but the one most commonly performed, and by far the safest, is that known as Graefe's method. The patient is subjected to careful examination to determine fitness for operation and for recumbency for at least one week. The healthy state of the conjunctiva and lachrymal sac is certified. Then operation may be performed. Anæsthesia with cocaine and adrenalin is sufficient. The lids are separated by a speculum. The surgeon stands behind the patient's head. He makes the corneal section with his right hand for the right eye, and with his left hand for the left eye. The section is made with a slender Graefe's cataract knife. The section follows the upper margin of the cornea from the position of X to II on the clock-face. It is desirable to carry with the corneal flap some conjunctival flap, for the conjunctiva heals much more rapidly than the cornea. The section complete, the iris is gently drawn to the lips of the wound and a narrow vertical piece cut out with scissors. Then, with a pointed instrument the lens capsule is cut across in two directions. Now comes the critical point of the procedure, the evacuation of the lens. With a suitable instrument the upper scleral lip of the wound is slightly depressed to make an easy slant for the delivery of the lens. Pressure is made upon the lower part of the cornea with a flattened instrument. If all the steps of the operation have been correctly performed, if the

corneal section is wide enough and the lens capsule has been sufficiently incised, the lens will glide upwards through the wound. Any broken fragments of lens may be removed, or washed out with a gentle stream of normal saline solution. Finally, the cut edges of the iris are replaced within the eye so that no knuckle or tag of iris is left within the wound. Atropine is instilled, both eyes are bandaged, and the patient is carried to bed. Uninterrupted recumbency is desirable, and a bed-pan must be used. Slop diet is ordered, and talking must be discouraged. Both eyes should be washed with boracic lotion daily and atropine instilled into the operated eye twice daily. After three days, if all is well, the unoperated eye may be left open, and at the end of the week the patient may be allowed out of bed. It is commonly found that the posterior capsule needs to be needled at a later date. Spectacles to make good the loss of the lens will be required, and on the same lines as noted for children.

Since these operations are made in elderly persons, whose eyes are abnormal by reason of the causes that brought the cataract into being, it is inevitable that results will not be uniformly successful. The seriousness of the operation may be appreciated when it is remembered that the eye on a sudden is laid open, its natural inner tension lost, and its vessels, often brittle with age, left unsupported and liable to rupture through any sudden strain from sickness or coughing on the part of the patient. Despite all these risks, however, the great majority of operations are successful, and achieve the restoration of sight to patients who would otherwise be helplessly blind.

CHAPTER L.

TROPICAL SURGERY.

By SIR FRANK POWELL CONNOR, D.S.O., K.H.S., F.R.C.S.

It is scarcely necessary to insist that there is no essential difference between surgery as it is practised in temperate and tropical climates. Probably it is more difficult to maintain asepsis in the latter, but that merely necessitates a more meticulous care in technique than in other climes. The chief differences which warrant a chapter being devoted to the subject lie in the character of the lesions which present themselves for treatment and the striking variations in incidence due to the effects of climate, dietary and other environmental conditions on the human organism. Space will not permit of these being discussed at length, but a few may be mentioned, such as the enormous incidence of gastro-duodenal ulceration in certain restricted areas, as in South India, probably due chiefly to vitamin deficiency; the great frequency of buccal and maxillary cancer in districts where plugs of betel leaf and lime are chewed; the great prevalence of stone in the bladder in certain areas; the much greater frequency of sarcoma as a variety of malignant disease of tropical countries. These and many other surgical problems provide a large field for practice and research. Many varieties of cutaneous affections occur which are quite unknown in temperate regions. This is probably due to a more receptive condition of the skin, and the greater activity of various types of organisms which are able to attack it. These are dealt with first, and then conditions will be considered which result from various tropical fevers and intestinal diseases.

Infective Granulomata.—Diseases of temperate climates, such as tuberculosis and syphilis, are well known in the tropics, but we have also to consider others which are peculiar to hot countries. The following is a convenient classification:

(*a*) Tuberculosis.
(*b*) Syphilis.
(*c*) Frambœsia (or yaws).
(*d*) Leishmaniasis.
(*e*) Tropical granulomata, including granuloma venereum, inguinal lymphogranuloma (or climatic bubo), diffuse spirochætal papillomatosis.
(*f*) Granulomata caused by pathogenic fungi: Actinomycosis, mycetoma, blastomycosis, rhinosporidiosis, mossy foot.
(*g*) Rhinoscleroma.

Tuberculosis is a very common disease in hot countries, and is responsible for an enormous mortality. The disease is widespread, but

particularly favours hot and moist districts and the deep valleys of mountainous tracts. Aboriginal tribes living remote from civilization may be free from infection, but suffer more severely when they are contaminated by intercourse with more populous areas.

All clinical and pathological types of tuberculous disease occur, but surgical lesions are less common than in colder and less sunny regions. Skin lesions, superficial lymphadenitis, and even bone and joint infection, are not as much in evidence. Pulmonary and generalized forms of tuberculosis are frequently met with alone, or complicating other surgical diseases. Masses of tuberculous granulation tissue, or of breaking down in caseous areas, are most often seen in individuals of low resistance or those coming from localities where tubercle is little known. Intestinal and mesenteric involvement are much rarer than in Europe, suggesting a lower incidence of bovine tuberculosis, but it must be remembered that unboiled milk is seldom used by residents in the tropics. Curiously, tuberculous lesions of the ileo-cæcal region of the bowel in adults are not very uncommon, and may be mistaken for a new growth.

Syphilis.—This world-wide disease is exceedingly common in tropical lands, except among isolated tribes. In Uganda 90 per cent. of the inhabitants were found to be infected (Lambkin). The disease is regarded as of no importance among the ignorant and working classes, owing to the fact that the early primary and secondary symptoms produce little suffering.

The *primary lesion of acquired syphilis* is as often as not unnoticed owing to carelessness, and because of the common incidence of soft sores and mixed affections which appear much earlier and attract more attention. Phagedænic ulceration is often seen, and may cause much local destruction. The typical Hunterian chancre is comparatively rare; extragenital chancres are generally allowed to run their course without any specific treatment. In females the difficulties of diagnosis are accentuated by greater diffidence in seeking medical aid, and owing to the fact that the lesion may be more concealed and is more liable to be complicated by gonorrhœa and soft sores than in the male. Owing to these various circumstances, it is inadvisable to accept the patient's statements when noting the case-history. It is necessary to rely entirely on a bacteriological examination or the Wassermann test.

The *secondary stage of syphilis* may also be missed by patients in the tropics. This is not to be wondered at in the case of pigmented skins, and when the body is covered with prickly heat and various parasitic skin eruptions. The early roseolar rash is not easily identified, except in its later stages, when the site of each macule becomes pigmented. Papular and pustular rashes are not uncommon quite early in the secondary stage, and scab formation may be exaggerated, producing a rupial appearance.

Mucous membranes are less affected than in European countries, and sore throat is less complained of, but condylomata round the anus are very common. Irregular fever may occur and may be mistaken

for malaria, and in Europeans tropical conditions seem to produce a greater liability to meningeal involvement late in the secondary stage, marked by headache and nervous irritation. Ocular signs are very common, particularly iritis, and lead to much impaired vision in untreated cases.

The *tertiary stage of syphilis* does not produce anything like as much disability in hot countries as would be expected, when one considers the almost universal distribution of the disease in some localities. It is true that horrible mutilations of the nose and naso-pharynx are met with, but these are not very common. Among the commoner tertiary lesions are bone affections, such as periostitis, subacute osteomyelitis, and caries; ophthalmic nervous lesions are seen in great numbers; parasyphilitic nervous lesions are quite rare; vascular complications are most marked at the aortic base, and aneurism is seldom met with. The infrequency of parasyphilitic lesions may be accounted for by a smaller incidence of the neuropathic form of syphilis, but it is probably due to the fact that the infection is less often driven into the deeper tissues by partial treatment.

Congenital Syphilis is responsible for an enormous infant mortality, and for gummatous lesions involving mucous membranes, bones, and viscera. These are not as commonly met with as would be expected, and this is probably explained by the fact that most cases of severe infection die during early childhood.

Most of the above remarks on syphilis refer to parts of the tropics where the disease has been in existence since its introduction into the Old World. In newly-infected regions it runs a much more acute course.

Frambœsia, or **Yaws,** is a specific contagious disease characterized by a granulomatous eruption. It occurs in restricted areas of the following tropical countries: India and Ceylon, Malay States, West and East Indies, Papua, China, Pacific Islands, and Africa. The causative organism is *Spironema pertenue* (Castellani), which is morphologically identical with *S. pallidum* of syphilis.

Clinical Features.—Yaws closely resembles syphilis, and the Wassermann reaction is positive in both diseases, but there are various differences which will be referred to later. The infection is conveyed through abraded skin directly or by means of flies and other insects, and among primitive or crowded people all are infected sooner or later. There is no evidence of antenatal infection, and the disease is commonest in children and among males. One attack confers considerable immunity. As in syphilis, the symptoms of yaws are usually described as occurring in three different stages.

The *Primary Lesion* usually appears as a papule from two to three weeks after infection, and may develop into a typical granuloma or a scabbed ulcer, or, as in syphilis, it may pass unnoticed in some cases. The site is seldom genital, the following regions being most often involved: the lower leg, arm, thigh, buttock, and breast. If untreated, the sore will usually continue into the secondary stage. Symptoms, such as fever and headache, together with vague pains in the body,

may appear, and the primary yaw itself may cause pain and irritation for a few days.

The *Secondary Stage* is marked by an eruption which appears ten to twelve weeks after infection as multiple papules, scattered or in groups, which develop into the characteristic 'framboesia,' or yaws. This may be preceded by a fine desquamation in patches. The lesions are insensitive, but the adjacent skin may become very irritable. The Wassermann reaction begins to be positive about the eighth week, and is well established at the end of the secondary stage. The typical 'yaw' of the secondary stage is pathognomonic of the disease when it is fully developed after ten or fifteen days. A raspberry-like excrescence is extruded through the epidermis, its centre becoming capped with a yellowish crust and the edges everted (Fig. 1070). The specific organism (*S. pertenue*) may be found in the serous exudation beneath the crust, and in the juice of the adjacent lymph glands. In atypical cases, a syphilitic rash may be closely simulated. The rash slowly disappears, but may be present up to a year, and late secondary lesions may persist even after two years.

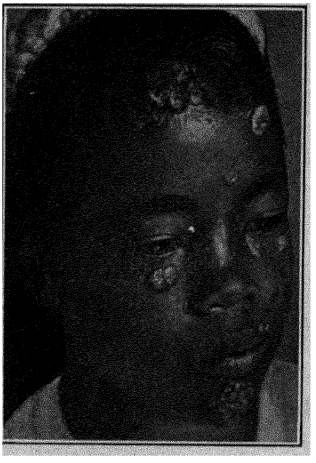

FIG 1070.—YAWS SECONDARY STAGE

The *Tertiary Stage* cannot always be recognized at first. Typical tertiary lesions are found on the hands and feet, in the bones and joints, in the naso-pharynx, and as extensive ulcerations in other parts of the body. In contrast to syphilis, vascular and visceral lesions are rare, and nervous lesions are doubtful. Some of the commoner types of tertiary manifestations are the following: Keratoderma, particularly of the hands and feet, associated with deep granulomata under the skin called 'crabs,' which produce very painful ulcerations and fissures; diffuse periostitis and osteitis, with areas of softened bone seen by X-rays, resulting in painful bony and joint deformities; more doubtful late para-yaw changes comparable to the tabetic and other parasyphilitic lesions of syphilis.

Three peculiar conditions believed by most authorities to be late yaws lesions remain to be described; these are gangosa, juxta-articular nodules, and goundou.

Gangosa is a naso-pharyngeal affection producing extensive destruction of the bones and soft tissues of the nose and palate, the larynx being usually spared. Progress is very slow, and arrest may take place even without treatment at any stage. This is the only type of yaws ulceration which involves mucous membranes.

Juxta-articular Nodules are now accepted as a tertiary manifestation of yaws, involving the long bones in the neighbourhood of joints such

as the knees. They are not painful, but are likely to break down. If for any reason they are found to be inconvenient, they may be removed surgically.

Goundou is the name applied to symmetrical hard nodes which are found to be growing from the upper part of the nasal processes of the superior maxillæ, and the nasal bones, in individuals who may also have osseous elevations on the clavicle, mandible, etc. They are believed to be tertiary yaws growths, and begin in childhood as subacute inflammatory elevations of the surface of the bones. Growth is very gradual, and if uninterrupted by treatment may produce unpleasant pressure effects by invasion of the cavities of the nose and orbits. The condition is most often seen in Central Africa and South America. The hyperostoses may be removed surgically, if necessary.

Diagnosis.—A typical case of yaws can be diagnosed by the clinical features, but its resemblance to syphilis both bacteriologically and clinically must be kept in mind, especially as both diseases may occur at the same time. Yaws differs from syphilis in that there is no evidence of antenatal infection; the primary lesion is usually extragenital, the eyes and mucous membranes are unaffected for the most part, the vascular and nervous systems usually escape; mercury has no specific action; treatment is much more rapidly efficacious.

Treatment.—Although mercury is of little value against infection by *S. pertenue*, the salvarsan group of drugs and bismuth are markedly effective. One full injection of novarsenobillon may cure yaws in the primary or secondary stage, but it is safer to give three injections at weekly intervals. For the treatment of large numbers of individuals, sodium bismuth tartrate or bismuth metal has been found effective. In the case of an infected community, efforts must be unremitting in the direction of personal hygiene.

Boomerang Leg consists of an antero-posterior curvature of the leg below the knee, with the convexity forwards, and is due to yaws. It occurs in Australian aborigines, and has been called 'sabre tibiæ.' The actual deformity varies greatly; the situation of maximum deformity is either about or a little above the centre of the tibia. Radiographically, there is marked thickening of the compact bone in the region of the bowing. There is no disability in any but the very advanced cases, when the tibial muscles become weakened and fail to compensate the forward displacement of the centre of gravity. In old-standing cases ulceration may occur over the thickened bowed portion of the tibia.

Leishmaniasis is an infection widespread in the tropics, and most of the clinical manifestations are of surgical importance. The following are some of these: Kala-azar and dermal leishmanoid, Oriental sore, diffuse cutaneous leishmaniasis, espundia or naso-pharyngeal leishmaniasis. The Leishman-Donovan body, the causative organism in this disease, is a rounded body 2 to 4 μ in length, with an oval trophonucleus and a smaller rod-shaped rhizoplast. They may be found in very large numbers, mostly inside endothelial cells. The mode of infection has not been worked out very clearly, but this will be referred

to again. An interesting recent discovery is their presence in large numbers in some cases in the mucous membrane of the tonsils and naso-pharynx. When cultivated outside the body, they assume the form of motile flagellates. The tropical fever kala-azar is a generalized form, but its surgical aspects must be described.

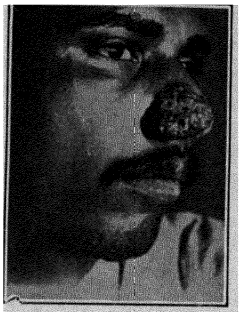

FIG 1071.—ORIENTAL SORE ON NOSE

Oriental Sore is also known by various other names, such as Bagdad boil, Delhi boil, Biskra button, etc., and, as the names suggest, this cutaneous form of leishmaniasis occurs in many of the hot and dry regions of the tropics. Oriental sore may be single or multiple, appearing chiefly on the face and extremities, and is first seen as cutaneous nodules. After some days or weeks they become granulomatous and begin to break down into scabbed ulcers. Some extension may occur at the edges, but no great size is reached except by the coalescence of several sores (Fig. 1071). If untreated, this chronic stage is maintained for several months, after which slow healing occurs, leaving an ugly and depressed scar. The leishmania parasite found in Oriental sores has been designated *L. tropica*, and is morphologically indistinguishable from *L. donovani*. It is found in large numbers inside the large mononucleate cells, which form part of the intense cellular exudation which occurs beneath the growing edge of the sore. The presence of ordinary septic organisms has the effect of driving the parasite into the deeper parts of the inflamed area. Experimental evidence favours the view that the ordinary mode of infection is by means of bites of sand-flies, such as *P. papatasii*, but there is evidence that direct transference of the organism is possible on abraded areas. Treatment is best effected by means of intravenous injection of one of the antimony derivatives. Sodium or potassium antimony tartrate is given up to a total of 20 to 30 grains in ten to twenty injections; healing is slow but steady. Fouadin is also recommended in doses of 0·5 to 5 c.c. A more rapid method of treatment is by berberine sulphate injections round the edges of the sore in 2 c.c. doses of a 1 per cent. solution. When the sore is very septic, the cure will be expedited by judicious scraping and cleansing. Various other local methods of eradication are practised, such as by carbon-dioxide snow, X-ray exposure, ionization, etc. It is important to remember that

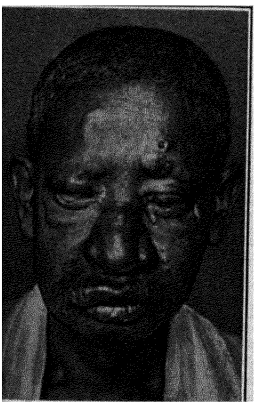

FIG 1072.—DERMAL LEISHMANIASIS RESEMBLING LEPROSY.

the deeper areas are invaded by the parasites, which extend a good deal beyond the apparent edge of the sore.

Diffuse Cutaneous Leishmaniasis differs in no essential respect from Oriental sore, but it is convenient to describe the condition separately to draw attention to the fact that these lesions are of a diffuse character, and may slowly progress for years. They are more often met with in districts where moist heat prevails (Fig. 1071). Diagnosis must never be made on clinical appearances alone, as the effects of secondary sepsis and partial attempts at cure may alter the character of the granulomatous area, so that ulcerative, papillomatous, and keloid types may result (Figs. 1072 and 1073).

Espundia, or naso-pharyngeal leishmaniasis, is prevalent in many parts of the South American continent, and is a much more serious and destructive form of the disease. The causative organism is indistinguishable from *L. tropica*, and has been named *L. braziliensis*.

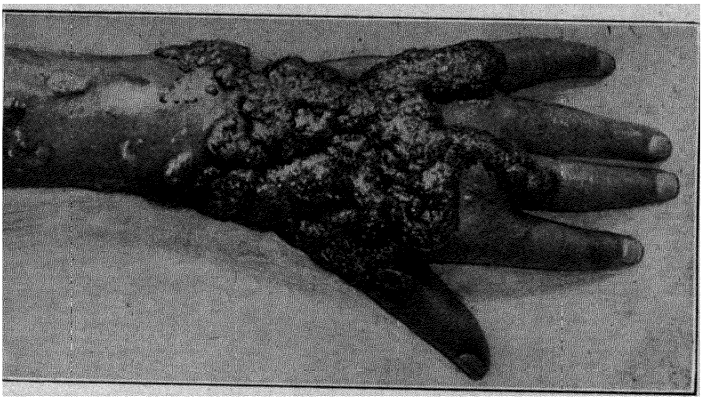

FIG 1073.—DIFFUSE CUTANEOUS LEISHMANIASIS OF THE PAPILLOMATOUS TYPE.

It is probable that the infection is carried by a phlebotomus, as in the case of Oriental sore. Clinically this disease begins as a sore on a mucous surface, and this gradually heals like an Oriental sore, but months or even years later secondary ulceration appears in the mouth or naso-pharynx. This results in a very serious destructive process resembling a gummatous ulceration, which gradually proves fatal if unchecked by treatment. Fortunately antimony has a specific action, and a course of 20 to 30 grains subcutaneously generally suffices, if local surgical cleansing is carried out and powdered antimony tartrate is applied to the ulcerated surface.

Tropical Granulomata.—The following are the more important granulomata met with in the tropics which merit a brief description:

Granuloma Venereum is a distinct form of granuloma, believed to be acquired during sexual intercourse, which is well known in some tropical countries, *e.g.* India, Southern China, Pacific Islands, West Africa, South America, North Australia. The ætiology of the disease

has not been satisfactorily worked out, but it is probable that the body originally described by Donovan in 1905 is the responsible organism, and recent work in Madras points to this being a capsulated bacillus. They occur in the large mononuclear cells. Pathological examination of the affected tissues shows numerous nodules made up of round cells near the edge of the ulceration, with much overgrowth of the papillæ and interpapillary processes. The epidermis is altered and broken down in places, while the normal connective tissue strands beneath the epidermis are replaced by inflammatory and plasma cells grouped around hair follicles; in healing areas fibrous tissue predominates. The *clinical features* of an established case seen months or years after infection present a characteristic picture. The disease is commoner in females, and occurs after puberty and up to fifty years of age. The affected area in the inguinal region and adjacent parts is granular with glazed patches; the edges are raised and have a circinate outline, and in places healing is attempted, under a cracked, pigmented, and scabbed surface. The usual history is that the disease began as a small papule which appeared a few days after sexual intercourse. Contiguous surfaces between the scrotum and thigh, or scrotum and perineum, are commonly involved. Diagnosis is usually made from the characteristic appearance and clinical history, but histological examination may be necessary to exclude lupus or epidermoid cancer. *Treatment* is not always satisfactory. Foul granulations should be cleaned up by scraping and antiseptic compresses. Injections of tartar emetic, if persisted in, are generally efficacious, and X-ray exposure will hasten recovery. Recurrence is to be expected unless all parts of the ulcerated areas are patiently dealt with.

Inguinal Lymphogranuloma (**Poradenitis venerea, Climatic Bubo**) is a very chronic type of venereal lymphadenitis, which most commonly occurs in the Malay States, China, and Japan, and more rarely in other parts of Asia, Europe, and America. A history is generally obtained of an infected abrasion discovered after sexual intercourse. A flood of light has been cast on this and kindred affections, such as genito-ano-rectal ulceration and stricture in both sexes, and the elephantoid ulcerating condition named ' esthiomène ' in the female, by the recent discovery that they are all due to the same ultra-microscopic virus. This was made possible by the introduction of the Frei intradermal test, carried out by injecting a saline solution of sterile pus obtained from an infected area. This discovery has opened up a new chapter not only in tropical surgery, but also in that of temperate climes. Those who wish to pursue the subject further are referred to the interesting monograph on the subject by Hugh Stannus entitled ' A Sixth Venereal Disease.' The characteristic feature of this infection is that it has an intense affinity for the lymph glands, unlike granuloma venereum, which attacks the epidermis and dermal tissues only. The *prominent clinical features* are subacute inguinal lymphadenitis persisting for weeks or months, accompanied by irregular fever, and usually resulting in breaking down of the affected glands with ulceration of the neighbouring tissues and skin (Fig. 1074). In the female the primary venereal sore often occurs in the region of the fourchette,

and the lymph glands involved are those in the pelvis, particularly those close to the rectum. Very intractable inflammation may follow and in the later stages stricture of the rectum and elephantoid enlargement of the labia, with ulceration. The inguinal glands may also be affected as in the male subject. No evidence is available to connect the disease with the ordinary venereal infections. *Treatment* in the past has been by surgical excision, and in less severe cases by intravenous injections of tartar emetic or iodine. In recent years striking results have been obtained by protein-therapy. Intravenous injections of a T.A.B. vaccine were first used for this purpose, a first injection of 100 millions, with an increase of 50 millions per dose at intervals of four or five days up to 500 million dead organisms. Intravenous injections of various antimony preparations, such as neostibosan and stibenyl, have also been used with good results. Locally, surgical cleansing is essential, fistulous tracks being opened up where necessary.

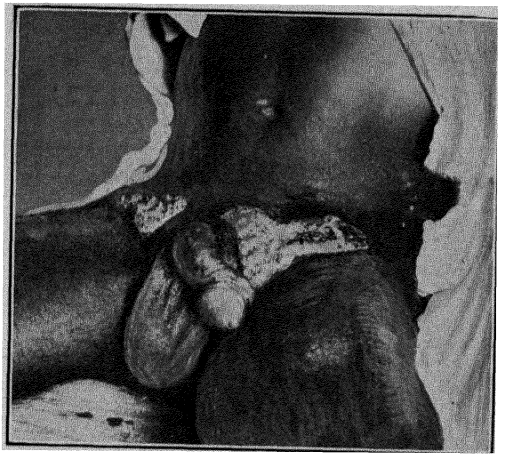

FIG 1074.—INGUINAL LYMPHOGRANULOMA.

Diffuse Spirochætal Papillomatosis has been described, particularly in Egypt by Madden, as a definite clinical entity. This is to be considered as distinct from secondary spirochætal infections of chronic bilharzial or other ulcerations. Primary spirochætosis of this type may involve the lips (granuloma labiale), and also other muco-cutaneous areas. The disease may assume a granulomatous or ulcerative character, closely resembling epidermoid carcinoma. When left untreated, the tissues are steadily destroyed. Diagnosis may be effected by examination of histological sections stained for spirochætes, and the specific action of salvarsan and its derivatives will afford further evidence in this direction.

Granulomata caused by Pathogenic Fungi are well known in hot countries, and some of the more important of these are discussed below.

Actinomycosis is a streptothrix infection which is not very uncommon in temperate zones, and has already been referred to on p. 182. In the tropics it very rarely attacks the jaw, but infection of the skin and subcutaneous tissues, lung and pleura, liver and intestinal tract may be observed (Fig. 1075). When the appendix or ileo-cæcal region is involved, the symptoms closely resemble those

of chronic dysentery. In later stages a mass may become obvious, simulating a new growth or tuberculous invasion. Details of pathology and treatment are dealt with on p. 183.

Mycetoma is another fungous disease found in many parts of India, and may be met with in any hot country. The specific organisms have been variously classified, but the various groups need not be described here. The subcutaneous tissues, particularly of the feet, are most often attacked, but in some forms such as the actinomycotic variety, the internal organs may also be involved. *Clinically*, mycetoma usually begins as a chronic affection of one foot, resulting in the formation of one or more painless nodules. Extension slowly occurs, accompanied by breaking down, and a viscid discharge results which often contains black, yellow, or red granules. Pain becomes a prominent feature as the deeper tissues are involved, and a shapeless foot with unequally retracted toes and many sinuses in various stages of

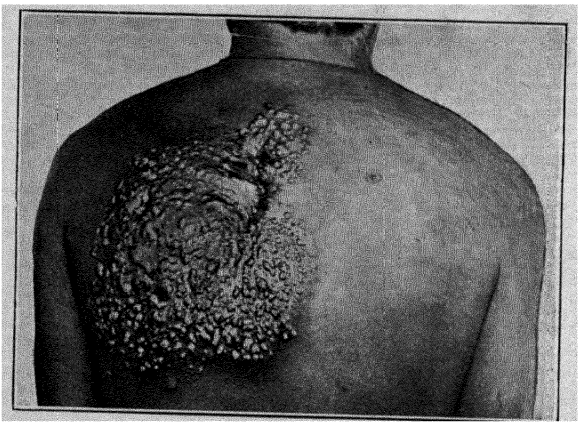

FIG. 1075.—ACTINOMYCOSIS OF BACK

activity is the outcome of the disease. *Pathological examination* of an affected foot or hand reveals areas of softening in which the mycelium and spore-like bodies are found, alternating with areas of very dense fibrosis. All tissues down to and even including the bones are ruthlessly destroyed, the tendons and nerves surviving the longest (Fig. 1076). The adjacent lymphatic glands may be involved by secondary infection, or by actual extension of the fungus. *Treatment* is very unsatisfactory in the absence of any specific drug. Amputation is often necessary to free the patient from a painful and useless member. Short of this drastic treatment, the only procedure which has been found efficacious to allay the constant pain is multiple diathermic puncture, the needle being pressed bone-deep into painful areas.

Blastomycosis is a fungous disease due to infection of the skin and subcutaneous tissues by a yeast-like fungus (saccharomyces). A chronic dermatitis of the buttock, perineum, or axilla may be due to

this cause. The *clinical features* do not always conform to a single type, and the history is not easily obtained, owing to the gradual onset and chronic character of the affection. The skin and cellular tissues become involved in a granulomatous lesion, active in some parts, and scabbed or keloid in others (Fig. 1077). There is often a foul discharge due to mixed infection and necrosis of skin and subjacent tissues. More serious types of the disease are known where mucous membranes are involved, *e.g.* lingua nigra, and systemic infection may occur with fatal results owing to extension to the lungs, liver, and other viscera. The term ' gummomycosis ' has been given to clinical types and gumma-

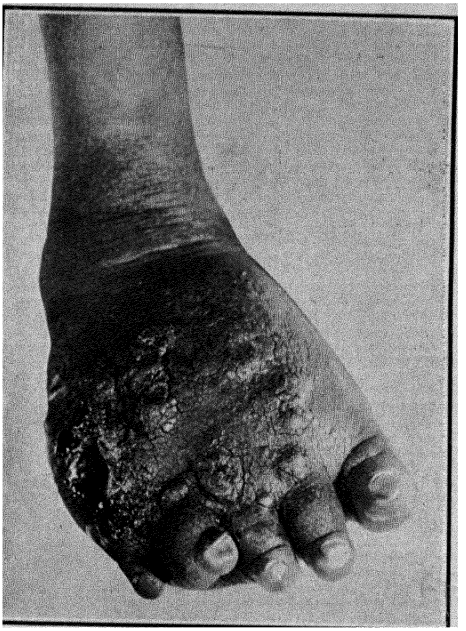

FIG. 1076.—MYCETOMA OR MADURA FOOT.
(Courtesy of Dr. Jones and Dr. Alden.)

like characteristics. The *diagnosis* can only be presumptive unless confirmed by bacteriological examination of smears or pieces of the affected tissues. It is easy to identify the yeast-like organism in most cases, but the possibility of casual secondary infection by fungi must be borne in mind. Agglutination and complement deviation tests have been usefully employed. *Treatment* is not very satisfactory. The affected area should be thoroughly cleansed by hot antiseptic compresses, and foul patches excised or scraped. Large doses of potassium iodide are generally beneficial, and X-ray exposure will hasten healing. Recovery is usually very slow, owing to the chronic nature of the disease.

Rhinosporidiosis is another granulomatous condition due to a yeast-like fungus, *Rhinosporidium seeberi*, which is met with in many parts of the tropics, and produces chronic lesions of the nose, eye, urethra, and other mucous surfaces. The parasite was first described in the Argentine, and was discovered independently in Calcutta by Vaughan in 1894, and described by O'Kinealy. It is considered to be a phycomycete. The affected tissue becomes riddled with minute cysts 0·25 to 3 mm. in diameter; each of these becomes filled with daughter spores, which escape when mature and involve the surrounding parts and lymphatics. *Clinically* a granulomatous, polypoidal, or ulcerating area is noticed, most commonly in the anterior part of the nasal mucosa, producing a strawberry-like appearance. Growth is quite slow, and local excision or destruction by the cautery can be readily effected where the disease is not advanced. In more accessible places, and when larger areas are involved, injection of tartar emetic in ordinary doses has a specific action.



FIG. 1077.—EARLY CASE OF BLASTOMYCOSIS.

Rhinoscleroma is a progressive granulomatous condition generally involving the nose, palate, pharynx, or larynx. It has a wide distribution over India, Sumatra, Brazil, South and East Europe, and Egypt, so that it is by no means confined to tropical lands. Firm and nodular swellings in the skin or mucous membranes are characteristic of the disease, and its slow but persistent growth is not usually arrested except by thorough excision. The *ætiology* has not been satisfactorily worked out, but the causative organism has been identified as a bacillus (*B. rhinoscleromatus*), which resembles Friedländer's pneumo-bacillus in its physical characters. Exaggerated and neglected cases are met with in the tropics in which overgrowth or ulceration has caused deformity (Fig. 1078), and it is probable that in such cases as the 'hippopotamus man' a secondary sarcomatous change has occurred. The granulation masses consist of firm connective tissue,

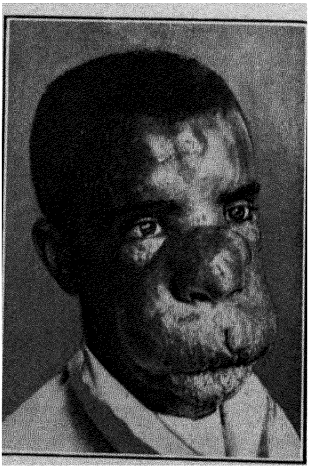

FIG. 1078.—RHINOSCLEROMA LATE CASE

with hyaline masses or collections of vacuolated cells, containing the specific bacilli. *Treatment* is very unsatisfactory, unless total excision is possible. X-ray radiation is beneficial after the accessible nodules have been removed surgically.

Surgical Complications of Tropical Fevers.—Most of the acute specific fevers prevalent in temperate countries, and their surgical complications, are well known in the tropics. We have to keep in mind, however, the surgical aspects of various fevers which are peculiar to hot countries Among the most important of these are the following: Malaria, dengue and sandfly fever, human trypanosomiasis, kala-azar, rat-bite fever, oroya fever and verruga peruana, undulant fever and evers of the enteric group. It is not possible to describe in detail the surgical complications of these fevers, but the most important will be enumerated.

Malaria.—Hæmorrhages from mucous membranes and post-operative bleeding. increased liability to septic complications; enlargement of the spleen, with liability to rupture or torsion of an elongated pedicle; splenic disease due to necrotic degeneration, peripheral neuritis and neuralgia; visceral complications of malignant tertian malaria, such as cerebral lesions, producing irritative or paralytic signs, abdominal lesions causing symptoms simulating appendicitis, cholecystitis, etc.; hæmoglobinuria, due to blackwater fever.

Dengue and Sandfly Fever are both short and very acute fevers, which may seriously complicate surgical cases and even cause death by hyperpyrexia. Dengue may produce arthritic sequelæ of varying severity, but seldom resulting in suppuration.

Human Trypanosomiasis exists in three well-known types, of which two are African, and caused by *T. gambiense* and *T. rhodesiense* respectively, and one is South American, caused by *T. cruzi* (Chagas' disease). The surgeon may be consulted in *T. gambiense* infections for various skin eruptions; for inflammatory signs, such as lymphadenitis, orchitis, periostitis, and eye affections, for nervous symptoms, including neuralgias, paralyses, or convulsions, pointing to a lesion of the central nervous system. *T. rhodesiense* infections run a much acuter course, marked by considerable glandular enlargements. Chages' disease attacks young infants in Brazil and Venezuela. In addition to fever and general anasarca, there is enlargement of the thyroid and lymphatic glands, and of the spleen and liver, the central nervous system is involved in the terminal stages.

Kala-Azar is an acute or chronic fever, due to infection by *Leishmania donovani*. The greatly enlarged spleen found in this disease is not amenable to surgical treatment, but various other surgical complications may occur. Hæmorrhages from various mucous membranes are a feature of the disease, and the increased liability to post-operative bleeding must be kept in mind. Gradual and painless enlargement of the lymph glands of the neck, axilla, or groin is common, and the specific organism is found in fluid extracted from such glands. Septic complications are sometimes very serious, and in the mouth may terminate in gangrene, producing the condition known as 'cancrum

oris,' or in other parts of the body may result in 'noma,' otitis media, ischio-rectal abscess, or gangrene, etc.

Rat-Bite Fever is caused by infection with *Spirillum minus* from the bite of a rat, after about ten days' incubation. A relapsing fever results, associated with signs of acute inflammation about the wound. The condition is important surgically because it is by no means uncommon, and it is often mistaken for cellulitis due to ordinary secondary infection. Appreciation of its ætiology will enable prompt treatment to be carried out by means of intravenous injections of novarseno-billon.

Oroya Fever and Verruga Peruana.—The former, known also as Carrion's disease, is an acute fever occurring in Peru and certain valleys of the Andes. It produces rapid emaciation and severe anæmia of the pernicious type. Closely associated with this fever is a granulomatous condition known as verruga peruana, which is now believed to be due to infection by a specific organism, *Bartonella bacilliformis*, common to both conditions. The eruption resembles that of yaws, except that mucous membranes are also affected and some of the individual granulomas may become large and pedunculated, and, being cavernous in structure, may cause dangerous bleeding. No specific treatment is known, but surgical excision or diathermy must be resorted to for serious hæmorrhage from accessible areas.

Undulant Fever, or **Malta Fever,** is by no means confined to tropical countries, but among its many complications there are some which the surgeon will be called upon to treat, and when these occur during periods of remission or of low fever, a suspicion of malaria or rheumatism may be aroused and the true diagnosis missed. Various types of inflammatory disturbance occur, such as orchitis, parotitis, mastitis, boils and abscesses, neuralgias and chorea, transient arthritis affecting one or more joints, phlebitis, and mucous hæmorrhages.

Fevers of the Enteric Group.—The surgical complications of this group of infections are well known in temperate countries, and a reference to an authoritative book on the subject* reveals a list of twenty-eight such complications which may occur during the course of typhoid and paratyphoid fever alone. In hot countries the enteric fevers are more prevalent, and it is the experience of most practitioners that the disease runs a more severe course, and the liability to serious complications is much increased. *Bacillus coli* and other bowel organisms, such as *B. fæcalis alkaligenes*, are also to be remembered in this connection. A very fatal form of multiple liver abscesses is well known to be due to *B. coli*, as also infection of the urinary tract, causing pyelitis and cystitis. Appendicitis and cholecystitis, otitis media, arthritis, tonsillitis, abscesses, and boils are a few of the important surgical complications which may occur, and in some instances lead to septicæmia. Infection is carried from the bowel in post-typhoid and post-dysenteric cases through abrasions of the intestinal mucosa, or as a result of greatly lowered resistance.

The *ætiology and treatment* of the various tropical fevers which have been mentioned above must be carefully studied in books on tropical

* 'Surgical Aspects of Typhoid and Paratyphoid Fevers' (Webb-Johnson).

medicine, if the surgical complications for which they are responsible are to be dealt with properly. Kala-azar, for instance, can now be most efficiently treated by tartar emetic and various other organic antimony compounds, such as neo-stibosan (No. 693). Specific treatment, where possible, is obviously the first essential when treating surgical complications.

It is convenient to summarize here the tropical fevers which are responsible for the production of two important surgical signs, namely, lymphadenitis and jaundice. **Acute lymphadenitis,** generally close to the area of primary infection, occurs in plague and rat-bite fever. Filarial enlargements of lymph glands are of various types, and are usually associated with other filarial signs; in climatic bubo the glands are subacutely inflamed, and may slowly break down; and, lastly, in trypanosomias and kala-azar there is painless enlargement of glands in the posterior triangles of the neck. **Jaundice** of hæmolytic origin is found in the following fevers: Subtertian malaria and blackwater fever, relapsing fever, and in Weil's disease and yellow fever. Obstructive jaundice has been noted in undulant fever, due to the pressure of lymphatic glands at the hilum of the liver, and in amœbic liver abscess.

Surgical Aspects of Dysentery in the Tropics.—The surgical treatment of the dysenteries and their surgical complications are of great importance in tropical countries. All types of dysentery are much more common, and certain varieties are met with which are little known in cold countries. We have to consider here the following important dysenteries: **Amœbic Dysentery,** caused by *Entamœba histolytica,* and other less important protozoal bowel lesions due to *Balantidium coli, Leishmania donovani, Lamblia intestinalis.* **Bacillary Dysentery,** caused by *B. dysenteriæ.* Dysenteric symptoms may be caused by *Schistosoma mansoni, S. japonicum,* and *S. hæmatobium* (Shiga and Flexner group), and by other helminths in rarer instances. **Ulcerative Proctitis,** or **Colitis,** due to various infections, often mixed, and not infrequently secondary to amœbic or bacillary dysentery.

The Surgical Aspects of Amœbic Dysentery are very important, as *E. histolytica* may travel to any part of the body and produce pathogenic effects; the term 'amœbiasis' is applied to such infections. The life-history of the parasite and the pathology of its invasion of human tissues cannot be described here. Suffice it to say that pathogenic amœbæ can be seen in microscopic sections to advance in the forefront of bowel lesions, until they reach the deep lymphatic spaces and enter portal radicles, and thus their spread to neighbouring tissues and to distant organs, such as the liver, is not difficult to understand. The surgical complications which follow may be considered according to the effects produced in the bowel, in contiguous tissues, and in distant organs.

Amœbic Ulceration of the Bowel may result in hæmorrhage and perforation, acute or chronic localized colitis, producing conditions resembling appendicitis or even gangrene of the bowel wall, fibrous thickenings and adhesions, carcinoma, intussusception, diverticulitis,

periproctitis and fistula-in-ano, hæmorrhoids and polypi. Extension of the amœbic infection to neighbouring parts may result in acute or chronic peritonitis, pericæcal or pericolic inflammation or abscess, or similar processes involving the perirenal or periproctal tissues. The invasion of more distant organs and tissues is of even greater importance in tropical surgery, especially as regards the effects on the liver by extension along the portal routes. Complications which may be thus produced include hepatitis and hepatic abscesses, cholecystitis, invasion of the pleura and lung, splenic and renal abscess, cerebral abscess, cystitis and epididymitis, cirrhosis and lymphadenitis. Space forbids a full description of these numerous complications, but a brief account of hepatitis and liver abscess is essential.

Amœbic Hepatitis and **Liver Abscess** may occur during any stage of the bowel infection, and even in cases where there is no clinical evidence of dysentery, so that the surgeon in the tropics must always keep in mind the possibility of this occurrence. The presence of amœbæ between the liver cells causes inflammation and later necrosis of liver tissue, but it is usually impossible to ascertain at what stage an actual abscess has begun to form. In considering the *clinical features* of acute amœbic hepatitis and liver abscess, certain predisposing factors must be kept in mind, such as race, sex, age, and various causes which lower the local powers of resistance, particularly alcohol. Infection of the liver is commonest among males between the ages of twenty and forty, and in low-lying and humid localities. The onset of acute hepatitis is characterized by severe pain and tenderness over the liver, with some enlargement of that organ, remittent fever, and high leucocytosis, there is always a favourable response to emetine. Examination with the X-ray screen shows some displacement upwards, with little or no excursion. The attack may begin with a rigor, and chills are complained of, the tongue is furred, there is sweating, and sometimes jaundice. The development of an abscess is associated with all or most of the above-mentioned signs, and in addition other signs may be noticed, *viz.* pain referred to the right shoulder, rigidity of the upper segment of the right or left rectus, inflammatory signs at the base of the right lung due to localized pleurisy or œdema, and fluctuation or actual evidence of a pointing abscess may be present. A tropical liver abscess is most often situated in the upper and back part of the right lobe, and in over 75 per cent. of cases is solitary. Typical liver pus is of a chocolate colour, but in old cases it may be dirty white or muddy. In over 90 per cent. of cases *E. histolytica* is the only organism present, microscopically red cells, leucocytes, and liver débris are found, and amœbæ are only present in the abscess wall or in thick débris. Extension of a liver abscess may occur in various directions. Abscesses of the right lobe most often involve the base of the corresponding lung, while on the left side the pus generally points forward in the epigastrium, or it involves one of the surrounding organs. Resolution or encystment may occur spontaneously, but usually this is the result of specific treatment. *Treatment* of acute amœbic hepatitis has been revolutionized by the introduction of emetine hydrochloride. Intramuscular injections of ½ to 1 grain are given daily up to a total of ten or twelve doses. This

drug has also by its amœbicidal effect a specific action on the bowel lesions, but in obstinate cases other drugs, such as emetine periodide or yatren, may be tried. Clinical experience has proved that these methods of treatment may also be efficacious in cases of established liver abscess, but it is unwise for the surgeon to rely on them entirely, and when pus is suspected or proved to exist it is necessary to arrange for its evacuation. *Aspiration* is by far the best method to adopt for this purpose, as an open operation introduces the grave risk of mixed infection. A spot is selected in the anterior axillary line in the eighth or ninth space, and an exploring needle 3 to 3½ inches in length and No. 9 bore (metric gauge) is inserted up to a depth of about 3 inches in an inward, backward, and slightly upward direction. If pus is discovered by suction on the first or succeeding punctures, it is better to introduce a larger cannula (No. 16) along the same track, so as to evacuate the cavity as completely as possible, and to remove the fibrinous sloughs which are nearly always present. The cannula is then withdrawn, a stitch inserted to close the small skin opening, and a firm bandage applied over the dressing. A second or third aspiration may be necessary if the cavity refills, but if very definite progress is not made after successive evacuations, arrangements must be made to drain the cavity through the aspiration tube or by open operation.

Treatment by *open operation* is necessary under certain conditions, *e.g.*, for anterior abscesses of the right or left lobe, for multiple abscesses, for deep-seated abscesses such as those occurring in the Spigelian or quadrate lobes, or of the suprahepatic or perihepatic variety, and for cases of mixed infection. Such operations are generally carried out by the epigastric route, the lateral transpleural route, or by the posterior route. The mortality of amœbic abscesses has been very greatly reduced during recent years by the introduction of emetine and the aspiration method of treatment, for which we are indebted to the work of Sir Leonard Rogers in Calcutta. It is only in cases of exceptional severity, in neglected or undiagnosed cases, and in cases of multiple abscesses, that a fatal result is likely to occur.

The Surgical Complications of Bacillary Dysentery are also very numerous, but need not be discussed here at any great length. The bowel itself may suffer in the following ways: Hæmorrhage and perforation, localized sloughing or gangrene, cæcitis or appendicitis, abscesses and sinuses in the mucous membrane, hæmorrhoids and polypi, fibrous thickenings, stricture and adhesion to adjacent structures, diverticulitis, intussusception, carcinoma. Extension of the inflammatory process to neighbouring tissues is not nearly as likely to occur as in the case of amœbic dysentery, but localized or general peritonitis may follow a leak in the bowel, and various complications result from burrowing abscesses. Secondary complications due to infection of distant parts by the specific organism, or some other organism introduced through dysenteric lesions, are important. The liver is not picked out in the same way as in amœbic disease, but very severe infection may occur, resulting in pylephlebitis or multiple abscesses and pyæmia. Cirrhosis of the liver is a later complication. Other well-

known sequelæ are conjunctivitis and iritis, cysto-pyelitis, urethritis, and arthritis.

The *arthritis* which follows attacks of bacillary dysentery has been recognized from ancient times. This may take the form of a poly-arthritis or a single joint may be involved; the knee, the ankle elbow, hand, shoulder, and wrist represent the order of frequency of involvement. It is generally in the later stages of the disease that the complication occurs, and this is another instance of infection being carried to distant parts from the infected bowel. Joint affections occur in about 1 per cent. of cases, and are more common in some epidemics than in others. The severity of the attack varies from a mild disturbance without effusion to severe arthritis involving ligaments and cartilage, with a liability to false ankylosis or deformity.

Surgical aid may be required in dysenteries of any type when ordinary medical treatment is incapable of arresting the course of the disease. Delay is most unfortunate in such cases, and a definite line of surgical treatment should be decided upon before the decline in health has progressed too far. *Appendicostomy* is a simple operation in most cases, and it is useful in relapsing cases of the severest type; it provides a means for thorough lavage of the large bowel, but does not give complete rest to the part. *Cæcostomy* is useful in the worst cases, where free drainage is necessary, as well as functional rest; the valvular form is available if the patient can stand a longer operation. *Ileostomy*, with an open cæcostomy, and *ileo-sigmoidostomy* may be advisable in selected cases when a skilful surgeon is at hand.

The Surgical Affections caused by Parasitic Worms in the tropics are very numerous, and two groups are especially worthy of close attention, namely, schistosomiasis and filariasis. Paragonimiasis, clonorchiasis, and the surgical complications caused by intestinal and other parasitic worms cannot be discussed here.

Schistosomiasis is caused by infection with trematodes, which live as parasites in the circulatory system during their definitive stage They are responsible for diseases of the urinary or intestinal tracts, which result in a great variety of surgical lesions. They are well known in Africa, Mesopotamia, Persia, South America, the West Indies, and the Far East. The intermediate hosts are fresh-water snails, which are, curiously, absent from India. The ova hatch out in water, releasing free-swimming embryos, or miracidia, which enter the bodies of the snails. After undergoing changes of structure they emerge as bifid-tailed cercariæ, which are capable of penetrating the skin of a suitable vertebrate to initiate a fresh infection.

Bilharziasis, or **Endemic Hæmaturia,** is the disease caused by *S hæmatobium* in Africa, Mesopotamia, Persia, and adjacent countries. In some parts of Egypt it is probable that no individual escapes infection. Toxic symptoms may appear a few weeks after the entrance of the parasites, and the various signs characteristic of the disease begin to appear within a few months up to two or three years. The parasites inhabit the portal circulation, particularly the pelvic plexuses, and the inflammatory lesions which involve the urinary bladder, rectum, and occasionally the lungs, are due to the deposit of great numbers of

terminally-spined ova in the submucosa and mucosa. Cystitis may be succeeded by ascending urinary infection, and this, together with rectal ulceration, produces abscesses, calculi, fistulæ, polypi, and even secondary carcinoma. In later stages grave anæmia, emaciation, and exhaustion set in. The characteristic ova are found in the urine and pathological discharges.

Intestinal Schistosomiasis is of two types: that due to *S. mansoni* in Africa, South America, and the West Indies, and the type found in the Far East, named *S. japonicum*. The adult parasites of *S. mansoni* live in the liver and mesentery, and the lateral-spined ova are found chiefly in the polypoidal masses and ulcerations of the rectal mucosa. The transverse and pelvic colon may be similarly affected, and infection of the liver occurs in the later stages, resulting in splenomegaly, cirrhosis, and ascites (Egyptian splenomegaly). *S. japonicum* causes an intestinal affection known as Katayama disease in China, Japan, and the neighbouring Pacific Islands. The ova of *S. japonicum* are without a spine, and are found in the abdominal organs, producing dysentery-like symptoms, ascites, anæmia, and emaciation; the liver and spleen are markedly affected in this disease *Treatment.*—The diseases caused by schistosomes can now be effectually controlled by means of a specific drug. Christopherson has proved in Egypt that intravenous injections of tartar emetic can kill the parasites. Doses of ½ grain in 6 to 10 c.c. of sterile salt solution are injected on alternate days, ½ grain being added to each dose up to a maximum of 2½ grains per dose. The course extends over four to five weeks without interruption. It is important to begin the treatment as early as possible, before surgical and other complications have become established.

Filariasis.—Filarial worms provide an enormous amount of surgical work in some parts of the tropics, *Filaria bancrofti* (*Wuchereria bancrofti*) and *Dracunculus medinensis* being the chief offenders, while two others are worthy of mention, namely, *Loa loa* and *Onchocerca volvulus*.

Filaria bancrofti is widely distributed in large areas of the tropical and subtropical world, Southern Europe, South America, Pacific Islands, Northern Australia, South China, India, Arabia, and Africa. Millions of human beings are affected, and a large proportion are incapacitated to some extent by the pathological lesions which follow. The female worm is 0·25 mm. in breadth and 50 to 100 mm. in length, and inhabits the lymphatic vessels and glands. The embryo filariæ, called *Microfilariæ bancrofti*, are given birth to in these situations as microscopic objects, 0·3 mm. in length by 0·006 mm. in width, and find their way to the blood-stream, whence they may escape by the help of various kinds of mosquitoes which act as intermediate hosts. After undergoing a transitional stage in the body of the mosquito during a period of twelve to twenty days, the metamorphosed embryos are found in the proboscis of their intermediate host ready for transfer to a new human host. This is the means by which a new cycle is started of young adults of both sexes.

Microfilaria bancrofti is a minute worm-like creature, with one end rounded and the other tapering to a point, and it is enclosed in a loose sac or sheath in which it can move freely, but which prevents inde-

pendent locomotion. Microfilariæ occur in countless numbers in the circulating blood of infected individuals in cases where the maternal nidus is not shut off from the general circulation by inflammatory changes in the lymphatics. Their appearance in the peripheral circulation observes a curious periodicity in most parts of the world, being confined to the night hours. This was first described by Manson in 1880, and is called 'filarial periodicity.'

The Surgical Aspects of F. bancrofti Infections.—The surgical lesions which are met with in filariasis are of two sorts: those which are believed to be due to the reaction of the tissues to the filarial parasite itself or its toxin, and those which are due to secondary infection. It is probable that in most cases both causes are at work at the same time, or are conjointly responsible for the disabilities which follow. The following is an enumeration of the most important surgical manifestations: *Filarial fever*, which may occur in association with other obvious surgical lesions or independently; *lymphangitis, cellulitis, abscess, gangrene, funiculitis, orchitis, acute and chronic hydrocele, synovitis, arthritis, abscess of joints. Lymphatic varices lymph fistulæ, gland varices, lymph scrotum. Chyluria and chylous effusions into the peritoneum, tunica vaginalis, pleura*, etc. *Elephantiasis of the legs, scrotum, mammæ, vulva, or skin.*

The *pathology* of filariasis has not been fully worked out. All the evidence points to the young adult and the mature parasites as the disturbing factors, and the fact that they produce obstruction of lymphatic channels with dilatation due to back-pressure. The inflammatory reaction is probably due to a combination of causes, namely, mechanical and toxic irritation, together with secondary infection from some septic focus in the body. Some important work has been done recently on this subject to prove that a condition of 'kataphylaxia' exists in or near the affected areas, resulting in a breakdown in the local cell-defence mechanism.

Filarial fever and the inflammatory outbursts generally occur at definitely periodic intervals, probably associated with the outpouring of embryos from the gravid female or some other event in the life-history of the parasite, resulting in the release of toxins. When these attacks are of an erysipelatoid character, it is not unusual to find streptococci in the sodden tissues. In severe attacks cellulitis, followed by abscesses or gangrene, may follow and require active surgical treatment; the scrotum and lower extremities are most often involved. A very serious condition, termed *funiculitis* or septic phlebitis of the spermatic cord, is associated with filarial disease. It is a streptococcic infection which rapidly spreads down to the testis, and upwards along the cord. The inflammation is of sudden onset, and is accompanied by high fever, great pain, and acute tenderness Urgent surgical treatment by laying open the affected tissues is necessary, or castration in more advanced cases. If treatment is delayed, there is grave danger of pyæmia and a fatal issue.

Inflammation of the testis and epididymis are common occurrences in filarial subjects. The attacks are usually of a subacute type, and may be accompanied by hydrocele. Suppuration is not common except in the more severe types, in which a chylous effusion may be found

swarming with microfilariæ. The typical 'tropical hydrocele' is probably not filarial. It is very common in some hot and moist districts, and is due to a subacute form of epididymitis, the ætiology of which has not been worked out. All forms of hydrocele, except in the acute stage, are treated by open operation with eversion of the sac. When the sac is very large or much thickened, partial removal is necessary.

Lymphatic obstruction of dependent parts and of lymphatic glands and in the thoracic duct system are among the most characteristic signs of filarial disease. Extreme instances of this are lymphatic varices which may rupture and produce lymph fistulæ; gland varices and lymph scrotum are also met with. Localized lymphangiectases and conditions such as lymph scrotum may usually be removed surgically

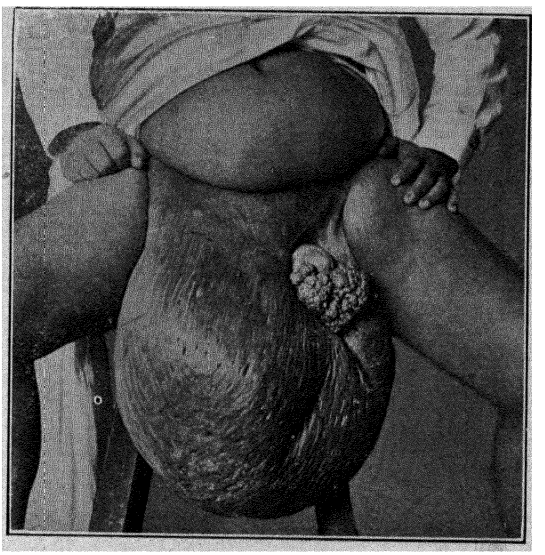

FIG 1079.—FILARIAL ELEPHANTIASIS OF THE SCROTUM

with advantage. The chylous effusions are only a stage farther in this process of obstruction, the thoracic duct being involved in these cases. Treatment is most unsatisfactory, and during periodic exacerbations the patient may suffer severely in general health.

Surgery is most useful in dealing with the well-known elephantoid enlargement of dependent parts, such as the legs, scrotum, arms, mammæ vulva, and skin. The unfortunate victims may be confined to their beds by the weight of the tumour, and few operations in surgery produce a more dramatic effect than the restoration of a patient to active life by the removal of a scrotal tumour weighing fifty or more pounds (Figs. 1079 and 1080).

Nothing is more efficacious in very early cases of filarial thickening

than the removal of the patient to a cooler and non-filarial climate. Much improvement can also be effected by rest and pressure bandages, but such methods are not available for the working classes. In the case of the lower extremities, masses of solid œdema, with or without papillomatous excrescences, can be removed and replaced by thick skin grafts. Kondoleon's operation is also practised; it consists essentially of the removal of large longitudinal strips of thickened tissue, including deep fascia, so as to open up the deep lymphatic spaces. Amputation is sometimes necessary when a leg has become riddled with abscesses and sinuses.

The operation for elephantiasis scroti consists in the removal of all the diseased skin and œdematous tissue after isolating the penis and

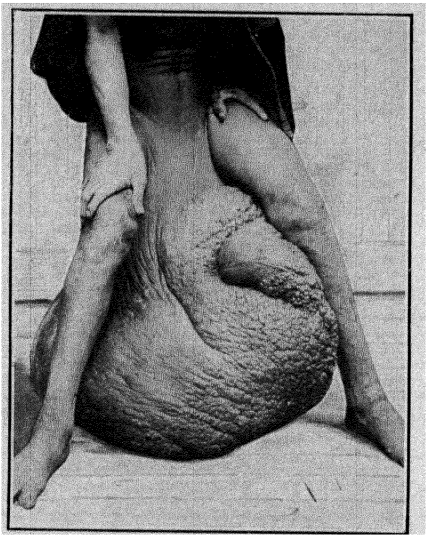

FIG 1080.—FILARIAL ELEPHANTIASIS OF SCROTUM AND PENIS

testicles The raw penis is covered with a skin graft, and the testicles covered by the narrow perineal flaps or buried in pouches prepared under the superficial fascia at the junction of the perineum and thigh.

Elephantiasis of the arms, mammæ, vulva, scalp, skin, etc., may be treated by surgical excision and skin grafting in a similar manner.

It will be observed that no effective specific treatment for filarial disease has yet been evolved. It is probable that one reason why anthelmintic drugs are useless is that the adult filariæ live for the most part in deep lymphatic vessels and glands, unlike bilharzia worms.

Loasis is not of great importance. The parasite is found in large

areas of tropical West Africa. The intermediate host is a day-biting fly, named Chrysops. Surgically, the most important lesions found are the transient inflammatory swellings termed 'Calabar swellings.' These may appear in the neighbourhood of the eye, under the skin of the penis, on the hands, chest, etc. They are not painful, and disappear in two or three days, being due to the irritation produced by the worms or their embryos.

Onchocerciasis is another filarial infection of minor importance found in Central Africa, the Gold Coast, and other places. Fibrous tumours are produced by the irritation of the worms in the axillæ, popliteal spaces, and other areas rich in large lymphatics. Surgical removal is practised when the tumours become inflamed or cause inconvenience.

Dracontiasis, or **Guinea-Worm Disease,** is found in India and other tropical countries, and is responsible for much suffering and disability.

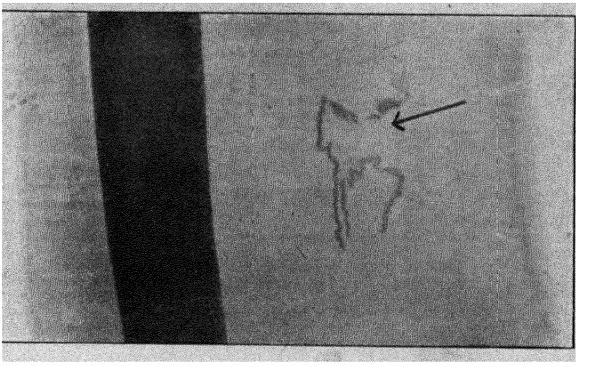

FIG 1081.—CALCIFIED REMAINS OF DEAD GUINEA-WORMS IN THE THIGH, CAUSING SCIATICA

The guinea-worm (*Dracunculus medinensis*) infects man as the definitive host, and is conveyed by drinking contaminated water in which the embryos are found inside their intermediate host, Cyclops, the water-flea. The female, when fully developed in the human subcutaneous tissues, reaches a length of 30 cm. to 1 metre, and 0·5 to 1·5 mm. in width. The male is seldom seen, and is said to be only 22 mm. in length. In parts of India infested by this worm the rate of infestation is as high as 30 per cent. The female reaches maturity in about a year, and in about 80 per cent. of cases develops in the subcutaneous tissues of the lower extremities, but any part of the human body may be affected. The emergence of the head, alongside which is the opening of the uterine sac, is made possible by local necrosis of tissue caused by a helminthic poison, and when this gives way a stream of embryos is exuded by the worm when the part is brought into contact with water. Various vasomotor symptoms may appear at this time, such as giddiness and vomiting. Septic infection of the necrotic tissue is very

ommon, resulting in cellulitis and abscesses. Trouble may also follow rom death of the worm in the tissues, and late sequelæ caused by the alcified remains of dead parasites may produce symptoms of sciatica, rthritis, etc. (Figs. 1081 and 1082). *Treatment.*—Removal of the worm nay be carried out by daily traction, by surgical excision, or by de-

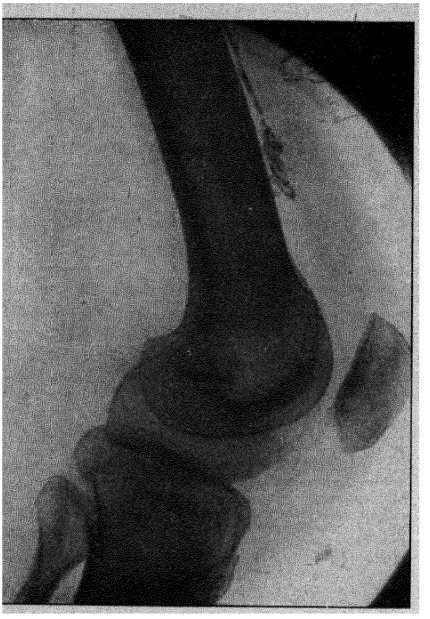

KNEE-JOINT

truction of the worm by the injection of various antiseptic fluids. Septic complications must be treated.

The reader is referred to books on tropical surgery and tropical nedicine for a fuller account of the special aspects of surgery as practised in the tropics; only the more important diseases and conditions have been referred to in this short chapter. It has not been ound possible, also, to discuss here the effects of tropical conditions f race and climate on ordinary surgical affections common to the ropics and other parts of the world.

CHAPTER LI.

WAR SURGERY.

ALTHOUGH war surgery must be looked upon in the main as traumatic surgery, and is therefore considered as such in the appropriate chapters, yet there are some details of treatment which do require more elaboration.

Under the heading of War Surgery must be included a consideration, not only of the wounds caused by rifle and revolver wounds, but also those inflicted by shell fragments, bombs, grenades, and any other projectile propelled by an explosive force, the outcome of the inventive genius of some of the best brains of this enlightened age. Naturally, to deal with such a subject *in extenso* in a textbook of this size is an impossibility, and merely an outline of the character, course, and treatment of such conditions can be given.

It is a curious fact that experience gained in war has always been a factor in surgical progress. All down the ages the majority of medical men gained their experience in war. The present European war, coming as it does some twenty odd years after the last great war, means that the experience gained then will be most useful to-day, and there are many medical men now in their prime who saw service in 1914-1918.

The **characters** of war wounds necessarily vary greatly with the nature of the projectile, the arm employed, the velocity of the missile, the distance from the body at which the firearm was discharged, the part of the body struck, and the direction of the shot.

1. **Modern Small-bore Rifle or Machine Gun.**—The wounds inflicted by these are very different from those produced by the old-fashioned guns of former years. The modern rifle has been designed to secure great muzzle velocity, a low or flat trajectory, and clean and hard hitting. To this end the barrel is rifled so as to cause the bullet to rotate on its own longitudinal axis, and the bullet has been greatly modified, whilst gunpowder has given way to more highly explosive substances.

The modern bullet of the British Army is a long, thin, conical body, consisting of a core of lead hardened by the addition of 2 per cent. of antimony, enclosed in a cover, jacket or mantle made of a copper-nickel alloy. The muzzle-velocity is very high, amounting to 2,000 feet per second. The trajectory is nearly flat; anything within 500 yards may be fired at point-blank, whilst in a range of 2,000 yards the bullet rises only 177 feet as compared with 866 feet with the Snider bullet.

The wounds caused vary according to the range and the part of the body struck. Under 500 yards the effects on the soft tissues are

frequently explosive, and may resemble those caused by a ragged piece of shell. At longer range the wounds of entry and exit may be clean and hardly noticeable, and, if missing a bone or other important structure, singularly little damage may be caused. Owing to the high velocity of these projectiles through-and-through wounds are common. Their action, however, may be modified by several conditions.

(i.) A secondary result of the rifling of the barrel may be to impart another type of rotation to the bullet, the base rotating in a larger circle than the apex, especially when the centre of gravity of the bullet is near to its base. After travelling for about 500 yards this movement generally disappears, and the bullet travels true and straight. Probably this 'wobbling' movement explains some of the disruptive phenomena caused at the shorter ranges, since on entry the bullet may tumble over and over, and so produce a badly lacerated track.

(ii.) **Soft-nosed Bullets** (*e.g.*, the Dum-Dum) are characterized by the mantle being absent at the top, whilst the lead core is usually free from antimony. The result of this is that, as soon as the bullet strikes, the lead core mushrooms out, and terrible mutilation or destruction of surrounding tissues ensues, whilst bones are comminuted and solid viscera pulped. A similar result follows from rubbing or cutting off the top of the Lee-Enfield or Mauser bullet, or even from incising the cover in two or three places. These bullets are 'expanding' and not 'explosive' in character, the latter property can only be secured by including some substance which detonates on impact.

(iii.) **Ricochet** bullets, which are likely to be distorted in shape, are only too liable to produce wounds of such serious nature as to be mistaken for the products of soft-nosed bullets.

Martini-Henry and Snider Bullets produce wounds which are intermediate in their severity between the preceding two. The aperture of entry is usually small, that of exit large and with everted edges. Portions of clothing are frequently carried in by these missiles, and add to the risks of infection.

2. **Shrapnel, High-explosive Shells, Bombs or Grenades** (rifle or hand) are responsible for the vast majority of war wounds.

Shrapnel shells, on explosion, propel a large number of lead balls about the size of marbles in various directions. These being free from jagged edges (unless having struck the ground or some other object first), cause less severe injuries than do the other three. They are, moreover, less likely to carry into the body portions of clothing, which are such predominant factors in the causation of the severer forms of wound infection. The casing of the shrapnel will, however, inflict precisely similar lesions to those caused by high-explosive bombs or grenades.

High-explosive Shells, Bombs, and Grenades.—Ragged fragments of metal are by these means scattered in all directions with great force, and the lacerating effect of these is usually more marked in the muscles than in the skin and superficial structures, large gaps being left, due to the retraction of torn muscle fibres. The skin-wound and opening

in the deep fascia may be surprisingly small. The gap between the torn muscle fibres is as a rule filled with blood-clot at first, but later on with pus surrounding the fragment (Fig. 1083).

The modern high-explosive bomb consists of a charge of high-explosive mixture contained in a steel case fitted with a fuse and exploder. The destructive effects of the bomb are twofold: those of the blast, which is the air pressure created by the explosion, and those of fragmentation, which is the breaking-up of the steel case of the bomb into small jagged pieces or splinters. The average size of the

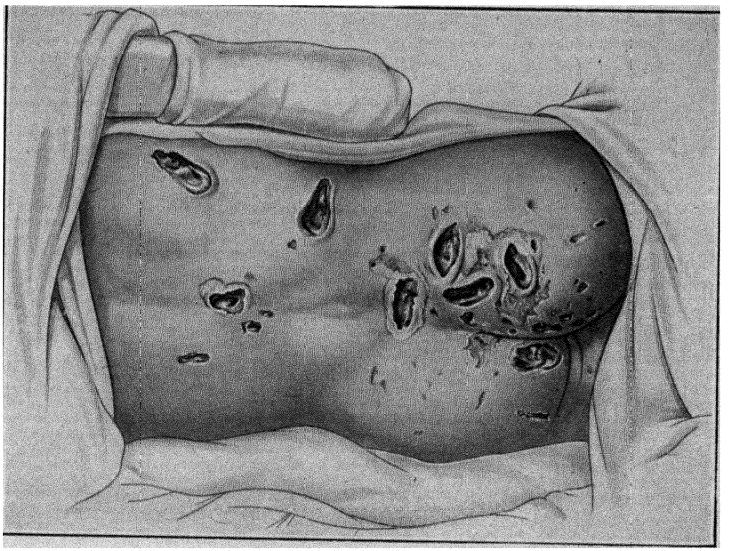

FIG. 1083.—MULTIPLE WOUNDS CAUSED BY BOMB EXPLOSION

splinters is about 1 inch across, and they are projected in large numbers in every direction at about twice the speed of a rifle bullet.

The bombs which are most commonly in use weigh anything between 100 to 500 pounds.

3. The effect of **revolver wounds** is very variable, and possibly corresponds most closely to those caused by shrapnel balls. They are more likely to be seen in civil life than any other form of gunshot wound, and then may be suicidal or accidental in origin.

Suicidal wounds are usually directed to the temple, the base of the skull, through the mouth or the heart. In the temporal region (right side for right-handed individuals) there is usually a small wound surrounded by an area in which the skin and hair are singed, and perhaps stained by the powder. The bullet pierces the bone and traverses the brain, but in the majority of cases does not emerge or

even fracture the other side. It may be found either embedded in the brain substances or loose under the dura mater. Death is not always instantaneous, as no large vessels may be torn. When the revolver is discharged upwards through the mouth, the base of the skull is penetrated, and death is more likely to be instantaneous; the bullet in some cases may dislodge a portion of the top of the cranium, but without penetration.

Accidental revolver wounds may present any variety of lesion, but the apertures of entry and exit are as a rule distinctly recognizable.

4. Dangerous wounds may be inflicted by **small shot** at point-blank range, lacerated wounds being caused, or even death if important organs are affected. At a range of 50 yards or more the result is negligible, unless such an organ as the eye is struck, or if grave infection follows.

5. A **blank cartridge** may similarly result in a severe wound or even death, if discharged at a short distance, and under such circumstances the skin around is likely to be burned or blackened, leaving a permanent bluish-black tattooing of the tissues. The wad may also be carried into the body, and if it consist of horsehair may induce tetanus.

Course.—A certain proportion of wounds caused by rifle, machine gun, revolver or shrapnel bullets remain uninfected, and then resemble the wounds met with in civil practice so closely that a special description of their course is not required; it is determined merely by the anatomical structures involved.

Generally speaking, however, every wound of war should be regarded as probably contaminated, and in fact the clinical course in the great majority of cases is entirely dependent on the degree or type of the infection. The nature of the campaign will determine this to a large extent.

When the fighting occurs in a healthy country where the soil is clean and uncontaminated by manure, and the air is dry and pure, gunshot wounds do wonderfully well, especially if the campaign is of a mobile character, so that a large majority of the wounds are due to rifle bullets. These conditions obtained in the South African War, where tetanus and gas gangrene were practically unknown. Things were, however, quite different in France and Belgium during the Great War of 1914-1918. Here the soil had been highly cultivated for many centuries, and was rich in manure; the weather was frequently wet, the men lived in trenches, and their clothes were caked with the thick, dangerous mud of the soil; washing and changing of clothes was impossible, often for weeks at a time; rifle bullet wounds were comparatively unfrequent, bombs and hand grenades being the favourite missiles; very powerful artillery was employed on both sides, disturbing the soil and casting it up in great showers, so that it is not surprising to find that wounds became grossly contaminated, especially if a portion of the man's clothing was carried in, or if treatment were delayed, as was so often the case owing to the impossibility of providing first aid at an early period. Naturally his resisting powers were reduced considerably under such circumstances.

When the fighting line on the Western front became practically stable, it was possible to establish well-furnished casualty clearing stations (C.C.S.) a few miles back. At these, all necessary operations could be carried out on the wounded under favourable conditions, usually within six or twelve hours of the receipt of the wound. At this period the organisms lie superficially in the track of the missile, and there are no manifestations of inflammation; it is in this pre-inflammatory stage that the best opportunity occurs for aborting septic complications.

It is quite unnecessary to enter into any lengthy disquisition as to the clinical course of a gunshot wound, since it is determined by the aseptic or septic conditions present. In the former the wound heals rapidly, and the subsequent events depend on the exact anatomical course of the missile. In the latter it is merely a story of virulent acute or mild cellulitis, as the case may be. The degree of mischief inflicted on the tissues, the irregular shape of the wound, the depth to which various layers are penetrated, and the effect of the inflammatory process in spreading around and among important structures—all of these contribute to make the progress eventful, and sometimes very dangerous, whilst complications are liable to occur at any time which may jeopardize life.

In the earliest stage those most likely to occur are hæmorrhage and shock; at a later date any or all of the many conditions associated with septic infection, to which may be specially added tetanus and gas gangrene. Most of these are described in other parts of the book, but gas gangrene must be specially considered.

It is unnecessary to discuss *in extenso* the **bacteriology** of war wounds, which has been the subject of much study since the war in 1914-1918. Suffice it that both aerobes and anaerobes are to be found. The former include the usual pyogenic organisms, as well as diphtheroid and coliform bacilli and the *B. proteus*. The anaerobes constitute a large and important class, divided into two groups. (1) The saccharolytic, decomposing some carbohydrates in the presence of organic matter, and acting feebly on proteid material, *e.g.* the *B. perfringens*; and (2) the *proteolytic*, which decompose proteid material, including the *B. œdematis maligni* and the *B. tetani*.

It is obvious that when the body defences, including the leucocyte army, are unprepared, infection is likely to occur in every degree of severity. During the first twenty-four hours the bacteria merely lie on the surface of the track of the projectile and of the blood-clot; they are usually anaerobic (*B. perfringens*), mixed with aerobes, such as staphylococci, streptococci, and *B. proteus*. In the later stages deeper structures become infected, and the anaerobes diminish quickly, whilst the aerobes increase rapidly, and in persistent suppuration the former are as a rule not demonstrable.

General Treatment of War Wounds.—Every soldier, whether in the firing line or on the lines of communication, is provided with a first field dressing, which consists of a pad of sterile gauze, an ampoule of iodine, and a bandage. This is applied to the wound by the man him-

self, or by a companion, as soon as possible. At the regimental aid-post the wound is inspected by a medical officer, dressed, and, if necessary, splints applied. At the advanced or main dressing station of the field ambulance operations of an emergency character can be undertaken, as for stopping hæmorrhage or removing a hopelessly mangled limb. The preliminary doses of antitetanic serum and sulphonamide are here administered. As a rule the patient is hurried through to the C.C.S., where most cases requiring operation are dealt with. Some mobile ambulance units with operating theatres and blood-transfusion units may in some cases be able to move up closer to the firing line. If the patient is suffering severely from shock, so that immediate operation is unadvisable, he is placed in the resuscitation ward, where the measures considered necessary in order to combat this condition are taken, and operation is deferred until he is thought fit to stand it. Otherwise missiles are localized by X-rays, and the patient is sent for operation at once.

Transport of Wounded.—This is a very important problem, and one of which every medical officer should have some knowledge. With war wounds it is important that treatment should be instituted as soon as possible. In the last war the abdominal surgeon could do nothing until the methods of resuscitation of the shocked had been carried out, the rule being that the less resuscitation required the greater the patient's chance. Therefore transport consists of two main things: time and rest.

Time is all-important, and every effort should be made to get the wounded back to the C.C.S. as soon as possible; this is especially so in wounds of the abdomen, thorax and head. Rest is also important, and in abdominal injuries the Fowler position should be maintained, wounded from the line should be transported in a chair.

In mobile warfare the only chance of saving patients with abdominal wounds is by the collection of wounded by aeroplane.

The **scope of the operation** is governed by two generally accepted facts: (1) That the track of the missile is lined by dead and damaged tissues, and (2) that the bacteria have not penetrated deeply, and probably not beyond these tissues within twelve hours of the infliction of the wound. Hence it is likely that within this limit of time, and possibly even after it, a complete excision of the wound track, if anatomically practicable, together with removal of the missile and of any foreign bodies which may have entered with it, will transform the wound into one that is clinically sterile, and *primary suture* may be attempted with good chances of success. After excision of the wound it is essential that rest should be given to the injured tissues, and to ensure this immobilization of the wounded limb in a complete plaster-of-Paris cast is undertaken.

This form of treatment was very successful in the Civil War in Spain and Trueta was full of praise for it. The rest does allow local venous and capillary thrombi to form. These thrombi prevent the spread of infection, and are not broken down by repeated handling. Also the ensured rest allows new capillaries to form which are not torn asunder by repeated dressing of the wound. The plaster itself maintains a

constant beneficial pressure on the wound and the calcium contained n it may be of local value.

The **primary operation** is therefore of the most supreme importance. Anæsthesia is secured, if possible, by gas and oxygen, or failing that, by warmed ether. The wound is temporarily packed with gauze, while the skin around is shaved and cleansed with ether soap. After his the skin surrounding the wound is painted with a weak alcoholic solution of iodine. An incision is made to surround the skin-wound, but as close to the edge as possible. The extremities of the excised area are prolonged to give good exposure to the injured subjacent parts. Careful excision of the tract is then carried out, taking every possible precaution to keep outside of it and so avoid contaminating he instruments.

The chief complications of war wounds are hæmorrhage, shock, etanus, and gas gangrene, and all of these have been already described n detail in former chapters.

Blast.

Although the effects of blast were known during the war 1914-1918, yet their importance was never recognized until the bombing of towns and cities in England began on a large scale.

The phenomenon of blast is not yet understood, but it has convinced he population of this country that adequate shelter is the only protection against it. In the bombing of towns blast may completely mutilate a person, or in other cases cause partial or complete loss of clothing In the patients who survive there is generally some lung damage, the condition being known as *pulmonary concussion*, or *blast lung*.

The clinical features may be characteristic or masked by shock Generally speaking, most cases develop severe shock associated with dyspnœa. Cyanosis may be present at first, but disappears in recovering patients. Pain in the chest may or may not be present, while in the majority of cases hæmoptysis is a constant feature

On examination, there is diminished movements of the diaphragm and a somewhat characteristic fullness of the chest, giving an emphysematous appearance. Pneumonia may develop at any time after the first twelve hours.

X-ray appearances show a heavy mottling scattered over the lung areas.

The *treatment* of blast consists in the treatment of the initial shock, which includes the hypodermic injection of morphine. *Morphine is not contra-indicated in cases of blast injury to the lungs*

The patient should be kept as quiet as possible and oxygen administered in high concentration, and for this a B.L.B. mask is essential

If there are other injuries, such as a fracture or open wounds which require operative treatment, then local or intravenous anæsthesia should be used, on no account should any inhalation anæsthesia be given.

Water Blast.—This has played an important rôle in this war in the Navy. The explosion of a depth charge, mine, or torpedo while men are in the water will cause death if the explosion is close by or blast

effects if it is at a distance. The commonest blast effects are signs of pulmonary concussion. In other cases a loop of bowel may be ruptured without any signs of external injury. Retro-peritoneal hæmorrhages are common (Fig. 1086), while in other cases hæmatemesis or hæmaturia may occur. In more severe cases rupture of the gut or solid viscera may occur (Figs. 1084 and 1085).

The patients give a very characteristic story. They tell of the feeling of a violent kick in the abdomen, accompanied by paralysis

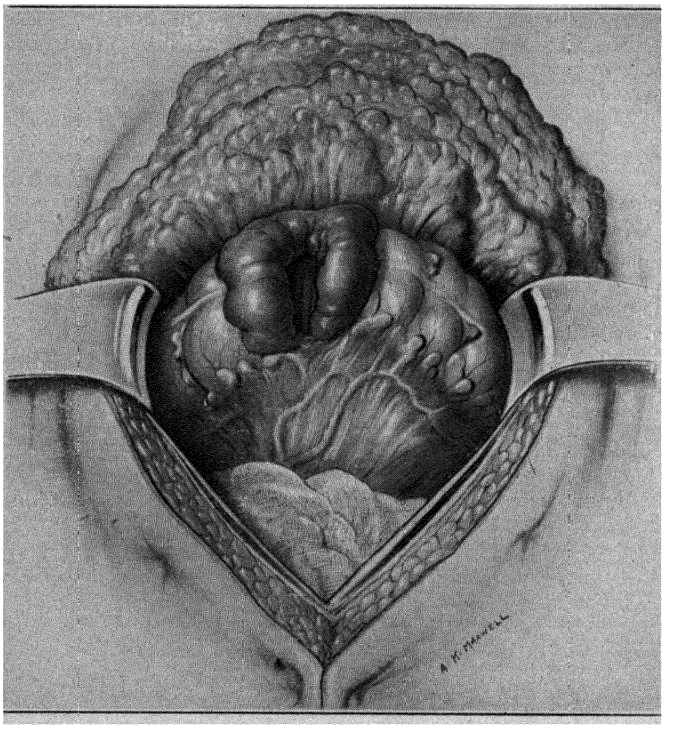

FIG. 1084.—RUPTURE OF THE TRANSVERSE COLON DUE TO WATER BLAST. Drawing made at time of operation. No external signs of injury.

of the legs. This paralysis disappears after an interval of ten minutes or so. Many thousands of men have lost their lives in this war due to the effects of water blast.

It is probable that the blast wave strikes the abdomen and is then transmitted through the diaphragm to the lungs, where it causes multiple hæmorrhagic areas and massive hilar contusions.

It has been demonstrated that abdominal protection by thick sorbo rubber will be effective against water blast, and this holds in

spite of no protection to the thorax. In the future adequate abdominal protection may be incorporated in a life-saving suit.

In those cases where abdominal injury is suspected a laparotomy should be performed under local anæsthesia. It is better to look and see rather than to wait and see.

Once the patient has recovered from the effects of blast there is very rarely any permanent disability or sequelæ.

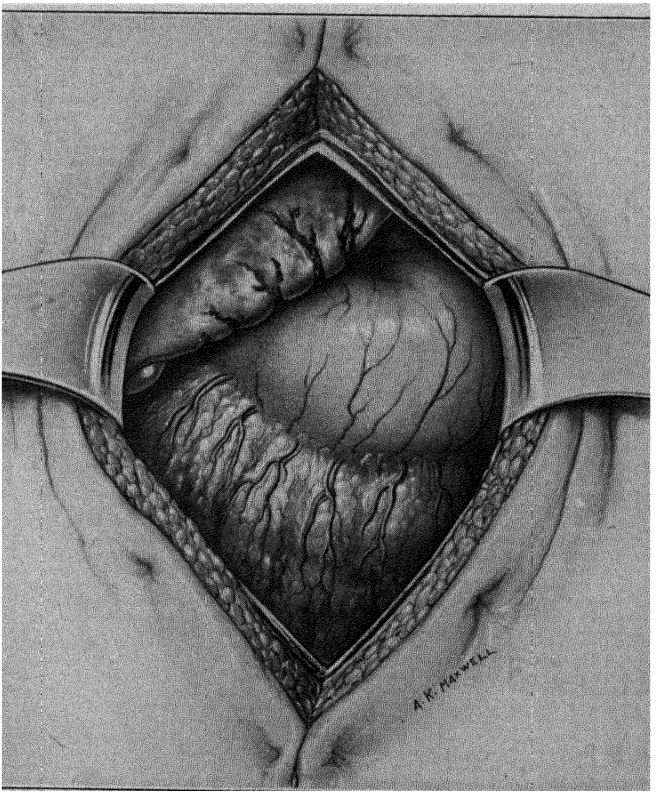

FIG. 1085.—RUPTURE OF THE LIVER DUE TO WATER BLAST. This patient had no sign of external injury.

Crush Syndrome.

This is a condition which was little known before this war, and it has come to the fore because of the repeated bombing attacks on cities and towns. Persons who get crushed under falling masonry are liable to develop this syndrome. No external wound is present in the majority of cases, but extensive muscle damage resulting in

the formation of hæmatomata is quite common. The development of anuria followed by fatal uræmia at the end of a week is the characteristic feature of this syndrome. The ætiology of this anuria is little understood at present, but it must be stated that it is very similar to the anuria which follows incompatible blood transfusion. It may be that histamine released from the crushed muscles may play an important part

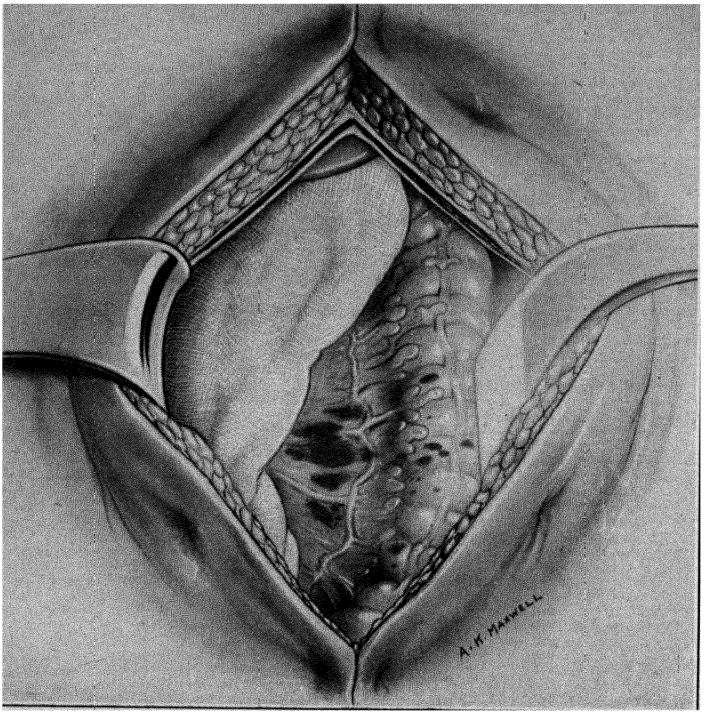

FIG. 1086.—RETRO-PERITONEAL HÆMORRHAGES ON THE COLON AND POSTERIOR ABDOMINAL WALL IN A MAN WHO WAS IN THE WATER WHEN A DEPTH CHARGE EXPLODED

It is important that the surgeon should be conscious of the possibility of the development of crush syndrome in all cases where a limb has been compressed or crushed so that effective measures may be instituted before the kidney function fails

Treatment consists in applying hot packs to the loins and the administration of intravenous isotonic sodium sulphate Not more than 1½ pints should be given unless the urinary flow is re-established.

Should these measures fail, a spinal anæsthetic should be given, as has been known to terminate reflex anuria.

As a last resort, and this should not be delayed too long, renal ecapsulation can be carried out.

Early recognition of the condition leads to early treatment, and this ives better results.

War Burns.

War burns form a very large proportion of service casualties and ulk heavily amongst the civilian population after bombing attacks. uch of the confusion that has arisen about the best form of treat- ient of war burns is due to the fact that there is an essential difference etween civilian burns, which are frequently treated within an hour f the injury, and service burns, which may not receive hospital treat- ient for one or two days. This fact is very important, and has ot been appreciated by the medical profession as a whole. If burns in be treated in hospital within a very short time of the injury, ien little need be done in the way of a first-aid dressing. If, n the other hand, hospital treatment cannot be given for a long eriod, then the first-aid treatment must ensure no loss of tissue fluids nd prevent any subsequent septic infection Under war conditions urns produced by bomb flash, gun flash, petrol or oil in the Atlantic cean may have to be treated by laymen in any armed trawler or in long-range aircraft. Similarly, in a tank in action in the African esert, any burns which occur must be treated by the soldiers them- lves until the base is reached and medical aid is forthcoming. This nportant fact has now been recognized by the three fighting forces id a first-aid treatment adopted as a routine. This treatment nsists in the application of a 1 per cent gentian violet jelly or triple ye jelly (triofax: gentian violet 1 per cent., brilliant green 0·1 per nt., euflavine 0·1 per cent. in a water-soluble base).

The application of such a jelly is painless and can be made by ntrained persons. No preliminary toilet is required, and the jelly ould be applied as soon after the injury as possible. The jelly is ntiseptic, soothing, and is a coagulant. No dressings are required. uch a first-aid treatment is simple, efficient, painless, and does ot produce shock. It does not matter how extensive the burn is, ie jelly should be liberally applied and the patient treated for ock.

In the Services the majority of burns affect the face and hands, and ith this treatment many sailors, after extensive second-degree burns the hands, have been able to keep watch some hours after the plication of the jelly. The naval authorities were quick to see the cessity of adequate protection of the face and hands of our seamen posed to bomb or gun flash. Hence to-day the anti-flash gear nsists of thin asbestos gauntlets and helmet and mask, while the es are protected by eye shields made of cellulose acetate (Fig. 1087). his protective gear is light and can be stowed away inside the standard eel helmet when not in use. If a gas attack is expected, the eye ields and mask are removed and the service respirator is substituted

(Fig. 1088). Since the introduction of this means of protection the number of burn cases in the Navy has been considerably reduced although the number of fighting ships has increased and so have the air attacks. Experience has shown that there is no contra-indication to coagulation methods in the treatment of war burns, but adequate cleansing must be performed prior to the use of tannic acid or silver nitrate, otherwise septic infection will appear under the tan. This is not appreciated by all medical officers who have burn cases under their care. On the other hand, it is essential that no local treatment to the burnt area should be attempted until the patient has been treated adequately for shock. Patients have been known to die in those cases where an anæsthetic has been administered and a very thorough cleansing technique performed while the patient was still in a shocked condition

For burns of the hands tannic acid should never be used because of the danger of ischæmic necrosis of the fingers. There still seems to be some difference of opinion as to the best form of treatment for burns of the hands: some advocate saline baths, while others are in favour of gentian violet or of triple dye. Under total war conditions saline baths are not likely to be generally satisfactory owing to the heavy nursing involved and the frequent need to transfer patients from hospital to hospital. On the other hand, it must be acknowledged that saline baths have a place in the treatment of war burns, especially in the late stages of infected burns, when they may complete the cleansing process.

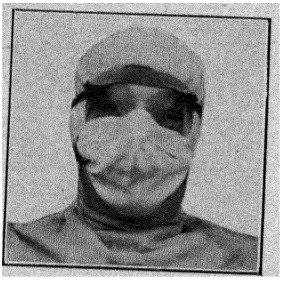

FIG. 1087.—NAVAL ANTI-FLASH GEAR



FIG. 1088.—NAVAL ANTI-FLASH GEAR WITH GAS MASK

Envelope Treatment.—Bunyan has devised an envelope method for the treatment of burns, in which the burnt area is segregated in a water tight jacket and irrigated with a solution of electrolytic sodium hypochlorite (5 per cent. Milton). This method is most suited for septic

urns of the limbs. The envelopes are simple covers of coated silk o designed as to envelop the limb. Means of inlet and outlet are rovided, so that a lesion of any part may be irrigated by the insertion f a glass nozzle through any one of the openings. The great ad-antage of this form of treatment is the absolute abolition of pain nd any form of dressing. Secondary infection or cross-infection is liminated, and movement within the envelope can be undertaken. or the R.A.F. in the Far East this method is one of choice, as it ntirely prevents the wound from becoming infected with flies.

Treatment by Sulphonamides.—As would be expected, many attempts ave been made to make use of a sulphonamide paste in the treatment f war burns because all deep burns have a great tendency to become eptic. Water-soluble sulphonamide in a solution of glycerine has een used quite extensively and given good results.

Skin Grafting in the Treatment of Burns—For all burns where the vhole thickness of the skin is involved skin grafting should be under-aken at once.

Too many war burns are allowed to heal up by epithelium growing n from the sides and leaving keloid scars and contractions.

All third-degree burns (total skin loss) should be skin grafted as oon as the wound has granulated, or even before. The area should e treated with a saline pack for twenty-four hours. Any moisture r exudate is removed by dry gauze. The granulations are now owdered with sulphonamide, and skin grafts are laid on the top of he powder. Quite 95 per cent. of the grafts take. For small areas inch grafts are used.

Electrical Burns.—The present war, with its repeated bombing ssaults and incessant torpedo attacks on our ships, has produced a arge number of electrical burns Such burns result from broken lectric cables, short circuits, and the like. Not only ships, but the nterior of tanks and aircraft, may be the scene of electrical burns, while shore establishments and power houses have frequently been ombed and electrical burns have been produced. Before discussing hese burns it may be appropriate to consider in a general way the lectrical skin lesions.

The skin, which, especially if dry, is a highly resistant barrier, is by ontact the place of entry and exit of electricity into the body, with he consequent liberation of a considerable amount of heat. The esultant lesions present variable appearances and characteristics epending on the amount of electrical energy which is passing the area f contact, and the duration of the electrization. The more serious esions, which vary in severity from erythema to a deep charring process involving muscle and bone, are commonly referred to as 'electric burns.' Perhaps a better appellation would be 'electrical necrosis.' It is important, however, to understand that the un-complicated specific electrical skin lesion will only be seen when a small amount of heat is generated by a low-voltage current with a short duration time of contact. Accidents resulting from the use of low-voltage domestic currents are responsible for the majority of such lesions. The high-voltage currents, which produce far greater quanti-

ties of heat, result in injuries in which the characteristics of the primary electric lesion are overshadowed by the ordinary burning which results from the high temperature, sometimes accompanied by a flash or flame. The electric arc, which may generate up to 7,000° C., commonly is responsible for this type of lesion. Speaking generally, then, there are two types of skin injury to consider: (1) The pure, uncomplicated electrical skin lesions, (2) the electrical skin lesion complicated by burning.

Observation has led to the differentiation of the following types of skin injury: (*a*) The electrical current mark; (*b*) the electrical necrosis; (*c*) electrical gangrene; (*d*) electrical metallization; (*e*) lightning figures; (*f*) electrical œdema

(*a*) *The Electric Current Mark.*—This is an example of the pure electrical lesion found in most cases of electrical accidents at the point of entry of the current, and seen commonly on the hands and feet. The shape of the mark varies with the shape of the object carrying the electricity, but usually they are circular or elliptical areas, varying in size from a pin's head to a pea. In colour they are greyish-white, with a slightly raised periphery, a depressed centre, and no surrounding area of hyperæmia. They look glossy, feel smooth, like parchment, and when on the fingers result in the complete obliteration of the papillary lines over the area they occupy.

Clinically, these marks are characterized by an absence of surrounding reactionary hyperæmia and by complete analgesia. They are easily overlooked, especially when situated on hairy skin such as the scalp. Seen microscopically, the parchment-like appearance of the skin is due to compression of the layers of the epidermis There is also an elongation of the basal cells of the Malpighian layer. Cases have occurred where sections of the skin showing these changes have been the only means of establishing the cause of death. In such sections the characteristic changes of burns—*e.g.*, vacuolization, coagulation, and altered staining capacities—are conspicuous by their absence

The local treatment for this type of electrical burn consists in applying some gentian violet jelly (1 per cent. with merthiolate) or some triofax, which is a triple dye jelly (gentian violet 1 per cent., brilliant green 0·1 per cent., euflavine 0·1 per cent. in a water-soluble base). It is most essential that some antiseptic jelly should be applied, as these small electric marks have a definite tendency to become septic after a few days.

General treatment may require the ordinary methods of dealing with shock, as the general manifestations may be more marked than the local condition seems to indicate. On the other hand, in quite a number of cases there has been a complete absence of a general upset.

(*b*) *The Electrical Necrosis.*—This is the type of injury that is so frequently described as 'the electrical burn.' The skin lesion is similar in type to the electrical mark, but of severer degree, resulting from the discharge of a greater quantity of electric energy, and may or may not be complicated by superficial burning. In appearance the electric necrosis resembles a burn, and may be of a degree of severity ranging from an erythema to a deep charring of muscles and bone

may occur on any part of the body, but naturally the hands are by far the most frequently involved. The general use of anti-flash gear has saved many a sailor from electric burns of the hands. When such an injury is uncomplicated by burning, the clinical characteristics resemble those of the electric mark. It is painless, and the usual surrounding hyperæmic area of reaction is absent, the necrotic area being limited by a sharp outline. There are no evidences of suppuration, and as a rule the patient exhibits no toxic signs. Such a pure electrical necrosis has a tendency to extend in area and depth for the first two or three weeks, much of the dead tissues being shed. The third week is the danger period, when severe hæmorrhage may occur owing to degenerative changes in the artery walls. Following the

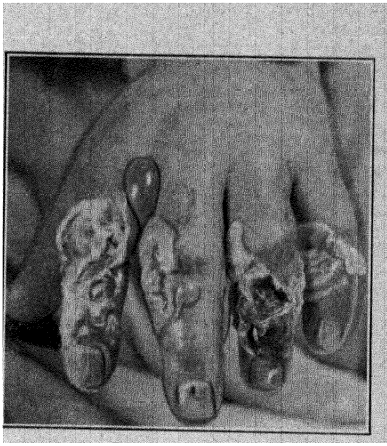

FIG. 1089.—ELECTRICAL NECROSIS OF THE FINGERS DUE TO A BROKEN CABLE IN THE ENGINE ROOM OF A DESTROYER



FIG. 1090.—TYPICAL CASE OF ELECTRICAL GANGRENE OF THE MIDDLE FINGER

initial phase a powerful healing period ensues and freely movable skin is the result. There is no tendency to contraction deformities.

When, however, superficial burning complicates the electrical necrosis, the chemical picture becomes one of a severe burn. The injuries are intensely painful; there is the usual red area of reaction around the wound, and the patient exhibits all the usual toxic signs.

This type of injury requires the same form of treatment as described for the electric mark, and most of the cases do exceptionally well. Avoidance of sepsis during healing is the keynote of the treatment.

(*c*) *Electrical Gangrene.*—Occasionally the electric necrosis affecting a digit (Fig. 1090) or a limb may be of such severity as to result in gangrene of the affected part. Gangrenous changes supervene in from two to several weeks after the initial injury (Fig. 1091). If a digit is involved, then the treatment is amputation, as no form of treatment will save the part. When the gangrene is local and on the forearm or leg, then excision and skin grafting should be employed as soon

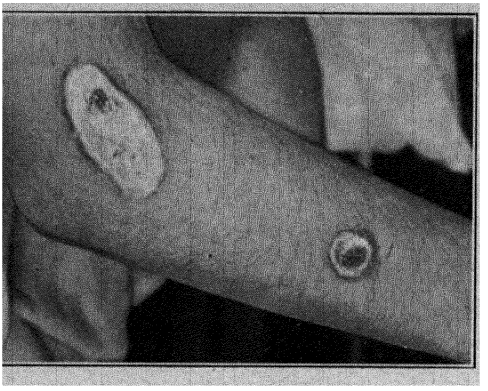

FIG 1091.—TWO AREAS OF ELECTRIC GANGRENE OF THE ARM

as possible after the injury. It is waste of time and bad practice to institute any other form of treatment. It has been possible in the Royal Navy to get key men back to work a month after their injury by immediate excision of the gangrene area and skin grafting.

Cases have been reported where dry gangrene which resembles mummification follows immediately after the accident. No satisfactory explanation of this extraordinary occurrence has so far been advanced.

(*d*) *Electrical Metallization*.—This may be defined as an impregnation of the epidermis by volatized metal occurring when the metal is molten in an electric light arc and become embedded in the epidermis. The affected skin is decolorized by the fine particles of metal, and the decolorized area cannot be cleansed by washing. The skin feels dry, and is restored to its normal condition by the shedding of the epidermis. The finger-nails, when metallized, are restored to normal by the growing away of the decolorized area. Since these accidents occur at high temperatures, the clinical picture is one of burning.

Treatment should be immediate in these cases, as some of them die from the initial shock. Morphia for the pain, $\frac{1}{3}$ to $\frac{1}{2}$ grain if the pain is severe. Warmth and fluids are necessary. The wound should be treated with gentian violet jelly until a definite tan forms. No dressings are required, but the patient should be put to bed, even if he states he is quite all right and wants to carry on with his work.

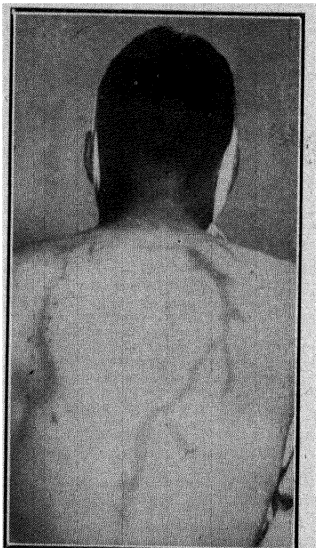

FIG 1092.—LIGHTNING FIGURES PRODUCED ON THE BACK OF A MAN BY A HIGH-VOLTAGE CHARGE

In bad cases it may be necessary to give some intravenous plasma if there is any hæmoconcentration.

(*e*) *Lightning Figures*.—Although the name suggests a lesion due to natural atmospheric forces, the same changes can be produced by high-voltage discharges. The manifestation of this type of injury is a simple erythema and dendritic arrangement of either very fine lines or broad stripes (Fig. 1092). The figures thus produced tend to divide up into smaller branches, and may spread over a considerable area of the body. The figures fade within a few days, leaving at first a brownish discoloration of the skin which soon desquamates.

Shock may be severe or absent. Local treatment with gentian violet jelly is all that is required.

(*f*) *Electrical Œdema*.—Electrical skin injuries may be accompanied by a peculiar type of œdema. The onset may be immediate or delayed, and may affect either the region adjacent to the skin lesion or a large and separate area of the body. Occasionally it is the only manifestation of the accident. The œdema is symptomless, and invariably disappears in a few days. Transient functional changes in local bloodvessels are believed to be the cause of the immediate œdema.

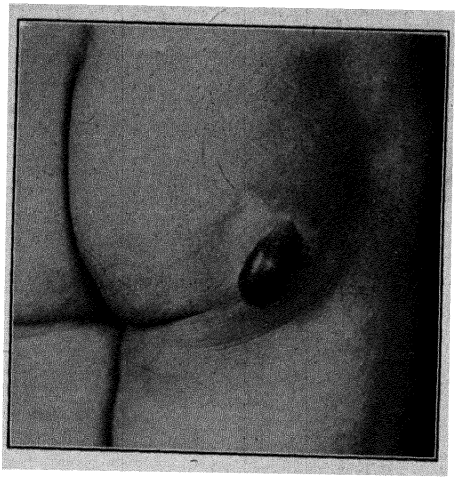

It must be realized that skin lesions constitute only one of the changes produced in the body as the result of electrical injury, and the importance of such local damage is often entirely secondary to the profound unconsciousness which may result from even low-voltage accidents.

Phosgene Burns.—These burns appear to be those of a first degree, causing an erythema or brown staining; they are themselves relatively unimportant in comparison to the rapidly fatal syncope produced by phosgene gas. This gas has the characteristic odour of new-mown hay, and unless a gas-mask is used at once and rest taken in the recumbent position, death will take place. The burns themselves should be treated with a weak solution of sodium bicarbonate and then tanned with tannic acid.

Mustard Gas and Lewisite Burns.—These burns are always severe and painful (Fig. 1093). These gases are nearly odourless and are used in liquid form, which soaks through clothes and boots and causes extensive burns. It is important, therefore, that all contaminated garments must be removed promptly and placed in containers for subsequent decontamination by bleaching powder solution. The burnt area can then be treated with tannic acid. If the eyes are burnt, drops of a sterile castor oil should be instilled into them.

War Wounds of Bones and Joints.

A high proportion of injuries of bones and joints result from modern warfare. Compound fractures are common and should be treated by the Winnett Orr method; this allows of easy transport and is by far the most comfortable as far as the patient is concerned. There is often great destruction of the muscles in cases due to bomb and shell fragments, but this does allow the surgeon to get alignment of the

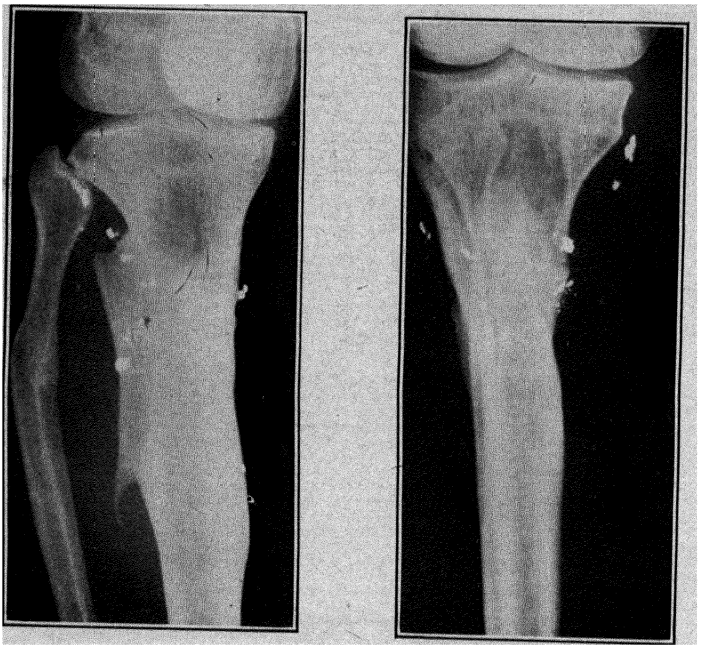

FIG. 1094.—LATE RESULT OF A COMPOUND FRACTURE OF THE TIBIA AND FIBULA DUE TO HIGH-EXPLOSIVE SHELL

FIG. 1095.—LATERAL VIEW OF THE SAME CASE AS FIG 1084

bones without having to use any extension apparatus or a special table. Adequate excision of the wound and a packing of gauze soaked in vaseline followed by a plaster-of-Paris encasing splint are essential. Figs. 1094 and 1095 demonstrate the value of this method. The soldier was wounded by fragments of a high-explosive shell which caused a compound comminuted fracture of his tibia and fibula. Excision of the wound and closed plaster-of-Paris bandaging was carried out. There are still some portions of the shell fragments in

the soft tissues and the bone, but the result from every point of view is excellent.

One of the great discoveries of the last war was the power of resistance to infection offered by the synovial membrane in a joint, and the



FIG. 1096.—COMPOUND FRACTURE OF THE LEFT FEMUR CAUSED BY A HIGH-EXPLOSIVE BOMB.

The hip-joint was opened up and there was much destruction of the soft parts

result of this has been to develop a conservatism which saved many a limb from amputation, and even restored it to mobility in spite of a serious injury to one of the main joints.

As a rule bullet wounds are much less destructive than those produced by high-explosive shells, aerial bombs, or hand grenades (Fig. 1096). In these cases radical excision of the wound and loose portions of bone is essential; the limb can then be treated by the Winnett Orr method. The earlier the case receives surgical treatment the better the result.

In some cases of compound fracture union does not take place, and the bones become infected to such an extent that amputation is called for owing to the patient developing a septicæmia (Fig. 1097).

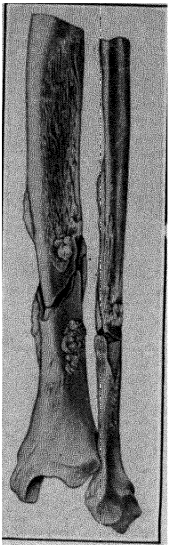

FIG 1097.—ANTERIOR SURFACE OF A LEFT TIBIA AND FIBULA, SHOWING FRACTURE OF BOTH BONES IN THE LOWER THIRD, WITH SEPARATION OF SEQUESTRA

Note the lace-like appearance of the new callus

Abdominal Wounds.

The commonest structure to be injured in war wounds of the abdomen is the small intestine, and if other structures are not damaged and the case is operated upon within six hours there is a 50 per cent. recovery rate. The time-factor is a most important one in abdominal injuries, and every effort should be made to get the man to a casualty clearing station with all speed. In the last war it was proved conclusively that the limit in successful cases was forty-eight hours for a resection of the small intestine and thirty-six hours for a suture of the colon.

The *symptomatology* of war wounds of the abdomen varies considerably. As a rule pain is a fairly constant symptom, but there are many recorded cases in which men have had their abdomens ripped open by bullets and have not experienced pain or exhibited much shock. The pain is often intense and commences from the moment of infliction, and it can be likened to the pain of a perforated gastric ulcer. In wounds of the lower part of the abdomen, if the lumbar plexus is involved, there may be referred pain in the leg, and this may be all that the wounded man complains about, no notice being taken of the actual entrance wound itself.

The appearance of the patient may be fallacious, but as a rule a man hit in the abdomen looks ill and blanched, however, some cases present almost a normal appearance, but the pulse rate will nearly always give the key to the actual situation. When there is a rapid pulse or a rising pulse operation is always indicated. The rapid pulse is invariably due to hæmorrhage, which may be said to be the greatest enemy of the surgeon. The hæmorrhage may come from various sources: the abdominal wall, the wall of the bowel, the mesenteric vessels, the omentum, or vessels in the retroperitoneal tissues. Hæmorrhage occurring in the retroperitoneal tissues is probably the worst type the surgeon may encounter because there is rarely any indication as to the source of the bleeding. It may come from the renal vessels or even from the inferior vena cava. The retroperitoneal hæmatoma may be so great that it raises the peritoneum of the posterior abdominal wall to such an extent that it almost approximates the anterior

abdominal wall. On opening the abdomen in such cases the surgeon appears to be dealing with an enormous purple intra-abdominal tumour, and once seen such a condition is never forgotten. Tenderness, although a fairly constant symptom, may occasionally be absent. It is well known that injuries of the thorax, especially if low down, may cause superficial abdominal tenderness, and it is always a wise precaution to examine the thorax thoroughly as well as the abdomen.

It is necessary when dealing with war wounds of the abdomen to have adequate exposure, therefore the most useful incision is the paramedian one. Wounds in the abdominal wall should be carefully

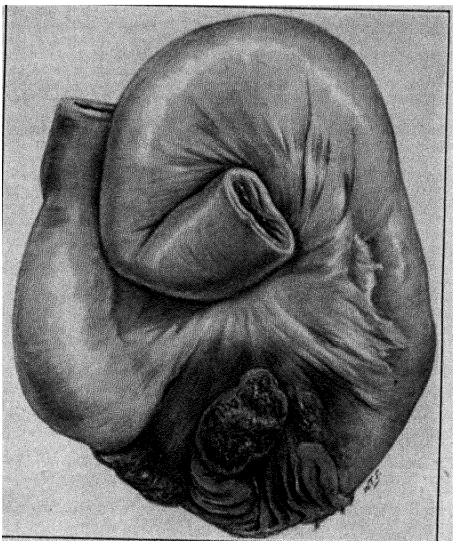

FIG 1098.—G.S.W OF SMALL INTESTINE AND MESENTERY

From a patient who died of hæmorrhage from the mesentery, and whose small intestine was extensively damaged and the adjacent mesentery injured

(Royal College of Surgeons, W O Collection, 887.)

excised. Should the wounds be in the flank an iliac incision may be used, in which the muscles in this region are divided, such an incision gives useful exposure. Once the abdomen is opened arrest of hæmorrhage is of prime importance because it is the commonest cause of death in war wounds of the abdomen Mesenteric vessels probably are the greatest danger, and the root of the mesentery should always be carefully inspected. However, bleeding may come from the wall of the gut, the stomach, liver, spleen or omentum. Once the hæmorrhage is controlled blood transfusion can be started while the surgeon makes a routine examination of the bowel.

The Small Intestine.—Commencing at the duodeno-jejunal junction, the small bowel should be examined carefully but quickly loop by loop and returned to the abdominal cavity. Any perforation or wound of the small bowel requires suturing. Some holes in the intestine are very small and it seems difficult to believe that they were caused by a bullet at all; these small perforations do not pout, and therefore may be missed. Usually the mucous membrane is seen prolapsed through the wound in the bowel wall (Fig. 1098). Unless there are multiple perforations in a loop of bowel simple suture is sufficient, but excision is necessary where many perforations are found close together. A single layer of suture is quite sufficient, whereas a double layer may cause stenosis of the lumen. Resection of the bowel must be performed when there has been a separation of the bowel from the mesentery for a distance of more than ½ inch. It must be performed in cases of complete rupture of the bowel or where there has been intestinal infarction. The character of the wounds of the small intestine varies considerably; quite often a bullet may cause as severe an injury as a piece of high-explosive shell.

The Large Intestine.—The large bowel injuries are in the main similar to those in the small intestine, but there is always a great tendency for escape of the contents of the large intestine. In many cases wounds of the large and small intestine co-exist. Colonic wounds are more grave not only because of the toxic contents of the large bowel but because of the proximity of the retroperitoneal tissues and of the fact that the ascending and descending colons are not completely invested with peritoneum, and therefore lack the protection of that membrane behind. Hæmatomata in the retrocolic and pericolic tissues are common and invariably become infected. Again, infarction is more frequently met with in the large bowel wounds.

A paramedian incision is the best for large bowel injuries as a general exploration is necessary, but quite often the colon may be the only part of the alimentary tract injured. However, there is quite a lot to be said for the transverse incision in some cases; it affords excellent approach to the ascending and descending colons, and the dangerous bare retroperitoneal aspect of the colon can easily be explored and if necessary, an artificial anus can be established at the posterior end of an incision of this kind. Transverse incisions should cut across the rectus muscles at one of the tendinous intersections so that no damage is inflicted on the nerve supply of the abdominal muscles.

Whatever incision is used adequate exposure is essential, as otherwise extraperitoneal wounds and hæmatomata may be missed.

Having opened the abdomen it is important to remove the large quantity of extravasated blood and bowel contents, because until this is done the surgeon is working in the dark. If possible a sucker should be used unless large clots are present, and then they should be removed with the hand. It is a curious fact that free gas is seldom present except in stomach wounds.

A systematic examination of the large intestine is carried out starting with the cæcum and passing along the ascending colon to the

transverse and descending colons, particular care being exercised not to overlook any retroperitoneal injury or hæmorrhage.

Wounds of the Cæcum.—Cæcal wounds may be small or large; in the former suture will suffice, but, if large, they will necessitate an artificial anus; if associated with retroperitoneal hæmorrhage drainage must be established.

Wounds of the Ascending Colon.—The ascending colon with its peculiar peritoneal relations, being covered in front medially and laterally but not posteriorly with peritoneum, may be wounded either intraperitoneally or extraperitoneally, or both forms of injury may be present. Intraperitoneal wounds of the ascending colon are as a rule easy to find and suture; however, the extraperitoneal wounds are often difficult to find as they may be small and valvular and are often obscured in the mass of retroperitoneal fat and hæmatoma. A colostomy may be necessary, but should be avoided if possible.

Wounds of the Hepatic Flexure.—These are easy to deal with owing to the fact that this part of the colon is superficial in position; however, multiple wounds may be present in this region, and these may necessitate a colostomy.

Wounds of the Transverse Colon.—The transverse colon may be injured in a variety of ways, it may be completely divided or a small perforation may be present. Quite often wounds of the transverse colon are associated with those of the stomach and small intestine, and such multiple wounds are generally fatal and do not survive long enough for the surgeon to see them on the operating-table. In single wounds of the transverse colon excision is the method of choice, but if this is impossible a colostomy should be performed as a life-saving measure.

Wounds of the Splenic Flexure.—The splenic flexure is one of the most difficult regions of the large intestine to treat for gunshot injuries; it is high in position and deep in the abdomen and therefore it is difficult to expose and mobilize; hence a colostomy is often necessary, and retroperitoneal hæmatomata are common and require drainage.

Wounds of the Pelvic Colon.—These wounds are easily dealt with if they occur in its upper portion, but lesions of the pelvirectal junction always demand colostomy. The surgeon is frequently confronted with the problem of suture versus colostomy in colon wounds, and it is hard to dogmatize on this subject, but each case must be judged on its own merits and surgical common sense is of more value than brilliant technique.

Wounds of the Rectum.—Wounds of the rectum are very fatal, especially if complicated by wounds of the buttocks, perineum and ischio-rectal fossæ. Such wounds are also liable to be further complicated with fractures of the pelvic girdle. Gas gangrene is especially liable to develop in wounds of the gluteal region. Wide excision of the wound and a colostomy are often required as a life-saving procedure. Transverse colostomy is the method of choice, as it is easier to manage; a better belt can be fitted and finally it is easier to close at a later date should this be considered safe.

Wounds of the Solid Viscera.—Although minor degrees of hepatic damage recover spontaneously, the more severe form demands instant surgery. If possible lacerations of the liver should be closed with sutures which act not only as approximation sutures but hæmostatic as well. If sutures cannot be inserted, hæmostasis may be secured by the use of diathermy cautery or actual packing with gauze.

Splenic injuries are best dealt with by excision of the organ.

Wounds of the pancreas are rare owing to its position in the abdomen, but it may be injured in association with other viscera. In a few cases the gland has been successfully sutured, while in others the tail of the pancreas has been excised. Wounds of the kidney should be treated conservatively unless there is extensive renal damage, when nephrectomy is indicated. Hæmaturia by itself is no indication for surgical intervention.

Wounds of the Chest.

War wounds of the chest carry a high mortality unless early surgical treatment is forthcoming. The immediate cause of death is hæmorrhage and shock and later from sepsis. Wounds which lay open the pleural cavity should be closed as soon as possible by suture; this immediately relieves respiratory distress. Other conditions, such as compound fractures of the ribs, crushed ('stove-in') chests, acute infected hæmothorax and abdomino-thoracic wounds, require primary operations.

The wound in the chest should be excised and any broken ends of ribs and all blood is removed from the pleural cavity. If a foreign body is found in the lung tissue it is removed by an incision made into the lung, bleeding being controlled by the surgeon's fingers and later by interrupted sutures passed through the lung tissue. If the diaphragm is lacerated it can be efficiently sutured from above. No attempt should be made to repair the chest-wall in layers. No drainage should be established, but regular post-operative aspiration is generally required to keep the pleural cavity dry, for after an extensive operation there is a fluid exudate which may become infected if not removed.

Wounds of the Head.

It must be remembered that the general treatment of a gunshot wound of the head presents a problem very similar to that of a wound of any other part of the body, and they are very liable to the fatal complication of sepsis, therefore every head injury should be given sulphonamide. Routine use of M. and B. 693 (two tablets thrice daily) is advisable. If the patient is unconscious an intravenous injection of a 10 per cent. solution M. and B. (one ampoule four-hourly) or an intramuscular injection of soluseptasine (one ampoule four-hourly) should be given.

Scalp wounds should always be excised and carefully explored. If there is no bony injury the wound can be sutured completely. In those cases where there is a compound fracture of the skull but no penetration of the dura mater, the depressed fragments of bone should be removed and the wound drained for twenty-four hours to prevent

the formation of a hæmatoma. Where actual penetration of the brain has taken place a thorough exploration is indicated After carefully shaving and cleaning the head the wound is completely excised, together with all underlying damaged tissue The hole in the skull is enlarged by means of bone forceps and the track of the wound in the brain explored. A previous X-ray examination will give the surgeon some idea of the depth of the missile. If the missile or missiles are deep in the substance of the brain no attempt should

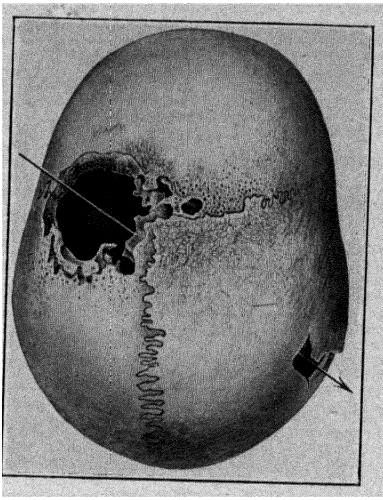

FIG 1099.—CALVARIA, SHOWING CONDITION OF A FRONTO-PARIETAL GUNSHOT WOUND A YEAR AFTER INFLICTION

(Royal College of Surgeons, W O Collection, 122)

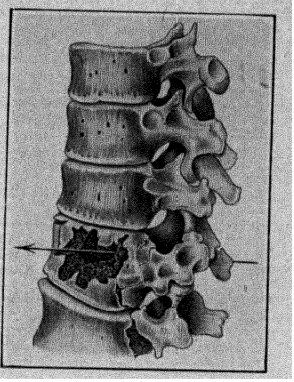

FIG 1100.—LEFT LATERAL VIEW OF LOWER DORSAL VERTEBRÆ AND FIRST LUMBAR VERTEBRA, SHOWING TRANS-SPINAL INJURY, WITH PERFORATION OF THE BODY OF THE TWELFTH DORSAL VERTEBRA

The arrow indicates direction taken by missile

(Royal College of Surgeons, W.O Collection, 3, 3816)

be made to remove them unless this can be done without increasing the damage to the brain. In order to facilitate the removal of small bony fragments and cerebral debris Cushing's method should be adopted. He used an ordinary Carrel syringe to which was attached a rubber catheter. This rubber catheter is inserted into the brain and the syringe, which is filled with normal saline solution, is used to wash out small debris. On releasing the rubber bulb, larger fragments of debris and small pieces of bone are caught in the eye of the catheter and are removed when the catheter is withdrawn.

As a dressing, when the brain is exposed, a watery solution of flavine, 1 in 2,000, should be used, as it does not injure nerve tissue. The complications of gunshot wounds of the head are fits, which occur in 5 per cent. of cases; meningitis, which should now be controlled to a certain extent by sulphonamide; cerebral abscess, which may continue for many months before a fatal termination occurs (Fig. 1099); and cerebral hernia.

The prognosis of gunshot wounds of the head which reach hospital is only fair, as they carry a mortality of 60 per cent., and practically none are ever fit to return to the fighting-line. It must also be remembered that the immediate results of gunshot wounds of the head show a very great mortality, as a large proportion of men with head injuries never reach a hospital at all.

Wounds of the Spine and Spinal Cord.

Every variety of injury to the spine is met with in modern warfare; fractures of the spine may vary from simple cracks and fissures to complete crushings and pulverization of the bones (Fig. 1100). Hence it is that such injuries carry a high mortality. Sepsis is the great bugbear in these cases and it is to be hoped that the sulphonamide drugs will be useful in combating this menace. Laminectomy is indicated whenever there are signs of meningitis, but the mortality is high. If there is any evidence that the dura mater is intact and that a foreign body (*i.e.*, bullet or piece of bone) is compressing the cord laminectomy should be undertaken.

Surgical common sense is far more valuable in the treatment of war wounds than any hard-and-fast rules which may from time to time be issued to the Services.

INDEX

ABDOMEN, drainage of, 1163, 1176
Abdominal aneurism, 339
  aorta, compression of, 262
    ligature of, 349
  cases, bleeding of, 1164
  contusions, 1168
  hysterectomy, 1615, 1618
  lesions, tender spots in, 1198
  muscles, paralysis of, 805
  myomectomy, 1614
  nephrectomy, 1435
  operations, general remarks on, 1160
    after-treatment, 1163
    incisions for, 1161
  pregnancy, 1627
  tonsil, 1262
  walls, injuries of, 1168
    wounds, non-penetrating, 1169
      penetrating, 1169, 1702
      visceral complications of, 1169, 1702
Abdomino-perineal excision of rectum, 1431
Abduction in fractured femur, 614
Abernethy's operation for ligation of external iliac artery, 351
Abortion due to syphilis, 164
  tubal, 1628
Abscess, acute, 46
    causes of, 46
    signs and symptoms of, 50
    structure of, 47
    treatment of, 52
  alveolar, 955
  anal, 1405
  antral, 1027
  appendicitic, 1267, 1270
  axillary, 375
  Bezold's, 1640
  Brodie's, 642, 653
  bronchiectatic, 1099
  cerebellar, 902, 1646
  cerebral, 900, 1646
  cervical, 376, 378
  chronic, 54
    of bone, 642, 653
    of breast, 1137
  cold, 54. *See also* Tuberculous abscess
  'collar-stud,' 379, 651
  definition of, 48
  dorsal, 820
  embolic, 76
  evacuation of, 52
  extradural, 894, 1644
  filarial, 1688
  formation of, 47
Abscess, gas in, 52
  gluteal, 479
  in glands of neck, 376, 378
  in groin, 376
  in hip disease, 773
  in spinal disease, 819
  intramammary, 1134
  ischio-rectal, 1406
  lacunar, 140
  lumbar, 820
  mastoid, 1639
  of breast, 1134
  of epididymis, 1533
  of joints, filarial, 1688
  of kidney, 1453
  of liver, 1283, 1684
  of lung, 1083, 1099
  of scalp, 842
  of spleen, 1325
  of testis, 1532
  of tongue, 983
  ovarian, 1623, 1625
  palmar, 247
  parametric, 1627
  parotid, 996
  pelvic, 1625
  pelvi-rectal, 1407
  perineal, 1519
  perinephritic, 1444, 1453
  peri-rectal, 1405
  peritonsillar, 1037
  peri-urethral, 1519
  pointing of, 50
  prostatic, 1493
  psoas, 173, 774, 820
  pyæmic, 76
  pyogenic, 54
  residual, 823
  resolution of, 50
  retropharyngeal, 819
  rupture of, 50
  subcranial, 849, 894
  sublingual, 983
  submammary, 1134
  submucous, of rectum, 1406
  subpericranial, 842
  subperiosteal, 640
  subphrenic, 1182
  supramammary, 1134
  treatment of, 52, 55
  tropical, of liver, 1284, 1684
  tuberculous, 172, 177, 745, 773, 819, 823, 829
    natural cure of, 173
    treatment of, 177, 745
  typhoid, 47

Abscess, urethral. *See* Perineal abscess
Acanthoma, 217, 218
Accessory auricles, 1636
sinuses of nose, affections of, 1024
thyroids, 1111
Accommodative shortening of muscles, 481
A.C.E. mixture, 1597
Acetabulum, fracture of, 602
travelling, 770
Acetylcholine in paralytic ileus, 1392
Achalasia, 1052
Achilles tendon, rupture of, 461
tenotomy of, 472
Achlorhydria, 1193
Acholuric jaundice, 1327
Achondroplasia, 667
Acidosis in shock, 273
in vomiting after anæsthesia, 1585
Acoustic nerve, tumours of, 409, 910
Acro-arthritis, 763
Acromegaly, 672, 929
Acromion, dislocation of, 697
fracture of, 576
Actinomyces, 182
Actinomycosis, 182, 969, 1114, 1279, 1289, 1677
bovis, 183
of breast, 1138
'sulphur granules' in, 182
Actual cautery, 297
Adam's osteotomy, 769
subcutaneous operation for Dupuytren's contraction, 499
Adamantinoma, 199, 930, 972
Adductor longus, rupture of, 462
spasm in hip disease (Gauvain), 774
Adeno-carcinoma of breast, 1153
papilliferous, of thyroid, 1126
Adeno-fibroma. *See* Fibro-adenoma
Adenoid facies, 1033
Adenoids, 1033
operation for, 1035
Adenoma, 213
congenital, of post-anal gut, 814
intracanalicular, of breast, 1143
malignant, 1126
of intestine, 1424
of liver, 1288
of palatal glands, 1012
of pancreas, 1317
of pituitary body, 929
of prostate, 1496
of thyroid, 1125
pericanalicular, of breast, 1143
sebaceous, 455, 843
Adeno-myoma, 1616
Adherent scars, 253
Adhesions after arthritis or synovitis, 727
after fracture, 544, 554
after tuberculous arthritis, 743
in appendicitis, 1267
in gastric ulcer, 1213
in hæmophilic joints, 763
in hernial sac, 1335
in peritonitis, 1179
Adolescent genu valgum, 507
rickets, 666
scoliosis, 487
Adrenalectomy, 1331
Adrenal glands, surgery of, 1330
tumours, 1330
Adrenalin, use of, in anaphylaxis, 12
in hæmorrhage, 262
Adreno-genital syndrome, 1331
Adventitious bursæ, 475
Aerial fistula, 1111
Agglutination groups, 33
reaction, 33
Agranulocytic angina, 31
Agranulocytosis, 31
Air, entrance of, into veins, 269
hunger, 257
injection into lateral ventricles. *See* Ventriculography
Air-passages, examination of, 1057
foreign bodies in, 1071
operations on, 1063
radiography of, 1057
surgery of, 1057
wounds of, 1109
Air-way in anæsthesia, 1580
Albee's operation, 795, 807, 828
Albuminoid (amyloid) disease, 56
Alcohol injections in causalgia, 391
in tic-douloureux, 396
Alcoholic poisoning, diagnosis of, 880
Aleucocytosis, 30
Alibert's keloid, 254
Allergy, 13
Alopecia in syphilis, 154
Alveolar abscess, 955
hare-lip, 943
process, affections of, 959
fracture of, 566
Amazia, 1128
Ambulatory treatment of fractures, 553
Ammonium urate calculus, 1482
Amœbic dysentery, surgical aspects of, 1284, 1683
hepatitis, 1286, 1684
liver-abscess, 1284, 1684
ulceration of the bowel, 1284, 1683
Ampulla of Vater, 1291, 1305
Amputation above knee, 1553
below knee, 1553
circular, 1551
elliptical, 1552
flap, 1552
for acute arthritis, 733
for aneurism, 332
for compound fractures, 560
for gangrene, 92
for sarcoma of bone, 683
for secondary hæmorrhage, 269
for senile gangrene, 93
for spreading traumatic gangrene, 116
for tuberculous disease of joints, 746, 779
general technique of, 1559
modified flap and circular, 1553
oval, 1552
racquet, 1552
site of, 1554
stumps, 1554
Amputations, 1550
special, 1561
Amygdaloid glands, 151

Amyloid degeneration of arteries, 56
disease, 56
kidney, 56
spleen, 56
Anæmia from focal sepsis, 58
in secondary syphilis, 152
secondary, after hæmorrhage, 28
splenic, 1325
Anæmic patients, operations on, 28
Anæsthesia, 1577
A.C.E. mixture, 1597
after-treatment of, 1584
avertin, 1503
barbiturates, 1503
carbonic acid gas in, 1599
chloroform, 1596
cocaine, 1603
cyclopropane, 1598
dolorosa, 822
due to nerve injuries, 386
endo-tracheal, 1600
ether, 1591
ethyl chloride, 1597
ethylene, 1598
evipan, 1503
freezing, 1602
gas and air, 1586
and oxygen, 1588
general, 1577
in reduction of dislocations, 694
in teeth extraction, 957
infiltration, 1603
local, 1602
nitrous oxide, 1585
paraldehyde, 1582
pentothal, 1583
premedication in, 1581, 1607
preparation for, 1581
pulmonary complications following, 1607
rectal, 1596
signs and stages of, 1577
spinal, 1603
splanchnic, 1606
surgical, 1578
Anæsthetics, basal, 1582
Analgesia *See* Anæsthesia
Anaphylaxis, 11
Anaplasia, 188
Anastomosis, end-to-end, of intestine, 1260
lateral, of intestine, 1261
Anatomical neck of humerus, fracture of, 577
tubercle, 244
wart, 244
Anel's operation for aneurism, 330
Aneurism, 323
by anastomosis, 369, 684
causes of, 323
circumscribed, 326
cirsoid, 369
consolidated, 328
diagnosis of, 327
diffuse, 328, 332
dissecting, 325
fusiform, 324
gangrene due to, 327
leaking, 328
of bone, 684
Aneurism, rupture of, 328
sacculated, 325
signs of, 326
spontaneous cure of, 328
structure of, 324
suppuration in, 328
traumatic, 323
treatment of, 329
varicose, 318
Aneurismal erosion of spine, 333
varix, 317
Aneurisms, special, 332
Angina of Ludwig, 63
pectoris, 434
Vincent's, 1043
Angioblastoma, 912
Angiomata, 214, 367
cavernous, 368
of liver, 1288
plexiform, 369
treatment of, 368
Angiomatosis, 913
Ångstrom unit, 304
Angular curvature of spine, 815
Ankle-joint, acute arthritis of, 735
amputation through. *See* Syme's amputation
ankylosis of, 768
dislocation of, 718
effusion into, 722
excision of, 787
fracture-dislocation of, 627
position of rest, 723
sprain of, 690
tuberculous disease of, 750
Ankyloglossia, 982
Ankylosis, 766
due to nerve injury, 387
false, 766
fibrous, 766
osseous, 767
treatment of, 768
Annular stricture of urethra, 1511
Anterior tibial artery, ligature of, 354
Antero-lateral tracts, section of, 425
Anthrax, 130
bacillus of, 5, 130
œdema, 131
spores, 130
Anti-anthrax serum, 11
Anti-bacterial sera, 11
Anti-bodies, 8
Anti-diphtheritic serum, 122
Anti-dysenteric serum, 11
Anti-gas-gangrene serum, 115
Anti-meningococcal serum, 11
Anti-peristalsis, 1379
Anti-pneumococcal serum, 11
Antiseptic dressings, 278
poultices, 294
treatment of wounds, 278
Antiseptics, 278
Anti-staphylococcal serum, 11
Anti-streptococcal serum, 11
in cellulitis, 61
in erysipelas, 121
in septicæmia, 75
Anti-tetanic serum, 115, 127
Anti-toxic sera, 10

Anti-toxin, 11
in appendicitis, 1278
Anti-venene, 244
Antro-choanal polyp, 1022
Antrum, mastoid, 1639
disease of, 1639
of jaw, affections of, 1026
anatomy of, 1026
chronic distension of, 1026
empyema of, 1027
hydrops of, 1031
puncture of, 1028
radiography of, 1028
suppuration in, 1027
transillumination of, 1027
tumours of, 1031, 1032
Antyllus's operation for aneurism, 330
Anuria in crush syndrome, 1702
treatment of, 1703
Anus, abscess of, 1405
absence of, 1403
artificial, 1257
epithelioma of, 1425
fissure of, 1412
imperforate, 1403
malformations of, 1402
prolapse of, 1420
pruritus of, 1413
stenosis of, 1403
syphilitic disease of, 153, 166, 1422
varicose veins of, 1414
Aorta, abdominal, aneurism of, 339
thoracic, aneurism of, 332
Aphasia, 882
Aphonia, 1111
Aphthous stomatitis, 981
Aplasia cranii congenita, 843
Apnœa. *See* Asphyxia
Apophysitis of the os calcis, 646
Appendicitis, 1262
abscess in, 1267, 1270
adhesions in, 1267
ætiology of, 1262
cæcum as affected by, 1267
catarrhal, 1266, 1268
clinical history of, 1268
complications of, 1268
diagnosis of, 1272
early operation in, 1274
fæcal concretions in, 1264
foreign bodies causing, 1264
injury a cause of, 1264
intestinal obstruction in, 1268
leucocytosis in, 29, 1271
obliterans, 1266
obstructive, 1271
operations for, 1276
ovaritis in, 1268
pathological anatomy of, 1265
peritoneal phenomena of, 1267
prognosis of, 1274
pylephlebitis in, 1278
quiescent interval in, 1271
rectal examination in, 1270
recurrent, 1272
relapsing, 1271
renal complications in, 1268
treatment of, 1274
Appendicostomy, 1256
Appendicular adhesions, 1267
colic, 1272
gastralgia, 1272
Appendix vermiformis, actinomycosis of, 1279
cancer of, 1280
concretions of, 1264
diverticula of, 1266
foreign bodies in, 1264
gangrene of, 1266
in hernial sac, 1336
intussusception of, 1278
necrosis of, 1266
situation of, 1263
stenosis of, 1264
suppuration of, 1266
tuberculosis of, 1279
tumours of, 1280
ulceration of, 1266
Apple-jelly nodules, 450
Arachnoid cyst, 230
Aran's irradiation theory, 851
Arches of foot, 511
Areola, abscess of, 1132
Argentaffine tumours, 1281
Argyll-Robertson pupil, 761
Arms, amputation through, 1564
deformities of, 494
Arterial encephalography, 937
hæmorrhage, 256, 266
primary, 266
reactionary, 266
secondary, 267
occlusion, 88, 92
spasm, 95
varix, 842
Arteries, anastomosis of, 317
calcareous degeneration of, 322
digital compression of, 262
inflammation of, 95, 318
injuries of, 314
ligature of, 250
rupture of, 314
suture of, 317
torsion of, 261
wounds of, 316
Arteriography, 335, 937
Arterio-sclerosis, 319
diffuse, 320
Arterio-venous anastomosis, 317
wounds, 317
Arteritis, 318
Artery, implication of main, in fractures, 551
Arthrectomy, 746
Arthritis, acute, of infants, 644
of special joints, 733
suppurative, 730
filarial, 1688
following bacillary dysentery, 1686
gonorrhœal, 142, 736
gouty, 738
neuropathic, 759
pneumococcal, 735
pyæmic, 728
rheumatoid, 752
tuberculous, 741
typhoid, 735
Arthrodesis, 531, 757
Arthroplasty, 759, 768

Arthrotomy, 745
Articular cartilages, destruction of, in acute arthritis, 730
in chronic osteo-arthritis, 753
in tuberculous disease, 742
Artificial limbs, 1553
pneumothorax, 1092
respiration, 1103
Aschheim-Zondek reaction, 226
Ascites, 1186
Ascitic tuberculous peritonitis, 1180
Aseptic treatment of wounds, 280
Asphyxia, 1102
Aspiration of empyema, 1076
of hæmothorax, 1081
of hydatid cyst, 1287
of joints, 726, 728
of liver abscess, 1286, 1685
of lung abscess, 1084
of pericardium, 1101
of pneumothorax, 1081
of tuberculous abscess, 177, 379
pneumonia, 58, 1607
Asthma, thymic, 1127
Astragalus, dislocation of, 719
excision of, 517, 720
fracture of, 632
in flat-foot, 520
in talipes, 513, 515
tuberculous disease of, 657
Astrocytoma, 913, 920
Atheroma, 319
Athetosis, 938
Atlas and axis, tuberculous disease of, 823
dislocation of, 796
Atony of bladder, 1488, 1492
Atrophic neuropathic arthritis, 760
pharyngitis, 1043
rhinitis, 1023
scirrhus, 1149
Atrophy of breast, 1136
of muscle, 385
of skull, 845
of testis, 1532, 1546
Atropine in anæsthesia, 1581
Auditory nerve, injury of, 408, 854
Auricles, accessory, 1636
Autogenous vaccines, 10
Automatic bladder of paraplegia, 437, 804
respiration in anæsthesia, 1579
Autonomic nervous system, 426
Avenoliths, 1228
Avertin, 1503
Avulsion of auriculo-temporal nerve, 1002
of limb, 239, 241
of phrenic nerve, 1093
Axillary abscess, 375
aneurism, 339
artery, ligature of, 347
cellulitis, 61
glands in cancer, 1149

B.I.P.P. *See* 'Bipp' treatment of wounds
Babinski's sign, 885
Bacillary dysentery, surgical complications of, 1683
Bacillus actinomycetem comitans, 182
aerogenes encapsulatus, 114
anthracis, 5, 130
Bacillus coli, 45, 1298, 1449, 1472
diphtheriæ, 121, 1015
fæcalis alkaligenes, 1682
fusiformis, 1043
Koch-Weeks, 1655
lepræ, 179
mallei, 75, 178
Morax-Axenfeld, 1655
œdematiens, 114
œdematis maligni, 114
of soft sore, 142
paratyphosus, 75
perfringens, 114
pyocyaneus, 45, 52, 53
sporogenes, 114
tetani, 5, 123
tuberculosis, 169
typhosus, 45, 75
Welchii, 45, 114
Bacteræmia, 73
Bacteria, aerobic and anaerobic, 2
conditions of life of, 2
effect of light on, 2
facultative, 2
hæmolytic, 4
in blood, 32, 58, 73, 77
infection by, 3
intoxication by, 3
mode of action of, 3
parasitic and saprophytic, 3
pathogenic, 5
pyogenic, 3, 42, 75
specific and non-specific, 5
spore-formation in, 2
virulence of, 4
Bacterial cultures, 4
products, 3
toxins, 3
Bacteriological examination of blood, 33
Bacteriology, 1, 75
Bacteriolysis, 11
Bacterium coli *See* Bacillus coli
paratyphosum, 45, 75
tularense, 132
typhosum, 45, 75, 1298
Bagdad boil, 1674
Baker's cysts, 740
Balanitis, 140, 1523
Balano-posthitis, 1523
Balkan beam, 615
Ball's operation for pruritus ani, 1413
Bandages, starch, 548
Bands, peritoneal, 1252
Barbiturates, 1503
Barium enema, 435, 1238, 1389
meal, 1190, 1223
platinocyanide, 301
Barlow's disease, 666
'Barrel' bandage for fractured mandible, 569
Bartholin's gland, abscess of, 1609
cyst of, 1610
Basal anæsthetics, 1582
meningitis, 899
Base of skull, fracture of, 851
Basilar artery, aneurism of, 335
Basophiles, 29
Bassini's operation for inguinal hernia, 1348
Baths, douche, 295

Baths, electric, 302
hot, 294
hot-air, 295
radiant-heat, 296
Russian, 295
sun, 299
Turkish, 295
B.C.G. vaccine, 175
Beaded ribs, 663
Bedsores, 100, 555
in spinal injuries, 796
Bellocq's sound, 1019
Bell's palsy, 406
Bennett's fracture of the thumb, 599
Berck board, 827
Berger's method of amputation, 1565
Bezold's abscess, 1640
Biceps cruris, tenotomy of, 472
cubiti, rupture of, 461
Bier's treatment by induced hyperæmia, 26
Bigelow's evacuator, 1486
method of reducing dislocated hip-joint, 709
Bilharzia hæmatobia, 1405, 1449
Bilharziasis, 1449, 1686
of rectum, 1405
Biliary colic, 1304
fistula, 1173
mud, 1305
passages, affections of, 1290
anatomy of, 1290
inflammation of, 1292
operations on, 1308
tumours of, 1310
Bi-malleolar fracture, 628
Biniodide of mercury, 278
'Bipp' treatment of wounds, 67, 70
Biskra button, 1674
Bismuth in syphilis, 161
Bites, snake, 244
Blackwater fever, 1681
Black widow spider, 243
Bladder, atony of, 1488, 1492
automatic, 437, 804
cancer of, 1478
congenital affections of, 1469
cystoscopy of, 1447, 1450, 1455, 1480, 1485
distension of, 1469, 1491
diverticula of, 1476
extroversion of, 1469
false incontinence of, 1491
foreign bodies in, 1472
functional derangements of, 1490
hernia of, 1336
in paraplegia, 437, 804
in prostatic disease, 1498
irrigation of, 1475
irritability of, 1473, 1474, 1476, 1479, 1484, 1498
methods of examining, 1468
overflow of, 1491
papilloma (villous tumour) of, 1477
paralysis of, 437, 804
perforation of, 1470
rupture of, 602, 1470
sacculi of, 1476
sarcoma of, 1478
Bladder, sounding of, 1485
stone in, 1482
traumatic affections of, 1470
tuberculosis of, 1476
tumours of, 1477
ulcer of, simple, 1477
Blank cartridge wounds, 123, 1696
Blanket suture, 237
Blast, anæsthesia in, 1699
effects of, 1699
treatment of, 1699
water-, 1699
Blastomata, 188, 189, 190
Blastomycosis, 1678
Bleeding time, 32
Blind boils, 444
external fistula, 1410
internal fistula, 1410
Blisters, 25
Blood, character of, in shock, 273
colour index of, 28
condition of, after hæmorrhage, 257
examination for bacteria, 33
examination of, in health and disease, 28
extravasation of, 256
in septicæmia, 33
in thrombosis, 356
test for incompatibility, 35
Blood-clot in thrombosis, 356
healing by organization of, 252
in fractures, 541
removal from brain, 891
Blood-count, differential, 29
in anæmia after hæmorrhage, 28
normal, 28
Blood-cultures, 32
Blood-cysts, 233, 1108
Blood-groups, 32, 34
classification of, 33
determination of, 34
Bloodless line of Brödel, 1462
Blood-letting, 24
Blood-plasma-transfusion. *See* Transfusion of blood-plasma
Blood-platelets, 31
Blood-pressure, fall of, after hæmorrhage, 257
in shock, 270, 273
Blood-serum-transfusion. *See* Transfusion of blood-serum
Blood-storage, 38
Blood-transfusion. *See* Transfusion of Blood
Blood-vessel tumours of brain, 912
Blood-vessels, operations on, 1102
'Blue-domed' cyst of breast, 1136
Bohler's method in leg-fractures, 627
stirrup, 553
traction apparatus, 581
Boil, 444
meatal, 1637, 1642
Bone, aneurism of, 684
carcinoma of, 684
caries of, 635, 636, 1012
contusion of, 534
cysts of, 672
diseases of, 634
growth of, 634

Bone, hydatid cysts of, 685
hypertrophy of, 674, 847
inflammation of, 635, 637, 651
injuries of, 534
necrosis of, 560, 635, 636
pulsating tumours of, 684
rachitic changes in, 663, 665
sarcoma of, 680
syphilis of, 511
tubercle of, 653
tumours of, 676
Bone-grafting, 686
double circular saw for, 687
varieties of graft, 688
Boomerang leg, 1673
Boric (boracic) acid, 278
fomentations, 294
Bougies, œsophageal, 1051
rectal, 1423
urethral, 1514
Bowel *See* Intestine
Bow-leg, 509, 510
Bowler's arm, 458
Boyle's anæsthesia outfit, 1588
Brachial aneurism, 339
artery, compression of, 262
ligature of, 348
birth palsy, 411
plexus, injuries of, 411
operations on, 412
pressure on, 411
Bradford's abduction splint, 778, 824
Brain, abscess of, 900
and its membranes, affections of, 862
embolus in, 360
foreign bodies, removal of, 887
general conditions of, after injuries, 873
glioma of, 913, 918
gumma of, 917
laceration of, 880
softening, yellow, of, 881
spreading œdema of, 881
wounds of, 880, 886, 1707
See also Cerebral, Cerebellar, Compression, and Concussion
Branchial carcinoma, 1106
clefts, 1105
cysts, 1106
fistulæ, 1105
Brasdor's operation for aneurism, 331
Braun's splint, 548, 613
Breast, abscess of, 1134
chronic, 1137
actinomycosis of, 1138
adeno-carcinoma of, 1153
atrophy of, 1136
cancer of, 1147
acinous, 1147
duct, 1152
encephaloid, 1151
en cuirasse, 1150
operation for, 1156
radium in treatment of, 1157
scirrhus, 1148
atrophic, 1149
cystic disease, general, of, 1136
cysto-adenoma of, 1145
cysts of, 1138
Breast, cysts of, 'blue-domed,' 1136
neoplastic, 1139
diffuse hypertrophy of, 1128
duct papilloma of, 1145
fat necrosis of, 1137
fibro-adenoma of, 1143
fibro-sarcoma of, 1147
intracanalicular adenoma of, 1143
mastitis of, acute, 1133
chronic interstitial, 1135
nipples, affections of, 1130
pericanalicular adenoma, 1143
sarcoma of, 1146
syphilitic affections of, 1133, 1138
tuberculous disease of, 1138
Bridled stricture of urethra, 1511
Broad ligament, cysts of, 1622
Broca's lobe, injury of, 882
Brodie's abscess, 642, 653
Bronchiectasis, 1085
multiple, 1100
Bronchiectatic abscess, 1099
Bronchobiliary fistula, 1307
Bronchocele. *See* Goitre
Bronchoscope, Jackson's, 1057
Bronchoscopy, 1057
in lung diseases, 1096
Bronchus, foreign bodies in, 1072
Brown-Séquard syndrome, 807
Bryant's splint, 723
test for dislocated shoulder, 699
line, 604
treatment of fractured femur, 616
Bubo, 143
climatic, 144, 1676
Bubonocele, 1339
'Bucket-handle' injury, 715
Buerger's disease, 95, 433
Bullet wounds, 1693
Bunion, 524
Burns, 104
acute toxæmia in, 105
after-treatment of, 111
causes of death from, 106
classification of, 104
electrical, 1705-1709
envelope-treatment of, 111
from X-rays, 303
gangrene in, 107
healing of, 106
necrosis of liver-cells following, 106
of eye, 1650
plasma-transfusion in, 108
serum-transfusion in, 108
shock in, 105
treatment of, 106
ulceration in, 107
of duodenum following, 106
war-, 1703-1709
treatment of, 1703, 1704, 1705
Bursa patellæ, 477
gluteal, 479
Bursæ, adventitious, 475
diseases of, 475
special, 477
in hammer-toe, 525
wounds of, 475
Bursal cysts in neck, 1108
Bursitis, acute simple, 476

Bursitis, chronic, 476
gouty, 477
suppurative, 476
syphilitic, 476
tuberculous, 476
Butcher's wart, 244
Buttonhole stitch, 237
wound of artery, 316

Cacosmia, 1027
Cæcoplication, 1262
Cæcostomy, 1256
Cæcum, cancer of, 1240
operation for, 1240
in appendicitis, 1267
tuberculous disease of, 1234
wounds of, 1705
Calabar swellings, 1691
Calcaneum. *See* Os calcis
Calcar femorale (Merkel), 604
Calcareous degeneration of arteries, 322
Calcification of fibro-myomata, 1613
of tuberculous glands, 377
Calcium lactate in chilblains, 449
in serum disease, 13
Calculous anuria, 1457, 1458
Calculus, alternating, 1483
biliary. *See* Gall-stones
encysted, 1483
fusible, 1483
intestinal, 1228
mulberry, 1482
oxalate of lime, 1482
pancreatic, 1316
phosphatic, 1483
prostatic, 1495
renal, 1456
salivary, 998
umbilical, 1172
ureteral, 1458
urethral, 1510
varieties of, 1482
vesical, 1482
causes of, 1483
diagnosis of, 1484
signs of, 1484
structure of, 1483
treatment of, 1486
in boys, 1490
in females, 1490
X-ray diagnosis of, 1458, 1485
xanthine, 1483
Caldwell-Luc operation, 1029
Callaway's test for dislocated shoulder, 698
Calliper, walking, for fractures, 616
Callus, 541
compression of nerves by, 544
definitive, 543
ensheathing, 542
internal, 542
permanent, 543
Calvarium, syphilis of, 659, 660
Calvé's disease, 780
Canal of Nuck, 229
Cancellous osteomas, 195
Cancer, 214
basal-celled, 218, 455
colloid, 222
columnar-celled, 220
Cancer, encephaloid, 221, 222, 1151
en cuirasse, 1150
glandular, 220
medullary, 222
nature of, 215
of antrum, 962
of appendix, 1280
of bile-ducts, 1311
of bladder, 1478
of bone, 684
of brain, 921
of branchial clefts, 1106
of breast, 1147
of cæcum, 1240
of colon, 1237, 1243
of cranium, 849
of gall-bladder, 1310
of gum, 960
of intestine, 1237
of kidney, 1465
of larynx, 1062
of lip, 951
of liver, 1288
of lung, 1099
of lymphatic glands, 382
of mandible, 971
of maxilla, 962
of nasal fossæ, 1031
of nipple, 1133
of nose, 1031
of œsophagus, 1052
of omentum, 1188
of ovary, 1621
of palate, 1013
of pancreas, 1318
of parotid, 974
of penis, 1524
of pharynx, 1045
of prostate, 1506
of pylorus, 1217
of rectum, 1425
of scrotum, 1549
of sebaceous glands. *See* Rodent ulcer
of spine, 832
of stomach, 1217
of submaxillary gland, 1005
of thyroid, 1125
of tongue, 988
of tonsil, 1041
of umbilicus, 1172
of uterus, 1616
of vulva, 1610
radium, use of, in, 311
scirrhus, 221
spheroidal-celled, 221
squamous-celled, 217
treatment of, 224
varieties of, 217
X-ray, 303
Cancrum oris, 116, 981, 1681
Capillary hæmorrhage, 256
lymphangioma, 372
Caput medusæ, 1172
Carbolic acid, 284
gangrene from, 108
Carbolized poultice, 294
Carbon arc light, 299
Carbonic acid gas in anæsthesia, 1599
snow, 368

Carbuncle, 445
of kidney, 1451
Carcinoid tumours of appendix, 1280
Carcinoma. *See* Cancer
sarcomatoides of thyroid, 1126
Carden's supracondyloid amputation of thigh, 1572
Cardiac massage, 1101
Cardiolysis, 1101
Cardiospasm, 436, 1052
Caries, 635, 636, 1012
fungosa, 637
necrotica, 637, 651, 654
of spine, 815
of temporal bone, 1642
sicca, 637
suppurativa, 637, 653
syphilitic, 636, 712
tuberculous, 636, 712
Carlsbad treatment, 1305
Carotid artery, abnormal arrangement of the branches of, 335
aneurism of, 334, 335
compression of, 262
hæmorrhage from, 263
ligature of, 343, 344
wounds of, 263
Carpal bones, dislocation of, 705
Carpus, fractures of, 596
Carrel-Dakin treatment of wounds, 69
Carr's splint, 594
Cartilages, laryngeal, necrosis of, 1060, 1061
semilunar, injuries of, 715
Caruncle, urethral, 1611
Caseation, 171
Castration, 1529, 1536, 1547
Cataphoresis, 303
Cataract, 1665
Catarrhal appendicitis, 1266, 1268
cholangitis, 1297
inflammation, 21
jaundice, 1297
stomatitis, 981
Catgut, 284
Catheter bicoudé, 1500
coudé, 1500
fever, 1515
life, 1500
Catheterism, dangers of, 1514
for enlarged prostate, 1500
for rupture of urethra, 1509
for stricture of urethra, 1514
in spinal injuries, 796
Catheterization of ureters, 1447, 1456
Catheters, method of introducing, 1500, 1514
sterilization of, 1513
varieties of, 1500, 1513
Cauda equina, injuries of, 805
tumours of, 838
Causalgia, 388, 438
Cauterization for hæmorrhage, 296
Cautery, diathermic, 297
uses of, 296
varieties of, 297
Cavernous angioma, 368
lymphangioma, 372
nævus, 368
sinus, injury of, 889
thrombosis of, 889
Cavum Retzii, 1489
Cell-nests, 218
Cellulitis, 42, 59, 1688
bacteriology of, 59
gangrenous, after extravasation of urine, 1521
of axilla, 61
of neck, 62
of orbit, 62
of scalp, 61
of scrotum, 1549
pelvic, 63, 1626
submaxillary, 63
treatment of, 60
Cellulo-cutaneous erysipelas, 120
Celluloid jackets, 828
plates, 867
Cementome, 200
Cephal-hæmatoma, 841
Cephal-hydrocele, traumatic, 850
Cerclage operation for fractured patella, 622
Cerebellum, abscess of, 902
tumours of, 913, 926
wounds of, 884
Cerebral abscess, 900
compression, 878
concussion, 274, 873
cortex, functions of, 883
decompression, 885
diplegia, 531
hæmorrhage, 893
irritation, 877
laceration, 880
œdema, 881
Cerebro-spinal fever, 894
Cerebro-spinal fluid, characters of, 867, 871
escape in fractures of base of skull, 854
in spinal disease, 834
removal of, 871
See also under Lumbar puncture
Cerebro-spinal rhinorrhœa, 854, 855
Cerumen in ear, 1637
Cervical abscess, 376, 378
caries, 819
fistula, median, 1108
glands, tuberculosis of, 377
plexus, injury to, 410
rib, 97, 485
spine, dislocation of, 797
fractures of, 794
tuberculous disease of, 817, 823
sprains, 788
Cervicitis, 1633
Cervix femoris, deformities of, 504, 506
division of, 769
fractures of, 604
uteri, cancer of, 1617
laceration of, 1633
Chalazion, 1652
Chancre, digital, 150
extragenital, 150, 950
hard, 149
Hunterian, 149
multiple, 150
of anus, 1422
of lip, 150, 950

Chancre of nipple, 150
of tongue, 986
of tonsil, 1041
of urethra, 150
relapsing, 152
soft. *See* Chancroid
syphilitic, 149
Chancroid, 142
Chaoul therapy, 305
Chapped lips, 951
Charcot's disease, 759
Chassaignac's tubercle, 262
Chauffeur's fracture, 590
Chaulmoogra preparations, 182
Cheilotomy, 757
Cheiragra, 738
Chemotherapy of cancer, 225
Cheyne-Stokes respiration, 878
Chilblains, 449
Child-birth, injuries from, 1633
Chimney-sweep's cancer, 1549
Chloramine-T, 280
Chloroform anæsthesia, 1596
as a cardiac poison, 1596
delayed poisoning by, 1585
method of administering, 1596
Cholangitis, catarrhal, 1297
infective, 1297
suppurative, 1284
Cholecystectomy, 1305, 1306, 1309
Cholecystenterostomy, 1310
Cholecystitis, 1298
acute, 1298
chronic, 1299
Cholecystography, 1291
Cholecystostomy, 1305, 1309
for pancreatitis, 1315, 1316
Cholecystotomy, 1309
Choledocho-duodenostomy, 1307
Choledochotomy, 1306
Cholelithiasis, 1301
Cholesteatoma, 908, 1642
Cholesterol, 1301, 1302
Cholesterosis of gall-bladder, 1301
Chondro-arthritis, syphilitic, 751
Chondrodystrophia fœtalis, 667
Chondroma, 194, 961, 970
Chopart's amputation, 1569
Chordee, 140
Chordoma, 195, 815, 913
Chordotomy, 425
median, 425
Chorion-epithelioma, 220, 1619
Choroid plexus, ablation of, 846
Choroido-retinitis, 155
Chromophile adenoma, 929
Chromophobe adenoma, 929
Chylous ascites, 1186, 1688
effusions, filarial, 1688, 1689
hydrocele, 373, 1544
Chyluria, 1688
Cicatrices. *See* Scars
Cicatricial stricture of intestine, 1235
Cigarette-smoker's disease, 433
Cinder-sifting movements of movable kidney, 1441
Circular amputation, 1551
Circumcision, 1522
Circumflex nerve, injury of, 413
Cirrhosis of the stomach, 1216
Cirsoid aneurism, 369, 842
Cisternal puncture, 870
Citrate method of transfusion, 37
Clairmont's operation, 702
Clamps, external, in fractures, 552
Clavicle, dislocation of, 697
fracture of, 573
Clavus (corn), 447
Claw-foot, 522
Claw-hands in leprosy, 181
in ulnar paralysis, 417
Cleft palate, 1005
operations for, 1008
tongue, 982
Clefts, branchial, affections of, 1105
Clicking hip, 506
Climatic bubo, 144, 1676
Cloaca, primitive, 1470
Clonorchiasis, 1686
Clostridium tetani. *See* Bacillus tetani
Welchii. *See* Bacillus Welchii
Clotting time, 31
Clover's inhaler for ether, 1594
Clovis Vincent's operation for brain abscess, 904
Club-foot, 512
Club-hand, 495
Coagulation necrosis, 17
of blood in aneurism, 328
in hæmorrhage, 258
Cocaine, uses of, 1603
Coccydynia, 603
Coccygeal tumours, 814
Coccyx, excision of, 603
fractures of, 603
Cochlea, disease of, 1643
Cock's peculiar tumour, 454
'Cock-up' splint, 289
Coffee, use of, in shock, 275, 277
Cold abscess, 54. *See also* Tuberculous abscess
in treatment of hæmorrhage, 261
of inflammation, 24
Colectomy, 1261
Coley's fluid, 209
Colic, appendicular, 1272
biliary, 1304
renal, 1457
type of intussusception, 1386
Colitis, 1229, 1683
Collapse, 272
Collar-stud abscess, 379, 651
Collateral circulation, 342
Colles's fracture, 591
law, 164
Colloid cancer, 222
goitre, 1115
Collosol manganese, 121, 445
Colon, cancer of, 1237, 1243
displacement of, 1250
idiopathic dilatation of, 1249
irrigation of, 1230
kinking of, 1250
operations on, 1245
sympathectomy of, 435, 1250
wounds of, 1704
Colostomy (Colotomy), 1257
closure of wound after, 1259

Colostomy (Colotomy), iliac, 1258
transverse, 1257
Colour-index, 28
Colporrhaphy, 1630
Colpotomy, posterior, 1626
Colt's treatment of aneurism, 332
Columbia paste, 307, 995
plaques, 1525
Coma, 878
diagnosis of, 879
in cerebral abscess, 902
compression, 878
tumour, 923
uræmic, 1451, 1458
Comminuted fracture, 537
Common bile-duct, anatomy of, 1291
stone in, 1305
carotid artery, aneurism of, 334
ligature of, 343
femoral artery, compression of, 263
ligature of, 351
iliac artery, ligature of, 349
Complement fixation test, 9, 134, 147
Composite odontomes, 200
Compound (open) dislocations, 692, 695
fractures, 556
amputations for, 560
involvement of joints in, 557
repair of, 557
septic osteomyelitis after, 557
treatment of, 559
Winnett Orr method in, 559
Compression, cerebral, 878
digital, in aneurism, 330, 340
of arteries, 262
fractures, 535
of nerves, 383
theory of fracture of base of skull, 851
Concentric hypertrophy of skull, 847
Concussion of brain, 274, 873
of nerves, 383
of spine, 799
Condyle of jaw, excision of, 977
fracture of, 568
Condyles, fracture of femoral, 618
Condylomata, 153
of anus, 1422
Congenital abnormalities of testis, 1526
absence of external ear, 1636
of patella, 506
of radius, 495
of uterus, 1631
of vagina, 1632
affections of bladder, 1469
of cranium, 843
of kidney, 1464
of knee, 506
atresia of ileum, 1390
cataract, 1665
cysts of kidney, 1440, 1463
of neck, 1107
deformities of fingers, 496
dislocation of hip, 500
of patella, 506
dislocations, 692
elevation of scapula, 493
hernia, 1333, 1341, 1359
hydrocele, 1539
Congenital hydronephrosis, 1444
hypertrophy of pylorus, 1217
induration of muscle, 483, 1107
malformations of breast, 1128
of intestine, 1224
of œsophagus, 1049
of rectum, 1402
of urethra, 1507
phimosis, 1521
sacral tumour, 814
sarcoma of kidney, 1464
scoliosis, 486
stenosis of duodenum, 1225
syphilis, 164, 1671
talipes, 512
torticollis, 483
umbilical fistulæ, 1173
hernia, 1359
Conical stump, 1558
Conjugate deviation of eyes, 883
Conjunctivitis, acute purulent, 1656
angular, 1655
epidemic, 1655
gonorrhœal, 142, 1656, 1657
muco-purulent, 1655
phlyctenular, 1659
Contraction, Dupuytren's, 498
of fingers, 498
of palmar fascia, 498
of plantar fascia, 513
of scars, 253
of sterno-mastoid, 483
Contracture, Volkmann's ischæmic, 464, 555
Contrecoup laceration of brain, 881
Contusions, 234
of abdominal walls, 1168
of arteries, 314
of bone, 534
of brachial plexus, 411
of cranium, 849
of intestine, 1226
of kidney, 1443
of lung, 1078
of muscles, 458
of nerves, 383
of testis, 1529
Convulsions, ether, 1592
in lesions of motor area, 882, 923
in meningitis, 896
in tetanus, 125
Cooper's, Astley, operation for ligature of external iliac artery, 350
reduction of elbow dislocation, 703
Coracoid process of scapula, fracture of, 576
'Cord-bladder,' 437, 804
Corneal ulcers, 1660
Corns, 447
in perforating ulcer, 448
Corona radiata, injury of, 883
Veneris, 153
Coronoid process of jaw, fracture of, 568
of ulna, fracture of, 588
Corpus striatum, injuries of, 883
Corrosive chemicals, effect of, 108
Costal cartilage, grafting of, 867
separation of, 572
Costo-transversectomy, 830
Counter-extension in fractures, 546
Counter-irritation, 25, 26

Cowper's glands, inflammation of, 143
Coxa plana, 779
valga, 506
vara, 504
Cracked lips, 951
nipples, 1130
Cranial bones, affections of. *See under* Calvarium, Cranium, Skull
Cranial lesions of seventh nerve, 854
nerves, affections of, 394
Cranio-cerebral topography, 862
Cranio-pharyngiomas, 911
Cranioplasty, 865
Craniotabes, 662, 845
Cranium. *See* also Skull
acquired affections of, 845
congenital affections of, 843
contusions of, 849
inflammatory affections of, 847
methods of opening, 863
syphilitic disease of, 848
traumatic affections of, 849
tuberculous disease of, 848
tumours of, 848
Credé's preventive treatment, 1657
Crepitus in fractures, 538
Cretinism, 1114
Crohn's disease, 1235
Crookes's tube, 300
Cross-bow incision for cerebellar tumours, 910
Crossed paralysis, 884
Croupous inflammation, 21
Crucial ligaments, rupture of, 714
Crus cerebri, wounds of, 884
Crush syndrome, 1701
treatment of, 1702
Crutch palsy, 555
Cubitus valgus, 494
varus, 494
Cultural methods of bacteriology, 33
Cuneiform osteotomy, 511, 760
Cupid's bow operation, 948
Curie (unit), 310
Curvature of spine, angular, 815
in hip disease, 772
in torticollis, 483
lateral, 486
rachitic, 486, 663
Cushing's cross-bow incision, 926
method of removing small bony fragments, 1717
suture, 1168
Cut throat, 1109
Cutaneous gumma, 157
leprosy, 180
syphilides, 152
tuberculosis, 449
Cyclopropane, 1598
Cylindroma, 199
Cystectomy, 1481
Cystic disease of breast, 1136
of kidney, 1463
duct, anatomy of, 1291
impaction of gall-stone in, 1304
hygroma, 229, 372, 1108
Cystine calculus, 1483
Cystitis, 1472
acute, 1473
Cystitis, chronic, 1474
irrigation for, 1475
in prostatic enlargement, 1498, 1499
in spinal affections 804
in stricture of urethra, 1512
Cysto-adenoma of breast, 1145
of ovary, 1620
Cystocele, 1629
Cysto-sarcoma of breast, 1145
Cystoscope, 1468
Cystoscopy, 1447, 1450, 1455, 1480, 1485
Cystotomy, suprapubic, 1475, 1505
Cysts, 226
acinous, 229, 1138
arachnoid, 230
Baker's, 740
blood, 233, 1108
branchial, 1106
bursal, 1108
dental, 199, 956
dentigerous, 199
dermoid, 225, 226, 814, 843, 937, 1107 1466, 1538, 1621
distension, 229
endothelial, 229
epithelial, 229
extraneous, 230
extravasation, 230
exudation, 229
hydatid, 231, 685, 1096, 1108, 111. 1139, 1287
implantation, 230
interacinous, 1139
involution, of breast, 1139
malignant, 1108
mucous, of lip, 951
multilocular, of jaw, 199
of bone, 672
of breast, 1138
of broad ligament, 1622
of canal of Nuck, 229
of degeneration, 233
of embryonic origin, 226
of funicular process, 229
of Gartner's duct, 229
of kidney, 1463
of Kobelt's tubes, 229
of labia, 1610
of mesentery, 1189
of Mullerian duct, 229
of neck, 1107
of ovary, 1620
'tarry-blood,' 1624
of pancreas, 1316
of salivary glands, 1108
of scalp, 843
of thyro-glossal duct, 1107
of thyroid, 1117
of Wolffian body, 228
parasitic. *See* Cysts, hydatid
parovarian, 229, 1622
pseudo-, 233
retention, 230, 1138
sebaceous, 454, 843, 1108
serous, 230, 1108, 1139, 1466
Czerny-Lembert suture, 1167

Dactylitis, tuberculous, 654, 656
Dakin's solution, 69, 279

Daufresne's solution, 279
Davis-Bovie electro-surgical unit, 297
'Dead spaces,' 286
Deafness from otitis media, 1638
Death, signs of, in tissues, 89
Decompression for cerebral injuries, 885
for cerebral tumour, 917, 925
in cancer of colon, 1237, 1243
Decortication, pulmonary, 1078
Deformities, 480
causes of, 480
in fractures, 538
in rickets, 663
of feet, 511
of fingers, 496
of hand, 495
of lower extremity, 500
of spine, 486
of upper extremity, 493
Delayed suture of wounds, 68
Delhi boil, 1674
Delirium, traumatic, 539
tremens, 540
Deltoid bursa, effusion in, 479
muscle, paralysis of, 411, 413
Dengue, 1681
Dental cysts, 199, 956
sepsis, 57, 954
ulcers of tongue, 985
Dentigerous cysts, 199
Depressed fracture of skull, 536, 855
Dermatitis maligna, 1130
of meatus, 1637, 1642
X-ray, 303
Dermoid cysts, 225, 226, 814, 843, 987, 1107, 1466
congenital, 227
of neck, 1107
of ovary, 226, 1621
of scalp, 843
of testis, 226, 1538
of tongue, 987
sacral, 814
Desmoid tumours, 191
'Dettol,' 279
Development of lips and palate, 944
Devine's enterotome, 1248
Diabetes, relation to pancreatitis, 1316
Diabetic gangrene, 94
Diaphragm, congenital defects in, 1364
in paraplegia, 806
wounds of, 1365
Diaphragmatic hernia, 1364
Diaphyseal aclasia, 197
Diaphysitis, acute, 639
Diathermic cautery, 297
Diathermy, 297, 303
electrode, 1505
for bladder tumours, 1481
Dichloramine-T, 861
Dick test, 9
Dietl's crises, 1442
Digital arrest of hæmorrhage, 259
chancre, 150
compression of arteries, 262
Dilatation, acute, of stomach, 1223
of cardiac orifice, 1052
of colon, idiopathic, 434, 1249
of œsophageal stricture, 1051, 1056
Dilatation of œsophageal stricture, retrograde, 1051
of rectum, 1423
of stomach, 1215, 1219
of urethral stricture, 1516
Dimpling in scirrhus cancer, 1148
Dinner-fork deformity, 592
Diphtheria, 121, 1024, 1060, 1172, 1610
Diphtheritic antitoxin, 122
Diplopia, 1664
Disarticulation at hip-joint, 1573
at knee-joint, 1572
at shoulder, 1564
Dislocations, 692
accompanying fracture, 554
complete, 692
complicated, 692
compound (open), 692, 695
congenital, 692
extension in, 695
fracture-dislocations, 692
incomplete (subluxation), 692
manipulation of, 694
of spine, 796
open, 692, 695
pathological, 692
recurring, 692, 702
reduction of, 694
signs of, 692
special, 696
traumatic, 692
treatment of, 694, 695
unreduced, 693
Displacement of kidney, 1440
of liver, 1281
of tendons, 459
of uterus, 1629
Dissecting aneurism, 325
Dissection wounds, 245
Distal ligature for aneurisms, 330
Distension of bladder with overflow, 1491
Diverticula of appendix, 1266
of bladder, 1476
of intestine, 1225
of œsophagus, 1049
Diverticulitis, 1230
Diverticulosis, 1233
Diverticulum of Meckel, 1224
'Dmelcos,' 144
Dorsalis pedis artery, ligature of, 354
Doyen's gag, 1040
Dracontiasis, 1691
Dracunculus medinensis, 1691
Drainage after operation, 286
in abdominal operations, 1163, 1176
of empyema, 1077
of gall-bladder, 1305
of wounds, 238
suction, of bladder, 1476
syphon, of bladder, 1476
Dress, surgeon's, 282
Dressings for operations, 286
'Drip' method of transfusion, 39
Drop-foot, 513
Drowned, treatment of the apparently, 1103
Ducrey's bacillus, 142
Duct cancer of breast, 1152
papilloma of breast, 1145

Dugas' test for dislocated shoulder, 698
Dumb-bell tumours, 203, 835
Duodenum, stenosis of, 1225
ulcer of. *See* Peptic ulcer
after burns, 105
Dupuytren's classification of burns, 104
contraction, 498
fracture, 628
Dura mater, inflammation of, 801, 894
tumours of, 906
Durham's tracheotomy tube, 1067
Dwarfism, renal, 667
Dyestuffs, elimination of, 1439
Dysentery, amœbic, 1284, 1683
bacillary, 1284, 1683
surgical aspects of tropical, 1683
Dyspeptic ulcer of tongue, 986
Dysphagia, 1048
in aneurism, thoracic, 333

Ear, affections of, 1634
examination of, 1634
examination of, in fractures of base, 853
external, affections of, 1636
middle, affections of, 1637
Eburnation of articular bones, 754
Ecchondroma, 194
Ecchondroses, 194, 754, 763, 764
Echinococcus, tænia, 231
Ecthyma, 155
Ectopia testis, 1528
vesicæ, 1469
Ectopic gestation. *See* Extra-uterine pregnancy
Ectrodactylism, 496
Eczema of external auditory meatus, 1637
of nipple, 1130
of scrotum, 1549
of umbilicus, 1172
varicose, 364
Eczematous ulcer, 83
Effleurage, 290
Egg-shell crackling, 676
Egyptian ophthalmia, 1658
Elastoplast treatment of ulcers, 84
Elbow-joint, acute arthritis of, 733
ankylosis of, 767
disarticulation of, 1564
dislocation at, 702
effusion into, 722
excision of, 785
position of rest, 723
tuberculous disease of, 748
Electrical burns, 1705-1709
skin lesions, 109
Electric baths, 302
current mark, 109
gangrene, 109, 112
metallization, 112
necrosis, 110
œdema, 112
Electricity as a diagnostic agent, 300
static, 303
uses of, in surgery, 300
Electrolysis, 303
Electro-surgery, 224, 297
Elephantiasis, 373, 1688
arabum, 373
filarial, 373
Elephantiasis, græcorum (leprosy), 179
non-filarial, 373
scroti, 373, 1689
Elimination of dyestuffs, 1439
Elliptical (oval) method of amputating, 1552
Embolectomy, 99, 1102
Emboli, 98, 358
effects of, 359
fat, 541
infective, 358
malignant, 358
parasitic, 359
pulmonary, 360
Embolic abscess, 76
arteritis, 318
gangrene, 98, 359
Embolism, 358
Embryoma, 1464, 1538
Emetine hydrochloride, 1286, 1684
Emphysema, surgical, 1079, 1110
Emphysematous gangrene, 113
Emprosthotonos, 125
Empyema, 1074
chronic, 1076, 1077
drainage of, 1077
of antrum, 1027
of gall-bladder, 1304
operations for, 1077
pulsating, 1075
scoliosis from, 486
spinal, 820
En bec de flute, fracture, 537
En glissade, hernia, 1343
Encephalocele, 844
Enchondroma, 195
Encysted abscess of breast, 1137
ascites, 1186
calculus, 1483
hernia, 1341
hydrocele of cord, 229, 1344, 1543
of epididymis, 1542
of round ligament, 229
of testis, 1543
Endarteritis, acute, 319
chronic, 95, 319, 321
obliterans, 95, 154, 321
syphilitic, 321
tuberculous, 321
Endemic hæmaturia, 1686
Endocarditis, infective, 142
Endometrioma of ovary, 1624
Endothelioma, 223, 972
Endotoxins, 3
Enemata, coffee, 275, 876, 1163
in treatment of chronic obstruction 1396, 1397
turpentine, 1168
use of, in diagnosis of intestinal obstruction, 1400
Entamœba histolytica, 1284, 1683
Enterectomy, 1259
Enteric group, fevers of the, 1682
intussusception, 1386
Enteritis, 1229
after strangulated hernia, 1377
X-ray, 304
Entero-anastomosis, 1260
Enterocele, 1335

Entero-epiplocele, 1335
Enteroliths, 1228
Enteroptosis, 1250
Enterostomy, 1255
Enterotomy, 1255
Entrance of air into veins, 269
Enucleation of prostate, 1501
of tonsils, 1039
Enuresis, 1491
Envelope treatment, 1704
Eosinophil adenoma, 929
Eosinophilia, 31
Ependymoma, 913
Epicritic sensation, 386
Epidemic conjunctivitis, 1655
parotitis, 996
Epididymectomy, 1535
Epididymis, abscess of, 1533
encysted hydrocele of, 1542
Epididymitis, acute, 1532
chronic, 1533
gonorrhœal, 1532
syphilitic, 154
tuberculous, 1534
Epiglottis in diseases of larynx, 1060
Epilepsy due to cysticercosis, 937
focal, 938
Jacksonian, 923
surgical treatment of, 937
traumatic, 938
Epiphyseal coxa vara, 504
Epiphyses in rickets, 665
of femur, 618
separation of, 537
Epiphysitis, 635, 651
syphilitic, 661
tuberculous, 655
Epiplocele, 1335
Epiploitis, 1188
Epiplopexy, operation of, for ascites, 1187
Epispadias, 1507
Epistaxis, 256, 1018
Epithelial odontoma, 199, 972
Epithelioma. *See* Cancer
after lupus, 451
of anus, 1425
of bladder, 1478
of cervix uteri, 1617
of ear, 1637
of gum, 960
of larynx, 1062
of lip, 951
of lower jaw, 971
of nipple, 1133
of œsophagus, 1052
of palate, 1013
of penis, 1524
of pharynx, 1045
of scalp, 843
of scars, 255
of scrotum, 1549
of tongue, 988
of tonsil, 1041
of umbilicus, 1173
of upper jaw, 962
of vulva, 1610
squamous, 217
Epityphlitis. *See* Appendicitis
Epoophoron, 228
Epulis, 959, 1012
giant-celled, 960
Erasion of joints. *See* Arthrectomy
Erb-Duchenne paralysis, 411
Ergot, gangrene from, 97
Erosion of cervix uteri, 1633
Erysipelas, 119
cellulo-cutaneous, 120
of scrotum, 120, 1549
treatment of, 121
of vulva, 1610
Erythema ab igne, 104
Erythremia crurum puellinum frigida, 645
Eserine in glaucoma, 1663
Espundia, 1675
'Esthiomène,' 1676
Ether anæsthesia, closed method, 1593
open method, 1594
rash, 1592
rectal method, 1596
with gas, 1593
Ethmoid, diseases of the, 1029
Ethyl chloride as a general anæsthetic, 1597
as a local anæsthetic, 1602
Ethylene, 1598
Eusol, 279
Eustachian catheter, 1636
Evacuator for removal of stone from bladder, 1487
use of, in diagnosis of stone, 1485
Ewald test meal, 1192
Ewing's sarcoma, 645, 684
Excision of ankle-joint, 787
of astragalus, 517, 720
of coccyx, 603
of condyle of jaw, 977
of elbow, 785
of eyeball, 1652
of gastric ulcer, 1202
of head of metatarsal, 524
of radius, 704
of hip-joint, 786
of joints, 746, 768, 783
of knee-joint, 786
of larynx, 1064
of lower jaw, 973
of rectum, 1430
of rib, 1077
of shoulder, 784
of stomach, 1208
of stricture of urethra, 1517
of tongue, 991
of upper jaw, 966
wrist, 786
Exercises, active, remedial, 292
Exomphalos, 1359
Exophthalmic goitre, 1121
Exophthalmos, 1122
pulsating, 337
Exostosis bursata, 196
cancellous, 195
ivory, 197
of ear, 1637
subungual, 196
Exotoxins, 3
Expansile impulse in aneurisms, 328

Extension in amputation stumps, 1551
in hip-joint disease, 778
in reduction of dislocations, 695
of fractures, 545, 613
External carotid, aneurism of, 335
ligature of, 344
ear, deformities of, 1636
genitalia, injuries to, 1529, 1632
iliac artery, aneurism of, 340
ligature of, 350
popliteal nerves, injuries of, 421
urethrotomy, 1518
Extirpation of aneurism, 329
of larynx, 1064
of tuberculous glands, 379
Extracapsular fracture of femur, 608
Extracranial lesions of seventh nerve, 406
Extraction of teeth, 957
Extradural abscess, 894, 1644
hæmorrhage, 878
Extragenital chancres, 150
Extramedullary hæmorrhage, spinal, 801
Extra-parietal hernia, 1343
Extra-peritoneal rupture of bladder, 602, 1471
of tubal gestation, 1628
Extra-uterine pregnancy, 1627
treatment of, 1628
Extravasation cysts, 230
of blood, 256
of urine, 1492, 1515, 1520
Extrinsic cancer of larynx, 1062
Extroversion of bladder, 1469
Eye, burns and scalds of, 1650
contusions of, 1650
foreign bodies in, 1647
injuries to, 1647
penetrating wounds of, 1650
rupture of, 1650
sympathetic disease of, 1651
Eyeball, excision of, 1652

Facial artery, compression of, 262
ligature of, 346
cleft, oblique, 948
nerve, affections of, 405
operations on, 407, 408
paralysis, 405, 854, 1642
tic, 408
Facies hippocratica, 1176, 1371
Facultative parasites, 2
Fæcal concretions in appendicitis, 1264
fistula, 1253
impaction, 1395
vomiting, 1371, 1379
Fæces, retention of, 800
Fallopian tube, malformations of, 1631
in hernial sac, 1337
tuberculosis of, 1626
Farabœuf's amputation of fingers, 1562
of great toe, 1567
Faradic current in diagnosis, 300
in treatment, 302
Farcy-buds. *See* Glanders
Fat embolism, 541
necrosis of breast, 1137
Fatty hernia, 193
tumours. *See* Lipoma
Feet, deformities of, 511
Female genital tract, infections of, 1624
Femoral artery, aneurism of, 340
compression of, 263
ligature of, 351, 352
hernia, 1354
strangulated, 1378
thrombosis, 358
Femur, abscess (tuberculous) of neck of, 770
cervix, fracture of, 604
compound fractures of, 613
condyles, fracture of, 618
fractures of, 603
treatment of, 605, 610, 613
intertrochanteric fracture of, 608
lower end, fracture of, 612
middle, fracture of, 611
rachitic deformity of, 510
shaft, fracture of, 611
upper end, fracture of, 604, 611
Fever, 23
catheter, 1515
fracture, 539
hectic, 55
scarlet, 1037
Fevers, tropical, surgical complications of, 1681
Fibrillation of cartilage, 754
Fibro-adenoma of breast, 1143
Fibro-cystic disease of jaw, 199, 972
Fibroid bursitis, 476
Fibroids, uterine, 1612
degeneration in, 1613
operations for, 1614
Fibromata, 190, 970
Fibromatosis of stomach, 1216
Fibro-myoma, 202, 1612
Fibro-sarcoma, 208, 1147
Fibrosis of appendix, 1266
of tuberculous nodules, 171
uteri, 1616
Fibrositis, 464
gonorrhœal, 142
Fibrous ankylosis, 766
odontome, 200
stricture of œsophagus, 1051
of rectum, 1422
union of fractures, 562
Fibula, fractures of, 625
rachitic, 511
Fifth nerve, affections of, 395
Filaria bancrofti, 1687
infections, surgical aspects of, 1688
sanguinis hominis, 373
Filarial elephantiasis, 373, 1688
fever, 1688
periodicity, 1688
Filariasis, 1687
Filiform bougies, 1514
Fingers, adhesions of tendons of, 248, 468
amputation of, 1561
clubbed, 674
congenital contraction of, 498
deformities of, 496
division of tendons of, 462
mallet, 463, 498
sloughing of tendons of, 247
webbed, 497

Finsen-light in lupus, 299, 451
First aid in fractures, 544
intention, healing by, 250
Fish-hook wounds, 243
Fissure of Rolando, 862
of Sylvius, 863
Fissured fractures, 536
of skull, 850
Fistula, 54
aerial, 1111
biliary, 1470
bimucosa, 1180, 1253
blind, 1410
branchial, 1105
bronchial, 1077, 1078
broncho-biliary, 1307
cervical, median, 1108
fæcal, 1253
horseshoe, 1408
in ano, 1408
œsophageal, 1111
pancreatic, 1313
penile, 140
perineal, 1512, 1520
perirectal, 1405
pharyngeal, 1111
pleural, 1077
recto-vaginal, 1427, 1633
recto vesical, 1427, 1428, 1480
salivary, 1000
scrotal, 1549
umbilical, 1173, 1470
urinary, 1173, 1444, 1470
vesico-vaginal, 1633
Fixation of limbs, prolonged, 288
Flail arm, 564
Flap method of amputation, 1552
Flaps, sloughing of, 1557
Flat-foot, 519
gonorrhœal, 142
Flavine, 71
Floating kidney, 1440
spleen, 1320
Fluctuation, 50
'Foamy' cells, 1301
Focal sepsis, 57
Fœtal adenoma, 1125
Follicular odontome, 199
Fomentations, 294
Fontanelles in rickets, 663
Foot, amputation of, 1569
arches of the, 511
deformities of, 511
painful lipoma of, 193
perforating ulcer of, 447
Foot-drop, 513
Foramen magnum, fracture into, 852
Forcipressure in hæmorrhage, 261
Forearm, amputation through, 1564
fracture of bones of, 595
Foreign bodies, cysts in connection with, 233
in appendix, 1264
in bladder, 1472
in brain, 878, 887
in bronchus, 1072
in ear, 1637
in eye, 1647
in intestine, 1228, 1390
Foreign bodies in larynx, 1071
in nose, 1018
in œsophagus, 1050
in rectum, 1404
in stomach, 1229
in trachea, 1072
in urethra, 1509
Forequarter amputation, 1565
Forster's operation, 425
Fourth nerve, paralysis of, 395
Fowler's position in peritonitis, 1176
Fractional test-meal, 1193
Fracture-dislocation of ankle, 627
of spine, 793
Fractures, 534
ambulatory treatment of, 553
causes of, 535
closed (simple), 535
comminution of, 537, 543
complete, 536
complicated, 537
complications of, 554
during treatment, 555
crepitus in, 538
deformity in, 538
dislocation with, 554
disunited, 565
extension in treatment of, 545
first aid in, 544
fissured, 536
fixation of, 546
green-stick, 536
impacted, 537
implication of joints in, 554
of main artery in, 554
incomplete, 536
infection in, 556
intra-uterine, 535
longitudinal, 537
massage in treatment of, 552
multiple, 537
nerves, involvement of, in, 555
oblique, 536
obstetric, 535
open (compound), 535, 556, 1700
operative treatment of, 548
plating in, 551
predisposing causes of, 534
radiography in diagnosis of, 539, 546
repair of, 541, 557
signs of, 538
simple (closed), 535
special, 565
spiral, 536
spontaneous, 534
subperiosteal, 536
transverse, 536
treatment of, 544, 559, 563
union of, 541
ununited, 561
varieties of, 535
vicious union of, 565
See also Special fractures
Fragilitas ossium, 668
Framboesia (yaws), 1671
Freezing for anæsthesia, 1602
Freiberg's disease, 646
Freyer's prostatectomy, 1503
'Frog-nose,' 1016

Frog's foot, inflammation in, 14
Fröhlich's syndrome, 930
Frontal bone, fracture of, 1030
lobes of brain, abscess in, 901
injuries of, 882
puncture for ventriculography, 869
sinuses, affections of, 1030
Frost-bite, 103
Functional derangements of bladder, 1490
Funicular process, cyst from, 229
Funiculitis, filarial, 1688
Furuncle, 444

Gaertner's duct, cyst of, 229
Galactocele, 1138
Gall-bladder, affections of, 1290
anatomy of, 1290
colic, 1290
drainage of, 1305
empyema of, 1304
excision of, 1305, 1306, 1309
rupture of, 1292
torsion of, 1290, 1312
tumours of, 1310
Gallie's fascial sutures for hernia, 1352
Gall-stones, 1228, 1301
impaction of, 1304
in intestine, 1228
treatment for, 1305
Galvanic electricity in diagnosis, 300
in treatment, 302
Galvano-cautery, 297
Games, remedial value of, 294
Gamma rays, 307
Ganglion, 469
compound palmar, 470
Ganglionectomy, sympathetic, 441, 442
Ganglio-neuroma, 203, 835
Gangosa, 1672
Gangrene, 80, 88
acute emphysematous, 113
amputation for, 102
diabetic, 94
dry, 89
embolic, 98, 359
following burns, 1707, 1708
from aneurism, 327
from arterial occlusion, 88, 92, 98
from cervical rib, 97
from chemical agencies, 112
from ergot, 97
from fractures, 555
from frost-bite, 103
from kala-azar, 1681
from ligature of arteries, 102, 342
from physical and chemical causes, 88, 103
from radiation, 113
from rupture of arteries, 102
from splint-pressure, 100, 556
from strangulation, 102
gas, 113
hospital, 116
infective, 88, 113
in intussusception, 1385
line of separation in, 91
moist, 89
of appendix, 1266
of intestine in hernia, 1370
Gangrene of lung, 1084
post-operational, 101
senile, 92
signs of local death in, 89
traumatic, 88, 99
treatment of, 91, 102
varieties of, 92
Gangrenous cholecystitis, 1298
periproctitis, 1408
stomatitis, 116, 981, 1681
vulvitis, 140, 1609
Gartner's duct, cyst of, 229
Gas gangrene, 113
amputation in, 116
Gasserian ganglion, injection of, 401
Gastralgia, appendicular, 1272
Gastrectomy, partial, 1208
Gastric juice in cancer of stomach, 1220
residuum, examination of, 1191
ulcer and its effects. *See* Peptic ulcer
Gastritis, phlegmonous, 1194
Gastrocnemius, rupture of, 462
Gastro-duodenostomy (Finney's operation), 1205
Gastro-enterostomy for cancer of stomach, 1221
for duodenal ulcer, 1203
for hour-glass stomach, 1215
for peptic ulcer, 1203
for pyloric cancer, 1221
for ulcer of stomach, 1202
hæmorrhage after, 1205
vomiting after, 1205
Gastro-jejunostomy, 1203
Gastroptosis, 1222
Gastroscopy, 1191
Gastrostomy, 1221
Gastrotomy, 1194
Gaucher's disease, 1325
Gauvain's test for hip disease, 774
'Gelenkmaus,' 765
Genital organs (female), diseases of, 1609
injuries of, 1632
Genu recurvatum, 509
valgum, 507
varum, 509
Gerlach's valve, 1264
Giant-cell tumour, 200, 676
Giant cells in myeloma, 200
in tubercle, 171
Gigantism, 672, 929
Gigli's saw, 864
Gillies' operation for cleft palate, 1008
on lip, 948
Gingivitis, 57, 955, 959
Giraldés, organ of, 228
Girdle pain, 22, 419, 805
Glanders, 178
Glands, lymphatic, affections of, 375
syphilitic, 153
tuberculous, 376
Glass wounds, 243
Glaucoma, 1662
chronic, 1664
Glazed red tongue, 984
Gleet, 135
Glénard's disease, 1222, 1250, 1281, 1320
Gliomata, 202
of brain, 913, 918

Globus hystericus, 1052
Glossitis, 983, 984
acute, 983
chronic streptococcal, 984
superficial, 984
Glosso-pharyngeal nerve, affections of, 409
Glossy skin, 388
Glottis, acute œdema of, 1059
Glover's stitch, 237
Glucose infusion, 75
Gluteal artery, aneurism of, 340
hæmorrhage from, 264
bursa, disease of, 479
Glycosuria. *See* Diabetes
Goitre, 1114
adolescent, 1115
causes of, 1115, 1122
colloid, 1115
exophthalmic, 1121
malignant, 1125
nodular, 1116
operation for, 1119, 1124
parenchymatous, 1116
physiological, 1114
simple, 1116
toxic, 1121, 1123
treatment of, 1119
Gold treatment for rheumatoid arthritis, 753
Gonococcus, 5, 133
Gonorrhœa, 133
arthritis in, 142, 736
chronic, 135
diagnosis of, 134
diathermy in, 139
in women, 140
prophylaxis of, 137
stricture from, 136
treatment of, 137
vaccine treatment of, 139
Gonorrhœal conjunctivitis, 142, 1656, 1657
endocarditis, 142
epididymitis, 1532
fibrositis, 142
flat-foot, 142
peritonitis, 141
proctitis, 141
prostatitis, 1493
pyæmia, 142
rheumatism of spine, 831
rhinitis, 141
salpingitis, 141
scleritis, 142
urethritis, 135
vaginitis, 140
vulvitis, 140
warts, 140
Gottstein's curette, 1035
Goundou, 1673
Gout, acute, 738
Gouty arthritis, 738
deposits in bursæ, 477
'toph,' 738
Graddy's expression forceps, 1653
Gradual dilatation of stricture of urethra, 1516
Graefe's, von, operation for cataract, 1667
Grafts, bone, 686
Grafts, fat, 389
nerve, 390
Granulation tissue, 48
Granuloma venereum, 1675
Granulomata, cerebral, 914
tropical, 1675, 1677
Graves' disease, 1121
Gravitation paraplegia, 801
Great sciatic nerve, injuries of, 419
operation on, 419
Great toe, amputation of, 1567
Greenfield's cerebro-spinal manometer, 871
Green-stick fracture, 536
Grouping of blood, 32, 34
Guillotine, tonsillar, 1040
Guinea-worm disease, 1691
Gum-arabic in shock, 276
Gumboil, 954
Gumma, 155
cutaneous, 157
of bone, 659, 661, 830
of brain, 917
of larynx, 1060
of lip, 951
of liver, 1289
of muscles, 465
of pharynx, 1044
of rectum, 1422
of spine, 661
of sternum, 660
of testis, 1536
of tongue, 986
of tonsil, 1041
perisynovial, 751
subcutaneous, 157
subperiosteal, 659
Gummatous osteomyelitis, 661
ulcer, 156
Gums, affections of, 959
Gunning's interdental splint, 570
Gunshot wounds, excision of track of, 67
of skull, 860
tetanus in, 123
Gutter fracture of skull, 857
operation on bone, 648
Gymnasium exercises, 293
Gynecomastia, 1128

Hæmangioblastoma, 912
Hæmangioma, 214
Hæmatemesis, 256
Hæmatocele in ectopic gestation, 1628
of cord, 1345, 1531
of tunica vaginalis, 1530
Hæmatocolpos, 1632
Hæmatoma, 234
of ear, 1636
of scalp, 841
pulsating, 315
Hæmatometra, 1632
Hæmatomyelia, 800
Hæmatorachis, 801
Hæmatosalpinx, 1627, 1632
Hæmaturia, 257, 1444, 1455, 1457, 1458, 1464, 1465, 1476, 1477, 1479
Hæmoconcentration, estimation of, 108
Hæmoglobin, effect of hæmorrhage on, 28
Hæmolytic groups, 4, 34
streptococci, 43

Hæmophilia, 269
joints in, 763
Hæmoplastin, 270
Hæmo-pneumothorax, 1079
Hæmoptysis, 256, 1079, 1080
from blast, 1699
Hæmorrhage, 256
arterial, 256, 266
blood examination after, 28
capillary, 256
concealed, 257
effects of, 257
fatal, 28, 257
leucocytosis after, 29
natural arrest of, 258
reactionary, 266
saline infusion in, 265
secondary, 267
transfusion of blood after, 270
treatment of, 259, 265
venous, 256
Hæmorrhagic infarct, 76
pancreatitis, 1314
rickets, 666
Hæmorrhoids, 1413
causes of, 1413
complications of, 1416
diagnosis of, 1416
injection treatment of, 1417
operation for, 1418
Hæmostasis, 286
Hæmostatic cautery, 261
forceps, 261
Hæmostatics, 261
Hæmothorax, 1079
surgical treatment of, 1081
Hallux rigidus (*Hallux flexus*), 523
valgus, 523
Halstead's intradermic stitch, 237
operation for hernia, 1351
suture, intestinal, 1167
Ham splint, 620
Hamilton's test for dislocated shoulder, 699
Hammer-nose, 1017
Hammer-toe, 524
Hammond's wire splint for fracture of lower jaw, 570
Hand, amputation of, 1563
deformities of, 495
Hands, sterilization of, 282
Hang-nail, 452
'Hard-bake spleen,' 380
Hard chancre, 149
fibroma, 190
Hare-lip, 942
operations for, 945, 947
Harrington's solution, 285
Harman's spud, 1648
Harris' bladder retractor, 1502
boomerang needle, 1503
prostatectomy, 1503
Hartmann's pouch, 1306
Hashimoto's disease, 1113
Head injuries *See* Fractures of skull *and* Injuries of brain
war wounds of, 1706
Healing by granulation, 250
by organization of blood-clot, 252
Healing by primary union, 250
by second intention, 250
of detached portions of body, 252
under a scab, 251
Hearing, investigation of, 1634
Heart, massage of, 1100
wounds of, 1100
Heat as a hæmostatic, 261
as a sterilizing agent, 280
dry, 295
in inflammation, 21, 25
in shock, 275, 296
moist, 294
remedial uses of, 294
Heat-stroke, 879
Hectic fever, 55
Heels, painful, 526
Heliotherapy, 299
Hemianæsthesia in head injuries, 884
Hemianopia (hemiopia), 930
Hemiatrophy of tongue, 982
Hemiplegia after head injuries, 884
Hepatic abscess. *See* Abscess of liver
duct, anatomy of, 1291
Hepatitis, amœbic, 1286, 1684
Hepatoptosis, 1281
Hernia, 1333
acquired, 1334
ætiology of, 1333
bladder in, 1336
bubonocele, 1339
cæcum in, 1335
cerebri, 939
congenital, 1333, 1341, 1359
contents of, 1335
coverings of, 1335
diaphragmatic, 1364
duodenal, 1381
en bissac, 1374
encysted, 1341
en glissade, 1343
enterocele, 1335
epiplocele, 1335
extraparietal, 1343
extraperitoneal, 1336
Fallopian tube in, 1337
fatty, 193, 1362
femoral, 1354
strangulated, 1378
funicular, 1341
infantile, 1341
inflammation of, 1368
inguinal, 1339
acquired, 1340
congenital, 1341
direct, 1342
oblique, 1339
radical cure of, 1347
strangulated, 1377
inguinalis ante-vesicalis, 1342
intra-iliaca, 1342
injection treatment of, 1354
internal, 1381, 1384
interparietal, 1343
interstitial, 1342
intraparietal, 1342
intraperitoneal, 1337
irreducibility of, 1366
Littré's, 1369

Hernia, lumbar, 1364
Maydl's, 1373
obstructed, 1368
obturator, 1365
of lung, 1082
omental, 1335
operation for radical cure of, 1347, 1357
Bassini's, 1348
Gallie's, 1352
Halstead's, 1351
Lotheissen's, 1359
Mayo's, 1361
ovary in, 1337
paraperitoneal, 1336
post-operative, 1278, 1363
properitoneal, 1342
pudendal, 1366
pudic, 1366
recurrent, 1354
reduction *en bloc*, 1374
Richter's, 1369, 1372
sac of, 1334
adhesions in, 1335
hydrocele of, 1335
sciatic, 1366
scrotal, 1339
signs of, 1338, 1344
strangulated, 1368
after-treatment, 1376
gangrene of bowel in, 1370
operative treatment of, 1374
pathological effects of, 1369
post-operative complications of, 1377
signs and symptoms of, 1371
taxis in, 1373
treatment of, 1373
structure of, 1334
testis, 1530, 1532, 1534, 1537
traumatic, 1334
treatment of, 1339, 1345
trusses for, 1345, 1356
umbilical, 1359
operations for, 1360
vaginal, 1341, 1366
ventral, 1278, 1362
vermiform appendix in, 1336
Herpes labialis, 951
preputialis, 1523
zoster, 419
Herpetic vulvitis, 1610
Hesselbach's triangle, 1342
Hexamine in cystitis, 1474, 1475
Hey's amputation, 1569
saw, 865
Hey Groves's method for fractured clavicle, 575
Hibbs's operation, 829
High-frequency current, 303
High-voltage therapy, 305
Hilton's method of opening abscesses, 53
Hip, clicking, 506
disease, 769
joint, acute arthritis of, 733
ankylosis of, 767, 769
disarticulation at, 1573
dislocation of, congenital, 500
traumatic, 706
Hip joint, effusion into, 722
excision of, 786
osteo-arthritis of, 756
osteo-chondritis deformans of, 779
position of rest, 723
scissor-like deformity of, 767
tuberculous disease of, 749, 769
typhoid disease of, 735
Hirschsprung's disease, 434, 1249
Histamine in shock, 273
Histrionic spasm, 408
Hodgen's splint, 547
Hodgkin's disease, 379
Hollow-foot, 522
Homonymous hemianopia, 883
Horn, sebaceous, 1524
Horseshoe fistula, 1408
kidney, 1440
Horsley's wax, 855, 863
Hot-air bath in diagnosis, 432
Hot bath, 294
Hour-glass stomach, 1214
Housemaid's knee, 477
Hudson's brace, 864
forceps, 809
Humerus, fracture of shaft, 581
with dislocation of head, 580
fractures of, 577
of anatomical neck, 577
of surgical neck, 578
of condyles, 586
of lower end, 584
of upper end, 577
ossification of, 587
separation of great tuberosity, 579
of lower epiphysis, 587
of upper epiphysis, 579
T-shaped fractures of, 585
transverse supracondyloid fracture of, 584
ununited fracture of, 583
Y-shaped fracture of, 585
'Hummy,' 475
Hunch- or hump-back, 819
Hunterian chancre, 149
Hunter's canal, ligature of femoral artery in, 352
operation for aneurism, 330
Hutchinson's teeth, 167
wart, 153, 986
Hydatid cysts, 231, 685, 1096, 1108, 1114, 1139, 1287
eosinophilia in, 233
of bone, 231, 685
of kidney, 1466
of liver, 1287
of lung, 1096
of neck, 1108
of pleura, 1078
of Morgagni, 229
Hydatidiform mole, 1619
Hydrarthrosis, 739, 740
Hydrencephalocele, 844
Hydrocele, 1539
acquired, 1539
acute, 1539
bilocular, 1539
chylous, 373, 1544

Hydrocele, congenital, 1539
diffuse, 1544
encysted, 229, 1344, 1542, 1543
of epididymis, 1542
infantile, 1539
of breast, 1139
of cord, 229, 1344, 1543
of hernial sac, 1335
of neck, 229
of round ligament, 229, 1543
of tunica vaginalis, 1532
radical cure of, 1541
tapping of, 1542
tropical, 1689
vaginal, 1539
Hydrocephalus, 845
Hydronephrosis, 1444, 1457
acquired, 1445
closed, 1445
congenital, 1444
idiopathic, 1445
nervous, 1445
open, 1445
Hydrophobia, 128
Hydrops antri, 1031
articuli, 739, 740
of appendix, 1266
of gall-bladder, 1304
tuberculous, 743
Hydrosalpinx, 1626
Hygroma, cystic, 229, 372, 1108
Hymen, imperforate, 1632
Hyoid bone, fracture of, 571
Hyperæmia, induced, 25
Hyperæsthesia in appendicitis, 1269
in paraplegia, 805
Hyperchlorhydria, 1193
Hyperextension treatment of spinal lesions, 793, 827
Hypernephroma, 223, 1465
Hyperostoses, 197
Hyperpituitarism, 673, 929
Hyperpyrexia in cerebral compression, 878
in tetanus, 125
Hypertonic salt solution, 72, 877
Hypertrophic osteo-arthropathy, 674
rhinitis, 1020
Hypertrophy of breasts, 1128
of gums, 959
of lips, 950
of prostate, 1495
of pylorus, 1215
of scar tissue, 254
of tonsils, 1039
Hypochlorous acid and hypochlorites, 279
Hypodermoclysis, 266
Hypoglossal nerve, injury of, 410
Hypophyseal duct tumours, 911
Hypopituitarism, 929
Hypopion ulcer, 1660
Hypospadias, 1507
Hypostatic pneumonia in fractures, 555
Hypothyroidism, 1114
Hypotonic salt solution, 72
Hysterectomy, abdominal, 1615, 1618
partial, 1614
total, 1614
Hysteria in spinal injuries, 803
Hysterical stricture of œsophagus, 1052
Hysterotomy, vaginal, 1614

Ichthyosis linguæ, 984
Icterus. *See* Jaundice
Idiopathic dilatation of colon, 434, 1249
erysipelas, 119
psathyrosis, 667
tetanus, 124
Ileitis, regional, 1235
Ileo-cæcal intussusception, 1386
Ileo-colic intussusception, 1386
Ileostomy, 1255
Iliac aneurism, 340
colostomy, 1258
vessels, ligature of, 349
Immunity, 5
acquired, 6
active, 6
mechanism of, 8
natural, 6
passive, 7
Immuno-transfusion, 39
Impacted calculus in ureter, 1458
fæces, 1395
fracture, 537
gall-stones, 1304
urethral calculus, 1510
Impaction of foreign bodies in bowel, 1228 1390
Imperforate anus, 1403
hymen, 1632
Implantation cysts, 230
lateral, of intestine, 1261
of ureters, 1470, 1481
Incontinence of urine, 1491
false, 1491
Indian clubs, use of, 293
ink method of demonstrating spirochætæ, 146
operation of rhinoplasty, 1016
Indigo-carmine test of renal function, 1439
Induced hyperæmia, 25
Infantile hernia, 1341
hydrocele, 1539
paralysis, 527
scurvy, 666
umbilical hernia, 1359
Infarct, 1453 *See also* Emboli
hæmorrhagic, 76, 360
Infection, 3
of open fractures, 556
of wounds, 64
post-operative, 64
Infections, pyogenic, 42
Infective arteritis, 318
diseases, specific, 119
emboli, 358
endocarditis, 142
gangrene, 88, 113
granulomata, 1669
osteomyelitis, acute, 639
phlebitis, 361
Infiltration anæsthesia, 1603
Inflammation, 14
acute, 15
catarrhal, 21
causes of, 14

Inflammation, chronic, 18, 21
croupous, 21
interstitial, 21
lymphatic phenomena of, 18
parenchymatous, 21
resolution in, 19
signs of, 21
terminations of, 18
tissue changes in, 17
treatment of, 24, 26, 27
vascular phenomena of, 15
Inflammatory fever, 23
lymph, 15
Infra-orbital neuralgia, 395
Ingrowing toe-nail, 453
Inguinal abscess, 376
aneurism, 340
bubo, 143
hernia, 1339
lymphogranuloma, 144, 379, 1676
Inhalations, steam, for sinusitis, 1028
Inherited syphilis, 164
bone affections in, 661
treatment of, 168
Injection treatment of hernia, 1354
aneurism of, 333
Innominate artery, ligature of, 343
Insanity, traumatic, 875
Insect stings, 243
Instruments, preparation of, for operations, 283
Intercostal artery, hæmorrhage from, 263
nerves, paralysis of, 806
neuralgia, 418
Interdental splint, 570
Internal capsule, injuries of, 883
carotid artery, aneurism of, 335
ligature of, 344
wounds of, 891
ear, diseases of, 1643
hæmorrhoids, 1413
iliac artery, ligature of, 350
malleolus, fracture of, 625
mammary artery, hæmorrhage from, 263
ligature of, 347
popliteal nerve, 421
saphena, varix of, 363, 1356
urethrotomy, 1517
Interrupted galvanic current, 302
Interscapulo-thoracic amputation, 1565
Interstitial emphysema of lungs, 1080
hernia, 1342
inflammation, 21
keratitis, 167
mastitis, 1135
Intertrochanteric fracture of femur, 608
Intervertebral disc, protrusion of, 833
Intestinal anastomosis, 1260, 1261
calculi, 1228
diverticula, 1225
kinks, 1252
obstruction. *See* Obstruction, intestinal
paralysis, 1391
schistosomiasis, 1687
stasis, 1252
sutures, 1166
Intestines, affections of, 1223
Intestines, carcinoma of, 1237
congenital malformations of, 1224
contusions of, 1226
embolus in, 360
foreign bodies in, 1228, 1390
operations on, 1255
perforation of, 1227
radiography of, 1223
rupture of, 1226
sarcoma of, 1237
stenosis of, 1235
strangulation of, by bands, 1382
syphilitic ulceration of, 1235
tuberculous ulceration of, 1234
tumours of, 1236
wounds of, 1714
Intra-abdominal bands, 1252
Intracanalicular adenoma of breast, 1143
Intracapsular fracture of femur, 604
Intracranial aneurism, 335
blood-vessels, injuries of, 889
complications of otorrhœa, 893, 1644
of sinusitis, 1031
inflammation, 893
tension, increased, 878, 895, 901, 917, 923
tumours, 906
Intradermic test for hydatids, 232
Intradural hæmorrhage, 890
Intramammary abscess, 1134
Intramedullary spinal hæmorrhage, 800
pegs in fractures, 551
plug in bone-grafting, 689
tractotomy, 405
tumours of spine, 836
Intrameningeal hæmorrhage, 892
Intramuscular injections of mercury, 162
Intrapelvic abscess, 1625
Intraperitoneal abscess, 1178
hæmorrhage, 1170
rupture of bladder, 602, 1470
of ectopic gestation, 1628
Intrathoracic aneurisms, 332
goitre, 1118
Intravenous infusion. *See* Infusion of salt solution
medication, 366
Intrinsic cancer of larynx, 1062
Intubation of larynx, 1070
of œsophagus, 1056
Intussusception, 1385
acute, 1388
anatomy of, 1385
cause of, 1386
chronic, 1389
treatment of, 1389
varieties of, 1386
Inunction of mercury for syphilis, 162, 168
Iodides in syphilis, 163
Iodine, antiseptic properties of, 278
sterilization of catgut by, 284
of skin by, 285
Iodoform, 279
emulsion, 176
Ionic medication, 303
Irido-cyclitis, 142
Iritis, acute, 1661
syphilitic, 154

Irradiation, Aran's theory of, 851
Irreducible hernia, 1366
Irrigation of bowel for colitis, 1230
of joints, 728
of urethra and bladder in gonorrhœa, 138
of urinary bladder in cystitis, 1475
Ischæmic contraction of muscles, 464
Ischio-rectal abscess, acute, 1406
chronic, 1407
Isotonic salt solution, 72
Ivory exostosis, 197
pegs for fractures, 550

Jacksonian epilepsy, 923
Jackson's bronchoscope, 1057
membrane, 1252
œsophagoscope, 1047
Jaundice, catarrhal, 1297
in cancer of biliary tract, 1311
of pancreas, 1318
of stomach, 1220
in gall-stones, 1304, 1305
in rupture of gall-bladder, 1292
in tropical fevers, 1683
Jaw, lower, dislocation of, 696
excision of, 973
fracture of, 566
necrosis of, 960, 967
osteomyelitis of, 966
tumours of, 970
upper, excision of, 966
fracture of, 566
necrosis of, 961
tumours of, 961
Jejunostomy, 1255
Jerk-finger, 498
'Joint-mouse,' 765
Joints, adhesions in, 727
ankylosis of, 766
diseases of, 721
dislocation of, 692
effusion into, 721
empyema of, 727
erasion of, 746
excision of, 746, 768, 783
false, 562
'flare,' 729
gonorrhœal affections of, 142, 736
gouty affections of, 738
gunshot wounds of, 691
hæmophilic disease of, 763
hysterical, 765
implication of, in fractures, 554
infected wounds of, 691
injuries of, 690
loose bodies in, 763
mobilization of, 727
neuralgic, 765
operations on, 724
penetrating wounds of, 691
position of rest of, 723
pyococcal infection of, 725
rheumatic affections of, 737
sprains of, 690
syphilitic affections of, 751
tuberculous disease of, 741
typhoid disease of, 735
Jones's elbow splint, 583
Jones's, Hugh, line, 1643
Junker's inhaler, 1597
Juxta-articular nodules, 1672
Juxta-epiphyseal strain (Ollier), 537

Kala-azar, 1681
Keloid, 254
Keratitis, 1659
interstitial, 167
punctata, 1651
Ketogenic diet, 1450
Keynes's flask, 37
Kidneys, affections of, 1435
abscess of, 1453
absence of, 1440
adenoma of, 1463
amyloid disease of, 56
angioma of, 1464
calculus in, 1456
capsule, rupture of, 1443
carbuncle of, 1451
carcinoma of, 1465
congenital affections of, 1440
displacement of, 1440
cystic disease of, 1463
dermoid cysts of, 1466
embolus in, 360
enlarged, signs of, 1435
examination of, 1435
floating, 1440
functional activity, tests of, 1437
hæmorrhage from, 1444
horseshoe, 1440
hydatid disease of, 1466
hypernephroma of, 1465
injuries of, 1443, 1706
malformations of, 1440
methods of exposure of, 1435
movable, 1440
papilloma of, 1464
purpura of, 1463
pyogenic infections of, 1448
radiography of, 1436
rupture of, 1443
sarcoma of, 1464, 1465
serous cysts of, 1466
surgical, 1448
tuberculous disease of, 1454
tumours of, 1463
Kienbock's disease, 646
Kinking of intestine, 1252
of ureter, 1441
Kirschner's wire, 614
Klapp's suction-balls, 26, 444
Klebs-Loffler bacillus, 121
Klumpke (lower arm), paralysis, 412
Knee, sprain of internal lateral ligament, 690
Knee-joint, acute arthritis of, 734
ankylosis of, 767, 769
congenital affections of, 507
dislocation of, 712
effusion into, 722
excision of, 786
internal derangement of, 712
loose body in, 717
position of rest, 723
rupture of crucial ligaments, 714
tuberculous disease of, 749

Knock-knee, 507
Knot, reef, 341
stay, 342
Kobelt's tubes, cysts of, 229
Kocher's method of treating dislocation of the shoulder, 700
operation on contracted palmar fascia, 500
pertrochanteric fracture, 609
Koch's tuberculin, 170
Koch-Weeks's bacillus, 1655
Kohler's disease, 646
Kollmann's dilators, 139
Kondoleon's operation, 1690
Krukenberg tumour, 1622
Kuntz's nerve, 430
Kyphosis, 491

Laboratory diagnosis of gonorrhœa, 134
of syphilis, 146
of tuberculosis, 170
Labyrinthitis, 1643
Lacerated wounds, 239
amputation after, 240
Laceration of arteries, 314
of brain, 880
of cervix, 1633
of lung, 1079
of perineum, 1633
of recto-vaginal septum, 1632
of urethra, 601, 1508
Lachrymal bone, fracture of, 566
diseases, 1661
Lactational cancer of breast, 1152
Lacunar abscess, 140
La Force adenotome, 1035
Lambkin's cream, 162
Laminæ, fractures of, 791
Laminectomy for division of antero-lateral tracts, 425
for spinal injuries, 795, 801, 808
in spinal caries, 829
Lane's ileal kink, 1252
plates for fractures, 551
theory of intestinal stasis, 1252
Langenbeck's operations for cleft palate, 1008
Laparotomy. *See* Abdominal operations
Lardaceous disease. *See* Amyloid disease
Laryngeal cartilages, necrosis of, 1060, 1061
mirror, 1057
paralysis, 409
from aneurism, 333
in cancer of œsophagus, 1054
in cut throat, 1109
in thyroid tumours, 1126
spasm in anæsthesia, 1580
stenosis, 1111
Laryngectomy, 1064
Laryngitis, acute and chronic, 1059
œdematous, 1059
tubercular, 1060
Laryngo-fissure, 1063
Laryngoscope, use of, 1057
Laryngotomy, 1065
Larynx, acute œdema of, 1059
diphtheria of, 1060
epithelioma of, 1062
extirpation of, 1064
Larynx, foreign bodies in, 1071
injuries of, 1058, 1109
intubation of, 1070
papilloma of, 1061
paralysis of. *See* Laryngeal paralysis
perichondritis of, 1061
syphilis of, 1060
tumours of, 1061
Lateral anastomosis of intestine, 1261
curvature of spine, 486
in hip disease, 773
graft (bone), 689
implantation of intestine, 1261
rhinotomy (Moure's operation), 964 1032
sinus, thrombosis of, 899, 1645
ventricles, hæmorrhage into, 884
Lavage of renal pelvis, 1450, 1452
Lead therapy, 209
Leaking aneurism, 328
Leather-bottle stomach, 1218
Leg, amputation of, 1571
Legg's disease, 780
Leiomyoma, 202
Leishmania braziliensis, 1675
donovani, 1674, 1681
tropica, 1674, 1675
Leishmaniasis, 1673
dermal (Delhi boil), 1674
diffuse cutaneous, 1675
naso-pharyngeal, 1675
Leiter's tubes, 24
Lembert's intestinal stitch, 1166
Leontiasis ossea, 961
Leprosy, 179
Lepto-meningitis, 801, 896, 898
Leucocytes, enumeration of, 29
varieties of, 29
Leucocythæmia, lymphatic, 381
Leucocytosis, 29
as sign of suppuration, 29
Leucopenia, 30
Leucoplakia, 984
vulvæ, 1610
Ligamentum patellæ, enlarged bursa beneath, 477
rupture of, 462
Ligature for aneurism, 330
for hæmorrhage, 260
for piles, 1418
gangrene following, 342
of vessels, 341
secondary hæmorrhage after, 261, 267
Ligatures, effects of, 342
materials for, 283, 284
preparation of, 283, 284
Light, use of, in surgery, 299
Lightning figures, 112
pains of Charcot's disease, 761
Lindau's disease, 233, 913
Linea alba, fatty hernia of, 193
Lingual artery, ligature of, 344
Linitis, plastic, 1216, 1218
Linseed poultice, 294
Lipiodol, 1083, 1085, 1090
Lipoma, 192, 970
arborescens, 193, 740
diffuse, 193

Lipoma, extradural, 193
intermuscular, 192
nasi, 1017
of femoral canal, 1356
of inguinal canal, 1345
of intestine, 1236
of mesentery, 1190
of scalp, 843
painful, of foot, 193
parosteal, 192
pericranial, 193
post-anal, 815
subfascial, 193
submucous, 192
subserous, 193
subsynovial, 193
Lipomatosis, 193
'Lipping' of joints, 754
Lips and jaws, affections of, 942
Lisfranc's amputation, 1569
Lister's antiseptic treatment of wounds, 278
bougies, 1514
excision of wrist, 786
modified flap and circular amputation, 1553
operation for fractured patella, 621
supracondylar amputation of thigh, 1572
Litholapaxy, 1487
Lithotomy, suprapubic, 1488
Lithotrity, 1486
contra-indications to, 1489
in boys, 1490
Little's disease, 531
Littré's hernia, 1369
Liver, abscess of, 1283, 1684
aspiration of, 1286, 1685
multiple, 1283
solitary, 1284
actinomycosis of, 1289
affections of, 1281
amyloid disease of, 56
carcinoma of, 1288
displacements of, 1281
embolus in, 360
gummata of, 1289
hydatid cysts of, 1287
in delayed chloroform poisoning, 1585
rupture of, 1170, 1281
tumours of, 1288
wounds of, 1706
Loasis, 1690
Lobectomy, 924, 1086, 1089
Local analgesia, 1602
Localization in cerebral affections, 882
Lockjaw, 125
Locomotor ataxy, joints in, 758
Loose bodies in joints, 763
Lorain's hypopituitarism, 929
Lordosis, 492
in hip disease, 772
Lotheissen's operation for femoral hernia, 1359
Lotio rubra, 85
Lower extremity, amputations of, 1567
Low-voltage therapy, 305
Ludwig's angina, 63
Lugol's iodine, 1123
Lumbago, 464
Lumbar abscess, 820
ganglionectomy, 442
hernia, 1364
nephrectomy, 1467
puncture, 871
for diagnostic purposes, 871
for spinal analgesia, 1605
for therapeutic purposes, 872
Lumpy jaw, 183
Lungs, abscess of, 1083, 1099
actinomycosis of, 184
collapse of, 1079, 1092
contusions of, 1078
embolus in, 360
gangrene of, 1084
hæmorrhage from, 1079
hernia of, 1082
laceration of, 1079
prolapse of, 1083
surgical affections of, 1078
tumours of, 1095, 1096
wounds of, 1082, 1706
Lupoid ulcers, 450
Lupus erythematosus, 452
vulgaris, 449
of nose, 1024
of palate, 1011
of tongue, 986
treatment of, 451
Luxatio erecta, 699
Luxation of joints, 692
'Lymph-bound' wound, 72
Lymph fistulæ, filarial, 1688
nodes in syphilis, 153
scrotum, filarial, 1688
Lymphadenitis, acute, 375, 1683
chronic, 376
syphilitic, 153, 376
tuberculous, 376
Lymphadenoma, 379
Lymphadenoid goitre, 1113
Lymphangioplasty, 374
Lymphangiectasis, 371, 372
Lymphangioma, 214, 371
capillary, 372
cavernous, 372
Lymphangitis, 370, 371
retiform, 370
tuberculous, 371
tubular, 370
Lymphatic glands, affections of, 375
tumours of, 379
leucocythæmia, 381
nævus, 372
œdema, 373
Lymphatics, diseases of the, 370
Lymphocytes, 29
Lymphocytosis, 30
Lymphogranuloma inguinale, 144, 379, 1676
Lymphorrhœa, 373
Lympho-sarcoma, 207, 381
of thymus, 1127
of tonsil, 1041
Lysol, 279

McBurney's method of opening the abdomen, 1161
McCarthy's resectotome, 1504

Macewen's operation for knock-knee (osteotomy), 508
McKesson's anæsthesia outfit, 1590
Machines for remedial movements, 293
Macrocheilia, 373, 950
Macrodactyly, 496
Macroglossia, 373, 982
Macrostoma, 949
Maculo-anæsthetic leprosy, 181
Madelung's deformity, 495, 595
Magill's laryngoscope, 1600
Main-en-griffe, 417
Malar bone, fracture of, 566
Malaria, 1681
Malarial spleen, 1681
Malignancy, characteristics of, 187
Malignant adenoma of thyroid, 1126
disease of scars, 255
embolus, 358
melanoma, 211
papilloma, 218
pustule, 131
syphilis, 159
tumours, 187
ulcers, 81, 217, 1150
wart, 217
Mallein in diagnosis of glanders, 179
Mallet-finger, 463, 498
Malposition a cause of deformity, 481
of feet *in utero*, 512
of testis, 1528
Malta fever, 1682
Mamma. *See* Breast
Mammaplasty, 1129
Mammography, 1141
Mandelic acid in pyelitis, 1450
Mandible. *See* Jaw, lower
Mandibular clefts, 949
Marjolin's ulcer, 255
Marriage after gonorrhœa, 137
after syphilis, 164
Martin's bandage, 740
Massage, 290
cardiac, 1101
for divided nerves, 390
for fractures, 552
in phlebitis, 362
in synovitis, 725
of prostate, 134, 796, 1494
Mastitis, acute, 1133
chronic interstitial, 1135
neonatorum, 1133
of puberty, 1133
Mastoid antrum, 1639
operation, 1641
Mastoiditis, 1639
Mattress, divided, 615
suture, 1167
Maxilla, affections of. *See* Jaw, upper
Maxillary sinus, empyema of, 1027
Maydl's hernia, 1373
Mayo's operation for hernia, 1361
Meckel's diverticulum, 1224
Median basilic vein, venesection of, 366
cervical fistula, 1108
hare-lip, 948
nerve, affections of, 415
Mediastinitis, 1102
Mediastinum, affections of, 1102
Mediastinum, tumours of, 1102
Medulla oblongata, injury of, 884
of bone, inflammation of. *See* Osteomyelitis
Medullary cancer, 222
Medulloblastoma, 919
Melæna, 257
Melanin, 211
Melanoma, 211, 971
Melanosis, 212
Melanuria, 212
Melon-seed bodies, 763
Membrana tympani, appearances of, 1634
puncture of, 1639
rupture of, 1637
Meningioma, 224, 906
Meningitis, basal, 899
cerebral, acute, 896, 1644
chronic, 898
serosa circumscripta, 838
spinal, acute, 801
chronic, 801
Meningocele, cranial, 844
spinal, 811, 815
Meningococcus, 894, 1015
Meningo-encephalitis, 897
Meningo-encephalocele, 844
Meningo-myelocele, 811
Meniscitis, 717
Menorrhagia, 1614
Mercurial cream (Lambkin's), 162
Mercurialism, 162
Mercury, biniodide of, 278
in treatment of syphilis, 162
vapour lamp, 299
Mesenteric glands, affections of, 1189
vessels, occlusion of, 1188, 1393
Mesentery, affections of, 1188
cysts of, 1189
tuberculosis of, 1189
tumours of, 1190
Mesodermal odontomes, 200
Metacarpal bones, dislocations of, 706
fractures of, 597
Metacarpo-phalangeal joint, amputation at, 1561
Metatarsal arch, transverse, loss of, 522
bones, fractures of, 633
Metatarsalgia (Morton's disease), 525
Meteorism, 806, 1175, 1380
Methylene blue test of renal function 1439
Metritis, 1616
Michel's clips, 238
Microcephaly, 847
Micrococcus ureæ, 1472
Microfilariæ bancrofti, 1687
Microstoma, 949
Middle-ear disease. *See* Otitis media
Middle lobe of prostate, 1497
meningeal artery, wounds of, 889
Mid-tarsal joint, amputation at, 1569
Miliary tubercle, 171, 1454
Milk engorgement, 1133
Millicurie (unit), 310
Miner's elbow, 479
Mirault's operation for hare-lip, 946

Miscarriage due to syphilis, 164
Mixed parotid tumour, 1003
Mobilization of fractures, 552
of joints, 727, 730
Modified flap and circular method of amputation, 1553
Moist gangrene, 89
Mole, tubal, 1628
Mollities ossium, 668
Molluscum contagiosum, 455
fibrosum, 190, 204
Mononucleosis, infective, 31
Moore's method of treating aneurism, 331
Morax-Axenfeld bacillus, 1655
Morcellement, 926
Morgagni, hydatid of, cysts from, 229
de Morgan spots, 368
Moriform enlargement of inferior turbinal, 1021
Morphia, use of, in acute intussusception, 1389
peritonitis, 1176
in anæsthesia, 1582
in delirium tremens, 541
in hæmoptysis, 1080
in shock, 275
Morton's disease. *See* Metatarsalgia
'Mother's mark,' 367
Motor aphasia, 882
area, paralysis of, in cortical hæmorrhage, 882
nerves, effects of division of, 385
oculi nerve, affections of, 395
Moure's operation (lateral rhinotomy), 961, 1032
Movable kidney, 1440
treatment of, 1442
Mucocele, 1661
Muco-membranous colitis, 1229
Muco-pus, 52
Mucous cysts of lips, 951
polypus of nose, 1021
tubercles, 163
Mulberry calculus, 1482
Mullerian body, 229
Mummification, 89
Mumps, 996
Muscles, affections of, 458
changes in, after injury to nerves, 385
injuries of, 458
rupture of, 460
tumours of, 466
Muscular relaxation in anæsthesia, 1579
Musculo-spiral nerve, injury of, 413
paralysis of, 413
Mushrooming of head of femur, 756
Myasthenia, thyrotoxic, 1122
Mycetoma (Madura foot), 1678
Myelitis, spinal, 802
Myelocele, 811
Myeloma. *See* Osteoclastoma
Myelomatosis, 201, 679
Myelopathic albumosuria, 202
Myeloplaxes, 201
Myoma, 202
Myomectomy, abdominal, 1614
Myositis, 463
fibrosa, 464
Myositis, ossificans, 466
traumatic, 466, 555
parasitic, 466
rheumatic, 464
suppurative, 465
syphilitic, 465
traumatic, 464
tuberculous, 465
Myringotomy, 1639
Myxœdema, 673, 1114
Myxoma, 191, 970
Myxo-sarcoma, 1146

N A.B., 160
Nævo-lipoma, 369
Nævus, 367
capillary, 367
cavernous, 368
diathermy cautery for, 368
electrolysis in, 368
lymphatic, 372
of lip, 951
of scalp, 842
spider (N. araneus), 367
unius lateris, 367
Nails, affections of, 452
Nares, palpation of posterior, 1015
plugging of, 1019
Nasal bones, fracture of, 565, 1015
polypi, 1021
septum, deviations of, 1018
fracture of, 566
spurs of, 1017
syphilis, 660, 1015, 1016, 1024
Naso-pharyngeal fibroma, 1035
sepsis, 58
Naso-pharynx, examination of, 1014, 1034
operations on, 1032
Navel, starting of, 1360
Neck, abscess in glands of, 376, 378
cellulitis of, 62
cysts of, 1107
tuberculous glands of, 377
wounds of, 1109
Necrobiosis of fibroids, 1613
Necrosis, 80
acute, 639
central, 650
chronic, 560
of bone, 560
of cranium, 848
of jaw, 960, 967
of laryngeal cartilages, 1060, 1061
of ossicles of ear, 1642
of palate, 1012
of temporal bone, 1642
phosphorus, 968
quiet, 636
syphilitic, 659, 660
tuberculous, of cranial bones, 848
tubular, 650
typhoid, 651
Needles, wounds by, 242
Negri bodies in rabies, 129
Neisseria gonorrhœæ, 133
Nélaton's line, 604
operation on naso-pharynx, 1032
Nembutal, 1503
Neoplastic cysts of breast, 1139

Neo-salvarsan, 160
Nephrectomy, abdominal, 1466
indications for, 1463
lumbar, 1467
Nephrolithotomy, 1461
Nephropexy, 1442
Nephrorrhaphy, 1442
Nephrostomy, 1452
Nerve anastomosis, 407
grafting, 390, 407
roots, affections of, 424
distribution of, 422
division of (Foerster's operation), 425
suture, 389
Nerves, affections of, 383
special, 394
bridging a gap in, 390
compression of, 383
concussion of, 383
division of, 384
treatment of, 389
injuries of, 383
involvement of, in fractures, 555
regeneration of, 389
rupture of, 384
suture of, 389
transplantation of, 384, 390
tumours of, 394
Wallerian degeneration of, 385
See also the special nerves
Nervous phenomena in intestinal obstruction, 1380
Neuralgia, infra-orbital, 395
intercostal, 418
of breast, 1136
of joints, 766
of testis, 1546
sciatic, 420
trigeminal, 395, 396, 438
Neurasthenia after head injuries, 876
after spinal injuries, 802
Neuritis, acute and chronic, 393
optic. *See* Optic neuritis
peripheral, joint changes in, 393
Neuroblastoma, 203
Neurofibromata, 203, 204, 835
Neuro-fibromatosis, 204, 835, 843
Neurolysis, 384
Neuroma, 203
central, 388
lateral, 387
terminal, 385
traumatic, 205
Neuro-mimetic joints, 765
Neuropathic arthritis, 759
Nicoll's operation for radical cure of femoral hernia, 1358
Nipple, abscess of, 1132
chancre of, 1133
eczema of, 1130
fissures of, 1130
keratosis of, 1133
Paget's disease of, 1130
retraction of, 1148
Nitrous oxide anæsthesia, 1585
method of administration with ether and oxygen, 1588
Nocturnal incontinence of urine, 1491
Noma, 118, 1610, 1682
Nose, affections of, 1014
depression of bridge, 166, 1015
destruction of, partial or total, 1016
examination of, 1014
expansion of bridge, 1016, 1036
foreign bodies in, 1018
malignant disease of, 1031
operations for malignant disease of, 1032
polypi of, 1021
surgical repair of. *See under* Rhinoplasty
tuberculosis of, 1024
Novarsenobenzol (N.A B), 160
Novocaine, 1605
Nuck, canal of, cysts of, 229
Nucleus pulposus, herniation of, 833
Nystagmus, 884, 902, 916, 923

Oat-celled sarcoma, 208
Oblique facial cleft, 948
inguinal hernia, 1339
Obliterated hypogastric artery, relation to hernia, 1342
Obliteration of appendix, 1266
Obstetric fracture, 617
Obstruction, intestinal, 1379
acute, 1379
chronic, 1395, 1423, 1428
diagnosis of, 1397
Obturator hernia, 1365
Obturators for cleft palate, 1008
Occipital artery, compression of, 262
ligature of, 346
lobe, injuries of, 883
Occiput, dislocation of, 796
Oculomotor paralysis, 395
Odontoid process, fracture of, 796
Odontomata, 198, 957
O'Dwyer's intubation tubes, 1071
Œdema, acute inflammatory, 15
of brain, 881
of glottis, 1059
of scrotum, 1549
solid, 361
Œdematous laryngitis. *See* Œdema of glottis
Œsophageal bougies, 1051
fistula, 1111
Œsophagectasia, 1052
Œsophagoscope, 1047
Œsophagus, affections of, 1047
anatomy of, 1047
cancer of, 1052
congenital malformations of, 1049
diverticula of, 1049
examination of, 1047
foreign bodies in, 1050
inflammation of, 1051
intubation of, 1056
spasm of, 1052
stricture of, 1051, 1052
varix of, 1052
Œstrin in prostatic enlargement, 1495
Olecranon bursa, 479
fracture of, 588
Oleothorax, 1092
Olfactory nerve, affections of, 394, 854

Ollier's disease, 195
Ombredanne's operation for misplaced testicle, 1528
Omental grafts, 1187
hernia, 1335
Omentum, affections of, 1187
cancer of, 1188
in chronic peritonitis, 1179, 1188
strangulation of, in hernia, 1373
torsion of, 1188
Onchocerciasis, 1691
Onychogryphosis, 454
Open (compound) fractures, 858
treatment of wounds, 287
Operating-theatre, essentials of, 281
Operation, after-treatment, 286
preparation of patient for, 284
Operative surgery, technique of, 278, 281
treatment of fractures, 548
Ophthalmia neonatorum, 1656
Ophthalmoplegia externa, 395
Opisthotonos, 125
Opium in internal hæmorrhage, 262
in intestinal obstruction, 1397
Optic nerves, affections of, 394, 921
atrophy, 62, 933
neuritis, 673
Orbit, penetrating wounds of, 852
Orbital aneurism, 337
cellulitis, 62
Orchidectomy, 1529, 1536, 1547
Orchidopexy, 1528
Orchitis, acute, 1532
chronic, 1533
filarial, 1688
syphilitic, 1536
tuberculous, 1534
Organ of Giraldés, 228
of Rosenmuller, 228
Oriental sore, 1674
Oroya fever, 1682
Orthopædic surgery, 480
Os calcis, apophysitis of, 646
fracture of, 631
spur of, 526
tuberculosis of, 657
Ossicles of ear, caries of, 1642
Osteitis, 635
deformans, 670
fibrosa, 671
syphilitic, 511, 659
tuberculous, 655
typhoid, 651
Osteo-aneurism, 684
Osteo-arthritis, 753
of hip, 756
of temporo-maxillary joint, 977
Osteo-arthropathy, hypertrophic, 674
Osteochondritis deformans, 779
juvenilis, 647
Osteoclastoma, 200, 471, 676, 970
Osteocopic pains, 154, 659
Osteogenesis imperfecta, 667
Osteoma, 195
of antrum, 1031
of ear, 1637
of jaw, 961, 970
of skull, 848
Osteomalacia, 668
Osteomyelitis, 635
acute infective, 639
of cranium, 847, 1031
of ribs, 685
of spine, 815
albuminous, 643
cancellous, 650
serous, 643
syphilitic, 661
traumatic, 650
Osteo-periostitis, chronic, 651
Osteophytes, 754, 760
Osteo-porosis, 635, 636
Osteo-sarcoma, 680
Osteo-sclerosis, 636, 659
Osteotomy, Adam's, 769
cuneiform, 511, 769
for rachitic deformities, 511
Macewen's, for knock-knee, 508
subtrochanteric, 759, 769
Otitis media, 1638
abscess of brain in, 900, 1646
complications of, 893, 900, 1642
thrombosis of lateral sinus in, 899, 1645
Otorrhœa, chronic, 900, 1638, 1641
Ovarian abscess, 1623, 1625
cysts, 1620
malignant, 1620
operative treatment of, 1623
rupture of, 1623
suppuration of, 1623
torsion of, 1623
dermoids, 1621
fibroma, 1621
pregnancy, 1627
Ovaries, removal of, in hysterectomy, 1615
Ovariotomy, 1623
Ovaritis complicating appendicitis, 1268
Ovary in sac of hernia, 1337
tumours of, 1620
complications of, 1623
Oxalate of lime calculi, 1482
Oxyuris vermicularis, 1405, 1413
Ozæna, 1023

Pacchionian bodies, 845
Pachydermatocele, 843
Pachymeningitis, cranial, 801, 894
Paget's disease of bone, 670
of nipple, 1130
'quiet necrosis,' 636
recurrent fibroid, 191, 208
Painful lipoma of foot, 193
sacralization, 831
scars, 255
stump, 1558
subcutaneous nodule, 203
Palate, affections of, 1005
cleft, 1005
perforations of, 1011
syphilis of, 660, 1011
tumours of, 1012
ulceration of, 1011
Palmar abscess, 247
arch, hæmorrhage from, 263
fascia, contraction of, 498
ganglion, compound, 470
Panaritium. *See* Paronychia

Pancreas, affections of, 1312
carcinoma of, 1318
cysts of, 1316
wounds of, 1313, 1706
Pancreatic adenoma, 1317
calculi, 1316
fistula, 1313
Pancreatitis, acute, 1314
chronic, 1316
diabetes in, 1316
Pannus, 1659
Panostitis, acute, 639
Pan-sinusitis, 1025
Papilliferous cysts, 1620
Papilloedema. *See* Optic neuritis
Papilloma, 212
malignant, 213, 218
Papillomata of bladder, 1477
of breast, 1145
of choroid plexus, 913
of intestine, 1236
of kidney, 1464
of larynx, 1061
of rectum, 1425
of scalp, 843
of tongue, 988
of vulva, 1610
Papillomatosis, diffuse spirochætal, 1677
Paquelin cautery, 297
Paracentesis abdominis, 1187
Paradidymis, 228
Paraffin cancer, 1549
Paraldehyde, 1582
use of, in delirium, 541
Paralysis, after injury to brain, 879, 882
to nerves, 385
to spine, 803
crossed, 884
Erb-Duchenne, 411
facial, 405, 854, 1642
infantile, 527
in Pott's disease, 822
Klumpke's, 412
of bladder, 437, 804
of intestine, 1391
of larynx. *See* Laryngeal paralysis
of serratus magnus, 493
of sphincter vesicæ, 1490
post-diphtheritic, 122
spastic, 531
Paralytic ileus, 1391
talipes. *See varieties of talipes*
Parametric abscess, 1627
Parametritis, 1626
Paraphimosis, 1522
Paraplegia, 794, 800, 801, 803
at different levels, 805
death from, 806
gravitation, 801
in spina bifida occulta, 814
in spinal caries, 822
Parasitic cysts. *See* Hydatid cysts
emboli, 359
myositis, 466
worms, surgical affections caused by, 1405, 1413, 1686
Parasympathetic, 426
Parathyroids, 1127
Paravertebral thoracoplasty, 1094
Parenchymatous glossitis, acute, 983
goitre, 1116
inflammation, 21
Paronychia, 452
Paroophoron cysts, 229
Parotid gland, tumours of, 1003
Parotitis, chronic, 999
epidemic, 996
post-operative, 996
simple, 996
suppurative, 996
Parovarian cysts, 229, 1622
Paroxysmal hæmoglobinuria, 96
Parrot's nodes, 661
Passive hyperæmia, 26
immunity, 7
movement of limbs, 292
Pasteur's treatment for hydrophobia, 130
vaccine for anthrax, 131
Pastille dose, X-rays, 304
Patella, congenital absence of, 506
dislocations of, 711
fractures of, 619
thickening of fatty pads behind, 713
Patellar bursa, enlargement of, 477
tap, 722
Pathetic nerve, affections of, 395
Paul and Mikulicz's operations, 1248
Paul's tube, 1255
'Peau d'orange' in cancer of breast, 1150
Pecten band, 1412
Pedicle-grafting, 87, 1016
Peg-leg, 1557
Pelvic abscess, 1626
cellulitis, 63, 1626
hæmatocele, 1628
inflammation, acute, 1625
chronic, 1625
Pelvirectal abscess, 1407
Pelvis, fractures of, 599
rachitic, 664
triradiate, 664
Penetrating wounds, 235
of abdominal walls, 1169
of arteries, 316
of brain, 880, 886
of chest, 1080
of eye, 1650
of heart, 1100
of joints, 691
of liver, 1281
of orbit, 851
of spine, 789
Penis, affections of, 1521
amputation of, 1525
chancre of, 148
soft, 143
congenital malformations of, 1507
epithelioma of, 1524
fistula of, 140
herpes of, 1523
paraphimosis, 1522
phimosis, 1521
plastic operations on, 1508
warts of, 1524
Peptic ulcer, 1195
acute, 1195

Peptic ulcer, anastomotic, 1205
chronic, 1196
hæmorrhage in, 1196, 1198, 1206, 1211
medical treatment of, 1201
perforation of, 1196, 1211
surgical treatment of, 1202
Perabrodil, 1437
Percaine, 1605
Perforating ulcer of foot, 447
Perforation of appendix, 1267
of intestine, 1227
of palate, 1011
of peptic ulcer, 1196, 1211
Periadenitis, 375, 378, 380
Perianal hæmatoma, 1419
Periapical infections of teeth, 954
Periarterial sympathectomy, 440, 441
Periarteritis, 267, 318
Pericanalicular adenoma of breast, 1143
Pericardial effusions, 1101
Pericarditis, suppurative, 1101
Perichondritis of larynx, 1061
Pericolitis, 1230
Pericranitis, 847
Perigastritis, 1213
Perineal abscess, 1519
resection of rectum, 1430
Perineo-abdominal resection of rectum, 1432
Perineorrhaphy, 1633
Perinephritic abscess, 1444, 1453
Perinephritis, 1452, 1453
Perineum, laceration of, 1633
Perineuritis, 393
Periosteal bridge, 541
nodes, 651, 659
sleeve, 537
Periostitis, 635
acute, 637, 847
chronic, 848
syphilitic, 659
tuberculous, 654
Peripachymeningitis, 810, 830
Peripheral neuritis, 393
Periphlebitis, 357, 361, 362
Periproctitis, gangrenous, 1408
Perirectal suppuration, 1405
Peristalsis in intestinal obstruction, 1378, 1395
in peritonitis, 1175
Perithelioma, 224
Peritoneal adhesions, 1179, 1267, 1382
Peritoneum, affections of the, 1173
toilette of, 1162
Peritonitis, 1171, 1173
acute diffuse, 1174
localized, 1178
chronic simple, 1179
following appendicitis, 1266, 1267, 1271
gonorrhœal, 1174, 1182
pneumococcal, 1174, 1181
puerperal, 1173
rheumatic, 1174
spreading septic, 1268
tuberculous, 1174, 1180
Peritonsillar abscess, 1037
Perityphlitis, 1262
Periurethral abscess, 1519
Permanent callus, 543
Permanganate of potash, 279
Pernicious vomiting, 1585
Pernio, 449
Peroneal artery, ligature of, 355
Peronei tendons, tenotomy of, 472
Peroxide of hydrogen, 279
Perthes's disease, 780
Pertrochanteric fracture, 609
Pes cavus, 522
Petechiæ, 257
Petit's triangle, 1364
Pétrissage, 290
Phagedena, 116, 151
Phagocytosis, 15
Phalanges, amputation of, 1561
dislocation of, 706
fracture of, 597
Phantom tumour, 1168
Pharyngeal diverticulum, 1045
fistula, 1111
stenosis, 1044
Pharyngitis, acute, 1042
atrophic, 1043
chronic, 1042
granular, 1043
Pharyngoplasty, 1010
Pharyngotomy, 1045, 1063
Pharynx, affections of, 1042
cancer of, 1045
syphilis of, 1043
Phenol-sulphonephthalein test of renal function, 1439
Phimosis, 1521
in association with cancer of penis, 1524
retention of urine from, 1492
Phlebitis, 360
infective, 361
spreading, 361
Phleboliths, 357, 364
Phlebotomy. *See* Venesection
Phlegmasia alba dolens, 358
Phlegmonous gastritis, 1194
Phlyctenular conjunctivitis, 1659
Phosphatic calculi, 1483
Phosphorus necrosis of jaw, 968
Phrenic nerve, avulsion of, 1093
injury of, 410
paralysis of, 410, 806
Phrenospasm, 1052
Physical agencies, use of, in surgery, 288
Pick's disease, 1101
Picric acid, sterilization of skin by, 285
treatment of burns by, 106
Pigeon-breast, 664
'Pig-skin' in cancer of breast, 1150
Piles. *See* Hæmorrhoids
Pin in urethra, 1509
Pineal teratoma, 920
tumours, operations for, 926
Pinealoma, 920
'Pink eye,' 1655
Pipe-stem motions, 1423
Pituitary tumours, 911, 928
operations for, 933
Pituitrin in paralytic ileus, 1392
in shock, 277

Placental polypus, 1616
Placentomata, 189
Plantar arch, hæmorrhage from, 264
fascia, contraction of, 513
division of, 523
Plantaris tendon, rupture of, 462
Plasma cells, 18
dried, 39
pooled, 39
Plaster-of-Paris bandages, 548
bed, 827
jackets, 827
splints, 548
Plastic inflammation, 21
linitis, 1216, 1218
Plates (Lane's) for fractures, 551
Pleura, tumours of, 1078
Pleural cavities, affections of, 1074
cavity, aspiration of, 1074, 1076
drainage of, 1077
effusion in, 1074
empyema of, 1074
fistula, 1077
Pleurosthotonos, 125
Plexiform neurofibroma, 204
Plombage, massive, 1089, 1094
Plummer's disease, 1121
Pneumatocele capitis, 1030
Pneumectomy, 1089
Pneumocele, 1082
Pneumococcal arthritis, 735
empyema, 1076
peritonitis, 1181
Pneumococcus, 44
Pneumogastric nerve, affections of, 409
Pneumonia, diagnosis from appendicitis, 1273
hypostatic, 555
leucocytosis in, 29
septic, after injury to lung, 1080
after tracheotomy, 1070
in cancer of tongue, 990, 993
in cut throat, 1110
Pneumothorax, 1079
artificial, 1092
extrapleural, 1094
Podagra, 738
Poisoned wounds, 243
Poker back, 832
Poliomyelitis, anterior, 439
Politzer's method of inflating middle ear, 1636
Polydactylism, 496
Polymastia, 1128
Polymorphonuclear leucocytes, 29
Polyorchism, 1527
Polyposis intestini, 1424
Polypus of intestine, 1424
of middle ear, 1642
of nose, 1021
of rectum, 1424
of umbilicus, 1172
of urethra, 1510
of uterus, 1616
Ponceau fuchsin stain, 1331
Pond fracture of skull, 857
Pons varolii, injury of, 884
Popliteal aneurism, 341
artery, ligature of, 352
Popliteal bursæ, affections of, 477
nerves, injury of, 421
Poradenitis venerea, 1676
Port-wine stain, 367
Position of rest for joints, 723
Post-anal dimple, 814
Posterior gastro-enterostomy, 1203
rhinoscopy, 1014
tibial artery, ligature of, 353
Post-mortem wart, 244
Post-operative retention of urine, 1419
Potassium iodide in syphilis, 163
Pott's disease, 810. *See* Spinal caries
fracture, 628
puffy tumour, 848, 895
Poultices, 294
Power (D'Arcy), treatment of aneurism, 332
Precipitin reaction, 232
Pregnancy, extra-uterine, 1627
ovarian, 1627
piles in, 1414
varicose veins in, 362
Pregnyl in retained testis, 1528
Preliminary cæcostomy, 1247, 1256
tracheotomy, 1066
Preparation of patient for operation, 284, 1160
Prepuce, affections of, 1521
herpes of, 1523
Priapism, 1499
Price Thomas's rib shears, 1095
Primary arterial hæmorrhage, 266
nerve suture, 389
shock, 270
tuberculosis of kidney, 1454
union of wounds, 250
Processus vaginalis, 229
Procidentia uteri, 1629
Proctitis, 1404
gonorrhœal, 141
ulcerative, 1683
Proctoclysis, 266, 1163
Proctoscopy, 1402
Prolan B, 226
Prolapse of anus, 1420
of rectum, 1419
operation for, 1421
of urethral mucous membrane, 1611
of uterus, 1629
Prolonged fixation of limbs. *See* Fixation
Prontosil. *See* Sulphanilamide
Prophylaxis, venereal, 137, 159
Proptosis. *See* Exophthalmos
Prostate, abscess of, 1493
calculi of, 1495
cancer of, 1506
enlargement of, 1495
diagnosis of, 1499
massage of, 134, 796, 1494
tuberculosis of, 1495
Prostatectomy, suprapubic, 1501
Prostatic bar, 1497
pouch, 1498
Prostatitis, acute, 1493
chronic, 1494
Prostatorrhœa, 1494
Protopathic sensation, 386
Pruritus ani, 1413
Psammoma, 224

Psathyrosis, idiopathic, 667
Pseudarthrosis, 693
Pseudo-agglutination, 35
Pseudo-coxalgia, 779
Pseudo-cysts, 233
Pseudo-hermaphroditism, 1632
Pseudo-mucinous cystadenoma, 1620
Pseudo-neuroma, 204
Pseudo-paralysis, syphilitic, 661
Psoas abscess, 173, 774, 820
  bursa, affections of, 479
Psoriasis linguæ, 984
Pudic artery, hæmorrhage from, 264
Puerperal peritonitis, 1173
Pulex papatasii, 1674
'Pulled elbow,' 705
Pulmonary abscess, 1083, 1099
  concussion in blast, 1699
    in water-blast, 1700
  decortication, 1078
  embolus, 360
  hæmorrhage, 1079
  tuberculosis (surgery in), 1092
Pulp-tumours, 188, 189, 190
Pulsating empyema, 1075
  exophthalmos, 337
  hæmatoma, 315
  sarcoma, 681
  tumours of bone, 684
Punctured fracture of skull, 851, 855
  wounds, 242
    of intestine, 1227
    of testis, 1530
Pupils in affections of cervical sympathetic, 422
  in alcoholism, 880
  in anæsthesia, 1579
  in cerebral compression, 879
    concussion, 875
Purpura, 1325
  rheumatica, 1326
  varieties of, 1326
Pus, characters of, 51
  in acid urine in pyelitis, 1449
  in acute abscess, 48, 51
  in chronic tuberculous abscess, 172
  muco-, 52
  sero-, 52
Pustule, malignant, 131
Putrid moist gangrene, 90
Pyæmia, 42, 66, 75, 77, 1453
  bacteriology of, 75
  chronic, 77
  gonorrhœal, 142
  in osteomyelitis, 640
  in suppurative arthritis, 732
  lateral sinus, 899
  treatment, 78
Pyelitis, 1448, 1449
Pyelography, 1437, 1447, 1464
  intravenous, 1447
Pyelo-nephritis, 796, 804, 1448, 1450, 1457
Pyeloplasty, 1447
Pyeloscopy, 1447
Pyelotomy, 1462
Pyelo-venous back-flow, 1446
Pylephlebitis, 77, 1268, 1278
Pylon or peg-leg, 1557
Pylorus, adhesions around, 1213
Pylorus, cancer of, 1217
  congenital hypertrophy of, 1215
  stenosis of, 1213
Pyococcal infection of joints, 725
Pyogenic bacteria, 3, 42, 75
  infections, 42
  membrane, 48
Pyonephrosis, 1449, 1452, 1457
Pyorrhœa alveolaris, 57, 959
Pyosalpinx, acute, 1625
  chronic, 1182, 1626
Pyo-septicæmia, 77
Pyothorax, 1076
Pyramidal tract, injuries of the, 884
Pyrexia, 23
Pyuria in pyelitis, 1449
  in tuberculous kidney, 1457

Queckenstedt's sign, 833, 834
Quiescent interval in appendicitis, 1271
    operation in, 1275
'Quiet' hip disease, 780
  necrosis, 636
Quinsy, 1037

Rabies, 128
Rachitic teeth, 663
  tibia and fibula, 511, 665
Racquet-shaped method of amputation, 1552
Radial artery, ligature of, 349
Radiant heat baths, 296
Radiation, gangrene due to, 113
Radical cure of hæmorrhoids, 1418
    of hernia, 1347, 1357
      recurrence after, 1354
    of hydrocele, 1541
    of varicocele, 1545
  mastoid operation, 1643
Radicular odontome, 200
Radiographic screen, 301
Radiography, 300
  of aneurism, 333, 937
  of biliary passages, 1291
  of breast, 1139
  of cervical rib, 486
  of colon, 1224
  of foreign bodies, 243, 302, 1050
  of fractures, 539, 546
  of gall-stones, 1291, 1295
  of gastric affections, 1190, 1201, 1220
  of hip disease, 777
  of intestines, 1223
  of kidneys, 1436
  of lung abscess, 1083
  of œsophagus, 1047
    stricture of, 1054
  of renal calculus, 1455, 1458
    dwarfism, 667
  of rickets, 665
  of spine, 824, 831
  of ureteral calculus, 1458
  of vesical calculus, 1485
  stereoscopic, 301
Radio-therapy, 303
  in cancer, 306, 1046, 1063, 1099, 1539, 1611, 1619
  in sarcoma, 209
  in toxic goitre, 1124
  result of prolonged exposure, 303

Radium, 303, 305
applicator, 307
bomb, 308
emanation, 307
Forsell and Heyman's technique, 1618
in cancer, 311
of bladder, 313, 1481
of breast, 311, 1157
of buccal cavity, 312
of cervix, 1618
of œsophagus, 1056
of pancreas, 1319
of penis, 1525
of rectum, 313, 1434
of tongue, 993
of vulva, 1611
in lupus, 311
in rodent ulcer, 311, 457
in sarcoma, 209
necrosis, 113
of jaw, 969
rays from, 306
uses of, 311
Radius, congenital absence of, 495
dislocations of, 704
excision of head of, 704
fractures of, 589, 595
separation of lower epiphysis of, 595
subluxation of head of, 705
Radius and ulna, dislocation of, 703
fractures of, 595
Radon, 307
seed introducer, 308
Railway spine, 802
Rammstedt's operation, 1215
Ranula, 997
Rarefaction of bone, 636
Rat-bite fever, 1682
Rathke's pouch, tumours of, 929, 930
Ray fungus, 182
Raynaud's disease, 95, 431
hæmoglobinuria in, 96
sympathectomy in, 432
Reaction from concussion, 875
from shock, 272
of degeneration, 300, 386
Reactionary hæmorrhage, 266
Re-amputations, 1560
Rectal administration of ether, 1596
of saline, 266, 1163
Rectocele, 1629
Rectopexy, 1421
Recto-sigmoidectomy, 1421
Recto-vaginal fistula, 1427
septum, lacerations of, 1632
Recto-vesical fistulæ in cancer of bladder, 1480
of rectum, 1427, 1428
Rectum, affections of, 1401
bilharzial infection of, 1405
cancer of, 1425
operative treatment of, 1430
radium treatment of, 1434
congenital malformations of, 1402
examination of, 1401
excision of, 1430
foreign bodies in, 1404
inflammation of, 1404
injuries of, 1404, 1705
Rectum, papilloma of, 1425
polypus of, 1424
prolapse of, 1419
sarcoma of, 1425
stricture of, 1422
suppuration, 1405
syphilis of, 1422
threadworms in, 1405
tuberculous disease of, 1422
Rectus abdominis muscle, injuries of, 459, 1168
Recurrence after radical cure of hernia, 1354
Recurrent appendicitis, 1272
dislocations, 692, 702
fibroid of breast, 1147
laryngeal nerve, paralysis of, 409
Red corpuscles, 28
in inflammation, 15
sedimentation-rate, 171
Redness in inflammation, 21
Reduction *en masse* of a hernia, 1374
of dislocations, 694
of fractures, 544
Reef-knot, 341
Referred pain in hip disease, 771
in inflammation, 22
in renal calculus, 1457
in spinal caries, 818
Reflex micturition, 796, 804
Reflexes in anæsthesia, 1579
in spinal disease, 823
injuries, 804
Relapsing appendicitis, 1271
chancre, 152
fever, 1683
Remedial exercises, 292
in scoliosis, 490
Renal calculus, 1456
colic, 1457
complications in appendicitis, 1268
dwarfism, 667
functions, examination of, 1437
hæmaturia, 1443, 1455, 1457, 1463, 1464, 1465
rickets, 667
sympathectomy, 1448
Repair after fractures, 541
after inflammation, 19
of wounds, 250
Resection. *See* Excision
Residual abscess, 823
urine, 1498
Respiration, artificial, 1103
cessation of, in general anæsthesia, 1578
obstruction of, in general anæsthesia, 1580
Rest in treatment of inflammation, 24
Restoration of function of divided nerves, 392
Retained testis, 1527
malignant disease of, 1528
operations for, 1528
treatment of, 1528
Retention cysts, 230, 1138
of urine, 437, 800, 804
Retina, embolism of, 360
Retroflexion, 1630

Retrograde dilatation of œsophageal stricture, 1052
Retropatellar fatty pads, thickening of, 713, 717
Retropharyngeal abscess, 819, 1044
Retrosternal goitre, 1118
Retroversion, 1630
Reverdin's method of skin-grafting, 86
Rhabdomyoma, 202
Rheumatic fibrositis, 464
  myositis, 464
  nodules, 737
  spondylitis, 830
  synovitis, 737
  torticollis, 482
Rheumatoid arthritis, 752. *See also* Osteo-arthritis
Rhinitis, acute, 1020
  atrophic, 1023
  chronic, 1020
  gonorrhœal, 141
  hypertrophic, 1020
  sicca, 1023
  suppurative, 1020
  syphilitic, 1024
Rhinolith, 1018
Rhinophyma, 1017
Rhinoplasty (Indian method), 1016
Rhinoscleroma, 1680
Rhinoscopy, 1014, 1034
Rhinosporidiosis, 1680
Rhinosporidium seeberi, 1680
Rhinotomy, lateral (Moure's operation), 964
Rib, cervical, 97, 485
Ribs, affections of the, 685
  beaded, in rickets, 663
  fracture of, 571
  osteomyelitis of, 685
  syphilitic disease of, 685
  tuberculous disease of, 685, 1138
  tumours of, 686
Richter's hernia, 1369, 1372
Rickets, 662
  adolescent, 666
  epiphyseal cartilage in, 665
  femur in, 664
  greenstick fractures in, 536
  hæmorrhagic, 666
  kyphosis from, 663
  of skull, 663
  of spine, 663
  of tibia and fibula, 511, 665
  scoliosis from, 663
  scurvy, 666
  treatment of, 665
Rickety rosary, 663
Rider's bone, 197
  sprain, 462
Riedel's disease, 1113
  lobe of liver, 1281
Rigg's disease, 959
Rigors, 51
Rind-tumours, 188, 189, 212
Rinne's tuning-fork test, 1634
Risus sardonicus, 125
Rodent ulcer, 218, 455
Rolando, fissure of, 862
'Rolandometer,' 862
Röntgen rays. *See* X-rays
  unit, 310
Roseola, syphilitic, 152
Rose's operation for hare-lip, 946
Rouge's operation for nasal disease, 1032
Round ligaments, hydrocele of, 229
  shoulders, 491
Roux's operation for femoral hernia, 1358
Rubber gloves, use of, 282
Rugby wrist, 459
Rupia, 155
Rupture. *See* Hernia
  of aneurism, 328
  of appendix abscess, 1267
  of arteries, 314
  of biceps, 461
  of bladder, 602, 1470
  of crucial ligaments, 714
  of eye, 1650
  of gall-bladder, 1292
  of hydatid cyst, 232
  of intestine, 1226
  of kidney, 1443
  of liver, 1281
  of membrana tympani, 1637
  of muscles, 460
  of nerves, 384
  of ovarian cyst, 1623
  of rectus abdominis, 459
  of sheath of muscle, 459
  of spleen, 1324
  of stomach, 1193
  of tendons, 460
  of thoracic duct, 370
  of tubal gestation, 1627, 1628
  of ureter, 1444
  of urethra, 1512, 1520
  of vaginal vault, 1632
  of vas deferens, 1532

Sabouraud's pastilles, 304
Sacculated aneurism, 325
Sacculi of bladder, 1476
Sacculitis, 1230
Sac of a hernia, description of, 1334
  in strangulation, 1371
Sacral tumour, congenital, 814
Sacralization, painful, 831
Sacro-iliac disease, 749, 781
  strain, 783
Sacrum, fractures of, 603
Saline infusion in hæmorrhage, 265
  in shock, 276
Salivary calculus, 998
  fistula, 1000
  glands, affections of, 996
Salivation, 163
Salmon patches of cornea, 167
Salpingitis, 1625
Salpingo-oöphoritis, 1626
Salvarsan, 159
  administration of, 160
Salvarsanized serum, 873
Sanatorium treatment in tubercle, 175
Sand-fly fever, 1681
Sanitas, 279
Saphena, varix of, 363
Saprophytes, 3
Sarcoma, 205

Sarcoma after fractures, 544
cause of fracture, 535
congenital, of kidney, 1464
dissemination of, 206
endosteal, 971
Ewing's, 645, 684
'oat-celled,' 208
of antrum, 962, 1032
of bladder, 1478
of bone, 680
of brain, 921
of breast, 1146
of cranium, 849
of gum, 960
of intestine, 1237
of kidney, 1464, 1465
of lungs, 682
of lymphatic glands, 381
of mandible, 971
of maxilla, 962
of mesentery, 1190
of muscles, 466
of naso-pharynx, 1032
of nose, 1032
of palate, 1012
of pancreas, 1319
of parotid, 1004
of rectum, 1425
of ribs, 686
of scalp, 843
of spine, 832
of spleen, 1325
of sternum, 686
of stomach, 1222
of thyroid, 1126
of tonsil, 1041
of upper jaw, 962
of uterus, 1619
of vulva, 1611
pulsating, 681
round-celled, 207
secondary, of bone, 684
spindle-celled, 208
treatment of, 209
'Satellite' chancre, 143
'Saturday-night' paralysis, 413
Saucer fracture of skull, 857
Sayre's treatment of fracture of clavicle, 575
Scab, healing under a, 251
'Scabbard' trachea in goitre, 1118
Scalds, 104
Scalp, affections of, 841
avulsion of, 841
cellulitis of, 61, 842
hæmatoma of, 841
suppuration of, 842
tumours of, 842
wounds of, 841, 1706
Scapula, congenital elevation of, 493
fractures of, 576
tilting of, 494
winged, 493
Scars, 252
adherent, 253
contraction of, 253
in amputation stumps, 1554
in brain a cause of epilepsy, 885
keloid of, 254
Scars, malignant disease of, 255
painful, 255
pathological conditions of, 253
ulceration of, 254
Schistosoma hæmatobium, 1686
japonicum, 1687
Mansoni, 1687
Schistosomiasis, 1686
intestinal, 1687
Schlatter's disease, 646
Schonlein's disease, 1326
Schwartz's operation for mastoid disease, 1641
Sciatic artery, aneurism of, 340
hæmorrhage from, 264
nerve, injuries of, 419
Sciatica, 420
Scirrhus cancer, 221
of breast, 1148
atrophic, 1149
of pylorus, 1217
'Scissor' deformity of hip-joint, 767
Sclavo's serum, 132
Scleritis, gonorrhœal, 142
Scleroderma, 439
Sclerosis of bone. *See* Osteo-sclerosis
Sclerotomy in glaucoma, 1663
Scoliosis, 486
compensatory, 486
rachitic, 486
static, 486
treatment of, 490
Scopolamine in anæsthesia, 1582
Scott's dressing, 25
Screen, X-ray, 301
Screws for fractures, 550
Scrotal tumours, general diagnosis of 1546
Scrotum, affections of, 1549
cellulitis of, 1549
eczema of, 1549
elephantiasis of, 1688
epithelioma of, 1549
erysipelas of, 120
fistulæ of, 1549
gangrene of, 1549
lymph, 1688
œdema of, 1549
sinuses of, 1549
Scurvy, infantile, 666
rickets, 666
Sebaceous adenoma, 455, 843
cysts, 454, 843, 1108
of neck, 1108
of scalp, 843
glands, affections of, 454
cancer of. *See* Rodent ulcer
horn, 454
Second intention, healing by, 250
Secondary anæmia, 28, 58
hæmorrhage, 267
nerve suture, 389
shock, 272
suture of wounds, 69
Semilunar cartilage, lesions of, 715
Semimembranosus bursa, enlargement of, 478
tendon, tenotomy of, 472
Seminoma, 1538

Semitendinosus, bursa beneath, disease of, 478
tendon, tenotomy of, 472
Senile atrophy of skull, 845
enlargement of prostate, 1495
gangrene, 92
Sensory nerve, results of section of, 386
'Sentinel' pile, 1412
Separation, line of, in gangrene, 91
Sepsis, focal, 57
Septicæmia, 42, 66, 73
chronic, 75
Septum nasi, fracture of, 566
lateral deviation of, 1018
resection of, 1018
Sequestration dermoids, 227
Sequestrectomy, 649
Sequestrum, 636
Sero-pus, 52
Serous cysts, 230, 1108, 1139, 1466
osteomyelitis, 643
synovitis, 739
Serratus magnus, paralysis of, 493
Serum, anti-anthrax, 11
antibacterial, 11
antidiphtheritic, 122
antidysenteric, 11
antigas-gangrene, 115
antimeningococcal, 11
antipneumococcal, 11
antirabic, 130
antistaphylococcal, 11
antistreptococcal, 11
antitetanic, 115, 127
antitoxic, 10
disease, 12
dried, 39
fractional method of administration, 12
Seventh nerve, affections of, 405
Sheath of muscle, rupture of, 459
Sheaths of tendons, disease of, 467
Shock, absorption of toxins in, 273
blood-pressure in, 273
by blast, 1699
diagnosis of, 274
in abdominal injuries, 1168, 1170
in burns, 105
in catheterism, 1514
in concussion of brain, 274
in contusion of testis, 1530
operation during, 275
post-operative, 272
prevention of, 275
primary, 270
reaction after, 272
secondary, 272
surgical, 270
symptoms of, 274
treatment of, 274
in burns, 1704, 1706
with blood-plasma, 38
with blood-serum, 38
Short-circuiting operations on intestine, 1261
Shoulder, disarticulation of, 1564
Shoulder-joint, acute arthritis of, 733
ankylosis of, 767
congenital elevation of (Sprengel's), 493
Shoulder-joint, dislocations of, 698
effusion into, 721
excision of, 784
position of rest of, 723
tuberculosis of, 747
Shrapnel wounds, 1694
Sialogram, 998
Sialography, 998
'Sieve' method of skin-grafting, 87
Sigmoid colon, cancer of, 1246
operation for, 1247
Sigmoiditis, 1230
Sigmoidoscope, 1401
Sigmoidoscopy, 1238, 1402
Silver wire in fractures, 550
Sinclair's foot-piece or skate, 614
Sinus, 54
tuberculous, 173, 178
Sinuses of nose, affections of, 1024
of skull, infective thrombosis of, 899, 1645
Sinusoidal currents, 302
Site of election for amputation of leg, 1571
Sixth nerve, injuries of, 405
Skeletal traction, 614
Skeleton splints, 547
Skiagraphy. *See* X-rays *and* Radiography
Skin-grafting, 86
in burns, 1705, 1707
Skin lesions, electrical, 1705, 1706
Skin, preparation of, for operations, 284
surgical diseases of, 444
Skull, acute necrosis of, 847
atrophy of, 845
forceps, 859
fractures of, 849
basal, 851
fractures of, compound, 858, 1707
depressed, 536, 855
elevated, 858
fissured, 850
punctured, 855
hypertrophy of, 847
in achondroplasia, 667
in acromegaly, 672, 847
in inherited syphilis, 845
in leontiasis ossea, 962
in osteogenesis imperfecta, 668
in rickets, 663
methods of opening, 863
Slipped epiphysis, 504
Slough, 80
Sloughing after burns, 105
of amputation flaps, 1557
of tendons of fingers, 247
Smith's fracture (radius), 595
Smith-Petersen's pin, 606, 759
Smoker's patch, 985
'Snail-track' ulcers of tonsil, 153, 1041
Snake-bites, 244
Snake venom, use of, in hæmorrhage, 270
Snap thumb, 459
Snare for nasal polypi, 1022
Snow-blindness, 1654
Snuffles in syphilis, 166
Sobernheim's serum in anthrax, 132
Sodium evipan, 1503
Softening, yellow, of brain, 881
Sordes, 23

Sounding the urinary bladder, method of, 1485
Souttar's tube, 1056
Spasm of glottis, 333
of œsophagus, 1052
of sphincter vesicæ, 1492
Spastic paralysis, 531
Speculum, nasal, 1014
Spermatic cord, hæmatocele of, 1345, 1531
hydrocele of, 229, 1344, 1543
torsion of, 1529
Spermatocele, 1543
Sphenoidal sinus, disease of, 1029
Spider nævus, 367
Spiller's operation, 425
Spina bifida, 811
occulta, 814
Spinal abscess, 815, 819
accessory nerve, affections of, 410
analgesia, 1603
in cases of shock, 276
caries (Pott's disease), 815
concussion, 799
cord, compression of the, 794, 822
hemisection of, 806
incomplete division of, 806
total transverse lesion of, 794
wounds of, 1708
cord and membranes, tumours of, 833
hæmorrhage, 800
meningitis, 801
myelitis, 802
nerves, affections of, 410
neurasthenia, 802
supports, 490, 828
Spine, ankylosis of, 823, 832
congenital malformations of, 486, 811
deformities of, 486
diseases of, 811
gonorrhœal rheumatism of, 831
injuries of, 788
bladder, effects on, 437, 804
dislocations, 796
fracture-dislocations, 793
fractures, 790
sprains, 788
wounds, 789, 1708
operations on, 807, 828
osteomyelitis of, 815
rheumatic spondylitis, 830
rickets of, 663
rigidity of, 818
syphilitic disease of, 830
tuberculous disease of, 815
tumours of, 832
Spinous processes, fractures of, 790
Spiral fractures, 536
Spirochæta pallida, 145
Spironema pallidum, 145
pertenue, 1671
Splanchnic anæsthesia, 1606
Splay-foot. *See* Flat-foot
Spleen, abscess of, 1325
accessory, 1320
amyloid disease of, 56
changes following removal of, 1320
embolus in, 360
enlargement of, 1321
floating, 1320
Spleen, functions of, 1319
infections of, 1325
neoplasms of, 1325
rupture of, 1324
surgical affections of, 1319, 1321
torsion of, 1320
wounds of, 1706
Splenectomy, 1329
indications for, 1323
Splenic anæmia, 1325
fever, 130
flexure, cancer of, 1245
hæmorrhage, 1324
notch, 1321
Splenomegaly, 1321
Splenopexy, 1320
Splint, 'cock-up,' 414
sores, 556
Splints, 546
Spondylitis deformans, 832
rheumatic, 830
traumatic, 831
Spondylolisthesis, 492
Spongioblastoma multiforme, 918
Spongy gums, 955
in mercurialism, 163
Spores, characters of, 2
Sprains of joints, 690
of ligaments, 690, 713
of muscles, 458
of spine, 788
'Spreader,' 614
Spreading gangrene, acute, 113
œdema of brain, 881
Sprengel's shoulder, 493
Spring-finger, 498
Spring ligament in flat-foot, 519
Spud for eye, Harman's, 1648
Spur in colostomy, 1257
of nasal septum, 1017
of os calcis, 526
of stump, 1558
Spurious valgus. *See* Flat-foot
Squamous epithelioma, 217
Squint in children, 1664
paralytic, 395, 405
Staphylococci, 42
Staphylorrhaphy, 1008
Starch bandages, 548
Stasis in inflammation, 15
intestinal, 1252
Static electricity, 303
genu valgum, 507
Status lymphaticus, 1127
Stave of thumb fracture, 599
Stay-knot, 342
Steinach operations, prostatic, 1505
Steinmann's pin, 614
Stenosing teno-vaginitis, 468
Stenosis after peptic ulcer, 1213
of intestine, 1235
of larynx, 1111
of pharynx, 1044
of pylorus, 1213
of trachea, 1111
Stenson's duct, wounds of, 1000
fistula of, 1000
'Stepping' ununited fractures, 563
Stercoraceous (fæcal) vomiting, 1371, 1379

Stereoscopic radiography, 301
Sterility after X-ray exposure, 304
Sterilization of dressings, hands, instruments, etc., 282
of skin, 284
of wounds, 67
Sterilizers, 280
Sterno-mastoid, congenital induration of, 483, 1107
tenotomy of, 472, 484
Sternum, affections of, 685
fracture of, 572
syphilitic disease of, 685
tuberculous disease of, 686
tumours of, 686
Sthenic fever, 24
Still's disease of joints, 753
Stings of insects, 243
Stitch, blanket, 237
buttonhole, 237
eversion, 238
glover's, 237
Halstead's, 237
suppuration, 283, 1165
Stitches, deep, 236
intestinal, 1166
subcuticular, 237
superficial, 236
Stoffel's operation, 532
Stokes-Gritti amputation of thigh, 1572
Stomach, affections of, 1190
anatomy of, 1190
cancer of, 1217
dilatation of, acute, 1223
excision of, 1208
fibromatosis of, 1216
foreign bodies in, 1194, 1221
hour-glass, 1214
radiography of, 1190
rupture of, 1193
stenosis of, 1213
test meal, 1192
tumours of, 1217, 1222
ulcer of. *See* Peptic ulcer
Stomatitis, 141, 981
mercurial, 981
Stone. *See* Calculus
Storage of blood, 38
Stovaine, 1605
Strabismus. *See* Squint
Strains. *See* Sprains
juxta-epiphyseal (Ollier), 537
Strangulated external hernia, 1368
complications, post-operative, 1377
gangrene of bowel in, 1370
operative treatment of, 1374
pathological effects of, 1369
persistence of symptoms after taxis, 1374
signs and symptoms of, 1371
stricture of intestine after, 1235
taxis in, 1373
Strangulation, acute, of testis, 1529
internal, of intestine by bands, 1382
of piles, 1416
Strangury, 1451, 1458, 1473
'Strawberry gall-bladder,' 1301
Streptococci, 43, 73
Streptococcus fæcalis, 44
mitis, 44
pneumoniæ, 44, 73
pyogenes, 43
salivarius, 44
viridans, 44
Stricture of anus, 1403
of appendix vermiformis, 1264
of intestine, 1235
of œsophagus, 1051, 1052
of rectum, 1422
of urethra, 1510
Strumpell-Marie's spondylitis deformans, 832
Stump exerciser, 1556
Stumps, after-care of, 1555
amputation, 1554
atrophy of, 1555
cicatrix of, 1554
conical, 1558
covering of, 1554
necrosis of, 1557
pain in, 1558
pathological changes in, 1557
spasmodic, 1558
Stye, 1654
Styloid process of ulna, fracture of, 589
Styptics, 261
Subaponeurotic (cranial) abscess, 842
cellulitis, 62
hæmatoma, 841
Subastragaloid amputation, 1569
dislocation, 720
Subclavian artery, aneurism of, 338
compression of, 262
ligature of, 346
Subclavicular dislocation of shoulder, 700
Subcoracoid dislocation of shoulder, 699
Subcranial abscess, 849, 894
inflammation, 894
Subcutaneous gumma, 157
infusion, 266
tenotomy, 471
whitlow, 246
Subdeltoid bursa, enlargement of, 479
Subdiaphragmatic abscess, 1182
Subglenoid dislocation of shoulder, 699
Subhyoid pharyngotomy, 1063
Sublingual abscess, 983
Subluxation of head of radius, 705
of joints, 692
of temporo-maxillary joint, 697
Submammary abscess, 1134
Submaxillary cellulitis, 63
gland, affections of, 1005
Submucous, resection of nasal septum, 1018
Subpericranial abscess, 842
hæmatoma, 841
Subperiosteal abscess, 640
gummata, 659
hæmorrhages in scurvy rickets, 667
Subphrenic abscess, 1182
Subspinous dislocation of shoulder, 700
Subtemporal decompression, 885, 917, 925
Subtrochanteric fracture, 610
osteotomy, 759, 769
Subungual exostosis, 196

Suction ball, Klapp's, 26, 444
Suicidal wounds, 1109, 1695
Sulphonamide preparations, 44, 74, 137, 1639, 1640, 1645, 1646, 1706, 1708
'Sulphur granules,' 182
Sun-baths, 299
Sunlight in rickets, 666
Superior longitudinal sinus, thrombosis of, 899
wounds of, 889
Suppression of urine, 1458
Suppuration, 42
leucocytosis in, 29
long-continued, 55
signs of, 50
Supraclavicular glands, enlargement of, in scirrhus, 1149
Supracondyloid amputation of thigh, 1572
fracture of humerus, 584
Supracoracoid dislocation of humerus, 700
Supramammary abscess, 1134
Suprapubic cystotomy, 1475, 1505
irradiation of bladder, 1482
lithotomy, 1488
prostatectomy, 1501
Surgeon's dress, 282
Surgery, general technique of operative, 278, 281
Surgical diseases of the skin and of the cutaneous appendages, 444
emphysema, 1079, 1110
kidney, 1448
neck of humerus, fracture of, 578
of scapula, fracture of, 577
shock, 270
Susceptibility, 5
Suture of arteries, 317
of bladder, 1471
of intestine, 1166
of kidney, 1444, 1462
of nerves, 389
of tendons, 461
of ureter, 1444
of wounds, 67, 69, 236
Sutures, preparation of, 283, 284
varieties of, 237, 283, 284
Swabs, 283
counting of, 283
Sylvester's method of artificial respiration, 1103
Sylvius, fissure of, 863
Symblepharon, 1650
Syme's amputation of foot, 1569
operation for epithelioma of lip, 953
for external urethrotomy, 1518
staff, 1518
Symond's tube, 1056
Sympathectomy, 97, 430, 441
indications for, 430
periarterial, 440
presacral, 443
renal, 1448
Sympathetic disease of eye, 1651
nerves, lesions of, 422
nervous system, surgery of, 426
Syndactylism, 497
Synostosis, 767
Synovial membranes of foot, 656
sheaths, suppuration in, 467
Synovial villi (fringes), 764
Synovitis, acute, 725
suppurative, 727
chronic, 739
filarial, 1688
gonorrhœal, 736
papillary, 739
pyæmic, 735
rheumatic, 737
serous, 739
syphilitic, 751
traumatic, 724
tuberculous, 742
Syphilides, 152
Syphilis, 145
bismuth in, 161
congenital (inherited), 164, 1671
incubation period, 148
infection, mode of, 147
iodide of potassium in, 163
laboratory diagnosis of, 146
malignant, 159
marriage after, 164
mercury in, 162
prevention of, 159
primary, 148
prognosis of, 158
salvarsan in, 159
secondary, 152
tertiary, 155
treatment of, 159, 168
tropical, 1670
Syphilitic affections of anus, 153, 166
of arteries, 154
of bone, 511, 659
of breast, 1138
of bursæ, 476
of calvarium, 659, 660
of choroid and retina, 155
of cornea, 167
of cranium, 848
of epididymis, 154
of epiphyses, 661
of eye, 154, 167
of joints, 751
of larynx, 1060
of lips, 950
of liver, 1289
of lymphatic glands, 153
of meninges, 898
of muscles, 465
of nipple, 1133
of nose, 660, 1015, 1016, 1024
of optic sheath, 395
of palate, 660, 1011
of periosteum, 154, 659
of pharynx, 1043
of rectum, 1422
of skin, 152
of spine, 830
of spleen, 1325, 1326
of sterno-mastoid, 483
of sternum, 660, 685
of teeth, 167
of testis, 1536
of thyroid, 1113
of tibia, 659, 662
of tongue, 984, 986
of tonsil, 153, 1041

Syphilitic alopecia, 154
caries, 636, 1012
chondro-arthritis, 751
endarteritis, 321
epiphysitis, 661
iritis, 154
keratitis, 167
osteo-chondritis, 661
pemphigus, 165
pseudo-paralysis, 661
rhinitis, 165
stomatitis, 982
stricture of rectum, 1422
synovitis, 751
ulcers, 156
Syphon drainage of bladder, 1476
Syringo-myelia, joint affections in, 762, 839
Syringo-myelocele, 811

T-shaped fracture of femur, 618
of humerus, 585
Tabes dorsalis, joint affections in, 759
mesenterica, 1189
Tænia echinococcus, 231
Talipes, 512
acquired, 512
calcaneo-valgus, 513, 515
calcaneus, 512, 515
compensatory, 512
congenital, 512
decubitus, 513
equino-varus, 513
equinus, 512, 513
paralytic, 512
valgus, 513, 515
varus, 512
Talma-Morison operation, 1187
Tannic acid for burns, 106
Tapotement, 290
Tapping a hydrocele, method of, 1542
Tarsectomy, 518
Tarso-metatarsal joint, amputation at, 1569
Tarsus, tuberculous disease of, 657
Taxis, in hernia, 1373
Taylor's brace, 828
Technique of operative surgery, 278, 281
Teeth, affections of, 954
extraction of, 957
in congenital syphilis, 167
in rickets, 663
tumours in connection with. *See* Odontomata
wisdom, 958
Tegmen tympani, disease of, 1645
Telangiectases, 368
from X-rays, 305
Teleradium therapy, 309
Temporal artery, compression of, 262
ligature of, 346
Temporo-maxillary joint, affections of, 977
arthritis of, 980
derangement of, 980
dislocation at, 696
osteo-arthritis of, 759
subluxation of, 697
synovitis of, 979
Temporo-sphenoidal lobe, abscess of, 900, 902
injuries of, 883
Tender spots in abdominal lesions, 1198
Tendo Achillis, affections of bursa beneath, 478
rupture of, 461
tenotomy of, 472
Tendon fixation, 474
implantation, 474
lengthening, 473
sheaths, affections of, 467
suppuration in, 467
tuberculous disease of, 468
shortening, 473
transplantation, 474
Tendons, adhesions of, 468
affections of, 458
contraction of, 463
displacement of, 459
of fingers, division of, 462
operations on, 471
rupture of, 460
suture of, 461
Tenesmus in cancer of rectum, 1428
in cystitis, 1473
in fissure-in-ano, 1412
in intussusception, 1388
in prostatic enlargement, 1498
in vesical calculus, 1484
in volvulus, 1394
Tennis elbow, 458
leg, 458
Tenoplasty, 473
Tenosynovitis, 467
Tenotomy, 471
of special tendons, 472
Teratoma, 188, 189, 225, 815
Tertiary syphilis, 155
Testicular sensation, loss of, 1536
Testis, absence of, 1527
atrophy of, 1532, 1546
congenital affections of, 1527
ectopia, 1528
gangrene of, 1529
hernia of, 1530, 1532, 1534, 1537
inflammation of, 1532
injuries of, 1529
inversion of, 1529
malposition of, 1528
neuralgia of, 1546
retention of, 1527
strangulation of, 1529
syphilis of, 1536
tuberculous disease of, 1534
tumours of, 1538
wounds of, 1530
Test meals, 1192
Tetanus, 123
ætiology of, 123
antitoxin, 127
bacillus of, 123
chronic, 126
fulminans, 125
head, 126
idiopathic, so-called, 124
neonatorum, 126
pathology of, 124
prophylaxis of, 127
symptoms of, 125
wounds, treatment of, in, 127
Tetany, 1127

Tetra operation cloths, 285
Thecal whitlow, 246
Thermo-cautery, 296
Thermo-therapy, 294
Thiersch's method of skin-grafting, 86
Thigh, amputation at, 1573
Third nerve, affections of, 395
Thomas's splint, 547, 778, 824
for fractures of the femur, 618
of humerus, 582
wrench, 521
Thomson-Walker's prostatectomy, 1503
urethrotome, 1517
Thoracic duct, obstruction of the, 370
pressure on, 370
rupture of, 370
Thoracoplasty, paravertebral, 1078, 1094
Thoracoscope, 1092
Thorax in rickets, 663
in scoliosis, 488
penetrating wounds of, 1080, 1706
Thorotrast, 335, 937, 1139
Threadworms in rectum, 1405
Throat, cut, 1109
Thrombo-angiitis obliterans, 95, 433
Thrombocytopenia, 33
Thrombosis, 356
arterial, 323
femoral, 358, 1268
gangrene from, 98
of cavernous sinus, 899
of intracranial sinuses, 899
of hæmorrhoids, 1416
of lateral sinus, 899, 1645
of mesenteric vessels, 1188, 1393
of superior longitudinal sinus, 899
of vena cava, 358
venous, 356
Thrombus, 356
organization of, 357
Thrush, 981
Thumb, amputation of, 1562
dislocation of, 706
stave, fracture of, 599
Thymic asthma, 1127
Thymus, affections of, 1127
Thyro-glossal cyst, 1107
duct, anatomy of, 1107
Thyro-hyoid space, wounds of, 1109
Thyroid, accessory, 1111
anatomy of, 1111
body, diseases of, 1111
cartilage, injuries of, 1058
extract in myxœdema, 1114
malignant disease of, 1125
vessels, ligature of, 347
Thyroidectomy, partial, 1119
Thyroiditis, acute, 1112
chronic, 1113
Thyrotomy, 1063
Thyrotoxic myasthenia, 1122
Tibia, fracture of, 623
with fracture of fibula, 625
internal malleolus, separation of, 625
rachitic, 511, 665
Tibial arteries, ligature of, 353, 354
nerves, injuries to, 422
Tibialis anticus, tenotomy of, 472
posticus, tenotomy of, 472
Tibio-fibular ligaments, rupture of, 719
Tic-douloureux, 395
facial, 408
Tiemann's catheter, 1513
Tinel's sign of nerve repair, 392
Toenail, ingrowing, 453
Toes, amputation of, 1567
deformities of, 523, 524
Tongue, abscess of, 983
affections of, 982
cancer of, 988
radiation in, 993
congenital abnormalities of, 982
in anæsthesia, 1580
operations on, 991
syphilitic disease of, 984, 986
tuberculous disease of, 986
tumours of, 987
ulceration of, 985
wounds of, 983
Tongue-tie, 982
Tonsillectomy, 1039
Tonsillitis, acute, 1037
chronic, 58, 1038
follicular, 1037
Tonsils, affections of, 1037
malignant disease of, 1041
syphilitic disease of, 153, 1041
tumours of, 1041
Tophi, 738
Topography, cranio-cerebral, 862
Torek's operation for misplaced testis, 1528
Torsion in treatment of hæmorrhage, 261
of omentum, 1188
of ovarian cyst, 1623
of spermatic cord, 1529
of spleen, 1320
Torticollis, 482
acute or rheumatic, 482
chronic, 483
spasmodic, 484
'Tour-de-maître' in passing catheters, 1514
Tourniquets in amputating, 1559
in arresting hæmorrhage, 259
Toxæmia, 42, 64
acute in burns, 105
in shock, 273
Trachea, foreign bodies in, 1072
stenosis of, 1111
wounds of, 1109
'Tracheal tug' in aneurisms of aorta, 333
Tracheitis, 1110
Trachelorrhaphy, 1633
Tracheo-bronchitis from foreign bodies, 1072
Tracheotomy, 1066
complications following, 1070
difficulties and dangers of, 1068
preliminary, 1066
tubes, 1067
Trachoma, 1658
Traction diverticula of œsophagus, 1049
Transfrontal exposure of pituitary tumours, 933
Transfusion, immuno, 39
of blood, 32
citrate method, 35
direct, 37
for hæmophilia, 270
for hæmorrhage, 270, 276

Transfusion of blood, for shock, 276
methods of, 35
testing blood for, 33
of blood-plasma, 38, 39
in burns, 108
of blood-serum, 38, 39
in burns, 108
Transhyoid pharyngotomy, 1063
Transillumination of antrum, 1027
of frontal sinus, 1030
of nasal fossæ, 1015
Transperitoneal uretero-lithotomy, 1462
Transplantation of skin, 86
of tendons, 474
Trans-sphenoidal exposure of pituitary tumours, 935
Transthyroid pharyngotomy, 1063
Transurethral prostatectomy, 1504
Transverse colon, cancer of, 1244
operation for, 1245
processes, fracture of, 791
Traumatic aneurism, 323
arteritis, 318
arthritis, 755
cephal-hydrocele, 850
delirium, 539
epilepsy, 938
fever, 539
flat-foot, 519
gangrene, 88, 99
genu valgum, 507
insanity, 875
myositis, 464
ossificans, 466
neurasthenia, 802
neuroma, 385, 387
spondylitis, 831
synovitis, 724
Travelling acetabulum, 770
Trendelenburg's operation, 1102
position, 1161
Trephining for fracture of skull, 860
for middle meningeal hæmorrhage, 801
operation of, 863
Treponema pallidum, 145
Trichina spiralis, 231
Trichinosis, 231
Trigeminal nerve, operations on, 401
neuralgia, 395, 396, 438
Trigger finger, 459
Triradiate pelvis, 664
Trismus, 125
Trochanters, fracture of, 611
Trophic changes after division of sensory nerves, 388
Tropical abscess of liver, 1284
fevers, surgical complications of, 1681
granulomata, 1675, 1677
hydrocele, 1689
surgery, 1669
Trunk neuroma, 203
Trusses for hernia, 1345, 1356
Trypanosoma cruzi, 1681
gambiense, 1681
rhodesiense, 1681
Trypanosomiasis, human, 1681
Tubal abortion, 1628
gestation, 1627
rupture of, 1627, 1628
Tuber ischii, bursa over, 479
fracture of, 602
Tubercle bacillus. *See under* Bacillus
miliary, 171, 1454
Tuberculin, 170
in diagnosis, 170
in treatment, 175
Tuberculomas, 914
Tuberculosis, 168
ætiology of, 168
bovine, 169
laboratory diagnosis of, 170
modes of infection in, 169
pathological anatomy of, 171
preventive vaccination in, 175
treatment of, 175
tropical, 1669
Tuberculous abscess, 172, 177, 745, 773, 819, 823, 829
cæcal tumour, 1234
caries of spine (Pott's disease), 815
dactylitis, 654, 656
disease of ankle-joint, 750
of appendix vermiformis, 1279
of arteries, 321
of astragalus, 750
of atlas and axis, 823
of bladder, 1476
of bone, 653
of brain, 914
of breast, 1138
of bursæ, 476
of cæcum, 1234
of cranium, 848
of elbow, 748
of epididymis, 1534
of epiphyses, 655
of Fallopian tube, 1626
of hip-joint, 749, 769
of intestine, 1234
of jaw, 961
of joints, 741
of kidney, 1454
of knee, 749
of larynx, 1060
of lung, 1092
of lymphatic glands, 376
vessels, 371
of meninges of brain, 899
of mesenteric glands, 1189
of muscles, 465
of nose, 1024
of os calcis, 657
of palate, 1011
of peritoneum, 1174, 1180
of phalanges, 656
of prostate, 1495
of rectum, 1422
of ribs, 685, 1138
of sacro-iliac joint, 749
of scaphoid, 657
of shoulder, 747
of skin, 449
of spine, 815
of sternum, 686
of tarsus, 657
of temporo-maxillary joint, 978
of testis, 1534
of thyroid, 1113

Tuberculous disease of tongue, 986
of vesiculæ seminales, 1548
of wrist, 748
endarteritis, 321
epiphysitis, 655
hydronephrosis, 1454
hydrops, 742, 743
ischio-rectal abscess, 1407
meningitis, 899
nephritis, 1454
osteitis, 655
papilloma of tongue, 986
perinephritis, 1454
periostitis, 654
peritonitis, 1174, 1180
sequestra, 654
sinuses, 173, 178
synovitis, 742
tenosynovitis, 468
tumour of cæcum, 1234
ulcers, 173, 1234
Tubes, Fallopian, diseases of, 1625, 1626, 1627
Tularæmia, 132
Tulip fingers, 447
Tulle gras, preparation of, 110
Tumor albus, 743
Tumour, Pott's puffy, 848, 895
Tumours, 186
benign, 187
carcinoid, 1280
classification of, 188
congenital sacral, 814
fatty. *See* Lipoma
intracranial, 906
malignant, 187
of acoustic nerve, 910
of adrenals, 1330
of antrum, 1031, 1032
of appendix, 1280
of bile-duct, 1310
of bladder, 1477
of bone, 676
of branchial clefts, 1106
of breast, 1141
of broad ligament, 1613, 1624
of cæcum, 1234
of cranium, 848
of gall-bladder, 1310
of intestine, 1236
of kidney, 1463
of larynx, 1061
of lip, 951
of liver, 1288
of lung, 1095, 1096
of lymphatic glands, 379
of mandible, 970
of maxilla, 961
of mediastinum, 1102
of mesentery, 1190
of muscle, 466
of nerves, 394
of nipple, 1133
of nose, 1031
of œsophagus, 1052
of optic nerves, 921
of ovary, 1620
of palate, 1012
of pancreas, 1317
Tumours of parotid, 1003
of pituitary body, 911, 928, 932
of rectum, 1424
of ribs, 686
of scalp, 842
of sebaceous glands, 454
of spinal cord, 833
of spine, 832
of spleen, 1325
of sternum, 686
of stomach, 1217, 1222
of testis, 1538
of thymus, 1127
of thyroid, 1125
of tongue, 987
of tonsil, 1041
of umbilicus, 1172
of upper jaw, 961
of uterus, 1612
of vulva, 1610
phantom, 1168
teratoid, 189, 226
Tunica vaginalis, hæmatocele of, 1530
hydrocele of, 1532
Tuning-fork ear tests, 1634
Turbinal bones, diseases of, 1021, 1024
Turkish baths, 295
Turpentine in frost-bite, 104
Twelfth dorsal nerve neuralgia, 419
Tympanic cavity, inflation of, 1636
membrane, appearances of, 1634
puncture of, 1639
rupture of, 1637
Typhoid bacillus. *See under* Bacillus
carriers, 45
cholecystitis, 1298
disease of joints, 735
ostitis, 651
state, 24
ulcer, perforation of, 1227
Typhoid-paratyphoid group, 45

Ulcer, callous, 83
chronic, 82
corneal, 1660
eczematous, 83
epitheliomatous, 81, 217
gummatous, 156
hypopyon, 1660
indolent, 83
irritable, 83
lupoid, 450
malignant, 81, 217, 1150
Marjolin's, 255
of bladder, 1477
of intestine (tuberculous), 1234
of palate, 1011
of pharynx, 1043
of tongue, 985
painful, 438
peptic, 1195
perforating, of foot, 447
phagedenic, 116, 151
serpiginous, 157
snail-track, 153, 1041
syphilitic, 153, 155, 157, 1041
traumatic, 80
trophic, 84
tuberculous, 173, 1234

Ulcer, typhoid, 1227
varicose, 83
Ulceration, 80
due to nerve injuries, 387, 388
duodenal, in burns, 105
intestinal, amœbic, 1284, 1683
of scars, 254
of umbilicus, 1172
Ulcerative colitis, 1230, 1683
endocarditis, 142
Ulcus molle, 142
Uleron, 137
Ulna, dislocation of, 703
fractures of, 588, 595
Ulnar artery, ligature of, 348
nerve, injury to, 417
Ultra-violet rays, 299
Umbilical biliary fistula, 1173
fæcal fistula, 1173
hernia, 1359
urinary fistula, 1173, 1470
Umbilicus, affections of, 1172
Undescended testis, 1527
malignant disease of, 1528
Undulant fever, 1682
Unna's treatment of ulcers, 84
Uræmia, 1440, 1451, 1458, 1499
in crush syndrome, 1702
Urate of ammonium calculus, 1482
Urea, estimation of, in blood, 1439
Urea-concentration test, 1438
Ureter, catheterization of, 1447, 1456
impaction of calculus in, 1458
implantation of, 1470, 1481
in tuberculous kidney, 1454
kinking of, 1441
pyogenic infection of, 1448
removal of, in nephrectomy, 1467
rupture of, 1444
Ureterocele, 1445
Uretero-lithotomy, 1462
Ureteroplasty, 1447
Urethra, affections of, 1507
calculus impacted in, 1510
changes of, in enlarged prostate, 1497
congenital malformations of, 1507
epithelioma of, 1510, 1611
false passages in, 1515
foreign bodies in, 1509
hæmorrhage from, 1514
irrigation of, 138
laceration of, 601, 1508
polypoid tumours of, 1510
stricture of, 1510
examination of, 1513
impassable, 1511
impermeable, 1511
organic, 1511
pathological effects of, 1512
spasmodic, 1510
treatment of, 1516
varieties of, 1510
Urethral caruncle, 1611
chancre, 150
dilators, Kollmann's, 139
fever, 1515
hæmaturia, 1508, 1510
Urethritis, 1510
gonorrhœal, 135
Urethritis, gouty, 136, 1510
pyogenic, 136
Urethroscope, 138
Urethrotomy, external, 1518
internal, 1517
Uric acid calculus, 1482
Urinary fever, 1515
fistula, 1173, 1470
Urine, bacilli in, 1472
examination of, 1438
extravasation of, 1492, 1515, 1520
treatment of, 1471, 1521
incontinence of, 1491
in cystitis, 1474
residual, 1491
retention of, 804, 1419, 1492
suppression of, 1458
Uroselectan B, 1437
Uterus, adenomyoma of, 1616
carcinoma of, 1616
displacements of, 1629
fibroids of, 1612
malformations of, 1631
uterus bicornis, 1632
uterus didelphys, 1631
uterus fœtalis, 1631
uterus pubescens, 1631
polypus of, 1616
prolapse of, 1629
sarcoma of, 1619
Uvula, bifid, 1005
elongation of, 1013

Vaccination, 6
Vaccine, B.C.G., 175
Vaccines, 9
Vagina, absence of, 1632
inversion of, 1630
Vaginal hysterotomy, 1614
Vaginitis, gonorrhœal, 140
Vagus nerve, affections of, 409
Valgus, spurious, 519
Valsalva's method of inflating middle ear, 1636
Varicocele, 1544
in carcinoma of kidney, 1465
Varicose aneurism, 318
eczema, 84, 364
ulcer, 83, 364
veins, 362
excision of, 366
hæmorrhage from, 364, 366
inflamed, 366
injection treatment of, 365
Varix, 362
aneurismal, 317
arterial, 842
of œsophagus, 1052
of saphena vein, 363, 1356
Vasa efferentia, ligation of, 1506
Vas deferens, rupture of, 1532
tuberculous disease of, 1534
Vaso-ligation, 1505
Vater, ampulla of, stone impacted at, 1305
Veins, affections of, 356
entrance of air into, 269
Vena cava, thrombosis of, 358
Venesection, 366

Venoclysis, 39
Venous hæmorrhage, 250, 266
secondary, 268
sinuses, thrombosis of, 899
wounds of, 889
thrombosis, 356
Ventral hernia, 1278
suspension, 1631
Ventricular estimation, 870
puncture, 868
Ventriculography, 302, 868, 903
Ventriculoscope, 846
Vermiform appendix. *See* Appendix vermiformis
Verruca. *See* Warts
necrogenica, 449
Verruga peruana, 1682
Vertebral artery, hæmorrhage from, 263
ligature of, 347
Vertical rotation of the patella, 712
Vertigo, 884, 902, 923
Vesical calculus. *See* Calculus, vesica
Vesico-vaginal fistula, 1633
Vesiculæ seminales, affections of, 1548
tuberculosis of, 1548
Vesiculitis, 1548
Vibrion septique (Pasteur), 114
Vibro-massage, 291
Villi, synovial, 755, 764
Villous tumour of bladder, 1477
Vincent's angina, 1043
Visceroptosis, 1320
Vitamin, antirachitic, 662
Volkmann's ischæmic contracture, 464, 555
Volvulus, 1393, 1394
Vomiting after concussion, 875
cerebral, 923
fæcal, 1371, 1379
in cancer of stomach, 1219
in congenital pyloric stenosis, 1215
in intestinal obstruction, 1371, 1379, 1381
in movable kidney, 1442
in peptic ulcer, 1198
in peritonitis, 1175
in strangulated hernia, 1371
pernicious, 1585
post-operative, 1585
Von Bechterew's spondylitis deformans, 832
Von Jaksch's anæmia, 1329
Von Pirquet's skin reaction, 171
Von Recklinghausen's disease, 671
Vulva, tumours of, 1610
Vulvitis, 140, 1609
gangrenous, 118, 1609
membranous, 1610
Vulvo-vaginitis, 141

Wagstaffe's fracture, 625
Wakeley-Rawling retractors, 926
Walking-calliper, 616
Wallerian degeneration, 385
Walton's anæsthesia outfit, 1589
War surgery, 1693
Wardill's operation, 1010
Wardrop's operation for aneurism, 331
Warts, 448. *See also* Papilloma
Warts, anatomical, 450
butcher's, 244
gonorrhœal, 140
Hutchinson's, 153, 986
malignant, 217
on lip, 951
venereal. *See* Gonorrhœal
War-wounds, 1710
abdominal, 1712
of bones, 1710
of brain, 1717
of chest, 1716
of colon, 1715
of head, 1716
of intestine, 1714
of joints, 1710
of kidney, 1716
of liver, 1716
of pancreas, 1716
of rectum, 1715
of spine, 1718
of spleen, 1716
Washington Lyon sterilizer, 280
Wassermann's reaction, 147
Water-blast, effects of, 1699, 1700
protection against, 1700
Watson Jones's method for spinal fracture, 793
Wax in ear, 1637
Waxy disease, 56
'Weaver's bottom,' 479
Webbed fingers, 497
Weber's tuning-fork test, 1635
Weight extension in fractures, 545
Weil's disease, 1683
Weir Mitchell's 'glossy skin,' 388
Whalebone bougie, 1051
Wheelhouse's operation for impassable stricture, 1519
staff, 1519
Whitehead's operation for cancer of tongue, 991
varnish, 992
White swelling, 742, 743
Whitlow, 245
Whitman's operation for talipes, 517
treatment for fracture of cervix femoris, 605
Wimshurst electrical machine, 303
Winged scapula, 413, 493
Winnett Orr treatment of compound fractures, 559, 1710
Wire suture set, 908
Wirsung, duct of, 1312
Wisdom teeth, 958
Wolfe's method of skin grafting, 86
Wolffian body, cysts in, 228
Wolfler's intestinal suture, 1167
Woody thyroid, 1113
tongue, 183
Woolsorter's disease, 132
Wool truss, 1346
Word-deafness, 923
Wounds, 234
abdominal, 1169, 1702
adhesive plaster for, 238
amputation after, 240
antiseptic treatment of, 278
arterio-venous, 317

Wounds, aseptic treatment of, 280
bullet, 1693
by needles, 242
Carrel-Dakin treatment of, 69
contused, 239
drainage of, 238
fish-hook, 243
healing of, 250
incised, 235
infection of, 64, 239
lacerated, 239
of air-passages, 1109
of arteries, 316
of bladder, 1470
of brachial plexus, 411
of brain, 880, 886
of bursæ, 475
of colon, 1704
of eye, 1650
of gall-bladder, 1292
of head, 1706
of heart, 1100
of internal carotid, 891
of intestine, 1227, 1704
of joints, 691, 1700
of kidney, 1706
of larynx, 1058, 1109
of liver, 1281, 1706
of lung, 1082
of middle meningeal artery, 889
of neck, 1109
of nerves, 384
of pancreas, 1313, 1706
of rectum, 1404, 1705
of scalp, 841, 1706
of spine, 789, 1708
of spleen, 1706
of Stensen's duct, 1000
of stomach, 1193
of testis, 1530
of thorax, 1080, 1706
of throat, 1109
of tongue, 983
of trachea, 1109
of urethra, 600, 1508
of venous sinuses of head, 889
open, 235
poisoned, 243, 245
primary suture of, 67, 236
union of, 250
punctured, 242
repair of, 250
secondary suture of, 69
shrapnel, 1694
sterilization of, 67, 236
suicidal, 1109, 1695
ture of, 236
vord-bayonet, 242
eatment of, 236, 240
Wounds, treatment of, by B.I.P.P., 67, 70
war, 1693
Wright's physiological method of treating wounds, 71
Wrist-drop, 414
Wrist-joint, acute arthritis of, 733
amputation at, 1563
ankylosis of, 767
dislocation of, 705
effusion into, 722
excision of, 786
position of rest, 723
tuberculous disease of, 748
Wry-neck. *See* Torticollis

Xanthine calculus, 1483
Xanthochromine, 834
X-ray burns, 303
cancer, 303
dermatitis, 303
effects on normal tissues, 303
in diagnosis of aneurism, 333
of cervical rib, 486
of fractures, 539, 546
of gastric affections, 1190, 1201, 1220
of intestinal lesions, 1223
of œsophageal conditions, 1047
of renal calculus, 1455, 1458
of tuberculous kidney, 1455
of ureteral calculus, 1458
of vesical calculus, 1485
in treatment of cancer, 305
of exophthalmic goitre, 1124
of lupus, 311, 451
erythematosus, 452
of lymphadenoma, 381
of rodent ulcer, 457
of sarcoma, 683
pastille dose (Sabouraud), 304
results of prolonged exposure, 303
X-rays (Röntgen), 301. *See also* Radiography, Radiotherapy

Yaws (framboesia), 1671
Yellow fever, 1683
softening of brain, 881
Y-ligament of hip-joint, importance of, 707
Y-shaped fracture of femur, 618
of humerus, 585

Z-operation on tendons, 473
Ziehl-Neelsen method of staining bacilli, 170, 180
Zinc ionization, 55
Zygoma, fracture of, 566