UNIVERSAL
LIBRARY

OU_170190

UNIVERSAL
LIBRARY

HISTOLOGY

LONGMANS, GREEN AND CO. LTD.

39 PATERNOSTER ROW, LONDON, E.C. 4
6 OLD COURT HOUSE STREET, CALCUTTA
53 NICOL ROAD, BOMBAY
167 MOUNT ROAD, MADRAS

LONGMANS, GREEN AND CO.

55 FIFTH AVENUE, NEW YORK
221 EAST 20TH STREET, CHICAGO
TREMONT TEMPLE, BOSTON
128–132 UNIVERSITY AVENUE, TORONTO

THE ESSENTIALS OF HISTOLOGY

DESCRIPTIVE AND PRACTICAL

FOR THE USE OF STUDENTS

BY

SIR EDWARD SHARPEY SCHAFER, F.R.S.

PROFESSOR OF PHYSIOLOGY IN THE UNIVERSITY OF EDINBURGH

TWELFTH EDITION

REVISED BY THE AUTHOR, WITH THE CO-OPERATION OF H. M. CARLETON, PH.D., LECTURER ON HISTOLOGY IN THE UNIVERSITY OF OXFORD

LONGMANS, GREEN AND CO.

LONDON • NEW YORK • TORONTO

1929

BIBLIOGRAPHICAL NOTE

First Edition, May 1885; *Second Edition, January* 1887; *Third Edition, May* 1892; *Fourth Edition, April* 1894; *Fifth Edition, June* 1898; *Sixth Edition, May* 1902; *Seventh Edition, January* 1907; *Eighth Edition, September* 1910; *Ninth Edition, January* 1914; *Tenth Edition, June* 1916; *Eleventh Edition, July* 1920; *Twelfth Edition, September* 1929.

Made in Great Britain

PREFACE

TO THE

TWELFTH EDITION

In preparing the twelfth edition of the 'Essentials of Histology' the author has had the aid of Dr. H. M. Carleton, Lecturer on Histology in the University of Oxford. The work has been revised throughout, numerous new illustrations having been added in the form of photographs; the success of these is largely due to Mr. James Pirie, Technical Assistant in the Department of Physiology in the University of Edinburgh. A plate illustrating the characteristic staining reactions of the white corpuscles of blood has been introduced; for the colouring of this plate we are indebted to Mr. Richard Muir, Demonstrator of Technical Methods in the Department of Pathology. Mrs. May L. Cameron, Lecturer on Histology in the University, has given valuable aid in the selection of microscopic preparations suitable for reproduction, and has contributed numerous details of histological methods; these methods, as in previous editions, are mainly dealt with in an Appendix. The authorship of other contributions is acknowledged in those parts of the text which deal with the subjects concerned.

CONTENTS

INTRODUCTORY

PAGE

ENUMERATION OF THE TISSUES—GENERAL STRUCTURE OF CELLS—CELL-DIVISION - - - - - - - - - - - - - - - 1

LESSON I.

USE OF THE MICROSCOPE—EXAMINATION OF COMMON OBJECTS - - - - 28

LESSONS II. AND III.

HUMAN BLOOD-CORPUSCLES—DEVELOPMENT OF BLOOD-CORPUSCLES—BONE-MARROW - - - - - - - - - - - - - - - 32

LESSON IV.

ACTION OF REAGENTS UPON HUMAN BLOOD-CORPUSCLES - - - - - 57

LESSON V.

BLOOD-CORPUSCLES OF OVIPARA - - - - - - - - - - - 62

LESSON VI.

AMŒBOID PHENOMENA OF LEUCOCYTES - - - - - - - - - 68

LESSON VII.

STRATIFIED, PAVEMENT AND GLANDULAR EPITHELIUM: SECRETING GLANDS - 73

LESSON VIII.

COLUMNAR AND CILIATED EPITHELIUM: ACTION OF CILIA - - - - - 82

LESSON IX.

CONNECTIVE TISSUES: AREOLAR TISSUE—RETICULO-ENDOTHELIUM—ADIPOSE TISSUE—RETICULAR TISSUE - - - - - - - - - - 91

LESSON X.

PAGE

CONNECTIVE TISSUES (*continued*): ELASTIC TISSUE—FIBROUS TISSUE—MINOR VARIETIES OF CONNECTIVE TISSUE—DEVELOPMENT OF CONNECTIVE TISSUE - - - - - - - - - - - - - - - 108

LESSON XI.

CONNECTIVE TISSUES (*continued*): ARTICULAR CARTILAGE—SYNOVIAL MEMBRANES - - - - - - - - - - - - - - - 116

LESSON XII.

CONNECTIVE TISSUES (*continued*): COSTAL CARTILAGE—YELLOW FIBRO-CARTILAGE—WHITE FIBRO-CARTILAGE—DEVELOPMENT OF CARTILAGE - 121

LESSON XIII.

CONNECTIVE TISSUES (*continued*): BONE - - - - - - - - 127

LESSON XIV.

CONNECTIVE TISSUES (*continued*): OSSIFICATION - - - - - - - 133

LESSON XV.

MUSCLE: STRUCTURE OF CROSS-STRIATED MUSCLE - - - - - - 145

LESSON XVI.

MUSCLE (*continued*): CONNEXION OF MUSCLE WITH TENDON—BLOOD-VESSELS OF MUSCLE—DEVELOPMENT OF MUSCLE—CARDIAC MUSCLE—PLAIN MUSCLE - - - - - - - - - - - - - - - 156

LESSON XVII.

TISSUES OF THE NERVOUS SYSTEM: NERVE-FIBRES - - - - - - 166

LESSON XVIII.

TISSUES OF THE NERVOUS SYSTEM (*continued*): NERVE-CELLS—GANGLIA—DEGENERATION AND REGENERATION OF NERVE-FIBRES AND NERVE-CELLS—NEUROGLIA—DEVELOPMENT OF NERVE-CELLS AND NERVE-FIBRES - - - - - - - - - - - - - - - 176

LESSON XIX.

MODES OF TERMINATION OF NERVE-FIBRES—SENSORY NERVE-ENDINGS—MOTOR NERVE-ENDINGS - - - - - - - - - - - - 204

LESSON XX.

THE LARGER BLOOD-VESSELS - - - - - - - - - - - 221

LESSON XXI.

PAGE

THE SMALLER BLOOD-VESSELS—LYMPH-VESSELS—SEROUS MEMBRANES—MICROSCOPIC STUDY OF THE CIRCULATION—DEVELOPMENT OF BLOOD- AND LYMPH-VESSELS - - - - - - - - - - - - 232

LESSON XXII.

LYMPH-GLANDS—SPLEEN—TONSILS AND OTHER LYMPHOID STRUCTURES—THYMUS - - - - - - - - - - - - - - 249

LESSON XXIII.

ENDOCRINE GLANDS: SUPRARENAL CAPSULES—CAROTID AND COCCYGEAL GLANDS—THYROID BODY—PARATHYROIDS—PITUITARY BODY—PINEAL GLAND - - - - - - - - - - - - - - 269

LESSONS XXIV. AND XXV.

SKIN—NAILS—HAIRS—GLANDS OF THE SKIN—MAMMARY GLANDS - - 290

LESSON XXVI.

HEART - - - - - - - - - - - - - - - - 315

LESSON XXVII.

LARYNX—TRACHEA—LUNGS - - - - - - - - - - - 323

LESSON XXVIII.

STRUCTURE AND DEVELOPMENT OF THE TEETH - - - - - - - 335

LESSON XXIX.

TONGUE AND GUSTATORY ORGANS—MUCOUS MEMBRANE OF THE MOUTH—PHARYNX—ŒSOPHAGUS - - - - - - - - - - - 347

LESSON XXX.

SALIVARY GLANDS - - - - - - - - - - - - - 355

LESSON XXXI.

STOMACH - - - - - - - - - - - - - - - 364

LESSONS XXXII. AND XXXIII.

SMALL AND LARGE INTESTINE - - - - - - - - - - - 374

LESSON XXXIV.

LIVER - - - - - - - - - - - - - - - - 391

LESSON XXXV.

PAGE

PANCREAS - - - - - - - - - - - - - - 400

LESSON XXXVI.

KIDNEY—URETER AND BLADDER - - - - - - - - - 406

LESSON XXXVII.

MALE GENERATIVE ORGANS - - - - - - - - - - 419

LESSON XXXVIII.

FEMALE GENERATIVE ORGANS - - - - - - - - - - 439

LESSON XXXIX.

SPINAL CORD: GENERAL STRUCTURE - - - - - - - - - 460

LESSON XL.

SPINAL CORD (*continued*): TRACTS AND CELL-GROUPS - - - - - 467

LESSON XLI.

MEDULLA OBLONGATA - - - - - - - - - - - - 479

LESSONS XLII. AND XLIII.

PONS—MESENCEPHALON—THALAMENCEPHALON - - - - - - - 495

LESSONS XLIV. AND XLV.

CEREBELLUM AND CEREBRUM - - - - - - - - - - 520

LESSONS XLVI., XLVII., AND XLVIII.

EYE - - - - - - - - - - - - - - - - 544

LESSONS XLIX. AND L.

NOSE AND EAR - - - - - - - - - - - - - - 572

APPENDIX.

METHODS - - - - - - - - - - - - - - - 587

INDEX - - - - - - - - - - - - - - - 617

Corrigenda.

PAGE

5. Description of fig. 4, line 1. *For* " I " *read* " In."
18. Description of fig. 25, line 1. *For* " to " *read* " into."
43. Line 2. Insert bracket after " Group I."
47. Line 6 from bottom. *For* " syncytial " *read* " syncytia."
49. Footnote, line 2 from bottom. *For* " with " *read* " into."
58. Line 11. *For* " in " *read* " to."
96. Line 9 from bottom. Omit the commas.
103. Line 4. *For* " or " *read* " of."
113. Line 4 from bottom. Omit comma after " elastic."
143. Fig. 173. Insert " *d* " an inch below " *c'*."
221. Line 4. *For* " Van Giesen " *read* " Van Gieson."
269. Line 1 of § 3. *For* " Zencker " *read* " Zenker."
276. Description of fig. 370, line 1. *For* " retciulum " *read* " reticulum."
321. Fig. 432. The letters " A " and " B " have been omitted.
327. Fig. 438. The letters *a*, *b*, *c*, *d*, are placed a little too low.
336. Bottom line. *For* " 399 " *read* " 339."
348. Title of fig. 467, line 1. Insert colon after " papilla."
350. Fig. 471. The upper *p* has been omitted from this figure.
371. Fig. 502. The letter " *c* " has been omitted ; it should be on the right of " *l*."
381. Fig. 516. The letters *e*, *c*, *l*, are placed $\frac{1}{8}$ inch too low.
384. Description of fig. 521, line 2. *For* " lymphoip " *read* " lymphoid."
408. Line 9. *For* " 553 " *read* " 550."
411. Title of fig. 555. *For* " convuluted " *read* " convoluted."
432. Fig. 586. " *sp* " has been omitted at the upper right-hand corner of this figure.
504. Fig. 656. *For* " ateral " *read* " lateral."
580. Line 5 from bottom. *For* " *l.sp.*" *read* " *sp.l.*"
582. Description of fig. 746, line 2. *For* " *l.sp.*" *read* " *sp.l.*"
591. Line 16 from bottom. *For* " susa " *read* " formol," and *for* " general " *read* " neutral."

THE ESSENTIALS OF HISTOLOGY

INTRODUCTORY.

ENUMERATION OF THE TISSUES AND GENERAL STRUCTURE OF ANIMAL CELLS.

Animal Histology [1] is the science which treats of the minute structure of the tissues and organs of the animal body; it is studied with the aid of the microscope, and is therefore also termed **Microscopic Anatomy.**

Every part or organ of the body, when separated into minute fragments, or when examined in thin sections, is found to consist of certain textures or tissues, which differ in their arrangement in different organs, but each of which exhibits characteristic structural features.

The following is a list of the principal tissues which compose the body:

Epithelial.

Connective: Areolar, Fibrous, Elastic, Reticular, Lymphoid, Adipose, Cartilage, Bone.

Muscular: Voluntary or striated, Involuntary or plain, Cardiac.

Nervous.

Blood and **Lymph.**

Some organs are formed of several of the above tissues, others contain only one or two.

It is convenient to include such fluids as the *blood* and *lymph* among the tissues, because they are studied in the same manner and contain cell-elements similar to those met with in some of the other tissues.

All the tissues are, prior to differentiation, masses of *cells* (embryonic cells). In some tissues elements become developed which take the form of *fibres*. Thus the epithelial tissues are composed throughout life entirely of cells, only slightly modified in structure, and the nervous and muscular tissues consist of cells which are greatly modified to form the characteristic element of those tissues. On the other hand, in the connective tissues an amorphous material becomes formed between the cells which is termed *intercellular substance* or *ground-substance*, and in this substance fibres make their appearance, sometimes, as in the fibrous connective tissues, in so large an amount as to occupy the whole of the intercellular substance, and greatly to preponderate over the cells. This ground-substance, by virtue of its

[1] From *ἱστός*, a web or texture.

incorporating a certain amount of inorganic chlorides, has the property of becoming stained brown or black by nitrate of silver and subsequent exposure to light, in which case the cells, which remain unstained, look like white spaces (cell spaces) in the ground-substance (see figs. 107, 108). When an epithelial tissue or an epithelium-like arrangement of cells is similarly treated, the narrow interstices between the cells are also stained (see fig. 83), from which it is concluded that a similar substance exists in small amount between the cells of such a tissue. It has here been termed cement-substance, but it is better to apply to it the general term *intercellular substance*.

The cells of a tissue are not always separate from one another, but are in some cases connected by bridges of the cell-substance, which pass across the intercellular spaces. This is especially the case with the cells of the higher plants, but it has also been found to occur in many animal tissues; *e.g.* in some varieties of epithelium (see figs. 78, 79), and in cardiac and plain muscular tissue. Occasionally the connexion of the cells of a tissue is even closer, and lines of separation between them are faint or absent. The term *syncytium* is given to any such united mass of cells.

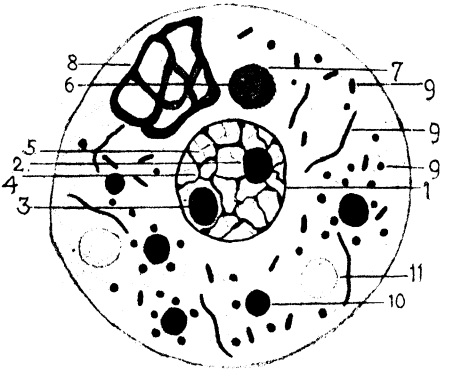

FIG. 1.—DIAGRAM OF CELL.
(H. M. Carleton.) Highly magnified.

1, nucleus; 2, karyosome; 3, nucleolus (plasmasome); 4, chromatin meshwork of nucleus; 5, 'linin' meshwork; 6, centriole; 7, centrosome; 8, Golgi apparatus; 9, 9, 9, mitochondria (granular, rod-shaped, thread-like); 10, metaplasmic inclusions; 11, vacuoles.

Some of the structures shown in this diagram are only visible in fixed and stained specimens.

THE STRUCTURE AND FUNCTIONAL CHANGES OF CELLS (CYTOLOGY).

A cell (fig. 1) is a minute portion of living substance (*protoplasm* or *cytoplasm*) which is enclosed by a *cell-membrane* and always contains a specially differentiated part which is known as the *nucleus*. The living substance including the nucleus is collectively known as *bioplasm*.

The study of the changes which the several parts of a cell undergo during life in the performance of its functions constitutes an important part of Physiology.

PROTOPLASM OR CYTOPLASM.

In living cells (fig. 8) the cytoplasm is seen with difficulty as a colourless, apparently fluid matrix, but it may contain various inclusions which are more apparent. There has been much discussion as to the structure of cytoplasm; but in all probability living protoplasm is devoid of structure, other than that met with in colloidal fluids generally. Various appearances of structure—granular, reticular, fibrillar—may be exhibited by it after fixation and staining, but these seem in many cases to have been determined

by the action of the fixative which has been employed, and do not necessarily represent modifications of structure.

Included in the cytoplasm of every cell and regarded as part of its living substance are (1) a minute particle termed the *centriole* [1]; (2) numerous other particles, often having the appearance of short threads, termed *mitochondria* [2]; (3) the *apparatus of Golgi*, which, although difficult of observation in the living cell, is demonstrable in most cells after fixation.

Chemical constitution.—The cytoplasm of the living cell consists of a complex mixture of colloids (emulsoids). Usually the colloidal matter is in the *sol*, sometimes in the *gel*, condition. In the former case, the colloidal particles, examined with the dark ground condenser, may be seen in active Brownian motion.

Chemically cytoplasm consists of proteins and nucleoproteins associated with carbohydrates, fats and lipoids; it also contains various inorganic salts. These constituents are mostly in solution, for from 50 to 90 per cent. of water enters into its composition. The *membrane* of the cell contains such lipoids as lecithin, as well as cholesterol; these substances also compose, at least in part, the *nucleus*, the *mitochondria*, and the *Golgi apparatus*.

Properties of living matter.—Living cells exhibit (1) irritability or the property of responding to stimuli; (2) chemical (metabolic) changes which result in assimilation or the taking in of nutrient matter and its conversion into living substance (anabolism), and disassimilation, the breaking down of such substance (katabolism); (3) reproduction, resulting in the multiplication of individuals. Of these properties, (2) and (3) are governed by the nucleus, and (3) is initiated by the centriole. The irritability of the cell depends mainly upon the protoplasm. It is in consequence of this property that protoplasm reacts, sometimes by contraction, sometimes by relaxation, to mechanical, chemical, thermal and electrical stimuli, and in the case of some cells (*e.g.* the pigment-cells and cones of the retina) to the stimulus of light. The amœboid movements of cells are also a manifestation of irritability, being produced and influenced by various external conditions (stimuli). Sometimes the result of a stimulus is to cause a cell or organism to move towards the source of excitation (attraction); in other cases the movement is in the reverse direction (repulsion). The terms positive and negative chemotaxis, phototaxis, thermotaxis, thigmotaxis, and the like, are used to indicate the nature of the effects produced by various forms of stimulation (chemical, light, heat, mechanical, and so on).

During life the cytoplasm often exhibits movements which are apparently spontaneous. When the cell is not enclosed by an unyielding membrane such as that which encloses most plant cells, a change in the shape or even in the position of the cell may be thereby produced. This is characteristically shown in the movements of the unicellular organism known as the *Amœba* (fig. 2); hence the term *amœboid* by which such movements and the phenomena dependent upon them are generally designated.

Cell-membrane.—A fine pellicle covers the exterior of the protoplasm of all living cells. This pellicle is composed of a material which, although not soluble in water, is permeable to watery fluids, and may even allow the passage of solids without permanent rupture. It has been suggested by Overton that such a material may be furnished by the lipoids. In plant cells and in some animal cells there is a thick cell-membrane; but it is then

[1] Formerly known as the *attraction-particle*, from the radiating lines which lead to it from all parts of the cytoplasm. But it is more probable that these lines represent repulsion rather than attraction, and it is therefore better to employ the non-committal term *centriole*.

[2] From μίτος, a thread, and χόνδρος, a grain.

mechanically. By using hollow needles fluids can be introduced into the cell through the surface film. By this means it has been possible, with the aid of indicator dyes, to determine the pH of the cytoplasm in living cells.

Proceeding in this way, R. Chambers found the pH of the living nucleus in various cells of *Rana* and *Necturus* to be about 7·5, whether normal or injured, but the pH of the cytoplasm to be distinctly more acid, being about 6·9 in the normal state, and about 5·3 when injured and cytolising. J. and D. M. Needham found the pH of the cytoplasm of *Amœba proteus* to be about 7·5: Pollack puts it lower (6·6 to 7·2), but the variety of Amœba may have been different. The cytoplasm has considerable buffering power and resists the action of acids if not in excess. The oxidation-reduction intensity (rH) has been similarly determined.

Remarkable results have been obtained by injecting into the interior of the cytoplasm substances which are toxic when added to the environment. Thus Pollack, working with Chambers, found that a solution of picric acid or fairly strong alcohol can be introduced into the cytoplasm without producing any deleterious effect, and Brinley makes the same statement for hydrocyanic acid and cyanides.

The injection of salts of the monovalent electrolytes, Na and K, increases the fluidity of the cytoplasm, whilst the salts of Ca and Mg produce coagulation. The electrolytes appear to maintain a balanced condition of the colloids in living protoplasm, being so proportioned that the coagulating action of one kind is offset by the dispersive action of the other kind.

If the surface pellicle of a cell is torn the fluid protoplasm may exude, but the exudation immediately forms a new membrane around itself; this, however, only occurs in the presence of calcium salts.

By the method of micro-dissection it has also been determined that the astral configurations (division spindle, etc.) seen during cell-division are gelated portions of the cytoplasm. The mitochondria and the chromosomes also appear to be gels: they can be stretched by the micro-needles and on release regain their original length.[1]

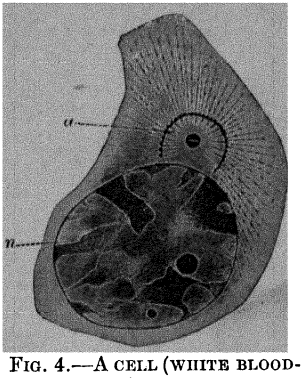

FIG. 4.—A CELL (WHITE BLOOD-CORPUSCLE) SHOWING ITS CENTRIOLE AND CENTROSOME. (M. Heidenhain.)

In this, as in most cases, the centrosome, *a*, lies near the nucleus, *n*.

Centriole.—All cells of the higher animals which are still capable of mitotic division contain this body. Highly specialised cells, which have lost the capability of reproduction, such as nerve-cells, are without it. In rounded or polyhedral cells the centriole lies close to the nucleus; it is often double. In elongated cells (*e.g.* in columnar epithelium) it usually lies between the nucleus and the free end of the cell. It is very resistant to reagents. It is deeply stained by iron-hæmatoxylin. When a cell is about to divide, its centriole divides first, and the two centrioles thus produced gradually separate from one another and pass to opposite poles of the cell. From each of the two centrioles a number of what appear to be fine fibres diverge towards the equator of the dividing nucleus and, joining with those from the opposite centriole, constitute what is known as the *achromatic spindle* (p. 20), to which the divided chromosomes of the nucleus become attached,

[1] For an account of the chief results obtained by methods of micro-dissection see R. Chambers, 'The Nature of the Living Cell,' in *Colloid Chemistry*, vol. ii, 1928.

and along which they appear to be guided towards the centrioles to constitute the daughter nuclei (see Cell-division).

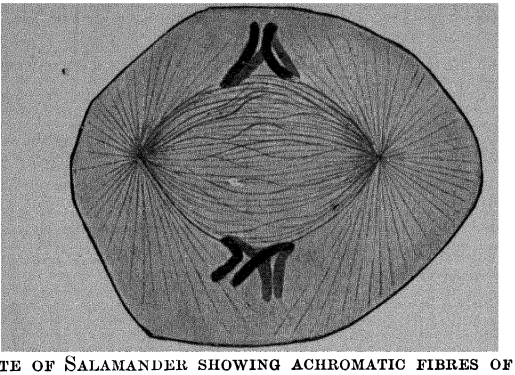

FIG. 5.—SPERMATOCYTE OF SALAMANDER SHOWING ACHROMATIC FIBRES OF SPINDLE AND OTHER FIBRES RADIATING FROM CENTRIOLES. (Flemming.)
Four chromosomes are represented at the equator of the spindle.

In some cells the centrioles are multiple; this is frequently the case with leucocytes, and always with giant-cells found in bone-marrow and elsewhere (fig. 6). The cytoplasm immediately surrounding the centriole is often different

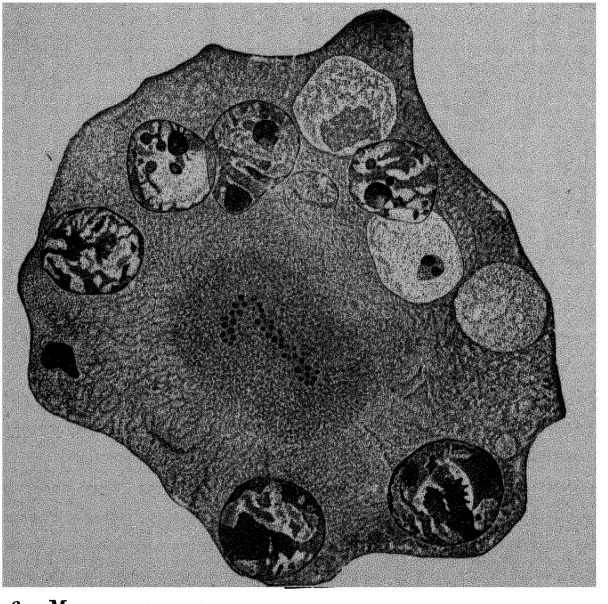

FIG. 6.—MULTI-NUCLEATED GIANT-CELL FROM LYMPH GLAND OF RABBIT.
(M. Heidenhain.)

in appearance from the rest, and is spoken of as the *centrosome*. This is sometimes itself enveloped by a feltwork of irregular filamentous particles which form a kind of capsular covering to it (M. Heidenhain, Champy and Gley). Including the radiating fibres and the fibres of the division spindle when this is formed,

the centrosome is considered by some to be distinct in nature from the general protoplasm, and has been termed *archoplasm.* No centriole has been found in the cells of the higher plants, although centrosomes and archoplasmic fibres are well marked in them, especially during cell-division.

Mitochondria.—These are either punctate, rod-like, or filamentous bodies (fig. 7); they appear to exist in all cells, plant and animal. They can be observed in the living cell when viewed with dark ground illumination (fig. 8); they then often appear to be in constant movement. Filamentous mitochondria have been seen to segment and reunite. In round or polyhedral cells the mitochondria are generally evenly distributed (fig. 9), but in elongated

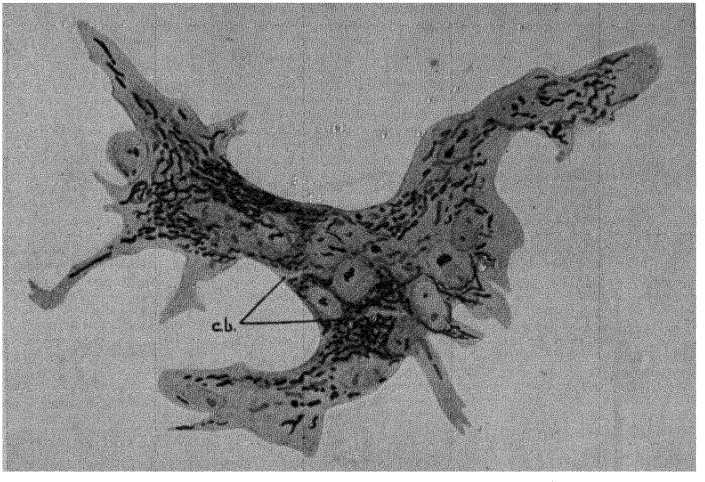

FIG. 7.—A GIANT-CELL (FROM BONE OF EMBRYO CHICK OF 10½ DAYS) STAINED WITH IRON-HÆMATOXYLIN TO EXHIBIT THE MITOCHONDRIA. (Honor B. Fell.)
The cell has been produced by the coalescence of smaller cells: cell-boundaries are seen at *cb.*

cells, such as the columnar cells of the intestine, they form two groups, one at each end of the cell. Mitochondria are probably composed of protein and lipoids, the latter being in larger proportion than in the rest of the cytoplasm. They contain glutathion. They can be selectively stained within the living cell by Janus green.

It is believed that mitochondria play an important part in the production of special structures and materials, such as enzymes, which occur in the cytoplasm of many cells. They are often termed collectively *chondriome.*

Apparatus of Golgi.—This, as already indicated, is not distinct in the living cell, but in fixed cells suitably stained it is very plain, usually taking the form of a network embedded in the cytoplasm near the nucleus (fig. 10). In spherical or polyhedral cells the network is arranged around the nucleus (fig. 11); in elongated or cubical cells it is generally placed near one pole. It is certainly not solid, but of viscous consistency. It often occurs in the form of scattered particles in place of a continuous network.

The Golgi apparatus, like the mitochondria, appears to be composed of proteins and lipoid substances—the latter preponderating. There seems to

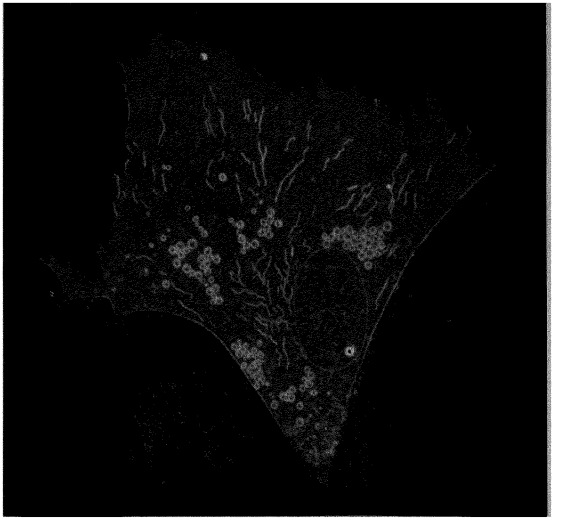

FIG. 8.—A LIVING CELL FROM A CULTURE OF EMBRYONIC CHICK TISSUE, SHOWING NUCLEUS WITH NUCLEOLI, MITOCHONDRIA AND FAT-GLOBULES AS SEEN BY DARK GROUND ILLUMINATION. (Drawn by Honor B. Fell.) Magnified about 1000 diameters.

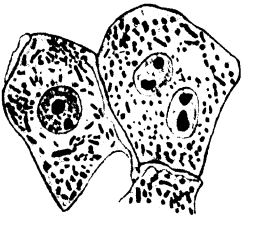

FIG. 9.—TWO LIVER CELLS OF RABBIT, SHOWING NUCLEI, NUCLEOLI AND MITOCHONDRIA. (H. M. Carleton.) × 1000.

One of the cells has two nuclei. Each nucleus has two nucleoli.

be no doubt that both mitochondria and Golgi apparatus are concerned with metabolism within the cell. In secreting cells the Golgi apparatus undergoes functional changes of form and position. According to Lim and Ma the

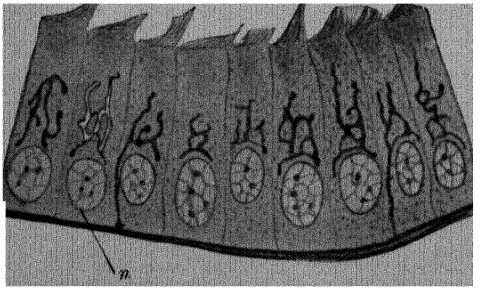

FIG. 10.—CELLS OF EPIDIDYMIS, SHOWING RETICULAR GOLGI APPARATUS IN THE CYTOPLASM. (E. Holmgren.)

n, nucleus.

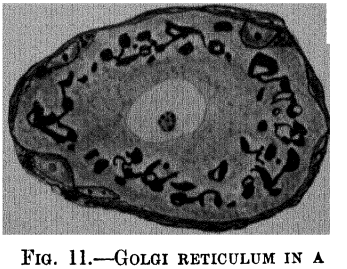

FIG. 11.—GOLGI RETICULUM IN A GANGLION-CELL OF CAT. (H. M. Carleton.) × 750. (From a preparation by W. Penfield.)

A reticulum can also be seen in the cells of the capsule. Note the minute particles nucleolini) in the nucleolus.

mitochondrial substance dissociates in the formation of secretions, giving rise to zymogen and setting free lipoid, which forms the Golgi material.

Metaplasmic inclusions.—Products of cell-activity in the shape of granules or globules (of zymogen, mucigen, or of unknown nature) are formed in the cytoplasm of many cells, and may be discharged from it to serve some purpose in the organism.



FIG. 12.—TWO PANCREAS CELLS, HIGHLY MAGNIFIED, SHOWING FILAMENTOUS MITOCHONDRIA AND SECRETION-GRANULES. (Champy.)

A, resting condition; B, condition during secretion.

These occur most prominently, but by no means exclusively, in the cells of secreting glands (fig. 12). Both mitochondria and the material of the Golgi apparatus have been described as taking part in the formation of such granules. A vacuole system (*vacuome*) is also developed in the cytoplasm of some cells in close relation to the

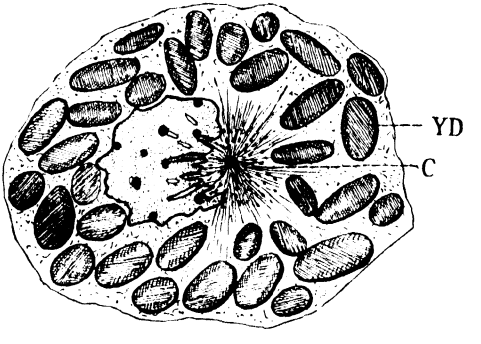

FIG. 13.—YOLK DISKS OR GLOBULES WITHIN CELL OF TRITON EMBRYO. (Champy and Carleton.) Highly magnified.

YD, yolk-disks; C, centriole, with astral rays. It will be seen that the outline of the adjacent nucleus is deformed under their influence.

Golgi apparatus (Gatenby). Some unicellular organisms possess rhythmically contractile vacuoles: these have been supposed to exercise an excretory function.

A system of lines or fibrils is also sometimes seen in the cytoplasm of cells (*e.g.* ciliated epithelium). Such a system has been termed a *fibrome*.

In addition to the above a number of reserve products, mostly nutritive, are also stored within cells. The most important of these in animal cells are fats, lipoids, and carbohydrates, especially glycogen.

Fat occurs in the form of droplets within the cytoplasm. When abundant these fuse to form one or more large drops.

Lipoid substances, apart from those which form an integral part of protoplasm, occur in the shape of globules, such as the yolk-particles in embryonic cells (fig. 13), or in the form of crystals, as in the cells of the suprarenal cortex.

Glycogen occurs in many organs and tissues of the adult, especially liver and muscle and in nearly all fœtal tissues. In contrast with fat and lipoid globules, glycogen is only seen in suitably fixed cells, in which it has probably been precipitated from a pre-existing state of solution. It is brought to view by its property of staining with iodine.

Deposition of these substances in a cell is often preceded by an accumulation of mitochondria at the seat of deposit.

NUCLEUS.

The nucleus varies greatly in shape. It may be either spherical, ovoid, elongated, kidney-shaped, annular, irregularly lobulated, double or multiple.

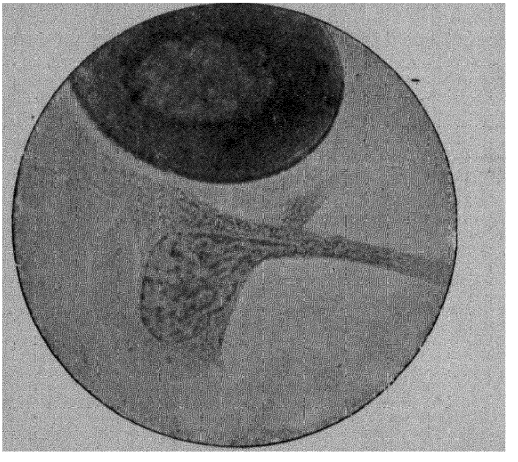

FIG. 14.—A LIVING LEUCOCYTE (WHITE BLOOD-CORPUSCLE) OF SALAMANDRA MACULATA, SHOWING LACE-LIKE RETICULAR APPEARANCE OF ITS PROTOPLASM. (E. Sharpey-Schafer.) × 1200. Untouched photograph.

An erythrocyte (red blood-corpuscle) is included in the photograph. A film of the protoplasm of the leucocyte extends over its margin.

It usually has the appearance of a vesicle bounded by a membrane. The contents of the vesicle appear to consist mainly of a homogeneous fluid material (*karyoplasm*). A well-defined spherical particle (*nucleolus*) is generally to be seen in it; and, even in the living cell, a network of fibres with enlargements at the junctions is occasionally visible (fig. 14). After the action of fixatives and stains this network is very distinct and is seen to be attached to the membrane of the nucleus (fig. 15). The nucleolus is placed at one of the junctions of the network, by which it appears to be supported. When a network is absent the nucleolus lies free in the karyoplasm (fig. 11).

The nucleus is not only concerned with cell division and multiplication in the manner to be described, but takes an active part in the chemical (metabolic)

processes which occur in the protoplasm, and is especially the seat of intracellular oxidations. Cells deprived artificially of their nuclei do not assimilate nourishment, and lose any power of secretion they may have possessed, although the protoplasm may continue for a time to live and exhibit amœboid movements. On the other hand, changes are caused in the nucleus by lesions of the cell-membrane, showing that nucleus and cytoplasm are interdependent (Chambers).

In the resting (non-dividing) cell the nuclear contents are, as above mentioned, always contained within an apparent membrane; this membrane disappears during division, the cytoplasm and karyoplasm being then continuous. By micro-dissection it can be shown that the nuclear membrane is not solid but is composed of a viscous material, which allows itself to be drawn out by a needle, and, on being released, recovers its previous form and position.

In fixed and stained specimens, most resting nuclei exhibit, as just stated, the appearance of a network formed of a substance easily stainable, particularly by basic dyes. Like the membrane of the nucleus it also seems to be of a viscous consistency during life; although, after fixation and staining, it acquires an appearance of solidity.

The material composing this stainable substance is termed *chromatin*; this term also includes the membrane of the nucleus and certain types of nucleoli sometimes present, which are similarly stained by basic dyes.

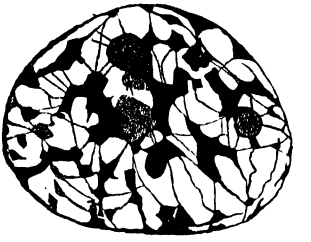

FIG. 15.—NUCLEUS OF AN EPITHELIAL CELL OF SALAMANDER-LARVA. (M. Heidenhain.) × 2300.

Two nucleoli are seen and several pseudo-nucleoli.

Nuclear chromatin consists of nucleic acid (remarkable for its high phosphorus content) combined in various proportions with proteins to form the so-called nucleins and nucleoproteins. It also contains lipoids, which are especially abundant in the membrane of the nucleus, and a relatively large amount of calcium.

There is sometimes seen in fixed and stained preparations a fine mesh (*linin network*) distinct from the chromatin (fig. 18). Its reaction towards dyes is oxyphil. It is not known if such a meshwork is present during life, or if it is produced by the fixative used.

Chromosomes.—In some resting cells the chromatin of the nucleus, instead of presenting the appearance of a network, takes the form of a convoluted filament or filaments having a skein-like arrangement (fig. 19). This is not an artifact, since it is visible in the living cell. It is always found when a nucleus is about to divide. When the filaments of chromatin are ununited to one another they are termed *chromosomes*. But in nearly all 'resting' cells the chromosomes cannot be seen as distinct structures, being merged into one another to form the network and the nuclear membrane (fig. 15). However, whether visible as distinct parts or not, the chromosomes are none the less potentially present. This is evidenced when the nucleus is dividing; in such case its chromosomes are always separate, and their number can be counted. The number varies with the species of animal or plant: it is



FIG. 16.—CHROMOSOMES OF A DIVIDING NUCLEUS OF SPERMATOGON OF MAN, SHOWING THE DIFFERENCES IN FORM AND SIZE WHICH THEY PRESENT. (Winiwarter and Oguma.)

believed to be constant for every somatic cell of the species. In man there are 48 (24 pairs) in each cell. In the male cell (fig. 16) one chromosome is usually said to be unpaired, the sex-chromosome (fig. 17), but some authorities hold that this also is double.

Chromosomes belonging to the same nucleus may be approximately of the same size and shape, but this is by no means always the case, some being short and then usually straight, others longer and then generally V-shaped (figs. 16, 17). They are usually linear, but in some cases are represented merely by particles of chromatin.

The cells of cultures from human embryos were found by Tage Kemp

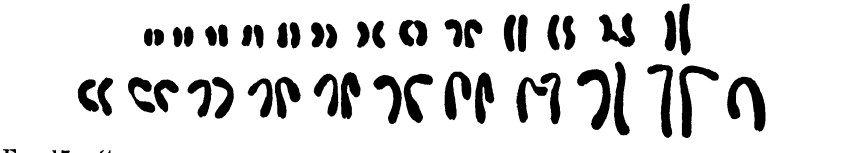

FIG. 17.—CHROMOSOMES OF A DIVIDING NUCLEUS OF SPERMATOGON OF MAN, ARRANGED IN ORDER OF SIZE AND SHAPE TO EXHIBIT THE PAIRS. (Winiwarter and Oguma.)

It will be seen that there are altogether 23 pairs of chromosomes (those of each pair being alike, but those of different pairs varying greatly in size and shape) and 1 unpaired, the sex-chromosome.

(1928) to have 48 chromosomes, varying in length from 1 μ to 8 μ and in thickness from 0·5 μ to 1 μ.

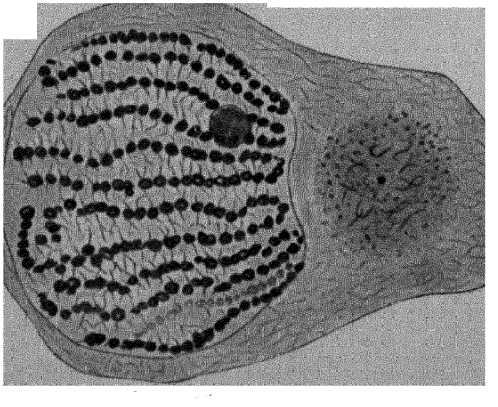

FIG. 18.—SPERMATOCYTE OF PROTEUS, SHOWING CHROMOSOMES OF NUCLEUS FORMED OF PARTICLES OF CHROMATIN UNITED BY ACHROMATIC FILAMENTS. (F. Hermann.)

The nucleolus is distinct from the chromosomes. In the cytoplasm an archoplasmic mass containing mitochondria is seen on the right.

With high magnification some chromosomes may be seen to be made up of fine juxtaposed particles (*chromomeres*) arranged either in single or double

rows (figs. 18, 19). The chromosomes of a nucleus are occasionally clumped together into a solid mass of chromatin, which comprehends the nucleolus when this is present. A good example is the nucleus of the spermatozoon—which, however, takes on the structural appearance of an ordinary cell-nucleus after penetrating the membrane surrounding the ovum (fig. 20).

The chromosomes of the gametes (spermatozoa and ova) are undoubtedly the structures which convey genetic characteristics to the offspring. Each gamete has one-half of the somatic number, and therefore twenty-four in man. When the gametes unite to form the *zygote* (the fertilised ovum) the latter acquires the full somatic number. In the subsequent division and subdivision of the fertilised ovum

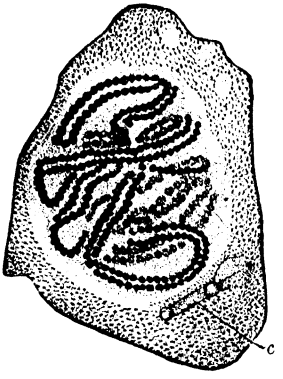

FIG. 19.—CELL SHOWING CHROMOSOMES OF NUCLEUS IN THE FORM OF THREADS COMPOSED OF DOUBLE ROWS OF CHROMOMERES. (F. Hermann.)

c, centrosomes with uniting spindle.

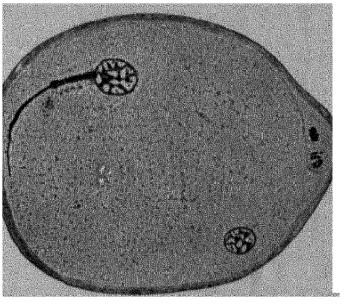

FIG. 20.—OVUM OF BAT WITH POLAR BODIES AND GERM- AND SPERM-NUCLEI. (Van der Stricht.)

The development of the sperm-nucleus from the head of the spermatozoon is very evident in this case, because the rest of the spermatozoon happens not to have been thrown off.

the chromosomes participate in such division, and convey specific characteristics of the parents to every cell in the reproduced organism. The chromosomes are themselves composed of minute ultra-microscopic particles which appear to be the actual agents or carriers (*genes*) on which the hereditary transmission of the ancestral characteristics depends.

Nucleolus.—The nucleolus is a homogeneous spherical body, of which one or more may be present in a nucleus. By the reaction to dyes two types of nucleoli can be recognised—one staining especially with basic dyes: this, during mitosis, furnishes part of the material for the chromosomes; and a second staining with acid dyes: this disappears during mitosis without blending with the chromosomes. The two are distinguished by the names *karyosome* and *plasmosome*. The nucleolus can frequently be observed to exhibit spontaneous movements in the living cell.

Both kinds of nucleoli may contain special particles termed *nucleolini*, which do not disappear during mitosis (Carleton).

CELL-DIVISION.

The chromatin within the nucleus may be observed to undergo spontaneous changes of form and arrangement; these changes become very evident during cell-division. The division of the protoplasm is always

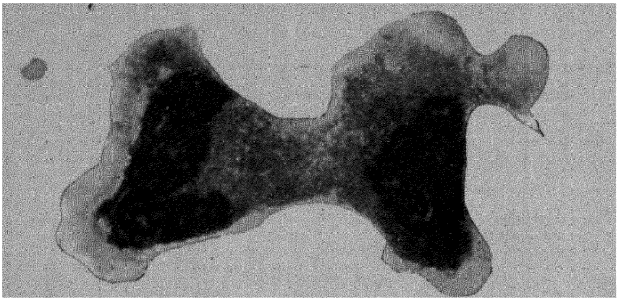

FIG. 21.—A LEUCOCYTE OF TRITON APPARENTLY UNDERGOING AMITOTIC DIVISION OF ITS NUCLEUS. (E. Sharpey-Schafer.) × 1360. Untouched photograph.

The nucleus is separated into two nearly equal parts, and the protoplasm is collecting around them and is constricted in the intermediate part of the corpuscle. The corpuscle was fixed by a jet of steam and stained with hæmatoxylin.

preceded by that of the nucleus, the chromosomes of which undergo a series of remarkable transformations which are known collectively by the term *karyokinesis* (Schleicher) or *mitosis* (Flemming).

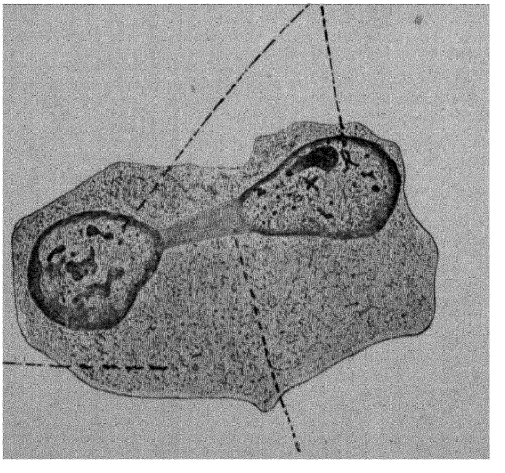

FIG. 22.—CELL OF BLADDER EPITHELIUM, SHOWING SUPPOSED AMITOTIC DIVISION OF NUCLEUS. (Nemileff.)

a, cytoplasm; *b*, daughter nuclei; *c*, strand of fibrils uniting daughter nuclei.

But sometimes the nucleus divides by a process of fission without karyokinetic changes: this is termed *amitotic division* (figs. 21, 22). It occurs in comparatively few situations, and is often not followed by the division of the cell, so that it is apt to result in the formation of bi-nucleated

and multi-nucleated cells, as in the superficial layer of the epithelium of the urinary bladder (fig. 22) and in some of the giant-cells of bone-marrow (fig. 6). The occurrence of amitotic division has by some been regarded as a sign of degenerative changes in the cell, but this is probably not the case. It has been caused, in cells which normally divide mitotically, by chemical changes in their environment.

Mitotic division.—The division of the nucleus is preceded by the division of the centrosome. The dividing nucleus passes through a series of phases (figs. 23, 24) as follows:

1. The network of chromatin filaments of the resting nucleus becomes transformed into a *skein*, formed apparently of one long, convoluted filament. The nuclear membrane and the nucleoli are merged into the skein. This is known as the *spirem phase.*

2. The skein breaks into a number of chromosomes, the number varying, as already stated, with the species of animal or plant. In one variety of *Ascaris megalocephala* there are only four chromosomes; in man, forty-eight; other plants and animals have more or fewer, but they are almost always multiples of two.

3. As soon as the chromosomes are distinct they become arranged radially around the equator of the nucleus; when V-shaped they look like a star when viewed from either pole of the cell (*equatorial* or *aster phase*).

4. Each chromosome splits longitudinally into two, so that they are now twice as numerous as before (*cleavage phase*). This longitudinal cleavage may occur at an earlier stage.

5. The chromosomes separate into two groups, the ends (if they are V-shaped) being for a time interlocked (*phase of separation*).

6. The two groups pass to the opposite poles of the now elongated nucleus and form a star-shaped figure at each pole. Each of the stars represents a daughter nucleus (*diaster phase*).

7, 8. Each star of the diaster goes through the same changes as the original nucleus, but in the reverse order—viz. a skein, at first more open and rosette-like, then a closer skein, then a network; passing finally into the condition typical of the resting nucleus.

The splitting and separation of the chromosomes is often spoken of as the *metaphase*, the stages leading up to this being termed the *prophase* or *anaphase*, and those which lead away from it the *kataphase*, the final stage being spoken of as the *telophase*. But these terms are sometimes used differently, and it is better to avoid them.

The time occupied in division varies, but is generally about an hour. It is quicker in warm-blooded than in cold-blooded animals. For a given cell a rise of temperature of 10° C. doubles the rate of mitosis; thus conforming to the law of Van 't Hoff and Arrhenius for chemical reactions.

The mode of division of the nuclear chromatin above described is known as *somatic* division, to distinguish it from two modes of division which are only seen normally in the formation of the gametes (spermatozoa and ova), and are known as *heterotypical division* and *reduction division* (figs. 25, 26).

Heterotypical division (which immediately precedes the reduction) is

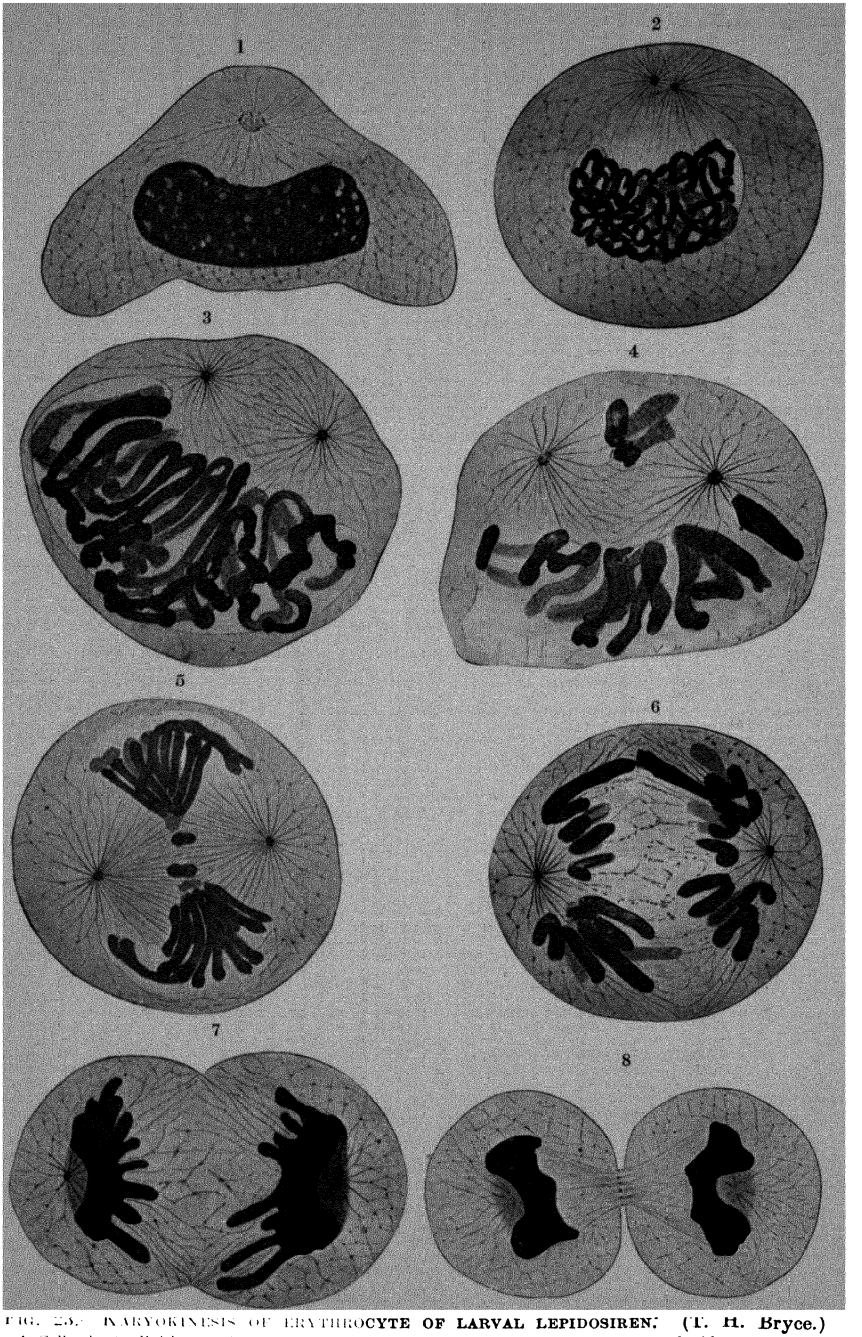

FIG. 23.—KARYOKINESIS OF ERYTHROCYTE OF LARVAL LEPIDOSIREN. (T. H. Bryce.)

1, Cell prior to division, centrosome single, nucleus a dense network; 2, centrosome double, nucleus a close spirem; 3, spirem breaking up into chromosomes; 4, division spindle forming, chromosomes V-shaped; 5, V-shaped chromosomes collected at equator of spindle, and undergoing longitudinal splitting; 6, the chromosomes which result from the splitting have become thicker and shorter, and are passing towards the centrosomes at the poles of the spindle to form the daughter nuclei; 7, 8, daughter nuclei formed by agglomeration of chromosomes, cytoplasm dividing.

characterised by a peculiar arrangement of the chromosomes, which, before separating to pass to the daughter nuclei, tend to adhere together in the form of loops or rings, or in the case of short straight chromosomes into

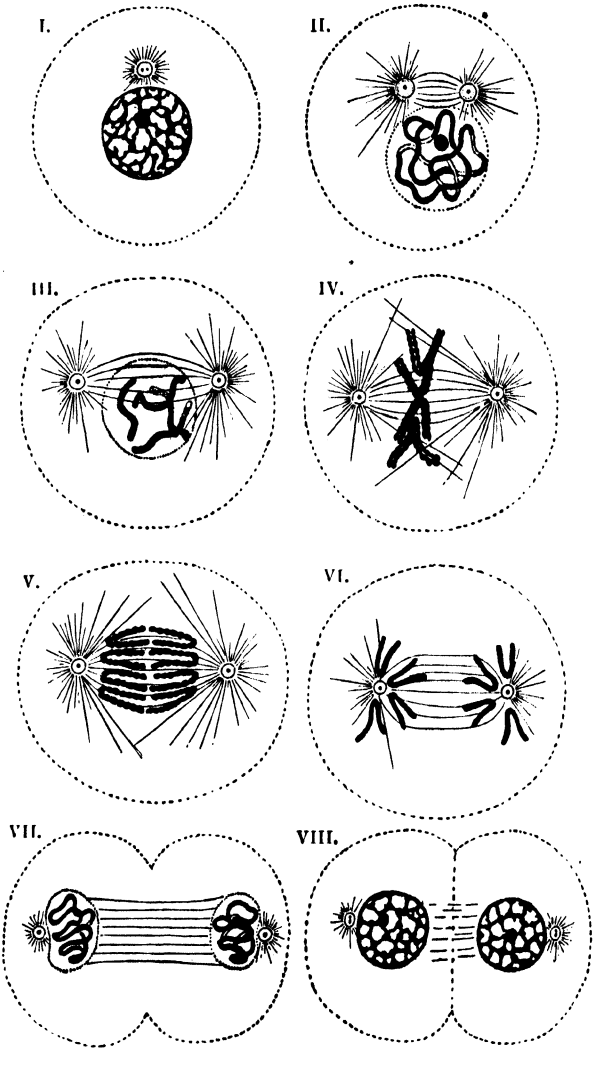

FIG. 24.—DIAGRAM SHOWING THE CHANGES WHICH OCCUR IN THE CENTROSOMES AND NUCLEUS OF A CELL IN THE PROCESS OF MITOTIC DIVISION.

The nucleus is supposed to have four chromosomes.

small quadrangular masses (tetrads) (see figs. 27, 28). In the reducti division the chromosomes do not undergo the usual longitudinal splittir but one-half of the total number passes into each daughter nucleus, so th

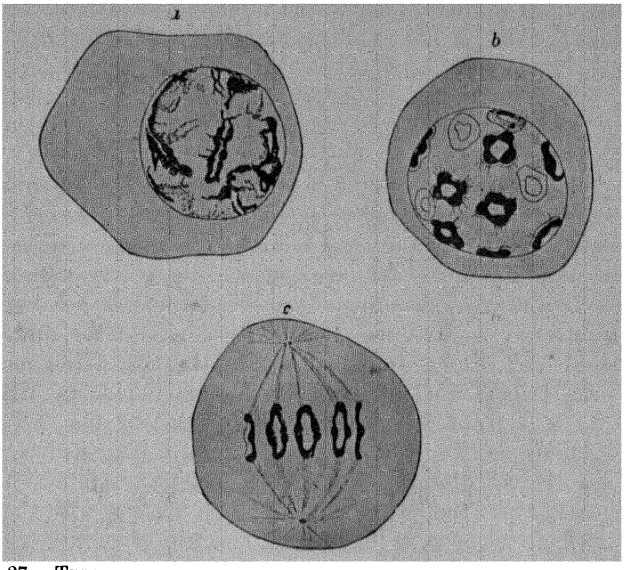

FIG. 27.—THREE STAGES OF HETEROTYPICAL MITOSIS IN SPERMATOCYTE OF TRITON. (Moore.)

a, geminal condition of chromosomes; *b*, gemini arranged in quadrate loops or tetrads; *c*, separation of tetrads into the duplex chromosomes of the daughter nuclei.

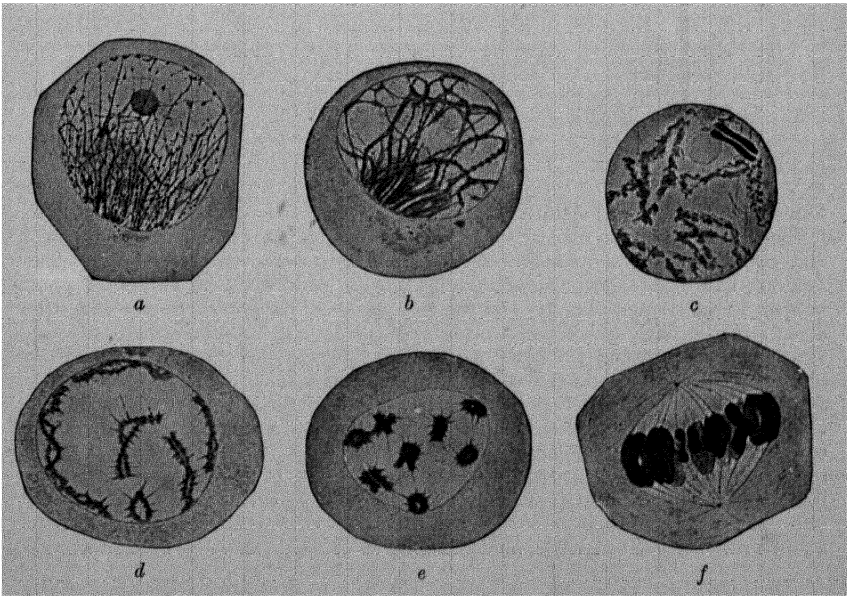

FIG. 28.—SPERMATOCYTES OF MYXINE SHOWING SYNAPTIC CONDITION IN *a* AND *b*, GEMINAL CONDITION IN *c* AND *d*, AND FORMATION OF TETRADS AND CHROMOSOME RINGS IN *e* AND *f*. (Schreiner.)

chromatin, which exhibits, prior to the formation of tetrads, a condition of entanglement which is known as a *synapsis* (fig. 28, *a* and *b*) in which the individual chromosomes cannot be distinguished. This change occurs in the male gamete immediately before the heterotypical mitosis, but long prior to that in the female gamete, in which it is followed by a prolonged period of nuclear quiescence.

The protoplasm of the cell divides soon after the separation of the chromosomes to form the daughter nuclei (figs. 23, 24). During cell-division fine lines are seen in the protoplasm radiating from the centrioles at the pole of the nucleus, while other lines form a system of fibres diverging from the poles towards the equator. This fibrome system is termed the *achromatic spindle.*

The centrioles, as we have seen, always initiate the division of the cell; indeed they are often found divided in the resting nucleus, the two particles being united by a small achromatic spindle. When mitosis is about to take place this spindle enlarges, and as the changes in the chromatin of the nucleus which have been above described occur—which changes involve the disappearance of the nuclear membrane—the spindle gradually passes into the middle of the mitotic nucleus, with the two poles of the spindle at the poles of the nucleus, and with the fibres of the spindle therefore completely traversing the nucleus (figs. 23, 24). The spindle fibres appear to form directing lines along which the chromosomes pass, after the cleavage, towards the nuclear poles to form the daughter nuclei. They perhaps represent lines of stress within the viscous fluid of the karyoplasm.

Observation of mitotic division during life.[1]—By cultivating fragments of tissue *in vitro* it is possible to observe the whole course of mitosis in growing tissue; it is found that almost all the appearances seen in fixed material can also be seen in the living cell. A living fibroblast which is about to divide *in vitro* slowly loses its amœboid form and becomes rounded or oval. The nucleoli gradually dissolve, whilst at the same time delicate filaments (the early chromosomes) appear in the nucleoplasm, and 'these are frequently seen in active writhing movement like eels in a box' (Strangeways). The nuclear outline then vanishes and the spindle appears as a rather clear area of cytoplasm in which it is difficult to distinguish definite fibres with certainty. Meanwhile the chromosomes thicken and contract and move irregularly towards the equator of the cell where, after much shifting of position and rearrangement, they finally settle down into the equatorial phase. They remain in this position for some minutes. Quite suddenly each chromosome can be seen to split longitudinally, and the two groups of daughter chromosomes draw apart and pass fairly quickly to opposite poles of the cell. At the same time a constriction appears round the equator of the cytoplasm, the chromosomes contract into a clump of short, thick rods, and the cytoplasm itself exhibits a remarkable, active bubbling movement at the surface. The equatorial constriction soon cuts the cell into two halves, the bubbling movement gradually ceases, and the two groups of chromosomes become diffuse, forming two small daughter nuclei. The cytoplasm of each cell spreads out into the typical amœboid form, the chromosome filaments in the nuclei become indistinguishable and nucleoli reappear. Mitosis, from the onset of prophase to the formation of the daughter cells, occupies about one hour. After an interval of eleven to twelve hours a daughter cell may again divide (Strangeways).

In some cells, especially in plants, the line of division of the protoplasm

[1] We are indebted to Miss Honor B. Fell for this account of the appearances seen in the living cell during mitosis.

of the cell becomes marked out by thickenings upon the fibres of the spindle which occur just in the plane of subsequent division, and have been termed collectively the *cell-plate* (fig. 29). But in most animal cells no cell-plate is formed, the protoplasm simply becoming constricted into two parts midway between the two daughter nuclei. Each daughter cell so formed retains one of the two centrioles of the spindle as its own centriole, and, when the daughter cells are in their turn again about to divide, this centriole divides first and forms a new spindle, and the whole process goes on as before. Rarely the division of a nucleus is into three or more parts instead of two. In such cases the centriole becomes correspondingly multiplied, and the achromatic system of fibres takes a more complex form than the simple spindle.

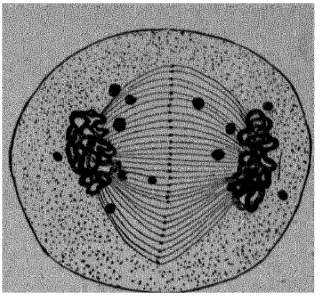

FIG. 29.—CELL-PLATE IN DIVIDING SPORE-CELL OF LILY. (Gurwitsch, after Zimmermann.)

It has been shown by Leduc that the appearance of the division spindle and the changes which the chromosomes undergo can be roughly imitated by allowing solutions of an electrolyte of different concentration, one of which contains carbon

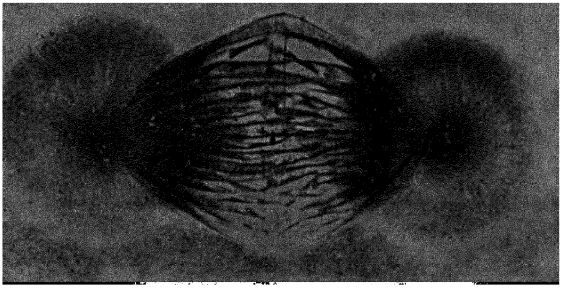

FIG. 30.—IMITATION OF DIVISION SPINDLE PRODUCED DURING THE MIXING OF DROPS OF A LESS CONCENTRATED SOLUTION OF SODIUM CHLORIDE CONTAINING PARTICLES OF CHINA INK IN SUSPENSION WITH A SOLUTION OF THE SAME SALT OF GREATER DENSITY. (Leduc.)

particles in suspension, to mix gradually (fig. 30). Indeed, that electrical attraction and repulsion come into play in the process of karyokinesis is more than probable (R. S. Lillie). W. B. Hardy finds evidence in the resting cell of the existence of opposite electric charges in the proteins of the cytoplasm (+) and those of the nucleus (—).

The mitochondria appear to be passively carried into each daughter cell during division of the cytoplasm: probably they also undergo division. The Golgi apparatus usually breaks up into a number of curved rodlets when the cell begins to divide. These are also carried into the daughter cells.

Division of the ovum.—Usually the two daughter cells are of equal size; but there is a notable exception in the case of the ovum, which, prior to fertilisation, divides by heterotypical mitosis into two very unequal

parts, the larger of which retains the designation of ovum, while the smaller, which becomes detached from it, is known as the *first polar body*. In the formation of a *second polar body* the *reduction-division* occurs, and the nucleus of

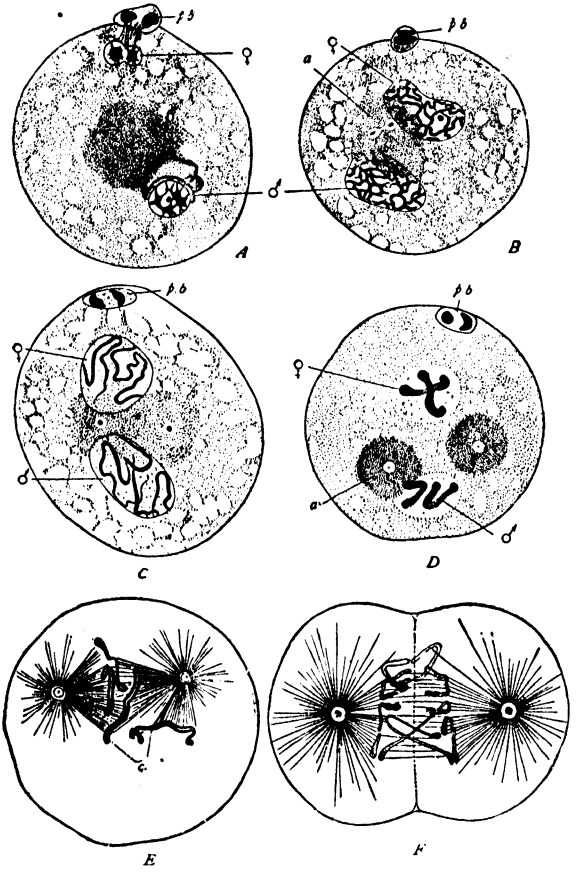

FIG. 31.—FERTILISATION AND FIRST DIVISION OF OVUM OF ASCARIS MEGALOCEPHALA. (Slightly modified from Boveri.)

A, second polar globule just formed; the head of the spermatozoon is becoming changed into a reticular male pro-nucleus (♂), which shows indistinctly two chromosomes; just above it, its archoplasm is shown: the female pro-nucleus (♀) also shows two chromosomes.

B, both pro-nuclei are now reticular and enlarged; a double centrosome (*a*) is visible in the archoplasm which lies between them.

C, the chromatin in each pro-nucleus is now converted into two filamentous chromosomes; the centrosomes are separating from one another.

D, the chromosomes are more distinct and shortened; the nuclear membranes have disappeared; the centrosomes are distinct.

E, mingling of the four chromosomes (*c*), each of which is seen to be splitting longitudinally; the achromatic spindle is fully formed.

F, separation (towards the poles of the spindle) of the halves of the split chromosomes, and commencing division of the cytoplasm. Each of the daughter cells now has four chromosomes; two of these have been derived from the male pro-nucleus, two from the female pro-nucleus.

the ovum, after the two polar bodies are extruded (now the *female gamete*), contains only one-half the number of chromosomes that it had previously; *e.g.* twenty-four in man in place of the normal somatic number of forty-eight

(see p. 12). Should fertilisation supervene, the chromosomes which are lacking are supplied by the male gamete (spermatozoon), the nucleus of which has also undergone similar heterotypical and reduction changes in the final divisions by which it was produced, the number of its chromosomes being brought down to one-half of the normal or somatic number.[1] The reduced nuclei—formed respectively from the remainder of the nucleus of the ovum after extrusion of the polar bodies, and from the head of the spermatozoon, which contains its nucleus—are known (within the ovum) as the *sperm-* and *germ-nuclei*, or the *male* and *female pro-nuclei*. In fertilisation these coalesce, and the ovum then again contains a nucleus with the number of chromosomes normal to the species. When it divides, each daughter cell is found to contain the normal or somatic number of chromosomes, derived from the splitting of both the male and female chromosomes, half the number from the one and half from the other (fig. 31), so that every cell in the body has the same number of chromosomes, one-half derived from the male parent and one-half from the female.

Determination of sex.[2]—It has been shown in an ever-increasing number of species that the sexes are to be distinguished by constant differences in the chromosome content of the tissue-cells. This difference is revealed most clearly in those forms in which the chromosomes are few in number and differ among themselves in size and shape. In these cases it is seen that the chromosome number is constant and characteristic of the species, being a multiple of two, and that the chromosomes themselves, in the somatic tissues and immature gametes, are present in pairs. Save in the case of birds, moths and butterflies, it is usual to find that in the cells of the female each of the pairs consists of two chromosomes exactly similar in size and shape, whereas in the cells of the male one of the pairs is remarkable in that its members are dissimilar. The chromosomes of this pair are nevertheless represented in the female. They are known as the *sex-chromosomes*, since in respect of them the sexes differ. Both members of this pair in the female, and the one sex-chromosome like them of the equivalent pair in the male, are known as the *X-chromosomes*: the unequal mate of the X in the male is known as the *Y-chromosome*. (To distinguish between sex-chromosomes and the ordinary chromosomes the latter are sometimes termed *autosomes*.)

The sex-chromosome constitution of the female can thus be symbolised as XX; that of the male as XY. Into each mature gamete, ovum or sperm, there passes one or other member, but not both, of each pair of homologous chromosomes. All ova elaborated by an XX female will contain an X-chromosome, but there will be two kinds of spermatozoa produced by the XY male, one containing an X-chromosome, the other a Y. Fertilisation involves the fusion either of an X-containing ovum and an X-containing sperm or of an X-containing ovum and a Y-containing sperm. In the first case an XX zygote will result: in the second an XY. The first has the constitution of, and is, a female, the second is a male. This difference in the sex-chromosome constitution of the sexes, together with the mechanism which reduces the number of the chromosomes during gametogenesis, furnishes a simple and efficient method of producing males and females in every generation in about equal numbers.

The evidence of sex-linked inheritance supports this conclusion. Certain hereditary characters, details of structure and of function, are transmitted from generation to generation in such a fashion as to make it necessary to postulate that the factors or genes which correspond to them are resident in the X-chromosome.

A son gets his single X-chromosome from his mother, and therefore will exhibit

[1] See, however, below, 'sex-chromosomes.'

[2] We are indebted to Professor F. A. E. Crew for this account.

those sex-linked characters the factors for which are resident in this X. A daughter receives one X-chromosome from her mother, another from her father, and therefore the sex-linked characters she will exhibit will be the dominant members of the sex-linked character pairs of the two parents.

The hæmorrhagic diathesis is a sex-linked recessive character, the factor for which is X-borne. A male therefore is either normal or hæmophilic: whereas a female is normal, hæmophilic, or a carrier, *i.e.* not exhibiting the abnormal state herself but carrying the factor for it on one of her X-chromosomes and therefore transmitting this to her offspring. A carrier is not herself hæmophilic, for the reason that the recessive factor on one X-chromosome is balanced by the factor for the alternative dominant normality on the other. The son of a carrier married to a 'normal' man will be hæmophilic if he should receive from his mother the

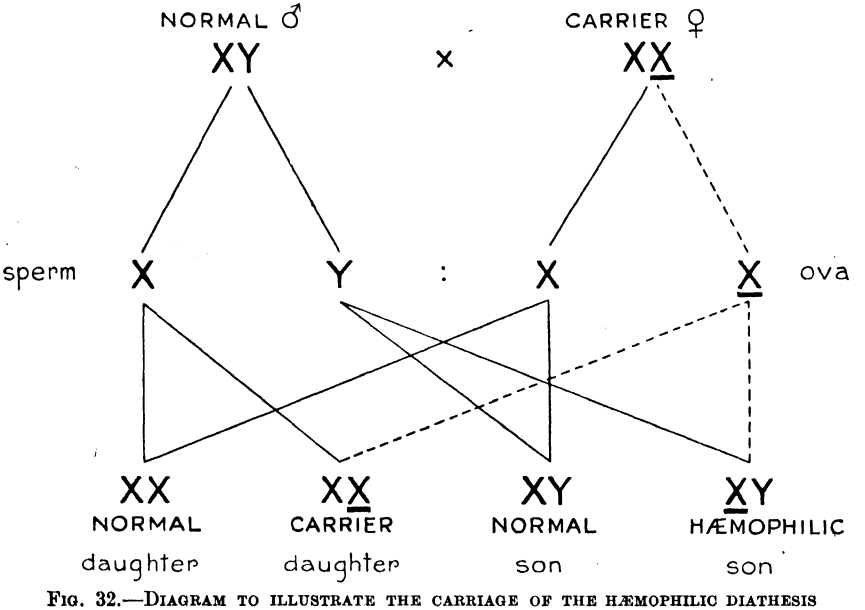

FIG. 32.—DIAGRAM TO ILLUSTRATE THE CARRIAGE OF THE HÆMOPHILIC DIATHESIS BY SEX-LINKAGE. (F. A. E. Crew.)

X-chromosome carrying the factor for this condition: should he receive the other, then he will be normal. Daughters will all be normal or carriers. Sex-linked characters are not limited to one sex: they are sex-linked because their factors are resident in the sex-chromosome.

While in man it is the male that is XY and the female that is XX in sex-chromosome constitution, in birds, moths and butterflies it is the male that is XX and the female XY. In many animals there is no Y-chromosome in the male, his sex-chromosome constitution being XO. There are other modifications of this XX: XY relationship, but in all the end result is the same: one sex is monogametic, elaborating but one kind of gamete in respect of the sex-chromosomes; the other is digametic, elaborating two; in all the mechanism yields males and females in every generation. Sex is determined at the time of fertilisation by the sex-chromosome distributive mechanism.

FORMATION OF THE TISSUES.

It appears to be established beyond doubt that new cells can only be formed from pre-existing cells. In the early embryo the whole body is an

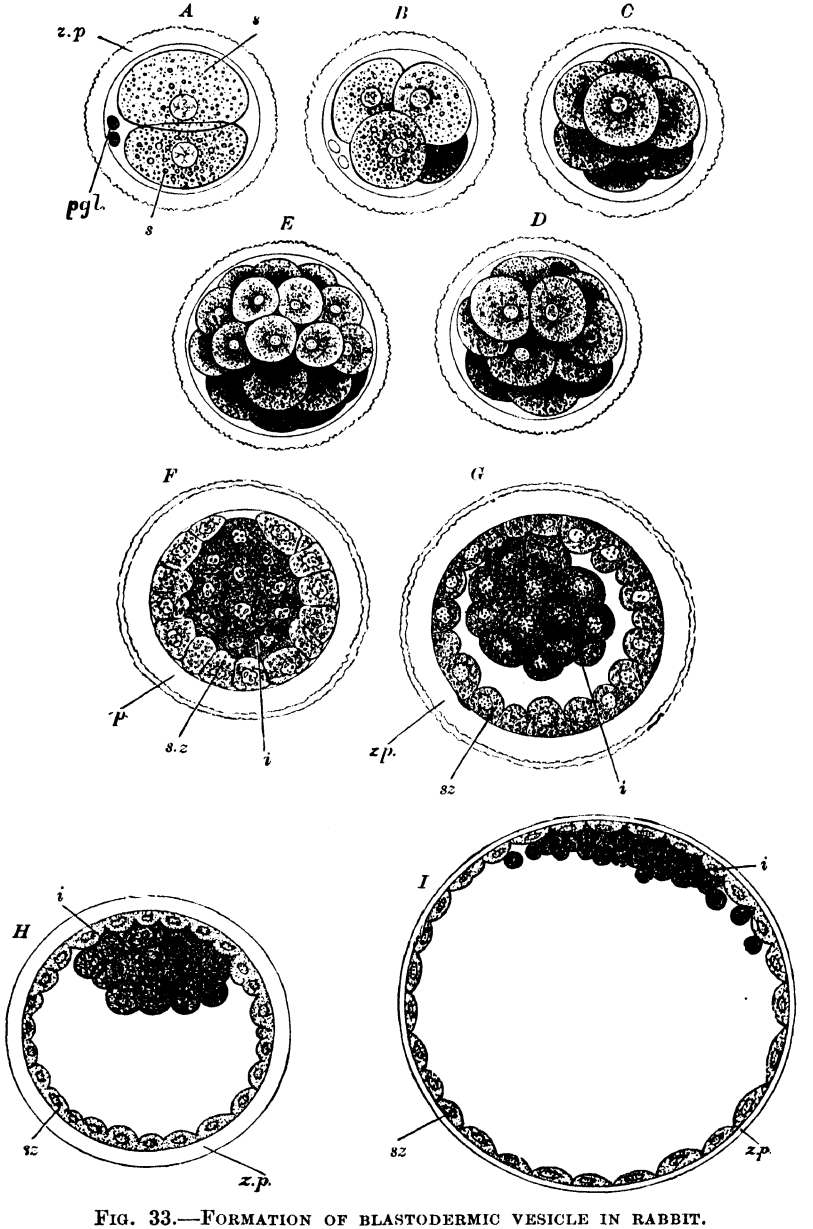

FIG. 33.—FORMATION OF BLASTODERMIC VESICLE IN RABBIT.

(Allen Thomson, partly after E. v. Beneden.) Diagrammatic.

A to *E*, division of ovum and formation of 'mulberry mass': *pgl*, polar globules; *s*, *s*, cells of primary division which already show a difference of appearance. This early differentiation is not, however, accepted by most authorities. *F* to *I*, sections of the ovum in subsequent stages: *zp*, membrane of ovum (zona pellucida); *sz*, subzonal layer, by means of which the ovum becomes attached to the uterine mucous membrane; *i*, inner cell-mass, which gives rise to the blastodermic layers. The accumulation of fluid in *G*, *H*, and *I* has swollen the ovum out to form the so-called blastodermic vesicle.

agglomeration of cells. These have all been formed from the *fertilised ovum* or *zygote*, which divides first into two cells, these again into two, and so on until a large number of cells (embryonic cells) are produced (fig. 33). In mammals these form at first an outer stratum of clear cells lying at the surface (fig. 33, *sz*), and an inner mass (*i*) of granular cells attached to the outer layer at one part, but elsewhere separated from it by clear fluid. Eventually the cells of the inner mass arrange themselves in the form of a membrane (*blastoderm*), composed of three layers. These layers are known respectively as the *ectoderm*, *mesoderm*, and *entoderm*, or *epiblast*, *mesoblast*, and *hypoblast* (fig. 34). The ectoderm gives rise to most of the epithelial tissues, and to the tissues of the nervous system; the entoderm to the epithelium of the alimentary canal (except the mouth), and the glands in connexion with it; and the mesoderm to the connective and muscular tissues.

The tissues are formed either by changes which occur in the intercellular substance or by changes in the cells themselves; frequently by both these processes combined. Among the cells which are least altered from their

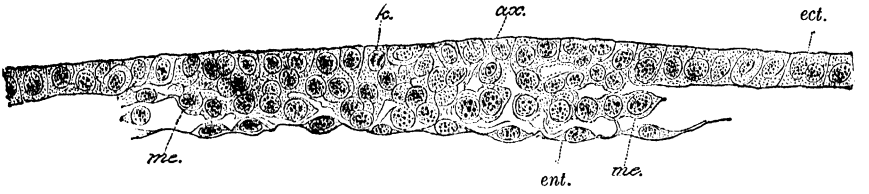

FIG. 34.—SECTION OF BLASTODERM OF RABBIT SHOWING THE COMMENCING FORMATION OF THE MESODERM. (Kölliker.)

ect, ectoderm; *me*, mesoderm; *ent*, entoderm; *ax*, axial part of ectoderm with cells undergoing division (*k*). The mesoderm is growing from this part.

embryonic condition are the white corpuscles of the blood; these are regarded as typical free cells.

The histogenetic relation between the three layers of the blastoderm and the several tissues and organs of the body is exhibited in the following table:

Ectoderm	The epithelium of the skin (epidermis) and its appendages, viz. the hairs, nails, sebaceous and sweat glands, and mammary glands. The muscular fibres of the sweat and mammary glands.
	The epithelium of the mouth, and the epithelium of the anus and anal canal. The salivary and other glands which open into the mouth. The enamel of the teeth. The gustatory organs.
	The epithelium of the lower part of the urethra.
	The epithelium of the lower part of the vagina.
	The epithelium of the nasal passages, and of the cavities and glands which open into them.
	The epithelium covering the front of the eye. The epithelium of the lacrimal canals and lacrimal glands. The crystalline lens. The retina. The pars ciliaris retinæ and the pars iridica retinæ. The sphincter and dilatator pupillæ muscles.

Ectoderm

- The epithelium lining the membranous labyrinth of the ear. The epithelium lining the external auditory meatus.
- The epithelium lining the central canal of the spinal cord, the aqueduct, and the fourth, third, and lateral ventricles of the brain.
- The tissues of the nervous system, including all nerve-cells and nerve-fibres and most neuroglia-cells.
- The greater part of the pituitary body. The pineal gland. The medulla of the suprarenal capsules.

Mesoderm

- All the connective tissues.
- The blood and lymph corpuscles.
- The spleen and lymph glands.
- The cortex of the suprarenal capsules.
- The endothelial lining of the heart, blood-vessels, lymphatics, and serous membranes.
- The epithelium of the uriniferous tubules, and that of the ureters and renal pelves.
- The epithelium of the male generative organs, including that of the testis and its ducts, and that of the prostatic vesicle, as well as the male generative cells (spermatozoa).
- The epithelium of the ovary and Graafian follicles, including the female generative cells (ova); the epithelium of the Fallopian tubes, and uterus, and the upper part of the vagina.
- The muscular tissues, voluntary, involuntary, and cardiac.

Entoderm

- The epithelium of the alimentary canal (from the pharynx to the lower end of the rectum, inclusive) and of all the glands which open into it (including the liver and pancreas).
- The epithelium of the Eustachian tube and cavity of the tympanum.
- The epithelium of the larynx, trachea, and bronchi, and of all their ramifications.
- The epithelium of the pulmonary alveoli.
- The thyroid body and parathyroids. Part of the thymus gland.
- The epithelium of the urinary bladder, of the female urethra, and of the uppermost part of the vagina.
- The epithelium of the upper part of the male urethra and of its glands.

All the connective tissues, the endothelium of the lymphatic and hæmal systems, and the vascular and lymph glands are formed from a special part of the mesoderm termed *mesenchyme*, which, at an early stage of development, consists of a syncytium of branched cells with a homogeneous intercellular matrix. Plain muscular tissue is for the most part also formed from mesenchyme, but in certain situations, as in the sweat glands and muscular tissue of the iris, it is ectodermal in origin. The generative cells (gonads) in both sexes, although developed in connexion with the mesoderm, are produced from special cells which are early differentiated from the somatic cells.

LESSON I.

USE OF THE MICROSCOPE. EXAMINATION OF CERTAIN COMMON OBJECTS.

THE requisites for practical histology are a good compound microscope; slips of glass technically known as 'slides,' upon which the preparations are made; pieces of thin glass used as covers for the preparations; a few instruments, such as microtome, scalpel, scissors, forceps, and needles mounted in wooden handles; and a set of fluid reagents for mounting and staining microscopic preparations.[1] A sketch-book and pencil are also necessary, and must be constantly employed.

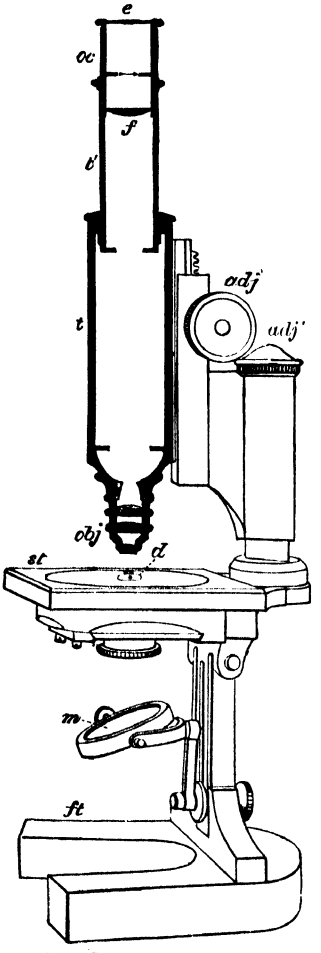

FIG. 35.—DIAGRAM OF MICROSCOPE.

Microscope.—The microscope (fig. 35) consists of a tube (*t t'*), usually about 160 millimeters (6·4 inches) long, having two systems of lenses, one at the upper end termed the 'eye-piece' or 'ocular' (*oc*), the other at the lower end termed the 'objective' (*obj*).

The focus is obtained by cautiously bringing the tube and lenses down towards the object by the coarse adjustment, which is usually a rack-and-pinion movement (*adj*), and focusing exactly by the fine adjustment (*adj'*).

The stage (*st*) upon which the preparations are placed for examination, the mirror (*m*) which serves to reflect light up through the central aperture in the stage and along the tube of the instrument, and the diaphragm (*d*) below the stage which is used to regulate the amount of light thus thrown up, are all parts the employment of which is readily understood. A substage condenser (not shown in the diagram), which serves to

[1] Directions for making the principal fluids used in histological work, and a description of methods for the preparation of specimens, are given in the Appendix.

concentrate the light thrown up by the mirror to the centre of the object, is valuable when high powers and stained preparations are employed.

For ordinary work there should be at least two objectives in constant use—a low power working at about 8 millimeters ($\frac{1}{3}$ inch) from the object, and a high power having a focal distance of about 3 millimeters ($\frac{1}{8}$ inch); it is useful also to have a lower power (commanding a larger field of view) for finding objects readily, and two or more oculars of different magnification.

The above combinations of objectives and oculars will give a magnifying power of from 40 to 400 diameters, sufficient for most purposes of histology. But to bring out minute points of detail in the structure of cells and of certain tissues examination with much higher magnifying powers may be necessary. Objectives of high power are usually made as immersion-lenses: *i.e.* they are constructed to form a proper image of the object when the lowermost lens of the system is immersed in a layer of liquid which lies on the cover-glass of the object and has a refractive index not far removed from that of the glass itself. For this purpose an essential oil (oil of cedar-wood) is used. Besides their high magnifying power, the advantages obtained by the employment of these oil-immersion lenses are: increased working distance from the object, increased angle of aperture with sharper definition of the object, and increased amount of light traversing the microscope.

Measuring.—A scale for measuring objects should be constructed for each microscope. To do this, put a stage-micrometer (which is a glass slide ruled in the middle with lines $\frac{1}{10}$ and $\frac{1}{100}$ millimeter apart) under the microscope in such a manner that the lines run from left to right (the microscope must not be inclined). Focus them exactly. Put a piece of white paper on the table at the right of the microscope. Look through the instrument with the left eye, keeping the right eye open. The lines of the micrometer will appear projected upon the paper. Mark their apparent distance from one another with pencil upon the card, and afterwards make a scale of lines in ink, of the same interval apart. A magnified representation is thus obtained of the micrometer scale. Mark upon it the number of the eye-piece and of the objective, and the length of the microscope tube. This scale will serve for the measurement of any object without the further use of the micrometer. To measure an object, place the scale upon the table to the right of the microscope and view the object with the left eye, keeping the right eye open. The object appears projected upon the scale, and its size in tenths or hundredths of a millimeter can be read off. It is essential that the same objective and eye-piece should be employed as were used in making the scale, and that the microscope tube should be of the same length, *i.e.* drawn out to exactly the same extent as when the scale was made.

STUDY OF COMMON OBJECTS.

Before beginning the study of histology the student should endeavour to familiarise himself with the use of the microscope, and at the same time learn to recognise some of the chief objects which are liable to occur accidentally in microscope specimens. On this account it has been considered

desirable to introduce directions for the examination and recognition of starch-granules, moulds and torulæ, air-bubbles, linen, cotton, and woollen fibres, and the usual constituents of the dust of a room (see fig. 36).



FIG. 36.—OBJECTS WHICH MAY BE ACCIDENTALLY PRESENT IN MICROSCOPE-PREPARATIONS. (E. Sharpey-Schafer.)

1, Starch-granules; 2, a small air-bubble and part of a large one; 3, yeast torulæ; 4, a mould (*Aspergillus glaucus*); 5, linen fibres; 6, cotton fibres; 7, woollen fibres; 8, hair, human; 9, epithelium scales; 10, micrococci; 11, bacilli and spores (*B. subtilis*). Magnified about 250 diameters.

In examining any object the student should always use the low power first: the object can be looked over with this before the cover-glass is applied. Before the high power is used a cover-glass must always be placed on the preparation. To facilitate changing the objectives they are screwed on to a rotating holder which is fixed to the lower end of the microscope tube: to this holder two or more objectives can be attached.

1. Starch-granules. Gently scrape the cut surface of a potato with the point of a knife; shake the starch-granules so obtained into a drop of water upon a clean slide and apply a cover-glass.

With the low power the starch-granules look like dark specks differing considerably in size; under the high power they are clear, flat, ovoid particles (fig. 36, 1), with a sharp outline when exactly focused. Notice the change in appearance of the outline as the microscope is focused up and down. On close examination fine concentric lines are seen in the starch-granules, arranged around a minute spot which is generally placed eccentrically near the smaller end of the granule. Sketch two or three starch-granules.

Pass a drop of dilute iodine solution under the cover-glass, and observe the staining of the starch-granules.

Notice the appearance of air-bubbles (air-bells) in the water (fig. 36, 2). If comparatively large they are clear in the middle, with a broad dark border due to refraction of the light; if small they may look entirely dark.

2. Look at yeast which has been grown in solution of sugar. Observe the yeast-particles or torulæ, some of them budding (fig. 36, 3). Each torula contains a clear vacuole, and has a well-defined outline, due to a membrane. Sketch two or three torulæ.

3. Examine some mould in water. Notice the long branching filaments (hyphæ), and also the torula-like particles (spores) from which hyphæ may in some instances be seen sprouting (fig. 36, 4). Sketch part of a hypha.

4. Mount fibres of linen and of cotton in water, using a high power. Compare the well-defined, rounded, relatively straight or but slightly twisted linen with the longer, broader but thinner, and more twisted cotton fibres (fig. 36, 5, 6). Sketch one of each kind.

5. Mount one or two hairs from the head in water and look at them first with the low, then with the high power (fig. 36, 8). Examine also fibres from any woollen material and compare them with the hairs. They have the same structure, although the wool is finer and is curled (fig. 36, 7); its structure may be obscured by dye. Draw one of each.

6. Look at a drop of hay infusion, which has been standing a day or two, for bacteria and other putrefactive organisms (fig. 36, 10, 11). The active movements which these exhibit are due to minute cilia or flagella, which can only be made visible by special staining methods and a very high magnifying power. Notice that all very minute particles, organic and inorganic, which occur in fluids may be seen to exhibit the peculiar tremulous dancing movement which is known as the 'Brownian' movement.

7. Examine some dust of the room in water with the high power. In addition to clumps of black particles of carbon (soot) there will probably be seen fibres of linen, cotton, or wool, and shed epithelium-scales (fig. 36, 9) derived from the epidermis.

8. Look at a drop of milk with the high power. Notice the particles of cream. Their fatty nature is shown by their high refracting power, and by their staining reactions with certain special reagents, such as osmic acid or Sudan III.

LESSONS II. AND III.

STUDY OF THE HUMAN BLOOD-CORPUSCLES.

1. HAVE ready a clean slide and cover-glass, and with a clean needle prick the finger smartly above the nail or on the pulp, and touch with the cover-glass the drop of blood which issues from the prick: place the cover-glass on the slide, blood down, as quickly as possible, so that the blood has time neither to dry nor to coagulate. Examine it at once, first with the low, then with the high power.

Note (*a*) the red cells, mostly in rouleaux but some lying apart seen flat or in profile; (*b*) the colourless cells, easily made out if the cover-glass is lightly touched by a needle, on account of their tendency to stick to the glass, whilst the coloured cells are driven past by the currents set up; (*c*) in the clear spaces, fibrin-filaments and blood-platelets.

Sketch a roll of red corpuscles and one or two colourless corpuscles. Count the number of colourless in a field of the microscope.

2. To be made as in § 1, but the drop of blood is to be mixed upon the slide with an equal amount of normal or isotonic saline [1] so that the red corpuscles tend to be less massed together, and their shape better displayed.

Sketch a red cell seen on the flat and another in profile (or optical section). Also a crenated corpuscle.

Measure with the scale (p. 29) ten red cells, and from the result ascertain the average diameter. Measure also the largest and the smallest you can find.

3. Make a preparation of blood as in § 1 and put it aside to coagulate. Keep the edges from drying by placing it in a moist chamber or by occasionally breathing upon it. After a few minutes place a drop of 1 per cent. methyl-violet in saline at one edge of the cover and allow this to pass in and mix with the blood: it may be drawn through the preparation by applying a very small fragment of blotting-paper to the opposite edge. The dye stains the nuclei of the white corpuscles, the blood-platelets, the network of fibrin-filaments, and the membranes of the red corpuscles.

4. Place a small drop of blood on a slide, and at once invert it over the mouth of a bottle containing formol.[2] After five minutes, gently wash with saline to remove blood-corpuscles, place a drop of 1 per cent. methyl-violet solution on it for one minute, wash with water, allow to dry, and cover in dammar. The blood-platelets are especially well shown in this preparation.

5. To fix and stain the red cells:—Place upon a slide a drop of 1 per cent. osmic acid mixed with an equal amount of saturated aqueous solution of eosin. Prick the finger, and mix the blood directly with the coloured fluid, stirring them together with a needle. Cover the mixture and put aside for an hour, protected from evaporation; then place a very small drop of glycerine and water at the edge of

[1] *Normal* or *isotonic saline* is the name given to a solution of sodium chloride containing from 7 to 9 grm. to the litre of distilled water for mammals, from 5 to 6 grm. for the frog. *Ringer's solution* is advantageously used in place of ordinary saline solution. This is made (Locke) by adding to every 100 c.c. of distilled water 0·9 grm. NaCl (0·5 grm. for the frog); 0·024 grm. $CaCl_2$; 0·042 grm. KCl and 0·1 grm. $NaHCO_3$. Or 0·5 grm. $NaHCO_3$ may be substituted for 0·1 grm. and 0·1 grm. $MgCl_2$ added (Dale).

[2] 'Formol' is the term used to denote a 40 p.c. solution of formaldehyde.

the cover-glass. When this has passed under, *i.e.* in about half an hour or more, fix the cover-glass with gold size.

6. Examine blood-crystals of rat, guinea-pig, and squirrel. They can be obtained by merely mixing blood from these animals with a little water, and can be preserved for a time in glycerine or Farrant's solution, or, after drying, in dammar.

7. Prepare hæmin (hydrochlorate of hæmatin) by heating a dry smear of blood on a slide with anhydrous glacial acetic acid. It is not necessary to add salt, since this is present in blood, but if a stain of blood, which may have been washed, is to be examined a small crystal of common salt should be added to scrapings of the stain before heating with the acetic acid, which must always be anhydrous. The crystals of hæmin are permanent.

8. To study the granules of the leucocytes thin blood films are made as follows :

Take up a small drop of blood from the pricked finger by touching it with one end of a slide. Immediately apply this slide, at an angle of from 35° to 45°, to the surface of another slide about half an inch from one end. Push it quickly but gently and evenly to the other end. The slides to be used must be cleaned in alcohol, and dried with a clean cloth. The slightest trace of grease (*e.g.* from the fingers) makes an even smear impossible.

Dry the film by waving the slide in the air to accelerate evaporation; if water is allowed to evaporate slowly from the blood plasma crenation of the red cells may result.

The dry film, having thus been made, is fixed by immersion for a minute in methyl alcohol. It is then stained by a 1 per cent. solution of eosin in rectified spirit (one minute), after which it is rinsed with water, and treated with a 1 per cent. solution of methylene-blue in water (three minutes). The film is again rinsed with water, rapidly dried, and mounted in dammar.

Combined eosin-methylene-blue stains, such as Leishman's, are also employed for films. These require only one operation (see Appendix).

9. Study sections of marrow (from a long bone of rabbit) which have been stained with alcoholic eosin and methylene-blue and mounted in dammar. Observe the fat-cells, the supporting reticular tissue, the proper marrow-cells (myelocytes), the myeloplaxes and the erythroblasts. [See Appendix for methods of fixation and staining.]



FIG. 37. PIPETTE USED FOR THE THOMA HÆMACYTOMETER.

10. Tease in Ringer's solution or serum some of the red marrow from the rib of a recently killed animal. Observe and sketch the varieties of marrow-cells (myelocytes), as well as myeloplaxes (giant-cells) and nucleated coloured blood-corpuscles (erythroblasts).

11. Make a film preparation of red marrow by smearing a little upon a cover-glass or slide, allowing it to dry quickly, and placing it in methyl alcohol. After a minute in this, the preparation may be stained with alcoholic eosin and methylene-blue (or by one of the combined stains) in exactly the same way as a film preparation of blood (see § 8), and mounted in dammar.

12. Enumeration of the blood-corpuscles. This is done by the hæmacytometer.

The principle of this instrument consists in diluting the blood 200 times with a hypertonic solution (which does not hæmolyse the corpuscles) and counting their number in a measured portion of the diluted blood. The counting is effected by placing the diluted blood upon a slide of plate glass to the centre of which is cemented a small glass plate having its upper surface ruled into large squares of $\frac{1}{5}$ mm., these being again subdivided into smaller portions of $\frac{1}{20}$ mm. to facilitate enumeration. The central ruled plate is surrounded by

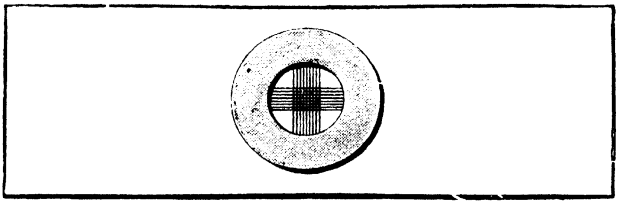

FIG. 38.—HÆMACYTOMETER SLIDE, RULED IN SQUARES FOR THE ENUMERATION OF BLOOD-CORPUSCLES.

a broad glass ring $\frac{1}{10}$ mm. thicker than the ruled glass plate, so that a layer of the diluted blood $\frac{1}{10}$ mm. thick can intervene between the ruled plate and a cover-glass which is laid over the ring. The diluting solution may be either that of Hayem (distilled water 200 c.c., sulphate of soda 5 grm., common salt 1 grm., corrosive sublimate 0·5 grm.) or that of Marcano (97 c.c. of a solution in distilled water of sulphate of soda of sp. gr. 1020, to which is added chloride of sodium 1 grm., and formol 3 c.c.). The finger is pricked, and the pipette (fig. 37) is filled with blood exactly up to the 0·5 mark. The pipette is then filled with diluting solution up to the 101 mark, the blood being thereby drawn up into the mixing vessel, where it is thoroughly mixed with the solution by rolling the pipette with the included glass ball round with the fingers. The blood is thus diluted 200 times. After expelling the clear fluid in the capillary part, a drop of the mixture is deposited in the centre of the ruled plate (fig. 38), and the cover-glass is gently laid on the drop, which thus forms a layer $\frac{1}{10}$ mm.



FIG. 39.—DIAGRAM OF A SECTION THROUGH THE HÆMACYTOMETER SLIDE.

thick between the ruled plate and the cover (fig. 39). In a few minutes the corpuscles will have sunk to the bottom of the layer of fluid and rest on the squares (fig. 40). The number on five of the $\frac{1}{5}$-mm. squares is then counted, and this, multiplied by 50, gives the number in a cubic millimeter of the diluted mixture, and if again multiplied by 200 (the amount of dilution) the number in a cubic millimeter of blood.

For the enumeration of the white corpuscles the blood is diluted only 20 times instead of 200 times. It is also convenient to use either one-half per cent. solution of acetic acid just coloured with methyl-violet as a diluent, or a 2 per cent. formol solution to each c.c. of which one drop of Giemsa's fluid is added. The former solution destroys the coloured corpuscles and stains the nuclei of the white; the latter preserves both red and white corpuscles and shows the granules of the latter (Stitt).

For counting the blood-platelets, blood is diluted (Van Herwerden) with a mixture of 10 per cent. urea solution (21 parts) and normal saline (9 parts). The red cells are hæmolysed and the blood-platelets remain separate.



FIG. 40.—APPEARANCE OF THE SQUARES OF THE THOMA HÆMACYTOMETER WHEN USED FOR A BLOOD COUNT. × 200. Photograph.

THE BLOOD-CORPUSCLES.

The blood contains (1) a large number of non-nucleated **coloured corpuscles** having the shape of biconcave disks (**red cells** or **erythrocytes**),

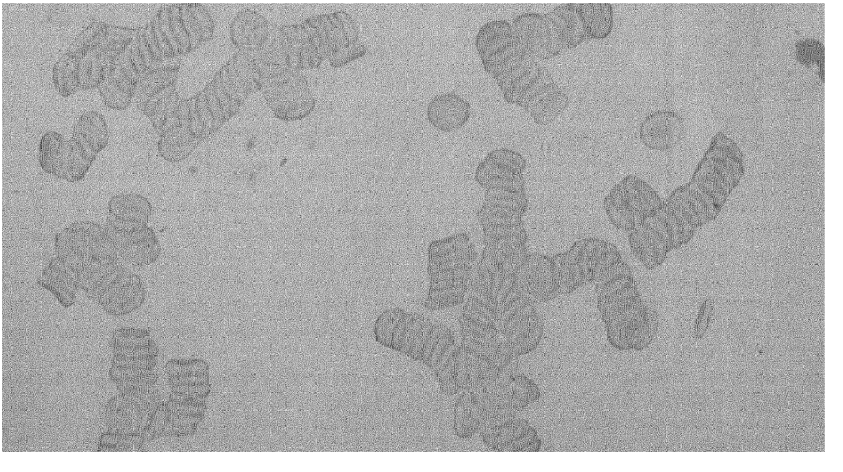

FIG. 41.—HUMAN RED BLOOD-CELLS. (E. Sharpey-Schafer.) × 650. Photograph.

(2) a much smaller number of nucleated **colourless corpuscles** (**white cells** or **leucocytes**), mostly spherical, and (3) a variable number of minute colourless

discoid particles, known as **blood-platelets (thrombocytes)**. All these float in a liquid (**plasma**). The red cells are for the most part in contact with one another like rolls of coins (rouleaux) and the rouleaux themselves form a loose network with clear spaces between occupied by plasma. The latter fluid, shortly after the blood is drawn, deposits fine filaments of fibrin which interlace with one another and entangle the corpuscles in their meshes.

The relative volume of red corpuscles to plasma in human blood, as determined by the hæmatocrit, is as 48 to 52 in the male adult and 43·3 to 56·7 in the female (Hédon).

RED CELLS (ERYTHROCYTES).

The red cell of human and mammalian blood is a fluid droplet consisting of a solution of hæmoglobin with various electrolytes, the droplet being enclosed by a delicate, colourless and highly elastic envelope. The electrolytes include Na, K, Mg, Ca, Cl, and P: of these Ca is in very small amount as compared with that of plasma. The hæmoglobin, to which the red cells owe their colour, is a compound of globin, a protein body containing sulphur, with hæmatin ($C_{34}H_{34}N_4O_5Fe$); it owes its chief function, that of a carrier of oxygen, to the iron in the hæmatin molecule. The envelope of the erythrocyte has a composition like that of cell-protoplasm in general, consisting of proteins and lipoids (phosphatides and cholesterol). There is some reason to believe that the lipoids are accumulated at the outer surface of the envelope. Normal blood of the adult contains about 16 grm. hæmoglobin in 100 c.c.

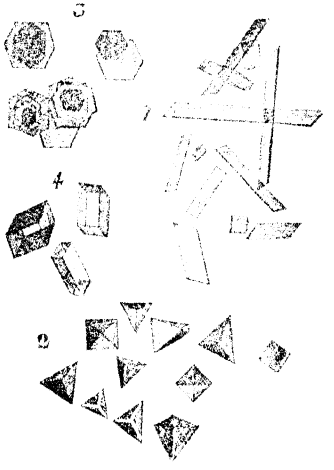

FIG. 42.—CRYSTALS OF HÆMOGLOBIN MAGNIFIED.

1, from human blood; 2, from the guinea-pig; 3, squirrel; 4, hamster.

Hæmoglobin can be obtained in a crystalline form. The crystals are rhombic prisms in man and most mammals, but in the guinea-pig they are tetrahedra and in the squirrel hexagonal plates. In some animals, *e.g.* the rat, they are easily obtained after extraction from the corpuscles by water or if blood is shaken up with chloroform or ether; in other animals and man they are more difficult to obtain. Hæmoglobin rarely crystallises within the corpuscles; the salts they contain appear to keep it in solution (Adrian).

Minute dark brown rhombic crystals are formed when hæmoglobin is heated with anhydrous acetic acid in presence of a chloride. The crystals are a combination of hæmatin with hydrochloric acid and are known as *hæmin* (Teichmann). Their formation constitutes a delicate test for blood.

Other brownish-yellow crystals are often found within phagocytic cells at the site of old blood extravasations (bruises, etc.) and in other places where red cells are undergoing disintegration within the tissues. The substance of which the crystals are formed is termed *hæmatoidin*. In chemical composition it is allied to the colouring matter of bile (bilirubin), which is also a derivative of hæmoglobin.

Hæmoglobin is, in the blood of vertebrates, confined to the red cells. It is also found in the blood of certain worms and other invertebrates; not always within cells, but frequently in solution in the plasma. In some invertebrates, *e.g.* molluscs, cephalopods, crustacea, and arachnids, it is replaced by *hæmocyanin*, a compound protein containing copper in place of iron. Hæmocyanin is never contained in corpuscles but, in those animals in which it occurs, is dissolved in the plasma, to which it gives a bluish colour when in contact with free oxygen, becoming almost colourless when deprived of oxygen.

When seen singly the coloured corpuscles are not distinctly red, but appear of a reddish-yellow tinge. They are biconcave circular disks in the blood of man and all other mammals, except the camel family where they are biconcave elliptical disks. The central part of the human erythrocyte usually has a lightly shaded aspect under a moderately high power; this is due to



FIG. 43.—HÆMIN CRYSTALS, MAGNIFIED. (Preyer.)



FIG. 44.—HÆMATOIDIN CRYSTALS. (Frey.)

its biconcave shape, not to the presence of a nucleus. The red cells only adopt rouleaux formation when the blood is at rest; if it is disturbed they readily separate, again forming rouleaux as it comes to rest.

If the density of the plasma is increased in any way, as by evaporation, or by the addition of a hypertonic solution, many of the red corpuscles become shrunk and irregular in shape (crenated) by the passage of water out of the corpuscle. On the other hand, a diminution in the density of the plasma, such as is caused by water or the addition of a hypotonic solution, tends to cause the red corpuscles to become first cup-shaped and then globular. It is, however, erroneous to describe either of these as normal forms, although a certain number of cup-shaped corpuscles may occur even in the circulating blood when examined in transparent parts of animals. But by far the larger number are biconcave.

The average diameter of the human red blood-corpuscle is usually stated to be 7·5 microns.[1] But Ponder, Millar, and Dryerre have shown that

[1] The micron—designated by the Greek letter μ—is the standard unit of measurement in Histology. $1\ \mu = \frac{1}{1000}$ mm. $= \frac{1}{25000}$ inch.

this figure is too small. These observers measured the corpuscles, floating in natural plasma, in photographs taken immediately after withdrawal. Precautions were employed against deformation caused by changes in the plasma, or by exposure to air or to gaseous mixtures other than those in equilibrium with the gases of the blood. They found the average diameter of the human red corpuscles to be 8·8 microns, and the variations in healthy subjects to be from 6 to 9 microns.[1] The thickness where greatest is about one-fourth of this. In infants up to one month old the red cells are larger than in the adult, but by two months they have assumed the normal size and retain this throughout life.

The following gives in microns the diameter of the red cells of some common mammals (Gulliver):—dog, 7·3; rabbit, 6·5; cow, 6·1; cat, 6·0; horse, 5·7; sheep, 5·0; goat, 3·7. Although of all mammals they are largest in the elephant, viz. 9 μ, their size bears no proportion to the size of the animal.[2]

That the mammalian erythrocyte is nothing but a minute drop of coloured fluid enclosed by a delicate envelope is evident from the way in which the corpuscle undergoes distortion when turning a corner in its passage along the capillaries, and the immediate recovery of shape which follows such distortion. It has been objected to this conclusion that any such minute drop of fluid floating in another fluid with which it does not mix should assume a spherical and not a discoid shape—and it has been suggested that the discoid form must therefore be produced by some internal structure binding the surfaces together.[3] But it was long ago shown by Norris (1882) that small drops of fluid enclosed in myelin (lipoid) envelopes tend to become flattened instead of spherical, as would be the case were the surface-film true fat. This observation of Norris has lately been recalled by Gough (1924), who finds that the flattened shape further depends upon their suspension in plasma or serum. For if erythrocytes are washed free from serum they become spherical, but if again placed in serum they resume the discoid form.[4]

In man there are normally about 5,000,000 red cells in each cubic millimeter of blood in the male adult, and somewhat fewer (about 4,500,000) in the female. There would be therefore at least twenty-five million million in the total quantity of blood (5½ litres) of an average person.

The number in the circulating blood is increased at high altitudes, where the number may be as high as 8,000,000 per c.mm. This is in part due to contraction of the spleen which, as Barcroft has shown, acts as a reservoir for blood-cells; the contraction being caused by diminution in the supply of oxygen. Later, there ensues an increased formation of blood-corpuscles in bone-marrow.

The same effect (increase in number of corpuscles) is produced by breathing

[1] Former measurements have been made from dry preparations (blood-films); a less accurate method.

[2] These figures are probably all low, having been obtained from dry preparations.

[3] Millar (1925) could see no sign of internal structure in the human red cell, even when examined with high powers by dark ground illumination.

A certain number—3 per cent. to 7 per cent.—of red cells have a minute brightly refractile spot on one side. The meaning of this is not understood (Krumbhaar).

[4] Ponder (1924) states that even if left in isotonic saline they eventually resume the discoid form.

rarefied air, while the opposite result is obtained in animals kept in air of greater density than that of the atmosphere (Argyle Campbell).

The volume of each erythrocyte is estimated by Ponder as about 110 cubic microns. It is to be noted that the biconcave discoid shape of the erythrocyte affords a greater surface and a better opportunity for gaseous exchanges between corpuscles and plasma than would be afforded by a sphere of the same volume. Welcker estimated the surface area of each red cell as 128 square microns. Taking this as approximately correct we arrive at the estimation of at least 3000 square metres of aggregate superficial area for the total number of red cells in the whole blood.

The duration of life of the red cell, judged by the amount of bilirubin formed and excreted, has been estimated at about fifteen days. But from experiments in

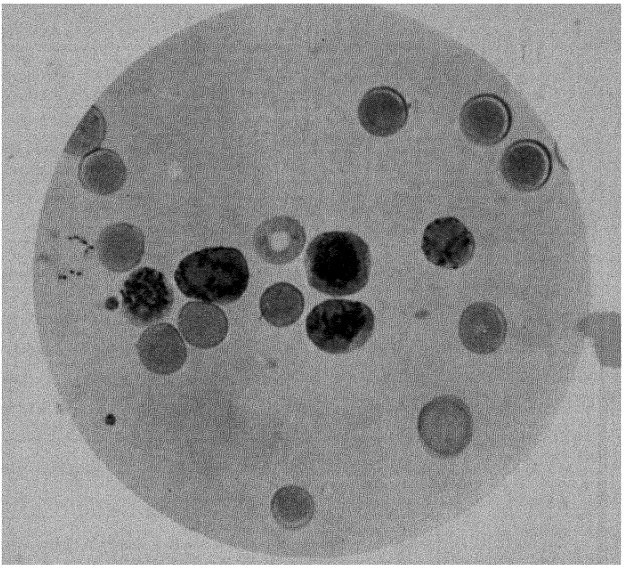

FIG. 45.—RETICULOCYTES IN HUMAN BLOOD. (Davidson and McCrie.) × 1000.
The sample of blood was taken two days after a severe hæmorrhage; it was stained with cresyl-blue.

which blood was transfused from one individual into another belonging to a different but compatible group (see p. 60) the foreign corpuscles have been detected after a much longer period (four to eight weeks).

Reticulocytes.—Besides the ordinary red cells there are present, even in normal blood, a certain number of erythrocytes characterised by a finely granular or reticular appearance when treated with certain 'vital' stains, especially cresyl-blue. Such cells have been termed 'reticulocytes.' They constitute about 0·3 per cent. of the total number of erythrocytes in the adult (Davidson and McCrie). There are more in some animals, the percentage being as much as 3 in the guinea-pig. The cells in question are more numerous in the fœtus and infant; and also in individuals in which, from hæmorrhage or other cause, there is reason to believe that blood-corpuscles are being produced more actively than usual. After severe hæmorrhage in man (fig. 45) the proportion may rise to 35 per cent.

The reticular appearance is not confined to the discoid red cells, but is also seen in nucleated red corpuscles of the marrow (megaloblasts, erythroblasts): it is generally considered to be characteristic of immature red cells. The name *reticulocytes* was given to the cells in question by Krumbhaar (1922), but cells of this description appear to have been observed by Ehrlich as long ago as 1881. The attention of pathologists has lately been centred upon these cells as indicative of stimulation of the blood-forming tissues.

In certain conditions—generally pathological—nucleated reticulated erythroblasts are found in blood, as well as many discoid reticulocytes. They are said to appear in rabbit's blood after repeated injections of splenic extract (Eddy and Downs, 1923). What causes the reticular markings in the developing red cell is not known. It has been suggested that the material taking that form is derived from the nucleus which is undergoing degenerative changes prior to removal, but there are various reasons against this. According to some authorities the appearance is an artifact, due to precipitation by the dye used of a substance in the immature cell which disappears as the cell matures. It is alleged that similar appearances can be produced in all erythrocytes if subjected to suitable preliminary treatment (W. E. Cooke). Nevertheless the reticulation when well marked seems to be a sign of immaturity of the corpuscle exhibiting it.

WHITE CELLS OR LEUCOCYTES.

These are nucleated protoplasmic amœboid cells and are destitute of colour. Hence they are known, in contradistinction to the coloured red cells, as the colourless or white blood-corpuscles. In human blood they are far fewer than the coloured, usually not numbering more than from 7000 to 8000 in a cubic millimeter of blood, about 1 to every 600 red corpuscles, but the proportion of white to red cells is much higher than this in infants and young children.

Considerable temporary variations occur in the number under different physiological conditions, especially the ingestion of food and muscular exercise; the effect in both cases being an increase in number. This is explained by the fact that under these conditions the flow of blood through such organs as the marrow of the bones, the spleen and the liver, in which it is naturally sluggish, becomes accelerated, and leucocytes which have tended to accumulate in these parts become driven out into the general circulation. There may also be a permanent increase or decrease in the number, but this generally indicates some pathological change. When the number is markedly increased the condition is termed *leucocytosis*; when it is markedly diminished it is known as *leucopenia*.

The white cells are specifically lighter than the red. If examined immediately the blood is drawn, they are spherical in shape, but soon become flattened and then irregular, owing to the amœba-like changes to which they are subject. Most are phagocytic, the protoplasm tending to take in foreign particles with which the cells come in contact. Some white cells contain fine, others coarse granules in their protoplasm; others again have a hyaline protoplasm without any apparent granules. They are usually examined in stained blood-films (fig. 46 and accompanying plate).

In size the smaller white cells are about the diameter of a red cell, but

most are larger. It should, however, be realised that the shape of the white cell in the living state is as variable as that of an amœba, and that its size in blood-films is influenced by the extent to which it is spread out on the glass. Hence in different blood-films white cells of the same kind may seem to vary in size more than they actually do. The best criterion is their relative size immediately the blood is drawn, when they are all spherical.

The white cells of the blood have each a single nucleus which, in outline, is either evenly circular or oval, or indented at one side, or definitely kidney-shaped; or it may be composed of a variable number of lobes, which are united to one another by threads or bridges of nuclear substance, the nucleus being apparently multiple. Each leucocyte has a centriole, sometimes more than one. The centriole is always near the nucleus; generally opposite

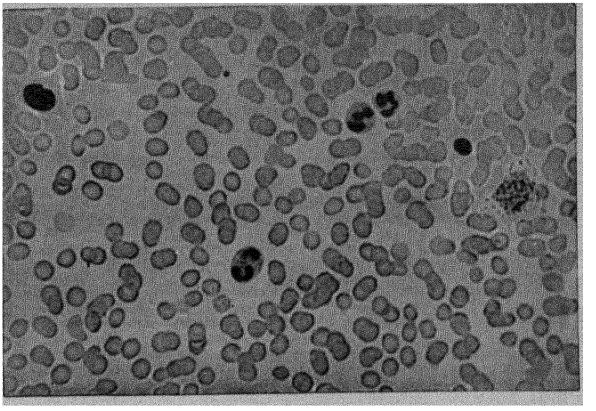

FIG. 46.—BLOOD-FILM STAINED WITH HÆMATOXYLIN AND EOSIN. (E. Sharpey-Schafer.) × 400. Photograph.

There are seen in the field, besides numerous red corpuscles, five leucocytes and a mass of blood-platelets (on the right), as well as a few scattered platelets. Of the leucocytes, that on the left is a macrocyte, that on the right a lymphocyte, and the rest polymorph.

an indentation in it. Blood-leucocytes never exhibit mitoses in the adult state. If they multiply at all in the blood, and of this there is little evidence, it is by amitosis (fig. 21). Like all other cells the white cells possess mitochondria. These vary in form, number, and arrangement in the different kinds of leucocyte. A Golgi apparatus can also be demonstrated, after appropriate fixation, in most leucocytes.

Classification.—Leucocytes are classified (Ehrlich) according to the character and appearance of the nucleus and cytoplasm and the nature and staining qualities of the granules in the latter. Some of the granules are readily stained by basic dyes such as methylene-blue; such granules are termed *basiphil*. Distinct coarse basiphil granules are, however, rare in normal blood, although cells with these granules are always present in the marrow and in some connective tissues, and make their appearance in the blood in some types of leucocythæmia. On the other hand, some granules readily take up colour from acid dyes, such as eosin; these have been

termed *oxyphil* or *eosinophil.* Others are stained impartially by basic and acid dyes: these are termed *amphophil* or *neutrophil.*[1]

In this manner the leucocytes of human blood can be arranged in five main groups as follows:

1. Polymorphs ('polymorphonuclear' and 'polynuclear' leucocytes of authors). These constitute from 65 to 70 per cent. of the total leucocyte number.

2. Lymphocytes. These constitute from 20 to 25 per cent. of the total leucocyte number.

3. Oxyphils or eosinophils. These embrace from 2 to 4 per cent. of the total leucocyte number.

4. Macrocytes (uninuclears).

(*a*) Large uninuclears ('mononuclears,' 'monocytes,' and 'macrophages' of authors). These form from 2 to 4 per cent. of the total leucocyte number.

(*b*) Medium-sized uninuclears ('transitional' leucocytes of authors). These constitute from 0·5 to 1 per cent. of the total leucocyte number.

5. Basiphils ('Mastzellen' of German authors). These form less than 0·5 per cent. of the total leucocyte number.

We may consider the leucocytes belonging to each of these groups separately. (See coloured plate.)

1. **Polymorphs.**—The polymorph leucocyte, when spherical, is rather larger in diameter than a red blood-corpuscle. Its cytoplasm contains a number of moderately fine 'neutrophil' granules staining reddish-purple with Leishman's stain.

The nucleus may be almost simple, *i.e.* may be composed of only a single lobe (this, however, is always elongated with a distinct bend or kink), or it may consist of from two to five interconnected lobes (fig. 47).

Arneth count.—Arneth pointed out that the degree of lobulation of the nucleus is of clinical interest. He divided the polymorphs into five groups as follows:—Group I containing those forms in which the nucleus is simple or uni-lobed, Group II bi-lobed, and so on to Group V in which, in man, there is the maximum number of five lobes. The average percentage number of each group in normal blood is, according to W. E. Cooke,

I.	II.	III.	IV.	V.
12	25	46	15	2

In several diseases these percentage numbers undergo characteristic variations. Alterations can also be produced experimentally: *e.g.* as the result of hæmorrhage, of changes in diet, exposure to X-rays, to ultra-violet rays, and so on. But the most effective agent in causing variations in the Arneth count is thyroid administration.

It has long been known that a leucocytosis can be induced (*e.g.* in rabbits) by the injection of thyroid extract subcutaneously. Ponder has shown that accompanying this there is a deflection of the count towards the left, *i.e.* towards

[1] It must be understood that although the term 'granules' is in common use for the cell-inclusions in question, it does not necessarily mean that they are solid; indeed there is reason to think that many are of a fluid nature and might therefore rather be termed 'globules.'

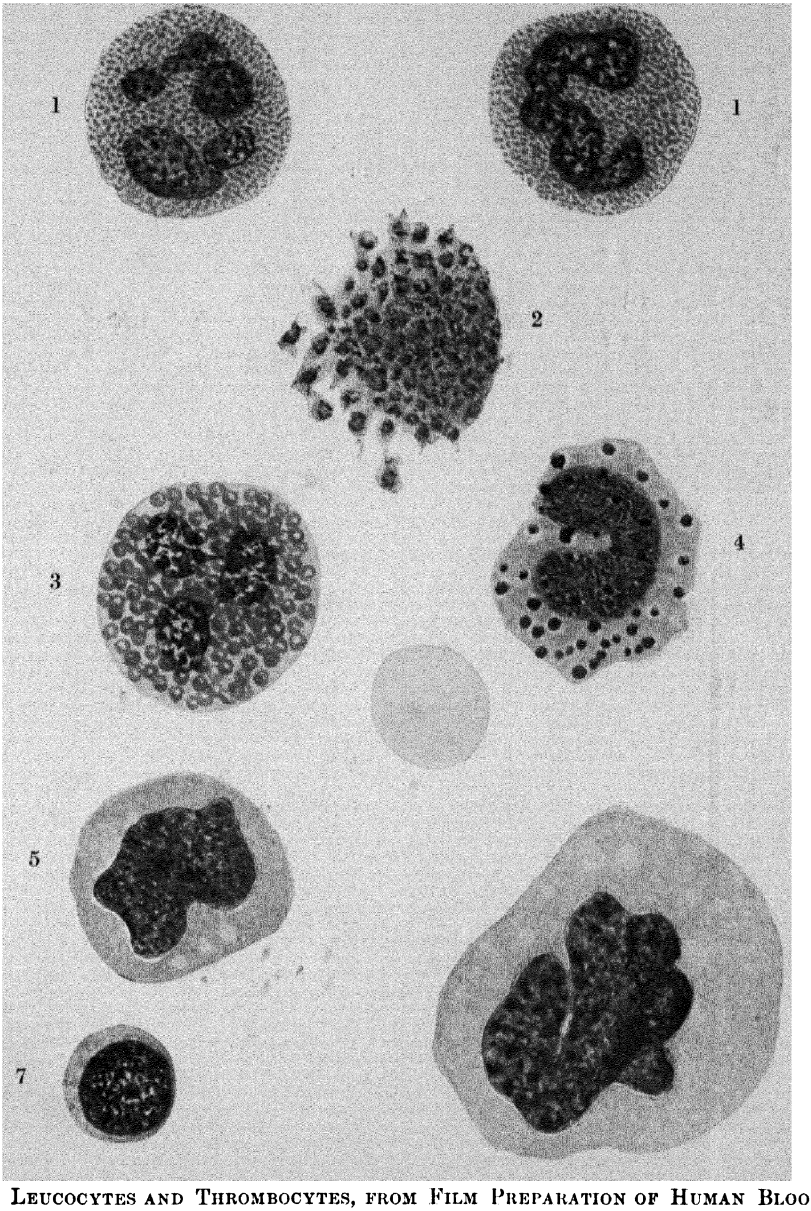

LEUCOCYTES AND THROMBOCYTES, FROM FILM PREPARATION OF HUMAN BLOOD, STAINED WITH METHYLENE BLUE AND EOSIN BY LEISHMAN'S METHOD. (E. Sharpey-Schafer.) $\times 2000$. From photographs.

1, 1, polymorph leucocytes; 2, clump of thrombocytes, some of them partly detached; 3, oxyphil (eosinophil) leucocyte; 4, basiphil leucocyte (mast-cell): the cell depicted has relatively few granules; 5, transitional leucocyte; 6, macrocyte; 7, lymphocyte.

An erythrocyte is also represented at the same magnification, but the relative size of the leucocytes cannot be judged from a film preparation, since they are liable to be flattened against the glass.

polymorphs with the more simple nuclei. This rise (which is absolute as well as relative in the number of cells in Group I is followed by a fall. Concomitantly with this fall in Group I a rise is now observed in Group II. Successive rises and falls pass right along the groups to Group V. Then the numbers of cells in the several groups again become normal.

On this and other evidence Ponder shows that the older cells are those with multi-lobed nuclei. It takes two to three weeks for a cell belonging originally to Group I to become a cell of Group V and then to disappear. If the count is displaced towards the left, there is going on regeneration of polymorphs and activity in bone-marrow, where they are formed; if deviated towards the right, polymorphs

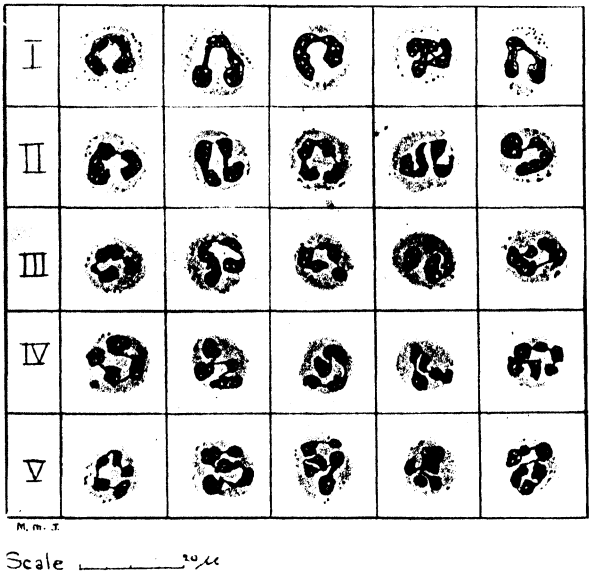

FIG. 47.—TO ILLUSTRATE THE APPEARANCE OF POLYMORPH LEUCOCYTES IN THE SEVERAL ARNETH GROUPS. (W. E. Cooke.)

are disappearing more rapidly than they are being replaced. It is probable that the life of a polymorph leucocyte does not exceed about four weeks (Ponder and Scott).

The polymorph is the most actively motile of the white cells. Its capacity for engulfing foreign particles (phagocytosis), and particularly bacteria, is well marked. But the polymorphs with many-lobed nuclei are no more phagocytic than those with more simple nuclei.[1]

2. **Lymphocytes.**—The majority of lymphocytes are about the diameter of a red cell; some are larger. The relationship of the larger to the smaller lymphocytes is uncertain, but possibly the large are older forms of the small.

The structure and staining are characteristic. The nucleus is round or oval, sometimes indented. In fixed preparations it is markedly reticular. The cytoplasm is small in amount and is hyaline, showing no distinct granules; it is, however, as a whole basiphil, staining very faintly blue with Leishman.

[1] For the literature of this subject see 'The Polynuclear Count,' by W. E. Cooke and Eric Ponder, 1927.

The mobility of the lymphocyte is much less than that of the polymorph; its phagocytic power is also slight.

3. **Oxyphils.**—The oxyphil (eosinophil) leucocyte ('acidophil' of some authors) is, in size, equal to, or rather larger than, the polymorph. The nucleus is kidney-shaped, bi-lobed or tri-lobed. Characteristic of the oxyphil are the numerous large spherical granules in its cytoplasm; these stain intensely with acid dyes, such as eosin. In the oxyphils of horse's blood the granules are very large and of an oval shape.

The oxyphil leucocyte is mobile, but not definitely phagocytic. It has a marked propensity for passing through the walls of blood-vessels into the surrounding tissues. This phenomenon, which is common in varying degrees to all the blood-leucocytes, is known as *diapedesis*.

4. **Macrocytes.**

(*a*) The large uninuclear leucocyte or true macrocyte is the largest of the white cells, often measuring from 15 μ to 20 μ in diameter. The nucleus is round or oval. The cytoplasm is in relatively large amount; it remains uncoloured by stains or is feebly basiphil. It does not contain characteristic granules, although it may occasionally show a few oxyphil particles.

In behaviour the large uninuclear is not only one of the most mobile but also the most phagocytic of the white cells, especially towards foreign bodies and parasitic organisms.

(*b*) The transitional macrocyte is not very unlike the polymorph but distinctly larger. Its nucleus is kidney-shaped or incompletely bi-lobed, and stains less intensely than that of the polymorph. The cytoplasm varies from showing indifference to staining to being slightly basiphil. A few neutrophil granules, staining like those of the polymorph, are sometimes seen in the cytoplasm. It was originally regarded as transitional between the large uninuclear and the polymorph, but the differences between it and the polymorph are considerable, viz. (1) its nucleus, nearly always lobed in the polymorph, is merely indented or kidney-shaped here, and is stained by basic dyes less intensely than that of the polymorph; (2) the amount of cytoplasm in the transitional is relatively greater than in the polymorph. On the other hand the transitional shows many points of resemblance with the large uninuclear leucocyte, having similar characters and staining reactions. And in those pathological conditions which cause the true macrocytes to increase or decrease in number the transitionals behave correspondingly. The grouping of both under the heading of 'macrocyte' appears therefore to be justified. The transitional may be a younger form.

5. **Basiphils.**—The basiphil leucocyte is somewhat larger than the polymorph. The nucleus is usually bi-lobed, sometimes kidney-shaped. Characteristic are the large basiphil granules staining a deep purple with Leishman and dark blue with methylene-blue and eosin. When numerous they obscure the nucleus. Apart from the basiphil staining of the granules this leucocyte is in general appearance very like the oxyphil. It has been suggested that the basiphil is a degenerating form of the oxyphil, the granules of which have undergone transformation into a mucin-like substance (mucoid degeneration), but this is doubtful.

Basiphils are rare in normal adult human blood, never forming more than 0·5 per cent. of the leucocyte count. Cells like the basiphil leucocytes of blood, but somewhat larger, are common in the tissues, particularly in those regions where fat is being deposited. The relationship of these tissue-cells to those of the blood is however uncertain.

In addition to the cells above described, large cells, often nearly double the diameter of the polymorph, may be found in the blood under certain pathological conditions (various infections, pernicious and some other forms of anæmia). Cooke has termed these cells *macropolycytes*, but *macropolymorphs* is a better designation. They resemble polymorphs in general characters, but are larger. Some of them resemble the megakaryocytes of marrow; these have only been seen in grave cases of pernicious anæmia.

BLOOD-PLATELETS.

In the clear fluid in which the blood-corpuscles are suspended, a network of fine intercrossing filaments of fibrin soon makes its appearance. This

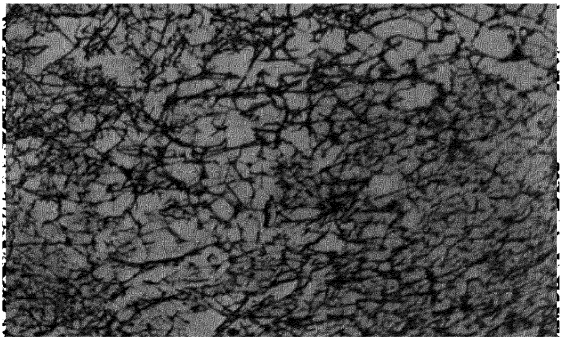

FIG. 48.—NETWORK OF FIBRIN-FILAMENTS FROM A SECTION OF BLOOD-CLOT. (E. Sharpey-Schafer.) × 400. Photograph.

fibrin network is well seen in sections of clotted plasma (fig. 48). The filaments generally radiate from minute round colourless discoid or spindle-shaped particles less than one-third the diameter of a red corpuscle, which either lie separately or are collected into clumps or masses of variable, sometimes of considerable size. These particles are the *blood-platelets*, or *thrombocytes* which were first described as constant constituents of the blood by Bizzozero (1882) although they had been observed previously. Most of the platelets measure not more than 2 μ, but a few are rather larger than this. In the blood-vessels they are discrete (fig. 49), but they immediately clump together when



FIG. 49.—BLOOD-CORPUSCLES AND ELEMENTARY PARTICLES OR BLOOD-PLATELETS, WITHIN A SMALL VEIN OF YOUNG RAT. (W. Osler.)

blood is drawn and is allowed to coagulate. If, however, the blood is examined under certain conditions which hinder coagulation, the platelets can be kept separate. In these circumstances they may be stained and submitted to high powers of the microscope. The result of such examination shows that each contains a minute particle or particles staining rather more deeply than the rest of the platelet (figs. 50, 51). These particles have been considered to represent nuclei, and the platelets have on this ground been regarded as cells (Deetjen). The view is supported by the fact that in Amphibia, where the thrombocytes are much larger, they unquestionably contain a nucleus. It is, however, doubtful if the thrombocytes of Amphibia are homologous with the blood-platelets of mammals (see p. 55).

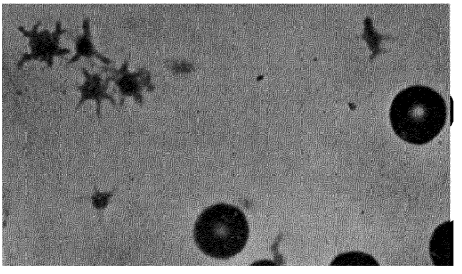

FIG. 50.—HUMAN BLOOD-PLATELETS FIXED WITH FORMOL AND STAINED WITH IRON-HÆMATOXYLIN. (Van Herwerden.) × 1000.

Two or three red cells are included in the photograph and serve to show the relative size.

Blood-platelets vary greatly in number. They are counted after dilution of blood with fluids which prevent clumping. Flössner states that they average in man 760,000, in woman 682,000, in each cubic millimeter of blood. This number is however unusually high; others have obtained a smaller figure (200,000 to 400,000 in both sexes). In any case, the number varies very greatly even in normal individuals. They are said to be much increased in number in anaphylaxis (Pardi).

Cramer states that the number of platelets is diminished if the diet is deficient in fat-soluble vitamin A and increased under the influence of light, especially ultra-violet. He suggests that the platelets assist in the mechanism of resistance to bacterial infection. This may be so, but their chief function is undoubtedly in connexion with blood-coagulation: hence the name *thrombocytes*. The tendency of plasma to coagulate depends on the number of thrombocytes it contains. Hydrocele fluid, which resembles plasma in its general composition but contains no thrombocytes, does not coagulate spontaneously. Both lymph and chyle contain platelets.

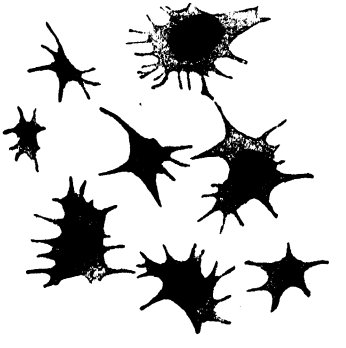

FIG. 51.—BLOOD-PLATELETS, HIGHLY MAGNIFIED, SHOWING THE IRREGULAR FORMS WHICH THEY ASSUME WHEN BROUGHT IN CONTACT WITH FOREIGN MATTER. (After Kopsch.)

If the platelets come in contact with glass or other foreign or injured surface they adhere to this and to one another and undergo a disintegrative change, shooting out clear globules in all directions, accompanied by the formation of filaments of fibrin, which fix themselves to adjacent structures (Tait and Burke).

In subjects of hæmophilia the blood-platelets undergo disintegration much more slowly than in the normal subject (Howell and Cekada).

The spreading out upon glass or other foreign surface is not analogous to the

amœboid movement of the leucocyte, for it is irreversible (Tait, 1918), being a pronounced example of *thigmotaxis* (tendency to adhere to solid substances): Tait has accordingly termed them *thigmocytes*. If solids in suspension, such as Indian ink particles, are injected into the blood, they adhere at first to the blood-platelets; subsequently such particles are taken up by phagocytic cells of the reticulo-endothelial system (see p. 105).

Besides blood-platelets various other minute particles in the plasma have been described. They are most evident when it is examined by dark ground illumination. The majority of the particles thus brought to view are fatty and have been derived from the chyle; they are therefore only abundant during digestion of a meal containing fat.

In fasting the fat of the body becomes mobilised and fatty particles appear in plasma; they begin to show themselves on the second day and increase up to the fifth day (Gage and Fish).

Formation and Development of Blood-cells: Hæmapoiesis.

In the early embryo.—The first blood-cells are developed along with the blood-vessels and heart, and are mesodermic (mesenchymic) in origin.



Fig. 52.—Development of blood-vessels and blood-corpuscles in the vascular area of the guinea-pig. (E. Sharpey-Schafer.)

bl, blood-corpuscles becoming free in the interior of a syncytium of mesoderm cells.

Their appearance takes the form of syncytial accumulations of cells (angioblasts) which are seen in the mesoderm of the yolk sac about the third week of intrauterine life in man. The central cells of the accumulations become free within a cavity in each syncytium. These central cells acquire hæmoglobin and become nucleated embryonic red cells whilst the peripheral parts of the syncytium presently anastomose with other syncytia by means of protoplasmic extensions into which the cavities of the syncytial are prolonged. The walls of the cavities become transformed into the endothelium of the developing blood-vessels; the endothelium being always the portion of the vessels to develop first, the other tissues of the vascular wall being added later. The isolated red clumps were first described by Pander, and were termed by him *blood-islands*.

As above stated the first appearance of blood-vessels is in the wall of the yolk sac. Here within an area surrounding the embryo known as the *vascular area* they develop into a complete network of vessels. Presently, as development proceeds, the vessels of this area extend into the embryo itself and, joining others which are similarly formed in the embryonic mesoderm, pour their contained blood into the

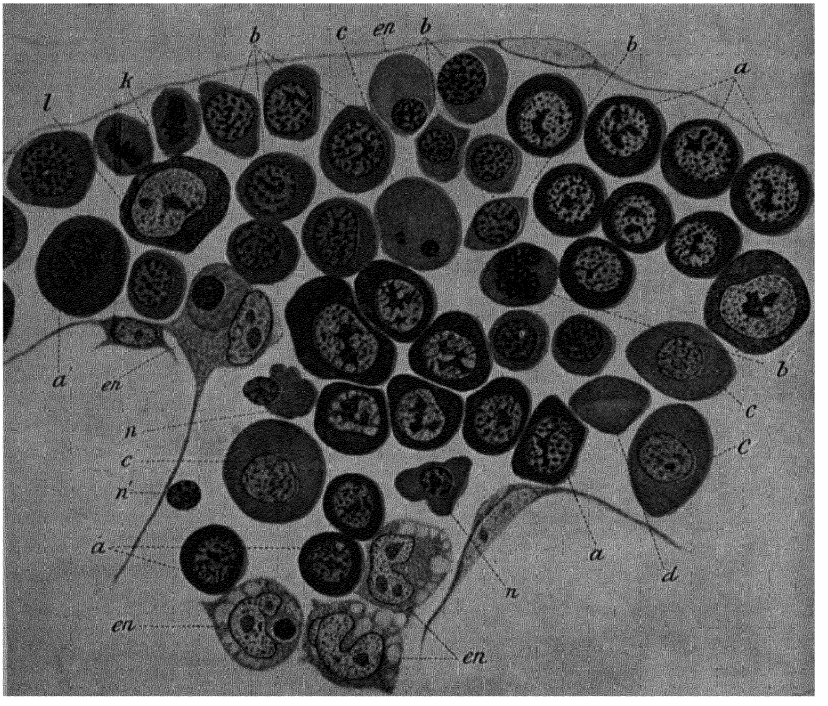

FIG. 53. BLOOD-VESSEL WITH DEVELOPING BLOOD-CORPUSCLES FROM YOLK SAC OF RABBIT EMBRYO. (Maximow.)

a, *b*, *c*, erythroblasts in various stages of development; in some the nucleus is becoming small and atrophic; *d*, an erythrocyte fully formed but not yet discoid; *n*, normoblasts, somewhat distorted in shape, with their nuclei atrophied and apparently becoming extruded; *n'*, an extruded nucleus; *k*, an erythroblast which has just divided; *en*, endothelium cells, one of them containing an erythroblast; *l*, a lymphoblast.

posterior or venous end of the simple tubular heart. From the other end of the tube the primitive aortæ pass with a backward curvature, and deliver the blood again to the vascular area of the yolk sac. This arrangement of the primitive vascular system can be readily observed in the incubated hen's egg of the second and third day.[1]

The blood-islands at first contain no white cells but only nucleated red cells. Considerably later, two types of cell may be recognised within the

[1] For a good account of the development of the blood-vessels and blood in the chick blastoderm see F. E. Sabin, 'Contributions to Embryology,' 1920 (Carnegie Institute of Washington), whose observations closely correspond to the account here given for the mammal, except that she believes that the erythroblasts are budded off the endothelium of the primitive vessels.

developing vessels, viz. (*a*) *embryonic cells*, known as **erythroblasts**,[1] having a spherical nucleus around which is a considerable amount of cytoplasm containing hæmoglobin. These first erythoblasts have large nuclei and are termed **megaloblasts**; (*b*) *embryonic white cells* termed **leucoblasts**, resembling the large mononuclear hyaline leucocytes of adult blood.

The primitive erythroblasts (megaloblasts) multiply by mitosis within the blood-vessels (fig. 53). It is stated that erythroblasts may also be formed by budding from the endothelium of the embryonic vessels. As development proceeds the erythroblasts acquire more hæmoglobin and their nuclei become smaller. They are now known as **normoblasts.** They

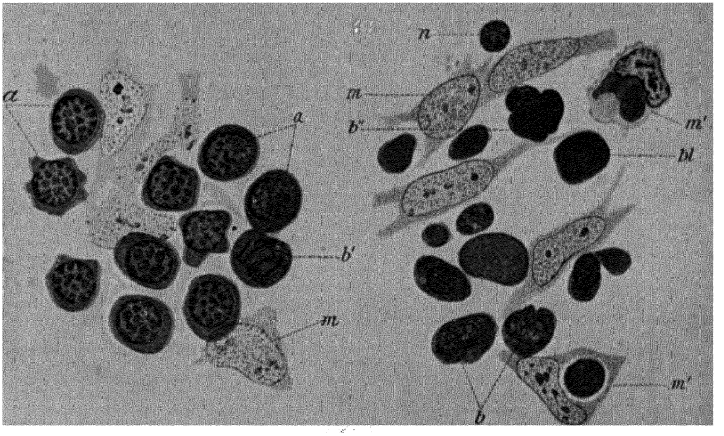

FIG. 54.—GROUPS OF ERYTHROBLASTS IN MESODERM OF EMBRYO RABBIT. (Maximow.)
a, *b*, *b'*, erythroblasts; *b''*, extrusion of nucleus from an erythroblast; *m*, mesoderm cells; *m'*, mesoderm cells containing hæmoglobin; *n*, an extruded nucleus; *bl*, erythrocyte.

are still spheroidal, but presently losing their nuclei they become discoidal like the red cells of the adult.

By the middle of intrauterine life most of the red cells are non-nucleated biconcave disks: at birth all are in this condition, which persists throughout life.

In embryonic and young connective tissue.—The formation of red cells takes place in the mesoderm of the embryo (fig. 54), and in some animals even after birth within certain cells of the connective tissue (Ranvier, Schafer). These cells are termed *vaso-formative cells* or *angioblasts*. Part of their cytoplasm is coloured with hæmoglobin: this coloured part becomes divided up into globular particles (fig. 55, *a*, *b*, *c*): these are subsequently moulded into disk-shaped red corpuscles. In the

[1] The term 'erythroblast' was originally applied by the discoverer (Bizzozero) to *all* nucleated red cells which are precursors of erythrocytes. It has, however, been restricted by recent authors (*e.g.* F. E. Sabin) to the nucleated red cells which are formed by division of the primitive large erythroblasts (megaloblasts), *i.e.* intermediate forms, and which become transformed with normoblasts; these again being transformed into erythrocytes. In the account here given the term is employed in its original meaning.

meantime the vaso-formative cells become hollowed out and give off branches which join with similar neighbouring cells to form blood-vessels (fig. 55, *d*, *e*, *f*). The process is somewhat different from that prevalent in the early embryo in which cell-nuclei are included in the hæmoglobin-holding protoplasm from which the erythrocytes are formed, although in places where the red cells are produced by budding off from the endothelium of the developing vessels, nuclei do not appear to be included in the separated buds (fig. 56).

It has been suggested that the vaso-formative cells containing coloured corpuscles in various stages of development are in reality portions of an already formed vascular network which is undergoing atrophy, and that the corpuscles within

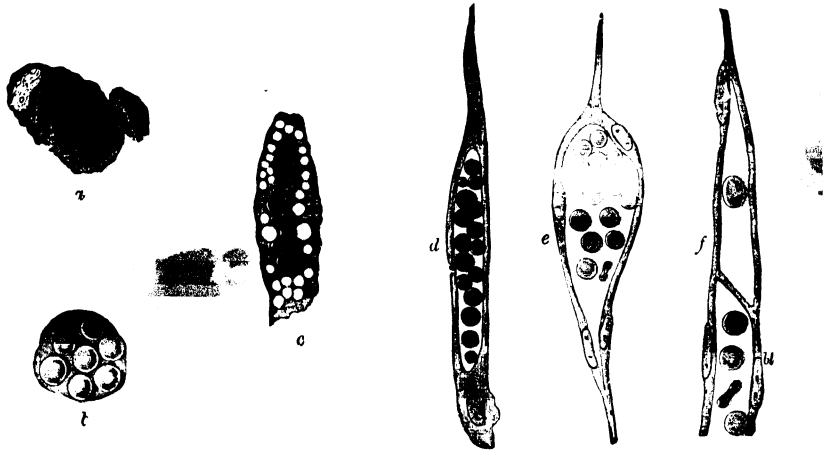

FIG. 55. BLOOD-CORPUSCLES DEVELOPING WITHIN EMBRYONIC CONNECTIVE-TISSUE CELLS. (E. Sharpey-Schafer.)

a, a cell containing hæmoglobin; *b*, a cell filled with globules of hæmoglobin; *c*, a cell containing hæmoglobin globules in the cytoplasm, and also numerous vacuoles; *d*, an elongated cell with a cavity occupied by fluid and blood-corpuscles, mostly globular; *e*, a hollow cell, the nucleus of which has multiplied. The new nuclei are arranged around the wall of the cavity, the corpuscles in which have become discoid; *f* shows the mode of union of a vaso-formative cell, which in this instance contains only one corpuscle, with the prolongation (*b'*) of a previously existing vessel.

such cells are not in process of formation but of disappearance. But since the appearances in question are seen in parts in which vascular tissues (such as fat) are undergoing not atrophy but formation; and since, moreover, the hæmatoidin crystals and pigment granules which are characteristic of the disintegration of erythrocytes within cells are never present, it seems reasonable to interpret the appearances as indicative of intracellular development of blood-corpuscles by differentiation of part of the protoplasm of the vaso-formative cell, rather than as a degeneration of already formed blood-vessels and blood-corpuscles.

In the fœtal liver. The liver is the most important red cell factory from about the third month until close upon birth. The red cells are produced by multiplication of erythroblasts, both within and outside the blood-channels (fig. 56); according to Maximow they may also be produced by budding from the endothelium of the blood-vessels. White blood-corpuscles appear to be formed as well as red within the embryonic liver.

In the fœtal spleen.—Here also both red and white cells are produced

during the latter part of fœtal life. The mode of formation is similar to that in the liver. Concomitantly with the development of the lymphoid tissue of the spleen, the formation of white cells increases while that of red cells diminishes. The formation of red cells ceases before birth and only white cells, in the shape of lymphocytes (formed in the Malpighian bodies) and large

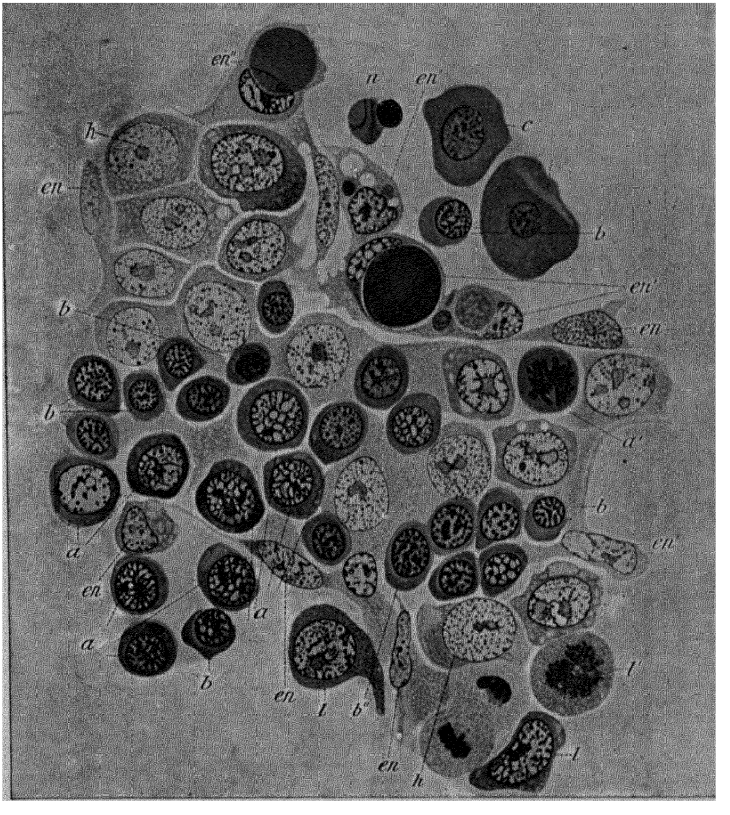

FIG. 56.—BLOOD-FORMATION IN LIVER OF EMBRYO RABBIT. (Maximow.)

en, endothelial cells of vessels; *en'*, *en''*, globules of hæmoglobin, some small, others large, forming within endothelium cells; these hæmoglobin globules do not involve the nucleus; *a*, *b*, *c*, erythoblasts in various stages of development, the larger being megaloblasts and the smaller normoblasts; *n*, a normoblast showing extrusion of an atrophic nucleus; *h*, hepatic cells; *l*, lymphoblasts; *l'*, lymphoblasts in mitosis.

mononuclear cells (formed in the reticulum of the pulp), are now produced in the spleen.

In lymph-glands.—As these glands become developed in the embryo, lymphocytes and perhaps cells of the large mononuclear type pass from them into the lymphatic system, whence they eventually enter the circulation The formation of red cells has also been described as occurring to a small extent in the lymph-glands of the fœtus.

In fœtal bone-marrow.—The blood-vessels which are developed in the

course of ossification, which invade the centre and gradually extend towards the still cartilaginous ends of the long bones, appear to be formed *in situ* by an outgrowth from the already existing vessels of the periosteum which accompany the ingrowth of the osteoblastic tissue (see 'Development of Bone,' Lesson XIII). There are some indications that blood-corpuscles are formed within the newly forming vessels, perhaps by budding from their endothelium. The original fœtal marrow is entirely composed of this vascular osteoblastic tissue which occupies the medullary spaces of the developing bone. But later, when those spaces have become enlarged by erosion of their partitions by osteoclasts (p. 137) the fœtal marrow is seen to be formed of a jelly-like tissue traversed by very large thin-walled blood-vessels. Within these vessels there may be some production of erythroblasts and erythrocytes, but there is none outside the vessels as in the adult. Later, the picture changes. The jelly-like marrow gives place to a tissue which resembles in all respects the red marrow of the adult and assumes the function of production both of red cells (erythroblasts and erythrocytes) and of white cells (myelocytes and leucocytes), as in the red marrow after birth and throughout life.

According to Jordan hæmapoiesis begins in man as early as the sixth week in the marrow of the clavicle; as late as the third month in that of the ribs, and as late as the fifth month in the sternum.

In the bone-marrow after birth and throughout life.—The marrow of bone is of a yellow colour in the shafts of the long bones of most mammals, and is there largely composed of adipose tissue, but in the shafts of the long bones of some animals such as the rabbit, and in the cancellated tissue of most mammals, especially that of the ribs, it has relatively few fat-cells, and is usually red; the colour being mainly due to the large amount of blood in its vessels. This red marrow (figs. 57, 58) is chiefly composed of protoplasmic cells termed **myelocytes** or **marrow-cells,** which resemble large leucocytes, and, like these, are amœboid. They are believed to give rise by division to certain of the blood-leucocytes. They exhibit the same kind of differences as the latter in respect of the character of the granules they contain, some having *oxyphil,* others *basiphil,* and others *neutrophil* granules—but basiphils are far more numerous in marrow than in blood.

There are also to be seen mingled with the myelocytes a number of nucleated cells of a reddish tint, mostly smaller in size than the myelocytes (fig. 58). These are **erythroblasts**; they resemble the nucleated coloured corpuscles of the embryo which are so designated (p. 49) and, like those, vary in size, some measuring about 0·007 mm. (**normoblasts**), but others being larger and with larger nuclei (**megaloblasts**). The smaller appear to be formed by division of the larger. The erythrocytes are formed from the normoblasts, the nucleus disappearing and the coloured protoplasm becoming fluid and moulded into a discoid shape.

This formation of blood-corpuscles in bone-marrow begins, as we have seen, in the fœtus; after it has commenced there it continues throughout the whole of life. The red marrow, particularly that of the ribs, is especially

A

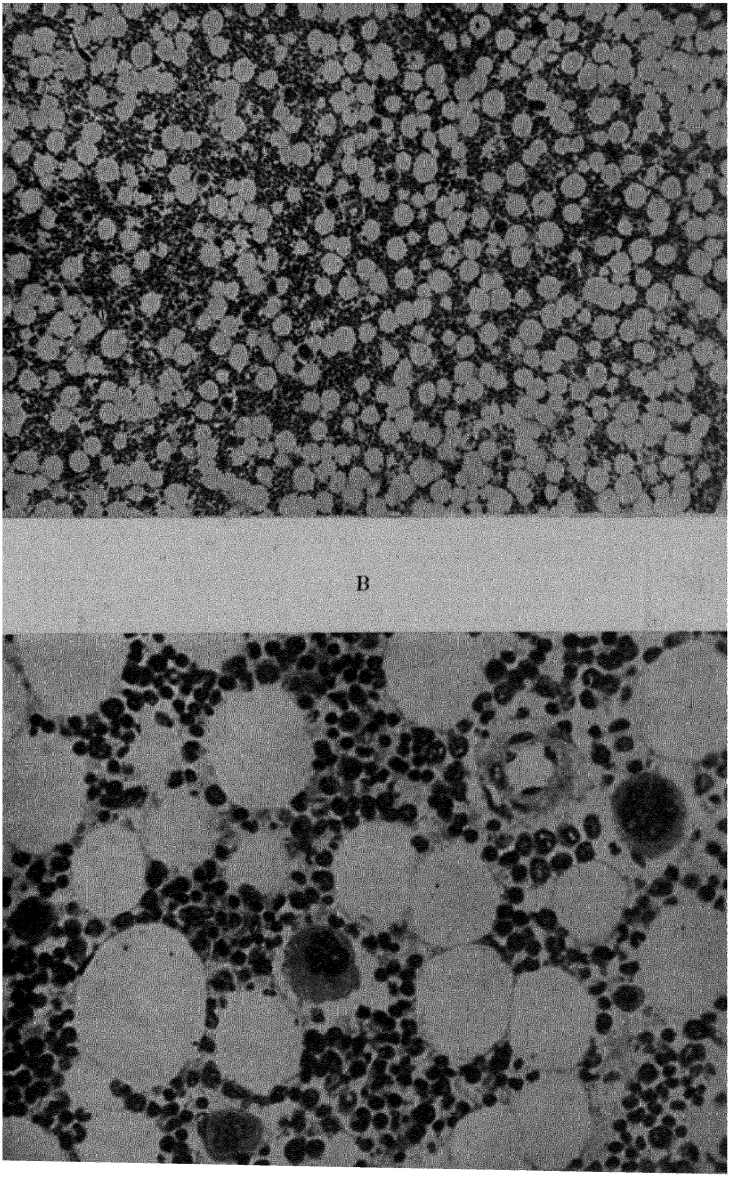

B

FIG. 57.—SECTIONS OF RED MARROW OF RABBIT. (E. Sharpey-Schafer.) Photographs.

A, Magnified 75 diameters. B, Magnified 400 diameters.
The clear spaces are due to fat-cells, the fat having been dissolved out in the process of mounting.

active in this respect, although hæmapoiesis is not necessarily confined to red marrow but may occur in yellow marrow as well.

In mammals the multiplication of nucleated coloured corpuscles and the formation of the discoid red cells appear to take place wholly within the tissue of the marrow and external to the blood-vessels. It is uncertain to what extent the capillary vessels of the marrow are limited by a complete endothelium, but in any case the erythroblasts when formed readily pass into the blood-stream. They are probably forced through the thin walls of the large capillaries by the pressure of the multiplying cells in the

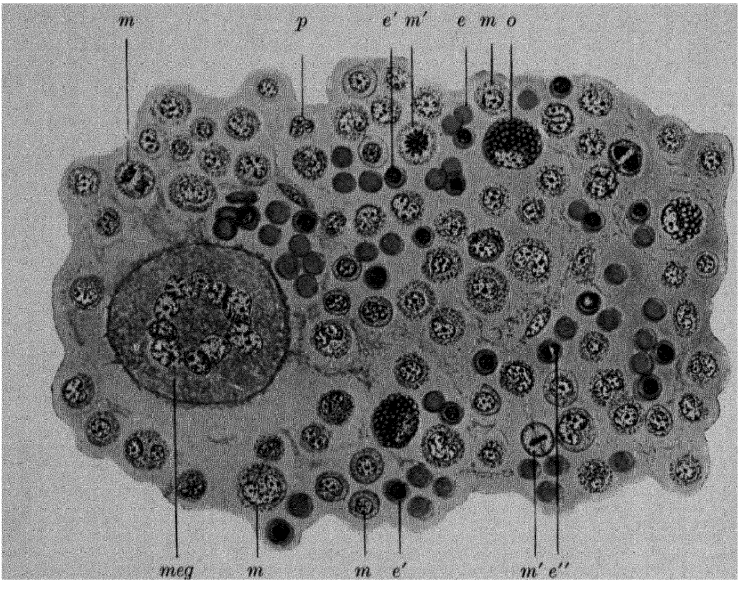

FIG. 58.—FROM A SECTION OF RED MARROW OF YOUNG RABBIT. (E. Sharpey-Schafer.) × 450.

e, erythrocytes; *e'*, erythroblasts; *e''*, an erythroblast undergoing mitotic division; *p*, a polymorph leucocyte; *m*, myelocytes; *m'*, myelocytes undergoing mitotic division; *o*, an oxyphil myelocyte; *b*, a basiphil myelocyte; *meg*, a megakaryocyte.

marrow tissue (Drinker and Lund, 1922). In birds erythroblasts are confined to the large blood-channels of the marrow, and the transformation into erythrocytes occurs within these channels.

The megaloblasts multiply by mitotic division to form normoblasts. The latter show every transition, including the reticular appearance already described (p. 39), to the ordinary red disks, some being seen with the nucleus in what appears to be an atrophied condition. The transformation of an erythroblast into a discoid red blood-cell is undoubtedly accompanied by disappearance of the nucleus, but whether this becomes extruded or simply undergoes absorption is uncertain.

The marrow also contains a number of very large giant-cells, the **myeloplaxes** of Robin (see figs. 57, 58, 59, 60. Myeloplaxes are especially numerous in places where bone is becoming absorbed, but are not confined

to such situations, being normal constituents of adult red marrow in which no such absorption may be taking place. Sometimes they possess several

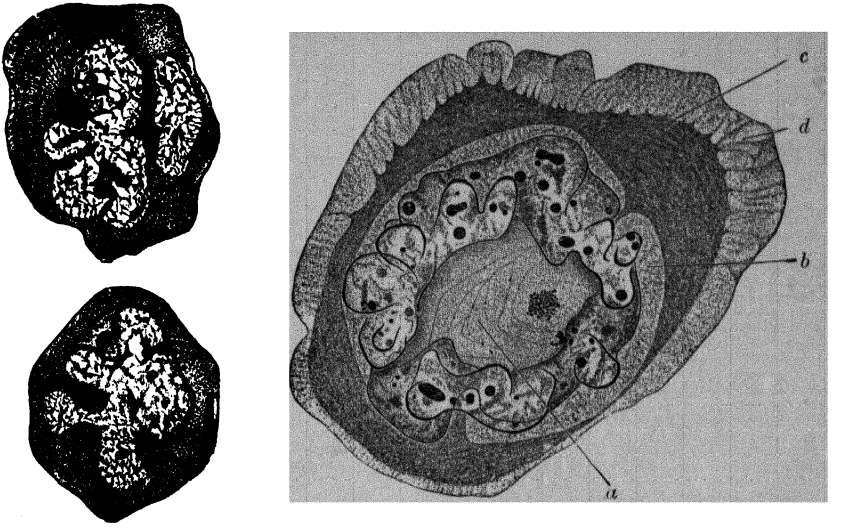

FIG. 59.—CELLS WITH IRREGULAR LOBED NUCLEI AND A GIANT-CELL WITH ANNULAR NUCLEUS FROM BONE-MARROW OF RABBIT. (M. Heidenhain.)

a, *b*, *c*, *d*, zones in the protoplasm.

nuclei: this seems to be the case when they are engaged in absorption of bone: but most—the so-called *megakaryocytes*—contain only one large nucleus, which has frequently an annular form, is lobulated, and contains a number of nucleoli. These cells are also characterised by possessing a number of centrioles grouped together near the centre. Such cells are not only present in bone-marrow but are found in other blood-forming organs, such as the lymph-glands and spleen of young animals.

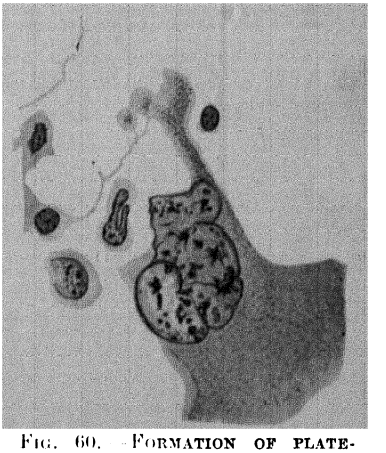

FIG. 60.—FORMATION OF PLATELETS FROM MEGAKARYOCYTE OF MARROW. (J. Homer Wright.)

The figure shows a megakaryocyte with a pseudopodium extending towards a blood-vessel into which platelets are becoming detached from the pseudopodium.

J. Homer Wright (who is confirmed by Ogata and others) described the blood-platelets of mammals as being formed by the megakaryocytes of marrow. He states that they are given off from amœboid processes of these cells which project from the marrow into the blood-channels traversing it (fig. 60). If this is the case the platelets of mammals are not homologous with the spindle-shaped thrombocytes of the frog. According to Wright the latter are rather homologous with the megakaryocytes of mammals and similarly bud off minute platelets (see p. 65 and fig. 71).

DEVELOPMENT OF THE WHITE CELLS (LEUCOCYTES) OF BLOOD.

The white blood-cells make their first appearance in the early embryo as free mesenchyme cells, not contained, like the red cells, within the developing vessels, these being originally occupied only by red cells floating in a clear fluid (plasma). Later, leucocytes find their way into the vessels, probably by virtue of their amœboid properties. Two views are held regarding their origin. One is that all kinds of leucocyte, granular and non-granular, are produced from undifferentiated 'stem-cells' which multiply and produce other cells, the protoplasm of which undergoes differentiation to form eventually the different kinds of leucocyte. This view, which is that of Miss Sabin and her fellow-workers, assumes a cell like the lymphocyte to be the primitive white blood-cell, all other kinds developing from it. Some authors (Maximow, Goodall) have even supposed that colourless primitive cells (*hæmatoblasts*) may give rise not only to leucocytes but also to erythroblasts and through these to erythrocytes. A second view supposes that, whilst some of the specialised leucocytes, such as the macrocytes, may be formed from an indifferent cell like the lymphocyte, all the granular kinds of leucocyte take origin as the result of multiplication of specialised cells in bone-marrow, whence they are discharged into the blood. Lymphocytes themselves are undoubtedly produced in lymph-glands, Malpighian corpuscles of spleen and other similar structures in various parts of the body, and pass into the blood-stream by way of the lymph.

That in the adult the bone-marrow is the chief source of the granular leucocytes seems evident from the fact that there is no other situation except the blood where cells of this description occur in any quantity, and that cases of pathological hypertrophy and hyperfunctioning of the marrow show a great accession into the blood not only of immature red cells but also of leucocytes, which for the most part belong to the granular varieties (including basiphils). Whereas, in hypertrophic conditions of lymphoid organs, the leucocytosis which results chiefly affects the lymphocytes and to some extent the macrocytes.

LESSON IV.

CHANGES IN THE HUMAN BLOOD-CORPUSCLES AS THE RESULT OF THE ACTION OF WATER AND OTHER REAGENTS.

1. MAKE a preparation of human blood, as in Lesson II, § 1, p. 32, and apply a very small drop of water at one edge of the cover-glass. Examine at a place where the two fluids are becoming mixed. Notice particularly the first effect of water upon both red and white corpuscles, as well as the ultimate action (*hæmolysis*).

2. Repeat on another preparation, using very dilute alkali (0·2 per cent. caustic potash) instead of water. Notice the solution of the white and the rapid hæmolysis of the red cells as the alkali reaches them.

3. Repeat on another preparation using bile, or a solution of bile-salts, or a dilute solution of saponin. The last especially is a very effective hæmolytic agent.

4. Repeat on another preparation, using dilute acetic acid (0·5 per cent. in normal saline). Observe that the ultimate effect of the acid upon the coloured corpuscles is similar to that of water, although a first result may be to cause crenation. But it has a different action upon the colourless corpuscles, especially bringing their nuclei into view.

5. Make a preparation of blood mixed with normal salt solution, as in Lesson II, § 2, p. 32, and investigate the action of tannic acid.

6. Study the phenomena exhibited in drops of blood taken from different individuals or different species of animal and mixed on a clean slide (see p. 60) with the object of observing agglutination (human blood) and specific hæmolysis (animals).

ACTION OF REAGENTS ON ERYTHROCYTES.

Hæmolysis.—The human red blood-corpuscle consists as we have already seen (p. 36) of a small drop of coloured liquid bounded externally by a film-like envelope of colourless matter which forms a semi-permeable membrane enclosing the fluid contents of the corpuscle. These consist of an aqueous solution of hæmoglobin, salts, and other substances. When treated with any solution which is hypotonic to the corpuscles water passes by osmosis through the envelope and swells the corpuscles, causing them to become first cup-shaped and then spherical; the spherical corpuscle is at first smaller in diameter than the discoid cell from which it is produced. Eventually the membrane is either burst by the passage of water into the interior, or sufficiently distended to allow the solution of hæmoglobin to escape through its pores, the colourless envelope being left (fig. 61, *a* to *e*). This phenomenon is known as *hæmolysis*. The opposite effect is produced by a hypertonic solution, *e.g.* of salt, which by increasing the density of the fluid in which the corpuscles float, causes diffusion of water out of the corpuscle and consequent shrinking and corrugation of the surface, a crenated form

being produced. The same change is brought about by the evaporation of water from the plasma, if the blood is exposed to air.

Besides the ordinary crenated form produced by hypertonic solutions another kind of crenation is often seen, in which the projections from the surface instead of being bluntly rounded are sharp and pointed (thorn-apple form: fig. 61, *f*).

Hæmolysis can be effected not only by water, but also by dilute acids and alkalies, by the action of heat (60° C.), by repeatedly freezing and thawing blood, by the action of ether or chloroform, and by the passage of electric shocks. An aqueous solution of saponin (1 in 10000 to 1 in 5000) is a most potent agent, and is extensively used in experiments to test the resistance of red cells in hæmolysis. Dilute alkalies and solutions of bile-salts rapidly cause the discoid red cells to become spherical, and then almost instantly effect their complete solution.



FIG. 61. — HÆMOLYSIS OF ERYTHROCYTE BY WATER; AND EFFECTS OF HYPERTONIC SOLUTION OF SALT AND OF TANNIC ACID ON RED CELLS. (E. Sharpey-Schafer.)

a-e, successive effects of water upon a red corpuscle; *f*, effect of hypertonic solution of salt; *g*, effect of tannic acid.

The proteins and lipoids of serum have an inhibitory action on hæmolysis, while certain other substances have the contrary effect (Ponder). Tannic acid produces a peculiar result (fig. 61, *g*); the hæmoglobin is discharged from the corpuscle, but is immediately precipitated in an altered form, remaining adherent to the envelope as a round globule of a brownish tinge.

Most of the hæmolytic effects here described occur, as above mentioned, by a process of osmosis. In others a solution of the envelope of the corpuscle is produced by the reagent. In other cases again the envelope is either distended until it bursts, or is altered and rendered more porous so that the hæmoglobin is caused to escape.

As has already been stated, the envelope is probably protoplasm and contains—besides proteins and nucleoproteins—lipoids, such as cephalin, lecithin, and cholesterol, substances which possess many of the physical properties of fats. If the lipoids are accumulated to form an external film to the corpuscles, as suggested by Overton, the action of lipoid solvents, such as ether and chloroform, in producing hæmolysis is readily understood.

On the same hypothesis the running of the red disks into rouleaux can be explained as a physical process. For it was shown by Norris (1882) that disks of any material, *e.g.* cork disks suitably weighted and suspended in a watery fluid, tend similarly to adhere in rouleaux, provided their surfaces are covered with a layer which is not freely wetted by the fluid in which they are suspended.[1] The fact that no cleft is seen in the envelopes of the red corpuscles even when they appear to have burst may also be explained on the same supposition, for, if there is an external film of a lipoid nature, any rent in it would tend immediately to close up again when the opposed edges come into contact. This also offers an explanation of the fact that blood-corpuscles can be cut through without the fluid contents escaping, and that when subjected to heat they break up into droplets of coloured fluid, each

[1] The circumstances affecting rouleaux formation and incidentally the rate of sedimentation of the red cells have been lately investigated by Ponder (1925, 1926).

surrounded by a lipoid film. Gentle heat increases the tendency to rouleaux formation, perhaps by increasing the stickiness of the surface layer of lipoid material.

Stroma theory.—The envelope of the erythrocyte was termed *stroma* by Rollett (1870), a name which rested upon a false conception of the structure of the corpuscle. In adopting the designation, he supposed the corpuscle to be formed of a homogeneous solid or semi-solid protein material, permeated by hæmoglobin. There is, however, no reasonable foundation for this supposition, which fails to explain the well-known osmotic phenomena of the corpuscle; whereas the supposition that the corpuscle consists of a drop of coloured fluid enclosed by a semi-permeable envelope is in accordance with all the known facts regarding such phenomena. It is true that in the fresh mammalian corpuscle the envelope is too delicate to be readily observed in the optical section of the corpuscle. But it can be stained by dyes (W. Roberts). And in the blood-corpuscles of Amphibia it can not only be distinctly seen, but with any slight increase in density of the plasma becomes wrinkled and creased. In these nucleated corpuscles also the nucleus becomes readily displaced in freshly drawn blood from its position in the centre of the corpuscle and may lie quite at the side (figs. 74, 75). This is a clear indication of the fluid nature of the contents of the corpuscle, and by analogy we may assume a similar condition for the mammalian corpuscle.

Specific hæmolysins.—The mixing of blood from one species of animal with the blood or serum of animals of another species generally has a marked hæmolytic effect. In this case the hæmolytic action is exerted by a constituent (a 'specific hæmolysin') of the foreign blood, which is special for each species and against which the 'host' can render itself immune if, prior to any large quantity of the foreign blood or serum being injected, successive small injections are made at intervals of two or three days; an 'anti-hæmolysin' is then gradually produced. This observation is not only of interest as bearing upon the general doctrine of immunity, but is also of use in assisting the detection of the source of a given sample of blood.

Precipitins.—Similarly if an animal is treated for a few days with several successive injections of water-extracts of the blood or serum of another animal of a different species, the serum of the first animal, if added to the serum of any individual of the same species as that which furnished the material for the injections, will produce a white precipitate. This reaction is due not to the corpuscles but to a specific substance (precipitin) in the plasma, and is a general reaction yielded by proteins. Like the specific hæmolysin reaction it may be employed in the case of blood-stains to determine whether the blood being investigated is human or not.

Agglutinins.—Another phenomenon which frequently occurs when the blood of two different individuals, even of the same race or family, is mixed—or if the plasma or serum of one is added to the blood-corpuscles of another—is a clumping (agglutination) of the red cells. This clumping is caused by a specific constituent (*agglutinin*) of the plasma of the one individual reacting with a specific receptor (*agglutinogen*) of the corpuscles of the other.

Observation has shown that all individuals, without distinction of age or sex, can, as regards blood-agglutination, be included in four groups. Of these groups one contains no agglutinogen in the corpuscles, which are therefore never agglutinated; these form a group designated O. In the three remaining groups there are specific agglutinogens, A and B, in the corpuscles. One of the three groups has only A, another only B, and the remaining one

both A and B. The four groups are accordingly known as O, A, B, and AB.[1] The plasma of group A contains an agglutinin, *b*, reacting with the agglutinogen B; the plasma of B an agglutinin, *a*, reacting with the agglutinogen A; the plasma of O an agglutinin, *ab*, reacting with the agglutinogens A and B. The plasma of AB has no agglutinin, and produces no clumping of the corpuscles of any group.

The mutual reactions of the agglutinins and agglutinogens of the various groups may be shortly stated as follows:

The plasma of O agglutinates the corpuscles of A, B, and AB.
" " " A " " " " B and AB.
" " " B " " " " A and AB.
" " " AB does not agglutinate the corpuscles of any group.

The corpuscles of O are not agglutinated by the plasma of any group.
" " " A " " " " A or AB.
" " " B " " " " B or AB.
" " " AB " " " " AB.

Since the corpuscles of O are not liable to agglutination an individual of this group can always be used as a donor of blood. For although his plasma can cause agglutination in the other groups, the amount transfused is generally insufficient to effect this. Nevertheless it is considered better to employ a donor belonging to the same group as the intended recipient, and for the operation of blood-transfusion both the group to which the patient belongs and that of the proposed donor should be determined.

The determination is simplified by the use of test-serums derived from individuals belonging to groups A and B respectively.[2] The following is the method:

Mix three drops of the patient's blood with 5 c.c. of a 3·8 per cent. solution of sodium citrate: this keeps the blood fluid and forms a suspension of corpuscles. Place a drop of testing serum from A on one microscope slide and a drop from B on another, and close to each of these drops place a small drop of the patient's citrated blood. Mix each pair of drops. Agglutination, if it occur, can be detected by the naked eye and confirmed by a low power of the microscope: the appearance is as if grains of cayenne pepper were floating in the fluid.

The result may be:

(*a*) Both serum of A and serum of B cause agglutination; therefore the patient belongs to group AB.
(*b*) Only serum of A causes agglutination; therefore he belongs to group B.
(*c*) Only serum of B causes agglutination; therefore he belongs to group A.
(*d*) Neither serum causes agglutination; therefore he belongs to group O.

If preserved serums are not available, a few drops of blood are taken from the patient and allowed to coagulate in a small test-tube. When serum exudes from the clot, a drop is mixed with citrated blood of the proposed donor. If agglutination is produced another donor must be found.

If time presses, a drop of blood from a proposed donor and a small drop of the patient's blood may be rapidly mixed with a needle on a slide, and the result as regards agglutination observed.

In all these operations particular care must be taken that the slides and other utensils employed are absolutely clean and free from grease.

Individual and racial variations in the blood-groups.—Several types of blood-groups are distinguished; these follow to a certain extent a racial distribution.

[1] According to the original description of Jansky (1906) these groups were numbered I, II, III, and IV. But as subsequent writers have reversed the numbers it is better to discard numerical designations.

[2] Such serums are sold commercially and will retain their properties for some time.

The average European type is approximately given as O, 45 ; A, 42 ; B, 10 ; AB, 3. Most oriental races show a smaller proportion of A and relatively more of B. This is also the case with negroid races. The Japanese type is peculiar, viz. O, 30·86 ; A, 37·66 ; B, 21·79 ; and AB, 9·68. The pure North American Indian type was found by Snyder to consist almost entirely of O individuals (O, 91·3 ; A, 7·7 ; B, 1 ; and AB, 0). On the other hand the Australian aborigines average O, 57 ; A, 38·5 ; B, 3 ; and AB, 1·5. The blood-group condition is hereditary and follows Mendelian laws. Probably the original condition of mankind was O (Group I of Jansky) and the two dominant mutations A and B (II and III) made their appearance later, A in Europe, B in the Orient.

The blood-group to which any individual belongs is already manifest at birth so far as the agglutinogens of the corpuscles are concerned, and remains the same throughout life. The agglutinins of the plasma do not appear until some months after birth. The agglutinogens A and B are inherited independently and are therefore not carried by the same chromosome. The ascertaining the group to which an individual belongs can therefore be made use of in determining questions of paternity.

Blood-groups have not been found in the lower animals, with the possible exception of the anthropoid apes. They were first noticed in man in 1900 by two independent observers, K. Landsteiner in Germany and S. G. Shattock in England. The investigation of the racial peculiarities is of considerable anthropological interest.

ACTION OF REAGENTS ON LEUCOCYTES.

The structure of leucocytes is brought out by the action of some of the reagents used to show that of erythrocytes. If water is added their amœboid movements soon stop (although with the addition of a very small quantity of water the movements may at first be increased), the cytoplasm becomes swollen out into a globular form by imbibition of fluid—this indicates that it must have a superficial film which can act as an osmotic membrane—and the granules within the protoplasm take on an active Brownian motion. The nucleus becomes clearer, more globular, and more conspicuous. With the further action of water the cytoplasm becomes disintegrated, and the granules are set free.

Under the action of acids, the nuclei of the white corpuscles become shrunken and distinct, and a granular precipitate is formed in the protoplasm around the nucleus. Along with these changes, a part of the protoplasm generally swells out so as to form a clear bleb-like expansion ; an appearance which often accompanies the death of the corpuscle from other causes. Caustic alkalies, even as dilute as 2 parts per 1000, rapidly cause complete destruction and solution of all leucocytes.

LESSON V.

THE BLOOD-CORPUSCLES OF OVIPARA.

1. OBTAIN a drop of frog's, toad's or newt's blood, and mount it either undiluted, or mixed with a very small quantity of frog-Ringer (p. 32, footnote). Examine with the high power. Notice the shape of the coloured corpuscles both when seen flat and edgeways, and the nucleus within each.

Measure with the scale (p. 29) ten corpuscles (long and short diameters), and from the results obtain the average dimensions of a corpuscle.

Notice the colourless corpuscles, smaller than the red, but larger than the pale corpuscles of human blood, although otherwise generally resembling these. Thrombocytes may also be seen; in the frog they are spindle-shaped and contain a nucleus.

Sketch two or three red corpuscles and as many white.

Be careful not to mistake the rounded liberated nuclei of crushed red corpuscles for pale corpuscles.

Very large cells and nuclei belonging to the cutaneous glands as well as the granular secretion of those glands may be present in this preparation if it is obtained from the newt by cutting the tail.

2. Apply a minute drop of water to the edge of the cover-glass of the above preparation and notice its action upon the corpuscles.

Sketch two or three cells altered by the action of water.

3. Mount another drop of blood, and apply dilute acetic acid (1 per cent. in saline) instead of water at the edge of the cover-glass. Make sketches showing the effect of the acid upon both red and white cells.

4. Examine the red cells of newt's blood which has been allowed to flow into boric-acid solution (2 per cent.). Notice the effect upon them. Sketch one or two.

5. Mount drops of glycerine-jelly containing (*a*) frog's or newt's blood, (*b*) bird's blood, (*c*) blood of a fish; all previously fixed by osmic acid (1 per cent) and stained with eosin. These are permanent preparations.

6. Make film preparations of blood of frog and other animals as described on p. 33, § 8, for human blood.

ERYTHROCYTES.

The red cells of Amphibia (figs. 62, 63), as well as of nearly all vertebrates below mammals, are biconvex elliptical disks, considerably larger than the biconcave circular disks of mammals.

The following are the dimensions in microns of the coloured corpuscles of some oviparous vertebrates:

	Long Diameter.	Short Diameter.
Pigeon	14·7	6·5
Frog	22·3	15·7
Newt	29·3	19·5
Proteus	58·0	35·0
Amphiuma	77·0	46·0

The measurements were made from dry films.

They are far less numerous than those of mammals, the number per cubic millimeter in the blood of the common frog (*Rana temporaria*) being only from three to four hundred thousand.

In addition to the coloured body of the corpuscle—which consists, as in mammals, of a solution of hæmoglobin and electrolytes enclosed within an envelope—there is a colourless nucleus, also of elliptical shape, but easily becoming globular, especially if liberated by any means from the corpuscle. The nucleus resembles that of many other cells in structure, being bounded by a membrane, and having a network of chromatin. It is not distinct in the unaltered corpuscle, since it is not coloured by hæmoglobin and therefore looks paler than the rest (figs. 62, 63, 74, 75). It is brought more clearly into view by the action of reagents, especially those of an acid nature. Otherwise the

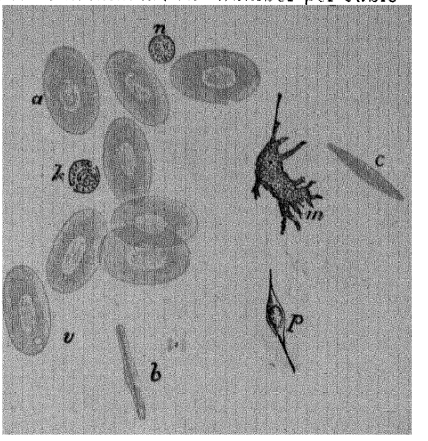

FIG. 62.—BLOOD-CORPUSCLES OF FROG. (Ranvier.)

a, seen on the flat; *b*, in optical section; *c*, in profile; *c'*, a corpuscle with apparent vacuoles (probably parasitic organisms which are common in frog's blood-corpuscles); *m*, an amœboid leucocyte; *n*, nucleus of an erythrocyte, set free and contracted to the spherical form; *k*, a lymphocyte; *p*, a blood-platelet.

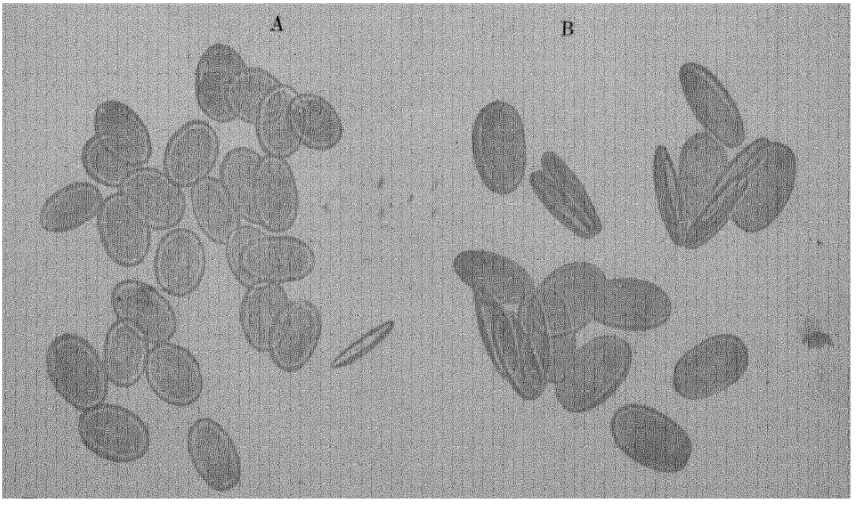

FIG. 63.—AMPHIBIAN ERYTHROCYTES. (E. Sharpey-Schafer.) × 450. Photographs.

A, from the frog. B, from the toad.

action of reagents upon the red corpuscle of ovipara is similar to that upon the mammalian corpuscle, water and hypotonic solutions causing

it to swell into a globular form and then to become decolorised; hypertonic solutions causing wrinkling of the envelope, and so on. As a first effect, water and certain other fluids may cause the hæmoglobin to retire from the envelope at the points where the fluid is passing through the membrane: a stellate appearance is thereby often produced. Boric acid causes the hæmoglobin of the newt's corpuscle to become partially or wholly collected around the nucleus, which may then be extruded along with it from the corpuscle.

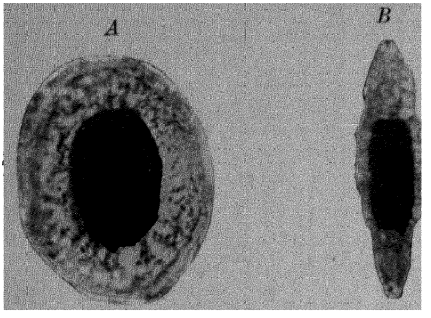

FIG. 64. ERYTHROCYTES OF LEPIDOSIREN LARVA, FIXED WITH FLEMMING'S SOLUTION AND STAINED WITH IRON-HÆMATOXYLIN. (T. H. Bryce.)

A, as seen on the flat; *B*, in section. In *A* the fibrils around the edge are visible as fine lines parallel to the margin of the corpuscle. In *B* their sections are seen as fine points just within the thinnest part of the edge.

Immediately within the envelope, at the periphery of the amphibian erythrocyte, is a band of fine fibrils which are stained by gentian-violet (Meves). As Bryce has shown, they can also be seen cut across in sections of the corpuscles, and may be stained with iron-hæmatoxylin (fig. 64).

A reticular apparatus of Golgi has been described in the erythrocytes of oviparous vertebrates.

LEUCOCYTES.

The colourless corpuscles of ovipara, although larger, are very similar to those of mammals, being either wholly pale and finely granular, or enclosing a number of very distinct granules of like nature to those met with in

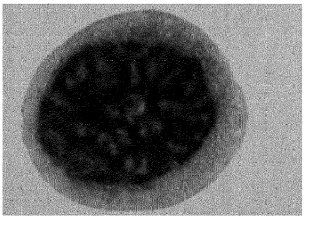

FIG. 65. LYMPHOCYTE OF TRITON, SHOWING THE RETICULAR STRUCTURE OF ITS NUCLEUS. (E. Sharpey-Schafer.) × 2000. Untouched photograph.

The cell was fixed by steam, and afterwards stained with hæmatoxylin.

Mammalia. And the same varieties of leucocyte can be distinguished, viz. polymorphs (fig. 66, *B*; fig. 67), lymphocytes (fig. 65), oxyphils, macrocytes (fig. 66, *A*), and basiphils. As might be expected, reagents have effects upon the amphibian leucocyte similar to those produced on the mammalian cell.

On the average there are in the frog about 7000 white cells in a cubic millimeter of blood, *i.e.* about the same number as in man, although the number of red cells is far less.

The presence of glycogen may be demonstrated in some leucocytes by its reaction with iodine solution (port-wine colour).

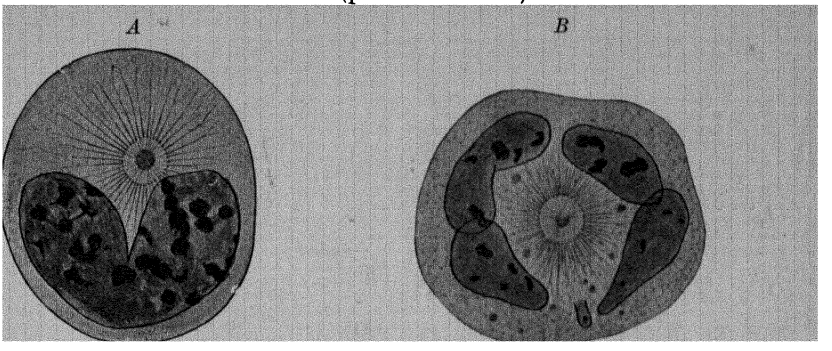

FIG. 66.—TWO LEUCOCYTES OF LEPIDOSIREN, SHOWING CENTRIOLE, CENTROSOME AND ASTRAL RAYS IN CYTOPLASM. (T. H. Bryce.)

A, macrocyte, with kidney-shaped nucleus.
B, polymorph, with lobed nucleus (the threads of chromatin joining the lobes are not shown).

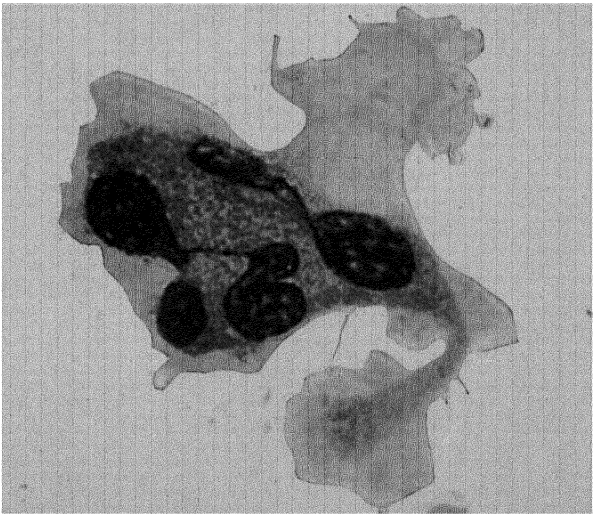

FIG. 67.—POLYMORPH LEUCOCYTE OF TRITON FIXED BY STEAM IN AMŒBOID CONDITION AND STAINED WITH HÆMATOXYLIN. (E. Sharpey-Schafer.) × 1360. Untouched photograph.

Notice the homogeneous appearance of the ectoplasm as compared with that of the endoplasm. The nucleus is multilobed, the lobes being joined by threads of chromatin. A reticular structure is apparent in it.

THROMBOCYTES.

The blood-platelets (**thrombocytes, thigmocytes**) are much fewer in number than in mammals. They are of a spindle shape (fig. 62, *p* ; fig. 68), often with one pole of the spindle drawn out more than the other. They contain a nucleus-like body which shows a tendency to be divided into lobes. The

cytoplasm may be clear or may contain particles staining with safranin. Like the blood-platelets of mammals, those of the frog show rapid changes as soon as the blood is drawn. These changes have been described by Meves and by Tait. The elongated corpuscle first contracts and becomes



FIG. 68.—THROMBOCYTE OF SALAMANDER, AND THE CHANGES WHICH IT UNDERWENT IMMEDIATELY AFTER WITHDRAWAL OF THE BLOOD FROM THE VESSELS. (F. Meves.)

more globular, its nucleus changing similarly in shape. Irregular processes then commence to protrude from the corpuscle (fig. 68), and very soon fine threads are shot out radially in all directions. These become attached to those of other platelets, or to any object which may be in the vicinity of the platelet (fig. 69). The filaments, which appear to be of a fibrinous nature, and may possibly be threads of fibrin, then begin to retract and drag upon



FIG. 69.—THROMBOCYTE OF SALAMANDER, WITH IRREGULAR PROJECTIONS AND FIBRINOUS FILAMENTS RADIATING FROM IT AND ATTACHED TO ADJACENT BLOOD-CORPUSCLES. (F. Meves.)

Two erythrocytes, a free nucleus, and a polymorph leucocyte are included in the figure.

the objects which are entangled by them. In this manner groups of erythrocytes may be drawn together towards common centres, producing a radiate or rosetted arrangement (fig. 70). These changes do not occur if the blood is kept on solid paraffin or any surface which it does not wet (Tait and Green).

It is suggested by Tait that the tendency of the blood-platelets to attach themselves to a foreign or injured surface (thigmotaxis), as well as their

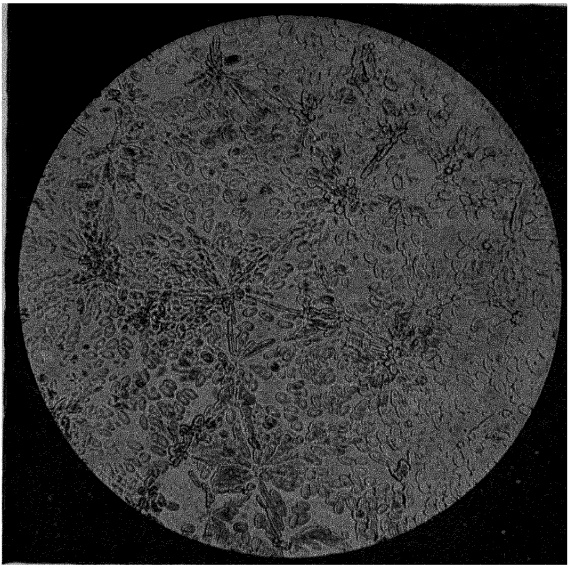

FIG. 70.—MICROSCOPIC PREPARATION OF FROG'S BLOOD SHOWING THE MANNER IN WHICH THE ERYTHROCYTES BECOME ARRANGED IN ROSETTED LINES OWING TO THEIR FIXATION BY THE CONTRACTING THREADS FROM THE THROMBOCYTES WHICH ARE AGGLUTINATED AT CERTAIN POINTS. (J. Tait.) × 90.

entanglement and agglutination, may serve to plug small apertures in blood-vessels caused by injury, and thus at once aid in arresting hæmorrhage. In many invertebrates plugging of a wound is effected in the same way by a special kind of amœboid cell (W. B. Hardy, Tait and Pringle).



FIG. 71.—AMPHIBIAN THROMBOCYTE WITH PLATELETS BUDDED OFF FROM IT. (J. Homer Wright.)

The thigmotaxis which is characteristic of these structures is further illustrated by the fact that fine suspended particles (Indian ink) introduced into the dorsal lymph-sac of the frog are found in considerable number in the cytoplasm of the platelets, as well as in the white corpuscles. Coarser particles (*e.g.* of quartz) cause lysis of the thrombocytes, which adhere to them (Tait and Elridge).

Notkin found the average number of platelets in frog's blood to be 15,000 in a cubic millimeter.

As already stated, J. Homer Wright regards the spindle-shaped thrombocytes of amphibian blood as representing the megakaryocytes of the marrow of mammals, and delineates minute platelets like those of mammalian blood as being budded off from them (fig. 71).

LESSON VI.

THE AMŒBOID PHENOMENA OF LEUCOCYTES.

1. MAKE a preparation of blood from the finger in the usual way. To prevent evaporation of water draw a brush just moistened with pure paraffin oil around the edge of the cover-glass. Avoid any excess of oil. Place the preparation upon a 'warm stage,' and heat this to about the temperature of the body (38° C.). Bring a leucocyte under observation with the high power, and watch the changes of



FIG. 72.—SIMPLE WARMING APPARATUS, COMPLETE, SHOWN IN OPERATION.

shape which it undergoes. To become convinced of these alterations in form, make a series of outline sketches of the same corpuscle at intervals of a minute.

The simplest form of warm stage is a copper plate of about the size of an ordinary slide, perforated in the centre and with a long tongue of the same metal projecting from the middle of one edge (fig. 72). The copper plate rests upon the stage of the microscope, with asbestos or other non-conducting material between. The preparation is made upon an ordinary slide or on a long cover-glass, which is placed upon the warm stage and fixed by the stage clips of the microscope. Heat is applied to the copper tongue by a small

spirit-lamp flame; a greater or less amount is conducted to the warm stage and the superjacent preparation according to the point to which the flame is applied. To ascertain that the right temperature is got and maintained, put two pieces of solid paraffin, one melting at 35° C. (95° F.) and another at 38° C. (100° F.), one on each side of the preparation. The temperature must be such that the first piece is melted and remains so whilst the second remains unmelted.[1]

2. Mount a drop of frog's or newt's blood diluted with an equal amount of frog-Ringer, and examine it in the same manner upon the copper stage, at first cold, afterwards warm; the temperature must, however, be kept below 30° C. Observe the effect of warmth in accelerating the amœboid movements of the pale corpuscles. Sketch one at intervals of a minute (*a*) in the cold, (*b*) whilst warmed.

3. Take a small quantity of yeast shaken up in frog-saline. Mix a very small drop of the yeast and salt solution with a drop of newt's blood, lightly oiling the edges of the cover-glass as before. Endeavour to observe the taking-in of the yeast-torulæ by leucocytes. Sketch one or two corpuscles which have ingested torulæ.

Particles of carbon (Indian ink) or of vermilion may be used instead of yeast for this experiment.

4. To obtain a specimen with leucocytes fixed in amœboid condition, a preparation of newt's blood mixed with frog-Ringer is made, and set aside for ten minutes. By this time the corpuscles will be freely amœboid, and many show well-marked pseudopodia. To fix them in this condition let a jet of steam from a tube attached to a flask of boiling water play for a second upon the cover-glass. The heat instantly kills the corpuscles, and they are fixed in the form they presented at the moment the steam was applied. They may now be stained by passing dilute hæmatoxylin [2] under the cover-glass, the stain being followed by dilute glycerine. When this has diffused through the preparation (it must not be drawn under by filter-paper), the cover may be cemented and the preparation kept.

The **amœboid phenomena** which are exhibited by the protoplasm of the colourless blood-corpuscles were first described in the blood of fish by Wharton Jones (1846). They consist mainly of spontaneous changes of form, produced by the throwing out of processes (*pseudopodia*) in various directions (figs. 73, 74, 75). When first thrown out the pseudopodia are quite clear; the granules of the cytoplasm may subsequently flow into them. If the corpuscle is stimulated, either mechanically, as by tapping the cover-glass, or electrically, all pseudopodia are retracted, the corpuscles becoming spherical. A change of form caused by the protrusion of the pseudopodia may, when active, be followed by changes in place, or actual locomotion (migration), of the corpuscle. When a pseudopodium, or the external surface of the protoplasm, comes in contact with any foreign body, the protoplasm tends to flow round and enwrap it (fig. 75); if it is small, it is drawn into the corpuscle; particles thus ingested may be conveyed by the corpuscle in its movements from one place to another.

This property (**phagocytosis**) plays an important part in many physiological and pathological processes. Thus certain large cells in the spleen pulp—the so-called *splenic cells*—take in blood-corpuscles, which become broken down within them. And pathogenic micro-organisms become taken into the protoplasm of some leucocytes,

[1] For exact work, a more complex apparatus is used, heated either by an electric current or by a stream of warm water at a constant temperature.

[2] The water used for the dilution of hæmatoxylin solutions must always be distilled.

there to be destroyed (Metchnikoff). The phagocytic properties of leucocytes become especially developed as the result of the action upon the bacteria of certain substances which are present to a variable extent in blood and are termed *opsonins* (Almoth Wright).

It is possible that particles of organic matter which are taken up by leucocytes may undergo a slow process of intracellular digestion within the protoplasm, but it is difficult to obtain definite proof of this.

The migration of colourless corpuscles from the blood-vessels into the surrounding tissues (which especially occurs in inflamed parts) is probably related to their amœboid activity.

Conditions which are favourable to amœboid activity of leucocytes are (1) the natural medium in which they live, such as plasma, serum, or lymph

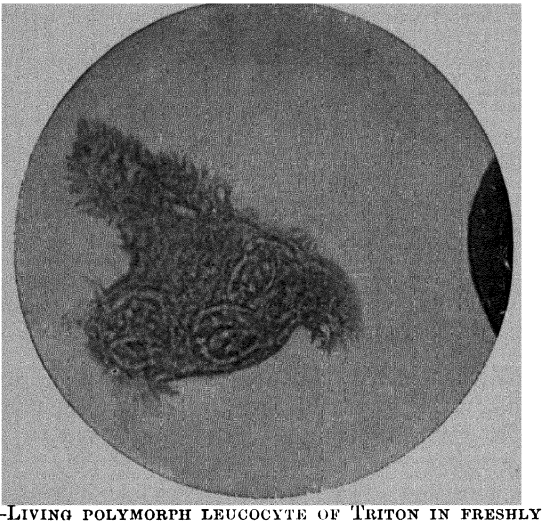

FIG. 73.—LIVING POLYMORPH LEUCOCYTE OF TRITON IN FRESHLY DRAWN BLOOD. (E. Sharpey-Schafer.) × 1360. Untouched photograph.

The photograph was taken in monochromatic light with Zeiss 2 mm. apochromatic objective and a compensation eye-piece.

(or a solution containing electrolytes in similar proportion, such as Ringer's fluid); (2) a certain temperature. In warm-blooded animals the phenomena cease below about 10° C: when gradually warmed, the movements become more and more active up to a point, the maximum being two or three degrees above the natural temperature of the blood: above this point they become spheroidal, and at a somewhat higher temperature their protoplasm is coagulated and killed; (3) a pH slightly above 7. On the other hand, a pH below 7 is detrimental to the movements, and the addition of even a minute amount of acid to the serum or Ringer in which leucocytes are being observed at once kills the corpuscles and stops their movements. Narcotic gases and vapours, such as carbonic acid gas or ether or chloroform vapour, also arrest the movements, but they recommence after a time if the action of the reagent is not too prolonged. Any increase in the density of the

medium produces a diminution of amœboid activity, whilst, on the other hand, a slight decrease in its density has the opposite effect.

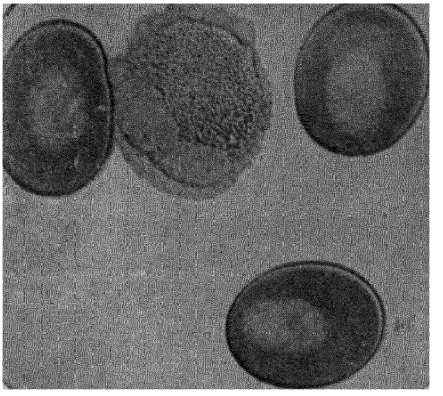

FIG. 74.—LIVING OXYPHIL LEUCOCYTE OF SALAMANDER BEGINNING TO ADHERE TO AN ERYTHROCYTE. (E. Sharpey-Schafer.) Fresh preparation without addition of fluid. × 600. Untouched photograph.

Two other erythrocytes are included in the field. Notice that the nuclei in these have undergone a change of position within the corpuscle, showing that its contents must be completely fluid.

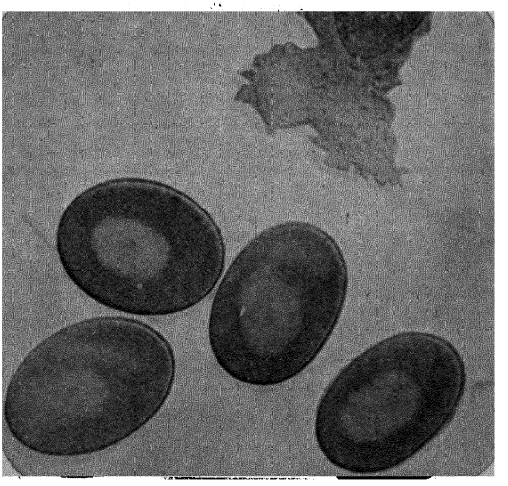

FIG. 75.—HIGHLY AMŒBOID PHAGOCYTIC LEUCOCYTE OF SALAMANDER, ENVELOPING AN ERYTHROCYTE (a portion only of this is included in the field). (E. Sharpey-Schafer.) × 600. Untouched photograph.

Four other erythrocytes are seen; all have their nuclei somewhat displaced.

If blood-plasma is preserved in sealed aseptic tubes, the white corpuscles may retain their amœboid activity for as long a period as four and a half months (J. Jolly). Sherrington had previously found that it is retained for three weeks

in plasma kept fluid by the addition of a minute amount of oxalate of potassium. There appears in fact no limit to the time cells may be kept alive *in vitro* so long as they are placed in an appropriate sterile nutrient medium and supplied with air or oxygen. This method is now in general use, under the designation 'tissue-culture,' for the study of the life processes of cells. For prolonged observation of growing tissues it is found necessary not only to keep the medium strictly aseptic but to renew it frequently—both with the object of supplying fresh nutriment and for the sake of removing waste products of metabolism.

Alexis Carrel, examining the movements of leucocytes by the kinematograph, found that while most throw out pseudopodia resembling those of Amœba, the large macrocytes show an undulating motion of the clear outer layer (ectoplasm). He was also able to observe a similar movement in large phagocytes (clasmatocytes) occurring in connective tissue.

LESSON VII.

STRATIFIED, PAVEMENT AND GLANDULAR EPITHELIUM AND SECRETING GLANDS.

1. MOUNT a drop of saliva and examine first with a low, afterwards with a high power. Observe the nucleated, scaly epithelium-cells, some single, others adhering together by overlapping edges. Measure three or four; also their nuclei. Sketch one or two on the flat and edgeways. Notice the salivary corpuscles, which are migrated white blood-corpuscles swollen by imbibition of the water of the saliva. Numerous bacteria are also always to be seen. A stained preparation may be made by allowing saliva to dry on a slide, and staining the film with 1 per cent. methylene-blue or gentian-violet (three minutes). It is then washed with water, dried, and mounted in dammar.

2. Put a small shred of human epidermis into a drop of strong caustic potash solution (35 per cent.) for five minutes. Then break it up in water with needles, cover, and examine. Observe the now isolated swollen scales (cells).

3. Study the arrangement of the cells in a section through a stratified epithelium, such as that of the mouth, skin, or cornea. Notice the changes in shape of the cells as they are traced towards the free surface. Measure the thickness of the epithelium. Count the number of layers of cells. Look for mitoses in the deeper layers.

4. Make a preparation of the epithelium of the urinary bladder. The bladder is slightly distended with bichromate of potassium (1 part bichromate to 800 of normal saline); after an hour it is cut open and placed in more of the same solution for a few days; it is then transferred to water. Take a small scraping of the lining epithelium on the point of a scalpel, and break it up by tapping it in a drop of distilled water coloured with Delafield hæmatoxylin. Put a small hair in the drop and cover. Add a small drop of dilute glycerine at one edge; allow this to diffuse under. Cement next day. Observe the large flat superficial cells, the smaller pear-shaped cells of the second layer, and the polyhedral cells of the deeper layers. Sketch each kind. The cells will vary greatly in appearance according to the amount of distension of the organ by the fixative.

5. The minute structure of epithelium-cells and their nuclei, both at rest and dividing, is studied in sections of the skin of the newt's tail, in shreds of peritoneum of salamander-tadpole, or amnion of rat, or in sections of the salamander- or frog-tadpole. If tadpoles are fed with thyroid gland for two or three weeks, the mitoses are very numerous. The preparations may be stained either with hæmatoxylin or iron-hæmatoxylin, or with saffranin (see Appendix).

Sketch a cell with resting nucleus, and others with nuclei in different phases of karyokinesis.

6. The simple saccular skin-glands of Amphibia may be studied in sections of the newt's skin.

An epithelium has the following characters:

The cells are generally arranged as an expansion covering a free surface, but may be disposed to form solid masses, as in the liver. They lie close

together, the cement-substance between the cells being small in amount. The cells, or, if in more than one layer, those of the lowermost stratum, rest on a layer of homogeneous substance. This is the *basement membrane*, which intervenes between the epithelium and the underlying connective tissue of which it forms the superficial stratum.

The structure of epithelium-cells, and the changes which they undergo in division, are well seen in the epidermis of the newt or of the salamander-tadpole (fig. 76); the cells and nuclei being much larger in these animals than in mammals.

An epithelium-cell consists, like other cells, of *cytoplasm* and *nucleus*. The cytoplasm either may look granular, or may have a reticulated appearance, or may exhibit fibrils. The nucleus is spherical or ovoid. Usually there is

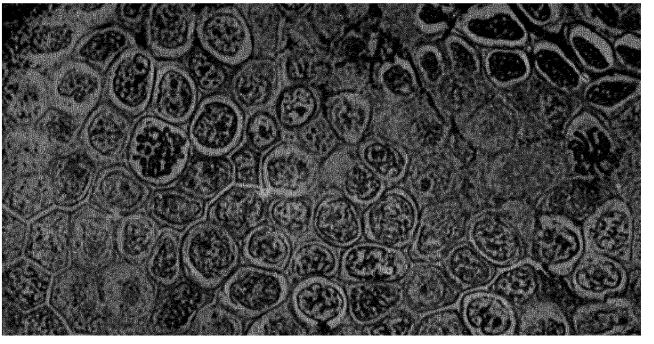

FIG. 76.—EPIDERMIS-CELLS OF A LARVAL SALAMANDER. (E. Sharpey-Schafer.) × 400. Photograph.

Some of the cells are undergoing division. Intercellular channels are seen in parts. At one place the branches of a pigment-cell extend between the epithelium-cells.

only one, but there may be two. The cell-substance is often modified in its chemical nature; its external layer may become hardened to form a sort of membrane, or the whole cell may become horny (keratinised); or there may be a special material in the form of well-marked granules or globules within the cell—material which is ultimately discharged and used by the organism, as occurs in secreting glands.

VARIETIES OF EPITHELIUM.

Epithelia are somewhat illogically classified, partly according to the shape and arrangement of the cells, partly according to their function. Thus we speak of *scaly* or *pavement*, *cubical*, *columnar*, *glandular*, and *ciliated* epithelium. Most of these are *simple* epithelia, with the cells only one layer deep. If forming several superposed layers, the epithelium is said to be *stratified*, and then the shape of the cells differs in the different layers. Where there are only three or four layers in a stratified epithelium, it is termed

transitional. Every epithelium receives nerves, but, with the exception of the endocrine glands, blood-vessels hardly ever penetrate between the cells.

A physiological classification according to the function of the epithelium may also be used. We should then include under the term *protective epithelia*, the pavement, stratified and transitional varieties; under the term *secreting epithelia*, the cubical, columnar [1] and glandular epithelia (some of the pavement epithelia would come also under this head); while *ciliated epithelium* would form a separate division, as in the classification usually adopted.

PROTECTIVE EPITHELIA.

Stratified epithelium (fig. 77) covers the anterior surface of the cornea, lines the mouth, pharynx (lower part), gullet, anal canal and part of the

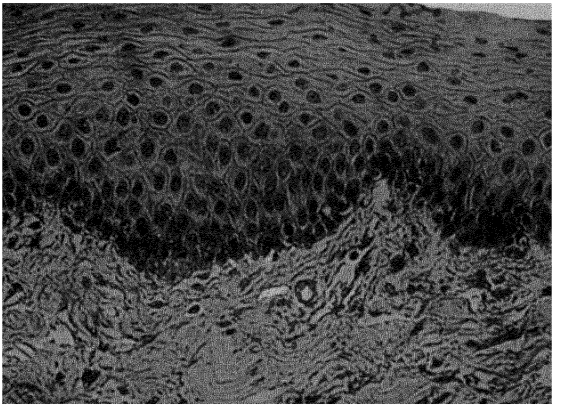

FIG. 77.—SECTION OF STRATIFIED EPITHELIUM FROM FAUCES OF RABBIT. Magnified 240 diameters. Photograph.

urethra, and forms the epidermis which covers the skin. The vocal cords are covered by stratified epithelium. In the female it lines the vagina and covers the os uteri. The cells nearest the surface are always flattened and scale-like, whereas the deeper cells are polyhedral, and those of the deepest layer are somewhat columnar in shape. Moreover, the deep cells are soft and protoplasmic, and are separated from one another by a system of intercellular channels, which are bridged across by numerous fibrils passing from cell to cell (figs. 78, 79), giving the cells, when separated, the appearance of being beset with short spines (*prickle-cells*). The fibrils are traceable through the cell-substance and from cell to cell, so that the cells are held firmly together and there is difficulty in isolating them. According to Shapiro some fibrils are confined to each cell and have a concentric arrangement. The fibrils are enlarged as they cross the intercellular spaces.

[1] The columnar epithelium of the intestine is concerned as much with absorption as with secretion, but absorption may be regarded as a kind of reversed secretion.



FIG. 78.—SECTION OF EPIDERMIS OF CAT'S FOOT, SHOWING INTERCELLULAR CHANNELS, WITH BRIDGING FIBRILS. (Kolossow.)

Bridging fibrils have also been described in the pavement epithelium of Descemet's membrane at the back of the cornea.

The deeper cells multiply by karyokinesis. The newly formed cells tend as they enlarge to push those superficial to them nearer to the surface, from which they are eventually thrown off. As they approach the surface they become keratinised, and in the case of the epidermis lose their nuclei and the appearance of distinct cells; this can, however, be in a measure restored by the action of alkalies (§ 2). The cast-off superficial cells of the stratified epithelium of the mouth, which are seen in abundance in the saliva (§ 1), are less altered than those of the epidermis, and the remains of a nucleus are still visible in them (fig. 80). The stratified epithelium of the human skin (epidermis) shows many peculiarities; these will be considered when the skin is treated of.

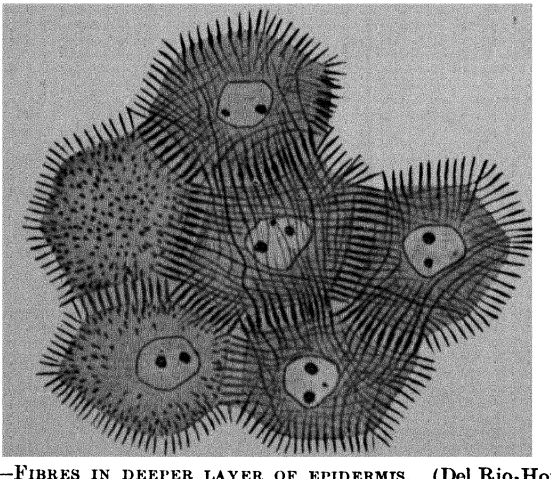

FIG. 79.—FIBRES IN DEEPER LAYER OF EPIDERMIS. (Del Rio-Hortega.) Highly magnified.

The name **transitional epithelium** is given to a stratified epithelium consisting of only three or four layers of cells. It occurs in the upper part of

the urethra, in the urinary bladder, the ureter, and the pelvis of the kidney. The superficial cells (fig. 81, *a*) are large and flattened; they often have two nuclei. Their free surface is covered with a cuticular stratum, and on

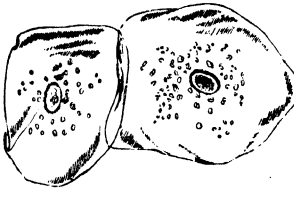

FIG. 80. — EPITHELIUM - SCALES FROM THE INSIDE OF THE MOUTH. (Henle.) Magnified 260 diameters.

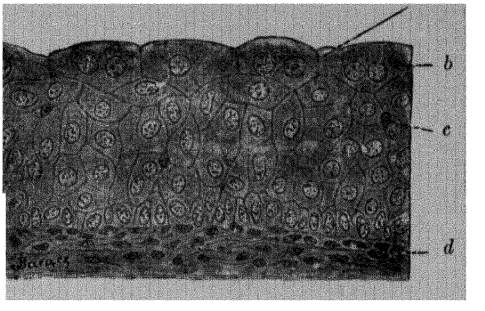

FIG. 81.—SECTION OF MUCOUS MEMBRANE OF URINARY BLADDER: MAN. (Szymonowicz.)

a, *b*, superficial indented epithelium-cells, many with two nuclei; *c*, leucocytes; *d*, corium of mucous membrane.

their under surface they exhibit indentations, into which fit the rounded ends of pyriform or columnar cells, which form the next layer (fig. 82). Next to this come one or two layers of smaller polyhedral cells. The

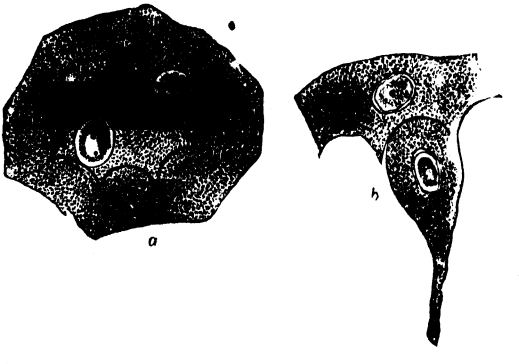

FIG. 82.—EPITHELIAL CELLS FROM THE BLADDER OF THE RABBIT. (Klein.) × 500.

a, large flattened cell from the superficial layer, with two nuclei and with strongly marked ridges and intervening depressions on its under surface; *b*, pear-shaped cell of the second layer adapted to a depression on one of the superficial cells.

epithelium is renewed by mitotic division of the deeper cells. It is possible that the superficial cells also multiply; if so, the division of their nuclei is amitotic.

The capacity of the bladder varies enormously with the amount of urine accumulated within it and the shape of the epithelium-cells is influenced by the resulting distension. When it is fully distended all the cells appear greatly flattened; when it is empty, all except the surface cells become elongated.

In some animals, such as the cat, the superficial cells are very large, with

numerous indented facets into which the cells of the second layer fit; in others, as in man, they are much less extensive and have only one or two facets.

Simple scaly or **pavement epithelium** is found in the alveoli of the lungs, in the ducts of the mammary glands, in the kidney (in the tubes of Henle,

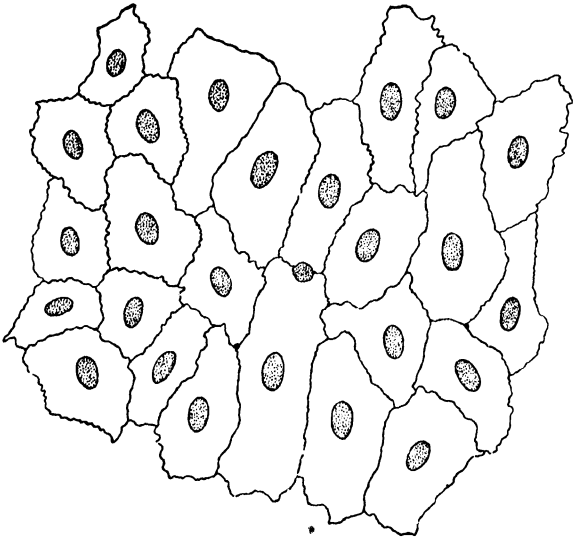

FIG. 83.—PAVEMENT EPITHELIUM (ENDOTHELIUM) OF A SEROUS MEMBRANE. NITRATE OF SILVER PREPARATION. (E. Sharpey-Schafer.)
The nuclei have been stained with carmine.

also lining the capsules of the Malpighian body, and covering the glomeruli), lining the cavities of serous membranes (fig. 83), the interior of the heart, blood-vessels, and lymphatics, and covering the membrane of Descemet at the back of the cornea of the eye. When occurring on internal surfaces, such as those of the serous membranes, blood-vessels, and lymphatics, it is spoken



FIG. 84.—ENDOTHELIUM-CELLS OF SEROUS MEMBRANE IN PROFILE VIEW, SHOWING PROTOPLASMIC BRIDGES STRETCHING ACROSS THE INTERCELLULAR SPACES. (M. Heidenhain.)

of as **endothelium** (ondo-epithelium). The cells of a serous epithelium have a striated border consisting of what looks like a fine pile of closely set hairlets on their free surface, somewhat like that which is found on columnar cells and resting on a thin homogeneous layer. The homogeneous layer also occurs in the endothelium of the blood-vessels, but the pile of hairlets is only found in the endothelia of serous membranes, at least in mammals (Kolossow). The cells are connected with one another by intercellular bridges (fig. 84).

In female Amphibia cilia are developed on parts of the peritoneal epithelium (Klein).

GLANDULAR EPITHELIUM.

Glandular or secreting epithelium is the essential tissue of all the organs which are known as *glands*, of which there are two chief kinds, known respectively as *externally* and *internally secreting glands*.

I. **Externally secreting** or **exocrine glands.**—These are furnished with a duct which ramifies in all parts of the gland and by its means the products of the secretory activity of the gland-cells are brought to a free surface. Such glands have been developed as involutions of the surface upon which they open; their epithelium is continuous with that of this surface, and in some cases, especially where the surface upon which the gland opens is covered with columnar epithelium, is of a similar character to that epithelium. In other cases it is different in character from the epithelium of the surface, becoming altered as we trace the duct back into the recesses or *alveoli* of the gland, and it is in these that the characteristic glandular cells, which are generally polyhedral in shape, are found. Every such involution or ingrowth of epithelium to form a gland is, when first formed, of a simple character, shaped either like a flask or test-tube and filled with a solid mass of cells, but it presently becomes hollowed out, some of the cells being left as a lining to the (connective-tissue) basement membrane which bounds the involution. The gland may remain simple and unbranched (*simple saccular* and *simple tubular glands*, fig. 85, I. and II.), or it may branch again and again until a complicated structure, in some cases small, in others of considerable size, is produced (*compound tubular* and *compound saccular* (*racemose*) *glands*) (fig. 85, III., IV., V.); instances of these are furnished by the kidneys and salivary glands respectively. The cells which furnish the secretion of the gland and which line the secreting parts of the tubules of a tubular gland, or the enlargements (alveoli, acini) at the ends of the ducts of a racemose gland, are often partly or wholly filled with granules or globules (fig. 86). These accumulate in the cell in the intervals of secretory activity, but become discharged or dissolved and pass into the secretion during activity. Secreting glands are always abundantly supplied with blood-vessels and nerves. The blood-vessels are brought to the alveoli in the connective tissue which holds together the alveoli and groups of alveoli (lobules) of the gland; the nerves are supplied partly to the blood-vessels and ducts and partly to the secreting epithelium-cells.

The liver differs from other externally secreting glands in being composed of solid masses of cells instead of tubular or saccular alveoli lined by epithelium. It exhibits also other important differences in the nature of its blood supply and the relation between the blood and the liver-cells.

II. **Internally secreting** or **endocrine glands.**—These are not furnished with ducts and were formerly classed with the spleen and lymphoid structures as *ductless glands*. But the true endocrine glands are, like the externally secreting organs, composed of epithelial cells, sometimes grouped in solid

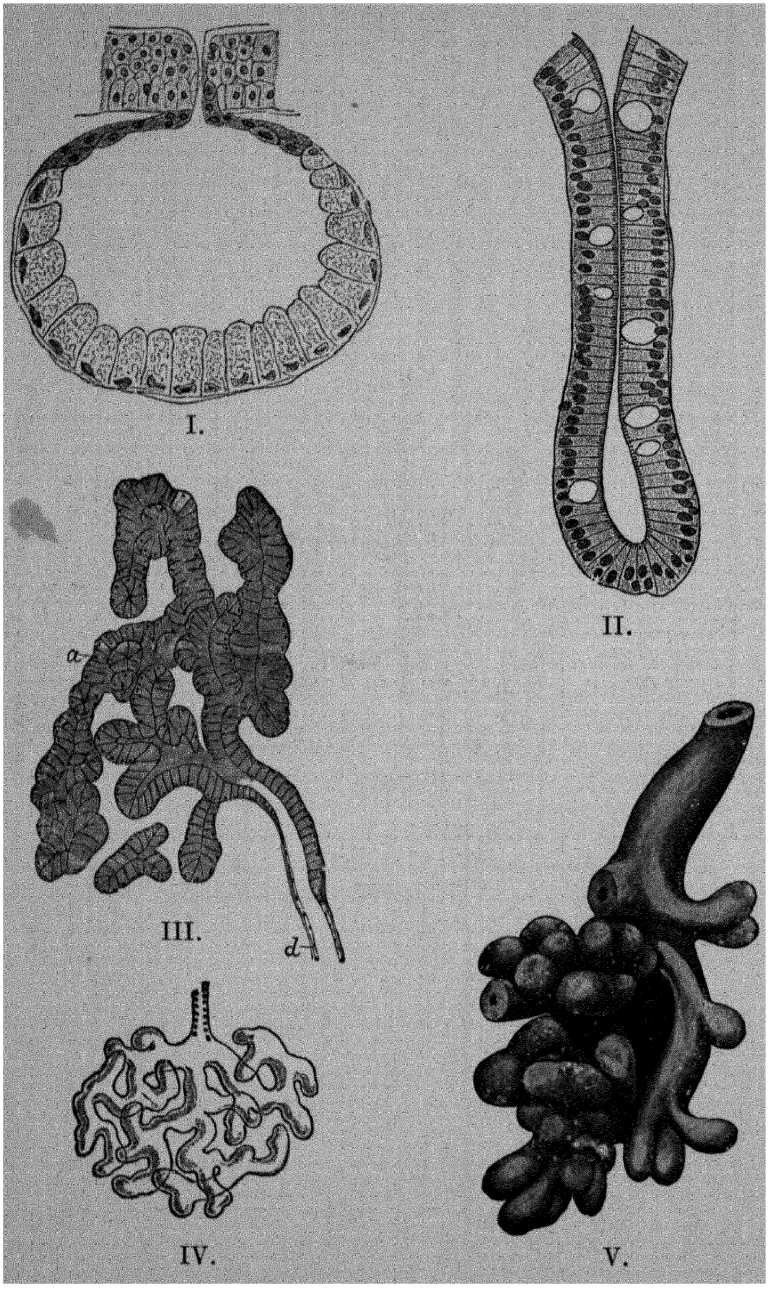

FIG. 85.—VARIOUS KINDS OF GLANDS.

I. Simple saccular gland from amphibian skin (Flemming). II. Simple tubular gland from intestine (Flemming). III. A small racemose gland with a simple duct, *d*, into which a number of irregularly tubular acini, *a*, open (Klein). IV. Part of a tubulo-racemose gland with the acini unravelled (Flemming). V. Wax model of a small tubulo-racemose gland from the epiglottis (Maziarski).

masses (as in the suprarenal), in other cases disposed around hollow vesicles (thyroid) which become filled with the material of the secretion. Since there is no duct in these glands the secretion is carried into the blood either directly by the blood-vessels of the gland or indirectly through the lymphatics.

In the great majority of glands, whether exocrine or endocrine, the secretion appears within the cells as granules or fluid globules, which are

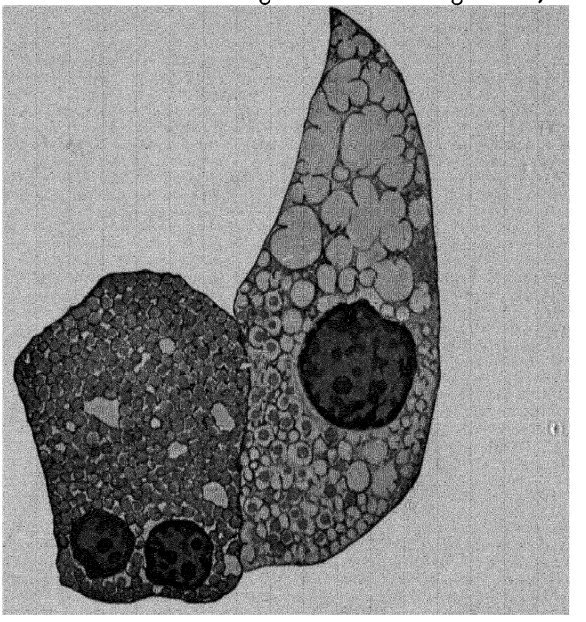

FIG. 86.—TWO CELLS FROM A CUTANEOUS GLAND OF SALAMANDER-LARVA, SHOWING SECRETION GLOBULES OR GRANULES. (Gurwitsch.)

The left-hand cell, which has two nuclei, is filled with granules. In the right-hand cell they are becoming swollen and dissolved.

extruded during secretory activity. But in some externally secreting glands (*e.g.* the sebaceous and mammary glands) the cells themselves undergo a varying amount of disintegration during secretion, sometimes the whole cell (sebaceous glands), sometimes only the free part (mammary glands), becoming disintegrated and dissolved or suspended in the secreted fluid.

The detailed study of glandular epithelium and of other epithelial structures may be reserved until the organs in which they occur are described, but columnar and ciliated epithelia will be dealt with in the next lesson.

The *hairs* and *nails* and the *enamel* of the teeth are modified epithelial tissues. They will be described with the skin and mouth respectively.

LESSON VIII.

COLUMNAR AND CILIATED EPITHELIUM: ACTION OF CILIA.

1. BREAK up in dilute glycerine a shred of epithelium from a minute piece of the mucous membrane of intestine (frog) that has been treated with 1 per cent. osmic acid for some hours, and has subsequently macerated in thymol water for a few days. The cells easily separate on tapping the cover-glass. The cover-glass may be at once fixed by gold size. Measure and sketch one or two cells.

Another method is to place a small piece of mucous membrane of intestine of frog or mammal in bichromate of potassium solution—1 to 800 of Ringer—for a

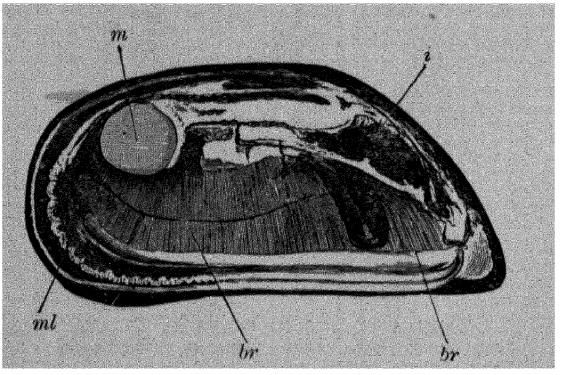

FIG. 87.—MUSSEL (MYTILUS EDULIS) FROM WHICH ONE SHELL-VALVE (THE RIGHT) AND THE CORRESPONDING MANTLE-LOBE HAVE BEEN REMOVED. (E. Sharpey-Schafer.)

br, *br*, the expanded gills or branchiæ, which, owing to the little bars of which they are composed, present a striated aspect; *ml*, mantle; *m*, cut adductor muscle; *i*, mass of viscera; the dark projection just below is the foot.

few days. Wash in distilled water. Break up a very small shred of the epithelium with needles in a drop of distilled water coloured with Delafield hæmatoxylin; cover, first placing a fine short hair in the drop to prevent crushing of the cells; then separate the cells by gently tapping on the cover-glass. Mount in glycerine as with the bladder epithelium (p. 73, § 4).

2. To make a permanent preparation of ciliated epithelium either from the œsophagus of the frog or from the trachea of a mammal the tissue may be treated with osmic acid like the last preparation, or it may be macerated in bichromate solution (1 to 800 Ringer) for a few days and stained and mounted as just described for columnar epithelium. Measure in one or two of the cells (*a*) the length of the cell, (*b*) the length of the cilia, (*c*) the size of the nucleus. Sketch two or three cells.

3. Mount in sea-water one or two bars of the gill of the marine mussel (fig. 87). Study the action of the large cilia. Now place the preparation upon the copper warm stage (see Lesson VI) and observe the effect of gently raising the temperature.

Put this preparation aside, until the end of the lesson, by which time many

of the cilia will have become languid. When this is the case pass a drop of dilute potash solution (1 part KHO to 1000 of sea-water) under the cover-glass and observe the effect.

4. Cement with sealing-wax a piece of small glass tubing to a slide so that one end of the tube comes nearly to the centre and the other end projects beyond the

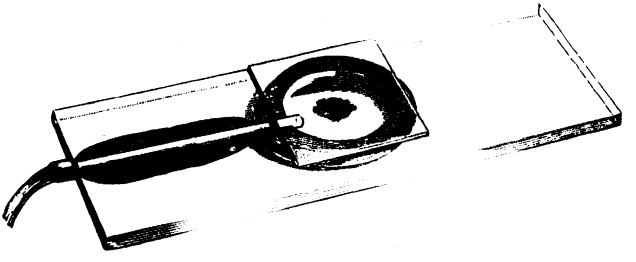

FIG. 88.—MOIST CHAMBER ADAPTED FOR PASSING A GAS OR VAPOUR TO A PREPARATION UNDER THE MICROSCOPE.

edge of the slide. To do this the slide must be heated, sealing-wax melted on to it and allowed to cool. The glass tube is then made hot and applied to the slide, embedding itself as it does so in the sealing-wax. Apply a ring of modelling wax or plasticine (half an inch in diameter and rising well above the glass tube) so as to include the end of the tube. Make a deep notch, or a hole, in the ring for the exit of gas. Place a drop of water within the ring (fig. 88).



FIG. 89.—METHOD OF SUBJECTING A PREPARATION TO A STREAM OF CARBON DIOXIDE.

b, bottle containing marble and hydrochloric acid; *b'*, wash-bottle, connected by indiarubber tube, *t*, with the moist chamber, *s*.

Put a bar from the gill upon a cover-glass in the least possible quantity of sea-water; invert the cover-glass over the ring, and (with another slide) press it down gently and evenly. The preparation now hangs in a *moist chamber* within which it can be studied through the cover-glass, and into which gases or vapours can be passed and their effects observed. The slide must be securely clamped to the stage of the microscope.

Pass CO_2 through the chamber (fig. 89), and after observing the effect replace it by air. Repeat with ether vapour and with chloroform vapour.

COLUMNAR EPITHELIUM.

Columnar epithelium occurs extensively in the body, lining the ducts of glands and covering the inner surface of mucous membranes. These are

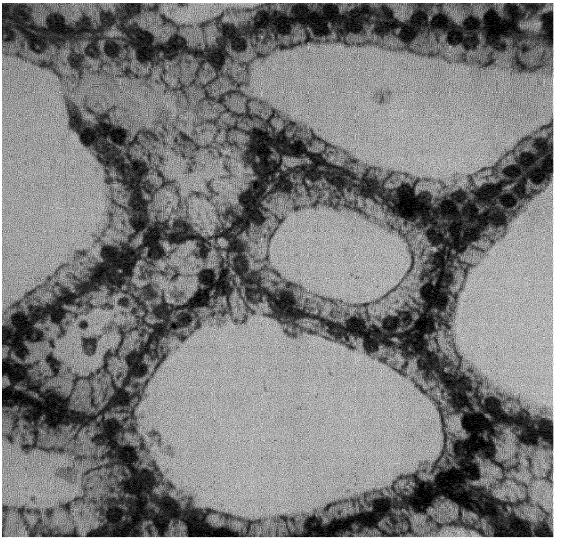

FIG. 90.—ORBITAL GLAND OF RABBIT, SHOWING CUBICAL EPITHELIUM LINING THE ALVEOLI. (E. Sharpey-Schafer.) × 300.

membranes moistened by *mucus* and lining passages in communication with the exterior, such as the alimentary canal and the respiratory and generative passages.

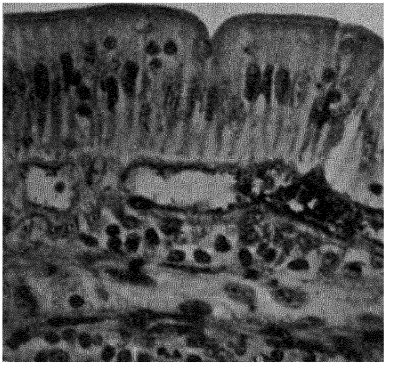

FIG. 91.—SECTION OF PART OF AN INTESTINAL VILLUS (CAT) SHOWING COLUMNAR EPITHELIUM CELLS COVERING THE FREE SURFACE. (E. Sharpey-Schafer.) × 400.

The cells of a columnar epithelium generally form a single layer, varying in thickness according to the length of the constituent cells. When the cells are short, the epithelium is spoken of as cubical (fig. 90). The cells are prismatic columns, which are set closely side by side, so that when seen in surface view a mosaic appearance is produced, the intercellular or cement substance forming a network around their ends ('Kittleisten' of German authors). They often taper somewhat towards their attached end, which is generally truncated, and set upon a basement membrane. In the cells lining the intestine, the

free surface is covered by a thick striated border (figs. 91, 92, 94) which may sometimes become detached in teased preparations, and has the

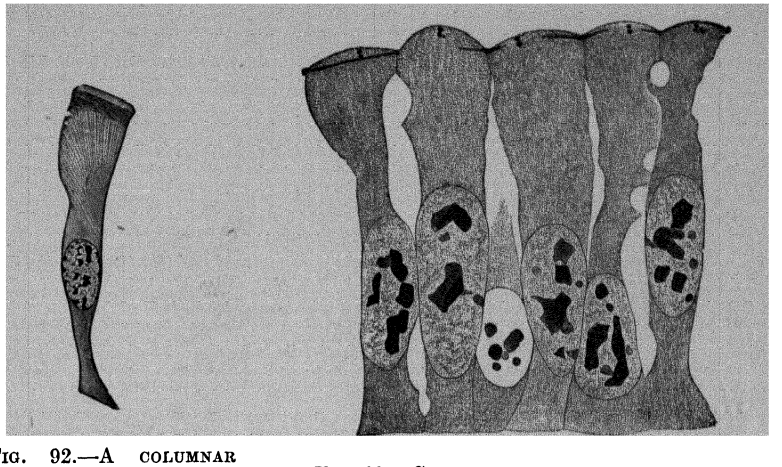

FIG. 92.—A COLUMNAR EPITHELIUM-CELL, SHOWING CYTOMITOME. (M. Heidenhain.)

FIG. 93.—COLUMNAR EPITHELIUM-CELLS FROM DUCK EMBRYO, EACH CONTAINING A DIPLOSOME (DOUBLE CENTRIOLE) AT THE FREE BORDER. (M. Heidenhain.) Highly magnified.

appearance of a dense mass of cilia (see p. 87). The protoplasm of the cell exhibits fibres or vacuoles or granules according to the method which has been used for fixation. It contains numerous filamentous mitochondria (fig. 94). Between the striated border and the protoplasm is a highly refractile disk, in the middle of which is a double centriole (diplosome) looking like a minute dumb-bell set vertically (fig. 93). A Golgi apparatus lies between the nucleus and the free end of the cell (fig. 101). The nucleus is ovoid and usually has two nucleoli. The lateral borders of the cells are often irregular or jagged, due to the presence of amœboid leucocytes, which are generally found between the columnar cells. After a meal containing fat some of the epithelium-cells of the small intestine contain fat-globules, staining black in osmic preparations, red with Sudan III.



FIG. 94.—TWO COLUMNAR EPITHELIUM-CELLS OF INTESTINE, STAINED TO SHOW THE MITOCHONDRIA. (Champy.)

Columnar epithelium-cells are found lining the whole of the interior of the stomach and intestines: they are also present in the ducts of most glands, and sometimes also in their secreting tubes and saccules. The epithelium which covers the ovary is also of a modified columnar shape, but cells possessing the striated border and other structural peculiarities above described occur only in the alimentary canal and in certain of its diverticula.

CILIATED EPITHELIUM.

Ciliated epithelium is found in man throughout the whole extent of the air-passages and their prolongations, but not in the uppermost part of the nostrils, supplied by the olfactory nerves, nor in the lower part of the pharynx, nor in the terminal bronchioles and pulmonary alveoli. Ciliated epithelium also occurs in the Fallopian tubes (oviducts) and the greater part of the uterus; in the efferent tubes of the testicle; in the ventricles of the brain, and the central canal of the spinal cord. The cells may be only one layer deep, but in the trachea there is a second or basal layer from which the ciliated cells may be regenerated. The ciliated cells are usually columnar in shape (fig. 95). In place of the striated

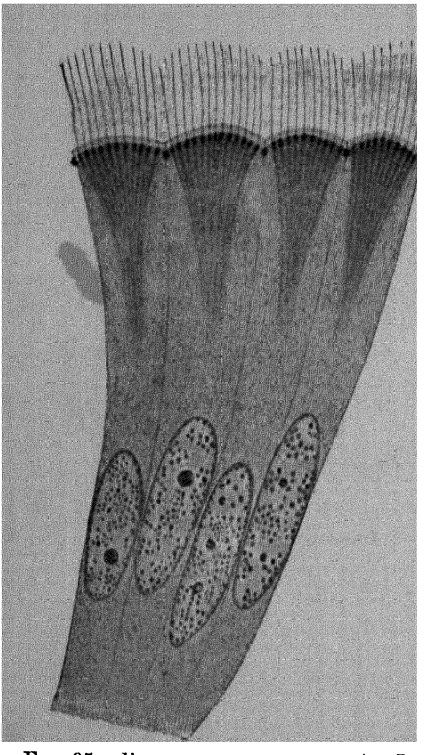

FIG. 95.—FOUR CILIATED CELLS. (v. Lenhossék.) Very highly magnified.

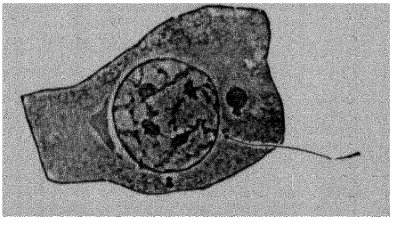

FIG. 96.—SPERMATID, SHOWING THE TAIL-FILAMENT (CILIUM) OF THE SPERMATOZOON DEVELOPING FROM THE CENTRIOLE OF THE CELL. (Niessing.)

border met with in the ordinary columnar cells, such as those found in the intestine, the free surface is surmounted by a bunch of fine tapering filaments (*vibratile cilia*), which, during life, move spontaneously to and fro, and serve to produce a current in the fluid which covers them. The border upon which the cilia are set has a bright appearance in the living condition: after fixation it appears formed of little juxtaposed *basal particles* to each of which a cilium is attached.

In the large ciliated cells which line the alimentary canal of some molluscs (fig. 95), and with less distinctness in the ciliated cells of vertebrates, the cilia seem to be prolonged through the basal particles into the protoplasm of the cell as fine varicose filaments termed *rootlets*. The nature of these has not been determined, but they resemble the fibrillar appearance (fibrome)

seen in many cells (p. 9) and possibly are mere indications of lines of stress in the colloidal substance of the cytoplasm.



FIG. 97.—CILIATED AND NON-CILIATED CELLS FROM EPIDIDYMIS OF RABBIT. (v. Lenhossék.) Very highly magnified.

The axial fibril in the tail of the spermatozoon (which is undoubtedly to be regarded as a cilium) is developed in connexion with the centriole (fig. 96), and it seems probable that the cilia of an ordinary ciliated cell may also be outgrowths from the multiplied centriole. Corroboration of this is found in the epididymis of the rabbit, where there are both ciliated and non-ciliated cells; the latter have a double centriole (diplosome), whilst the ciliated cells have no centriole, but a series of basal particles, which, it is believed, have been formed by multiplication of the original centriole (fig. 97). In the renal epithelium of the salamander-tadpole there is a centriole near the free border of each cell, with a single cilium attached to it (fig. 98). But it would appear that cilia are not always developed from centrioles. In plant spores, which have no centrioles, the cilia are said to be developed from amœboid processes of the cytoplasm.

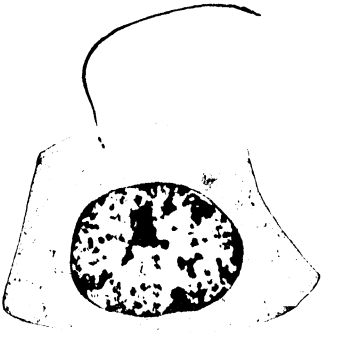

FIG. 98.—A RENAL EPITHELIUM-CELL OF SALAMANDER-TADPOLE, WITH CENTRIOLE AND CILIUM. (Meves.)

Basal particles like those of ciliated cells are also found in columnar cells (p. 85); they have been thought homologous with those of the ciliated cell, the bunch of cilia of the latter being perhaps represented by the striated border of the columnar cell, which looks very like a bunch of cilia although showing no ciliary movement. But the columnar cell contains an ordinary centriole, whereas the ciliated cell does not.

The action of cilia.—When in motion a cilium is bent quickly over in one direction with a lashing whip-like movement, immediately recovering itself. In the

effective direction it is stiff, in moving backward it is limp (Carter, 1923). When vigorous the action is so rapid, and the rhythm so frequent (ten or more times in a second), that it is impossible to follow the motion with the eye. All the cilia upon a ciliated surface are not in the same phase of action at the same instant, but



FIG. 99.—DIAGRAM TO SHOW THE MANNER IN WHICH CILIARY MOVEMENT PASSES IN WAVES OVER A CILIATED SURFACE. (Verworn.)

the movement travels in waves over the surface (fig. 99). If a cell is detached from the general surface, its cilia continue to act for a while, but their movement at once ceases if they are completely detached from the cell, and if a ciliated cell (of the frog) is merely pierced by a fine glass point, so that the protoplasm undergoes coagulation, the cilia cease to act (Chambers and Rémy).

The rhythm is slowed by cold and quickened by warmth; but heat a few degrees above body temperature kills the cells and stops the action. The presence of calcium is essential for ciliary movement (Gray, 1922). It will continue for about an hour in water deprived of oxygen. CO_2, ether vapour and chloroform vapour arrest the movement; but it recommences on restoring air, if the action of those agents, especially of chloroform, is not too prolonged. Very dilute alkaline solutions quicken the activity of cilia, or may even restore the movement shortly after it has ceased.

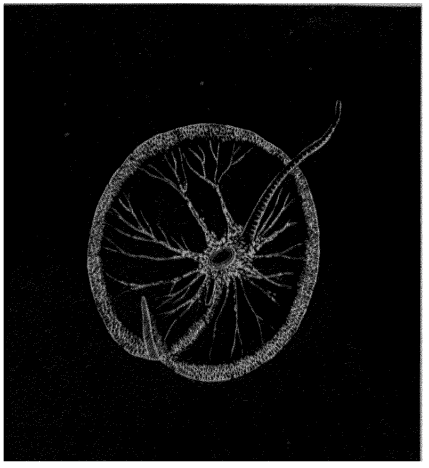

FIG. 100.—NOCTILUCA MILIARIS: A UNICELLULAR PHOSPHORESCENT MARINE ORGANISM PROVIDED WITH A SINGLE LARGE CILIUM (FLAGELLUM). (Verworn.)

Like all other movements of cells the action of cilia is probably brought about by displacement of fluid and consequent alterations in turgor in the part of the cell from which the cilia spring. To judge by what one can see in the case of large cilia, such as the flagellum of *Noctiluca miliaris* (fig. 100), cilia are hollow projections of the cytoplasm. If we suppose either that they are naturally curved or that one side is more resistant to extension than the other, a rhythmic increase and decrease of fluid pressure in the part of the cell from which they project could cause movements such as cilia exhibit. This would explain why it is that such apparently soft structures are able to create currents in a viscid fluid like mucus.

Most cilia are independent of nerves, but in the freshwater snail the cilia around the mouth can be set in activity by stimulating the nerve-fibres passing to that part (Merton, 1923). It is stated that the cilia lining the œsophagus of the frog can be accelerated or retarded in their movements by stimulation of the vagus and sympathetic nerves, either directly or through the action of autacoids and drugs.

Goblet or chalice cells.—Some of the cells of columnar and ciliated epithelia (fig. 101), which lie between the ordinary cells of the tissue, and occasionally cells in glandular and transitional epithelia, secrete mucin,

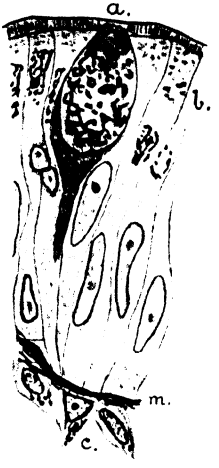

FIG. 101.—FIVE COLUMNAR CELLS AND ONE GOBLET-CELL FROM THE SMALL INTESTINE OF THE CAT. (H. M. Carleton.) × 1000.

a, goblet-cell; *b*, columnar cells; *c*, connective-tissue cells; *m*, basement membrane.

A Golgi apparatus is visible in each cell, and there are also indications of mitochondria. The Golgi reticulum of the goblet-cell is large and the distal portion appears to be breaking up as the secretion (mucin) is being formed.

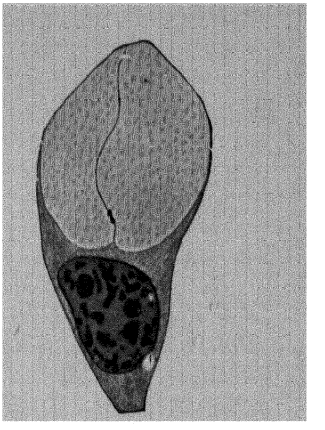

FIG. 102.—GOBLET-CELL OF SALAMANDER-LARVA, WITH A DIPLOSOME IN THE MUCIN-CONTAINING PORTION OF THE CELL. (Joseph.)

A fibril is prolonged from each of the two centrioles forming the diplosome.

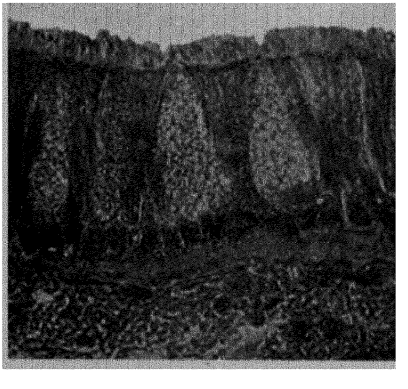

FIG. 103.—CILIATED EPITHELIUM FROM THE TRACHEA OF A CAT, SHOWING GOBLET-CELLS ALTERNATING WITH THE ORDINARY COLUMNAR CILIATED CELLS. (E. Sharpey-Schafer.) × 800.

The goblet-cells are full of globules of mucigen. Note the thick basement membrane above the corium of the mucous membrane and the numerous elastic fibres in the mucous membrane.

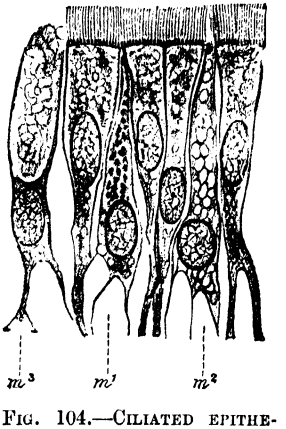

FIG. 104.—CILIATED EPITHELIUM FROM THE TRACHEA OF THE RABBIT. (E. Sharpey-Schafer.) Magnified about 1000 diameters.

m^1, m^2, m^3, indicate mucin-secreting cells (between the columnar ciliated cells) in three stages of mucin-formation.

which is laid down within the cell in the form of granules or globules of mucigen (figs. 103, 104). The granules eventually swell up to form globular masses which clump together and greatly distend the part of the cell nearest the free border. When the mucigen is extruded as mucus the free part of the cell becomes emptied and the cell then takes the form of a goblet or chalice, hence the above name. The nucleus always lies near the attached end of the cell, in the stem of the goblet. The centriole or diplosome lies between the nucleus and the free border (fig. 102). The Golgi apparatus lies within and at the base of the goblet (fig. 101).

These *goblet-cells*, or, as they may be appropriately termed, *mucus-secreting cells*, are not mere temporary modifications of the ordinary columnar and ciliated cells amongst which they are found, but permanently differentiated cells; they may be regarded as unicellular glands. After having got rid of their mucigen by extrusion, they again form a fresh supply in the same way as before. In the gastric mucous membrane all the surface epithelium is composed of mucus-secreting cells, and here they extend also a certain distance into the tubular glands. In the small intestine they occur here and there between the ordinary columnar cells covering the general surface and the villi, and also between those lining the crypts of Lieberkühn. In the large intestine most of the cells both of the surface and in the glands are goblet-cells. Goblet-cells also occur abundantly amongst the cells of some ciliated epithelia, such as that of the trachea (figs. 103, 104).

LESSON IX.

AREOLAR TISSUE: ADIPOSE TISSUE: RETICULAR TISSUE: RETICULO-ENDOTHELIUM.

1. TAKE a little of the subcutaneous tissue or of the intermuscular connective tissue of a rabbit or guinea-pig and spread it with needles on a dry slide into a large thin film. Keep the centre moist by occasionally breathing on it, but allow the edges to dry to the slide. Before commencing put a drop of salt solution on a cover-glass, and now invert this over the film, which should be a good deal larger than the cover-glass, so that the thinned-out edges remain dried on to the slide. Examine with a high power. Sketch one or two bundles of white fibres and also one or two elastic fibres, distinguishable from the former by their sharp outline, isolated course, and by their branching. Sketch also one or more connective-tissue cells. Next carefully remove the cover-glass and replace it after adding a drop of dilute acetic acid (1 per cent.). Watch the effect. The white fibres become swollen, whilst the elastic fibres and corpuscles come more clearly into view. Look for constricted bundles of white fibres.

2. Make another very thin film in the same way, but allow it to dry completely. Pour over the film a 1 per cent. solution of acid fuchsin in equal parts of water and alcohol, to which 1 drop per c.c. of a 1 per cent. solution of gentian-violet in alcohol has just been added. After one minute drain off, and remove the remainder of the staining solution by pressing a piece of clean blotting-paper on it; allow the film again to dry completely and mount it in dammar. The elastic fibres are deeply stained; the cells are also shown.

Van Gieson's and Mallory's stains (see Appendix), which contain acid fuchsin, are also used for staining connective-tissue fibres, especially in sections of organs.

3. Prepare another moist film of subcutaneous tissue, including a little adipose tissue. Fix by pouring over it formol (10 per cent.); leave this in contact with the film for twenty minutes. Wash with water and stain with saturated solution of Sudan III or Scharlach R in 75 per cent. alcohol; wash with 75 per cent. alcohol to remove stain from everything except fat, then rinse with water and counterstain with dilute hæmatoxylin. Mount in dilute glycerine. Examine first with a low and afterwards with a high power. The fat is well brought out by the Sudan III or Scharlach R stain; if the preparation is from a young animal, fat-cells will be found in process of formation. Measure and sketch two or three of the fat-cells.

Fat may also be stained, with or without prior fixation by formol, by treatment with 1 per cent. osmic acid solution, which colours it intensely black.

4. Spread out another film of connective tissue, letting its edges dry to the slide, but, as before, keeping the middle part moist by the breath. Place on its centre a large drop of 1 per cent. nitrate of silver solution. After five minutes wash this away with distilled water, and expose on white paper to direct sunlight until slightly brown. Now remove the water with blotting-paper, allow the film to dry completely, and cover it in dammar. Sketch the outlines of some of the cell-spaces which are displayed.

5. For reticular tissue the following method is recommended (Spalteholz). Place a piece of the organ (*e.g.* lymphatic gland) for twenty-four hours or more in 90 per cent. alcohol, then overnight at 38° C. in a 1 per cent. solution of carbonate

of soda to which a few drops of a solution] containing trypsin have been added. Cautiously transfer the semi-digested structure to alcohol again, and leave it for a few hours. Embed in paraffin in the usual way and stain the sections with iron hæmatoxylin (see Appendix). The fibrils of connective and reticular tissue are the only structures which have remained undigested; they are deeply coloured by the stain.

Reticular tissue is also well shown in sections of lymph-glands or spleen stained with Mallory or Van Gieson.

The term 'connective tissue' includes *areolar, elastic, reticular, adipose,* and *fibrous tissues* and also *cartilage* and *bone.*

All the connective tissues have certain features in common:

They are developed from the same blastodermic layer—the mesoderm.

The intercellular substance tends to be highly developed (in contrast with epithelia).

Fibres are formed in the intercellular substance.

Transitions between the different varieties are common in places where they come into contact.

The functions of connective tissue are largely mechanical. Adipose tissue, although mainly concerned with metabolism, is grouped with them because it is developed in connexion with areolar tissue.

Of the varieties of connective tissue above enumerated three are so intimately allied that they may be described together, for they are composed of exactly the same elements, and differ only in the relative development of those elements: these three are the *areolar, elastic,* and *fibrous* tissues. Areolar tissue being the commonest and, in a sense, the most typical, its structure will be described first.

AREOLAR TISSUE.

Areolar tissue presents to the naked eye an appearance of fine transparent threads and laminæ which intercross in every direction with one another, leaving intercommunicating meshes (areolæ) between them. When examined with the microscope, these threads and fibres are seen to be principally made up of wavy bundles of exquisitely fine transparent fibres (*white fibres,* fig. 105). The bundles run in different directions, and may branch and intercommunicate with one another (fig. 106); but the individual fibres, although they pass from one bundle to another, never branch or join other fibres. The fibres are cemented together into the bundles by a clear substance containing mucin, and the same material in a semi-fluid condition forms also the basis or *ground-substance* of the tissue, in which the bundles themselves course, and in which also the corpuscles of the tissue lie embedded. This ground-substance between the bundles can with difficulty be seen in the fresh tissue on account of its extreme transparency; but it can be brought to view by treatment with nitrate of silver (§ 4). The whole of the tissue is thereby stained a yellowish-brown colour, with the exception of the spaces occupied by the cells (*cell-spaces,* figs. 107, 108). This reaction is due to the presence of chlorides in the intercellular substance.

Besides the white fibres of connective tissue above described, fibres



FIG. 105.—WHITE FIBRES OF AREOLAR TISSUE. (W. Sharpey.)
The bundles of white fibres are partly unravelled.

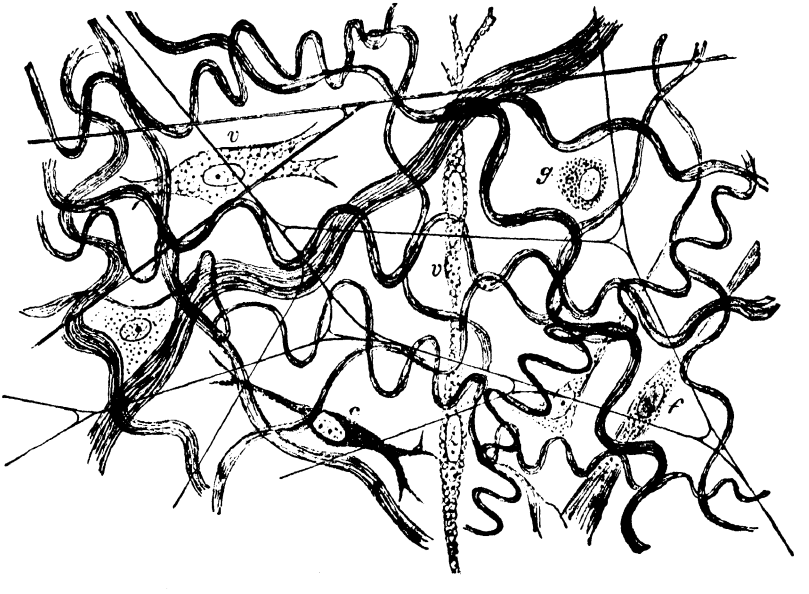

FIG. 106.—SUBCUTANEOUS AREOLAR TISSUE FROM A YOUNG RABBIT.
(E. Sharpey-Schafer.) Much magnified.

The figure shows the appearance of the fresh tissue prepared by the demi-desiccation method. The white fibres are in wavy bundles; the elastic fibres form an open network.
c, macrophagocyte; *g*, basiphil or mast-cell; *f*, fibrillated cell: the remaining cells are lamellar cells. They vary greatly in shape and size but all consist of clear cytoplasm ,some ,*v*, containing vacuoles and a few granules.

of a different kind (fig. 109) occur; these are the *elastic fibres*. They are especially well seen after treatment with acetic acid, and also after staining

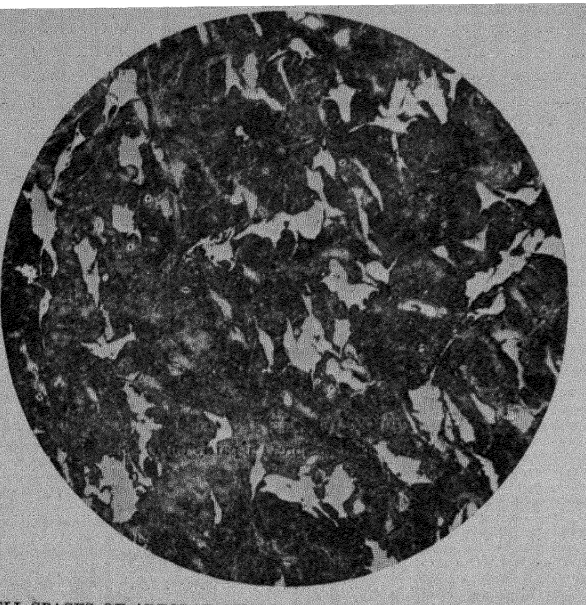

FIG. 107.—CELL-SPACES OF AREOLAR TISSUE OF RABBIT, STAINED WITH SILVER NITRATE (E. Sharpey-Schafer.) × 110. Photograph.



FIG. 108.—PART OF THE SAME PREPARATION. × 400.

Bundles of connective-tissue fibres and elastic fibres are indistinctly visible in the ground-substance.

with acid fuchsin or (in sections) with orcëin; but they can be detected in fresh preparations mounted in normal saline. They are characterised by

their distinct outline, their straight course, the fact that they do not run in bundles, but singly, and that they branch and join neighbouring fibres. If broken by the needles used in teasing, the elastic recoil causes them to curl up, especially near the broken ends. Besides these histological differences,

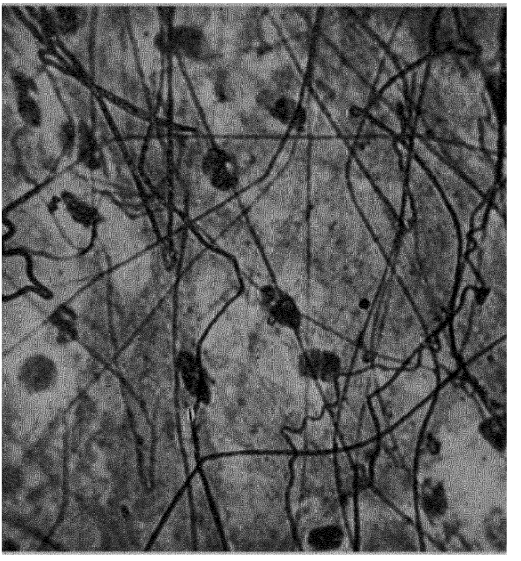

FIG. 109.—AREOLAR TISSUE FILM STAINED WITH ACID FUCHSIN. (E. Sharpey-Schafer.) × 400.

Only the elastic fibres and the nuclei of the connective-tissue cells are shown.

the two kinds of fibre differ also in their chemical characters. Thus the white fibres are formed of a material (*collagen*) which is dissolved by boiling in water, forming a solution of gelatine; they are also dissolved by peptic digestion, but not by tryptic; whereas the substance of which the elastic

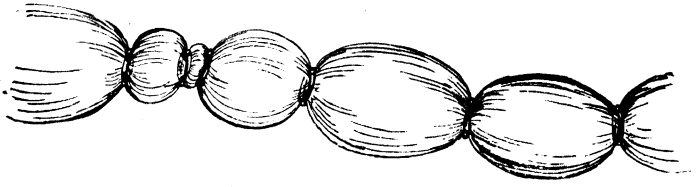

FIG. 110.—A WHITE BUNDLE SWOLLEN BY ACETIC ACID. FROM THE SUB-ARACHNOID TISSUE AT THE BASE OF THE BRAIN. (Toldt.)

fibres are composed (*elastin*) resists for a long time the action of boiling water and peptic digestion, and is dissolved by tryptic digestion. Moreover, the white fibres swell and become indistinct under the action of dilute acetic acid; the elastic fibres are unaltered by this reagent. Elastic fibres appear to have a sheath which is more resistant to reagents than the internal part of the fibre.

Bundles of white fibres which have been swollen by acid sometimes exhibit constrictions at irregular intervals (fig. 110). These constrictions are thought to be due to elastic fibres coiling round the white bundles.

The cells of areolar tissue.—Areolar connective tissue contains many cells. The following types have been described :

(1) **Lamellar cells (fibroblasts).**—These elements lie upon and amongst the fibre-bundles ; the cell-body is usually flattened (fig. 111, *c*) and irregular

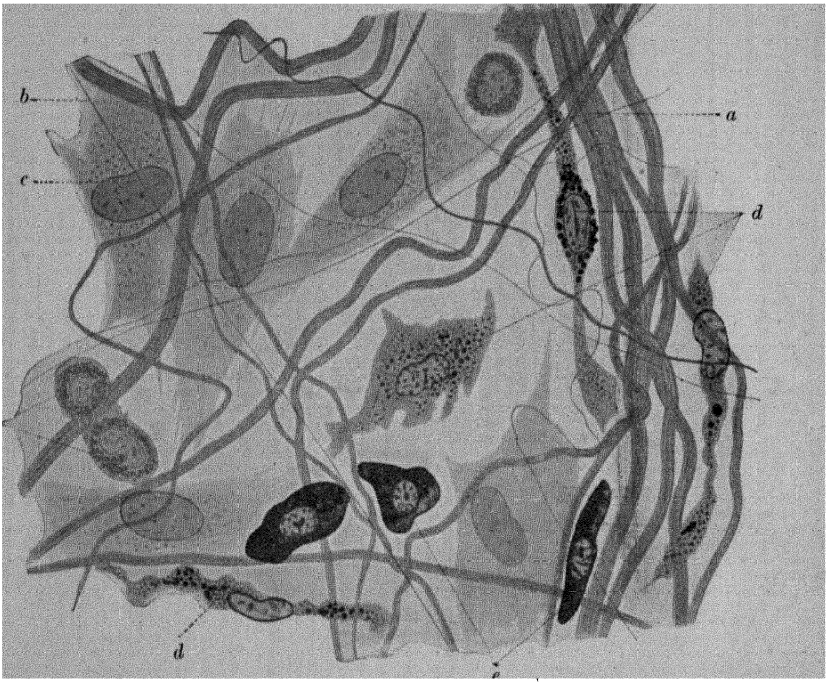

FIG. 111.—FIBRES AND CELLS OF AREOLAR TISSUE OF A GUINEA-PIG FROM A FILM-PREPARATION ; STAINED WITH NEUTRAL RED. (Maximow.)

a, bundles of white fibres ; *b*, fine elastic fibres ; *c*, lamellar cells ; *d*, macrophagocytes ; *e*, plasma cells *f*, oxyphil leucocytes.

in shape, often branched ; the nucleus is oval. In certain situations, as when they lie upon the surface of an aponeurosis, the lamellar cells are joined edge to edge, like cells, of an endothelium (fig. 112). When branched they come in contact with one another by their branches, as in the cornea The formation of white connective-tissue fibres is thought to be dependent on these cells, for the fibres in question first make their appearance in the immediate neighbourhood of the fibroblasts ; but the white fibres are not formed within the cell-substance, they are deposited in the intercellular substance itself.

(2) **Macrophagocytes (clasmatocytes** of Ranvier ; **histiocytes** of Aschoff).—Both in film-preparations and sections these appear as irregularly shaped

cells (fig. 111, *d*) with oval or spherical nuclei and basiphil cytoplasm. They are most easily identified by their tendency to take up vital stains, and by otherwise displaying active phagocytic properties.

(3) **Basicytes** ('Mastzellen' of German authors).—These are usually spheroidal or ovoidal and are full of granules staining intensely with basic dyes. In general appearance the connective-tissue basicytes are like the basiphils of the blood, although their relationship to these is problematic: they are generally much larger than the blood-leucocytes. They are common where fat is being laid down.

(4) **Plasma-cells.**—The plasma-cell is thought to be derived from the lymphocyte, by an increase in size. The nucleus is spherical; the chromatin

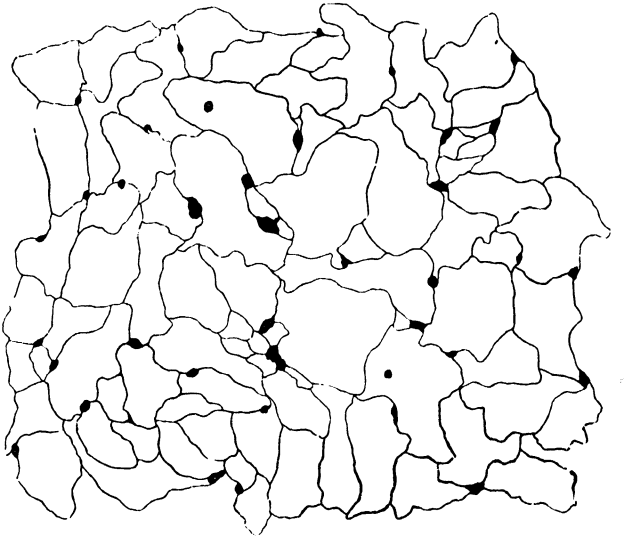

FIG. 112.—ENDOTHELIUM-LIKE CELLS OF CONNECTIVE TISSUE FROM THE SURFACE OF AN APONEUROSIS. NITRATE OF SILVER PREPARATION. (E. Sharpey-Schafer.)

is often arranged in irregular masses within it. The cytoplasm, oval or irregular, is basiphil, but without granules.

Leucocytes are normally found in small numbers in areolar tissue, whither they may have migrated from the blood-stream. They are generally either lymphocytes or polymorphs.

The connective-tissue cells occupy spaces (*cell-spaces*) of corresponding shape in the ground-substance (figs. 107, 108), lying between the bundles of white fibres. In some parts the white bundles are developed to such an extent as to pervade the whole of the ground-substance, and then the connective-tissue corpuscles become squeezed into the interstices; flattened lamellar expansions of the cells extending between the bundles (as in tendon; see next Lesson).

The cells of areolar tissue come into intimate relation with the cells lining

the lymph-vessels and the small blood-vessels. This connexion can best be seen in silvered preparations, where both the cells and the lymphatics

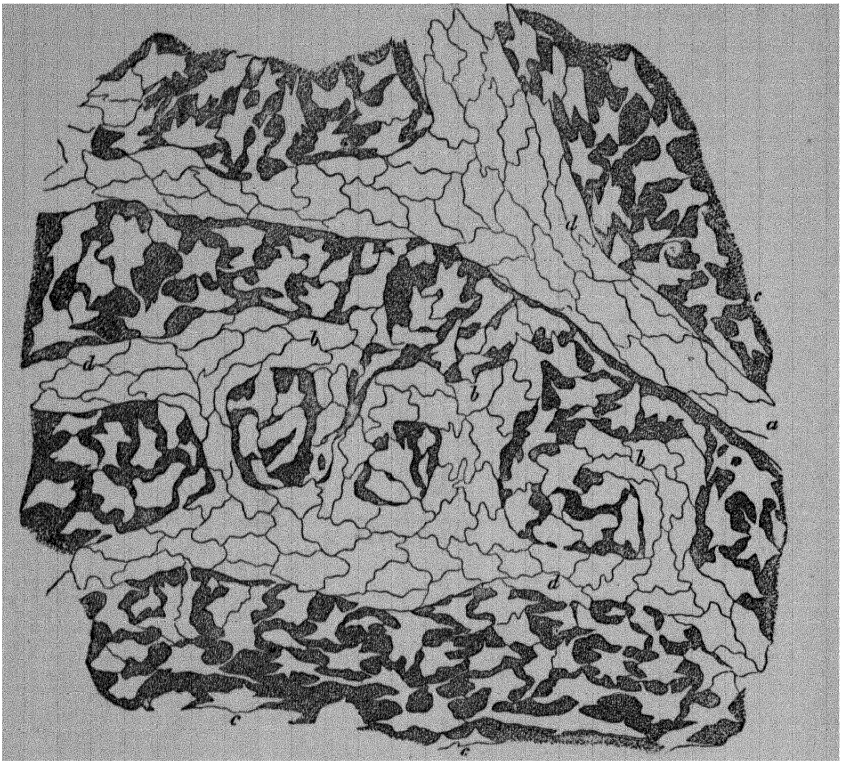

FIG. 113.—ORIGIN OF LYMPH-VESSELS IN CONNECTIVE TISSUE, SHOWN BY THE NITRATE OF SILVER METHOD. (v. Recklinghausen.)

a, efferent lymphatic vessel; *b*, rootlets of the lymph-capillaries; *c*, connective-tissue cells seen as white cell-spaces in the brown ground-substance; *d*, lymph-capillaries.

are left white on the brown ground of stained intercellular substance (fig. 113); this arrangement will be again referred to in speaking of the origin of the lymphatics.

PIGMENT.

In the middle coat of the eye in mammals (fig. 114) and also in certain parts of the skin, some of the connective-tissue cells are occupied by granules of pigment. Such cells are much more extensively present in lower vertebrates, especially in Amphibia and fishes, where they are either black (melanophores) or of a yellowish colour (xanthophores). The cells in question exhibit changes which result in the pigment being at one time diffused over a considerable area and at another time restricted to the immediate neighbourhood of the nucleus. The changes are produced

by variations in the environment (light, moisture, etc.). Such variations cause alterations in the general shade and colour of the integument, and

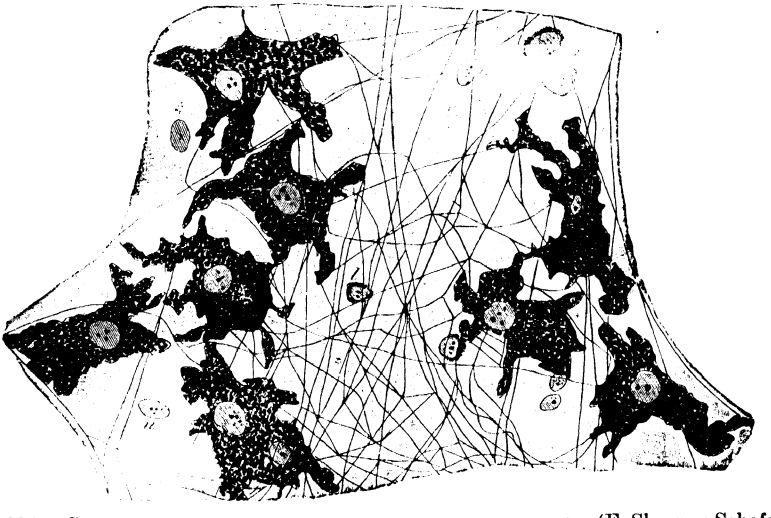

FIG. 114.—CONNECTIVE TISSUE OF CHOROID FROM THE HUMAN EYE. (E. Sharpey-Schafer.) Highly magnified.

The branching pigment-cells and elastic fibres are well shown; *n*, nuclei of lamellar cells; *l*, lymphocytes.

serve the purpose of protective adaptation of the animals to their surroundings, but all pigment-cells do not exhibit the changes in question.

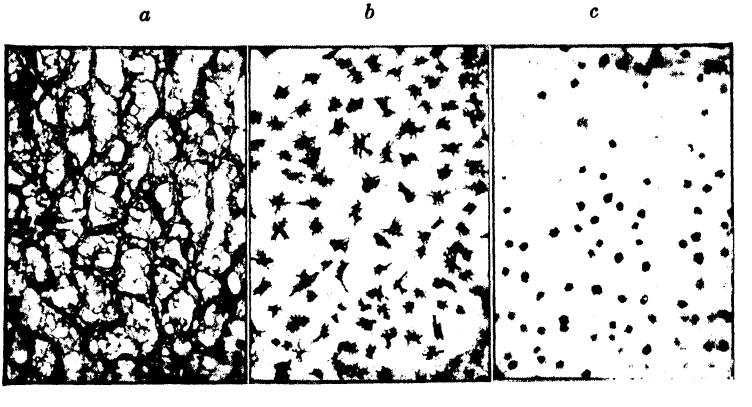

FIG. 115.—CUTANEOUS PIGMENT-CELLS (MELANOPHORES) OF FROG-WEB. (L. Hogben.)

a, from a *dark* animal, with the pigment spread out over the whole cell; *b*, with the pigment partially retracted; *c*, from a *pale* animal, with the pigment wholly retracted and concentrated around the nucleus of each cell.

In those cells in which the alterations occur, the distribution of the pigment within the cell is effected by migration of the pigment granules in the relatively fixed body (fig. 115), the granules being either heaped round the

nucleus (light effect) or scattered throughout the cytoplasm (dark effect) (Lister).

Not only do the pigment-cells respond to light through the agency of the nervous system, but in some animals also to autacoid substances (hormones or chalones) produced within the organism. Thus in the frog's skin the pigment-granules of the melanophores are collected upon the nucleus as a result of the action of adrenaline, and causes the integument to appear light; whereas they spread out into all the processes of the cells as a result of the action of an extract of the pars intermedia of the pituitary body, producing the effect of making the integument appear dark.

ADIPOSE TISSUE: FAT.

Adipose tissue consists of vesicular cells filled with fat (figs. 116 to 119) and collected into lobules or masses, or into tracts which accompany the smaller

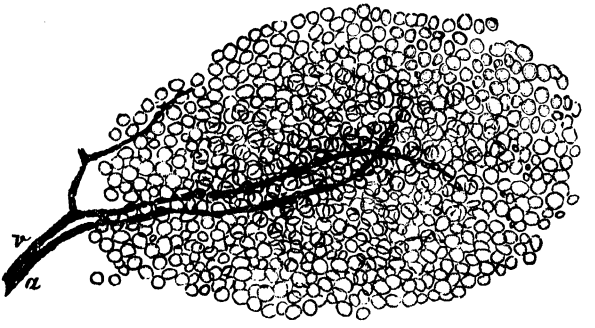

FIG. 116.—A SMALL LOBULE OF ADIPOSE TISSUE. (E. Sharpey-Schafer.) × 20.
a, *v*, small artery and vein entering the lobule.

blood-vessels. The vesicles are round or oval in shape, except where closely packed, when they become polyhedral from mutual compression. The fat-drop is contained within a delicate protoplasmic envelope (fig. 117), which represents the cytoplasm of the cell and is thickened at one part, here including an oval flattened nucleus. The fat is stained black by osmic acid (fig. 119); a deep orange-red by Sudan III (fig. 118); and an intense red by Scharlach R. The vesicles are supported partly by filaments of areolar tissue, partly by a fine network of capillary blood-vessels.

The fat when first formed in the embryo is deposited within large granular basiphil cells (fig. 120) of a spheroidal or polyhedral shape. Some authorities regard these cells as of a specific nature, for they are in certain situations collected into gland-like masses abundantly supplied with blood-vessels. The masses have been compared with internally secreting glands and the name *adipose glands* has been applied to them. Before the fat is fully formed in their cells they have a brownish colour, and if the fat is absorbed, *e.g.* in starvation, they return to the embryonic condition. The chief of these masses lies at the back between the scapulæ.

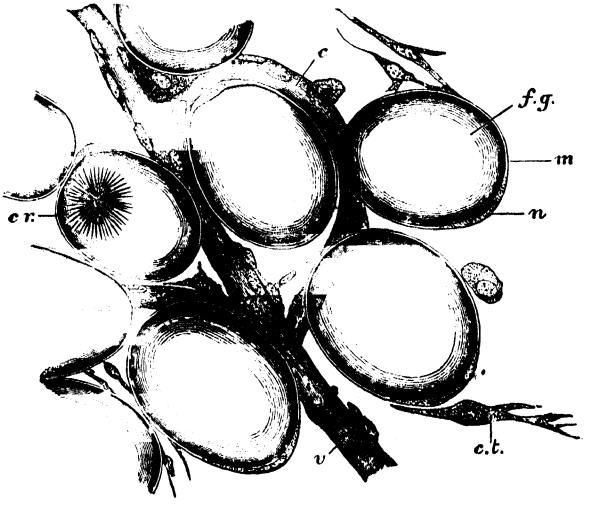

FIG. 117.—CELLS FROM THE MARGIN OF THE FAT-LOBULE REPRESENTED IN FIG. 116. (E. Sharpey-Schafer.) Highly magnified.

m, membrane of fat-cell consisting of cytoplasm and nucleus (*n*) and enclosing the large fat-globule, *f.g.*; *c.r.*, crystals of fatty acid; *c*, a capillary joining a venule, *v*; *c.t.*, a connective-tissue cell.

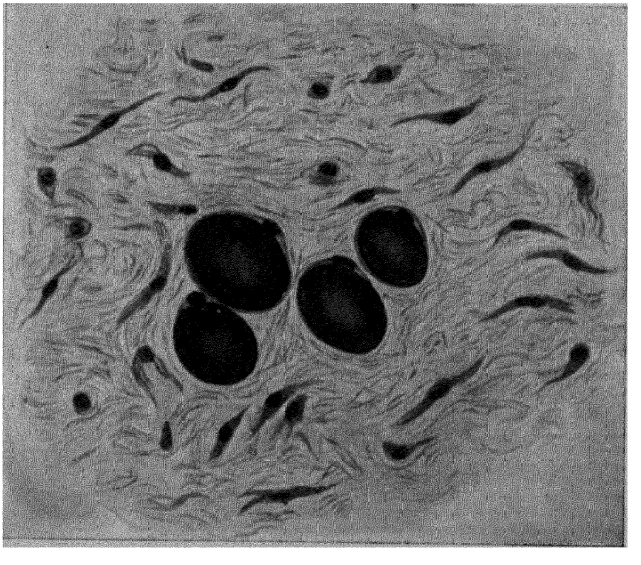

FIG. 118.—FOUR FAT-CELLS IN CONNECTIVE TISSUE. (E. Sharpey-Schafer.) × 400.

Each cell is distended by the fat-globule, the cell-protoplasm forming a thin envelope to the globule. The nucleus lies at one side in a somewhat larger amount of protoplasm. The fat was stained red with Sudan III and appears black in the photograph.



FIG. 119.—FAT-CELLS FROM YOUNG ANIMAL. OSMIC ACID PREPARATION. (Ranvier.)
The drops of fat are stained of an intense black. *n*, nucleus; *g*, small globules of fat.

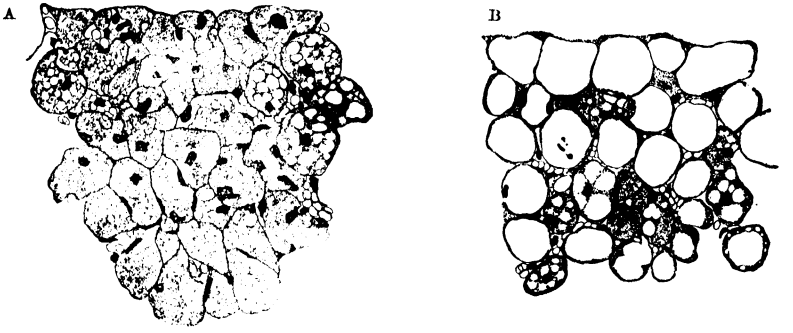

FIG. 120.—TWO STAGES OF FORMATION OF ADIPOSE TISSUE IN A 'FAT-GLAND.' (H. Batty Shaw.)
In A the tissue appears as a gland-like mass of granular-looking cells, some of which contain a number of small fat-globules (white in the section). In B the fat completely fills many of the cells.

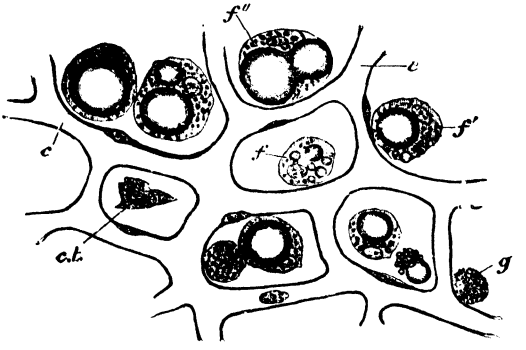

FIG. 121.—DEPOSITION OF FAT IN CONNECTIVE-TISSUE CELLS. (E. Sharpey-Schafer.)
f, a cell with a few isolated fat-droplets in its protoplasm; *f'*, a cell with a single large and several minute drops; *f''*, fusion of two large drops; *g*, basicyte; *c.t.*, lamellar connective-tissue cell; *c*, network of capillaries.

Fat is, however, also laid down elsewhere in ordinary cells of connective tissue (fig. 121). This is conspicuously the case with the subcutaneous fat. It has been described as produced by a transformation into fatty droplets or granules, which may be of mitochondrial nature, and as being preceded by deposition of lipoids. As the fat (oil) droplets increase in size they run together into a larger drop, which gradually fills the cell, swelling it out more and more, so that eventually the cytoplasm remains merely as a thin envelope surrounding the fat-drop.

Fat is found most abundantly in the subcutaneous areolar tissue, and in some deeper parts, *e.g.* between the scapulæ, around the kidneys, under the epicardium, at the back of the peritoneum, and in the mesentery and omentum. The yellow marrow of the bones is also principally composed of fat. There is no adipose tissue within the cavity of the cranium.

RETICULAR (RETIFORM) TISSUE: LYMPHOID TISSUE.

In reticular tissue (figs. 122, 123) the intercellular substance is largely replaced by lymph, and is traversed by a network of collagenous fibres,

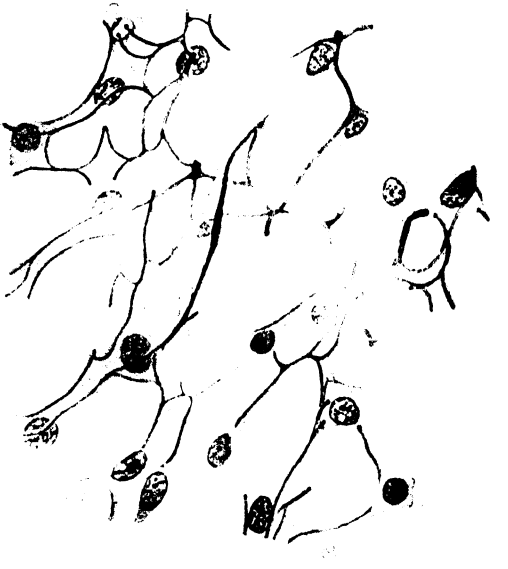

FIG. 122.—RETICULUM OF A LYMPH-GLAND, WITH ITS FIBRES OVERLAID BY ENDOTHELIAL CELLS. (M. Heidenhain.)

This furnishes a typical example of a reticulo-endothelium (see p. 105).

the meshes of which vary in size, being very small and close in some parts; more open and like areolar tissue in other parts. There are few or no elastic fibres. The fibres are often enwrapped by branched cells, the so-called *reticulo-endothelial cells*. Chemical differences between the fibres of reticular tissue and those of ordinary areolar tissue have been described by Mall and

others, but it is doubtful if they are really of a different nature, and microscopically the fibres of the two are indistinguishable: being stained by the same reagents and occurring in complete continuity with one another

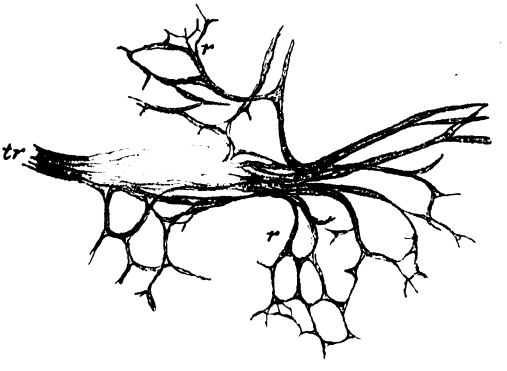

FIG. 123.—RETICULAR TISSUE FROM A LYMPH-GLAND. (E. Sharpey-Schafer.)
Showing the continuity of the reticular tissue, *r*, with the connective tissue of a trabecula, *tr*.

(see figs. 123, 125). Reticular tissue forms a fine framework in many organs; supporting the proper elements and extending into the interstices between the larger connective-tissue bundles. It can be shown by

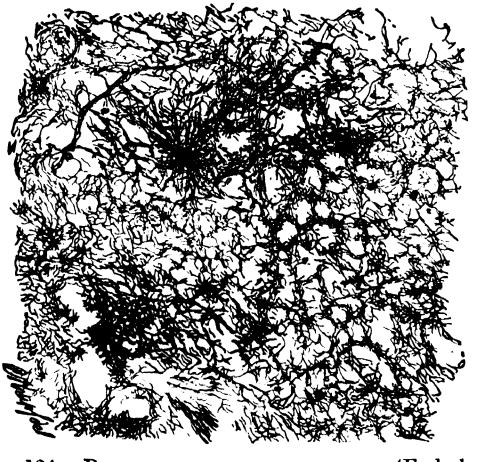

FIG. 124.—RETICULUM OF BONE-MARROW. (Enderlen.)

dissolving the cells of the tissue by tryptic digestion and subsequently staining the fibres which form the reticulum (p. 91, § 5). It occurs in lymph-glands, in the spleen, liver, bone-marrow (fig. 124), mucous membranes, and many other parts.

Lymphoid or adenoid tissue is reticular tissue in which the meshes of

the network are largely occupied by lymph-corpuscles (fig. 125), as in the lymph-glands and allied structures, such as the tonsils, lymphoid follicles, and Malpighian corpuscles of spleen. It will be described with those structures.

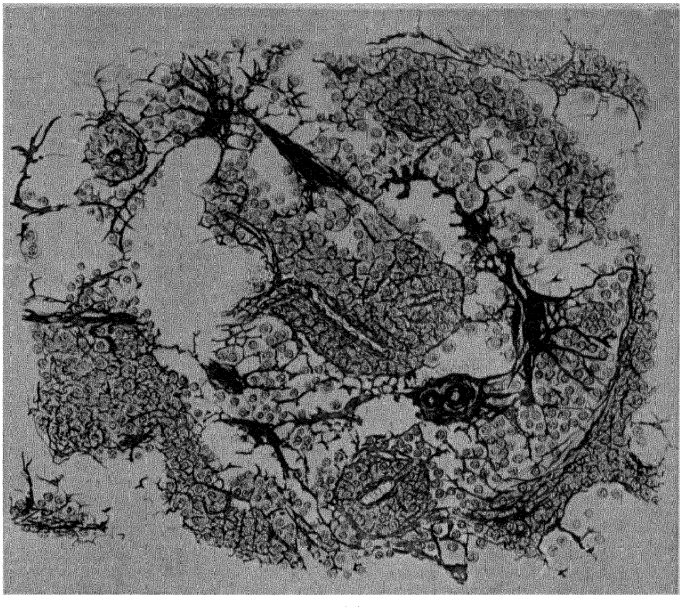

FIG. 125.—LYMPHOID TISSUE OF A LYMPH-GLAND. (E. Sharpey-Schafer.)
The fibres of the tissue have been stained. Their continuity with the connective-tissue trabeculæ is well shown.

THE RETICULO-ENDOTHELIAL SYSTEM.[1]

Ribbert (1904) first showed and Aschoff and others have since accentuated the fact that there exist in different situations phagocytic cells having a special affinity for certain dyes of a colloidal nature; the dye when introduced into the circulation being taken up by these particular cells, which then show an appearance of coloured granules in their cytoplasm. This is known as *vital staining*. Among such dyes are pyrrhol-blue, lithium-carmine, and trypan-blue. They are mostly of an acid nature.

Basic dyes may also be taken up by living cells. They, however, have no special affinity for particular cells, but under suitable conditions stain every cell, especially the nucleus.[2] Such staining is usually preceded by the death of the cell.

Ribbert, and subsequently Tait and other workers, have shown that fine suspended particles (quartz, carbon particles, etc.) introduced into the

[1] For this history of the subject with bibliography, the article by v. Möllendorff in *Ergebnisse der Physiologie*, Bd. xviii, may be consulted.

[2] Methylene-blue stains living nervous tissue selectively and other dyes have a special affinity for certain cell-constituents, such as fat, but these are exceptions.

blood-stream are taken up by the ' vitally staining ' cells and not by others. They also take up lipoid matter introduced into the circulation. The name ' reticulo-endothelial system ' (Aschoff) has been given collectively to these special phagocytes wherever they occur: the term includes the network of branched cells in which the phagocytes in question are involved.

The following are generally enumerated as belonging to the reticulo-endothelial system :—the cells of the reticulum of lymph-glands, the cells of the reticulum of the spleen-pulp, isolated cells in the blood-channels of the liver (von Kupffer's cells), the vascular endothelium of bone-marrow,

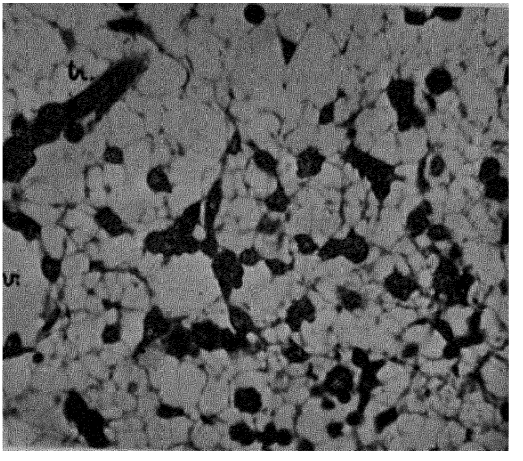

FIG. 126.—RETICULO-ENDOTHELIAL TISSUE OF SPLEEN-PULP. (E. Sharpey-Schafer.) × 385. Photograph.

The specimen is from a rabbit's spleen which had been perfused with Ringer to wash out the blood from the interstices of the pulp. *tr*, a trabecula; *v*, venous sinus, communicating with the interstices of the tissue.

that of the sinus-like blood-vessels of the suprarenal capsules, and that of the anterior lobe of the pituitary body.

To these some authors have added certain cells (macrophagocytes) in connective tissue (clasmatocytes of Ranvier, histiocytes of Aschoff) and blood-leucocytes of the macrocyte type, such as the large mononuclears and transitionals; these are termed ' blood-histiocytes ' by Aschoff.

The cells above enumerated are commonly assumed to have been derived from the endothelium of the blood-vessels and lymphatics. But endothelium in general does not show this affinity for vital stains and lipoids, nor do the ordinary phagocytes of the blood and lymph; these are therefore not usually included in the reticulo-endothelial system.

Organs like the spleen and lymph-glands containing much reticular tissue exhibit a relatively considerable number of large phagocytes, both in the reticulum (fig. 126) and in the blood or lymph leaving the organ. It has been affirmed that the venous blood in the right side of the heart is relatively rich in such large phagocytes, whereas that of the left heart, and the

arterial blood generally, contains but few: if this is the case some of the phagocytic cells disappear in passing through the lungs. Others may migrate from blood-vessels elsewhere, leaving the capillaries of the systemic circulation and wandering into the connective tissue; this has been suggested as the source of the macrophagocytes (clasmatocytes, histiocytes) of areolar tissue.

The cells of the reticulo-endothelial system, besides having an affinity for colloidal dyes and arresting inorganic particles such as carbon introduced into the blood, also have a special tendency to engulf micro-organisms and may in this way serve as a protection against invasion by pathogenic bacteria. Moreover, the Kupffer cells of the liver and the macrophages of the spleen have long been remarkable for the tendency they exhibit to take in red blood-cells, which appear to undergo disintegration within them, the hæmoglobin furnishing material from which the pigments of the bile are produced. It is known that such production is not confined to the liver; it is probably a general function of these phagocytic cells wherever they occur.

It will be seen that the elements which are grouped together under the head of reticulo-endothelium are of somewhat diverse character and origin. Although it is assumed by the title that they are produced from the vascular endothelium—which lines, often somewhat incompletely, the sinus-like spaces of organs like the spleen and lymph-glands—this mode of origin cannot be regarded as proved. The one link which binds the elements of the system together is the possession of a pronounced degree of phagocytosis: a purely physiological characteristic. The phagocytic cells are not permanently fixed: they are liable to become detached. The reticulo-endothelium of Aschoff is therefore not a well-defined tissue with special anatomical characters such as those which have been ascribed, since Bichat (1801), to the histological systems enumerated on p. 1.

Blocking.—Importance is attached by pathologists and bacteriologists to the possible activities of the reticulo-endothelial cells in connexion with protection against and destruction of micro-organisms by virtue of the pronounced phagocytosis characteristic of those cells. With the view of studying their functions in this respect, experiments have been made to produce engorgement of their cytoplasm with solid particles by intravascular injections (*e.g.* of Indian ink or of quartz particles), with the idea of producing interference with the functions of the cells. To this the term 'blocking' has been applied. When thus treated the 'histiocytes' may break away from their normal position and become carried away in the blood-stream; this has been described for the Kupffer cells of the liver.

LESSON X.

ELASTIC TISSUE: FIBROUS TISSUE: DEVELOPMENT OF CONNECTIVE TISSUE.

1. TEASE out as finely as possible a small shred of elastic tissue (ligamentum nuchæ of the ox or ligamentum subflavum of man) in glycerine and water, tinged by acid fuchsin. Cover and cement the preparation. Note the large well-defined fibres constantly branching and uniting with one another. Sketch a small part of the network. Note the existence of bundles of white fibres amongst the elastic fibres.

2. Examine a thin transverse section of ligamentum nuchæ which has been fixed in 2 per cent. solution of bichromate of potassium followed by alcohol. The section is to be stained with hæmatoxylin and eosin and mounted in dammar by the usual process, or it may be left unstained and simply mounted in glycerine and water. Observe the grouping of the fibres and their angular shape. Frequently the angles are rounded.

3. Pinch off the end of the tail of a dead mouse or rat, draw out the long silk-like tendons and put them into Ringer. Take one of the threads, which should be nearly three inches long, and stretch it along a slide, letting the ends dry firmly to the glass but keeping the middle part wet. Put a short piece of fine hair on each side and cover in salt solution. Observe with a high power the fine wavy fibrillation of the tendon. Draw. Now run dilute acetic acid (1 per cent.) under the cover-glass; watch the tendon where it is becoming swollen by the acid. Notice the oblong nucleated cells coming into view between the tendon-bundles. Sketch three or four cells in a row. Lastly, lift the cover-glass, wash away the acid with distilled water, place a drop of Delafield's hæmatoxylin solution on the tendon, and leave the preparation until it is deeply stained; then wash away the hæmatoxylin and mount the preparation in dilute glycerine.

4. Take another long piece of tail-tendon, and after washing it in distilled water stretch it upon a slide as before, fixing the ends by allowing them to dry on to the slide but keeping the middle wet. Put a drop of nitrate of silver solution (1 per cent.) on the middle, and leave it for five minutes. Then rinse off the silver nitrate with distilled water, drain this off and lay the slide on a piece of white paper in direct sunlight. In a very few minutes the silvered part of the tendon will be brown. Drain off the water, allow the preparation to dry completely and mount in dammar.

5. Stain with acid fuchsin solution a thin section of ox-tendon which has been hardened in 70 per cent. alcohol. The section may be cut by hand with a razor. Or the tissue may be hardened in 10 per cent. formol, soaked in gum and cut frozen. Mount in dilute glycerine and cement at once.

6. For studying the development of connective tissue, sections of the umbilical cord at different periods of intrauterine life may be used. Fix with formol. Stain with Van Gieson and hæmatoxylin.

ELASTIC TISSUE.

Elastic tissue is a variety of connective tissue in which elastic fibres preponderate. It is found most characteristically in the ligamentum nuchæ

(of quadrupeds) and in the ligamenta subflava of the vertebræ, but the connective tissue of other parts may also have a considerable development of



FIG. 127.—ELASTIC FIBRES FROM THE LIGAMENTUM NUCHÆ OF THE OX, SHOWING TRANSVERSE MARKINGS. (E. Sharpey-Schafer.) × 150.

elastic fibres. It occurs in abundance in the walls of the air-tubes, and uniting the cartilages of the larynx. It also enters largely into the formation of the lungs and of the walls of the arteries.

In the ligamentum nuchæ most of the fibres are large (fig. 127). They



FIG. 128.—CROSS SECTION OF ELASTIC FIBRES FROM THE LIGAMENTUM NUCHÆ OF THE OX. (E. Sharpey-Schafer.) × 200. Photograph.
The angles of the fibres are mostly rounded.

often exhibit cross markings or even transverse clefts. When dragged asunder they break sharply across. They constantly branch and unite, so as to form a network. In transverse section they appear angular, but usually the angles are rounded (fig. 128). They are separated into small groups or bundles by intervening areolar tissue.

Elastic tissue does not always take the form of fibres, but also occurs as

membranes (*e.g.* in the blood-vessels). In areolar tissue the elastic fibres may be very fine, but their microscopic and chemical characters are always well marked (p. 95).

FIBROUS TISSUE.

Fibrous tissue is almost wholly made up of bundles of white fibres running in determinate directions. These bundles again are collected into larger

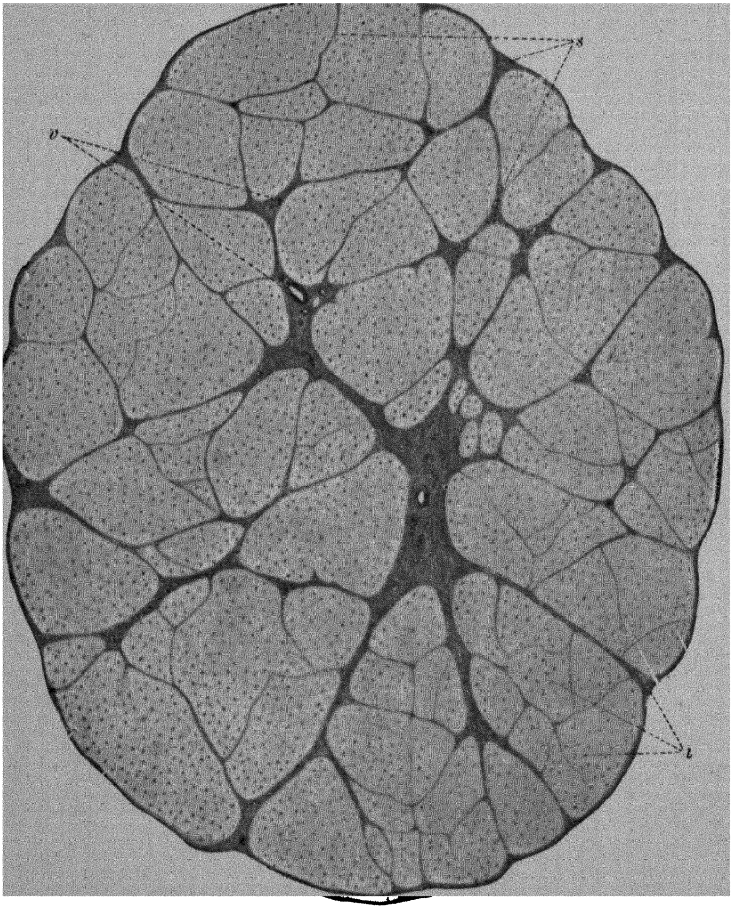

FIG. 129.—SECTION OF TENDON, HUMAN. (Sobotta.) × 32.
t, tendon-bundles; *s*, septa of areolar tissue; *v*, vessels.

bundles, which give the fibrous appearance to the tissue. The bundles are constantly uniting with one another in their course, although their component fibres remain distinct.

The interspaces between the larger bundles are occupied by areolar tissue (fig. 129, *s*; fig. 130, *c*, *d*, *e*) in which the blood-vessels, lymphatics, and nerves

of the fibrous tissue are conveyed. The interstices between the smallest bundles are occupied by rows of lamellar connective-tissue corpuscles (*tendon-*

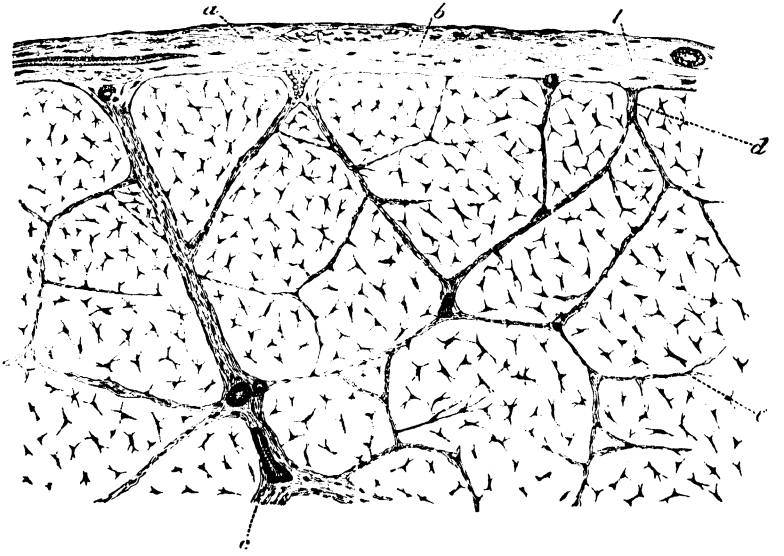

FIG. 130.—PART OF A LARGE TENDON IN TRANSVERSE SECTION. (E. Sharpey-Schafer.) More highly magnified.

a, areolar sheath of the tendon, with the fibres for the most part running transversely; but with two or three longitudinal bundles, *b*; *l*, lymphatic cleft in the sheath; immediately over it a blood-vessel is seen cut across, and on the other side of the figure a small artery is shown cut longitudinally; *c*, large septum of areolar tissue; *d*, smaller septum; *e*, still smaller septum. The irregularly stellate bodies are the tendon-cells in section.

cells), which, from being squeezed up between three or more bundles, become flattened out in two or three directions. In transverse section the cells look irregularly stellate (figs. 130, 131), but when seen on the flat they appear lamellar (fig. 132, A; fig. 133); from this aspect their general shape is square or oblong. They lie, as before said, in rows between the tendon-bundles; the nuclei of adjacent cells are placed opposite one another in pairs (fig. 133). The cell-spaces correspond in figure and arrangement with the cells which occupy them (fig. 133, B).

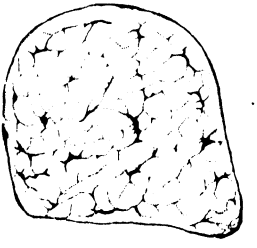

FIG. 131.—SECTION OF TENDON FROM TAIL OF MOUSE. (E. Sharpey-Schafer.) × 150.

The dark branched bodies are sections of the tendon-cells.

Fibrous tissue forms the tendons and ligaments, and also certain membranes, such as the dura mater, the fibrous pericardium, the fasciæ of the limbs, the fibrous coverings of organs, etc. It is found wherever great strength, combined with flexibility, is concerned. It receives a few blood-vessels, disposed longitudinally for the most part, and contains many lymphatics. Both blood-vessels and lymphatics run in the areolar tissue which separates and surrounds the tendon-bundles. Tendons and ligaments also

receive nerve-fibres, many of which end in localised ramifications within fusiform enlargements of the tendon-bundles (organs of Golgi), while others

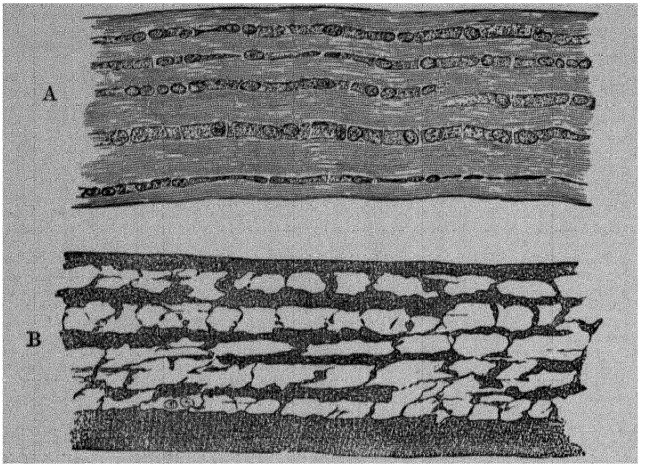

FIG. 132.—TENDONS OF MOUSE TAIL, SHOWING CHAINS OF CELLS BETWEEN THE TENDON BUNDLES. (E. Sharpey-Schafer.) × 175.

A, stained with hæmatoxylin; B, stained with silver nitrate, showing cell-spaces.

terminate in end-bulbs or in simple Pacinian corpuscles. These will be described with the modes of ending of nerve-fibres.



FIG. 133.—EIGHT CELLS FROM THE SAME TENDON AS REPRESENTED IN FIG. 132, A. × 425.

The dark lines on the surface of the cells are the optical sections of lamellar extensions directed towards or away from the observer.

MINOR VARIETIES OF CONNECTIVE TISSUE.

Basement-membranes (*membranæ propriæ*) are homogeneous-looking membranes, which are found forming the surface layer of connective-tissue expansions in certain parts, especially where there is a covering of epithelium, as on mucous membranes, in secreting glands, and elsewhere. They seem sometimes formed of flattened connective-tissue cells joined together to form a membrane; but in most cases (*e.g.* front of cornea, trachea) they are evidently formed not of cells, but of condensed ground-substance, and in yet other cases of elastic substance (back of cornea). The name basement-membrane has therefore been used to denote structures of a totally different nature.

Jelly-like connective tissue, although occurring largely in the embryo, is found only in one situation in the adult—viz. forming the vitreous humour

of the eye. It is composed mainly of soft, fluid or semi-fluid ground-substance, with cells scattered here and there through it, and with fibres which interlace throughout the tissue and confine the fluid of the ground-substance within their meshes, thus conferring upon the tissue its jelly-like character. All embryonic connective tissue is at one period of this jelly-like nature.

HISTOGENESIS OF CONNECTIVE TISSUE.

Connective tissue is developed in connexion with certain cells of the mesoderm (mesenchyme) of the embryo. In those parts which are to form connective tissue there may frequently be seen a clear space separating the

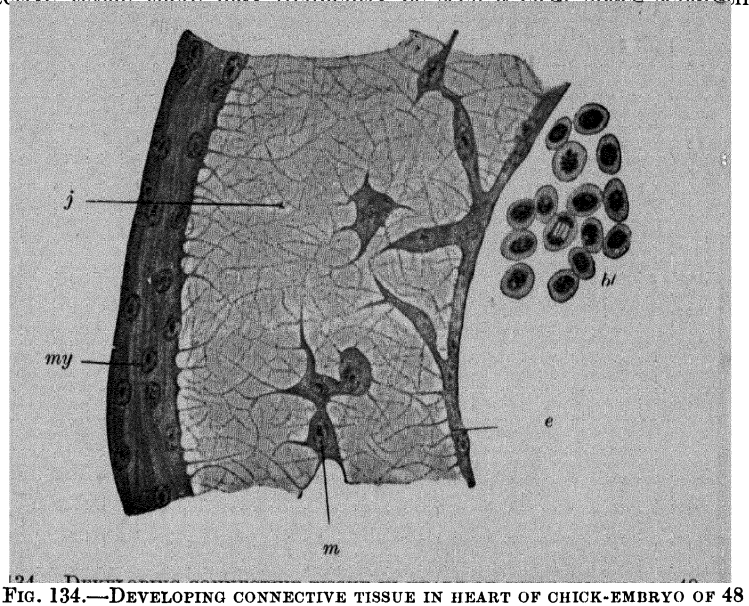

FIG. 134.—DEVELOPING CONNECTIVE TISSUE IN HEART OF CHICK-EMBRYO OF 48 HOURS. (Szily.)

my, cells forming myocardium; *j*, jelly formed of reticulum with enclosed fluid; *e*, endothelium; *m*, mesenchyme cells in jelly; *bl*, blood-corpuscles.

cell-layers which are already formed, this clear space being sometimes permeated with a network of fibres which appear to be in continuity with the cells bounding the space. Branching mesenchyme cells, which separate off from the bounding cells, are presently found forming a syncytium within the clear space (fig. 134, *m*; fig. 135). In the meshes of this syncytium is a semi-fluid intercellular substance (ground-substance). The connective-tissue fibres, both white and elastic, are deposited in this ground-substance. The elastic substance takes in the first instance the form of granules or globules (fig. 136, *g*), which subsequently become connected together into elastic, fibres or laminæ, as the case may be. The white fibres appear at first as single threads, which soon become numerous and are ultimately collected into fine bundles. The bundles become gradually larger; so that in some

tissues the whole ground-substance is eventually pervaded by them, and the cells of the tissue become squeezed up into the intervals. Before any considerable development of fibres has taken place, the embryonic connective

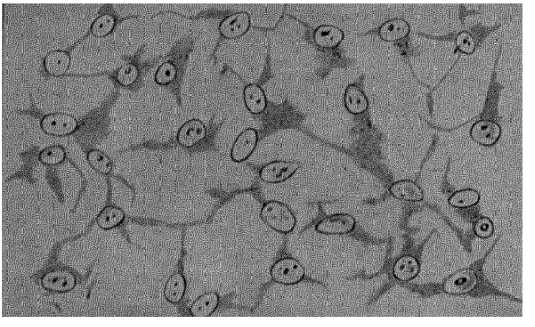

FIG. 135.—CELLS OF DEVELOPING CONNECTIVE TISSUE (MESENCHYME) UNITED TO FORM A SYNCYTIUM. (Prenant, Bouin, and Maillard.)
No fibres are as yet developed in the intercellular substance.

tissue has a jelly-like appearance; in this form it occurs in the umbilical cord, where it is known as the *jelly of Wharton* (fig. 137). A jelly-like connective tissue is also seen forming the marrow of embryonic bones at a certain stage of development.

There has long been a difference of opinion as to the origin of the

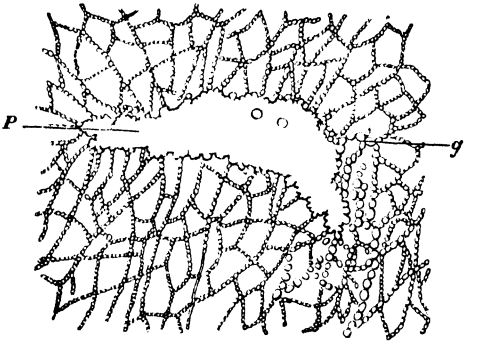

FIG. 136.—DEVELOPMENT OF ELASTIC TISSUE BY DEPOSITION OF FINE GRANULES. (Ranvier.)
g, fibres being formed of rows of 'elastin' granules; *p*, flat plate-like expansion of elastic substance formed by the fusion of 'elastin' granules.

fibres of connective tissue, some histologists holding that they are formed within the protoplasm of the cells, which gradually lose their cell-characters as fibres become developed within them; others taking the view that the fibres, both white and elastic, are extracellular formations. While it is certain that they are produced under the influence of the cells it is no less

certain that both kinds of fibres are deposited in the ground-substance between the cells and not in the cell-protoplasm, so that they are rather to be looked upon, like the ground-substance itself, as formed by a process of secretion

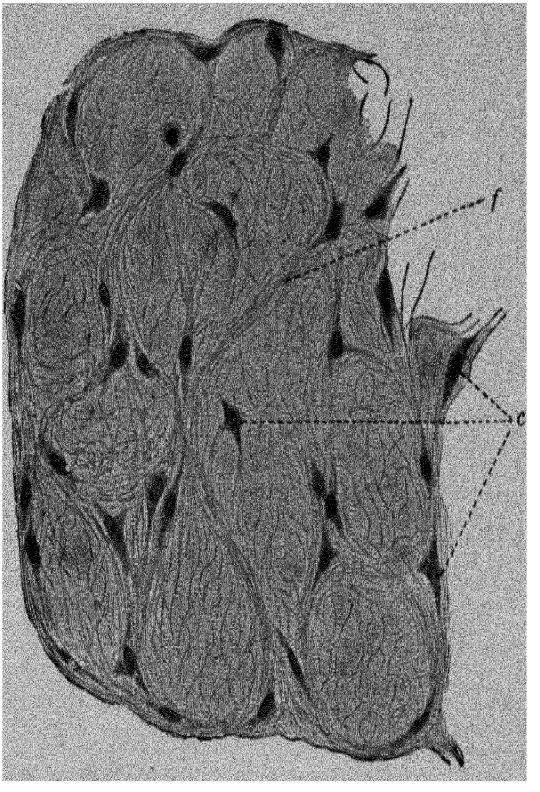

FIG. 137.—JELLY OF WHARTON FROM UMBILICAL CORD OF NEW-BORN CHILD. (Sobotta.) × 280.

f, connective-tissue fibres ; *c*, cells.

than by one of direct cell-transformation. That this is the true account of the mode of their formation is shown by the manner in which fibres of both kinds become developed in the ground-substance or matrix of hyaline cartilage, without any change in the form or structure of its cells being evident.

LESSON XI.

CARTILAGE AND SYNOVIAL MEMBRANES.

1. CUT two or three thin tangential slices of the fresh cartilage of a joint (sheep's foot), mount them in normal saline, and examine with the high power. Observe the form and grouping of the cells. Look at the thin edge of the section for spaces from which the cells have dropped out. Measure two or three cells and their nuclei, and sketch one or two groups. Now replace the salt solution by water and set the preparation aside for a little while. On again examining it, many of the cartilage-cells will be found to have contracted, leaving a clear space between each cell and the containing capsule.

2. Make other sections of the cartilage (1) from near the middle, (2) from near the edge at the attachment of the synovial membrane. Place the sections for two or three minutes in acetic acid (1 per cent.), wash them with water, and stain with dilute hæmatoxylin solution. When stained mount in dilute glycerine and cement the cover-glass. In (2) look for branched cartilage-cells.

3. Study vertical sections of articular cartilage from an end of bone which has been fixed and decalcified, and mount the sections in glycerine and water, or, after staining with hæmatoxylin, in dammar. Sketch the arrangement of the cells.

4. Rinse a fresh joint with distilled water; drop 1 per cent. nitrate of silver solution over it; after five minutes wash away the nitrate of silver and expose in water to direct sunlight. When browned, place in 70 per cent. alcohol for half an hour or more, and then with a razor wetted with the same spirit cut thin sections from the surface and mount in dammar after passing through clove oil. The cells and cell-spaces show white in the brown ground-substance.

5. To study the structure of synovial membrane mount other slices from the same silvered preparation of the joint (§ 4) taken just beyond the limits of the articular cartilage. Also look for small fringed projections of the membrane. Snip them off with scissors and mount as before.

6. The superficial flexor tendons of the foot (ox or sheep) run in grooves formed by the deep flexors, and these grooves are lined, and the tendons which pass through them are covered by vaginal synovial membranes. To show the structure of these, treat one of the superficial flexor tendons with silver nitrate in the manner recommended for the joint (§ 4), and after hardening in 70 per cent. alcohol, cut sections from the surface, pass through clove oil, and mount in dammar as before.

CARTILAGE.

Cartilage (*gristle*) is a translucent bluish-white tissue, firm, and at the same time elastic, and for the most part found in connexion with bones of the skeleton, most of which are in the embryo at first represented entirely by cartilage. Three chief varieties of cartilage are distinguished. In one, which is termed *hyaline*, the matrix or ground-substance is almost clear, and free from obvious fibres; in the other two, which are termed *fibro-cartilage*, the matrix is pervaded by connective-tissue fibres. When these

are of the white variety, the tissue is *white fibro-cartilage*; when they are elastic fibres, it is *yellow* or *elastic fibro-cartilage*.

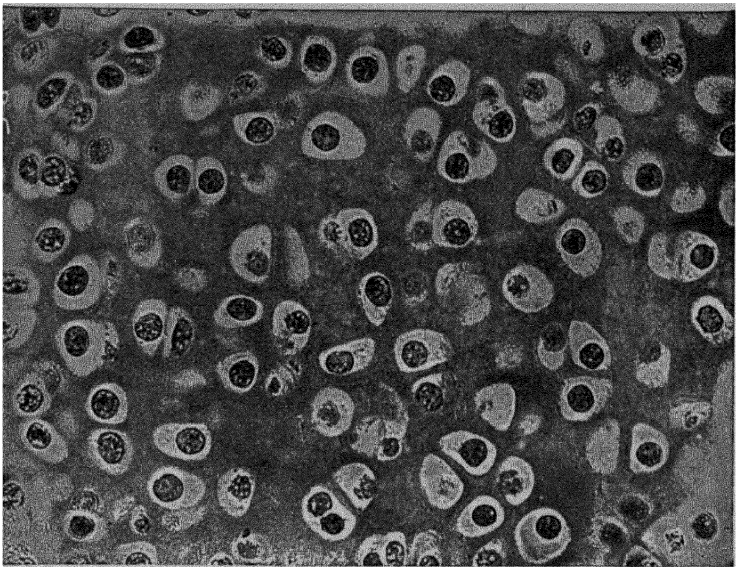

FIG. 138.—SECTION OF HYALINE CARTILAGE OF SALAMANDER. (E. Sharpey-Schafer.) × 200. Photograph.

The matrix immediately around the cartilage-cells is often marked off from the rest by concentric lines; the part of the matrix nearest each cell, the latest formed, being known as the *capsule* of the cell. The cells, which lie in groups of two, four, eight, etc., in the matrix, are bluntly angular in form, the sides opposite one another in the groups being generally flattened (fig. 138). The protoplasm is clear; it may have droplets of fat; and with a high power fine interlacing filaments and granules (mitochondria) can be observed in it (fig. 139). Cartilage-cells also contain, as a rule, glycogen: this can be shown by staining with iodine. During life the protoplasm entirely fills the cavity or cell-space which it occupies in the matrix; but after death, and in consequence of the action of water and some other agents, it tends to contract away from the capsule. The nucleus is generally spherical.

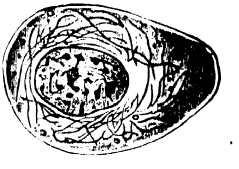

FIG. 139.—A CARTILAGE CELL OF SALAMANDER, SHOWING MITOCHONDRIA. (Flemming.) Highly magnified.

The disposition of the cells of cartilage in groups of two, four, eight, etc., is due to the fact that these groups have originated from the division of a single cell first into two, and these again into two, and so on. The division of the cartilage-cell, like that of most other cells, is effected by karyokinesis.

It would seem that the matrix is formed of successive portions, each being deposited around the cartilage-cell as a so-called 'capsule' (fig. 140). The newly formed portion blends in its turn with the previously formed matrix, whilst a new capsule is deposited within it. The more newly formed portions of matrix stain with hæmatoxylin more deeply than the rest; in some cartilages this gives the appearance of rounded clumps of darkly stained matter surrounding each cell or cell-group, the so-called *chondrin-balls* (fig. 146).

Hyaline cartilage occurs principally in two situations—namely (1) covering the ends of the bones in the joints, where it is known as *articular cartilage*; and (2) forming the rib-cartilages, where it is known as *costal cartilage*. It also forms the cartilages of the nose, of the external auditory meatus (but not of the pinna), most of those of the larynx, and the cartilages of the wind-

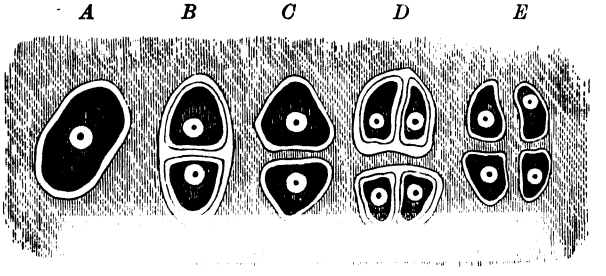

FIG. 140.—PLAN OF THE MULTIPLICATION OF THE CELLS OF CARTILAGE. (W. Sharpey.)

A, cell in its capsule; *B*, divided into two, each with a capsule; *C*, primary capsule disappeared, secondary capsules coherent with matrix; *D*, tertiary division; *E*, secondary capsules disappeared, tertiary coherent with matrix.

pipe and bronchial tubes; in these places it serves to maintain the shape and patency of the orifices and tubes.

By long maceration in brine, evidence of a fibrous structure may be obtained, even in the matrix of true hyaline cartilage. Some histologists have described fine communications in the matrix uniting the cartilage-cells with one another, but these are of doubtful occurrence in vertebrate cartilage, although they unquestionably exist in the cartilage of cephalopods.

Nutrition and gaseous exchanges between the cartilage cells and the blood-vessels of the perichondrium take place by diffusion and imbibition through the ground-substance. If the cartilage is thick, as in costal cartilage, canals carrying blood-vessels penetrate it here and there.

The cells of **articular cartilage** are generally arranged in elongated groups throughout the matrix. The latter is free from obvious fibres, except at the extreme edge of the cartilage, where the connective-tissue fibres from the synovial membrane extend into it; and here also the cartilage-cells are often branched, and offer transitions to the connective-tissue corpuscles of that membrane (*transitional cartilage*, fig. 141).

In vertical section (fig. 142) the deeper cell groups (*c*) are seen to be arranged vertically to the surface, the more superficial ones (*a*) parallel with

the surface; whilst in an intermediate zone the groups are irregularly

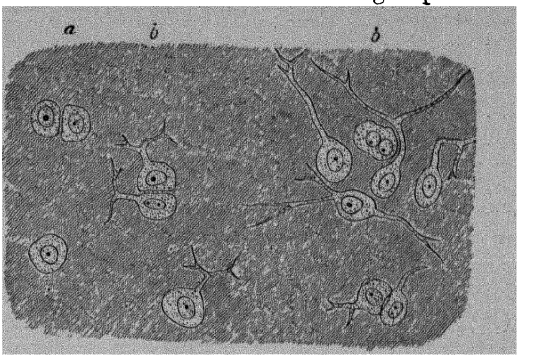

FIG. 141.—BORDER OF ARTICULAR CARTILAGE SHOWING TRANSITION OF CARTILAGE-CELLS INTO CONNECTIVE-TISSUE CORPUSCLES OF SYNOVIAL MEMBRANE. FROM HEAD OF METATARSAL BONE: HUMAN. (E. Sharpey-Schafer.) × 340.

a, ordinary cartilage-cells; *b*, *b*, with branching processes.

disposed (*b*). In the deepest part of the cartilage, next to the bone, there is often a deposit of calcareous salts in the matrix (*calcified cartilage, d*).

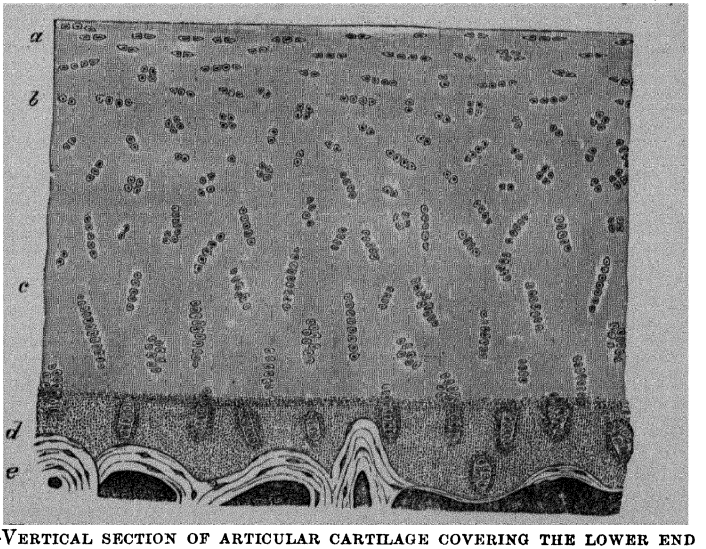

FIG. 142.—VERTICAL SECTION OF ARTICULAR CARTILAGE COVERING THE LOWER END OF THE TIBIA: HUMAN. (E. Sharpey-Schafer.) × 30.

a, cells and cell-groups flattened conformably with the surface; *b*, cell-groups irregularly arranged; *c*, cell-groups disposed perpendicularly to the surface; *d*, layer of calcified cartilage; *e*, bone.

SYNOVIAL MEMBRANES.

Synovial membranes are connective-tissue structures occurring in connexion with articular cartilage (fig. 143) and in certain other movable parts, *e.g.* where a tendon glides within a fibrous sheath, and at the so-called bursæ, such as that which lies between the skin and the patella. Their cells are for

the most part branched connective-tissue cells, but in some places they resemble cartilage-cells, and where a synovial membrane is continuous with cartilage, transitions occur between them (*transitional zone*).

The synovial membranes are often compared with serous membranes. Like the latter they bound closed cavities moistened with fluid, but they are not connected with the lymphatic system, nor is the glairy fluid (synovia) which moistens them of the nature of lymph. Moreover, there is either no endothelial lining, or it occurs only in patches, in place of the continuous lining which we find in serous membranes. Long villus-like projections, simple (fig. 144) or compound—the so-called *Haversian fringes*—occur in some situations; they contain a few cells, with the character of cartilage-cells, surrounded by cartilage-matrix. The fringes probably serve to extend the surface for the secretion of synovia.

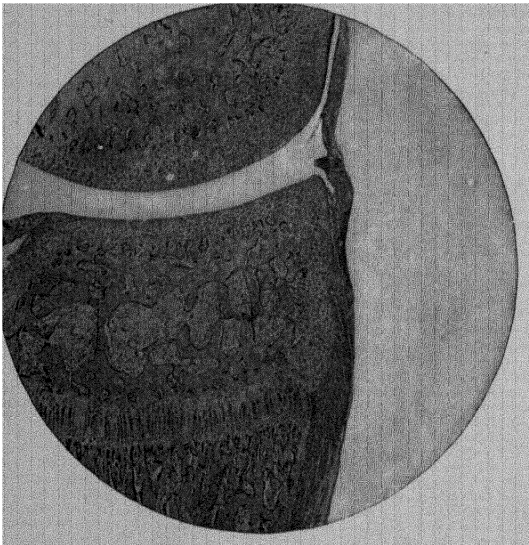

FIG. 143.—SECTION OF JOINT OF YOUNG RABBIT. (E. Sharpey-Schafer.) × 50. Photograph.

tice the capsular ligament uniting the ends of the bones and lined by the thin synovial membrane in which there are folds projecting slightly into the edge of the joint.



FIG. 144.—VILLUS OF SYNOVIAL MEMBRANE: HUMAN. (Hammar.)

Besides the Haversian fringes and synovial villi there are often larger folds of the membrane containing fat.

The synovial membrane of a joint is not prolonged over the opposed surfaces of the articular cartilages, but ceases near the edge of these in the transitional zone already alluded to. The blood-vessels of the membrane terminate here in capillary loops. The nerves of synovial membranes end partly in peculiar end-bulbs in the substance of the membrane, partly in a fine terminal plexus close to the inner surface. Pacinian corpuscles are also found in some places.

LESSON XII.

COSTAL CARTILAGE AND FIBRO-CARTILAGE.

1. MAKE transverse and tangential sections of a rib-cartilage (young animal) which may either be fresh or may have been fixed (*e.g.* in 10 per cent. formol). Stain the sections with hæmatoxylin (if fresh, after treatment with acetic acid as in Lesson XI. § 2; or they may be placed for an hour in 0·5 per cent. osmic acid), and mount in glycerine. Sketch a part of a transverse section under a low power and a cell-group from one of the tangential sections under a high power. Notice especially the arrangement of the cells, somewhat concentric near the surface but radial near the centre. The costal cartilages tend as age advances to become ossified; this occurs near the middle of their thickness in some animals, but in man when ossification occurs it is the superficial layer which is first invaded.

2. Make sections of the elastic cartilage of the external ear (pinna), either fresh or after hardening in alcohol. Mount in dilute glycerine faintly coloured with acid fuchsin or stain with orcëin and mount in dammar. The upper end of the arytenoid cartilage of the ox or calf may also be used to display the structure of elastic cartilage. Notice the large reticulating elastic fibres in the matrix of this. Notice also the isolated granules of elastin, and around each cartilage-cell an area of clear ground-substance. If the preparation is from the ear of the mouse or rat there is very little matrix and no elastic fibres, and the cells are almost in contact (parenchymatous cartilage).

3. Mount a section of the epiglottis in the same way. Notice the closer network of much finer elastic fibres in its cartilage.

4. Cut sections of white fibro-cartilage (intervertebral disk or semilunar cartilage of knee), which has been hardened in picric acid followed by 90 per cent. alcohol, or in the latter only. Stain with dilute hæmatoxylin. Mount in dilute glycerine. Observe the wavy fibres in the matrix, and the cartilage-cells, sometimes branched, lying in clear areas often concentrically striated. Sketch three or four cells and the adjoining fibrous matrix.

Costal cartilage.—In the rib-cartilages (fig. 145) the matrix is not always as clear as in the cartilages of the joints, and it more often happens that fibres become developed in it. The cells are generally larger than those of articular cartilage, and collected into larger groups (fig. 146). The matrix surrounding these is stained more deeply than the rest by hæmatoxylin: often this more deeply stained part is itself separated from the rest of the matrix by a less stained area. Near the circumference, and under the perichondrium or fibrous covering of the cartilage, the cell-groups are flattened and parallel to the surface, but in the deeper parts they have a more irregular or a radial arrangement. The cells frequently contain fat globules. The cartilages of the larynx, windpipe and bronchial tubes and of the nose resemble the costal cartilages; they will be further noticed when the organs where they occur are dealt with.

Yellow fibro-cartilage.—Elastic or yellow fibro-cartilage occurs in only a few situations, viz. the cartilage of the external ear, that of the Eustachian

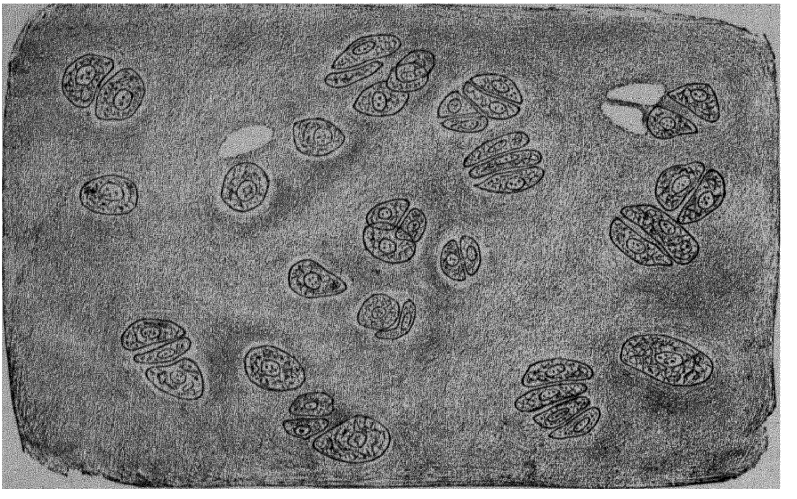

FIG. 145.—SECTION OF RIB-CARTILAGE OF CALF. (E. Sharpey-Schafer.) × 300.
The matrix is distinctly fibrous. Two or three empty cell-spaces are seen in the section, the cells having dropped out in the course of preparation.

tube, and the cartilages of the epiglottis and of Santorini in the larynx. The matrix is everywhere pervaded, except immediately around the cells and



FIG. 146.—SECTION OF COSTAL CARTILAGE. (E. Sharpey-Schafer.) × 240.
Photograph.
The section shows several groups of cartilage-cells. Capsule outlines are seen around the groups and also around the individual cells. The part around the cells and cell-groups is stained more than the rest of the matrix.

cell-groups, with well-defined branching fibres, which unite with one another to form a close network (fig. 147). These fibres resist the action of acetic acid,

and are stained deeply by acid fuchsin and orcëin ; they are evidently elastic fibres. In the ox (fig. 148) they are large, but smaller in man, especially

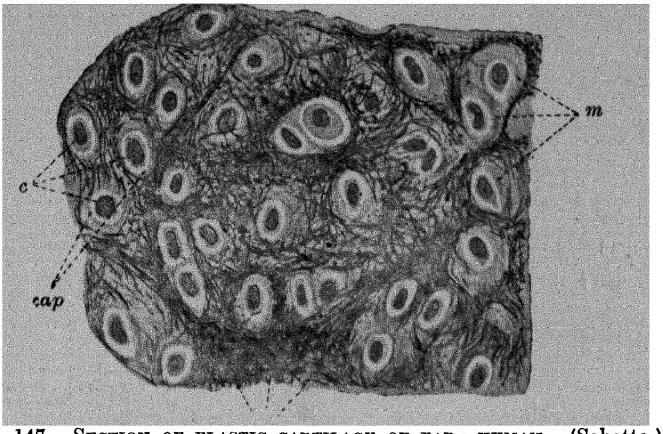

FIG. 147.—SECTION OF ELASTIC CARTILAGE OF EAR : HUMAN. (Sobotta.) × 280.
c, cartilage-cells ; *cap*, their capsules ; *m*, clear matrix around cells and cell-groups ; *f*, elastic fibres.

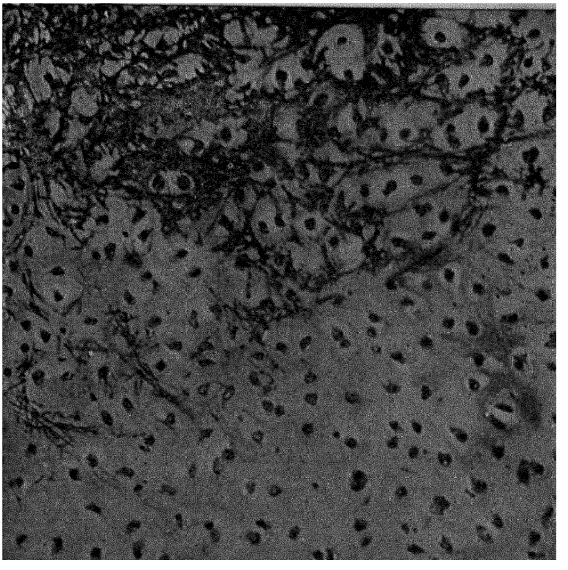

FIG. 148.—SECTION OF ARYTENOID CARTILAGE OF CALF AT JUNCTION OF HYALINE WITH ELASTIC PORTIONS. (E. Sharpey-Schafer.) × 50. Photograph.
The section was stained with acid fuchsin.

in the cartilage of the epiglottis. They appear to be developed, as with elastic tissue elsewhere (see p. 113), by the deposition of granules of elastin in the matrix (fig. 149) ; the granules at first lie scattered, but afterwards

become joined to form fibres. As the name implies, elastic cartilage is very flexible, and after being bent readily recovers its original form.

White fibro-cartilage.—White fibro-cartilage is found wherever great strength combined with a certain amount of rigidity is required: thus we frequently find this form of fibro-cartilage joining bones together, as in the intervertebral disks and other symphyses. In these cases the part in contact with the bone is always hyaline cartilage, which passes gradually into the fibro-cartilage forming the bulk of the symphysis. White fibro-cartilage is also found lining grooves in which tendons run, and it may be found here

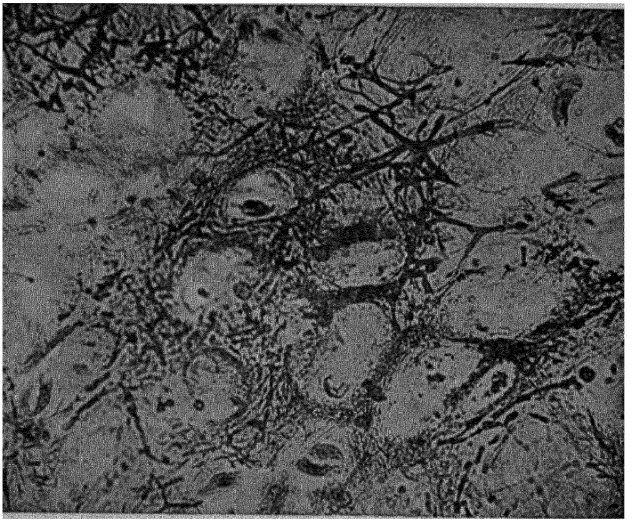

FIG. 149.—SECTION OF ELASTIC CARTILAGE (UPPER PART OF ARYTENOID OF CALF); STAINED WITH ACID FUCHSIN. (E. Sharpey-Schafer). × 200. Photograph.

The elastin is seen partly in the form of a granular deposit, partly as finer and coarser intercommunicating fibres. These are nowhere in contact with the cartilage-cells, which are surrounded by clear cartilage-matrix. At most parts of the section the cells have dropped out, but two or three are seen still *in situ*.

and there in the tendons themselves. It is employed to deepen cup-shaped articular surfaces; and in the case of the interarticular cartilages, such as those of the knee and lower jaw, to allow greater freedom of movement whilst diminishing the liability to dislocation. Under the microscope white fibro-cartilage looks very like fibrous tissue, but its cells are cartilage-cells, not tendon-cells (figs. 150, 151). They are rounded or bluntly angular and surrounded by a concentrically striated area of non-fibrous cartilage-matrix. In some parts of the intervertebral disk some of the cells are branched; these may perhaps be looked upon as transitional forms to connective-tissue corpuscles.

HISTOGENESIS OF CARTILAGE.

Cartilage is formed in the embryo from mesenchyme similar to that which gives origin to other forms of connective tissue. Each cell forms a capsule

around itself; the blended capsules compose the first matrix. Cartilage sometimes remains in this condition throughout life; it is then termed

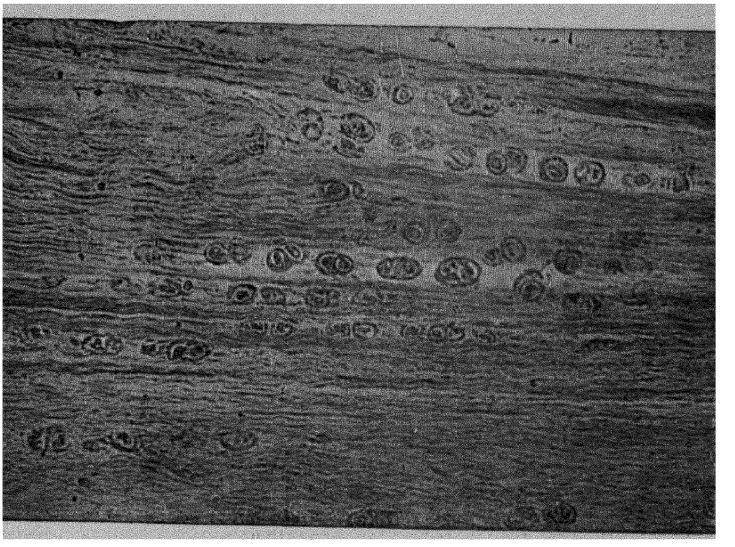

FIG. 150.—SECTION OF WHITE FIBRO-CARTILAGE. (E. Sharpey-Schafer.) × 200. Photograph.

The ground-substance is pervaded by wavy connective-tissue fibres.

parenchymatous cartilage. This can be seen in the mouse's ear, where also the cartilage-cells become filled with fat. Cartilage at first grows partly by interstitial expansion accompanied by cell multiplication and by formation, around and between the cells, of intercellular substance, partly by apposition

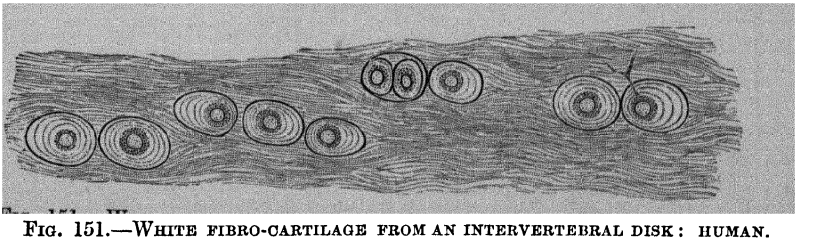

FIG. 151.—WHITE FIBRO-CARTILAGE FROM AN INTERVERTEBRAL DISK: HUMAN. (E. Sharpey-Schafer.) Highly magnified.

The concentric lines around the cells indicate the limits of deposit of successive capsules. One of the cells has a forked process which extends amongst the fibres of the general matrix beyond the hyaline area surrounding the cell.

at the perichondrium, the connective tissue becoming here transformed into cartilage. At a later period of growth the increase in size and change in shape of cartilages are due almost entirely to the agency of the perichondrium. This is inevitably the case if the matrix becomes calcified.

Embryonic cartilage is usually characterised by the cells being more sharply angular and irregular; in some cases they are branched, like those

which occur at the junction of cartilage and synovial membrane in the adult. The cells are also more closely packed, the matrix being in relatively less amount than in later life.

Fibro-cartilage is developed at first in exactly the same manner as hyaline cartilage, but at a certain stage connective-tissue fibres, either elastic or white, become formed in the ground-substance or matrix, and as they accumulate they impart their distinctive character to the tissue. The development of elastic fibres is preceded by the deposition of granules of elastin in the matrix: these run together to form fibres, as in the development of elastic tissue elsewhere (see p. 113).

In some parts where white fibro-cartilage is found the tissue is at first entirely fibrous, like tendon or ligament, and the cartilage is a secondary formation. In such cases the cartilage-cells are formed by direct transformation from the tendon-cells.

The formation of cartilage in cultures of undifferentiated mesoderm cells from the limbs of early chick embryos has been studied by Miss H. B. Fell, who has shown that, even *in vitro*, true bone may eventually be developed in connexion with the cartilage nodules which make their appearance in such cultures.

LESSON XIII.

BONE.

1. In thin sections of hard bone made by grinding,[1] observe the Haversian canals, lamellæ, lacunæ, canaliculi, etc. Make sketches under low and high powers.

2. With fine forceps strip off a thin shred from the superficial layers of a macerated bone which has been decalcified in commercial sulphurous acid solution and afterwards washed with water for 24 hours. (The decalcified bone may be kept in 33 per cent. alcohol.) Mount the shred in water. Observe the fibrous structure of the lamellæ. Look for perforating fibres or the holes from which they have been dragged out. Sketch a small piece of the thin edge of a lamella.

3. Stain successively with dilute acid fuchsin and hæmatoxylin solution, or with hæmatoxylin and eosin, very thin sections of fresh compact bone which has been fixed with 10 per cent. formol (3 days) and then decalcified in sulphurous acid as above. Mount in dilute glycerine, cementing at once. Look for fibres of Sharpey piercing the circumferential lamellæ. The elastic perforating fibres are darkly stained by the acid fuchsin. Notice the nuclei of the bone-corpuscles in the lacunæ. In thin sections the blood-vessels and other structures in the Haversian canals may be made out.

Bone is a connective tissue in which the ground-substance is impregnated with salts of lime, chiefly phosphate, these salts constituting about two-thirds of the weight of the bone. When bones are macerated this earthy matter prevents the putrefaction of the animal matter. When bone is calcined it loses one-third of its weight, owing to the destruction of the animal matter; when bone is steeped in acid the earthy salts are dissolved and only the animal matter is left. This, like areolar and fibrous tissue, is converted into gelatine by boiling.

Bony tissue is either *compact* or *cancellated*. Compact bone is dense, almost like ivory; cancellated is spongy with obvious interstices. The outer layers of all bones are compact, and the inner part is generally cancellated, but the shaft of a long bone is almost entirely made up of compact substance, except in and near the middle, which is hollow and filled with marrow. The interstices of cancellated bone are also occupied by marrow. Externally bones are covered, except at the joints, by a vascular fibrous membrane, the *periosteum*.

True bone is always made up of *lamellæ*, and these again are composed of fine *fibres* lying in a *calcified ground-substance*. Between the lamellæ are branched cells, the *bone-cells*, which lie in *cell-spaces* or *lacunæ*. The ramified passages containing the cell-processes and uniting the lacunæ are termed *canaliculi*.

[1] Such a section should be purchased: it is difficult to make without a proper lathe.

In cancellated bone the blood-vessels run in the interstices of the bone, surrounded and supported by the marrow. In compact bone they are contained in canals—the *Haversian canals*—which everywhere pervade the bone. These canals average 50 μ ($\frac{1}{500}$ inch) in diameter; some are much smaller, others much larger than this. Their general direction is

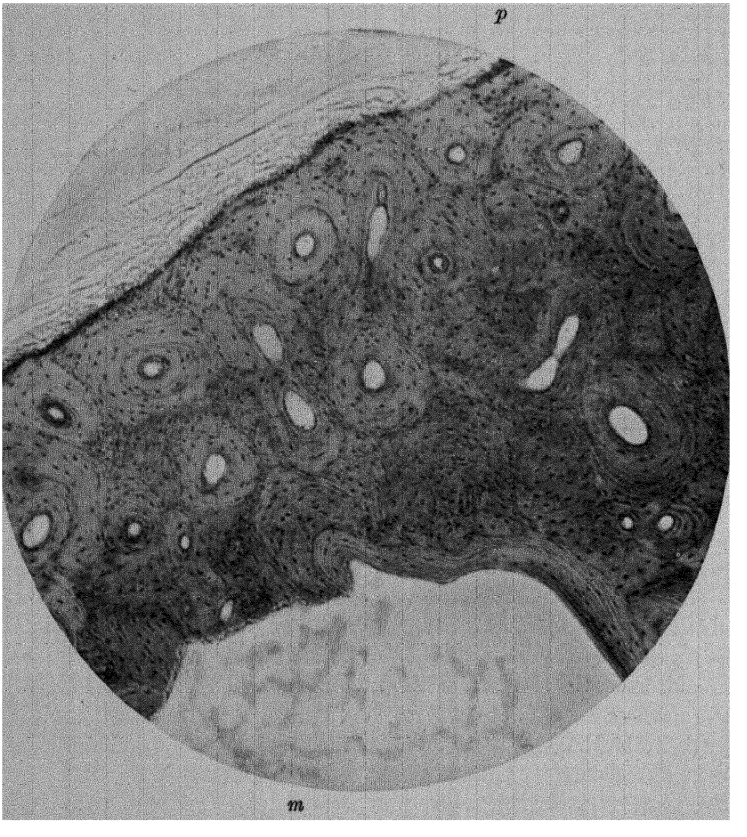

FIG. 152.—TRANSVERSE SECTION OF DECALCIFIED BONE: HUMAN FIBULA. (E. Sharpey-Schafer.) × 56. Photograph.
p, periosteum; *m*, marrow.

longitudinal, *i.e.* parallel with the long axis of the bone, but they are constantly united by transversely and obliquely running passages. In a section across the shaft of a long bone they are seen as small rounded or elongated holes (fig. 152). When the section has been made by grinding, the holes get filled with air and débris; the air causes them to look black by transmitted light (p. 31). This is also the case with the lacunæ and canaliculi (fig. 153).

Most of the lamellæ in compact bone are disposed concentrically around the Haversian canals; they are known as Haversian lamellæ, and with the included canals, form what are known as *Haversian systems*. The lacunæ of

a Haversian system communicate both with one another and with the Haversian canal which they encircle, but not as a rule with the lacunæ of adjacent Haversian systems. The angular interstices between the Haversian systems are generally occupied by bony substance which is not regularly lamellar (figs. 153, 154, *d*). Besides the concentric lamellæ of the Haversian systems there are other lamellæ both at the surface, immediately underneath the periosteum (fig. 152), and throughout the thickness of compact bone, between the Haversian systems (fig. 153, *c*, *c*, *c*), arranged parallel



FIG. 153.—PHOTOGRAPH OF TRANSVERSE SECTION OF COMPACT BONE, MADE BY GRINDING, SHOWING THREE HAVERSIAN CANALS WITH THEIR CONCENTRIC LAMELLÆ, AND ALSO INTER-HAVERSIAN BONY SUBSTANCE. (E. Sharpey-Schafer.) × 200. Photograph.

a, Haversian canal, filled with air and débris; *a'*, a very small canal; *b*, *b*, junctions of Haversian systems; *b'*, margin of Haversian system abutting on non-Haversian lamellæ; *c*, *c*, *c*, lamellæ parallel to periosteum; *d*, inter-Haversian bone with irregular lacunæ.

with the surface; these are known as *periosteal lamellæ*. They are pierced here and there by simple canals for blood-vessels, the so-called *Volkmann's canals*, which are proceeding from the periosteum to join the system of Haversian canals; and also by calcified bundles of white fibres and by elastic fibres prolonged from the periosteum. These are the *perforating fibres of Sharpey* (fig. 155) most of which represent the actual insertion of tendons and ligaments into the bone. They are only found in the periosteal lamellæ and, as may be understood from the above, do not occur everywhere in bone.

The lamellæ of bone are fibrous in structure. This may be seen in shreds torn off from the superficial layers of a decalcified bone. The fibres (*decussating fibres of Sharpey*) often cross one another in adjacent lamellæ,

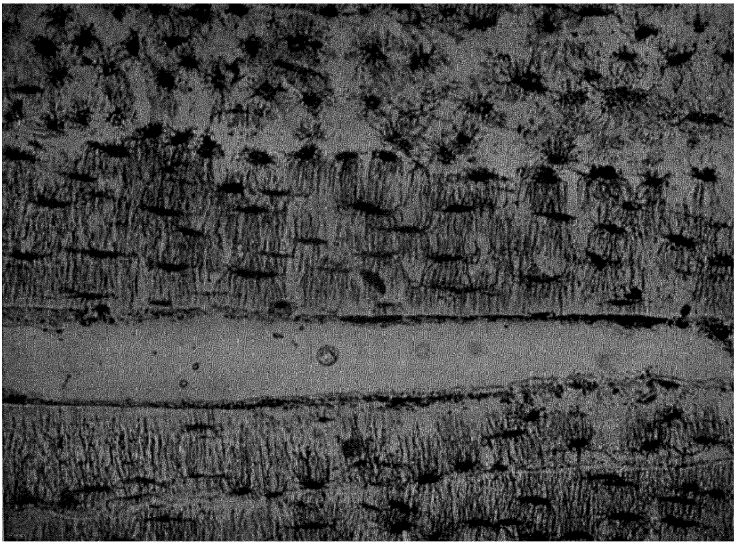

FIG. 154.—LONGITUDINAL SECTION OF COMPACT BONE, SHOWING HAVERSIAN SYSTEMS AND INTER-HAVERSIAN BONE. (E. Sharpey-Schafer.) × 200. Photograph.

a, Haversian canal cut longitudinally; *b*, junction of two Haversian systems of lamellæ; *c*, margin of Haversian system abutting upon inter-Haversian bone with irregular lacunæ, *d*.

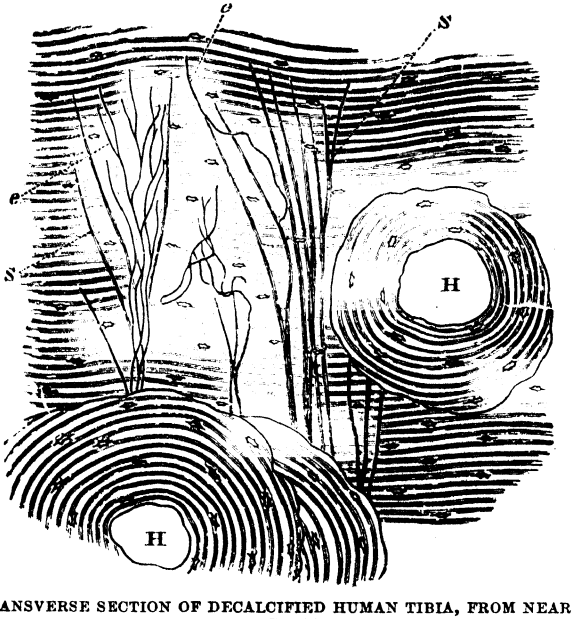

FIG. 155.—TRANSVERSE SECTION OF DECALCIFIED HUMAN TIBIA, FROM NEAR THE SURFACE OF THE SHAFT. (E. Sharpey-Schafer.)

H, H, Haversian canals, with their systems of concentric lamellæ; in all the rest of the figure the lamellæ are periosteal; *s*, *s*, ordinary perforating fibres of Sharpey; *e*, *e*, elastic perforating fibres. Drawn under a power of about 150 diameters.

and in the Haversian systems they run in some lamellæ concentrically, in others parallel with the Haversian canal. In shreds of lamellæ which have

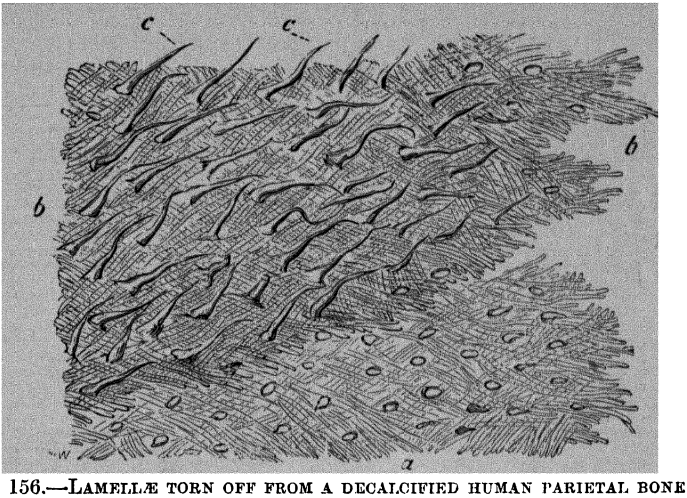

FIG. 156.—LAMELLÆ TORN OFF FROM A DECALCIFIED HUMAN PARIETAL BONE AT SOME DEPTH FROM THE SURFACE.

a, lamellæ, showing decussating fibres; *b*, *b*, thicker part, where several lamellæ are superposed; *c*, *c*, perforating fibres; the fibrils which compose them are not shown in the figure. Apertures through which perforating fibres had passed are seen, especially in the lower part, *a*, of the figure. Magnitude as seen under a power of 200 diameters, but not drawn to scale. (Sketched by Allen Thomson from a preparation by W. Sharpey.)

been peeled from the surface the perforating fibres may sometimes be seen projecting from the surface of the shred, having been torn out of the deeper lamellæ (fig. 156, *c*, *c*).

The lacunæ are occupied by nucleated corpuscles (*bone-cells*), which send branches along the canaliculi (fig. 157). Both lacunæ and canaliculi have a special lining which is different in chemical composition from the rest of the bone, being much more resistant to the action of strong chemical solvents such as hydrochloric acid (Neumann). The dentinal tubules of the teeth have a similar lining.

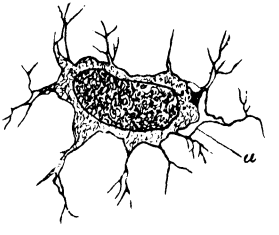

FIG. 157.—A BONE-CELL ISOLATED AND HIGHLY MAGNIFIED. (Joseph.)

a, proper wall of the lacuna (Neumann's layer), where the corpuscle has shrunk away from it.

Each Haversian canal contains one or two blood-vessels and nerves besides connective tissue (fig. 158); the larger ones may include a few marrow-cells. There are also cleft-like lymphatics running with the blood-vessels. The Volkmann canals have similar contents but the vessels are larger (fig. 159).

Nutrition and gaseous exchanges take place from and to the vessels in the Haversian canals by diffusion along the protoplasmic processes which connect adjacent bone cells to one another and to connective-tissue cells and blood-vessels in the canals.

The **periosteum** may be studied either in torn-off shreds, or in preparations treated *in situ* with silver nitrate, or in stained sections from an unmacerated bone which has been decalcified. It is a fibrous membrane composed of two layers, the inner of which contains many elastic fibres. In the outer

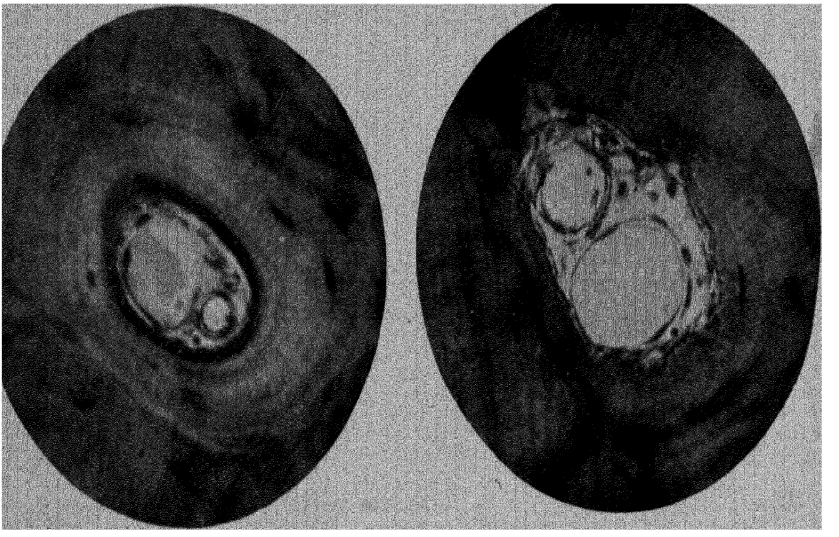

FIG. 158.—SECTION OF A HAVERSIAN CANAL WITH ITS CONTENTS. (E. Sharpey-Schafer.) × 300. Photograph.

Notice the concentric lamellæ of the Haversian system around the canal. The latest lamella to be formed is more darkly stained than the rest. Within the canal are seen the sections of two blood-vessels (arterial and venous), and of nerve-fibres: as well as a cleft-like lymph vessel.

FIG. 159.—SECTION OF A VOLKMANN CANAL WITH ITS CONTENTS. (E. Sharpey-Schafer.) × 300. Photograph.

There are no concentric lamellæ around this canal. The blood-vessels are larger and there is, besides these and nerve-fibres, a quantity of delicate connective tissue.

canals of the bone. The periosteum ministers to the nutrition of the bone, partly on account of the blood-vessels and lymphatics it contains, partly, especially in young animals, on account of the existence between it and the bone of a layer of *osteoblasts* or *bone-forming cells*, a remainder of those which originally produced the bone. It also serves to give attachment to muscular fibres.

The **marrow** of bone has been already considered (pp. 52 to 56).

LESSON XIV.

DEVELOPMENT OF BONE : OSSIFICATION.

1. MOUNT in dammar sections, longitudinal and transverse, of fœtal limbs which have been stained in bulk. The bones will be in different stages of ossification, those of the wrist or ankle and digits being least developed. Make sketches illustrating the three chief stages of endochondral ossification. Notice the peculiar terminal ossification of the third phalanx.

2. Mount in dammar sections of a fœtal lower jaw (membrane bone) which has been stained in bulk and embedded in paraffin.[1] Find the part where the lower jaw-bone is becoming ossified, and study the appearances it presents. The bone is prolonged in the form of osteogenic fibres which are covered with osteoblasts.

3. Intramembranous ossification may also be studied in the parietal bone of embryos preserved in Müller's fluid. A piece of the growing edge is scraped or brushed free from its investing membranes and from most of the cells which cover and conceal it, and is mounted in glycerine after previous staining with hæmatoxylin. But the tissue shows well without being stained.

True bone is formed in all cases by ossification of connective tissue. Sometimes the bone is preceded by cartilage, which first becomes calcified, and is then invaded, and for the most part removed, by vascular embryonic connective tissue which re-deposits bony matter in the interior of the cartilage. This is *cartilaginous* or *endochondral ossification*. At the same time layers of bone are being formed outside the cartilage by the periosteum. This is *membranous ossification*. The whole bone thus formed is termed a *cartilage-bone*. When bone is not preceded by cartilage, the only process which occurs is one corresponding to the periosteal ossification of a cartilage-bone; the ossification is then entirely membranous, and the bone formed is a *membrane-bone*.

By endochondral ossification are formed the majority of the bones, including those of the limbs and vertebral column. Membranous ossification supplies most of the bones of the skull, including all those of the face; also the clavicle. But, as will be apparent when the process of ossification has been described, bone which is originally formed in cartilage becomes largely replaced, as growth proceeds, by bone formed in connective tissue.

Ossification in cartilage.—This may be described as occurring in three stages.

In the *first stage* the cells in the middle of the cartilage become enlarged

[1] See Appendix for methods of staining in bulk. In place of this, sections may be stained by Mallory's method, which brings out the osteogenic fibres.

and arranged in rows radiating from the centre (fig. 160), and fine granules of calcareous matter are deposited here in the matrix. Simultaneously with this the cells (*osteoblasts*) underneath the periosteum deposit layers of fibrous

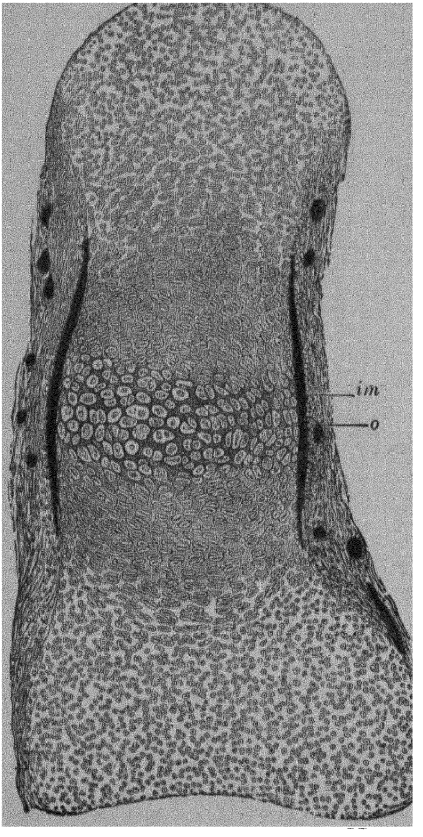

FIG. 160.—SECTION OF PHALANGEAL BONE OF HUMAN FŒTUS AT THE TIME OF COMMENCING OSSIFICATION. (E. Sharpey-Schafer.) × 75. Preparation by F. A. Dixey.

The cartilage-cells in the centre are enlarged and are separated from one another by stained calcified matrix; *im*, layer of bone deposited underneath the periosteum; *o*, layer of osteoblasts, by which the layer has been formed. Some of the osteoblasts are already embedded in the new bone as bone-cells within lacunæ. Above and below the calcified centre the cartilage-cells are flattened and arranged in rows. At the ends of the cartilage the cells are small and the groups are irregularly arranged. The fibrous periosteum is not sharply marked off from the cartilage.

material upon the surface of the cartilage; this material also becomes calcified (fig. 160, *im*). As the layers are formed, some of the osteoblasts (*o*) are included between them and become bone-corpuscles.

In the *second stage* vascular subperiosteal tissue eats its way through the newly formed layer of bone and into the centre of the calcified cartilage (fig. 161, *ir*). This is freely absorbed before it (figs. 161, 163), so that large spaces are produced which are occupied by embryonic connective tissue (fig. 163), including numerous osteoblasts and many sinus-like blood-vessels

which have grown in from those of the periosteum. The spaces are termed *marrow spaces*, and this second stage is known as the *stage of irruption*.

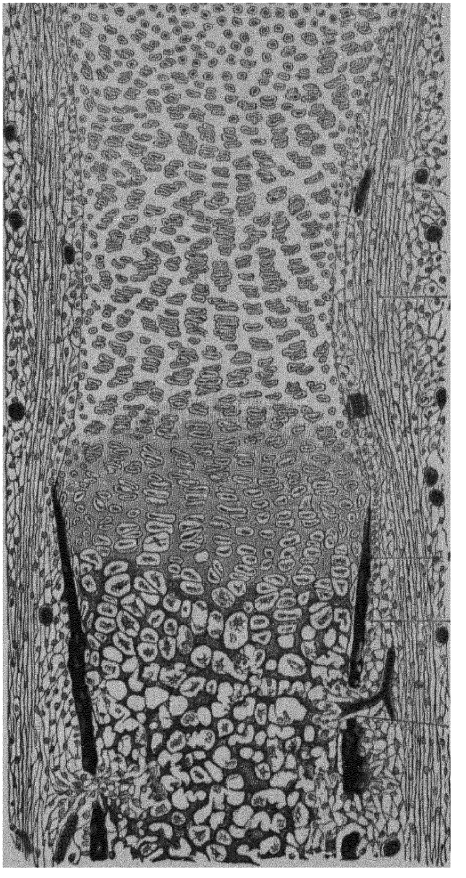

FIG. 161.—SECTION OF PART OF ONE OF THE LIMB-BONES OF A FŒTAL CAT, AT A MORE ADVANCED STAGE OF OSSIFICATION THAN THE BONE REPRESENTED IN FIG. 160, AND MORE HIGHLY MAGNIFIED. (E. Sharpey-Schafer.)

The calcification of the cartilage-matrix has advanced from the centre, and is extending between the groups of cartilage-cells, which are arranged in characteristic rows. The subperiosteal bony deposit (*im*) has extended *pari passu* with the calcification of the cartilage-matrix. The cartilage-cells in the calcified part are mostly shrunken and stellate; in some cases they have dropped out of the spaces. At *ir* and in two other places an irruption of the subperiosteal tissue has penetrated the subperiosteal bony crust, and has begun to excavate spaces in the calcified cartilage; *p*, fibrous layer of the periosteum; *o*, layer of osteoblasts: some of them are embedded in the osseous layer as bone-corpuscles in lacunæ. The blood-vessels are seen occupied by blood-corpuscles. Beyond the line of ossific advance the periosteum may be noticed to be incurved. This incurvation is gradually moved on, the cartilage expanding beyond it until the head of the bone is reached, when it forms the periosteal notch or groove represented in figs. 164 and 165.

In the *third stage* of endochondral ossification there is a gradual advance of the ossification towards the extremities of the cartilage, and at the same time a deposition of fresh bony layers on the walls or septa of the marrow spaces, and on the surface of the new bone under the periosteum (figs. 162,

166, 168). The advance into the cartilage always takes place by a repetition of the same changes, the cartilage-cells first enlarging and becoming arranged in rows, the matrix nearest the already formed osseous tissue becoming calcified, and then the calcified cartilage being excavated from behind by the

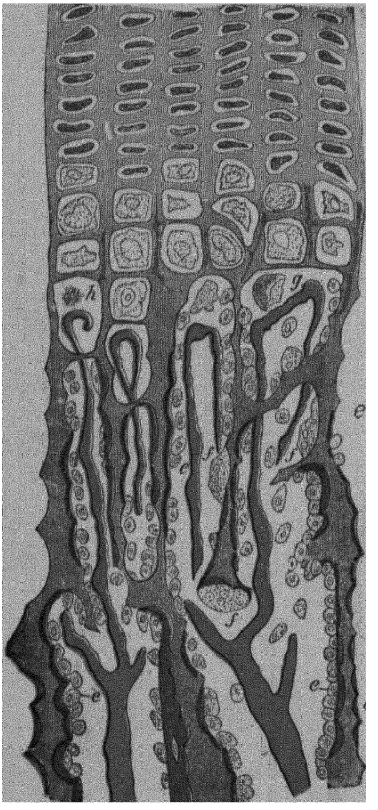

FIG. 162.—PART OF A LONGITUDINAL SECTION OF THE DEVELOPING FEMUR OF THE RABBIT. (Klein.) Drawn under a magnifying power of 350 diameters.

a, rows of flattened cartilage-cells; *b*, greatly enlarged cartilage-cells close to the advancing bone, the matrix between is partly calcified; *c*, *d*, already formed bone, the osseous trabeculæ being covered with osteoblasts (*e*) except here and there, where an osteoclast (*f*) is seen eroding parts of the trabeculæ; *g*, *h*, cartilage-cells which have become shrunken and irregular in shape. From the middle of the figure downwards the trabeculæ, which are formed of calcified cartilage-matrix, are becoming covered with secondary osseous substance deposited by the osteoblasts. The vascular loops at the extreme limit of the bone are well shown, as well as the atrophy and abrupt disappearance of the cartilage-cells.

invading vascular tissue so as to form new marrow spaces (fig. 162). The septa between these are at first formed only by remains of the calcified cartilage-matrix (fig. 162, *c*), but they soon become thickened by layers of fibrous bone deposited by the osteoblasts (figs. 168, 169), and between the layers bone-corpuscles become included, as in the case of the subperiosteal bone. The latter advances *pari passu* with the endochondral calcification, growing both in length and thickness: its growth is preceded by the forma-

tion of osteogenic fibres like those met with in developing membrane-bone (see fig. 174). Beyond the line of advance of ossification the uncalcified cartilage grows by expansion both in length and breadth, so that the ossification is always advancing into a larger mass of cartilage; hence the endochondral bone as it forms assumes the shape of an hour-glass, the shaft being maintained of a cylindrical shape by addition of periosteal bone to the

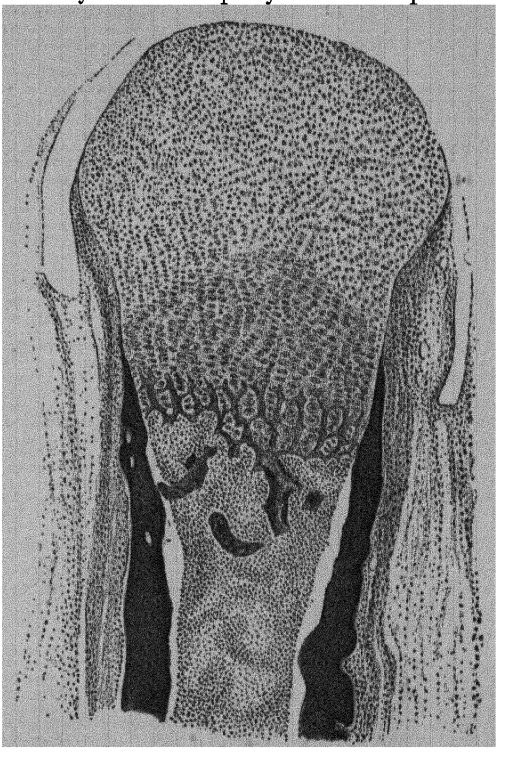

FIG. 163.—LONGITUDINAL SECTION THROUGH PART OF A PHALANX OF A SIX MONTHS' HUMAN EMBRYO. (Kölliker.)

The calcified cartilage is completely absorbed almost to the limit of advancing calcification. The osseous substance on either side is periosteal bone. The embryonic marrow has shrunk somewhat away from it in the process of fixation.

outside, this addition being of course always thickest in the middle of the shaft (see figs. 164, 167). The absorption of the calcified cartilage matrix appears largely to be effected, as is the case with absorption of bony matter wherever it occurs, by special cells (fig. 162, *f*, *f*) termed *osteoclasts*. In their fully formed typical condition these are multi-nucleated giant cells. They are found on surfaces where absorption of bone is taking place, whereas on surfaces where bony deposit is proceeding osteoblasts occur (fig. 170).

It would appear that osteoclasts are formed from osteoblasts, either by increase of size and multiplication of nuclei or by coalescence of several osteoblasts (H. B. Fell) (see fig. 7, p. 7), and that they afterwards break up into separate osteoblasts.

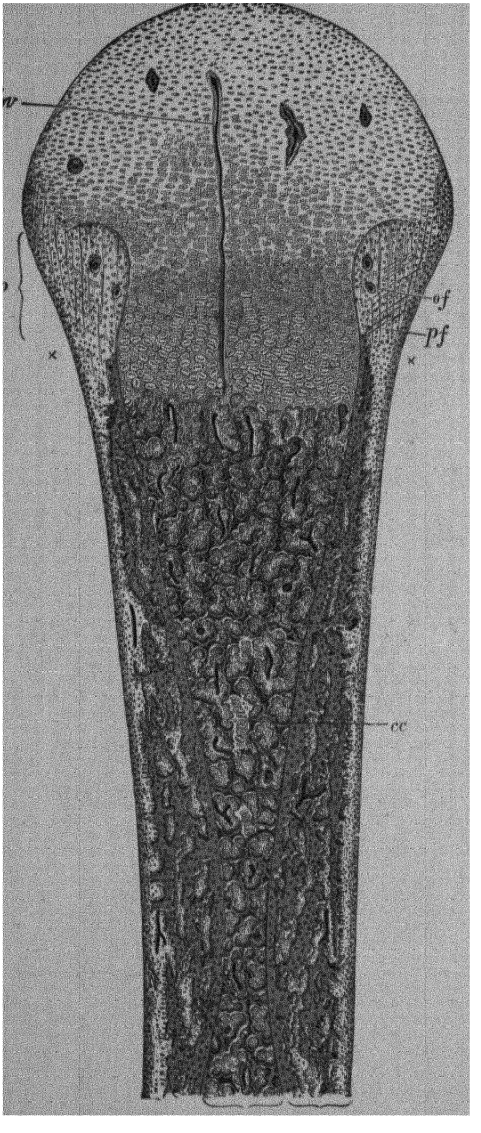

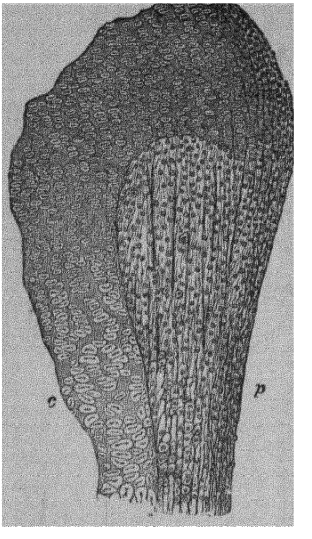

FIG. 165.—SECTION OF THE OSSIFICATION GROOVE IN THE HEAD OF A LONG BONE. (E. Sharpey-Schafer.)

c, cartilage; *p*, periosteal tissue with osteogenic fibres and osteoblasts. This tissue occupies the "groove."

FIG. 164.—LONGITUDINAL SECTION THROUGH THE UPPER HALF OF THE DECALCIFIED HUMERUS OF A FŒTAL SHEEP, AS SEEN UNDER A MAGNIFYING POWER OF ABOUT 30 DIAMETERS. (E. Sharpey-Schafer.)

c, the part of the shaft which was primarily ossified in cartilage; what remains of the primary bone is represented dark, enveloped by the clear secondary deposit. The spaces in the bone are occupied by embryonic marrow with osteoblasts, and blood-vessels variously cut. One long straight vessel (*bv*) passes in advance of the line of ossification far into the cartilaginous head, most of the others loop round close to the cartilage. At one or two places in the older parts of the bone elongated groups of cartilage-cells (*cc*) may still be seen, which have hitherto escaped absorption. *m*, the part of the bone that has been ossified in membrane, that is to say, in the osteoblastic tissue under the periosteum. It is well marked off from the central portion (*c*), and is bounded, peripherally, by a jagged edge, the projections of which are indistinctly seen to be prolonged by bunches of osteogenic fibres. A row of osteoblasts covers the superficial layer of the bone. The subperiosteal layer is prolonged above into the thickening (*p*) which encroaches upon the cartilage of the head of the bone, and in which are seen, amongst numerous osteoblasts and a few blood-vessels, straight longitudinal osteogenic fibres (*of*), and some other fibres (*pf*) crossing them, and perhaps representing fibres of Sharpey. Observe the general tendency of the osseous trabeculæ and the vascular channels between them to radiate from the original centre of ossification. This is found to prevail more or less in all bones when they are first formed, although the direction of the trabeculæ [illegible] cells become modified in relation to varying physiological conditions, and especially as the [illegible] ssure. (Figs. 160, 161, 164 and 165 were drawn by T. W. P. Lawrence.)

The bone which is first formed is less regularly lamellar than that of the adult, and contains no Haversian systems, but it has a distinctly fibrous

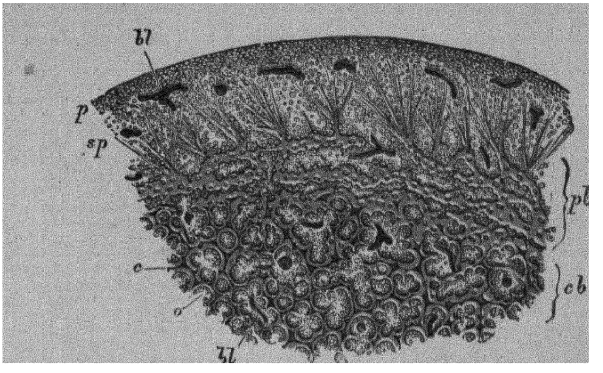

FIG. 166.—TRANSVERSE SECTION OF A DEVELOPING BONE SIMILAR TO THAT SHOWN IN FIG. 164, SHOWING THE PERIOSTEAL LAYER BECOMING FORMED FROM OSTEOGENIC FIBRES. (E. Sharpey-Schafer.)

cb, cartilage bone; *pb*, periosteal bone; *sp*, bone trabeculæ prolonged by osteogenic fibres; *p*, periosteum; *bl*, blood-vessels; *c*, remains of calcified cartilage; *o*, osteoblasts forming bone upon this.

structure (fig. 171). It often retains in the middle of the new bony trabeculæ angular patches of the original calcified cartilage matrix, which are

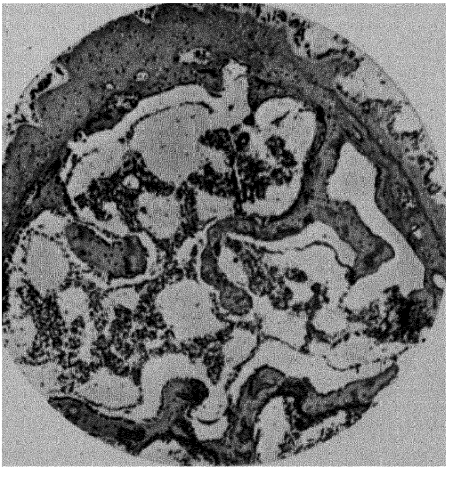

FIG. 167.—SECTION ACROSS LONG BONE OF HUMAN FŒTUS. (E. Sharpey-Schafer.) × 58. Photograph.

Note the periosteal bone outside, thickened at one place, and the irregular trabeculæ of endochondral bone. The spaces of this are occupied by marrow, with large thin-walled blood-vessels.

very evident in preparations stained with hæmatoxylin (figs. 168, 169, 171). The regular lamellæ are not deposited until some little time after birth; their deposition is generally preceded by a considerable amount of absorption, so that irregular spaces (Haversian spaces) (fig. 172) are at this time

formed in the interior of the original cartilage bone. It is about now also that the large marrow cavity of the long bones is formed by the absorption of the bony tissue which occupies the centre of the shaft.

After a time the cartilage in one or both ends of the long bones begins to ossify independently, and *epiphyses* are formed (fig. 173). These are

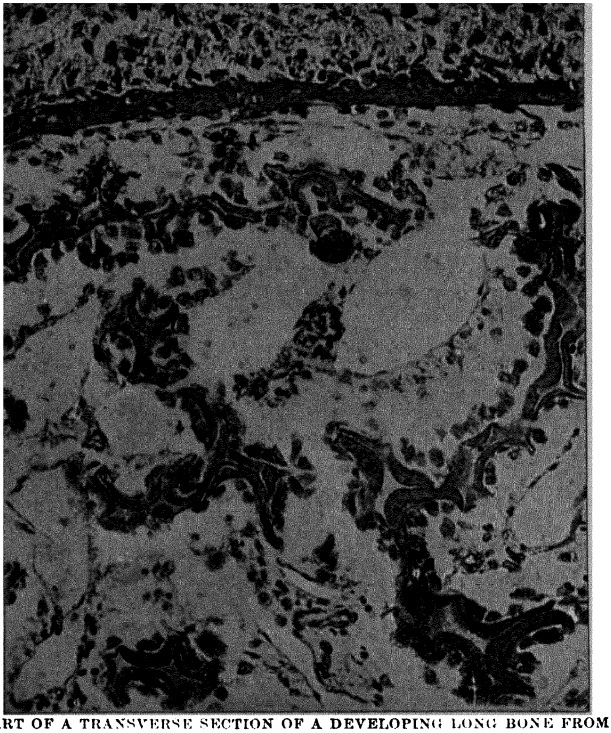

FIG. 168.—PART OF A TRANSVERSE SECTION OF A DEVELOPING LONG BONE FROM A HUMAN FŒTUS. (E. Sharpey-Schafer.) × 200. Photograph.

p, fœtal periosteum; *p'*, bone laid down in periosteum; *e*, endochondral bone composed of calcified cartilage in the centre of the septa and layers of true bone covering this; *m*, marrow spaces mainly filled with jelly-like embryonic connective tissue and large sinus-like blood-capillaries. Notice the osteoblasts on the surfaces of the newly formed bone—both periosteal and endochondral. Two or three osteoclasts can also be seen.

not joined to the shaft (*diaphysis*) until the growth of the bone is completed. Growth takes place *in length* by an expansion of the cartilage which intervenes between the shaft and the epiphyses (*intermediate cartilage*), the ossification gradually extending into it; *in width* entirely by the deposition of fresh bony layers under the periosteum. Once the epiphysial cartilages have become entirely transformed into bone, increase in length is no longer possible. But increase in thickness may occur at any time; even in the adult under abnormal circumstances, as, for example, in the affection known as *acromegaly*. In the terminal phalanges of the digits the ossification starts, not from the middle of the cartilage, but from its distal extremity.

For the regeneration of portions of bone which have been removed by disease or operation it is of some importance that the periosteum should be

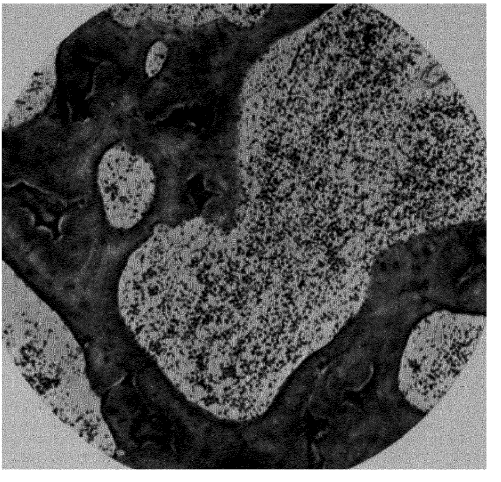

FIG. 169.—TRABECULÆ OF ENDOCHONDRAL BONE, FROM TIBIA OF ADVANCED HUMAN FŒTUS, WITH REMAINS OF CALCIFIED CARTILAGE IN PLACES. (E. Sharpey-Schafer.) Moderately magnified.

left, because a considerable amount of the blood-supply comes through the vessels of the periosteum, and there are also osteoblasts on its under surface. But fragments of bone may undergo regeneration even after removal of the periosteum, by the agency of osteoblasts in the marrow (McEwen).

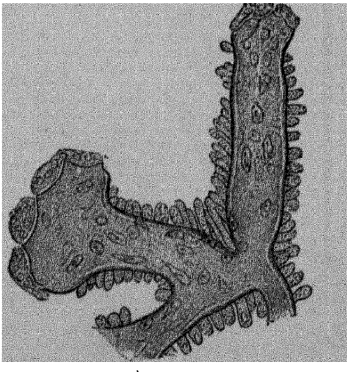

FIG. 170.—BONY TRABECULÆ FROM THE DEVELOPING LOWER JAW OF A CALF, SHOWING OSTEOCLASTS AT THE EXTREMITIES WHERE ABSORPTION IS PROCEEDING, AND OSTEOBLASTS COVERING THE SIDES WHERE DEPOSITION OF BONE IS GOING ON. (Kölliker.)

Membranous ossification.—In this variety of ossification (figs. 174, 175) the bone is not preceded by cartilage at all, and therefore no endochondral bone is formed, but the calcification occurs in an embryonic connective tissue which contains numerous osteoblasts and blood-vessels. The fibres of this tissue (*osteogenic fibres*) are collected into fine bundles, and become enclosed in a calcareous matrix, produced by the deposition of lime salts in the ground-substance of the connective tissue; as the fibres grow, the calcification extends radially from the original centre, bony spicules being formed, which become thickened and run together to form reticulated layers,

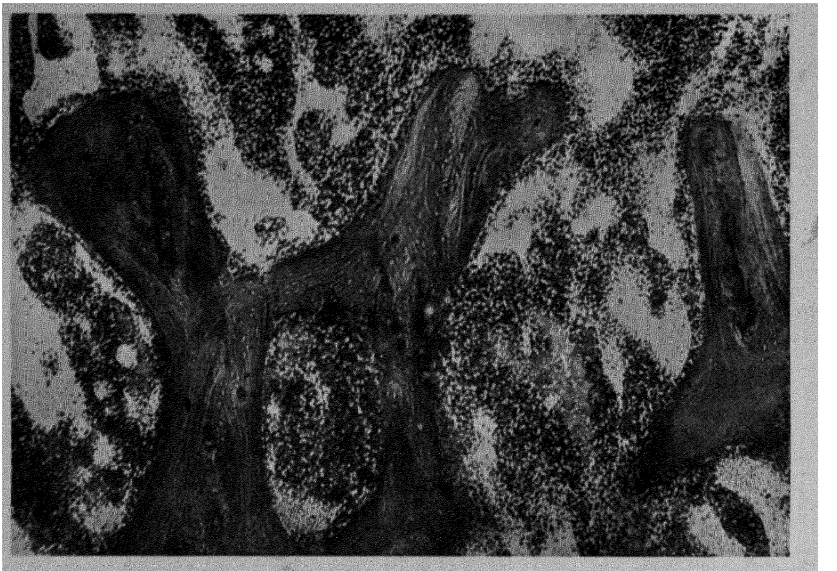

IG. 171.—ENDOCHONDRAL BONE FROM TIBIA OF CHILD ONE YEAR OLD, SHOWING FIBROUS STRUCTURE. (E. Sharpey-Schafer.) × 50. Photograph.

few fat-cells have begun to make their appearance in the marrow. Note the large irregular blood-channels. Also the remains of calcified cartilage in the trabeculæ.

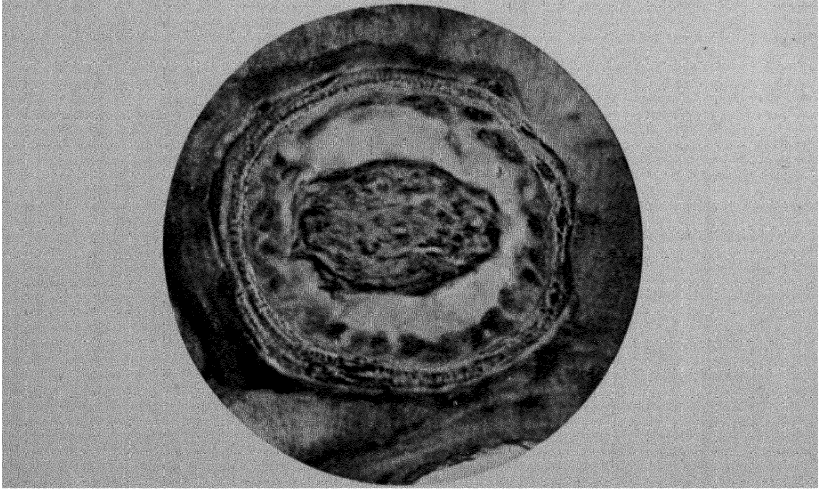

FIG. 172.—HAVERSIAN SPACE BECOMING CONVERTED INTO A HAVERSIAN SYSTEM BY DEPOSITION OF CONCENTRIC LAMELLÆ ON ITS WALLS. (E. Sharpey-Schafer.) × 210.

The photograph is from a fibula (human) at a moderately advanced stage. Most of the contents of the space are separated by a clear space from the wall of the canal, but the layer of osteoblasts is seen to be adherent to the wall. Two or three layers of fibrous bony lamellæ have been deposited—the fibres appearing in sections in the alternate layers as fine points. Some of the osteoblasts are already enclosed between the new lamellæ.

leaving spaces filled with jelly-like connective tissue containing osteoblasts surrounding blood-vessels. The osteogenic fibres are covered with osteoblasts, and as bone is deposited, some of the osteoblasts become left as

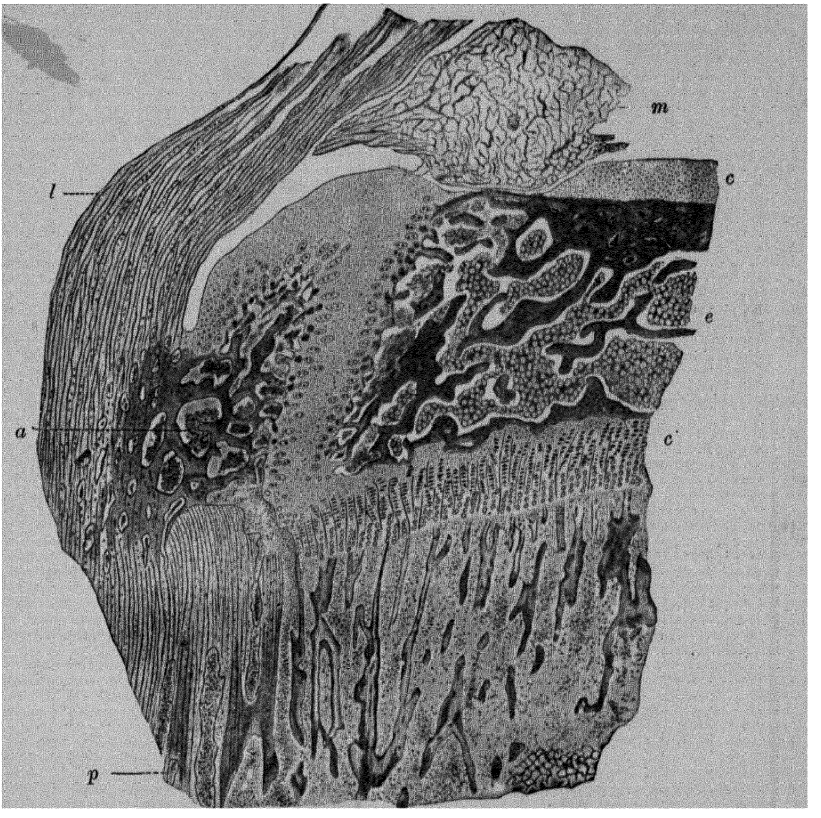

FIG. 173.—SECTION THROUGH UPPER END OF TIBIA OF A HALF-GROWN RABBIT. (A. Bidder.) Drawn under a magnifying power of 30 diameters.
a, apophysis; *e*, epiphysis; *d*, diaphysis; *l*, ligamentum patellæ; *c*, cartilage of articular surface; *c'*, intermediate cartilage; *p*, periosteum, with periosteal bone; *m*, pad of synovial membrane.

bone-cells within lacunæ. Thus in every particular the development of the membrane-bones resembles that of the subperiosteal layer of endochondral bone; which is, in fact, membranous ossification taking place on the surface of cartilage in and underneath the perichondrium, itself a connective-tissue membrane. Moreover, it is the same subperiosteal tissue which, in endochondral ossification, invades the calcified cartilage and, after causing the absorption of marrow spaces within this, deposits true or secondary bone upon those parts of the calcified cartilage-matrix which have escaped absorption; this secondary bone must also, therefore, be reckoned as developed according to the same type. In fact, even in so-called ossification of cartilage, very little of the calcified cartilage-matrix eventually remains, for this is

almost wholly absorbed; being replaced by true fibrous bone which has been formed by osteoblasts, or being entirely swept away to form the marrow cavity and other spaces in the bones.

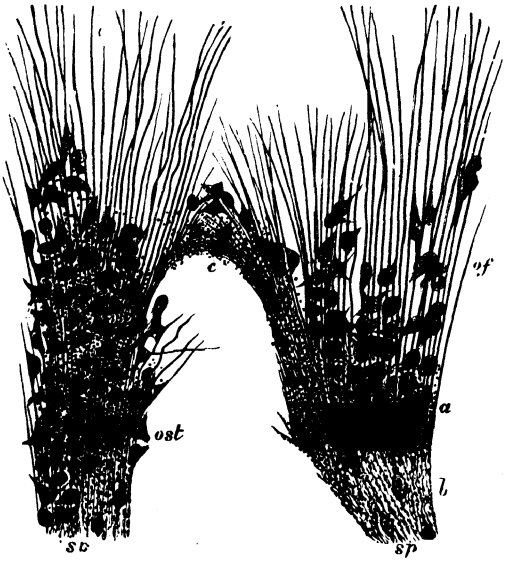

FIG. 174.—PART OF THE GROWING EDGE OF THE DEVELOPING PARIETAL BONE OF A FŒTAL CAT. (E. Sharpey-Schafer.) × 230.

sp, bone spicules, with some of the osteoblasts embedded in them, producing the lacunæ; *of*, osteogenic fibres prolonging the spicules, with osteoblasts (*ost*) between them and applied to them; *a*, granular calcific deposit occurring in the ground-substance between the fibres; *c*, calcareous deposit joining two adjacent spicules.



FIG. 175.—FROM A SECTION OF DEVELOPING LOWER JAW (MEMBRANE BONE) FROM A HUMAN FŒTUS OF 8½ MONTHS. (E. Sharpey-Schafer.) × 230. Photograph.

Note the osteoblasts [illegible] bone-cells in the already formed bone, and the osteogenic fibres prolonging the newly formed bone into the adjacent tissue.

LESSON XV.

MUSCLE.

1. TAKE a shred of white muscle from a recently killed rabbit, and on a dry slide carefully separate long pieces of muscle (single fibres if possible) and stretch them out, keeping them moist during the process by breathing on the slide. A drop of serum or mammalian Ringer must be ready on the cover-glass, which is then quickly inverted over the preparation. Study first with a low, then with a high power. Sketch all the appearances seen in a small piece of a fibre, focusing carefully the most superficial layers. Then allow a little dilute acetic acid to run under the cover-glass and watch its effect. Notice the oval nuclei immediately under the sarcolemma. The acid may be followed by dilute hæmatoxylin, and the preparation mounted in glycerine by adding a small drop of this at one edge of the cover-glass.

2. Repeat with a portion of red muscle.

3. Prepare frog's muscle in the same way, mounting in frog-Ringer. Notice the muscular substance shrinking away here and there from the sarcolemma, which then becomes distinctly visible. Sketch a piece of sarcolemma bridging across an interval thus produced. The preparation can be stained and mounted in glycerine like the last.

4. Study stained longitudinal and transverse sections of muscle which have been hardened in 90 per cent. alcohol or 10 per cent. formol. The sections are stained with hæmatoxylin and mounted in dammar. Examine them first with a low and then with a high power. Sketch the appearances which are seen. Measure the diameter of some of the fibres. Sections of muscle-spindles should be looked for.

5. Tease in dilute glycerine a small shred of alcohol-fixed muscle (crab) which has been stretched upon a cork. Cover and examine with a high power.

6. Cut off the head of a garden beetle or wasp, and bisect the trunk longitudinally so as to expose the interior. Notice two kinds of muscular tissue, the one belonging to the legs greyish in colour, the other attached to the wings yellowish. Preparations of both kinds of muscle are to be made in the same way as living mammalian muscle (§ 1). Mount them in a small drop of white of egg. In both preparations the dark-looking air-tubes or tracheæ form prominent objects ramifying amongst the fibres. Observe the structure of the two kinds of muscle so far as it can be seen in the fresh preparation. If made quickly, waves of contraction may be observed passing along the fibres.

7. Make another preparation of the leg-muscles, mounting in dilute acetic acid. Alcohol-hardened muscle of insect or crab may also be used for this purpose. Notice that the muscular substance swells and becomes clearer, whilst the sarcoplasm-network, with its appearance of lines and dots, comes more distinctly into view. In a well-teased preparation made in acid, the fibres are frequently found breaking across into disks. Make careful drawings from this preparation.

8. Rollett's method. Cut off the head of an insect (wasp, small beetle), bisect the trunk and place in 90 per cent. alcohol for 24 hours. Then take a small piece of each kind of muscle, and place in strong glycerine overnight. Wash thoroughly with water and transfer to 1 per cent. chloride of gold solution: leave the pieces of muscle in this from 15 to 30 minutes according to size. From the gold solution

they are transferred to formic acid (1 part of the strong acid to 3 of water), and kept in the dark for 24 hours; but they may be kept longer without disadvantage. The muscle is then teased in glycerine. Some of the fibres will be found after this process to have their sarcoplasm darkly stained, and to show the appearance of a network both in longitudinal and transverse view: others, on the other hand, have the sarcous elements of the fibrils or sarcostyles stained, whilst the sarcoplasm has remained colourless. This preparation is especially designed to show the structure of the fibrils of the wing-muscles. The staining is uncertain, but when successful is unsurpassed by any other method.

9. The structure of the fibrils can also be studied in longitudinal sections of wing-muscles fixed with alcohol and stained by the iron-hæmatoxylin method (see Appendix). This does not give as good a result as a successful Rollett preparation.

CROSS-STRIATED, VOLUNTARY, OR SKELETAL MUSCLE.

Cross-striated muscle is composed of long cylindrical fibres, measuring on an average 50 μ ($\frac{1}{500}$ inch) in diameter in mammals, and often having a



FIG. 176.



FIG. 177.



FIG. 178.

FIG. 176.—SARCOLEMMA OF MAMMALIAN MUSCLE. (E. Sharpey-Schafer.) Highly magnified.

The fibre is represented at a place where the muscular substance has become ruptured and has shrunk away, leaving the sarcolemma (with a nucleus adhering to it) clear. The fibre has been treated with serum acidulated with acetic acid.

FIG. 177.—MUSCULAR FIBRE OF A MAMMAL EXAMINED FRESH IN SERUM, THE SURFACE OF THE FIBRE BEING ACCURATELY FOCUSED. (E. Sharpey-Schafer.) Highly magnified.

The nuclei are seen on the flat at the surface of the fibre, and in profile towards the edge.

FIG. 178.—PORTION OF A MEDIUM-SIZED HUMAN MUSCULAR FIBRE, SHOWING THE INTERMEDIATE LINE (DOBIE'S LINE) MENTIONED IN THE TEXT. (W. Sharpey.)

length of an inch or more. But many fibres are much larger or smaller than the average. Each fibre has an extensible sheath, the *sarcolemma*, which encloses the contractile substance. The sarcolemma is seldom visible, unless

the contained subs[redacted]comes broken (fig. 176). A fibrillar structure has been described in the sarcolemma, but under ordinary circumstances it appears completely homogeneous.

The contractile substance is characterised by the alternate dark and light stripes which run across the length of the fibre (fig. 177); hence the term cross-striated. On focusing, it can be seen that the stripes pass through the whole thickness of the fibre; they have therefore been looked upon as representing alternate disks of dark and light substance. If the fibre is very carefully focused, rows of apparent granules (dots) are seen lying in or at the



FIG. 179.



FIG. 180.



FIG. 181.

FIG. 179.—SMALL PORTION OF A HUMAN MUSCULAR FIBRE TEASED INTO SMALL LONGITUDINAL FRAGMENTS. (Sharpey.) Magnified about 800 diameters.

a, *b*, *c*, larger and smaller groups of fibrils; *d*, ultimate fibrils.

FIG 180.—SMALL PORTION OF A MUSCLE-FIBRE OF CRAB SPLITTING UP INTO FIBRILS. (E. Sharpey-Schafer.) Magnified 600 diameters. From a photograph.

FIG. 181.—SECTION OF A MUSCULAR FIBRE, SHOWING AREAS OF COHNHEIM. (E. Sharpey-Schafer.)

Three nuclei are seen lying close to the sarcolemma.

boundaries of the light streaks, and very fine longitudinal lines may, with a good microscope, be detected uniting the dots (fig. 177). These fine lines, with their enlargements the dots, are conspicuous in the muscles of arthropods (figs. 186, 187). They indicate an interstitial material between the longitudinal elements (*fibrils* or *sarcostyles*) which compose the fibre. In preparations treated with dilute acid the material appears to form a fine network, which pervades the muscle-substance (fig. 188, B). This network, which is sometimes very distinct in preparations of muscle treated with chloride of gold, is, however, a network in appearance only: in reality it is the optical expression of the interstitial substance which lies between the fibrils. This substance is termed *sarcoplasm.*

Nuclei.—Besides sarcolemma and striated substance, a muscle-fibre possesses a number of oval nuclei which have the usual structure of cell-nuclei; they often show spiral markings. Sometimes there is a little



FIG. 182.—FIBRES OF WHITE MUSCLE OF RABBIT SHOWING THE NUCLEI. (E. Sharpey-Schafer.) × 435. Preparation by May L. Cameron.

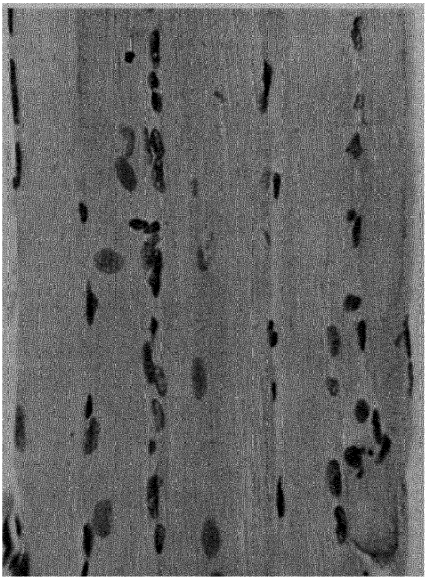

FIG. 183.—FIBRES OF RED MUSCLE (SEMITENDINOSUS) OF RABBIT SHOWING THE NUCLEI. (E. Sharpey-Schafer.) × 435. Preparation by May L. Cameron.

granular substance (protoplasm) at each pole of the nucleus; each nucleus with the adjacent protoplasm has then been spoken of as a *muscle-corpuscle*. But the protoplasm which is adjacent to the nuclei is continuous with the sarcoplasm between the fibrils; both being remains of part of the original protoplasm of the cells from which the muscular fibres are developed. In mammalian muscle the nuclei are usually immediately under the sarcolemma (figs. 181 to 185), in a frog's muscle they are scattered throughout its thickness, in the leg-muscles of insects they lie in the middle of the fibre (fig. 188, A).

Red muscles.—In most mammals all the striated muscles have the deep red colour characteristic of the 'flesh' of animals. In the frog all the muscles are pale in colour. In the rabbit the muscles of the ordinary type of structure are pale in

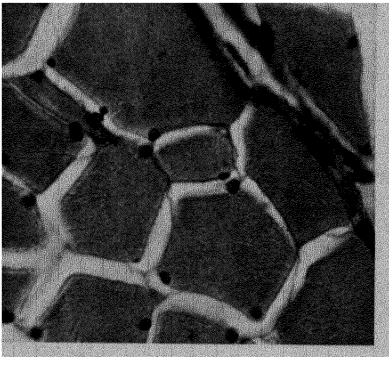

FIG. 184.—FIBRES OF WHITE MUSCLE OF RABBIT IN TRANSVERSE SECTION. (E. Sharpey-Schafer.) × 435. Preparation by May L. Cameron.

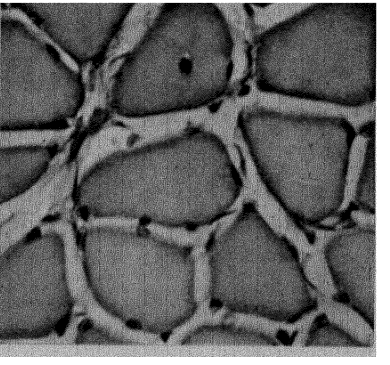

FIG. 185.—FIBRES OF RED MUSCLES OF RABBIT IN TRANSVERSE SECTION. (E. Sharpey-Schafer.) × 435. Preparation by May L. Cameron.

colour, but there occur others of a deep red colour. The fibres of this 'red' muscle usually contain more granular sarcoplasm than the ordinary fibres; their blood-vessels have a peculiarity of structure which will be afterwards noticed. They have many more nuclei than the ordinary fibres (figs. 182 to 185) and occasionally there are nuclei in the substance of the fibre as well as under the sarcolemma; but this is not common, nor is it entirely confined to fibres of the 'red' muscles. The 'red' fibres contract more slowly than the ordinary muscles.

In muscles which are in constant activity, such as the diaphragm and the dorsal fin-muscles of Hippocampus, the protoplasm (sarcoplasm) of the fibre is present in relatively large proportion; this is also true for the wing-muscles of insects (see p. 151).

The transverse section of a muscle shows the fibres to be nearly cylindrical in figure (fig. 181), but in places where they are closely set (figs. 184, 185) they may be angular in section. Between the fibres is a certain amount of areolar tissue, which serves to support the blood-vessels and to unite the fibres into fasciculi; the fasciculi again are united by a larger amount of this intra-muscular connective tissue, known as the *endomysium*.

On examining the cross-section of a fibre with a high power, it may be

seen subdivided everywhere into small angular fields, *Cohnheim's areas* (fig. 181), which are themselves finely dotted. The dots represent sections of the fibrils of which the fibres are composed, and into which they may be split after death (figs. 179, 180), especially after being hardened in certain reagents, such as alcohol, chromic acid or osmic acid. The areas represent groups of fibrils, and are usually polyhedral, but they may be elongated; in some kinds of muscle, but not in mammals, they are disposed radially, and occasionally concentrically with the circumference of the section. The interstitial substance or sarcoplasm lies between the fibrils and can be made visible by treatment with dilute acid or by staining with chloride of gold (figs. 187, 188, B). It is sometimes in relatively large amount and then usually contains granules, but in most muscular fibres is reduced to a very fine interstitium.

An ill-defined clear line is sometimes seen running transversely across the fibre in the middle of each dark band. This is termed *Hensen's line.*

If instead of focusing the surface of the fibre it is observed in its depth, an appearance different from that shown in fig. 177 is frequently visible, namely, a fine dotted line (*Dobie's line*), bisecting each clear stripe (fig. 178). This appearance is often considered to represent a membrane (*Krause's membrane*), which subdivides the fibrils at regular intervals (see p. 152). But the membranes of the individual fibrils or sarcostyles are rarely, if ever, visible in an intact mammalian fibre, and it is certain that the appearance known as Dobie's line in the middle of the clear stripe of the intact fibre is due to interference, caused by the light being transmitted between disks of different refrangibility.

Haycraft suggested that the cross-striation of voluntary muscle is due to refractive effects produced by varicosity of the component fibrils; he based his view upon the fact that in impressions of the fibres made on soft collodion all the cross-striations which are observed in the fibre itself are reproduced. There is no doubt that a well-marked cross-striated appearance can be produced in homogeneous fibrils by regularly occurring varicosities, and some of the appearances observed in muscle may, as Haycraft contended, be referred to this cause. But even when a fibre or fibril is stretched so that it exhibits no varicosities, the cross-striations are still perfectly distinct. Moreover, in view of the entirely different manner in which the substances of the dark and clear stripes behave to many staining reagents, and especially to chloride of gold when applied as directed in § 8, the fact being that very definite structural appearances can under these circumstances be made out, the homogeneity of the muscle-fibril cannot be admitted. This inference is confirmed by the microchemical work of A. B. Macallum, who has shown that the potassium salts of the wing-muscle fibrils are accumulated in a portion only (the sarcous elements) of the fibril (fig. 193).

Muscles of insects.—In the muscles of insects (and crustaceans) the stripes are relatively broad, and the structure can be more readily made out than in mammals. In the living fibres from the muscles which move the legs of insects, the sarcoplasm presents a striking appearance of fine longitudinal lines traversing the muscle, and enlarging within the light stripes into rows of dots (figs. 186). This is also seen in fibres and portions of fibres which have been treated with acid. In separated disks, produced by the

breaking across of muscle-fibres, the surfaces of the disks show a network: with polyhedral meshes in some insects (fig. 188, B); formed of lines radiating from the centre of the fibre in others.

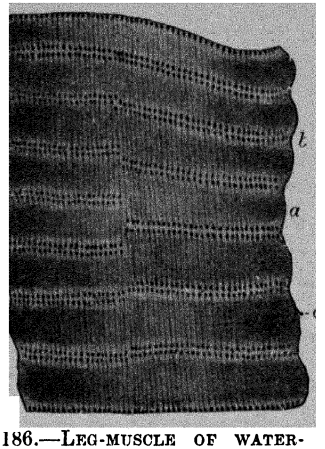

FIG. 186.—LEG-MUSCLE OF WATER-BEETLE IN LIVING CONDITION. (E. Sharpey-Schafer.) Highly magnified.

a, dim stripe; *b*, bright stripe; *c*, fine lines, with dot-like enlargements upon them which represent the interfibrillar sarcoplasm.

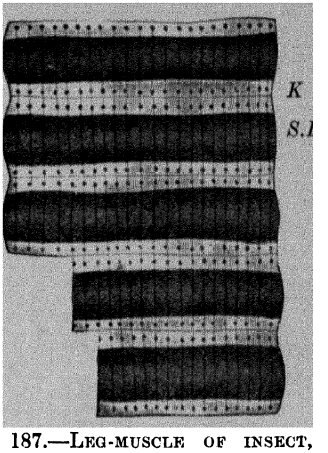

FIG. 187.—LEG-MUSCLE OF INSECT, STAINED WITH GOLD CHLORIDE BY ROLLETT'S METHOD. (E. Sharpey-Schafer.)

K, line formed by membranes of Krause; *S.E.*, dark stripe formed by sarcous elements. The sarcoplasm has the appearance of longitudinal lines with dots.

The muscular fibres of the wings of insects are considerably larger than those of the legs and contain a far greater amount of sarcoplasm, in which the fibrils are embedded. Hence, when a wing-fibre is broken up its fibrils

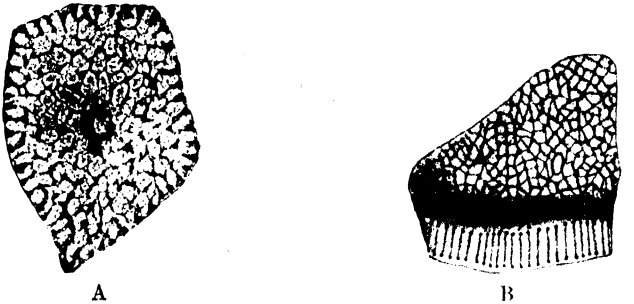

FIG. 188.—LEG-MUSCLE FIBRES OF INSECT IN TRANSVERSE SECTION. (E. Sharpey-Schafer.)

A shows the sarcostyles (fibrils) cut across; they are separated by sarcoplasm, of which there is an accumulation in the centre with a nucleus. Notice the mottled appearance of the sarcostyles, indicating a porous structure. Very highly magnified. From a photograph.

B, portion of a leg-muscle fibre, separated off as a disk after treatment with dilute acetic acid. Note the lines of sarcoplasm in longitudinal view and the network in surface view.

are easily isolated, even in the fresh tissue (figs. 189, 190). It can then be seen even in the living muscle, but much more distinctly after fixation and staining, that each fibril or sarcostyle is composed of alternating dark and light

portions, which by juxtaposition in adjacent fibrils produce the cross-striated appearance of the fibre. Further, in the middle of each of the clear striæ is a transverse septum, known as the *membrane of Krause*; by these membranes the fibril is subdivided at regular intervals into serial portions, termed *sarcomeres*. The middle of each sarcomere is occupied by a *sarcous*

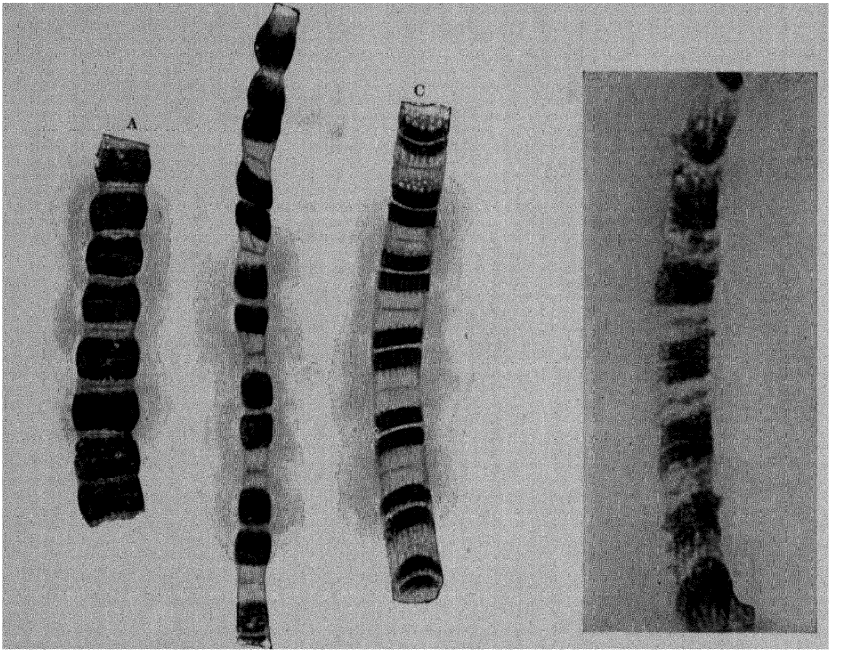

FIG. 189.—FIBRILS (SARCOSTYLES) OF THE WING-MUSCLES OF A WASP, PREPARED BY ROLLETT'S METHOD. (E. Sharpey-Schafer.) × 2000.

A, a contracted fibril. B, a contracted fibril which has been forcibly stretched, causing each sarcous element to be separated into two parts at the line of Hensen. C, an uncontracted fibril, showing the porous structure of the sarcous elements.

FIG. 190.—A FIBRIL (SARCOSTYLE) OF WING-MUSCLE OF WASP, STAINED BY ROLLETT'S METHOD. (E. Sharpey-Schafer.) × 2000. Untouched photograph.

element; the sarcous elements by their juxtaposition in adjacent fibrils form the dark striæ of the fibre.

The sarcous element is really double, as is shown by the fact that in the stretched fibril it separates into two (*line of Hensen*) (fig. 189, B). At each end of the sarcous element is clear substance (probably watery fluid) separating it from the membrane of Krause: this clear substance is more evident the more the fibril is extended, but diminishes, even to complete disappearance, in the retracted (contracted) fibril (fig. 189, A). The cause of this change is explained if we study more minutely the structure of the sarcous element. For it can be shown that each sarcous element is pervaded by longitudinal canals or pores, which are open in the direction of Krause's

mbranes, but closed at the middle of the sarcous element (figs. 189, 191, 192). In the contracted muscle it can be seen that the clear part of the muscle-substance has nearly disappeared, the sarcous element is swollen and the sarcomere is shortened; in the uncontracted muscle, on the other hand, the clear part occupies a considerable interval between the sarcous element and the membrane of Krause, the sarcomere being lengthened and narrowed. The sarcous element does not lie free in the middle of the sarcomere, but is attached at either end to Krause's membrane by what look like very fine lines, which may represent septa, running through the clear substance (fig. 190); on the other hand, Krause's membrane is attached laterally to a fine membrane which limits the fibril externally.

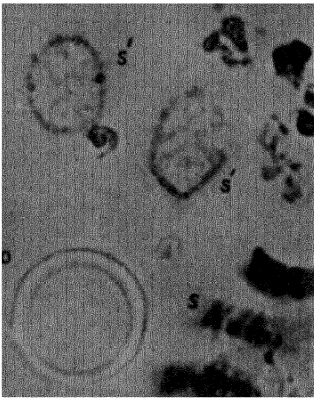

FIG. 191.—ISOLATED SARCOUS ELEMENTS OF WING-MUSCLE OF WASP, SHOWING THE POROUS STRUCTURE. (E. Sharpey-Schafer.) × 2300. Untouched photograph.

s, sarcous element seen in profile; *s'*, *s''*, two sarcous elements on the flat, seen in optical section; *o*, an oil drop.

As already stated, the sarcous elements are set side by side in planes, thus forming the dark stripes or *principal disks* of the striated substance of ordinary muscle-fibres. In the wing-muscles of insects, the fibrils are surrounded by so considerable an amount of granular sarcoplasm that the whole fibre is only very indistinctly cross-striated, although each individual fibril is markedly so. As already mentioned, the sarcous elements contain a large proportion of potassium salts (fig. 193).

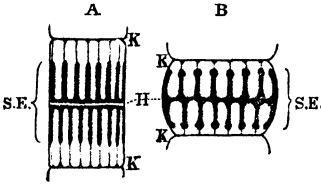

FIG. 192.—DIAGRAM OF A SARCOMERE IN A MODERATELY EXTENDED CONDITION, A, AND IN A CONTRACTED CONDITION, B.

K, K, membranes of Krause; H, line or plane of Hensen; S.E., poriferous sarcous element.

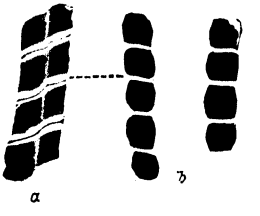

FIG. 193.—LOCALISATION OF POTASSIUM IN SARCOUS ELEMENTS OF WING-MUSCLE OF BEETLE. (A. B. Macallum.)

a, resting; *b*, contracted.

Sometimes in the ordinary (leg) muscles of arthropods what look like detached dot-like portions of the sarcous element are seen within the clear stripes, lying usually near Krause's membrane. The rows of such dots have been termed *accessory disks*. Most muscles show no accessory disks, but the dot-like sarcoplasm-enlargements between the fibrils (fig. 187) are often mistaken for them.

Muscle in polarised light.—When muscle-fibres are examined with polarised light between crossed nicols, the sarcous elements (which form the dark stripe) are seen to be doubly refracting (anisotropous), while the clear substance (forming the light stripe) is singly refracting (isotropous). In contracted parts of the muscle the (anisotropous) sarcous elements are seen to have increased in bulk, while the isotropous substance of the clear stripe has correspondingly diminished (fig. 194).

Merkel imagined that there is a reversal of the stripes during contraction, *i.e.* a transference of the anisotropous substance of the dark stripe from Hensen's line to

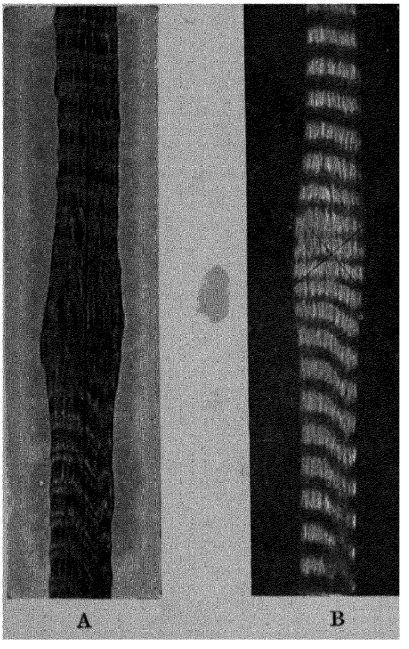

FIG. 194.—LEG-MUSCLE FIBRE OF CHRYSOMELA CŒRULEA WITH (FIXED) CONTRACTION WAVE PHOTOGRAPHED UNDER POLARISING MICROSCOPE.

A, with uncrossed nicols; *B*, with crossed nicols. Untouched photograph of a preparation by T. W. Engelmann.



FIG. 195.—WAVE OF CONTRACTION PASSING OVER A LEG-MUSCLE FIBRE OF DYTISCUS. (E. Sharpey-Schafer.) Highly magnified.

Krause's membrane, the place of the dark stripes thus becoming occupied by clear material, that of the light stripes by dark. He further described this condition as being preceded by an intermediate stage in which the fibril shows homogeneity of shading. No doubt in the ordinary muscle-fibres of arthropods, when we observe the so-called 'fixed' waves of contraction (fig. 194, A), there is often an apparent blurring of the cross-striation of the fibre just where the muscle is passing from extension to contraction, but this is explicable by the unequal pull of the contracted parts of the fibrils upon those which are not yet contracted. The contraction in each fibre starts from the nerve-ending, which is at one side of the fibre, and spreads first across the fibre and then tends to pass as a wave towards either end. The one side always has a start in the progress of this wave, and the fibrils must thus receive an unequal pull, so that they are shifted along one another and the line of cross-striping is broken. That no transference of anisotropous substance really

occurs is at once clear from the appearance of the contracting fibre under polarised light (fig. 194, B), and the study of the isolated fibrils of wing-muscle gives no support to the theory of reversal. That the apparent reversal is not real is also illustrated by fig. 195, which represents a leg-muscle fibre of an insect in process of contraction. The dark bands of the contraction-wave are seen to be really due to accumulations of sarcoplasm. Owing to this having a higher index of refraction than the rest of the muscle-substance these accumulations appear as dark lines which not only obscure the continuity of the fibrils, but by contrast cause the whole of the sarcomeres between them to appear light.

LESSON XVI.

MUSCLE (*continued*).

1. To study the connexion of muscle with tendon, a frog is killed by destruction of the brain and spinal cord, and placed in about a litre of normal saline raised to a temperature of 55° C. It is left in this for 15 minutes, the liquid gradually cooling. It is then easy to dissociate the muscular fibres in large numbers. To observe their attachment to the tendon-bundles a fine longitudinal shred must be snipped off with scissors at the tendinous attachment, and dissociated upon a slide in a drop of Ringer. It will usually be found that the muscular substance is retracted from the end of the sarcolemma tube, which is firmly cemented to the tendon-bundle. The structure may be brought more distinctly into view by adding to the dissociated fibres a drop of solution of iodine in iodide of potassium.

This method is the one recommended by Ranvier. The muscle-endings are also well seen at the extremities of the tendons which are removed from the mouse's tail in the manner described in Lesson X.

2. The blood-vessels of muscle. These are studied in fairly thick longitudinal and transverse sections or in flattened-out pieces of injected muscle mounted in dammar. It will be noticed that the capillaries are very numerous, and form a network with oblong meshes. In the red muscles of the rabbit, small dilatations are seen on the transverse vessels of the network.

3. Heart-muscle. The arrangement of the muscular tissue of the heart will be considered later (Lesson XXVI.), but the tissue itself may be studied now in teased preparations. To prepare these, place a small piece of heart-muscle, preferably from a young animal, in 33 per cent. alcohol for a few days; stain in picro-carmine or borax-carmine solution for some days; tease in dilute glycerine.

4. Plain muscle. Tear off a small shred of the muscular coat of a piece of intestine which has been 48 hours or more in 1 in 2000 chromic acid. Hold the shred with forceps in a drop of distilled water on the slide and fray its edge with a needle. In this process many cells will be set free and can be seen with a low power. Remove the rest of the shred. The preparation may then be covered and examined with a high power. Sketch one of the cells. Then allow a drop of dilute Delafield's hæmatoxylin to diffuse under the cover-glass; to be followed by a drop of dilute glycerine. Cement cover-glass next day. Sketch a cell after staining. Measure two or three cells and their nuclei.

Sections of involuntary muscle will be seen and studied along with those viscera which possess muscular coats.

CONNEXION WITH TENDON: BLOOD-VESSELS: DEVELOPMENT OF CROSS-STRIATED MUSCLE.

Ending of muscle in tendon.—A small tendon-bundle passes to each muscular fibre and becomes firmly united with the sarcolemma which extends over the end of the fibre (fig. 196). Besides this attachment, a further connexion is established by the fact that the areolar tissue between

the tendon-bundles is continuous with that which lies between the muscle-fibres. There is no actual continuity between contractile substance and tendon.

Blood-vessels of muscle.—The capillaries of muscle are very numerous. They run, for the most part, longitudinally, with transverse branches, so as to form oblong meshes (fig. 197). No blood-vessels penetrate the sarco-

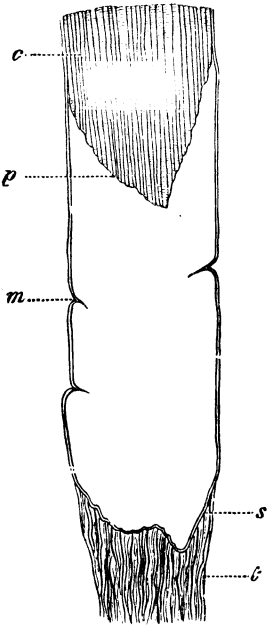

FIG. 196.—TERMINATION OF A MUSCLE-FIBRE IN TENDON. (Ranvier.)

m, sarcolemma; *s*, the same membrane passing over the end of the fibre; *p*, extremity of muscular substance, *c*, retracted from the lower end of the sarcolemma-tube; *t*, a tendon-bundle passing to be fixed to the sarcolemma.



FIG. 197.—CAPILLARY VESSELS OF MUSCLE: HUMAN. (E. Sharpey-Schafer.)

lemma. In the red muscles of the rabbit the transverse capillaries have small dilatations upon them (fig. 198).

Lymph-vessels, although present in the connective-tissue sheath (perimysium) of a muscle, do not penetrate between the component fibres.

Nerves.—The motor nerves of voluntary muscles pierce the sarcolemma and terminate in ramified expansions known as *end-plates* or *motor end-organs*; the sensory nerves end in groups of specially modified muscle-fibres known as *muscle-spindles* (Lesson XIX.). Sympathetic fibres, of unknown function, are also distributed to voluntary muscle (see p. 220).

Histogenesis of striated muscle.—Voluntary muscular fibres are developed from embryonic cells of the mesoderm (muscle-plate cells), which become

elongated, and their nuclei multiplied, so as to produce long, slender, multinucleated embryonic fibres (figs. 199 to 201). It is not quite certain whether,

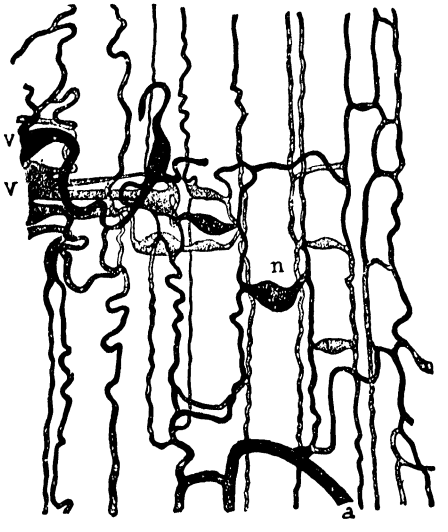

FIG. 198.—VASCULAR NETWORK OF A RED MUSCLE (SEMI-TENDINOSUS) OF THE RABBIT. (Ranvier.)

a, arteriole; v, v, venules; n, dilatation on transverse branch of capillaries.

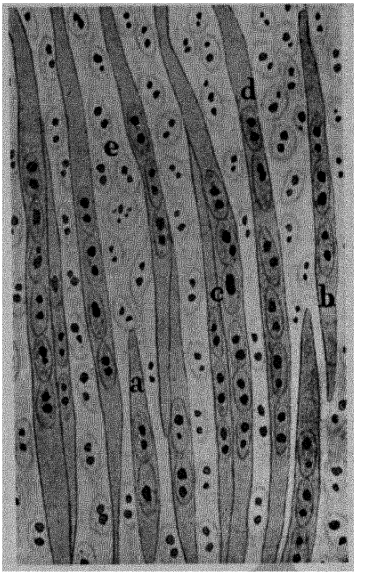

FIG. 199.—DEVELOPING MUSCLE OF CHICK, AFTER FIVE DAYS' INCUBATION. LONGITUDINAL SECTION. (J. F. Tello.) × 600.

a, muscle-cell with two nuclei; b, muscle-cell with three nuclei; c, group of two muscle-cells; d, muscle-cell with six nuclei.

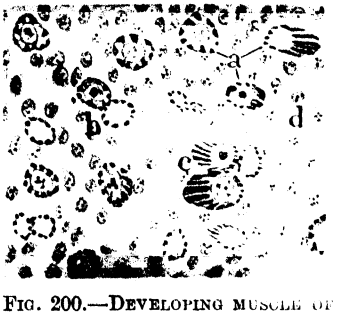

FIG. 200.—DEVELOPING MUSCLE OF CHICK, AFTER SEVEN DAYS' INCUBATION. TRANSVERSE SECTION. (J. F. Tello.) × 600.

a, three isolated muscle-fibres (myo-tubes) showing differentiation at periphery; b, a group of two muscle fibres (myo-tubes); c, a group of three; d, developing connective tissue.

as has usually been supposed, the whole fibre is formed of a single enlarged cell, or whether it may be produced by the joining together, end to end, of a number of cells of the muscle-plate (or of more than one muscle-plate), so as to produce a syncytium, within which the striated fibrils make their appearance. The cross-striations appear at first along one side of the cell (fig. 201, A), the change gradually extending around the circumference and also penetrating towards the centre; but the protoplasm both at the middle of the fibre, to which the nuclei are at first confined, and at the side opposite to that at which the differentiation began, remains for some time unaltered in character (fig. 201, B, C). Eventually the change in structure extends to these parts also, and the nuclei pass gradually to occupy their ordinary

position under the sarcolemma, which has by this time become formed. The young muscle-fibres are at first isolated, but after a time are seen in groups (fig. 200). It is uncertain whether the groups are formed by longitudinal splitting of the original primitive fibre or by the differentiation of adjacent cells to form other muscle-fibres.

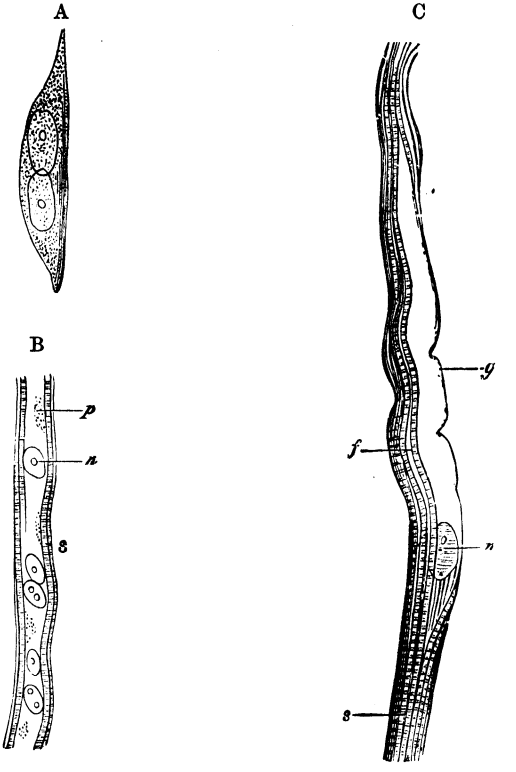

FIG. 201.—DEVELOPING MUSCULAR FIBRES OF MAMMALS.

A, elongated cell with two nuclei from fœtal sheep. Striation is beginning in the protoplasm along one side of the cell. (Wilson Fox.)
B, from human fœtus of two months. (Ranvier.) *p*, central protoplasm with several nuclei, *n*, scattered in it; *s*, commencing sarcolemma, with striated muscular substance immediately beneath it.
C, from human fœtus of three months. (Ranvier.) The contractile substance, *f*, encloses the unaltered protoplasm, except at one place; *g*, sarcolemma; only one nucleus, *n*, is represented.

The mode of development of the sarcolemma has not been clearly made out, but it is generally regarded as a connective-tissue structure.

CARDIAC MUSCLE.

The muscular substance of the heart is composed of transversely striated muscle fibres, which differ from those of voluntary muscle in the following particulars, viz. (1) their striations are less marked; (2) they have no distinct sarcolemma, although they may have a thin superficial layer of

non-fibrillated substance; (3) they branch, and unite by [redacted]s, and also at the side with neighbouring fibres; (4) their nuclei lie in the thickness

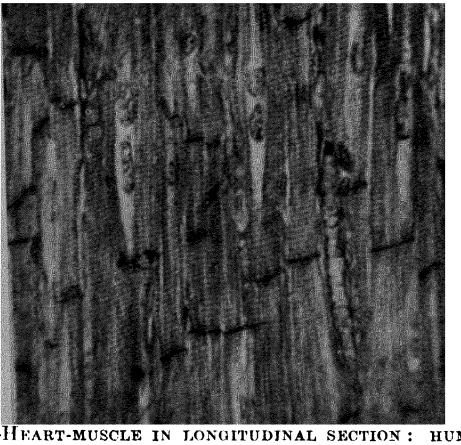

FIG. 202.—HEART-MUSCLE IN LONGITUDINAL SECTION: HUMAN. (E. Sharpey-Schafer.) × 400. Photograph.

Note the interruptions on the fibres, stained darkly, and the nuclei, mostly in pairs, in clear substance (sarcoplasm) in the middle of the fibre.

and often near the centre of the fibres. In man and many mammals the fibres exhibit transverse markings apparently dividing them into a series of



FIG. 203. PORTION OF CARDIAC MUSCLE EXHIBITING CONTINUITY OF FIBRILS ACROSS JUNCTIONAL LINE. (Przewosky.) Highly magnified.



FIG. 204.—SIX MUSCULAR FIBRE-CELLS FROM THE HEART. (E. Sharpey-Schafer.) × 425.

a, line of junction between two cells; *b*, *c*, branching of cells. (From a drawing by J. E. Neale.)

short cylindrical segments (figs. 202, 204), joined together end to end and side to side; often there seems to be a nucleus corresponding to each

portion. The transverse markings are evident in longitudinal sections of appropriately stained fixed tissue; they also come distinctly into view in preparations stained with nitrate of silver. They are bridged by the muscle-fibrils, which are thus in continuity from one segment to the next (fig. 203). These transverse markings were regarded by Schweigger-Seidel, who first described them, as intercellular septa (cell-junctions) for they resemble intercellular substance in staining with nitrate of silver. But other authorities have taken different views regarding the transverse markings. H. E.

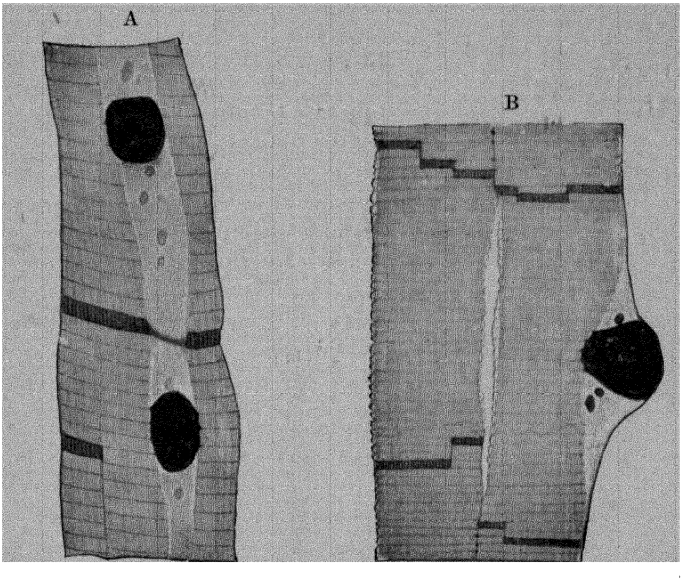

FIG. 205.—PORTIONS OF MUSCLE-FIBRES FROM THE ADULT HUMAN HEART. (v. Palczewska.)

In A one of the so-called septa traverses the protoplasm which extends between the nuclei as well as the striated substance. A second incomplete septum is also shown.
In B a nucleus is seen at the surface, and serves to render the investing membrane apparent. Notice the zigzagging of the septa, an appearance which is not infrequent.

Jordan regards them as due to fixed localised contractions, while Martin Heidenhain considers that they represent portions of the fibres at which growth in length occurs (analogous to the suture-lines between the flat bones of the cranium). As against these views of the transverse septa, and in favour of the original view of Schweigger-Seidel, must be set the silver-staining of the supposed cell-junctions, and the fact that it is easily possible in some animals to separate the fibres after maceration into short uninucleated fragments (fig. 204). Schweigger-Seidel's view is upheld by v. Palczewska and Werner (working with Zimmermann), who studied the subject in the heart of man and of various mammals. These observers point out, as had been previously done, that the short non-nucleated segments often seen, which Heidenhain regards as fatal to the cell-theory of cardiac muscle, may be parts of cells lying in other planes of the myocardium, which are inserted

between those belonging to the plane included in the longitudinal section. On the other hand, the continuity of the muscle-fibrils within the masses of Purkinje's fibres under the endocardium in the sheep, the fibrils belonging to one cell being freely continued into those of the neighbouring cells (see fig. 424, p. 318), is in favour of a syncytial theory of the structure of heart-muscle. Indeed, in many vertebrates, including some mammals, no cell-territories can be made out in the myocardium.



FIG. 206. SECTION FROM HEART OF FIVE MONTHS' EMBRYO: HUMAN. (G. Mann.)

Histogenesis of cardiac muscle.—The explanation of these differences appears to be that heart-muscle at an early period of development is a syncytium within which the contractile fibres are developed, and that a differentiation of the syncytium into cells is only produced later. Even then the lines of junction are bridged across by muscle-fibrils. And in some animals a differentiation into separate cell-territories is incomplete or altogether lacking.

Further details regarding its muscular structure will be given when the heart as a whole is treated of (Lesson XXVI.).

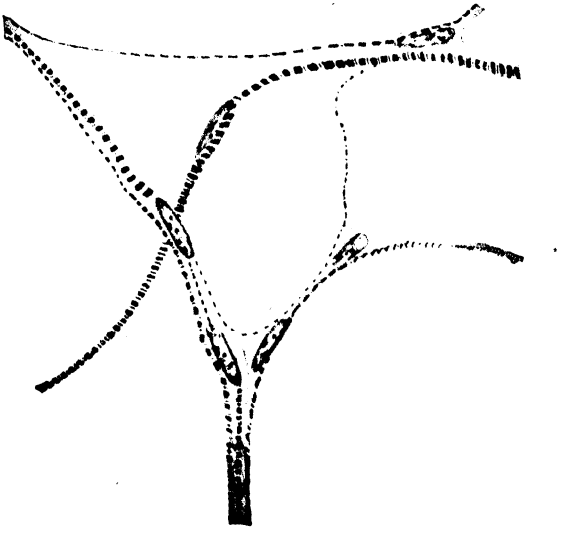

FIG. 207.—SYNCYTIUM OF HEART-MUSCLE OF AURICLE OF FROG-EMBRYO, SHOWING MUSCLE-FIBRILS PASSING FROM CELL TO CELL. (G. Mann.) Highly magnified.

NON-STRIATED, PLAIN OR INVOLUNTARY MUSCLE.

Non-striated or **plain muscular tissue** is composed of elongated fusiform cells (fig. 208), which vary much in length. In cross-section they are usually angular, an appearance due to mutual compression (fig. 210). The cell-nucleus is either oval or rod-shaped; it has the usual structure and commonly one or two nucleoli. There is a centriole—sometimes double—close to the nucleus (fig. 209). The cell-substance is finely fibrillated longitudinally, but does not exhibit cross-striæ like voluntary and cardiac muscle. There appears to be a delicate external layer, probably a stratum of undifferentiated protoplasm, not a true sarcolemma. Next to this, in some smooth muscle, is a layer containing coarser fibrils (boundary fibrils of M. Heidenhain) (fig. 208, B). Frequently there is seen a series of irregularly placed transverse markings which appear as knot-like condensations of the cell-substance

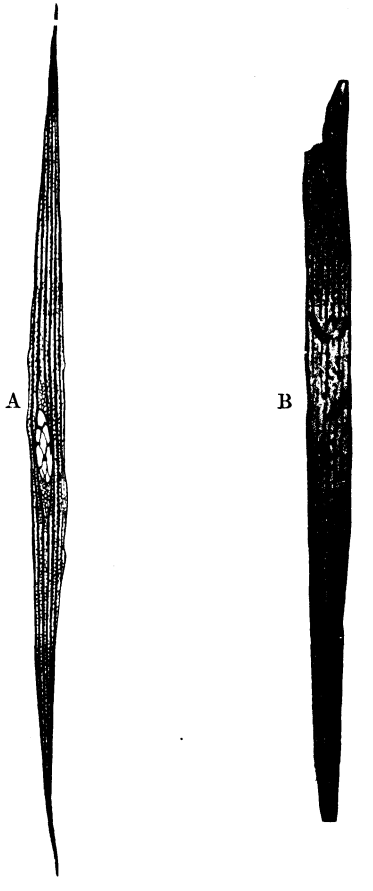

FIG. 208.—MUSCLE FIBRE-CELLS FROM INTESTINE OF CAT. (E. Sharpey-Schafer.)

A, a complete cell showing the nucleus and longitudinal fibrillation. × 250.
B, part of a cell showing the nucleus and the coarser fibrils. Photograph. × 450.



FIG. 209.—MIDDLE PART OF A MUSCLE FIBRE-CELL SHOWING FINE LONGITUDINAL STRIATION AND ELONGATED NUCLEUS.

The centriole is seen opposite an indentation in the nucleus. (v. Lenhossék.)

(fig. 208, B) staining somewhat differently from the rest of the cell. The nature of these is not well understood, but they are perhaps produced by localised contractions at the moment of death of the cell; the fibrils are enlarged as they run through the knots. The intercellular substance is bridged by filaments passing from cell to cell (figs. 210, 211).

Plain muscular tissue is found chiefly in the walls of hollow viscera; thus it forms the muscular coat of the stomach and intestines, and occurs abundantly in the muscular coat of the gullet, although it is here intermixed with cross-striated muscle; it is found also in the mucous membrane of the whole alimentary canal from the œsophagus downwards; in the trachea and its ramifications; in the urinary bladder and ureters; in the uterus and Fallopian tubes; in the prostate; in the spleen and lymphatic glands; forming the muscle of Müller in the orbit, and the ciliary muscle and iris-musculature. The walls of gland-ducts also contain it; and the middle coat of the arteries, veins, and lymphatics is largely composed of this tissue. It occurs in the skin, both in the secreting parts of the sweat glands and in small bundles attached to the hair-follicles; in the scrotum it is found abundantly in the subcutaneous tissue (dartos); it also occurs in the mammary gland, both in the areola of the nipple and in the walls of the secreting alveoli.

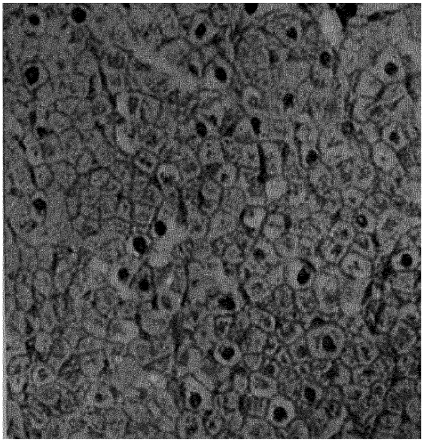

FIG. 210.—TRANSVERSE SECTION OF PLAIN MUSCLE-FIBRES OF INTESTINE. (E. Sharpey-Schafer.) × 400. Photograph.

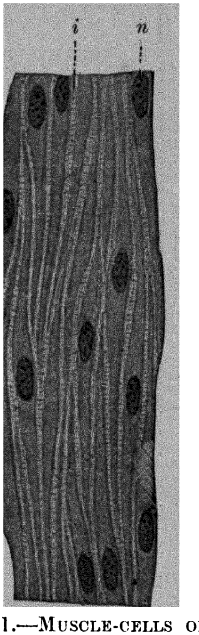

FIG. 211.—MUSCLE-CELLS OF INTESTINE. (Szymonowicz.) Magnified 530 diameters.

The fibres are represented in longitudinal section; the interstices between them are seen to be bridged across by fine fibrils. *i*, interstice; *n*, nucleus.

Histogenesis of plain muscle.—C. M'Gill states that the smooth muscle of the alimentary canal (pig) is developed from a syncytium of mesenchyme cells which surrounds the entoderm. Some of these cells become elongated and spindle-shaped while retaining their interconnexion. Myofibrils are

developed in their protoplasm. These need not be confined to the limits of a single cell, but may extend over a number of cells. The myofibrils are of two kinds, coarse and fine, varying in relative number in different parts. As stated above, an interconnexion of the cells obtains even in the fully formed muscle, which thus retains something of its syncytial character.

In certain situations plain muscle is formed from ectoderm; this is the case with the muscular tissue of the sweat glands (Ranvier) and with that of the alveoli of the mammary gland. It is also true for the muscular tissue of the iris (Nussbaum).

LESSON XVII.

NERVE-FIBRES

1. TEASE a piece of fresh nerve (vagus of cat or rabbit) rapidly; either in Ringer or by the method of semi-desiccation, keeping the preparation moist by the breath, afterwards mounting in Ringer. Touch the fibres as little and obtain them as long and straight as possible. Study the myelinate fibres, carefully noticing all the structures that are visible—viz., nodes of Ranvier, nuclei of neurolemma, double contour of myelin-sheath, segments, etc. Besides the ordinary fibres, some very fine myelinate fibres, and some amyelinate, will be seen in this preparation. Measure the diameter of four fibres. Draw a short length of one or more very exactly.

2. In a drop of dilute glycerine, coloured by gentian violet, separate into its fibres a short length of a smallish nerve, or nerve-root (this is more easy to separate into its fibres), that has been two hours in 1 per cent. osmic acid and then in water for twenty-four hours or longer. The nerve should have been laid out straight upon a piece of card before being placed in osmic acid. Keep the fibres as straight as possible and only touch them near their ends with the needles. Sketch two portions of a fibre under a high power, one showing a node of Ranvier and the other a nucleus of the neurolemma. Look for amyelinate fibres. Measure the length of a nerve-segment between two nodes of Ranvier.

3. Mount in dammar transverse and longitudinal sections of nerve fixed (*a*) with picric acid or 10 per cent. formol followed by alcohol, (*b*) with 1 per cent. osmic acid followed by alcohol. The sections from picric acid and formol may be stained with hæmatoxylin. The nerve should be laid out straight upon a piece of card as recommended in § 2. Examine the sections first with a low and afterwards with a high power. Notice the lamellar structure of the perineurium, the varying size of the nerve-fibres, the axis-cylinder in the centre of each fibre, etc. Measure the diameter of four fibres. Sketch a small portion of a section.

4. Teased preparations and longitudinal sections from the peripheral portions of nerves, cut seven, fourteen and twenty-one days before killing the animal. The nerves are prepared with osmic acid as in § 2. Notice the breaking up of the myelin of the sheath, varying in degree according to the length of time the lesion was made previous to death.

In longitudinal sections of the central cut end of the nerve, prepared by Cajal's reduced silver method (see Appendix), new fibres may be seen budding from the extremities of the fibres of the stump.

STRUCTURE OF NERVE-FIBRES.

Nerve-fibres are of two kinds, *myelinate* and *amyelinate* (*medullated* and *non-medullated*). The cerebro-spinal nerves and the white matter of the nerve-centres are composed chiefly of myelinate fibres; the sympathetic nerves near their peripheral distribution are largely made of amyelinate fibres. The latter are also found in considerable numbers in the vagus.

The **myelinate, medullated** or **white fibres** are characterised, as their name implies, by the presence of the *myelin sheath* or *white substance of Schwann*. This is a layer of semi-fluid substance which encircles the essential part of a nerve-fibre, viz., the *axis-cylinder*. Outside the myelin sheath is a delicate but tough homogeneous membrane, the *neurolemma* (*nucleated sheath of Schwann*); this is not present in all myelinate fibres, being absent from those within the nerve-centres.

The *myelin sheath* is composed of a highly refracting lipoid material (myelin), which gives a characteristic double contour and tubular appearance to the nerve-fibre (fig. 212). It affords a continuous investment to the

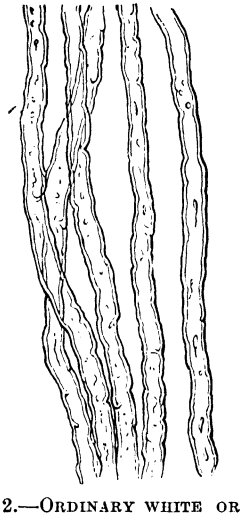

FIG. 212.—ORDINARY WHITE OR MYELINATE NERVE-FIBRES, SHOWING A SINUOUS OUTLINE AND DOUBLE CONTOURS. (Bidder and Volkmann.)

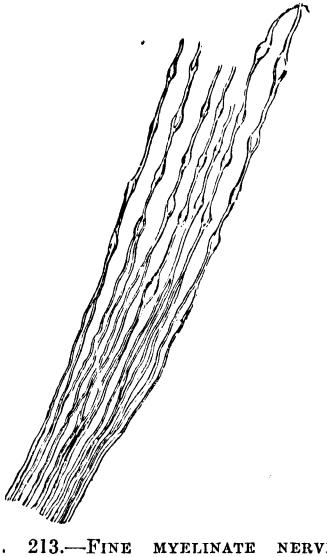

FIG. 213.—FINE MYELINATE NERVE-FIBRES, PARTS OF WHICH HAVE ACQUIRED A VARICOSE APPEARANCE—PROBABLY THE RESULT OF MANIPULATION. (Valentin.)

axis-cylinder, except that, as was shown by Ranvier, in peripheral nerve-fibres it is interrupted at regular intervals. At these places the neurolemma appears to produce constrictions in the nerve-fibre (figs. 214, 216, 217, 221, 224), the *nodes of Ranvier*, the latter term having been applied from the resemblance which they bear to the nodes of a bamboo. It is uncertain whether the constriction is entirely occupied by neurolemma or partly by a special band (*constricting band of Ranvier*); if the latter, it is composed of a material which resembles intercellular substance in being stained with nitrate of silver (fig. 228). The segment of nerve between two successive nodes is termed an *internode*; in the middle of each internode is one of the nuclei of the neurolemma (fig. 214). Besides these interruptions the myelin sheath shows a variable number of oblique clefts (figs. 215, 218, 221),

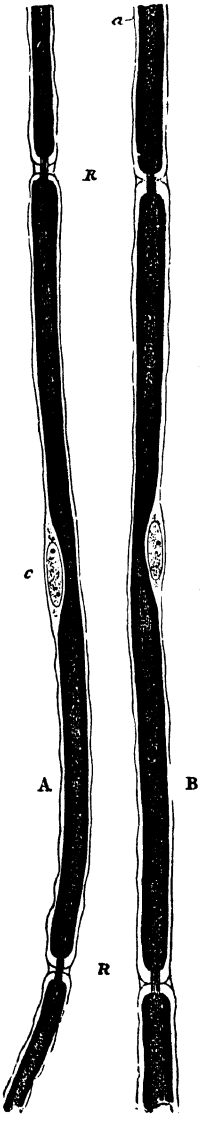

FIG. 214.—PORTIONS OF TWO NERVE-FIBRES STAINED WITH OSMIC ACID. Diagrammatic. Drawn by J. E. Neale.

R, [illegible] Ranvier, with [illegible] *a*, neurolemma of the nerve; *c*, opposite the middle of the segment, indicates the nucleus and protoplasm lying between the neurolemma and the myelin sheath. In A the nodes are wider, and the intersegmental substance more apparent than in B.



FIG. 215.



FIG. 216.

FIG. 215.—A SMALL PART OF A MYELINATE FIBRE, FRESH. (E. Sharpey-Schafer.) Very highly magnified. Photograph.

The fibre looks in optical section like a tube—hence the term tubular formerly applied to these fibres. Three partial breaches of continuity or clefts are seen in the myelin sheath, which at these places exhibits a tendency to split into laminæ. Elsewhere the myelin shows coagulation-appearances. At *n* is a nucleus belonging to the neurolemma, embedded in protoplasm; the outline of the nucleus itself is not focused.

FIG. 216.—MYELINATE NERVE-FIBRE, FRESH, SHOWING A NODE OF RANVIER. (E. Sharpey-Schafer.) Very highly magnified. Photograph.

The coagulation of the substance of the myelin sheath is advanced, and the axis-cylinder is slightly shrunken away from it, and is thus rendered distinctly visible. In places the axis-cylinder shows a fibrillar appearance.

subdividing it into conico-cylindrical portions of variable [redacted] *segments*); there is reason to believe that the clefts are artificially produced. At the clefts there is a laminated appearance in the myelin sheath, especially after treatment of the nerve with certain reagents; sometimes the clefts look as if they contain spiral fibres. But it is probable that all these appearances are artifacts and do not represent pre-existing structures.

The myelin sheath contains mitochondria, for the most part disposed

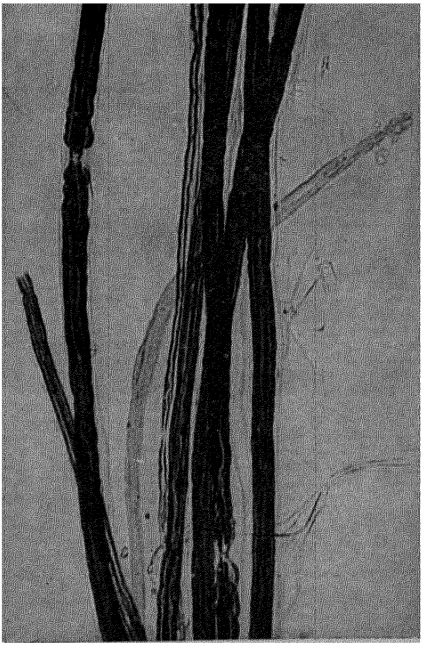

FIG. 217.—NERVE-FIBRES FROM SCIATIC NERVE INCLUDING, BESIDES SEVERAL ORDINARY LARGE MYELINATE FIBRES, AN AMYELINATE FIBRE AND A FINE MYELINATE FIBRE. (E. Sharpey-Schafer.) Osmic preparation. × 300. Photograph.

radially. A reticular appearance has also been noticed in the myelin sheath after fixation with alcohol (*neurokeratin network* of Kühne, fig. 219) but it varies greatly in aspect and is probably produced by the action of the reagents employed to show it. By other modes of fixation (*e.g.* picric acid) the myelin sheath seems to have a rod-like structure (fig. 222); this is perhaps due to the radial disposition of the mitochondria. Osmic acid stains the myelin sheath black (figs. 217, 218, 221, 223).

The *neurolemma* is a thin homogeneous sheath which closely invests the myelin sheath of the peripheral nerve-fibres but is absent from the fibres of the central nervous system. It is the toughest part of the fibre and remains unbroken if the nerve is pinched, whereby both the myelin sheath and the axis-cylinder may be ruptured. The oval nuclei seen at regular

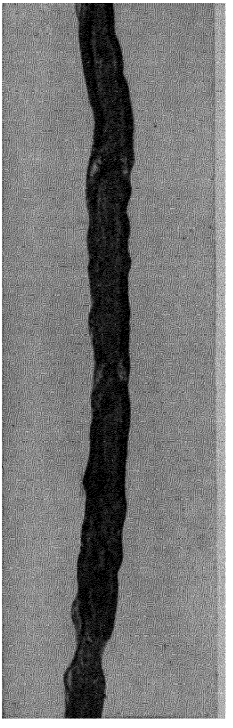

FIG. 218.—NERVE-FIBRE PREPARED WITH OSMIC ACID. Magnified about 500 diameters. Photograph.

A constriction of Ranvier is seen. The intervals between the myelin segments appear as clear oblique lines.

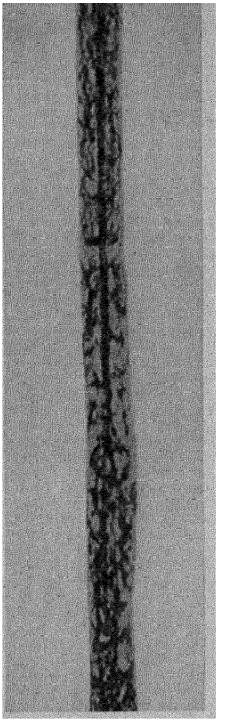

FIG. 219.—RETICULUM OF NEUROKERATIN IN MYELIN SHEATH OF NERVE-FIBRE. Magnified 600 diameters. Photograph.

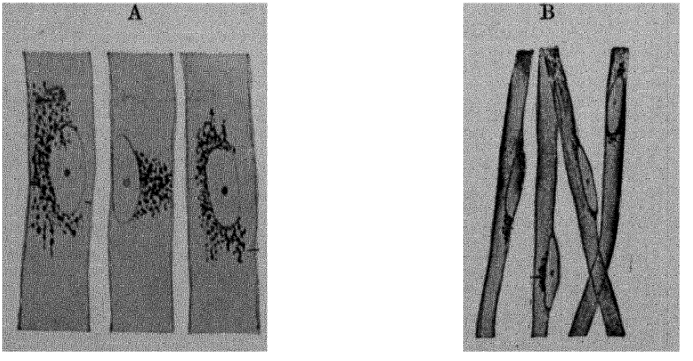

FIG. 220.—GOLGI RETICULAR APPARATUS, A IN MYELINATE FIBRES AND B IN AMYELINATE FIBRES. (R. y Cajal.)

intervals along the nerve-fibre midway between the nodes embedded in the myelin sheath belong to the neurolemma, as well as a small amount of protoplasm, containing a Golgi apparatus which adjoins each nucleus (fig. 220). The neurolemma dips inwards at the nodes of Ranvier and thus produces the interruptions of the myelin sheath. Nerve-fibres within the central nervous system, which do not possess a neurolemma, show no interruptions.

The *axis-cylinder*, which runs along the middle of the nerve-fibre, is a soft, transparent thread which is continuous from end to end of the fibre. On account of the peculiar refractive nature of the myelin sheath it is difficult to see the axis-cylinder in the fresh nerve except at the nodes, where it may be observed stretching across the interruptions in the myelin sheath; it may also sometimes be seen projecting from a broken end of a nerve-fibre. It shows an appearance of extremely fine longitudinal fibrils (*neuro-fibrils*, fig. 221). They are seen isolated at the terminations of nerves, as in the cornea, and are also visible in the section of a nerve-fibre as fine dots (fig. 221), which sometimes appear to have a clear centre (fig. 222), as if the fibrils were tubular. The axis-cylinder contains delicate rod-like mitochondria, disposed longitudinally. Neither the axis-cylinders nor their neuro-fibrils are to be looked upon as solid structures, in spite of the wire-like appearance which the latter exhibit



FIG. 221. — LONGITUDINAL AND TRANSVERSE SECTION OF MYELINATE NERVE-FIBRE OF FROG (OSMIC ACID AND ACID FUCHSIN). (After Biedermann.)

The longitudinal section shows one node of Ranvier and two myelin clefts. The fibrillar structure of the axis-cylinder is shown in both longitudinal and transverse section.



FIG. 222.—SECTION ACROSS FIVE NERVE-FIBRES. (E. Sharpey-Schafer.) × 1000.

The nerve was hardened in picric acid and stained with picro-carmine. The radial striation of the myelin sheath is very apparent. In one fibre the rays are broken by shrinkage of the axis-cylinder. The fibrils of the axis-cylinder appear tubular. (From a photograph.)

after fixation and staining. For there is no doubt that the whole nerve-fibre, with the exception of the neurolemma, is quite soft; probably of a viscous fluid consistency.

As shown in fig. 228, c, staining with nitrate of silver produces a curious transversely striated appearance in the axis-cylinder (Frommann); this is due to successive precipitations of chlorides, and does not indicate a pre-existing structure (A. B. Macallum).

Myelinate nerve-fibres vary greatly in size (figs. 223, 224), but may be classified as *large, intermediate,* and *very small.* The largest are those which

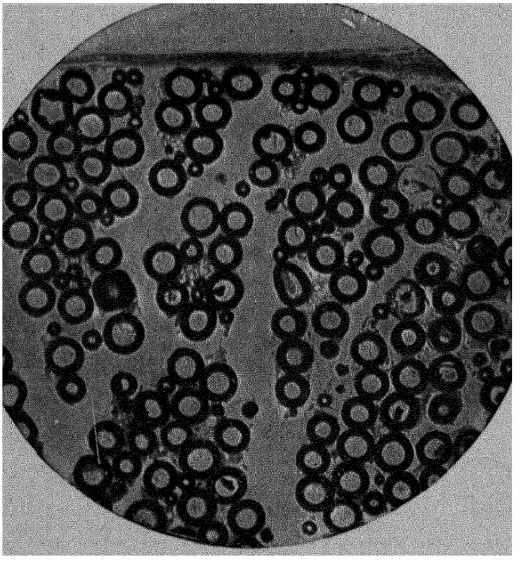

FIG. 223.—SECTION OF THE SCIATIC NERVE OF A CAT, SHOWING THE VARIATIONS IN SIZE OF ITS CONSTITUENT FIBRES. (E. Sharpey-Schafer.) × 300. Photograph. The nerve was fixed with osmic acid.

are passing to the skin and to the voluntary muscles; the smallest are those destined for viscera and blood-vessels; these constitute the preganglionic autonomic nerves of Langley. As shown by W. H. Gaskell, the ventral roots of the last one or two cervical nerves, of all the thoracic, of the first and second lumbar, and of the second and third sacral nerves contain, besides the ordinary large myelinate fibres, bundles of these very small fibres. Some of the cranial nerves (spinal accessory, vagus, glosso-pharyngeal, facial) contain similar very fine myelinate fibres, intermixed with the larger fibres. And it has lately (1928) been shown by Kure that similar fine myelinate fibres are found in many of the dorsal roots of the spinal nerves, amongst the large myelinate fibres which chiefly compose these roots.

The term 'autonomic' was introduced by Langley to include both the fibres of the sympathetic system and the analogous fibres (parasympathetic) proceeding

from the cranial and sacral regions. All autonomic nerves consist (1) of fine myelinate 'preganglionic fibres' arising in the central nervous system and ending in ganglia, and (2) of amyelinate 'postganglionic fibres' arising in the ganglia and passing thence to their peripheral distribution.

Amyelinate (non-medullated) fibres.—Intermingled with the myelinate fibres there may always, in peripheral nerves, be found a certain number of fibres devoid of the distinct double contour which is characteristic of the presence of a myelin sheath (fig. 224). These are the *grey* or *amyelinate fibres*, also called, after their discoverer, *fibres of Remak* (figs. 224, 225,

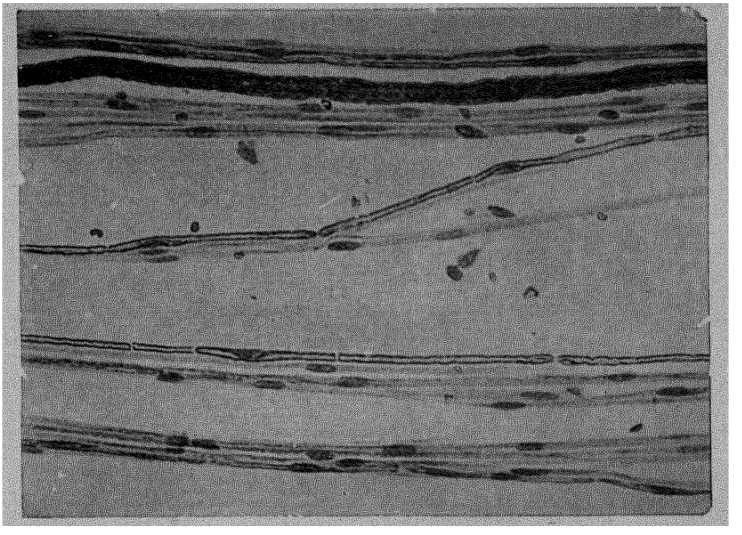

FIG. 224.—NERVE-FIBRES FROM A TEASED PREPARATION OF VAGUS OF CAT FIXED WITH OSMIC ACID. (E. Sharpey-Schafer.) × 300. Photograph.

About a dozen amyelinate fibres are included in the photograph. Besides these one ordinary myelinate fibre and three fine myelinate fibres are seen.

226). They are beset with numerous nuclei which have usually been regarded as belonging to a delicate sheath, although it must be admitted that the nuclei often appear to lie in the substance of the fibres rather than at their surface. A reticular apparatus of Golgi is closely related to each nucleus (fig. 220, B). As just stated, all the autonomic nerves, when they approach their peripheral distribution, are chiefly made up of fibres of this nature (the so-called postganglionic fibres); whereas the preganglionic fibres, both of sympathetic and of other autonomic nerves, always possess a thin myelin sheath, and have the usual structure of myelinate fibres.

By the pyridine silver method of staining, it can be shown that the ordinary nerves of the limbs contain a very large number of amyelinate fibres—which, according to S. W. Ranson, are derived only in part from the sympathetic but mainly from the small cells of the spinal ganglia (see p. 189).

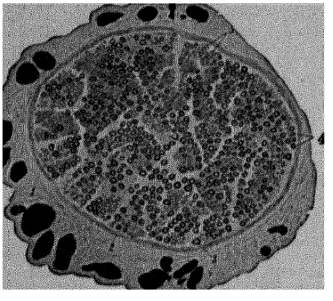

FIG. 225.—SECTION OF THORACIC SYMPATHETIC CORD OF CAT. (Fischer.) Osmic preparation.

1, Epineurium, with fat-cells (stained black); 2, perineurium; 3, 4, fine myelinate fibres; 5, amyelinate fibres.

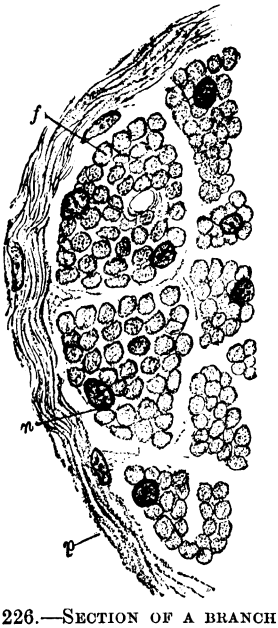

FIG. 226.—SECTION OF A BRANCH OF SYMPATHETIC OF OX, CONTAINING ONLY AMYELINATE FIBRES. (R. y Cajal.) Very highly magnified.

p, perineurium; *n*, nuclei; *f*, section of amyelinated fibres.

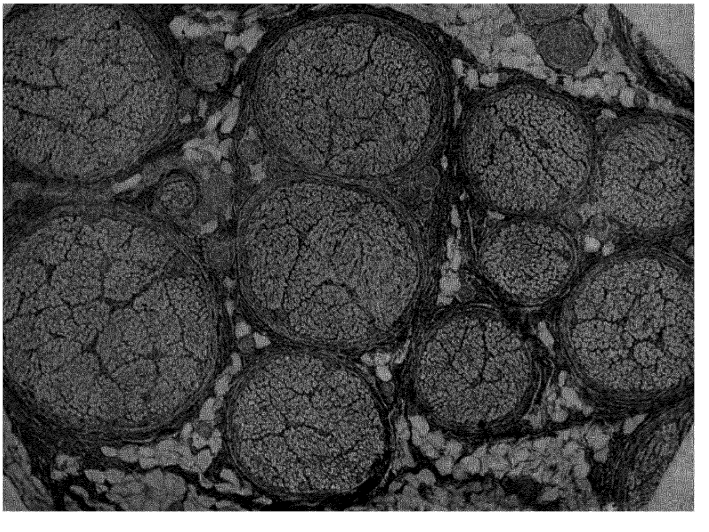

FIG. 227.—SECTION OF PART OF SCIATIC NERVE OF MAN. (E. Sharpey-Schafer.) Preparation by H. Pringle. × 60. Photograph.

A dozen funiculi of various sizes are included in the photograph. The fat-cells in the epineurium appear as clear spaces.

STRUCTURE OF THE NERVE-TRUNKS.

In their course through the body the nerve-fibres are gathered up into round bundles (*funiculi*) and the funiculi are again united to form the nerves met with in dissection (fig. 227). The connective tissue which connects the funiculi and invests the whole nerve, uniting it to neighbouring parts and conveying to it blood-vessels, lymphatics, and even nerve-fibres destined for its coats, is termed the *epineurium*; it frequently contains fat-cells. That which ensheathes the funiculi is known as the *perineurium*. It has a lamellar structure, the lamellæ being composed of connective tissue covered by flattened endothelial cells (fig. 228, A). Between the lamellæ are clefts which convey lymph from the interior of the funiculus to the lymphatics of

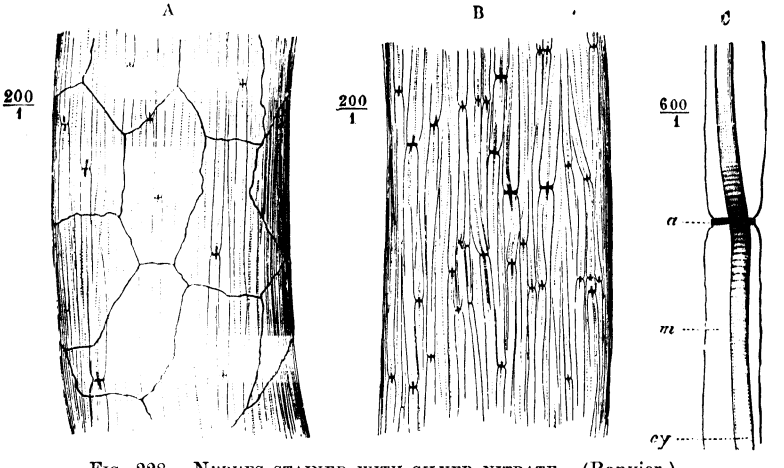

FIG. 228.—NERVES STAINED WITH SILVER NITRATE. (Ranvier.)
In A the endothelial layer of flattened cells belonging to the sheath of Henle is stained. In A and B the cruciform markings at the nodes are exhibited. In C a single fibre is shown more highly magnified, with Frommann's transverse markings of the axis-cylinder. *a*, constricting band; *m*, myelin sheath; *cy*, axis-cylinder.

the epineurium. The delicate connective tissue which lies between the nerve-fibres of the funiculus is termed *endoneurium*. The longitudinally arranged meshwork of blood-capillaries is conveyed in it; its interstices communicate with the lymph-clefts of the perineurium.

All the branches of a nerve, and even single nerve-fibres which are passing to their distribution, are invested with a prolongation of the perineural sheath, often of considerable thickness, known as the *sheath of Henle*.

The nerve-trunks themselves receive sensory nerve-fibres (*nervi nervorum*) which ramify chiefly in the epineurium and terminate within this in end-bulbs (Horsley).

Nerves contain few blood-vessels, from which it may be inferred that their metabolism is not active. The degenerative processes which occur in cut nerve-fibres as well as the subsequent reparative processes are dependent on the nerve-cells from which the fibres take origin and will be dealt with after the structure of nerve-cells has been studied (see p. 192).

LESSON XVIII.

NERVE-CELLS.

1. EXPOSE a small fragment of spinal ganglion of frog or mammal to osmic acid vapour for a few hours. Place in dilute glycerine (two-thirds water) for a few days. Tease in the same fluid. Notice the spheroidal ganglion-cells; their large nuclei and distinct nucleoli. Many of the cells may still be seen within their nucleated membranous sheaths. Look for cells which still retain the axis-cylinder process and for T-shaped junctions of nerve-fibres with this. Fat-cells may be present in the periganglionic connective tissue. These appear intensely black in osmic preparations.

2. Prepare in the same way a fragment of a spinal ganglion or of the Gasserian ganglion of the ray. Notice the bipolar character of many of the cells.

3. Prepare a piece of sympathetic ganglion as in §§ 1 and 2. If from the rabbit observe that many of the cells have two nuclei.

Measure two or three cells in each of the above preparations.

4. Study stained sections of ganglia, both spinal and sympathetic. These serve to show the general arrangement of cells and fibres in the ganglion and the nucleated sheaths around the nerve-cells.

The ganglia are fixed and hardened in 'susa' (see Appendix) or in saturated solution of picric acid or in 10 per cent. formol. They may either be stained in bulk or the sections, cut from paraffin, may be stained on the slide.

5. Ehrlich's methylene-blue method, Golgi's silver chromate method, or Cajal's silver reduction method, especially the last named, are all useful for showing the connexions of ganglion-cells with nerve-fibres. (See Appendix.)

6. Take a small fragment of the grey matter from a piece of spinal cord of ox, or calf, either fresh or after a few days' maceration in very dilute chromic acid solution (1 in 2000). Choose by preference a piece from the lumbar enlargement (ventral horn). Spread the fragment out with needles into a fairly even film on a slide. Immerse in alcohol for a few minutes. Stain with 1 per cent. aqueous methylene-blue for 2 minutes. Rinse with water, dry completely and mount in dammar. Notice the large branching cells, some with a mass of pigment near the nucleus. Observe the fibrillation of the cell-processes. Many axis-cylinders of nerves will be seen in this preparation deprived wholly or partially of myelin sheath; their fibrillar structure can be seen. Sketch these appearances. Similar preparations may be made from the grey matter of the cerebral cortex and cerebellar cortex to show the nerve-cells in those parts for comparison with the cells of the spinal cord.

7. Examine sections of spinal cord, medulla oblongata, and brain stained by methylene-blue by Nissl's method (see Appendix), to exhibit the angular particles within the nerve-cells.

8. Examine sections of parts of brain, spinal cord, and ganglia prepared by Cajal's silver reduction method to exhibit the neuro-fibrils in the cells and cell-processes. These preparations are best made from young animals.

9. Examine the nerve-cells and neuroglia-cells in sections from the spinal cord, cerebrum, or cerebellum of a small animal, *e.g.* young rat or kitten, prepared by Golgi's method. The sections are placed in thick xylol balsam or dammar on a

cover-glass, dried rapidly on a warm plate, and fixed inverted over a glass or card ring on a slide. They must not be covered and mounted in the ordinary way. (See Appendix.)

10. Examine sections of spinal cord (lumbar enlargement) and of corresponding spinal ganglia taken from an animal in which the sciatic nerve was cut about three weeks before it was killed. The sections are stained by Nissl's method. Most of the ventral horn nerve-cells and the ganglion-cells on the side of the lesion will exhibit chromatolysis (breaking down of the Nissl granules) which is characteristic of cells the axons of which have been severed. The altered cells may be compared with the normal cells on the intact side.

It will be better to defer preparations 7, 8, 9, and 10 until the central nervous system is studied.

STRUCTURE OF NERVE-CELLS.

A nerve-cell (neurocyte) consists of a cell-body and cell-processes (fig. 229). One of the processes is always a nerve-fibre or the axis-cylinder of a nerve-fibre. The cell-bodies lie either in the grey matter of the nerve-centres, or in little groups on the course of certain of the peripheral nerves; these groups cause nodular enlargements, known as *ganglia*. The most conspicuous ganglia are those found upon the dorsal (posterior) roots of the spinal nerves, upon the roots of some of the cranial nerves, and upon the trunk and principal branches of the sympathetic. Minute ganglia are also found very numerously in connexion with the nerves which are supplied to glands and involuntary muscular tissue, as in the salivary glands, heart, alimentary canal, bladder, uterus, etc.

Nerve-cells vary much in size and shape; many are large, some being among the largest cells met with in the body, but others are quite small. The *cell-body* (*cyton*), usually erroneously termed the 'nerve-cell,' is the part of the cell containing the nucleus. The latter is large and generally spherical and contains a very distinct nucleolus, readily displaced in the living cell (as by centrifuging). All nerve-cells possess at least one process; this is the *axon* (*nerve-fibre process, axis-cylinder process*); it becomes either an amyelinate nerve-fibre or the axis-cylinder of a myelinate fibre. If other processes are present they branch almost from their commencement at the cell-body, and are, therefore, termed *dendrites* or *dendrons*.

The following structures have been described in the cytoplasm of nerve-cells.

1. **Neuro-fibrils.**—With certain methods fine fibrils can be seen (fig. 230) passing from the axon and dendrons into the body of the cell, where they form an intricate plexus. The exact condition of the neuro-fibrils in living nerve-cells and fibres is not certain. But their study is of value as an index of the activity of the cell, for their thickness is said to vary in different physiological states (Cajal and Tello).

2. **Nissl bodies.**—These are angular masses of granular material (chromaphil substance) (fig. 229), with affinity for basic dyes. The Nissl bodies extend some way along the dendrons, but the axon, and the part of the cytoplasm from which it springs, is free from them. The Nissl granules change in number and size with the physiological condition of the cell. Thus it is found that nerve-cells which have been fatigued by prolonged

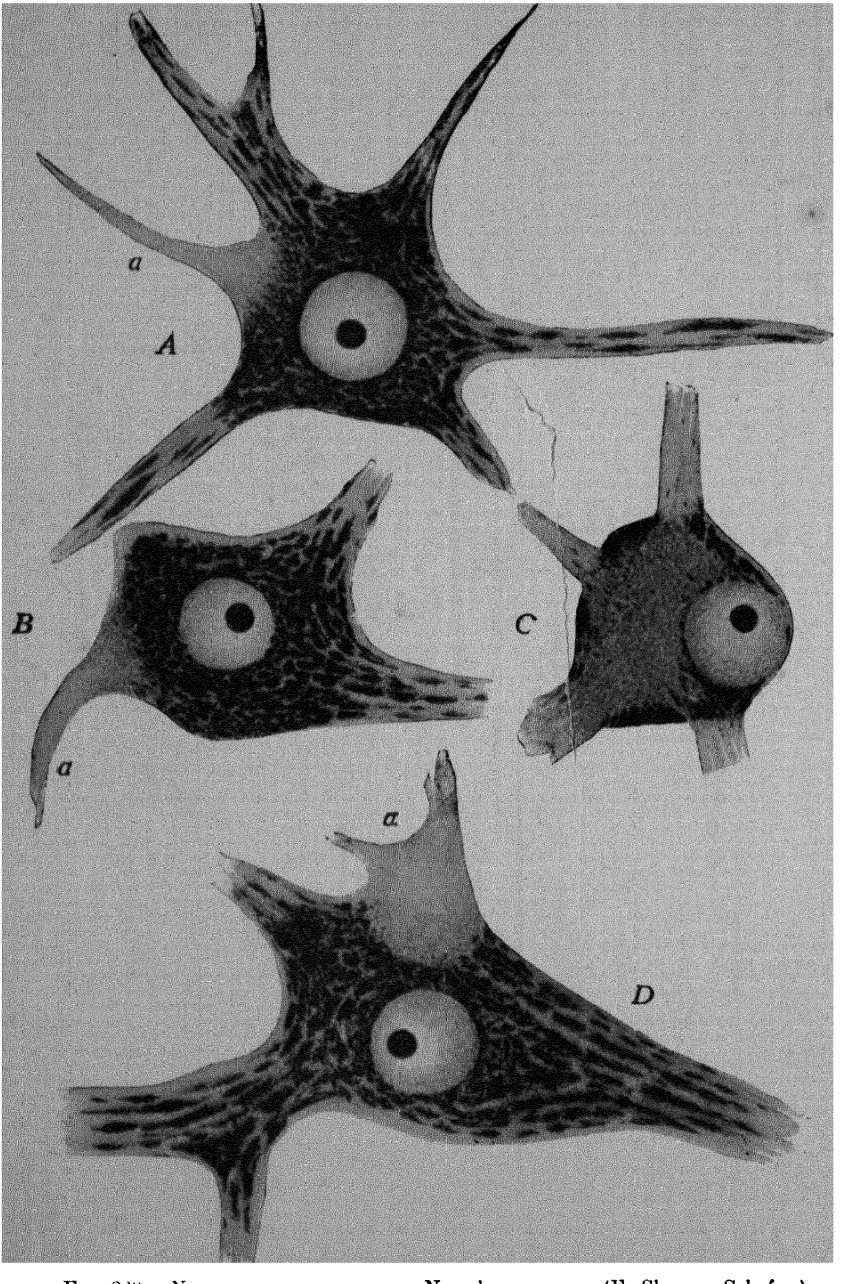

FIG. 229.—NERVE-CELLS STAINED BY NISSL'S METHOD. (E. Sharpey-Schafer.) × 750.

A, from ventral horn of spinal cord, monkey; *a*, commencing axon. *B* and *C*, from facial nucleus, dog. *C*, shows Nissl degeneration consequent on section of the facial nerve fifteen days previous to death *D*, from reticular formation of pons, dog; *a*, part of cell which gives origin to axon.

activity (fig. 231), and also those the axis-cylinder process of which has been cut (fig. 229, C) show the Nissl granules becoming disintegrated; they may even disappear for a time from the cell. A similar result is found to occur after the action of poisons which especially affect the nervous



FIG. 230.—NERVE-CELLS OF KITTEN (FROM THE ANTERIOR CORPORA QUADRIGEMINA) SHOWING NEURO-FIBRILS. (R. y Cajal.)

a, *a*, axons; *b*, *c*, *d*, various parts of the intracellular plexus of fibrils.

system. Nissl granules appear to consist chemically mainly of nucleoprotein. They contain organically combined iron (A. B. Macallum).

Although they are not distinct when the living cell is observed by dark ground illumination, the Nissl granules are not artifacts for they are shown in photographs of living nerve-cells taken by ultraviolet light. They are not present in all nerve-cells, being absent from many of the smaller cells of the grey matter of the brain. In the ganglion-cells they are not nearly as large and conspicuous as in the large multipolar cells of the spinal cord, but are more numerous, and are arranged concentrically with the nucleus. In the sympathetic cells they are also small and generally occupy a more peripheral position in the cell-body than in the spinal ganglion-cells.

3. **Mitochondria.**—These are scattered through the cytoplasm as small rodlets and granules. They can be seen in the living cell with dark-ground illumination.

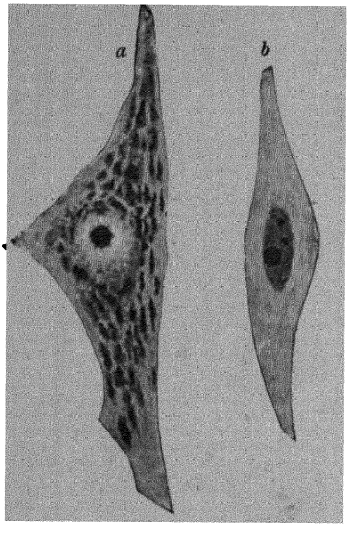

FIG. 231.—TWO MOTOR NERVE-CELLS FROM THE DOG.

a, normal; *b*, after a period of prolonged activity. (Photographed from preparations by G. Mann.)

4. **Cytoplasmic apparatus of Golgi** (fig. 232).—This requires special methods of fixation and staining; it is not visible in the living cell, examined either by transmitted light or by dark-ground illumination. In fixed specimens it appears as a varicose network, extending partly into the dendrons but not into the axon. Variations in nerve cell activity apparently do not affect it, but following section of the axon it fragments and becomes peripherally displaced (Penfield).

5. **Pigment.**—Many nerve cells have a clump of pigment granules (fig. 233), containing lipoids, at one side of the nucleus. This is especially marked at certain localities (locus caeruleus, locus niger), and is more frequent in man than in the lower animals. The pigment tends to increase in amount as age advances.

6. **Holmgren canaliculi.**—These form a system of fine channels permeating

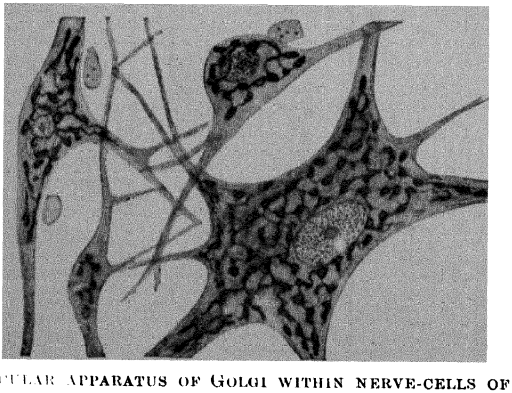

FIG. 232.—RETICULAR APPARATUS OF GOLGI WITHIN NERVE-CELLS OF SPINAL CORD. (R. y Cajal.)

the cytoplasm of the cell-body in some nerve-cells (fig. 234), distinct from the cytoplasmic reticulum of Golgi. Holmgren described the canals as occupied by branching processes of neuroglia cells (*trophospongium*).

In the very large nerve-cells from which the nerves to the electric organs

of the electric fish of the Nile (*Malapterurus*) arise, even blood-vessels penetrate into the cytoplasm.

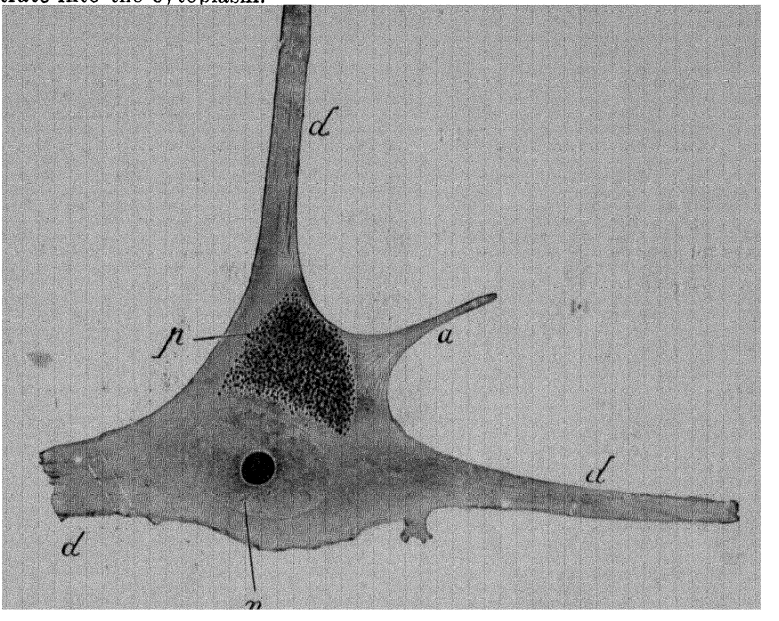

FIG. 233.—A NERVE-CELL FROM THE HUMAN SPINAL CORD. (From Prenant, Bouin, and Maillard.)
a, axon; *d*, *d*, dendrons; *n*, nucleus with nucleolus; *p*, clump of pigment-granules.

7. **Superficial reticulum of Golgi** (fig. 235).—This is found on most, if not on all, nerve-cells. According to J. Turner it is an investment derived from neuroglia cells.

A centrosome is lacking in the adult nerve-cell. This is perhaps related to the circumstance that fully developed nerve-cells do not multiply and, when damaged, are not replaced.

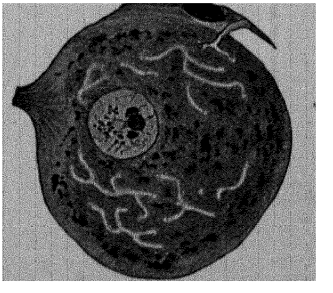

FIG. 234. — TROPHOSPONGIUM WITHIN A GANGLION-CELL. (E. Holmgren.)

Processes of nerve-cells.—As already intimated the processes are of two kinds. The first kind is the *axis-cylinder process* (Deiters) or *nerve-fibre process*, so called because in myelinate nerve-fibres it becomes the axis-cylinder (fig. 236, *a*, *a'*); in amyelinate fibres it forms the nerve-fibre itself. It is also known as the *axon* or *neuraxon*, although the term *neuron*[1] would better express the fact that it is the actual nerve-fibre.

[1] From the Greek word νεῦρον, a nerve, and not to be confounded with neurōne (often erroneously termed 'neurŏn') which was invented by Waldeyer to express the whole nerve-cell with all its processes (p. 186) and is widely used in that sense.

No fully developed nerve-cell is without this process. The place where it arises from the body of the nerve-cell (*cone of origin*) is marked off from the rest of the cell-substance by absence of Nissl granules (see fig. 229). The other processes of the nerve-cell are those which were termed by Deiters 'protoplasmic processes'; they are now usually termed the *dendritic processes*, *dendrons*, or *dendrites*, and are generally multiple, whereas the axon is single. The dendrons are characterised by the fact that as soon as they leave the cell they begin to ramify like the roots of a tree, whereas the axis-cylinder process usually does not branch until near its termination. Dendrons may be altogether absent; the cell is then *adendritic*. Some nerve-cells have only one process (*unipolar cells*), but most have two or more (*bipolar*, *multipolar*). The dendrons near the cell-body contain Nissl granules, but the axons do not.



FIG. 236.—AXIS-CYLINDER PROCESS OF A NERVE-CELL FROM THE SPINAL CORD. (M. Schultze.)

× ×, portion of the cell-body, out of which the fibrils of the axis-cylinder process, *a*, are seen to emerge. At *a'*, this process acquires a myelin sheath. Highly magnified.

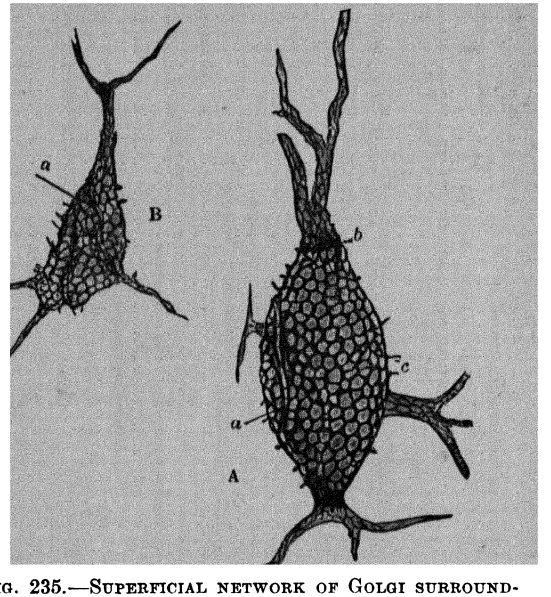

FIG. 235.—SUPERFICIAL NETWORK OF GOLGI SURROUNDING TWO CELLS FROM THE CEREBRAL CORTEX OF THE CAT; EHRLICH'S METHYLENE-BLUE METHOD. (R. y Cajal.)

A, large cell; B, smaller cell. *a*, *a*, folds in the network; *b*, a ring-like condensation of the network at the poles of the larger cell; *c*, spinous projections from the surface.

The shape of the cell-body depends largely on the number of processes and

the manner in which they come off. If there is but one chief process the cell-body is generally nearly spherical. This is the case with most of the cells of the spinal ganglia; in these the single process, after a short course, divides into two fibres, which pass the one centrally the other peripherally (fig. 237). When there are two main processes from a nerve-cell they often go off in opposite directions from the cell-body, which is thus rendered somewhat spindle-shaped (fig. 238); but occasionally they emerge at the same part. When there are three or more processes, the cell-body becomes irregularly angular (figs. 229, 230, 235).

In some cases where there appear to be two fibres connected with a cell, one is derived from another nerve-cell elsewhere, and is passing to end in a ramification which envelopes the cell-body. In certain situations the ramification is coarse and forms a calyx-like investment to the cell-body; in other places the pericellular fibrils are very delicate and form a fine arborisation over the cell-body (fig. 239). Where the fibrils come in contact with the surface of the cell they may end in small button-like enlargements or varicosities (fig. 240).

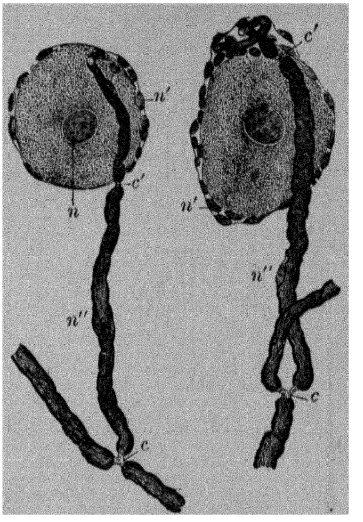

FIG. 237.—TWO SPINAL GANGLION-CELLS, SHOWING BIFURCATION OF THEIR NERVE-FIBRE PROCESSES. (Ranvier.) Osmic preparation.

n, nucleus of one of the cells; *n'*, nuclei of capsules; *n''*, nuclei of neurolemma; *c*, *c'*, constrictions of Ranvier.

In preparations made by Golgi's chromate of silver methods the nerve-cells with all their processes are coloured black by a deposit of reduced silver, so that the processes can be traced for a considerable distance from the body of the cell, in many instances as far as their remotest ramifications. It has been found by the employment of this method that the axis-cylinder process is not always an unbranched process, as was formerly supposed, but that it usually gives off fine lateral branches (*collaterals*), which themselves tend to ramify in the adjacent nerve-substance (fig. 241). And although the main part of the process usually passes on and becomes the axis-cylinder of a long myelinate nerve-fibre (*long-axoned cell*, fig. 241), this is not always the case, for in another type of nerve-cell within the nerve-centres (*short-axoned cell*, fig. 242), the axis-cylinder process breaks up almost immediately into an arborescence. The long process of the first type (which becomes the axis-cylinder of a long nerve-fibre), although it may remain unbranched throughout its course, ultimately ends in almost every instance in a terminal ramification or arborescence; and this whether the ending is at the periphery or within the central nervous system itself.

Synapses.—Each nerve-cell, including all its processes, is regarded as an anatomically independent element or *nerve-unit*, the *neurone* of Waldeyer,

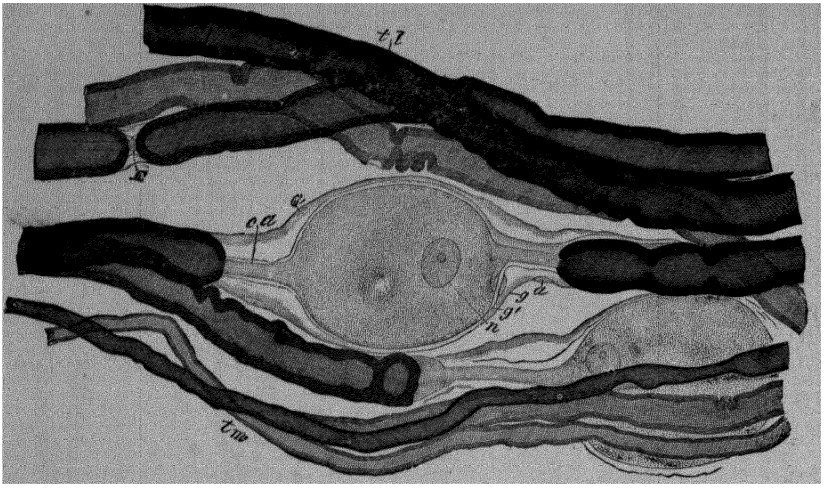

FIG. 238.—SPINAL GANGLION-CELLS AND FIBRES OF RAY. Osmic preparation. (Ranvier.)

t.l., large myelinate fibres; *t.m.*, medium-sized myelinate fibres; *E*, constriction of Ranvier; *g*, sheath of ganglion cell; *a*, *a*, nuclei of sheath; *g'*, surface of cell; *n*, its nucleus; *c.a.*, axis-cylinder process entering the cell; a similar process is seen emerging at the opposite pole. The myelin sheath of the nerve-fibres is stained black by the osmic acid.

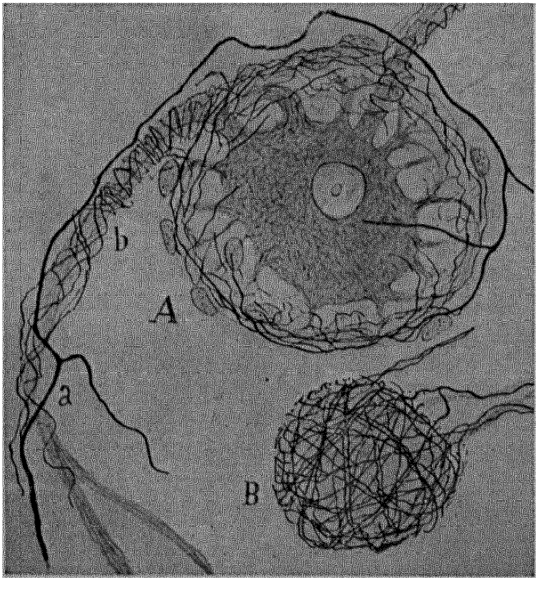

FIG. 239.—TWO CELLS FROM A SYMPATHETIC GANGLION OF MAN SHOWING THE TERMINATION OF AFFERENT FIBRES WITHIN THE CELL-CAPSULE. (R. y Cajal.)

A, large cell; B, smaller cell. a, b, afferent fibres surrounding a dendron and passing into the capsule.

and the connexion of one nerve-cell with another is believed to be effected through the medium of the terminal arborisation of their cell-processes. Such arborisations may interlace with one another, as in the olfactory glomeruli

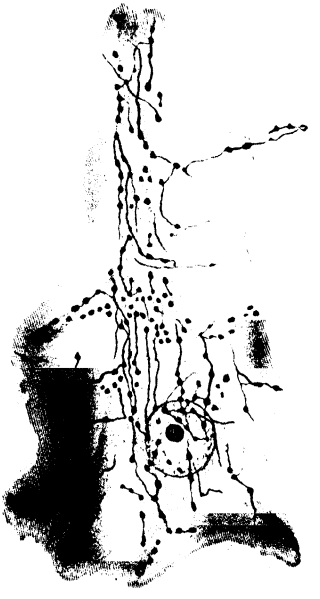

FIG. 240. — PERICELLULAR NEUROFIBRILS AROUND A LARGE PYRAMIDAL CELL OF THE HUMAN CORTEX CEREBRI. (J. Turner.)

(fig. 244), in the retina, and in sympathetic ganglia; or a terminal arborisation from one cell may embrace the body or the cell-processes of another cell; as with the cells of the spinal cord (fig. 243), the cells of the central acoustic nucleus in the pons and in many other places. The term *synapse* (*neuro-synapse*) is applied to these modes of junction (M. Foster). By them nerve-cells are linked together into long chains (*nerve-cell chains*, *neurone chains*); the anatomical

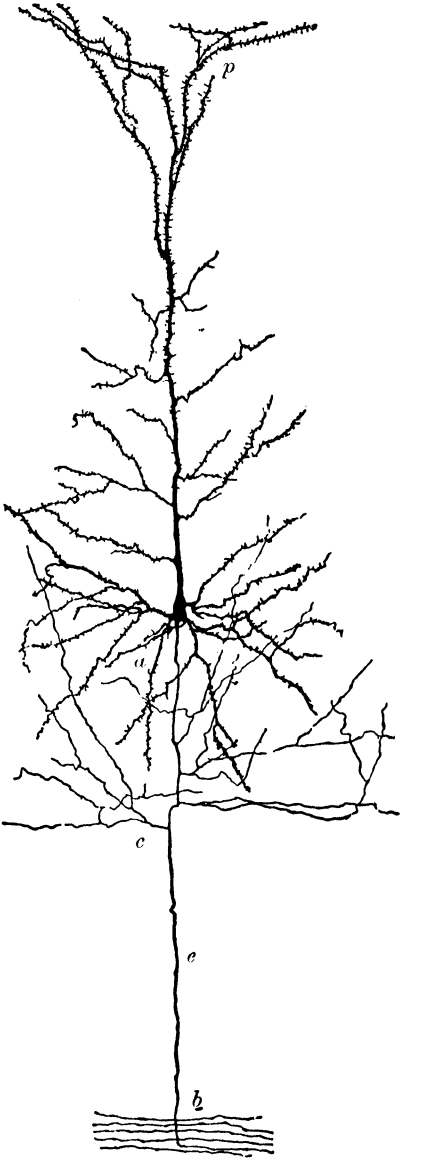

FIG. 241.—A PYRAMIDAL CELL OF THE CORTEX CEREBRI OF THE RABBIT. CELL OF TYPE I. OF GOLGI (WITH LONG AXON). (R. y Cajal.)

a, basal dendrons; *p*, apical dendron ramifying near surface; *e*, axon or nerve-fibre process; *c*, its collaterals; *b*, fibres of white matter of brain.

path, as above indicated, being interrupted at the synapses, although physiological changes (nerve-impulses) are propagated—stepping over, as it were, from one cell to the other at each synapse. Probably what really happens is a generation of new nerve-impulses in the successive cells forming the chain.

The doctrine of the anatomical independence of the nerve-cell is known as the 'neurone-theory.' It is supported by the appearances of chromate of silver (Golgi) preparations. In these the reduction of the silver is strictly confined to single cells, which become stained *with all their processes*; and these processes, when

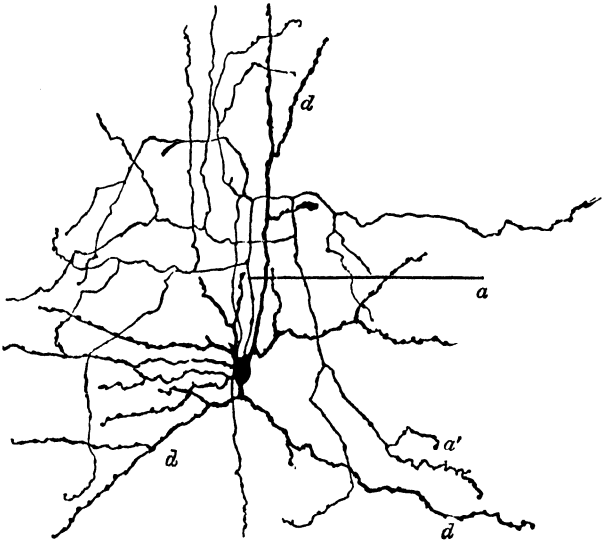

FIG. 242.—CELL OF TYPE II. OF GOLGI, WITH SHORT AXON RAMIFYING IN THE ADJACENT GREY MATTER. GOLGI METHOD. (R. y Cajal.)

a, axon; *d*, *d*, dendrons.

demonstrated by this method, are never found in continuity either with the processes or with the bodies of other nerve-cells. Moreover, many of the facts relating to nerve-degeneration can be better interpreted by this theory than by one which assumes the existence of direct continuity between the nerve-units, which Apáthy and others have thought to occur.

There undoubtedly exists a physiological independence so far as the maintenance of nutrition of the cell and its processes is concerned; and there is also evidence that, in the transmission of nerve impulses from one neurone to another, a block always occurs at the synapses, causing a slight arrest or delay in the transmission. It is also noteworthy that nerve-impulses, so far as is known, pass a synapse in one direction only, never in the reverse direction (*valve-like action*).[1] In motor or efferent nerve-cells this direction is always towards the cell-body by the dendrons and away from it by the axon, but in sensory or afferent fibres the conduction both towards and away from the cell-body is effected by nerve-fibre processes.

[1] The expression 'law of forward direction' has been employed by Sherrington to express this fact.

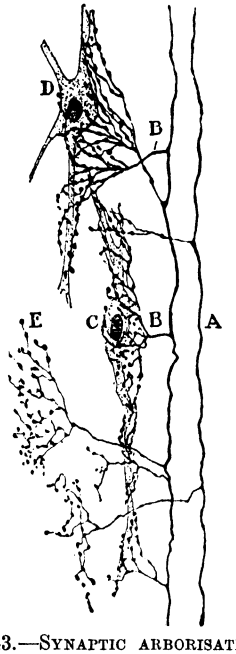

FIG. 243.—SYNAPTIC ARBORISATION OF COLLATERALS FROM THE DORSAL ROOT-FIBRES AROUND CELLS IN THE DORSAL HORN OF GREY MATTER. (R. y Cajal.)

A, fibres of dorsal column derived from dorsal root; B, collaterals; C, D, nerve-cells in grey matter surrounded by arborisations of the collaterals; E, an arborisation shown separately.

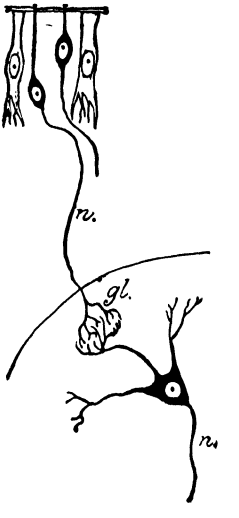

FIG. 244.—DIAGRAM OF SYNAPSE BETWEEN OLFACTORY CELLS AND CELLS OF OLFACTORY BULB. (G. Retzius.)

n, *n*, axons of the nerve-cells; *gl*, an olfactory glomerulus with a synapse between the axon of an olfactory cell and a dendron of a cell in the olfactory bulb.

CELLS OF NERVE-GANGLIA.

In ganglia (figs. 245, 246, 251) each cell-body has a nucleated sheath which is continuous with the neurolemma of the nerve-fibre which belongs to the cell. In the **spinal ganglia** of mammals and of most other vertebrates, and in many of the corresponding ganglia on the roots of the cranial nerves, the cells have only one issuing process, the axon, or nerve-fibre process. This soon acquires a myelin sheath and then passes with a convoluted course to a little distance from the cell-body, where, still within the ganglion, it divides into two; one fibre passing to the nerve-centre and the other towards the periphery. The branching is T-shaped or Y-shaped, and always occurs at a node of Ranvier (figs. 237, 247). The neuro-fibrils of the central and peripheral branches retain their individuality in the common trunk; branches from them are traceable from the T-shaped junction into a neuro-fibril network within the cell-body. The spinal ganglion-cells have, as a rule, no dendrons, but some show, besides the axons, short processes terminating in bulbous enlargements (fig. 248) either within the cell-capsule or

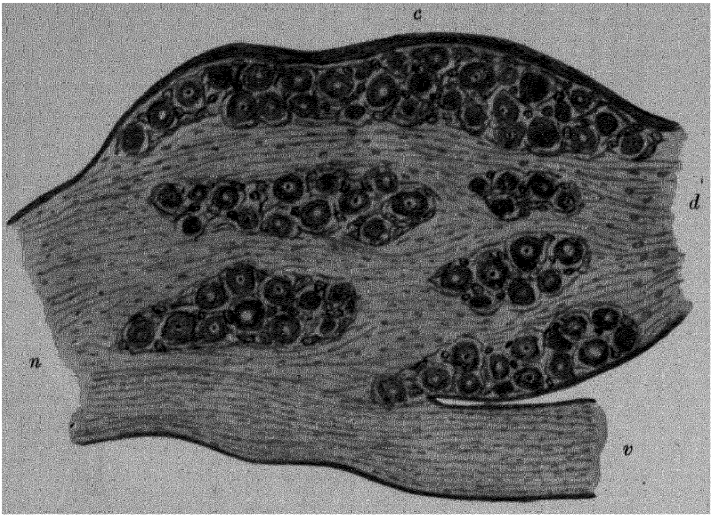

FIG. 245.—SECTION OF SPINAL GANGLION. (H. M. Carleton.) × 27. From a preparation by C. S. Sherrington.

c, capsule; *d*, dorsal root; *v*, ventral root; *n*, mixed spinal nerve.

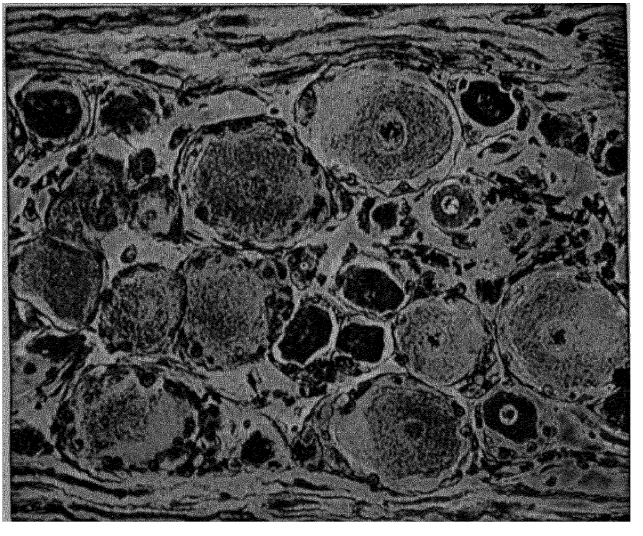

FIG. 246.—FROM A SECTION OF DOG'S SPINAL GANGLION, SHOWING DIFFERENT TYPES OF CELLS. (E. Sharpey-Schafer.) × 240.

The clear patch, free of Nissl granules, seen in some of the cell-bodies is the place of origin of the axon. Some of the cell-bodies have shrunk away from the nucleated capsule. Notice the smaller and more darkly stained cells, contrasting with the larger and clearer cells.

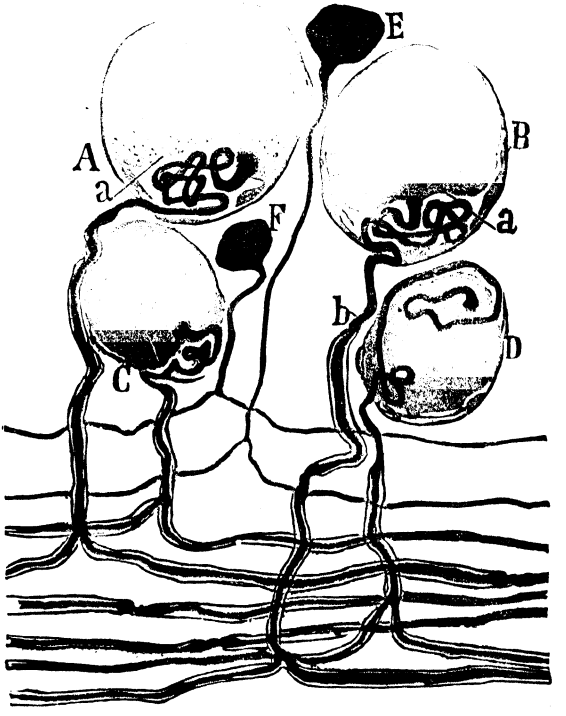

FIG. 247.—TYPES OF CEREBRO-SPINAL GANGLION-CELLS, FROM VAGUS GANGLION OF CAT. (R. y Cajal.)

A, B, large cells with much convoluted commencement of axon; C, D, smaller cells; E, F, smallest cells, staining darkly and without axonal convolution; a, a, cell-bodies; b, issuing nerve-fibre.

immediately outside it (Huber, Cajal). Short intracapsular processes frequently occur in sympathetic ganglia (fig. 252) and in senile spinal ganglion-cells.

The origin of the axon is not always simple, but may be multiple, the several parts forming at first a plexus close to the cell, eventually joining to produce a single axon. According to Cajal this multiple condition tends to become accentuated with age (fig. 249).



FIG. 248.—CEREBRO-SPINAL GANGLION-CELL. (R. y Cajal.)

a, b, intracapsular processes, with knobbed extremities.

Two chief varieties of cell occur in the spinal ganglia, one large and clear, the other small and staining almost uniformly dark (figs. 246, 247). According to Ranson, the small cells give origin to amyelinate nerve-fibres. The cell-body of the spinal ganglion-cell is sometimes invested by ramifications of a fine

nerve-fibre (fig. 250), derived either from one of the other cells of the same ganglion or from a cell in a neighbouring sympathetic ganglion. Similar fibres, forming pericellular plexuses, also occur in sympathetic ganglia (fig. 239).

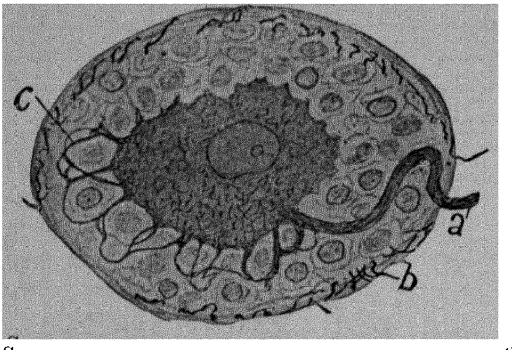

FIG. 249.—SENILE TYPE OF CEREBRO-SPINAL GANGLION-CELL. (R. y Cajal.)
a, issuing axon; *b*, part of pericellular plexus; *c*, multiple origin of axon.

Sections of **sympathetic ganglia** (fig. 251) do not show the regular arrangement of large bundles of myelinate fibres traversing the ganglion which forms a conspicuous feature in spinal ganglia. The cell-bodies are smaller;

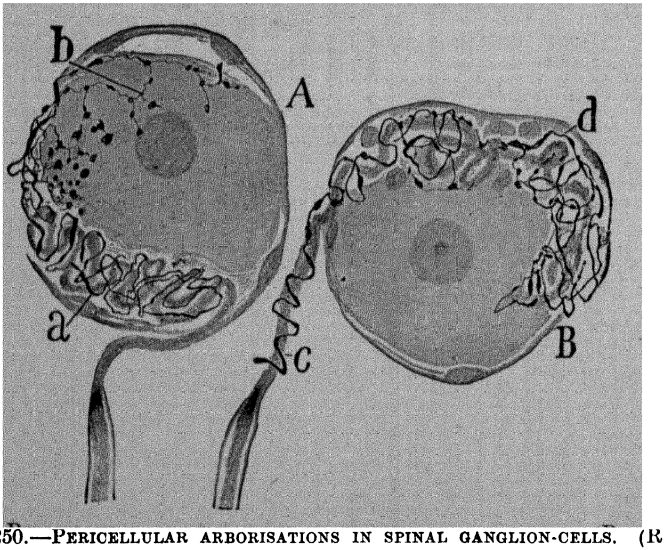

FIG. 250.—PERICELLULAR ARBORISATIONS IN SPINAL GANGLION-CELLS. (R. y. Cajal.)
In A the arborisation extends over the cell-body; in B it is limited to the axon.
a, *b*, *c*, *d*, afferent fibres.

they usually have several dendrons and one axon; this generally becomes an amyelinate nerve-fibre, but is occasionally a fine myelinate fibre. In certain animals (rabbit, hare, guinea-pig) each sympathetic cell has two nuclei. In the frog the sympathetic cells are unipolar, but sometimes show a second spiral fibre winding round the issuing axon. Such spiral fibres

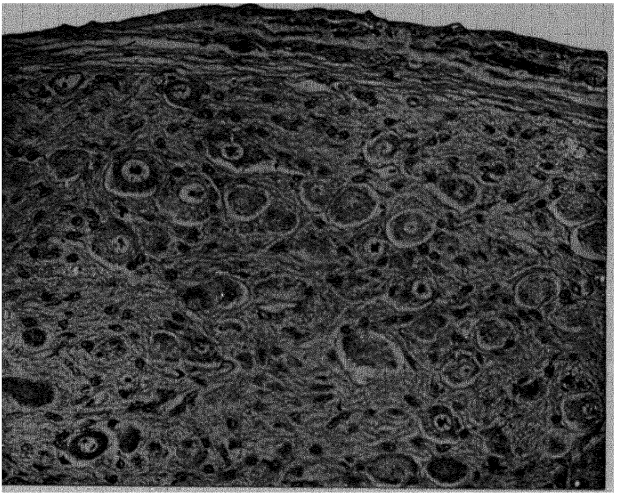

FIG. 251.—SECTION OF SYMPATHETIC GANGLION OF DOG. (E. Sharpey-Schafer.) × 240. Photograph.

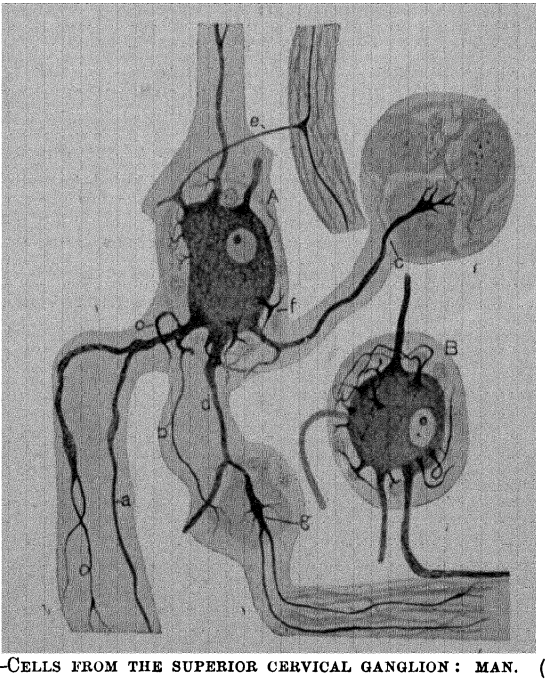

FIG. 252.—CELLS FROM THE SUPERIOR CERVICAL GANGLION: MAN. (De Castro.)

A, a cell with numerous long dendrons, some of which are passing to cells in other parts of the ganglion. From one of the long dendrons the axon (a) arises. Besides the long dendrons (b, c, d, e) there are several short ones (f), mostly ending close to the cell.

B, another cell with three long dendrons and an axon, and numerous short dendrons, ending close to the cell.

occur also in man; here, as already stated, they appear to be afferent fibres which are forming synapses around the axons and cell-bodies of the ganglion-cells (fig. 250).

The cell-bodies in both spinal and sympathetic ganglia are disposed in aggregations of different size, separated by bundles of nerve-fibres (figs. 245, 251). The ganglion if large is enclosed by an investing capsule of connective tissue which is continuous with the epineurium and perineurium of the entering and issuing nerve-trunks.

DEGENERATION AND REGENERATION OF NERVE-FIBRES AND NERVE-CELLS.

Wallerian degeneration.—Since each nerve-fibre is the process of a nerve-cell, when a nerve is cut or crushed so as to sever the continuity of its fibres the distal separated part degenerates (fig. 253). Its axis-cylinder becomes broken up and disappears, the nuclei of the neurolemma multiply, and the myelin sheath undergoes a process of disintegration into droplets of fatty substance which stain intensely black when treated by the method of Marchi (see Appendix), a procedure which does not blacken the myelin sheath of normal fibres. In the course of time the degenerated myelin disappears; this is due to its removal and digestion by phagocytes.

The network of neuro-fibrils in the nerve-endings—both motor and sensory—begins to show changes within a few hours; the fibrils swell and become blended with one another, and the mass thus formed then breaks up into portions and disappears.

The alteration in the myelin sheath of the fibres was described by the elder Waller in 1850, and is known as *Wallerian degeneration*. In man and mammals a change is apparent twenty-four to twenty-eight hours after section of the nerve, and proceeds rapidly; by the third day the nerve-fibres cease to conduct impulses.

When a peripheral nerve is cut, all the nerve-fibres distal to the point of section must undergo degeneration, because all have grown from and are processes of nerve-cells—the afferent fibres arising from the cells of the spinal ganglion on the dorsal root, the efferent fibres from the cells of the ventral horn of the spinal cord or from similar cells in the brain. This is merely an example of the general law—common to all cells—that any portion of a cell, cut off from the nucleus, after a time ceases to function and undergoes degeneration.

Waller supposed that no changes are produced centrally to the injury when a nerve is cut, nor indeed is there any obvious immediate alteration in the nerve-fibre itself between the place of injury and the cell-body. But it was found by Nissl that degenerative changes occur in the cell-body of every cell (whether motor or sensory) the axis-cylinder of which has been severed.[1] These changes become apparent a few days after section of the

[1] But section of the dorsal root-fibres central to the ganglia does not entail degeneration of the ganglion-cells from which they arise. Nor does section of a spinal nerve always entail degeneration of the ventral horn cells from which its motor fibres arise (Van Gehuchten). Why these exceptions occur is not understood.

nerve-fibre and consist in a disintegration of the Nissl granules, associated at first with a general swelling of the cytoplasm and nucleus, which last passes to the periphery of the cell-body. After a time the disintegrated chromatic substance becomes removed and the cell-body and nucleus become

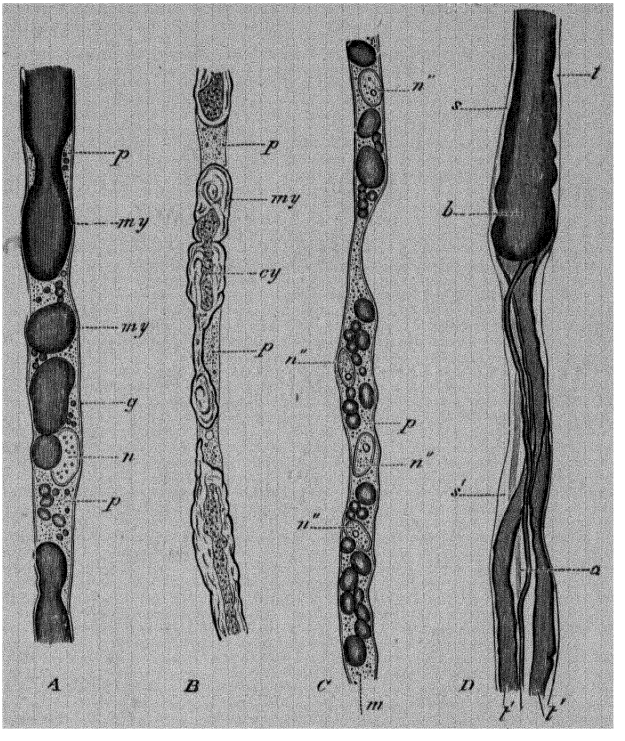

FIG. 253.—DEGENERATION AND REGENERATION OF NERVE-FIBRES IN THE RABBIT. (Ranvier.)

A, part of a nerve-fibre in which degeneration has commenced in consequence of the section, fifty hours previously, of the trunk of the nerve higher up; *my*, myelin of sheath becoming broken up into drops; *p*, granular protoplasmic substance which is replacing the myelin; *n*, nucleus; *g*, neurolemma. *B*, another fibre in which degeneration is proceeding, the nerve having been cut four days previously; *p*, as before; *cy*, axis-cylinder partly broken up, and the pieces enclosed in portions of myelin, *my*. *C*, more advanced stage of degeneration, the myelin sheath having almost disappeared, and being replaced by protoplasm, *p*, in which, besides drops of fatty substance, *m*, are numerous nuclei, *n''*, which have resulted from the division of the single nucleus of the internode. *D*, commencing regeneration of a nerve-fibre. Several small fibres, *t'*, *t'*, have sprouted from the somewhat bulbous cut end, *b*, of the original fibre, *t*; *a*, an axis-cylinder which has not yet acquired its myelin sheath; *s*, *s'*, neurolemma of the original fibre. *A*, *C*, and *D* are from osmic preparations; *B*, from an alcohol and carmine preparation.

shrunken in volume. This process of disintegration and disappearance of chromatin is termed *Nissl degeneration* or *chromatolysis*. It is brought about not only by section of the axon (fig. 229, C), but also as the result of excessive fatigue of the intact cell (fig. 231), and by the action of a large number of drugs and poisons.

The chromatolysis may be persistent or may be recovered from. Sometimes it is followed by almost complete atrophy of the cell-body; when

this is marked there may ultimately ensue a secondary Wallerian degeneration of the part of the nerve-fibre still attached to the cell.

Very little is known about the microscopic changes which ensue on section of amyelinate nerve-fibres, although it may be conjectured that they will show changes similar to those which have been described in the axis-cylinders of the myelinate fibres. That they resist degeneration longer than myelinate fibres seems clear from the fact that they will continue to conduct nerve-impulses, when artificially stimulated, for a considerably longer time after section than will the myelinate fibres. The latter generally lose their power of conducting such impulses after two or three days in mammals.

Regeneration.—After a certain lapse of time, especially if the cut ends of the nerve are brought into apposition, functional continuity between them may become re-established, at least in part. When such re-establishment of function takes place in a cut nerve, it is effected not by re-establishment of anatomical connexion between the cut-off degenerated fibres and the non-degenerated fibres of the central stump, but by an outgrowth of new fibres from that stump (figs. 253, *D*; 254; 255). If the nerve has been cut right across several buds grow out from the end of each axon in the stump. If the severance has been merely by crushing, so that the neurolemma remains intact—as by tying and releasing a ligature—the proximal end of the axon may simply grow down into the distal part of the sheath as a single fibre as shown by Langley. When the nerve is merely crushed, and not cut right across, the neurolemma is not severed, and complete restoration of function may take place within a few weeks, because each axon grows down in its original sheath and is by it conducted directly to the original termination, whatever that may have been. But when the nerve is completely cut across, scar tissue forms between the cut ends, and the newly sprouting fibres have to find their way through this scar tissue, in order to pass towards the periphery along the course of the degenerated fibres. The sheaths of the latter would serve as guides for the down-growing axons, provided that the new fibres could succeed in re-entering their original sheaths. Any that happened to do so would be able to proceed to their original destination, and their continuity and specific functions would become ultimately restored. But this restoration may not occur for many months, according to the width of the gap between the cut ends and the nature of the cicatricial tissue formed between them. Not infrequently the restoration of function, especially of afferent nerves, is permanently defective.

Some investigators have attempted to show that regeneration may take place independently in the peripheral part of the cut nerve. But no regeneration of axons occurs in the peripheral cut end, although certain changes take place there, *e.g.* multiplication of nuclei and their regular arrangement in long protoplasmic strands (occupying the old sheaths) into which the new fibres may find their way (fig. 256). But there is never actual union of the down-growing fibres of the central stump with others formed independently in the peripheral severed trunk, and of course no union with the old axis-cylinders, which have wholly disappeared.

The protoplasmic strands just mentioned were first described by Büngner, and are known by his name. Boeke has shown that even when the regenerating fibres grow not into but between the strands of Büngner they become enclosed within the protoplasm of cells and maintain an intracellular position even to their remotest end. The cells which thus conduct and probably minister to the nutrition of the growing nerve-fibres are termed by Boeke 'conducting cells.' Such cells

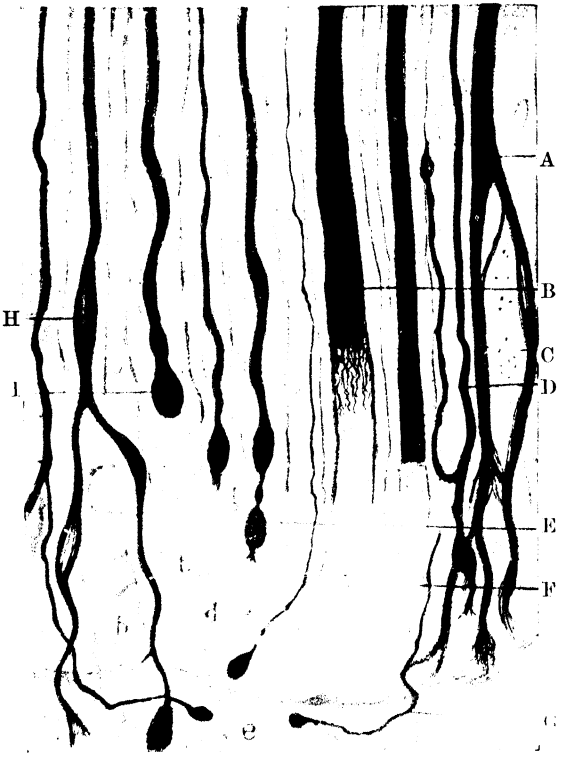

FIG. 254.—COMMENCING OUTGROWTHS FROM AXIS-CYLINDERS IN CENTRAL STUMP OF CUT NERVE. (R. y Cajal.)

A, an axon bifurcating; it shows a distinct fibrillar structure; B, an axon which has not grown out peripherally; C, nuclei of neurolemma, proliferated; D, an axis-cylinder which has bifurcated; one fork has begun to grow upwards in the stump; E, bulbous enlargement of growing end of axis-cylinder; F, empty sheath; G, fine axon with bulbous growing end; H, enlargement in the course of a budding axis-cylinder; I, bulbous end of thick axis-cylinder; b, c, d, myelin drops, escaped from the cut fibres; e, blood-clot.

are even found enclosing the growing axis-cylinders in the scar-tissue which separates the ends of a cut nerve.

The advancing axis-cylinders are usually terminated by a bulbous swelling similar to that which characterises the growing fibres of the embryonic nerves (figs. 254, 256); they may also exhibit lateral ramifications. Even when the cut central stump is turned backwards and fixed amongst the muscles or under the skin, a certain number of newly budded fibres may find their way from it into the degenerated peripheral part of the nerve, being probably directed to it by chemiotaxis.

When the union is effected between the cut ends of an ordinary mixed nerve,

sensory fibres may ultimately reach some of the sensory structures in which the original fibres terminated and motor fibres may arrive at the end-plates on the

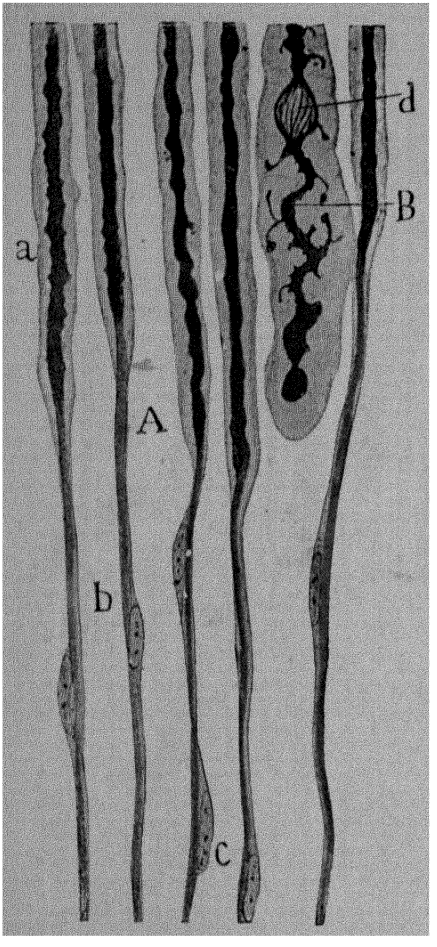

FIG. 255.—FIBRES FROM THE CENTRAL CUT END OF SCIATIC NERVE (OF YOUNG RABBIT) SEVERED TEN DAYS BEFORE DEATH. (R. y Cajal.)

A, down-growth of axons (a, b, c) above the point of section. At this level most of the fibres have been crushed, rather than cut across. B, a fibre which has been completely severed at this point shows peculiar degenerative appearances, *e.g.* buds from the axis-cylinder, and at d a separation of the neuro-fibrils.

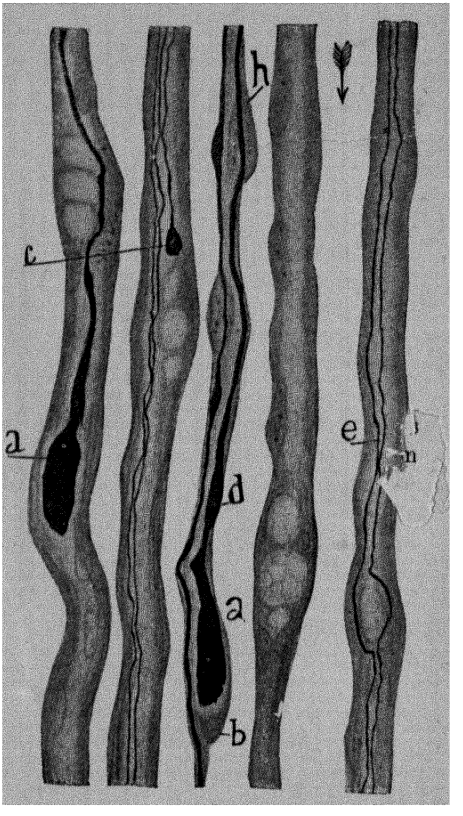

FIG. 256.—FIBRES FROM THE DISTAL END OF A NERVE CUT SEVENTY-EIGHT DAYS BEFORE DEATH. (R. y Cajal.)

Shows axis-cylinder sprouts which have grown down from the central cut end of a nerve into the old sheaths of the nerve-fibres; myelin drops are still visible within the old sheaths. Two of the new fibres (d) are interstitial (not in old sheaths), they are growing in a newly formed nucleated protoplasmic strand, h, b. Some of the down-growing fibres (a, a) show enlarged ends; c, a fine fibre with bulbous enlargement; e, two fine fibres growing down within an old sheath; to the left of this, an old sheath without new fibres.

muscle-fibres. These end-plates have for the most part remained as small collections of sarcoplasm with numerous muscle-nuclei, but have lost the terminal ramifications of the axis-cylinder. When the axis-cylinders grow down to the end-plates their terminal ramifications grow into the end-plates.

Restoration of the functions of sensory fibres appears to present much greater

difficulty than that of motor fibres, except in the case of those sensory fibres which subserve pain; these requiring no special nerve-endings such as tactile corpuscles, Pacinian corpuscles, end-bulbs, etc.

It is nevertheless possible to effect a crossed connexion between dissimilar nerves, as for example between the motor (hypoglossus) and sensory (lingual) nerves of the tongue. Boeke has shown that in this case (hypoglossus and lingualis) the hypoglossus fibres will grow down into the peripheral degenerated part of the lingualis and will form ramified endings in the mucous membrane, and the lingualis fibres will grow down into the peripheral degenerated part of the hypoglossus and form motor endings in the muscular fibres. It is also possible, as Langley and Anderson showed, to cause the cut central end of the cervical vagus to grow into the cut peripheral end of the cervical sympathetic: in this case the regenerating fibres of the vagus pass into and end within the superior cervical ganglion. Cannon has effected a similar junction between the phrenic and the cervical sympathetic.

If from any cause regeneration fail to establish itself, the central end of the cut fibre and the cell-body from which it takes origin undergo slow atrophic changes resulting from disuse. These atrophic changes may ultimately extend to other links in the cell-chain, especially in young animals; so that even remote cells in the same physiological path may eventually become atrophied (*v. Gudden's atrophy, secondary atrophy*).

No effective regeneration of cut nerve-fibres is ever seen in the brain or spinal cord. The process of degeneration of all the fibres which are cut off from their cell-bodies occurs in the same manner as at the periphery; Nissl degeneration also takes place in the cell-bodies. But in the nerve-centres the place of the degenerated nerve-fibres becomes eventually occupied by strands of fine fibres, probably formed mainly of neuroglia. These strands stain deeply with carmine and remain unstained by osmic acid and by the Weigert-Pal method, and can thus be differentiated from the surrounding normal myelinate nervous tissue.

NEUROGLIA.

Besides nerve-cells and nerve-fibres there occurs in the brain and spinal cord a peculiar tissue which has been termed *neuroglia*.[1] It is composed of cells and fibres, the latter being prolonged from and through the cells.

Of the neuroglia elements some are radially disposed. These start from the lining layer of the central canal of the spinal cord and the ventricles of the brain, being derived from the ciliated epithelium-cells lining those cavities. They course in a radial direction, slightly diverging and constantly branching as they proceed towards the surface of the organ, where they end in enlargements attached to the pia mater. Radial neuroglia-cells and fibres are seen in the embryo before the nervous elements are fully developed (fig. 260); the neuroglia-cells when first distinct form a kind of spongework.

Special methods are necessary to study the branching cytoplasm and fibres of neuroglia-cells. With stains such as hæmatoxylin and eosin, only the nuclei and a little of the adjacent cytoplasm can be seen.

According to the observations of Cajal, Penfield and others, there are four types of neuroglia-cells (figs. 257, 258, 259):

[1] From νεῦρον, and γλοιά, glue.

1. **Protoplasmic cells** (protoplasmic astrocytes of Cajal).—Almost exclusively found in grey matter. The nucleus is rounded; radiating processes spring from the cytoplasm; hence the names astrocyte and spider-

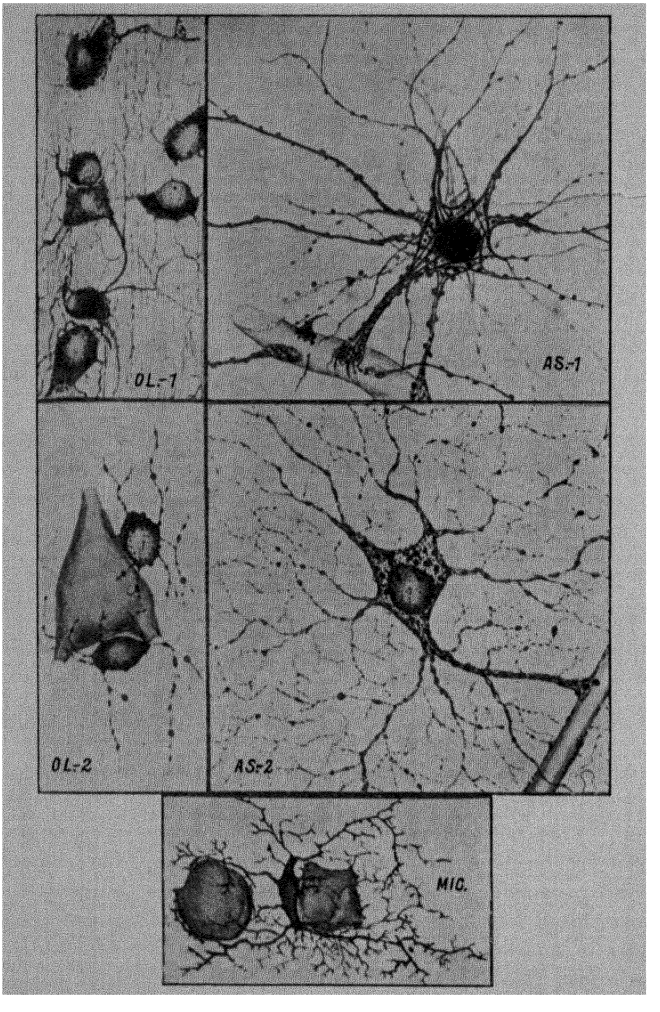

FIG. 257.—NEUROGLIA-CELLS. (Penfield and Cone.) **Highly magnified.**

OL.-1, oligodendroglia cells from white matter (interfascicular cells); *AS.-1*, **fibrous astrocyte** from white matter; *OL.-2*, oligodendroglia cells from grey matter (satellite cells); *AS.-2*, **protoplasmic astrocyte** from grey matter; *MIC.*, microglia cells. Note the attachment of the **astrocytes to blood-vessels.**

cell, by which these neuroglia-cells are also known. Often the processes end in expansions (vascular feet) which are closely applied to the capillary blood-vessels. There are no fibres in the cytoplasm.

2. **Fibrous cells** (fibrous astrocytes of Cajal). Almost exclusively found in white matter. The radiating processes are much longer than those of the

protoplasmic cells; they also comprise thick fibres, often attached to blood-vessels. Their purpose is to support and bind together the nervous elements.

3. **Oligodendroglia cells.**—More frequent in white than grey matter. Oligodendroglia cells are smaller than 1 and 2; they do not contain fibres; they have no vascular feet.

4. **Microglia cells.**—More numerous in the grey than in the white matter.

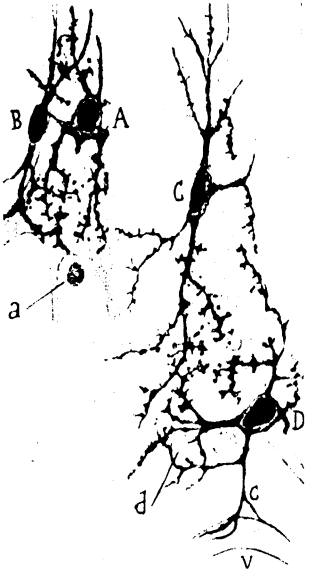

FIG. 258.—NEUROGLIA - CELLS FROM CORTEX CEREBRI (CAT). (R. y Cajal.)

A, B, C, oligodendroglia cells attached to large pyramids; D, an astrocyte, attached on the one hand to the base of a pyramid, on the other (c) to a blood-vessel v; a, d, small adendric satellite cells.

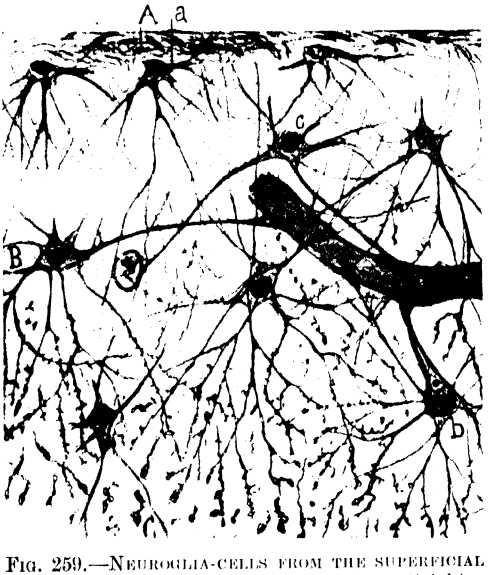

FIG. 259.—NEUROGLIA-CELLS FROM THE SUPERFICIAL LAYER OF THE CEREBRUM (DOG). (R. y Cajal.)

A, fibrous cap with astrocytes (a) partly embedded in it; B, b, c, astrocytes, with intracellular fibrils and 'feet' attached to blood-vessels; C, enlarged endings of their other branches.

The cell-bodies and processes are very irregular, branch freely, and end in terminal spines. As the name implies, they are smaller than the other types of neuroglia-cells. Under pathological conditions they may become amœboid and phagocytic. There is some reason to suppose that they are mesodermic in origin, in contrast with 1, 2 and 3, which are certainly ectodermic.

HISTOGENESIS OF THE NERVOUS SYSTEM.

Development of nerve-cells.—All nerve-cells are developed from the cells of the neural groove and neural (ganglionic) crest which separates off when the groove closes to form the neural canal. The cells of the neural canal

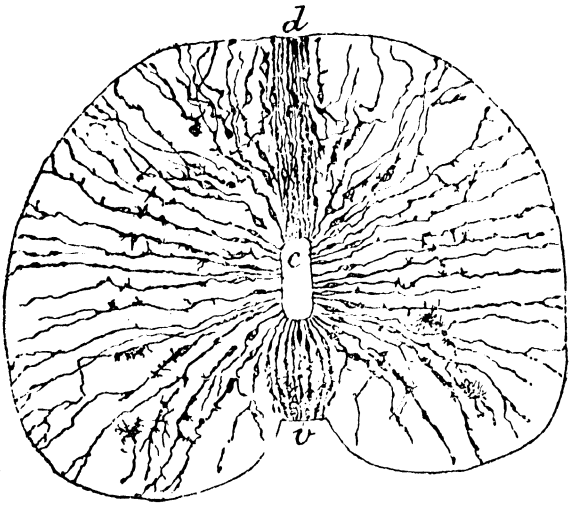

FIG. 260.—SECTION OF SPINAL CORD OF EMBRYO CHICK, SHOWING NEUROGLIA-FIBRES PROLONGED FROM THE EPITHELIUM OF THE CENTRAL CANAL. (R. y Cajal.)

d, dorsal; *v*, ventral surface; *c*, central canal from which the neuroglia-cells and fibres are seen to radiate to the periphery of the cord. Some detached neuroglia-cells are also represented.

form the spinal cord and brain, and the neural crest gives off at intervals sprouts which become the rudiments of the spinal ganglia.

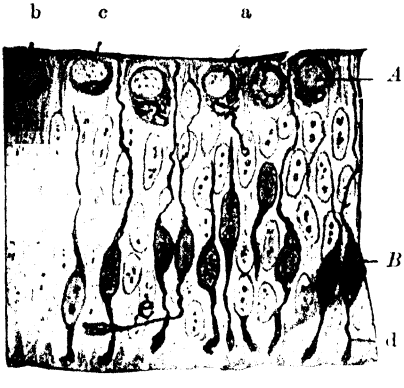

FIG. 261.—SECTION OF PART OF NEURAL CANAL OF CHICK OF TWO AND A HALF DAYS. (R. y Cajal.)

A, germinal layer containing spherical neuroblasts, a, b, c (a neuro-fibril has already begun to grow out from a); *B*, neuroblasts in a bipolar stage; d, enlarged end of growing axon; e, another axon growing tangentially.

The cells which line the neural canal are at first all long columnar cells, but amongst these, and probably produced by cell-division from some of them (fig. 261, *A*), spherical and spindle-shaped cells, which give origin to nerve-cells, make their appearance, and rudimentary nerve-fibres presently grow out from them. These cells are termed *neuroblasts*. The remaining cells of the neural canal are known as *spongioblasts*; they give origin to neuroglia-cells.

Development of the efferent nerves.—The nerve-fibres which eventually form the ventral (anterior) roots of the nerves, as well as others which remain within the central nervous system, are developed from the neuroblasts. From each a single process first grows out. This is the axon; it is characterised by an enlarged extremity (figs. 261, 262, 263). Some of the growing axons

emerge from the ventro-lateral region of the canal and become the axis-cylinders of the motor or efferent nerves. The dendrons appear later than the axons. The axon processes of those neuroblasts which do not pass out with the nerve-roots but continue within the nerve-centre become developed into intercentral fibres.

Harrison directly observed the outgrowth of the axon processes of the neuroblasts of the amphibian larva in isolated neuroblasts examined in serum under the microscope. The growth of nerve-fibres can also be seen at the ends of the developing nerve-fibres in the tail of the tadpole (fig. 264). In this case, as

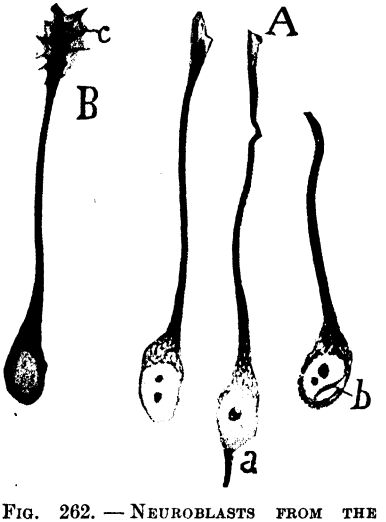

FIG. 262. — NEUROBLASTS FROM THE SPINAL CORD OF A THIRD-DAY CHICK EMBRYO. (R. y Cajal.)

A, three neuroblasts, stained by Cajal's reduced silver method, showing a network of neurofibrils in the cell-body; a, a bipolar cell. B, a neuroblast stained by the method of Golgi, showing the incremental cone, c.

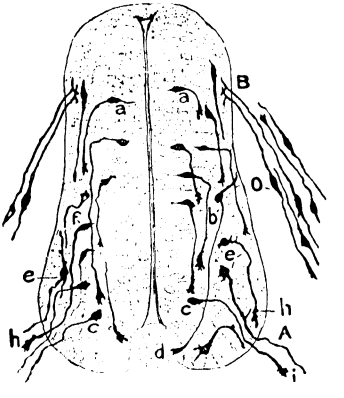

FIG. 263.—SECTION OF SPINAL CORD OF CHICK OF THIRD DAY OF INCUBATION. (R. y Cajal.)

A, ventral root-fibres formed by outgrowths of motor neuroblasts, c, e; B, dorsal root-fibres formed by ingrowths of bipolar sensory neuroblasts, O, in ganglion rudiment; a, early neuroblasts; b, neuroblast giving rise to a commissural nerve-fibre, d; h, i, enlarged ends of growing axons; e, e, neuroblasts of which the dendrons are beginning to appear.

normally in all others within the body, the growing fibres are not free but are enclosed in elongated, nucleated cells—the *lemmal* or *sheath cells*. Harrison has recently shown that the sheath cells have nothing to do with the formation of the axon. Nor are they mesodermic; they are derived from the neural crest. If this is removed the efferent nerves grow out as usual from neuroblasts within the cord, but are not surrounded by lemmal cells and develop no neurolemma. The sensory roots and ganglia, which take origin from the cells of the crest, are of course not formed at all under these conditions. The sheath cells appear to represent neuroglia in peripheral nerves.

Development of the afferent nerves.—The afferent nerve-fibres, which are characteristic of the dorsal roots, are developed as sprouts from the cells of the neural crest (p. 199), which are therefore also neuroblasts. Each cell becomes elongated and from either end an axon grows out, so that the cells become bipolar (figs. 263, 265). One set of processes, forming the *dorsal*

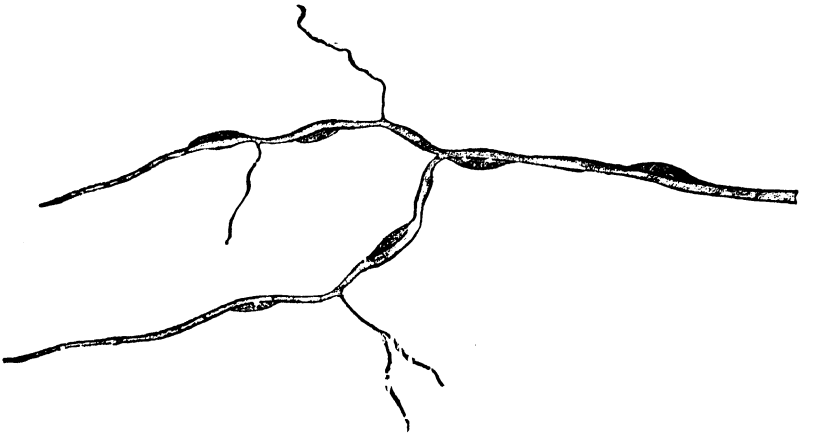

FIG. 264.—GROWING NERVE-FIBRES IN TAIL OF TADPOLE. (Kölliker.)

e nerve fibres, which are amyelinate, are growing into elongated nucleated cells, which probably represent the 'conducting cells' of Boeke.

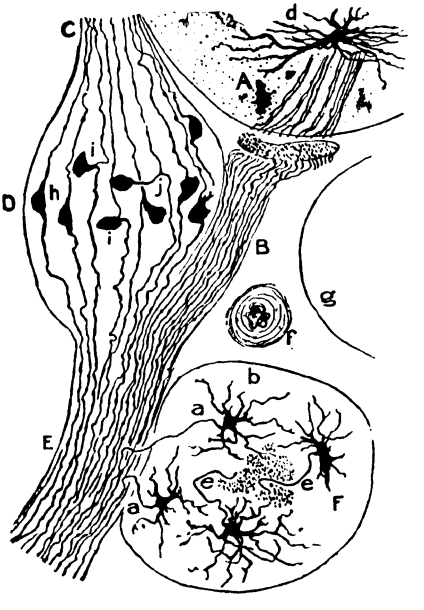

FIG. 265.—SPINAL AND SYMPATHETIC GANGLIA AND PART OF SPINAL CORD OF CHICK OF SEVENTEENTH DAY OF INCUBATION. (R. y Cajal.)

, ventro-lateral part of spinal cord with d, a motor nerve-cell; the fibres of the ventral root are seen emerging and passing to B (the connexion appears interrupted in the section); C, posterior root formed of fibres which have grown from the ganglion-cells in D, a spinal ganglion; E, mixed spinal nerve; F, sympathetic ganglion; a, a, axons of sympathetic cells, passing to join the spinal nerve; b, dendrons of these cells; e, e, axons passing to the sympathetic cord; h, cells of spinal ganglion still bipolar; i, i, bipolar cells becoming transformed into unipolar; j, unipolar cell with T-junction; f, section of artery; g, body of vertebra.

(*posterior*) *root*, grows into the dorsal portion of the neural canal: these fibres ramify in the developing grey matter; the other set, containing the afferent fibres of the spinal nerves, remains outside the canal and grows towards the developing ventral root, the fibres eventually mingling to form the mixed nerve. As development proceeds, the bipolar ganglion cells become gradually transformed in most vertebrates by a shifting of the two axons into unipolar cells (fig. 265, h, i, j); but in some fishes the cells remain permanently bipolar (fig. 238). This is also the case, in all vertebrates, with the ganglion-cells of the eighth cranial nerve (ganglion of Scarpa and ganglion of the cochlea).

Development of sympathetic nerves and ganglia.—The ganglia on the sympathetic and on other peripheral nerves are developed from small collections of neuroblasts which have become detached from the rudiments of the spinal ganglia; they give origin to axons and dendrons much in the same way as do the neuroblasts within the central nervous system.

Development of the nerve-sheaths.—The myelin sheath and the nucleated sheath (neurolemma) of the nerve-fibres are developed quite differently from one another. The myelin is formed by the axis-cylinder itself, whilst the neurolemma with its nuclei is derived from the sheath cells (*lemmal cells*) which have wandered out from the ganglionic outgrowths of the neural crest (see p. 201).

Development of neuroglia. The neuroglia cells are developed from the spongioblasts of the neural canal. These, in place of giving off an axon and dendrons like the neuroblasts, send out a number of fine processes in all directions from the cell-body; fibres are formed in some of these. As already stated, one type of neuroglia (microglia), appears to be developed from mesoderm.

LESSON XIX.

MODES OF TERMINATION OF NERVE-FIBRES.

1. **Pacinian corpuscles.**—Shell out a Pacinian corpuscle from a piece of cat's mesentery, which may either be fresh or have been kept for a few days in 2 per 1000 chromic acid or in 5 per cent. formol. Clear it as much as possible of adhering fat, but be careful not to prick or otherwise injure the corpuscle itself. Mount in water or saline with a thick hair on either side to prevent crushing with the cover-glass. Sketch the corpuscle under a low power, and afterwards draw under a high power the part of the core where the nerve enters and the part where it terminates. Notice the fibrous structure of the lamellar tunics of the corpuscle and the oval nuclei belonging to flattened endothelial cells which cover the tunics. The distinct lines, which when seen in the fresh corpuscles are generally taken for the tunics, are really the optical sections of these flattened cells. Pacinian corpuscles may also be observed in sections of skin in the subcutaneous tissue of various parts.

2. **Tactile corpuscles.**—Tactile corpuscles may be seen in sections of the palmar skin of the hand and fingers. Their study will be reserved for the present.

3. **End-bulbs.**—Dissect off a small portion of conjunctiva from the fresh eye of a calf. Spread it out on a slide with the under surface uppermost, and place upon it a drop of 1 per 1000 methylene-blue solution. Watch the preparation with a low power until the nerve-fibres come into view, then cover the preparation and trace them with the high power. They will be seen to terminate in end-bulbs.

Somewhat similar endings can be shown in the same manner in a piece of parietal peritoneum stripped off, laid out flat upon a slide and placed in methylene-blue solution. Do not cover the preparation until the nerve-fibres begin to show up.

4. **Grandry and Herbst corpuscles.**—Study the corpuscles of Grandry and Herbst in sections of the skin covering the duck's bill.

5. **Free nerve-endings.**—Mount in glycerine sections of a rabbit's cornea which has been stained with chloride of gold by Klein's method (see Appendix). The sections should be cut by the freezing method. Notice the arrangement in plexuses of the darkly stained nerve-fibres and fibrils: (1) in the connective-tissue substance, (2) under the epithelium, and (3) between the epithelial cells. Make one or two sketches showing the arrangement of the fibrils.

6. **Nerve-endings in muscle.**—Spread out a shred of muscle which has been stained with chloride of gold by a combination of Ranvier's and Löwit's methods (see Appendix), and examine it with a low power to find the nerve-fibres crossing the muscular fibres and distributed to them. Occasionally nerve-fibres which end in muscle-spindles (sensory endings) may be observed.

The shreds of muscle are advantageously thinned out for observation by pressure upon the cover-glass: they should not be separated into their fibres. Search thoroughly for the close terminal ramifications (end-plates) of the axis-cylinders immediately within the sarcolemma. The endings are readily shown in the muscles of reptiles such as snakes and lizards and in the eye-muscles of mammals.

SENSORY NERVE-ENDINGS.

Sensory nerve-fibres end either in *special terminal connective-tissue organs* or in *free terminal ramifications*. Within the special organs the actual nerve-ending is also generally ramified.

Nerve-endings in special connective-tissue organs.—Three chief kinds of these special organs are usually described, represented in man by *end-bulbs*, *tactile corpuscles*, and *Pacinian corpuscles*. The type is the same in all: a lamellated connective-tissue *capsule* encloses a *core* of a soft material which appears to be mainly composed of protoplasmic cells. The capsule is an expansion of the perineurium of the nerve. Within the core the axis-cylinder terminates either simply or by an arborescence. The variations which occur are chiefly due to the complexity of this arborescence and that of the

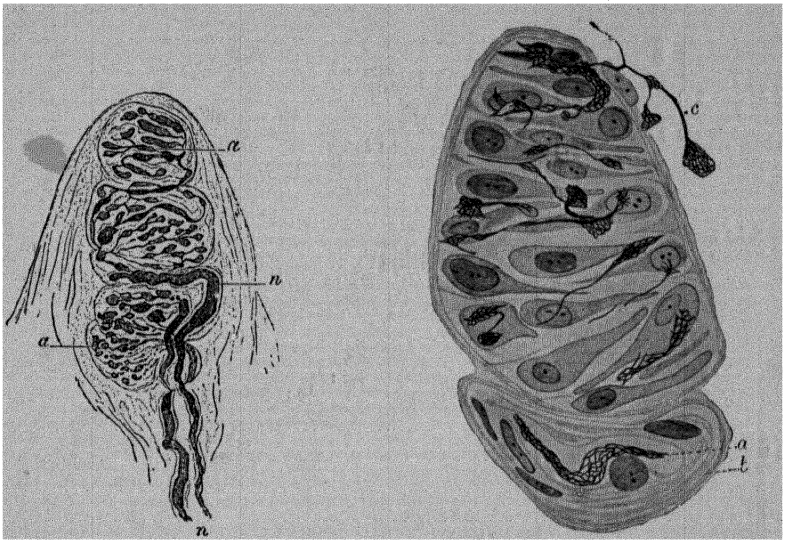

FIG. 266.—TACTILE CORPUSCLE WITHIN A PAPILLA OF THE SKIN OF THE HAND, STAINED WITH CHLORIDE OF GOLD. (Ranvier.)

n, two nerve-fibres passing to the corpuscle; *a*, *a*, varicose ramifications of the axis-cylinders within the corpuscle.

FIG. 267.—SECTION OF A TACTILE CORPUSCLE, SHOWING THE CELLS COMPOSING THE CORE AND THE RAMIFICATIONS OF THE AXIS-CYLINDER AMONG THEM, ENDING IN FIBRILLATED ENLARGEMENTS. (Van de Velde.)

a, axis-cylinder; *b*, capsule of corpuscle; *c*, a nerve-termination outside the corpuscle.

capsule, which is simplest in the end-bulbs and most complex in the Pacinian corpuscles.

In **end-bulbs** and **tactile corpuscles** the perineural connective-tissue sheath of the myelinate fibre expands to form a bulbous enlargement, which is cylindrical or spheroidal in end-bulbs and ellipsoidal in tactile corpuscles. In both kinds of end-organ as the nerve-fibre enters (in the tactile corpuscle this only happens when it has reached the distal extremity after having wound spirally once or twice round the corpuscle) it loses its sheaths and is prolonged as an axis-cylinder only. This generally soon ramifies and its branches terminate after either a straight or a convoluted course within the organ; it sometimes remains almost unbranched (see figs. 266 to 272).

Tactile corpuscles occur in some of the papillæ of the skin of the hand and foot,

in sections of which they will be studied (see fig. 390). End-bulbs are found in the conjunctiva of the eye, where in most animals they have a cylindrical or oblong shape, but in man they are spheroidal (fig. 268). They have also been found in papillæ of the lips and tongue, in serous membranes, in tendons and

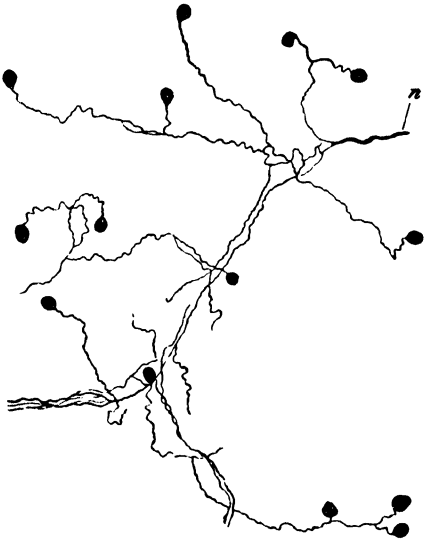

FIG. 268.—END-BULBS AT THE TERMINATIONS OF NERVES IN THE HUMAN CONJUNCTIVA, AS SEEN WITH A LENS. (Longworth.)

aponeuroses, and in the epineurium of the nerve-trunks; and somewhat similar sensory end-organs (*genital corpuscles*) also occur in the integument of the penis and clitoris (fig. 269, 272). Similar bodies of larger size are also met with in the neighbourhood of the joints (*articular corpuscles*). In the skin covering the duck's bill,

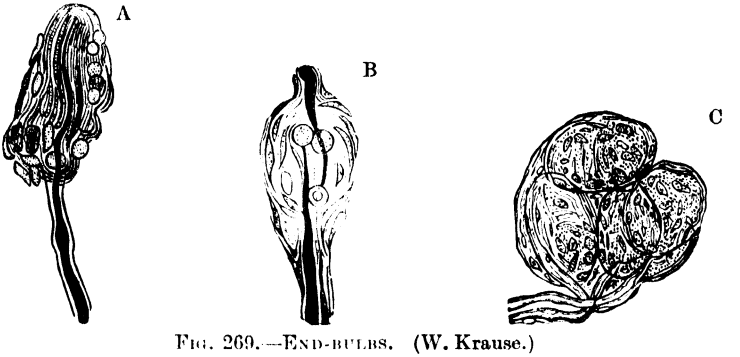

FIG. 269.—END-BULBS. (W. Krause.)

A and B from the clitoris of the rabbit; C, a compound end-bulb from the human clitoris.

a simple form of end-organ (*corpuscle of Grandry*, fig. 273) occurs, consisting of two or more cells piled up within a capsule, with the axis-cylinder terminating in flattened expansions (*tactile disks*) between the cells. These so-called tactile disks are composed, like the terminations of axis-cylinders everywhere, of neuro-fibrils

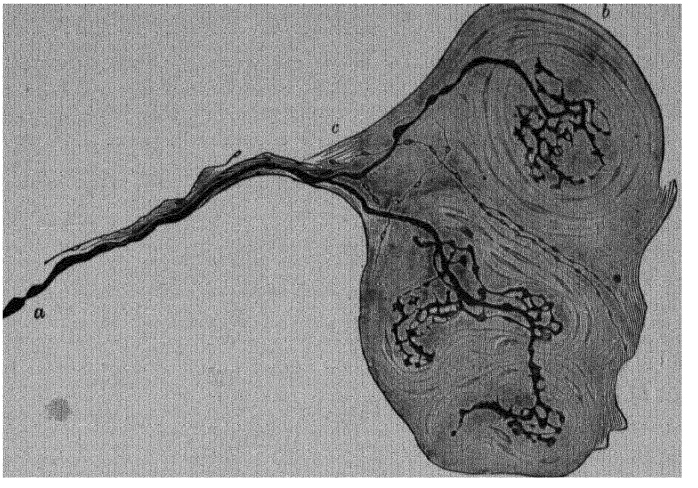

FIG. 270.—END-BULBS FROM THE HUMAN PERITONEUM. METHYLENE-BLUE PREPARATION. (Dogiel.) Highly magnified.

a, myelinate fibre; *b*, nucleated lamellated capsule of end-bulb; *c*, amyelinate fibres, probably destined for the capillaries which surround the end-bulbs.



FIG. 271.—END-BULB FROM THE CENTRAL TENDON OF THE DIAPHRAGM OF THE DOG. (Dogiel.) Showing besides the main myelinate fibre terminating by an arborescence within the core, a second very fine myelinate fibre, forming a more delicate arborescence around the ending of the main fibre in the outer part of the core. Methylene-blue preparation.

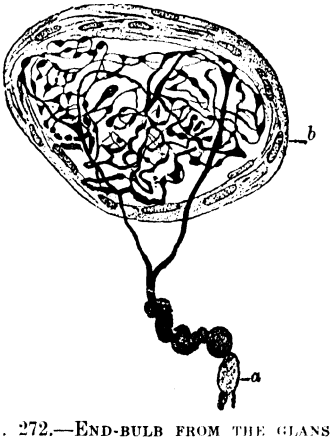

FIG. 272.—END-BULB FROM THE GLANS PENIS, SHOWING TERMINATION OF AXIS-CYLINDER. METHYLENE-BLUE PREPARATION. (Dogiel.)

a, myelinate nerve-fibre; *b*, sheath of end-bulb.

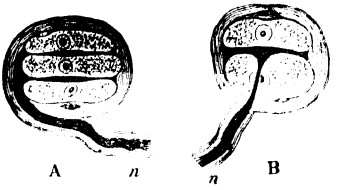

FIG. 273.—GRANDRY CORPUSCLES FROM THE DUCK'S TONGUE. (Izquierdo.)

A, composed of three cells, with two interposed disks, into which the axis-cylinder of the nerve, *n*, is observed to pass; in B there is but one tactile disk enclosed between two tactile cells.

which in the disk are arranged in a close network. Heringa, working with Boeke, has shown that this network is prolonged into the protoplasm of the cells which bound the disks, so that the actual ending of the axis-cylinder is intracellular. It is not improbable that this will prove true for many other instances of sensory nerve-termination; it has long been known to be the case with motor nerve-endings.

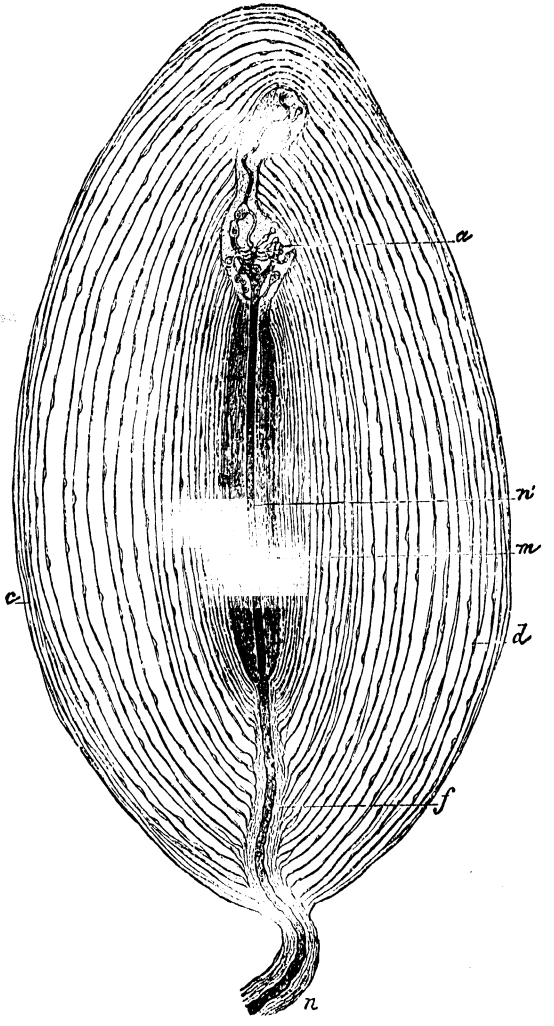

FIG. 274.—MAGNIFIED VIEW OF A PACINIAN BODY FROM THE CAT'S MESENTERY. (Ranvier.)

n, stalk of corpuscle with nerve-fibre, enclosed in sheath of Henle, passing to the corpuscle; *n'*, its continuation through the core, *m*, as axis-cylinder only; *a*, its terminal arborisation; *c*, *d*, sections of endothelial cells of tunics, often mistaken for the tunics themselves; *f*, channel through the tunics which expands into the core of the corpuscle.

Pacinian corpuscles (figs. 274, 275) are larger and have a more complex structure than the tactile corpuscles and end-bulbs. They are composed

of a number of concentric coats arranged like the layers of an onion, and enclosing the prolonged end of a nerve-fibre. A single myelinate nerve-fibre goes to each Pacinian corpuscle, encircled by a prolongation of the perineurium (*sheath of Henle*), and within this by endoneurium; when it reaches the corpuscle, of which it appears to form the stalk, the lamellæ of the perineurium expand into the tunics of the capsule. The nerve passes on,

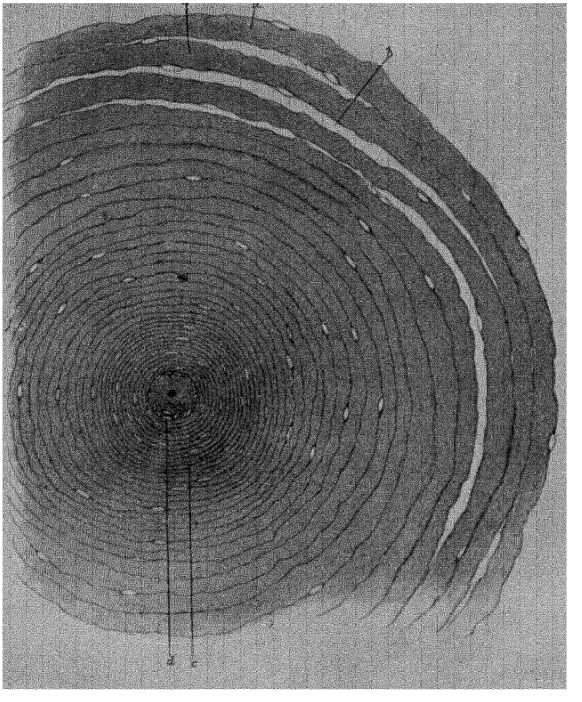

FIG. 275.—SECTION OF PACINIAN CORPUSCLE. (E. Sharpey-Schafer.)

a, *a'*, outer tunics of capsule; *b*, space between two tunics; *c*, *d*, inner tunics closely packed around the core, in the middle of which the axis-cylinder is cut across.

piercing the tunics, surrounded by endoneurium and still provided with myelin sheath, to reach the central part of the corpuscle. Here the endoneurium gives place to a core of cylindrical shape, along the middle of which the nerve-fibre, now deprived of its myelin sheath and neurolemma, passes in a straight course as a simple axis-cylinder (fig. 274, *n'*) to terminate at the farther end of the core, either in an arborisation or in a bulbous enlargement. In its course through the core it may give off lateral ramifications, which penetrate to all parts of the core, and themselves end in fine branches.

The tunics of the capsules are composed of connective tissue, the fibres of which for the most part run circularly. They are covered on both surfaces

with a layer of flattened endothelial cells (fig. 276), and here and there cleft-like lymph-spaces can be seen between them like those between the layers of the perineurium of a nerve.

Occasionally the axis-cylinder passes completely through one Pacinian corpuscle, reacquires its sheaths, and eventually ends in another corpuscle.

A simple form of Pacinian corpuscle with fewer tunics and a core formed of regularly arranged cells is found in birds (*corpuscle of Herbst*, fig. 277).

Besides the myelinate fibre, which is always very conspicuous, it has been shown that both the Pacinian and Herbst corpuscles receive a fine amyelinate nerve-fibre which arborises over the outer surface of the core. A similar

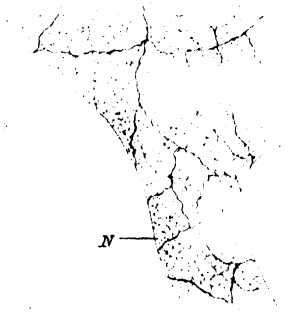

FIG. 276.—ENTRANCE OF NERVE (*N*) INTO PACINIAN CORPUSCLE. NITRATE OF SILVER PREPARATION. (E. Sharpey-Schafer.)

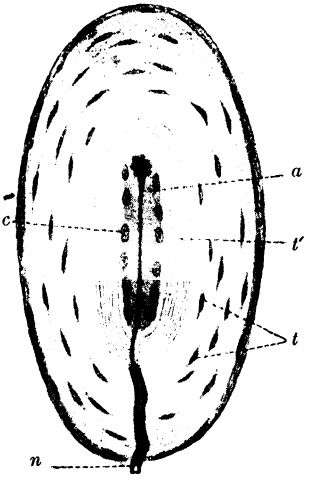

FIG. 277.—HERBST CORPUSCLE OF DUCK. (Sobotta.) × 380.

n, myelinate nerve-fibre; *a*, its axis-cylinder, terminating in an enlargement at end of core; *c*, nuclei of cells of core; *t*, nuclei of cells of outer tunics; *t'*, inner tunics.

arrangement also obtains in Grandry's corpuscles, where the tactile cells are surrounded with such an arborisation (Dogiel and others).

Pacinian corpuscles occur in many situations, especially the deeper layers of the skin of the hands and feet and penis, the periosteum of bones, especially in the neighbourhood of tendons and ligaments, and the connective tissue at the back of the abdomen. In the cat they are found very numerously in the mesentery, where they are most easily obtained.

Although most of the nerve-endings in connective-tissue structures are enclosed within lamellated capsules, nerves are found to end in some situations in arborisations between bundles of connective-tissue fibres. This has been shown by Dogiel to occur in intermuscular connective-tissue septa (fig. 278), and in serous membranes; in the latter such arborisations may be quite superficial and placed just below the endothelium.

Organs of Ruffini. These, which resemble long cylindrical end-bulbs, are connective-tissue bundles, within which the axis-cylinders of the nerves

ramify, ending in flattened expansions (fig. 279). They occur fairly numerously in the subcutaneous tissue of the fingers. Other bulb-like organs,

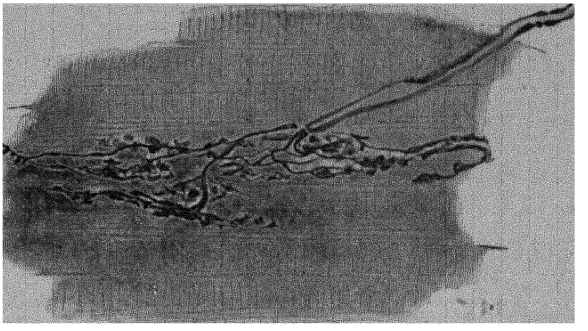

FIG. 278.—TERMINAL ARBORISATION FROM THE INTERMUSCULAR CONNECTIVE-TISSUE OF THE RECTUS ABDOMINIS OF THE RABBIT. METHYLENE-BLUE PREPARATION. (Dogiel.)

spheroidal, oval, or cylindrical in form, have been described by Ruffini under the name of Golgi-Mazzoni corpuscles (fig. 280); they appear to be varieties of the end-bulb. They also occur in the subcutaneous tissue of the pulp of the finger and in tendons.

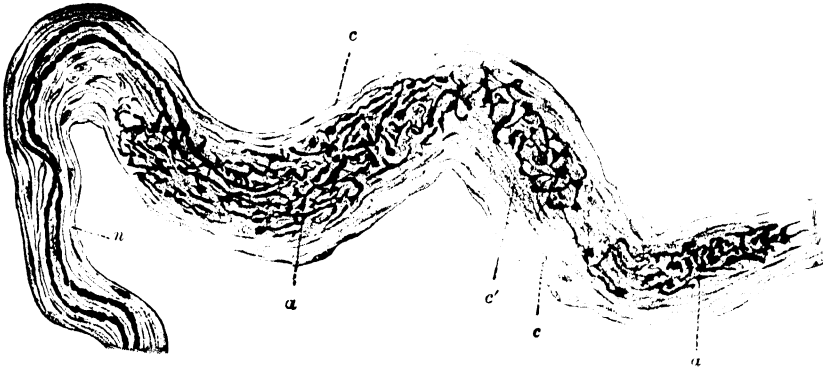

FIG. 279.—AN ORGAN OF RUFFINI FROM THE SUBCUTANEOUS TISSUE. (Ruffini.)
n, entering nerve-fibres; *a*, *a*, ending of their axons; *c*, *c*, capsule of organ; *c'*, core.

Organs of Golgi.—A special mode of nerve-ending is met with in many tendons, near the points of attachment of the muscular fibres. The tendon-bundles become somewhat enlarged and split into smaller fasciculi, and the nerve-fibres—one, two, or even more in number—pass to the enlarged parts and penetrating between the fasciculi lose their myelin sheaths, while the axis-cylinders end in a terminal arborisation, beset with irregular varicosities. The structure (figs. 281, 282) is enclosed within a fibrous capsule continuous



FIG. 280.—ORGAN OF GOLGI-MAZZONI FROM SUBCUTANEOUS TISSUE. (Ruffini.)
The organ resembles an end-bulb in general structure.

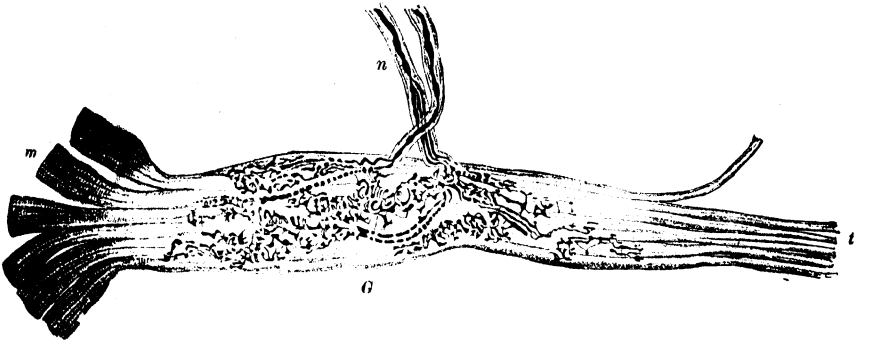

FIG. 281.—ORGAN OF GOLGI FROM THE HUMAN TENDO ACHILLIS. CHLORIDE OF GOLD PREPARATION. (Ciaccio.)
m, muscular fibres; *t*, tendon-bundles; *G*, organ of Golgi; *n*, two nerve-fibres passing to it.

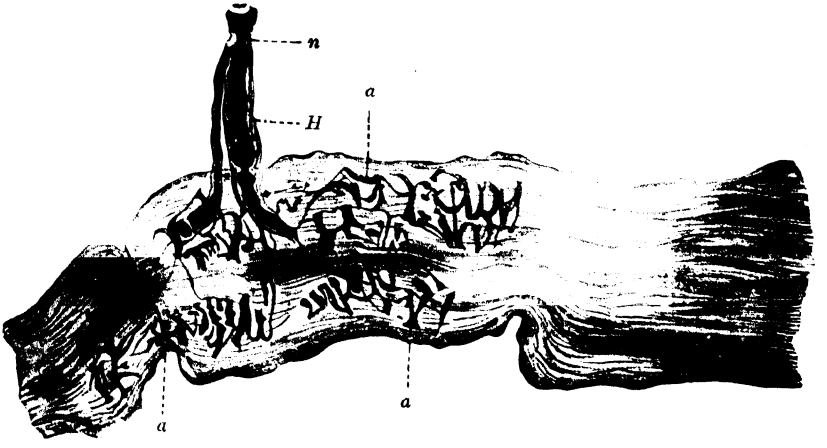

FIG. 282. [illegible] OF GOLGI, MORE HIGHLY MAGNIFIED. (Ciaccio.)
n, entering [illegible] *H*, its sheath of Henle; *a*, *a*, ramification of axis-cylinders between the tendon-bundles.

with the areolar tissue covering the bundles of the tendon; between the capsule and the organ proper is a lymph-space, similar to that which is found in the muscle-spindle (see p. 216).

Free nerve-endings.—When sensory nerve-fibres end in epithelium, they generally branch once or twice in the sub-epithelial connective tissue on nearing their termination. The sheaths of the fibres then successively become lost, first the connective tissue or peri-neural sheath, then the myelin sheath, and lastly the neuro-lemma, the axis-cylinder with its neuro-fibrils being alone continued. This branches and interlacing with the ramifications of the axis-cylinders of neighbouring nerve-fibres forms a primary plexus. From the primary plexus smaller branches come off, and form a secondary plexus nearer the surface, generally immediately under the epithelium if the ending is in a membrane covered by that tissue. Finally, from the secondary plexus nerve-fibrils proceed and terminate by ramifying amongst the tissue-cells (figs. 283, 284), the actual ending being generally

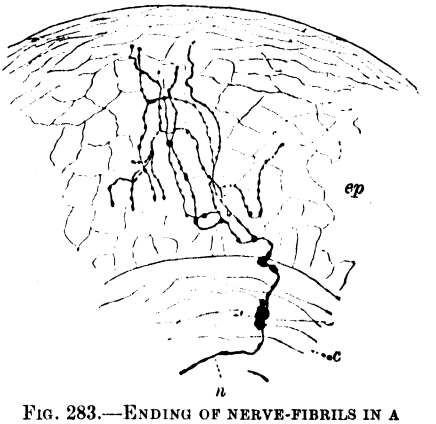

FIG. 283.—ENDING OF NERVE-FIBRILS IN A STRATIFIED EPITHELIUM. (G. Retzius.)

n, nerve-fibre in corium, *c*, and breaking up into varicose fibrils in the epithelium, *ep*.

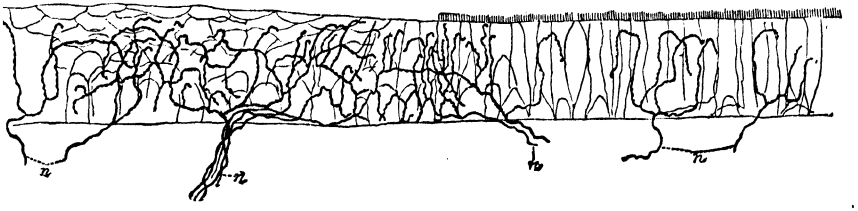

FIG. 284.—INTRA-EPITHELIAL NERVE-TERMINATIONS IN THE LARYNX. GOLGI METHOD. (G. Retzius.)

On the left the epithelium is stratified and on the right ciliated columnar. *n*, nerve-fibres in corium.

in free varicose fibrils. This mode of ending is well seen in the cornea of the eye, but can also be rendered evident in many other places.

Tactile disks.—In some situations the nerve-fibrils within a stratified epithelium terminate in flattened or crescentic expansions which lie in the interstices of the deeper epithelium cells, to some of which (*tactile cells*) they are applied. The expansions are known as *tactile disks*; they are characteristically developed in the pig's snout (fig. 285). Similar expansions are also found in the outer root sheath of hairs and in the deeper part of the

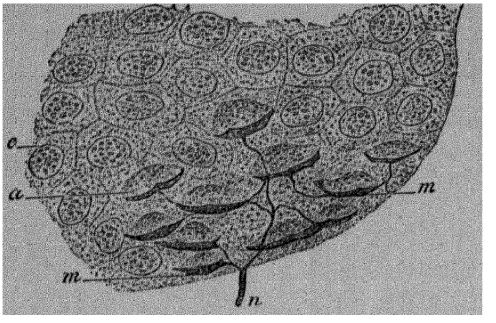

FIG. 285.—ENDING OF NERVE IN TACTILE DISKS IN THE PIG'S SNOUT. (Ranvier.)
n, myelinate fibre; *m*, terminal disks or menisci; *e*, cells of the Malpighian layer of the epidermis; *a*, cell to which a tactile disk is applied.

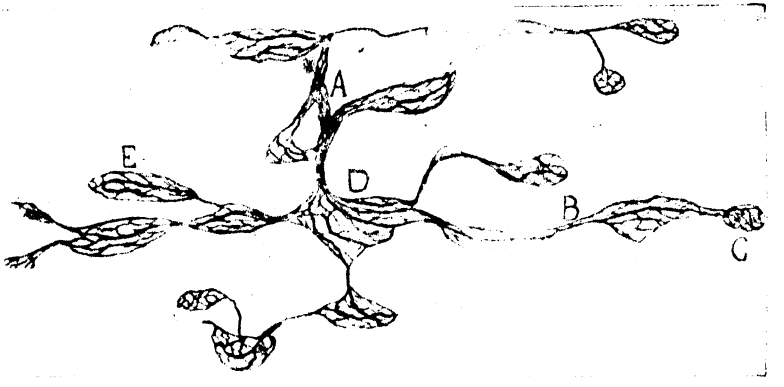

FIG. 286.—ENDING OF NERVE-FIBRE IN TACTILE DISKS. (R. y Cajal.)
The neuro-fibrils of the branched axis-cylinder form a network in each disk.

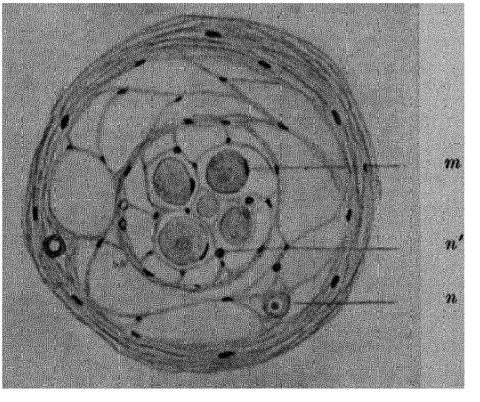

FIG. 287.—DIAGRAM OF SECTION OF MUSCLE-SPINDLE. (E. Sharpey-Schafer.)
m, intrafusal muscle-fibres; *n*, entering nerve-fibre with thick sheath of Henle; *n'*, branches of nerve passing to muscle-fibres of spindle.

epidermis in various situations. With appropriate treatment it may be shown that they contain a fine network of neuro-fibrils (fig. 286).

Sensory nerves of muscles.—The sensory nerves of muscles end in peculiar organs termed *muscle-spindles* (Kühne). Their structure has been specially

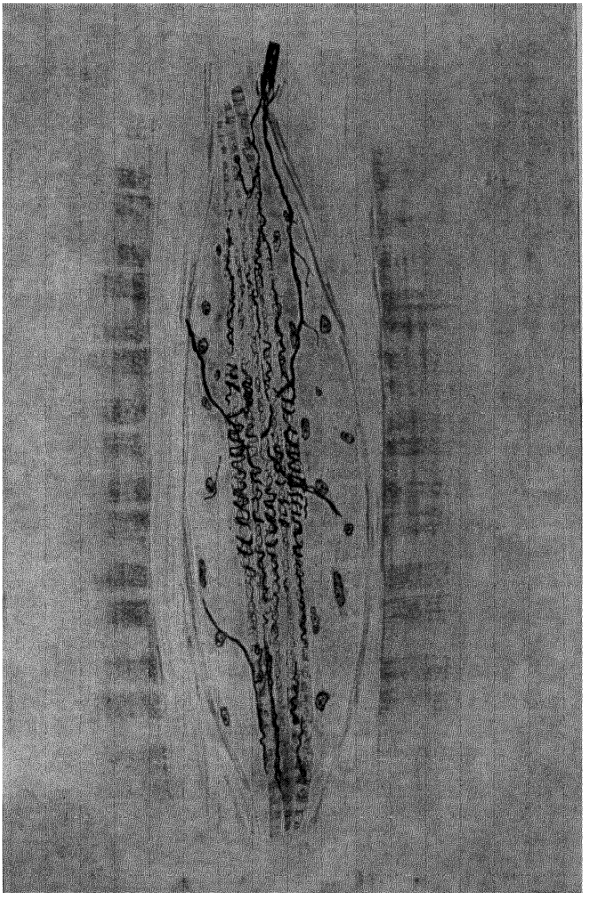

FIG. 288.—DIAGRAMMATIC REPRESENTATION OF A MUSCLE-SPINDLE IN SITU. (Modified from Boeke.) Drawn by R. K. S. Lim.

m, *m*, ordinary fibres of the muscle; *m'*, bundle of intrafusal fibres; *n*, sensory nerve entering spindle and passing to terminate in annulo-spiral endings around its muscle-fibres.

investigated by Ruffini and by Sherrington. Sherrington has shown that the large myelinate nerves which they receive are derived from the dorsal root-ganglia, and they are therefore undoubtedly sensory organs.

The **muscle-spindle** is a fusiform body, from 0·75 to 4 mm. long, and from

0·08 to 0·2 mm. in diameter; it lies parallel with the general direction of the fibres of a muscle. It consists (figs. 287, 288) of a lamellated connective-tissue sheath externally, within which are from two to twelve peculiar 'intrafusal' muscle-fibres. These, with some connective tissue and the nerve-fibres, form an axial bundle between which and the sheath is a lymphatic periaxial space, bridged across by connective-tissue cells and fibres. The intrafusal

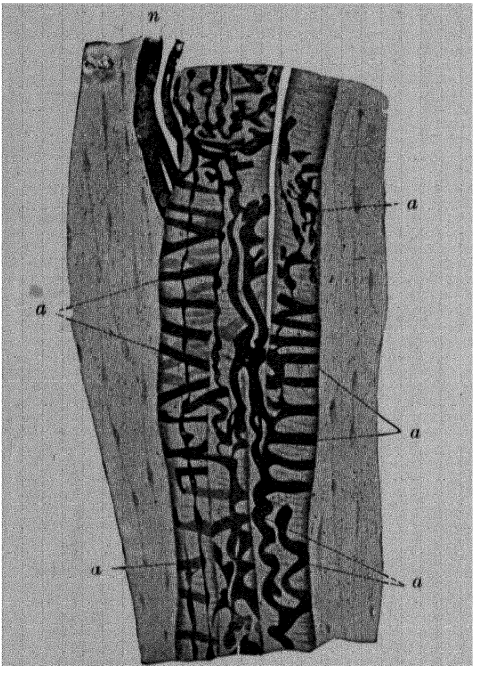

FIG. 289.—ENDING OF NERVE-FIBRES IN MUSCLE-SPINDLE. (Ruffini.)

Three intrafusal muscle-fibres are shown. *n*, nerve-fibres entering spindle; *a*, axis-cylinders terminating around and between the intrafusal fibres in ring-like, spiral, and irregularly ramified endings.

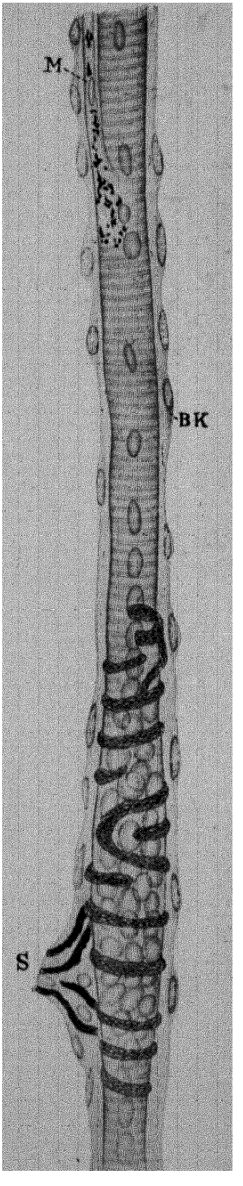

FIG. 290.—MUSCLE-FIBRE FROM A SPINDLE OF INTERCOSTAL MUSCLE OF CAT IN WHICH THE NERVE-ROOTS IMPLICATED HAD BEEN CUT WITHIN THE VERTEBRAL CANAL FOUR DAYS PREVIOUSLY. (J. Boeke.)

S, sensory fibres, forming annular endings around a highly nucleated portion of the intrafusal muscle-fibres; M, ending of a fine motor nerve, which has undergone degeneration, showing that its origin was in the spinal cord; BK, connective-tissue sheath of the muscle-fibre.

muscle-fibres are somewhat like embryonic fibres in appearance, being smaller than the ordinary fibres of the muscle and having a relatively large number of nuclei with surrounding protoplasm. At the proximal end of

the spindle they are usually only two or three in number, but they often become cleft as they pass through it; at the distal end they may terminate in tendon-bundles. The nerve-fibres which pass to the spindle are mostly of large size and are enveloped by a thick sheath of Henle (fig. 287, *n*). They divide within the spindle, but retain their myelin sheath for a time, although eventually terminating as axis-cylinders, which wind in a spiral manner between and around the intrafusal muscle-fibres (figs. 288, 289, 290), which they clasp by flattened encircling branches (*annulo-spiral endings*). Other, much finer, myelinate fibres pass to the spindle and terminate in ramified or plate-like expansions (fig. 290, M). According to some observers these fine fibres are prolonged from the annulo-spiral endings of the coarser fibres; but Dogiel states that they run independently to the intrafusal bundle. None of the ordinary motor nerve-fibres appear to pass into the spindles, nor do the muscle-fibres of the spindle undergo atrophy on section of the motor nerve-roots, as is the case with ordinary muscle-fibres after section of their nerves. Boeke, however, describes the intrafusal fibres as provided with end-plates, like those which occur on the ordinary fibres, but they are much smaller. Both the end-plates and the fine myelinate fibres which supply them undergo Wallerian degeneration after section of the nerves from which they arise, which may, according to Boeke, be either spinal or sympathetic in origin.

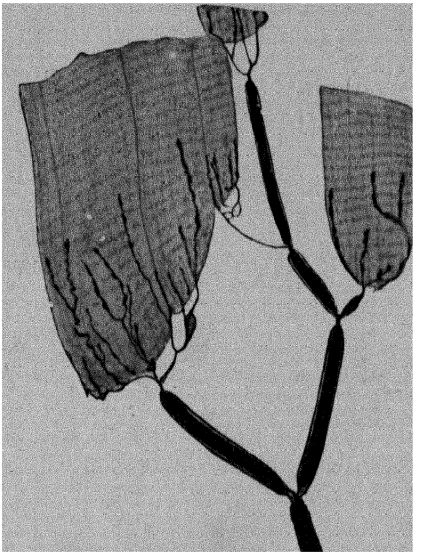

FIG. 291.—SENSORY NERVE TERMINATING IN ARBORISATIONS AROUND THE ENDS OF MUSCLE-FIBRES. (Ceccherelli.)

It is not uncommon to find two or three spindles close to one another or even enclosed in a common sheath.

Another kind of ending of sensory fibres in muscle has been described in the form of an arborisation of nerve-fibrils around the ends of the muscle-fibres which are inserted into tendon (fig. 291).

ENDING OF MOTOR NERVES.

In **cross-striated muscles,** the efferent nerves, which are for the most part large and myelinate, terminate in special end-organs, the so-called *end-plates* (figs. 292, 293). A myelinate fibre will branch two or three times before ending, and then each branch passes directly to about the middle of

a muscle-fibre. Having reached this, the neurolemma of the nerve-fibre is continued into the sarcolemma of the muscle, the myelin sheath stops short,

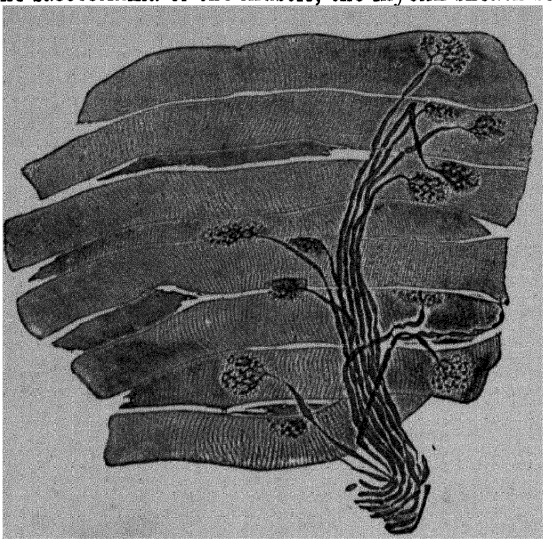

FIG. 292.—MOTOR NERVE-ENDINGS IN THE ABDOMINAL MUSCLES OF A RAT. GOLD PREPARATION. (Szymonowicz.) × 170.

and the axis-cylinder ends in a close terminal ramification with varicose expansions upon its branches. This ramification is embedded in a layer of

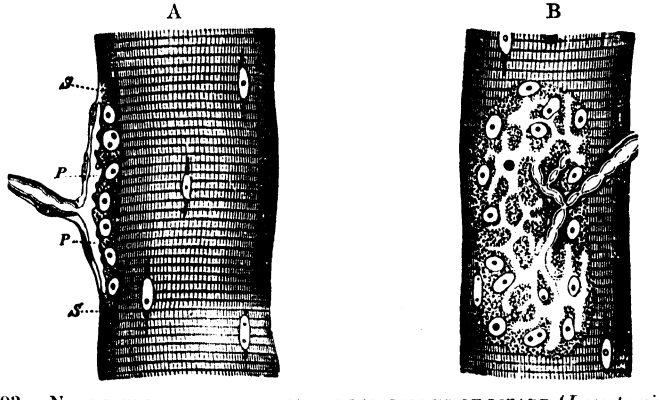

FIG. 293.—NERVE-ENDING IN FRESH MUSCULAR FIBRES OF LIZARD (*Lacerta viridis*). (Kühne.)

A, end-plate seen edgeways; B, from the surface; *s*, *s*, sarcolemma; *p*, *p*, expansion of axis-cylinder. In B the expansion of the axis-cylinder appears as a clear network branching from divisions of the myelinate fibre.

granular sarcoplasm (*sole*) (fig. 293), which is collected into a small mass at the place of nerve-ending. Embedded in this mass of sarcoplasm are two kinds of nuclei: one oval in shape resembling muscle-nuclei generally; the

other circular and more closely connected with the expanded and branched ending of the axis-cylinder. Aggregated around the nuclei are very numerous mitochondria.

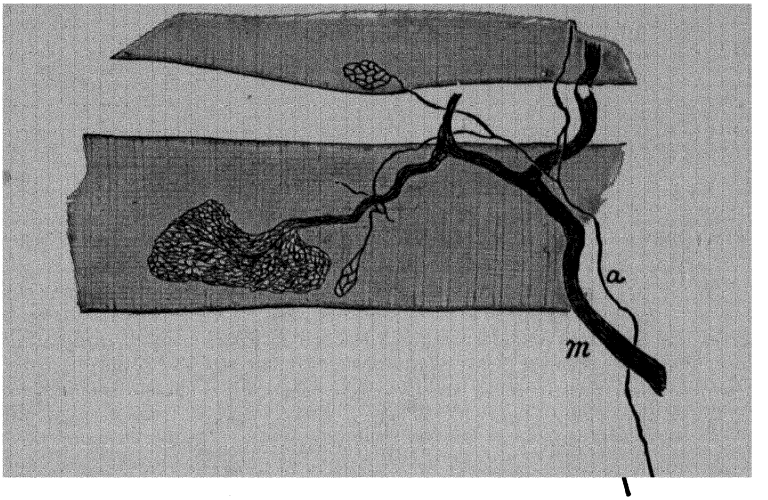

FIG. 294.—MUSCLE-FIBRES OF MOUSE WITH FINE AMYELINATE ACCESSORY FIBRES, DERIVED FROM THE SYMPATHETIC, ENDING IN SMALL EXPANSIONS: ONE NEAR AN END-PLATE. (J. Boeke.) × 1800.

m, myelinate fibre; *a*, accessory fibre.

When a motor nerve is cut and undergoes degeneration the nerve-endings become atrophied and disappear, but the *sole* and its nuclei remain; and if the nerve undergoes regeneration a new axis-cylinder eventually finds its way to it and develops a ramification with the usual fibrillar network (Boeke).

In some cases the ramification of the axis-cylinder is restricted to a small portion of the muscular fibre, and forms with the granular bed a slight



FIG. 295.—MOTOR ENDINGS FROM AN OCULAR MUSCLE OF THE HEDGEHOG SHOWING, BESIDES THE ENDING OF A MYELINATE FIBRE IN A RAMIFICATION AT THE END-PLATE, AN AMYELINATE FIBRE DERIVED FROM THE SYMPATHETIC, BIFURCATING, AND ITS FORKS TERMINATING WITH RELATIVELY SIMPLE ENDS, ONE AT THE END-PLATE OF THE MYELINATE FIBRE, THE OTHER AT A SMALL SPECIAL END-PLATE. (J. Boeke.)

prominence (*eminence of Doyère*). This is the case in insects and mammals. In reptiles the ramification is rather more extended than in mammals, whilst in the frog it is spread over a considerable length of the fibre. The ramification always shows a fibrillar structure, when appropriately fixed and stained (fig. 294). In mammals there appears to be only one such end-plate to each fibre; in reptiles there may be several. The end-plate is covered, externally

to the sarcolemma, by an expansion of the sheath of Henle of the nerve-fibre. This expansion has been termed the *end-sheath* or *telolemma*.

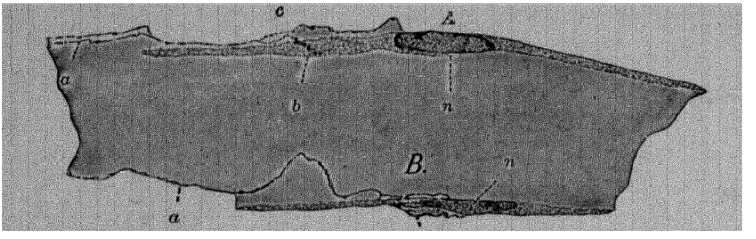

FIG. 296.—ENDING OF NERVE-FIBRILS IN PLAIN MUSCLE. (Huber and de Witt.)
a, fibrils passing to their termination; *b*, a terminal fibril; *c*, a branch passing to another muscle-cell; *n*, nuclei of cells.

Besides the myelinate nerve-fibre with its end-plate, many if not all muscle-fibres receive an accessory amyelinate nerve-filament which also ends in a fibrillar expansion at the surface of the fibre (figs. 294, 295). These filaments do not degenerate if the motor nerve is cut before it receives fibres from the sympathetic, but do degenerate if the sympathetic supply is cut off. It may be assumed, therefore, that they are derived from the latter. But a few may come from the spinal cord since, even after ablation of the sympathetic, there are still a few fine undegenerated fibres in muscle (Boeke). These accessory fibres are also described by Garven (1925) as they occur in hedgehog, frog, lizard, and man.

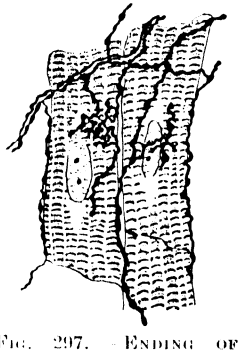

FIG. 297. ENDING OF NERVES IN CARDIAC MUSCLE. (Smirnow.)

In **involuntary muscle**, both plain and cardiac (figs. 296, 297), the nerve-fibres, which near their termination are entirely amyelinate, end in plexuses. The primary plexuses are generally furnished with ganglion-cells in abundance. Such gangliated plexuses are best developed in the wall of the intestine, where they form the *enteric nervous system*. The cells of the plexuses send out axon-processes to form secondary plexuses, from which the fibres pass to end in ramifications among the contractile fibre-cells, to the surface of which their branches, often slightly enlarged, are applied (Huber and de Witt). Boeke, however, finds (in the ciliary muscle) that the terminal fibrils pass *into* the muscle-cells, ending within them in loop-like expansions.

LESSON XX.

STRUCTURE OF THE LARGER BLOOD-VESSELS.

1. TRANSVERSE sections of a medium-sized peripheral artery and vein, *e.g.* popliteal or radial. In this preparation the limits of the vascular coats can be well seen and also the differences which they present in the arteries and veins respectively. The sections may be stained with hæmatoxylin and Van Giesen or with orcëin, and mounted in dammar.

2. Mount in glycerine a thin tangential slice cut from the inner surface of a large artery which, after having been cut open longitudinally and washed with distilled water, has been rinsed with 1 per cent. nitrate of silver solution and subsequently with distilled water and exposed for a minute or two to sunlight. It is then hardened in 90 per cent. alcohol and the section dehydrated and mounted in dammar. This preparation will show the outlines of the endothelium-cells which line the vessel. A similar preparation may be made from a large vein.

3. A piece of an artery which has been macerated in 33 per cent. alcohol is to be teased so as to isolate some of the muscular cells of the middle coat and portions of the elastic layers (networks and fenestrated membranes) of the inner and middle coats. The teasing is best done by holding the piece with forceps and fraying the edge with a needle in a drop of distilled water, thus separating small fragments and single muscle-cells. The fragments may be stained cautiously with diluted hæmatoxylin, and dilute glycerine afterwards added at the edge of the cover-glass. The muscle-cells are recognisable by their long rod-shaped nuclei; the cells often have an irregular outline. Sketch one or two and also a piece of the elastic network or fenestrated membrane. The fenestrated membrane is best obtained from one of the arteries of the base of the brain; it is also seen in the arteries within the kidney.

4. Transverse sections of aorta and carotid. Notice the preponderance of elastic tissue in these as compared with the radial. To show the elastic tissue well, sections are stained with orcëin.

5. Transverse section of vena cava inferior. Notice the comparatively thin layer of circular muscle, and outside this the thick layer of longitudinal muscular bundles in the adventitia.

Make sketches from 1, 4, and 5 under a low power, from 2 and 3 under a high power.

ARTERIES.

An artery is usually described as being composed of three coats, an *inner* or *elastic*, a *middle* or *muscular*, and an *outer* or *areolar* (fig. 298). It would be more correct to describe the wall of an artery as being mainly composed of muscular and elastic tissue, lined internally by a pavement epithelium (*endothelium*), and strengthened externally by elastic and connective tissue (*adventitia*).

The **inner coat** (*tunica intima*) is lined by a thin layer of *pavement epithelium* (*endothelium*) the cells of which are somewhat elongated in the direction of

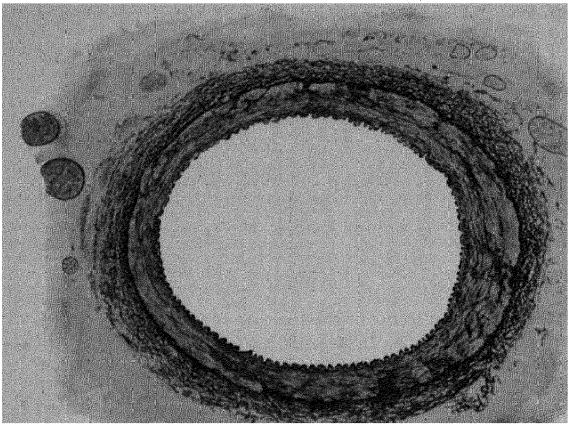

FIG. 298.—SECTION OF RENAL ARTERY OF DOG. (G. Mann.) Low power. Photograph.

The elastic layer of the thin inner coat is thrown into corrugations by the post-mortem contraction of the middle coat. The distinction between middle coat and adventitia is well shown. Some branches of the renal nerves are seen, cut across, in the tissue around the artery.

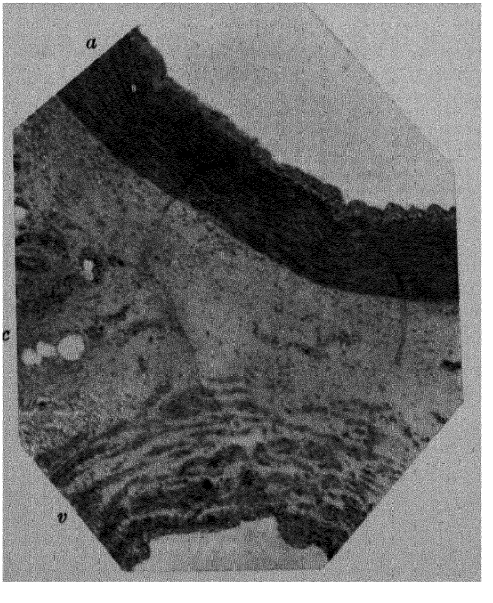

FIG. 299.—SECTION ACROSS POSTERIOR TIBIAL ARTERY AND VEIN : HUMAN. (E. Sharpey-Schafer.) × 75.

a, artery ; *v*, vein ; *c*, connective tissue uniting the vessels and in complete continuity with the tunica adventitia of each.

the axis of the vessel (fig. 301), and form a smooth lining to the tube. After death they become easily detached.

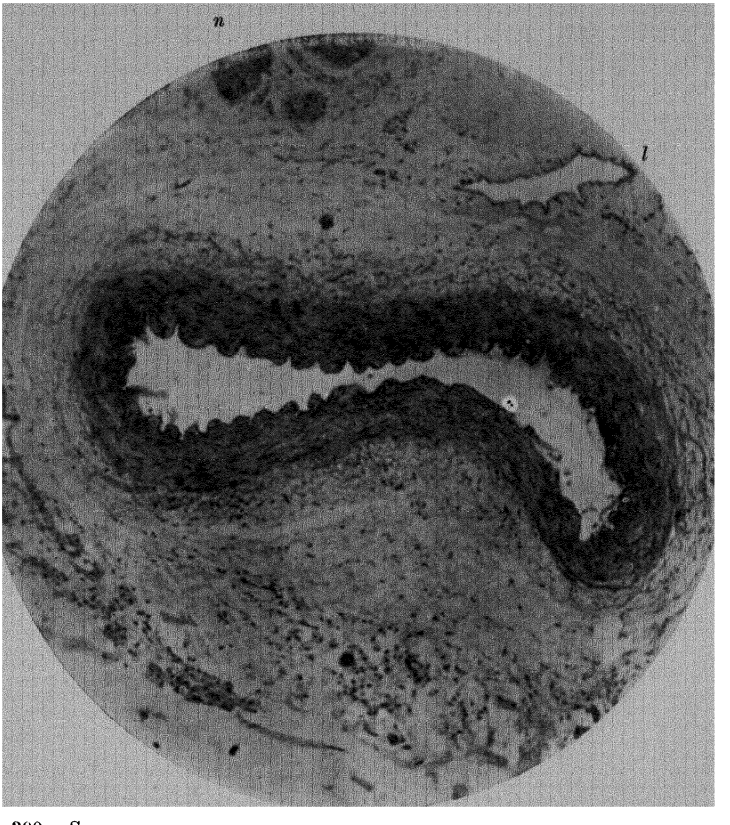

FIG. 300.—SECTION OF A SMALL ARTERY OF CAT, RATHER MORE MAGNIFIED.
(H. M. Carleton.) Photograph.

The inner coat is corrugated from post-mortem contraction of the middle coat. This is the darkly stained layer and in it are seen the elongated nuclei of the muscle-cells of which it is mainly composed. The adventitia merges into the surrounding connective tissue. At *l* a periarterial lymphatic is cut; at *n*, nerve-bundles.

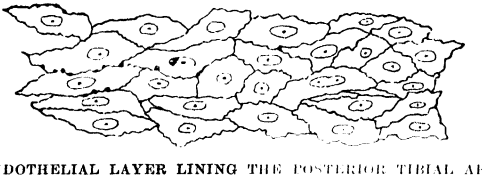

FIG. 301.—ENDOTHELIAL LAYER LINING THE POSTERIOR TIBIAL ARTERY: MAN.
(E. Sharpey-Schafer.) × 250.

The endothelium is the essential layer in all blood-vessels. It is always the first part to be developed, and in some (capillaries) it remains as the only layer of the vessel.

Next to the endothelium of the arteries comes an elastic layer in the form

either of *elastic networks* (fig. 302) or of a *fenestrated membrane* (figs. 303, 304). In some arteries there is a layer of fine connective tissue intervening between the endothelium and the fenestrated membrane (*subendothelial layer*).

The **middle coat** (*tunica media*) consists mainly of circularly disposed plain muscular fibres, but it is also pervaded in most arteries by a network of elastic



FIG. 302. ELASTIC NETWORK OF ARTERY. (Toldt).

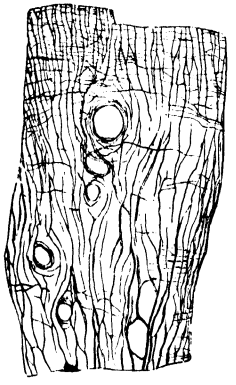

FIG. 303.—PORTION OF FENESTRATED MEMBRANE OF HENLE FROM AN ARTERY. (Toldt.)



FIG 304.—FENESTRATED MEMBRANE OF ONE OF THE CORTICAL BRANCHES OF THE RENAL ARTERY. (Mann.)

fibres connected with the fenestrated membrane of the inner coat (fig. 305): sometimes almost as much developed as the muscular tissue itself. This is especially the case with the largest arteries, such as the aorta and its immediate branches, whereas in the arteries of the limbs, especially those of smaller size, the middle coat is composed almost purely of muscular tissue (figs. 299, 300), the elastic tissue being best developed in the vessels nearest the trunk, becoming less in the more peripherally situated.

The muscular fibres are short as compared with those of the viscera. They have long rod-shaped nuclei (fig. 306) which assume a spiral form when the vessel is fixed with its muscular tissue in a contracted condition

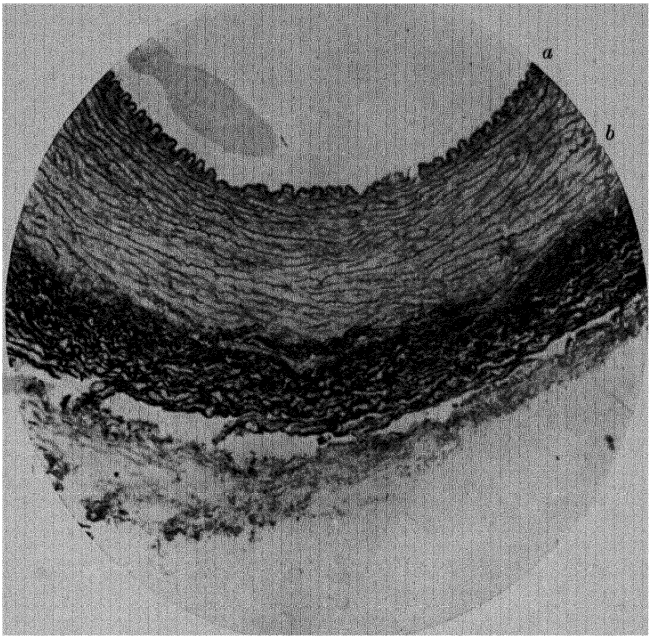

FIG. 305.—SECTION OF ARTERY STAINED WITH ORCËIN TO SHOW THE ELASTIC TISSUE. (E. Sharpey-Schafer.) × 50.

a, elastic lamina of inner coat, corrugated from contraction of muscular coat; *b*, elastic fibres forming a network which pervades the middle coat; *c*, numerous and thick elastic fibres of the outer coat; *d*, surrounding connective tissue.

(fig. 307). The muscle-cells are often very irregular (fig. 308), particularly so if the middle coat contains much elastic tissue.

The **outer coat** is formed of areolar connective tissue. It also contains a good many elastic fibres, especially next to the middle coat (fig. 305). But in the large arteries which have much elastic tissue in the middle coat this tissue is deficient in the outer coat.

The strength of an artery depends largely upon the connective tissue of this coat; it is far less easily cut or torn than the other coats, and it serves to resist undue expansion of the vessel. Its outer limit is not sharply marked, for it tends to blend with the surrounding connective tissue; hence it has been termed *tunica adventitia.*

Variations in different arteries.—The *aorta* (figs. 309, 310) differs in some respects in structure from an ordinary artery. Its inner coat is lined by

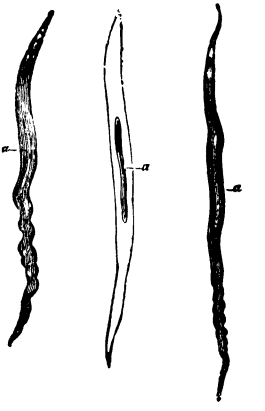

FIG. 306.—MUSCLE-CELLS OF ARTERY. (Kölliker.)

a, nucleus.

the usual endothelium (fig. 311); outside this is a considerable thickness of subendothelial connective tissue, with elastic tissue chiefly composed of fine fibres; it is not especially marked off by a definite elastic layer from

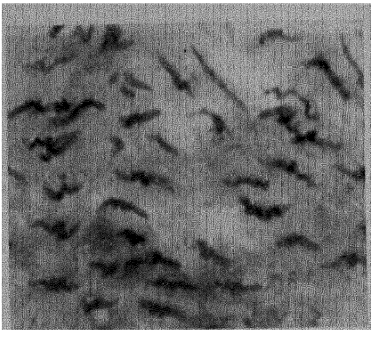

FIG. 307. NUCLEI OF GREATLY CONTRACTED RADIAL ARTERY: MAN. (E.Sharpey-Schafer.) × 435. Preparation by A. Abrahams.

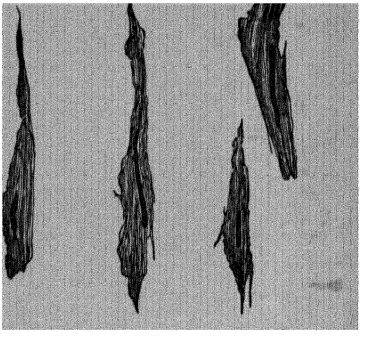

FIG. 308.—MUSCLE-CELLS FROM SUPERIOR THYROID ARTERY. (E. Sharpey-Schafer.) × 340.



FIG. 309.—SECTION OF AORTA: HUMAN. (E. Sharpey-Schafer.) × 50.

the middle coat, so that the inner and middle coats are blended with one another. There is a great development of elastic tissue in the middle coat, where it forms membranous layers or lamellar networks which alternate

with the muscular layers. A good deal of connective tissue also takes part in the formation of the middle coat, making it unusually strong. This

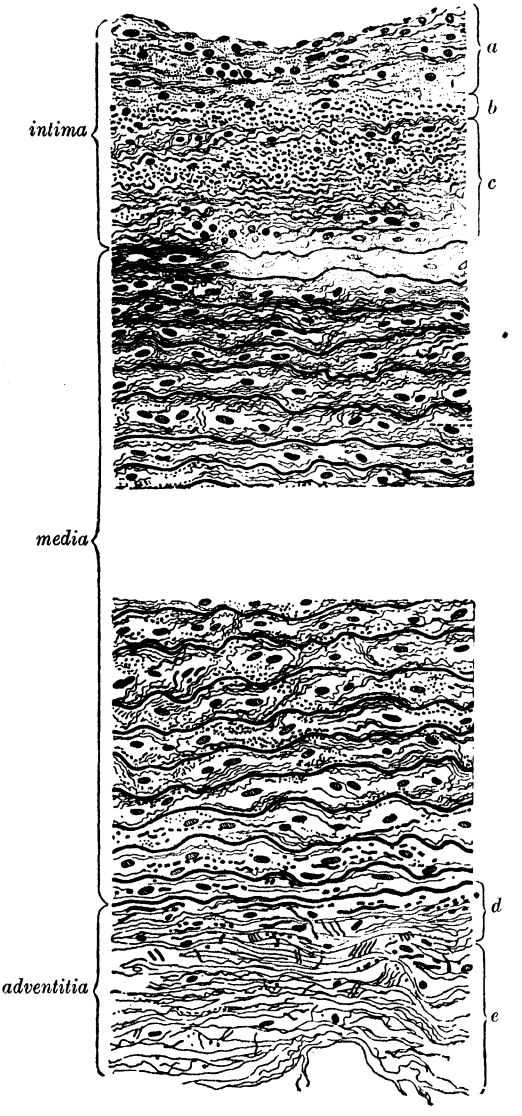

FIG. 310.—SECTION OF AORTA MORE MAGNIFIED. (Grünstein.)

a, endothelial and subendothelial layers of inner coat; *b*, *c*, outer layer of inner coat containing many fine elastic fibres; *d*, *e*, parts of outer coat.

middle coat constitutes almost the entire thickness of the wall, the inner and outer coats being thin. Near the ventricles both the aorta and pulmonary artery have a certain amount of cardiac muscle in this coat.

Apart from the relative amount of elastic tissue which has been alluded to, the variations which occur in the arterial system have reference chiefly to the development and arrangement of the muscular tissue. Thus in many of the larger arteries, especially in the *aorta* and its larger branches, and in the *popliteal* and the *brachial*, there are longitudinal muscular fibres at the inner boundary of the middle coat; in some arteries they occur amongst the circular fibres of the middle coat and occasionally even in the outer coat, as in the upper part of the descending aorta. In the *subclavian* there are more longitudinal fibres than circular. In the part of the *umbilical arteries* within the umbilical cord there is a complete layer of longitudinal fibres internal to the circular fibres and another external to them, whilst the amount of elastic tissue is very small. Longitudinal fibres are also present in some other arteries (*iliac, superior mesenteric, splenic, renal*, etc.), external to the circular fibres, and therefore in the outer coat of the artery.



FIG. 311.—ENDOTHELIUM OF AORTA: HUMAN. NITRATE OF SILVER PREPARATION. (E. Sharpey-Schafer.) × 230.

The *pulmonary arteries* have a well-developed muscular coat, although it is generally thinner than in arteries of corresponding size belonging to the systemic circulation. In the guinea-pig and opossum the muscular coat of the pulmonary arteries shows a peculiarity of structure in that it is thickened in some parts and absent or nearly absent between the thickened parts, thus giving the arteries a varicose appearance (Schultz and Jordan). In ruminants (ox, sheep) and in the pig the muscular coat of the pulmonary arteries is disposed in an open spiral.

VEINS.

The veins resemble the arteries in structure, but exhibit certain differences. In the **inner coat** (fig. 312) the same layers are present, but the elastic tissue is less developed, and may be quite inconspicuous; it seldom takes the form of a complete membrane. The endothelium-cells are less elongated than those of the arteries. The **middle coat** contains less elastic tissue and also much less muscular tissue, being partly occupied by bundles of connective-tissue fibres. These are continuous with those of the

outer coat which is relatively better developed in the veins than in the arteries, so that, although thinner, the walls are often stronger.

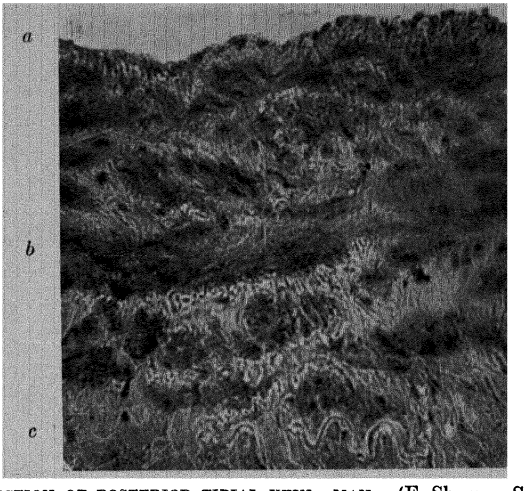

FIG. 312.—SECTION OF POSTERIOR TIBIAL VEIN: MAN. (E. Sharpey-Schafer.) × 230.

a, endothelial layer; *b*, middle coat (muscle, with connective and elastic tissues); *c*, adventitia.

Valves.—Many of the veins are provided with *valves* (fig. 313), which are crescentic pocket-like folds of the inner coat strengthened by fibrous tissue: a few muscular fibres may be found in the valve near its attachment. The layer of the inner coat is rather thicker and the endothelium-cells are more elongated on the side which is subject to friction from the current of blood than on that which is turned towards the wall of the vessel. The vein is dilated on the heart side of each crescentic valve-fold, and as there are usually two such folds for each valve in the larger veins the dilatations are opposite one another, and when the vein is distended by obstructing the flow of blood in it they form knot-like swellings upon its course. There are no valves in veins less than 2 mm. in diameter. It is chiefly the larger veins of the limbs that possess valves. They are wanting in most of the veins of the viscera, although occurring in some of the tributaries of the portal vein. They are also wanting in all veins within the cranium and vertebral canal, in the veins of the bones, and in the umbilical vein.

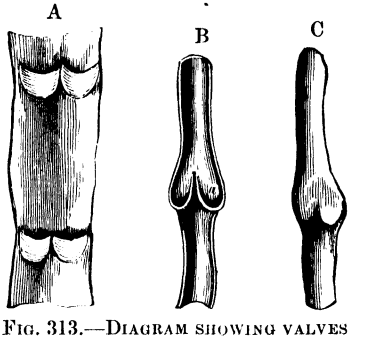

FIG. 313.—DIAGRAM SHOWING VALVES OF VEINS. (W. Sharpey.)

A, vein laid open showing the folds forming a valve; B, longitudinal section through a vein at a valve; C, a distended vein showing the swellings opposite the valve-folds.

Variations in different veins.—The veins of different parts vary considerably in structure. In many veins longitudinal muscular fibres are

found in the inner part of the middle coat, as in the *iliac, femoral, saphenous.* In the *umbilical* vein within the umbilical cord there are three muscular layers as in the corresponding arteries; in contradistinction to these the vein has a well-developed internal elastic layer. Hence, when the umbilical cord is cut the vein remains open while its arteries which have very little elastic tissue contract and close up.

In some other veins, longitudinal fibres occur external to the circularly disposed fibres; they may be described as belonging to the outer

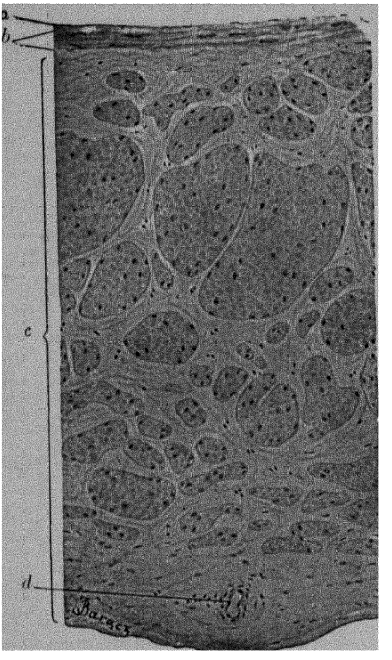

FIG. 314. TRANSVERSE SECTION OF THE INFERIOR VENA CAVA OF THE DOG. (Szymonowicz.) × 150.

a, intima; *b*, thin layer of circular muscle; *c*, thick adventitia with longitudinal muscular bundles; *d*, a vas vasis.

coat. This is the case with the abdominal, and especially the hepatic, portion of the *inferior vena cava* (fig. 314), and some of its tributaries (the ***renal, suprarenal***, and to a less extent the *hepatic* veins); also with the ***portal*** vein and its tributaries. In the ***superior vena cava,*** in the upper part of the *inferior vena cava* and in the ***jugular, subclavian,*** and ***innominate*** veins muscular fibres are almost entirely absent from the middle coat and there are but few in the adventitia. The veins of the pia mater, brain and spinal cord, retina, and bones, and the venous sinuses of the dura mater and placenta have no muscular tissue.

Vessels and nerves of blood-vessels.—The larger arteries and veins possess blood-vessels (*vasa vasorum*) and lymphatics, both of which ramify chiefly

in the external coat. Nerves are distributed to the muscular tissue of the middle coat, after forming a plexus in the outer coat (fig. 315). Most of the nerves are amyelinate. But in larger vessels there are a certain number of myelinate fibres intermingled with the amyelinate and passing to end



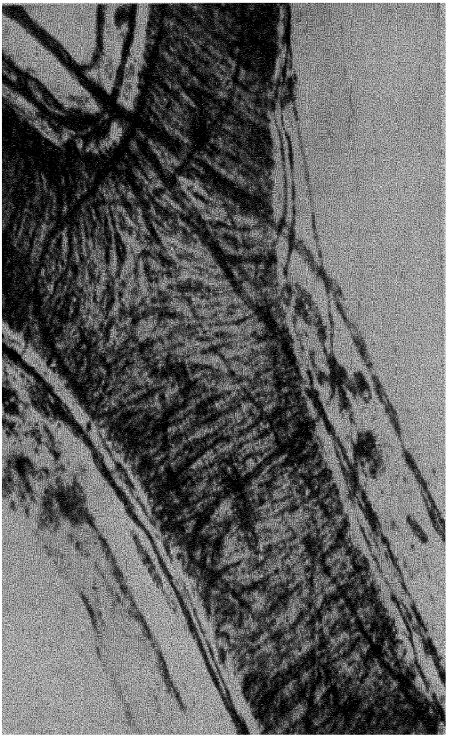

FIG. 315. NERVES DISTRIBUTED TO A SMALL ARTERY. (E. Sharpey-Schafer.)

A, magnified 52 diameters; B, magnified 290 diameters. The preparation is from a lizard's muscle, stained with gold chloride, and in B fine nerve-filaments are seen passing to the muscular coat.

in localised arborescences partly in the adventitia, partly in the intima. These myelinate fibres are probably afferent; most if not all of the amyelinate are efferent and derived from the sympathetic (vaso-motors). In the aorta of man and in some of the larger mammals Pacinian corpuscles are here and there met with in the adventitia.

LESSON XXI.

SMALLER BLOOD-VESSELS AND LYMPH-VESSELS. SEROUS MEMBRANES. MICROSCOPIC STUDY OF THE CIRCULATION. DEVELOPMENT OF BLOOD-VESSELS.

1. TAKE a piece of pia mater which has been fixed in 2 per cent. bichromate of potassium for several days, then well washed with distilled water and stained with hæmatoxylin. Separate from it some of the small blood-vessels of which it is largely composed. Mount the shreds in dilute glycerine; or, after dehydrating with alcohol and passing through clove oil, mount them in dammar. The structure of small arteries can be studied in this preparation; the nuclei of the endothelium and of the muscular coat are brought distinctly into view by the stain. The veins of the pia mater possess no muscular tissue. Capillary vessels which have been dragged out from the brain in removing the pia mater will also be seen. Sketch two small arteries of different sizes.

2. Mount in dammar a piece of the omentum (or mesentery) of the rabbit, stained with silver nitrate. The membrane may be stretched over a ring of cork or vulcanite; or a pill-box may be used for the purpose, the top and bottom disks having been removed. A larger piece may conveniently be fixed by spreading it over a glass plate (lantern slide) and, having brought its margins round the edges of the plate, placing another plate of the same size at the back, and binding the plates together by a couple of rubber bands. Whichever method is used, the exposed surface is treated in the following way: Rinse with distilled water, cover for five minutes with 1 per cent. nitrate of silver solution, again wash with distilled water and expose to sunlight in water. When slightly browned, the preparation is removed from the light. Pieces may now be cut off from the membrane, floated flat on a slide, allowed to dry completely and mounted in dammar; they should include blood-vessels. Or the glass plate (ring) with the omentum stretched over it may, after staining with silver, be placed in alcohol to fix and dehydrate the tissue and cleared with clove oil before cutting off pieces to be mounted in dammar. It is easier to cut up the membrane after treatment with clove oil.

The preparation is intended to show the smaller blood-vessels and accompanying lymphatics, and the endothelium of the serous membrane. Make sketches.

In this and all other silvered preparations great care must be taken not to rub, pull or crumple the membrane or to injure it in any way.

3. Mount in dammar a piece of the central tendon of the rabbit's diaphragm which has been prepared with silver nitrate in the same manner as the last preparation. The pleural surface is first brushed to remove its serous endothelium and thus enable the nitrate of silver more readily to penetrate to the network of underlying lymph-vessels. Observe the lymphatic plexus in the central tendon under a low power; sketch a portion. If the peritoneal surface is focused, the endothelium which covers that surface will be seen, and, opposite the clefts between the radially disposed tendon-bundles, stomata may be looked for in the endothelium.

4. Stomata. Open the abdomen of a freshly killed male frog and remove the abdominal viscera, taking care not to injure the membrane at the back of the

abdomen, which lies between and at the sides of the kidneys and separates the peritoneal cavity from the *cisterna lymphatica magna*, a large lymph-space in which the aorta and vena cava are contained. Cut out one kidney along with as much as possible of the membrane which lies between the kidney and abdominal wall; rinse with distilled water and place in a watch-glass of 1 per cent. silver nitrate for one minute. Rinse again in distilled water and expose in tap water to the light. When slightly browned snip off a portion of the thin membranous septum, float it flat on a slide, drain off the superfluous water and allow it to dry; then add a drop of dammar and cover the preparation.

Before or after the preparation is dried upon the slide it may be stained with gentian-violet solution, washed with distilled water and then allowed to dry and mounted in dammar. The nuclei of the cells are thus shown.

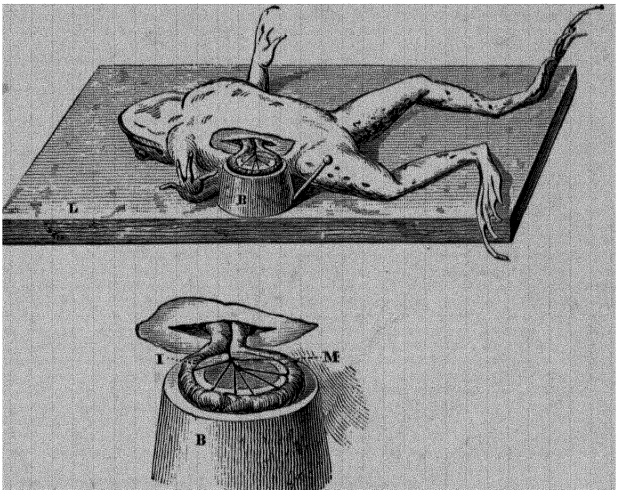

FIG. 310.—METHOD OF STUDYING THE CIRCULATION IN THE FROG'S MESENTERY. (Ranvier.)

L, cork or glass plate; B, perforated cork, the aperture in which is closed by a circular glass cover; M, mesentery laid over the glass cover; I, intestine. The brain is destroyed and the animal immobilised with ether or urethrane.

5. Examine sections of the thoracic duct. Unless filled with chyle it may be difficult to find. Therefore the animal (cat or dog) should be fed with fat (which may first be deeply stained with Sudan III) three hours before killing it. The sections are made in the same way as sections of the blood-vessels.

6. Kill a frog by destroying the brain and study the circulation of the blood in the mesentery. It can also be studied in the web of the frog's foot, in the lung, bladder or tongue of the frog or toad, and in the tail of the tadpole or of any small fish. But for observing the phenomena attending commencing inflammation and the emigration of leucocytes from the vessels, the mesentery is the most convenient part. The decerebrated frog may be immobilised with urethrane or by placing it in water in which a little ether has been shaken up: a lateral incision is made in the abdominal wall, a loop of intestine drawn out, and laid over a ring of cork which is covered with glass and cemented to a glass or cork plate (fig. 316). The membrane must be kept wet with frog-Ringer. A low-power objective is used for studying the circulation, higher magnifications being obtained by the employment of high-power oculars.

7. The arrangement of the blood-vessels in the various tissues and organs will be studied in injected preparations (see Appendix for methods) as each organ is dealt with.

THE SMALL BLOOD-VESSELS.

The coats of the small arteries and veins are simpler in structure than those of the larger vessels, but contain the same elements. Thus there is a lining endothelium and an elastic layer, the two together forming an *inner coat*; a *middle coat* of circularly disposed plain muscular tissue; and an *outer coat* or *adventitia*. The same differences are found between the smaller arteries and veins as with the larger; the walls of the venous vessels being thinner and containing less muscular tissue (fig. 317), and the lining endothelium-cells, much elongated in both vessels, being far longer and narrower in the small arteries than in the corresponding veins (fig. 318).

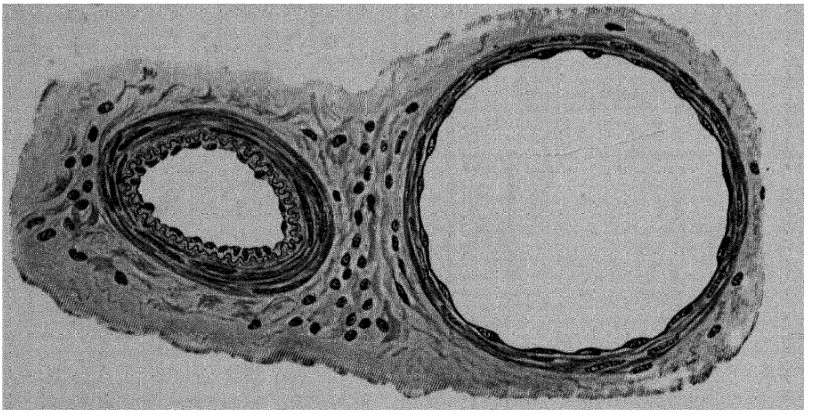

FIG. 317.—TRANSVERSE SECTION OF A SMALL ARTERY AND VEIN. (E. Sharpey-Schafer.) × 250.

In the smallest vessels it will be found that the elastic layer has entirely disappeared in the veins, and that the muscular tissue is considerably reduced in thickness in both kinds of vessel. Indeed, it is soon represented by but a single layer of cells, and these eventually no longer form a complete layer. By this time, also, the outer coat as well as the elastic layer of the inner coat have disappeared from both arteries and veins. The vessels are reduced, therefore, to the condition of a tube formed of endothelium-cells, with a partial covering of circularly disposed muscle-cells.

Even in the smallest vessels which are not capillaries the differences between arteries and veins are still manifested. These differences may be recapitulated as follows: The veins are larger than the corresponding arteries; they branch at less acute angles; their muscle-cells are fewer, and their endothelium-cells less elongated; the elastic layer of the inner coat is always less marked, and disappears sooner as the vessels become smaller.

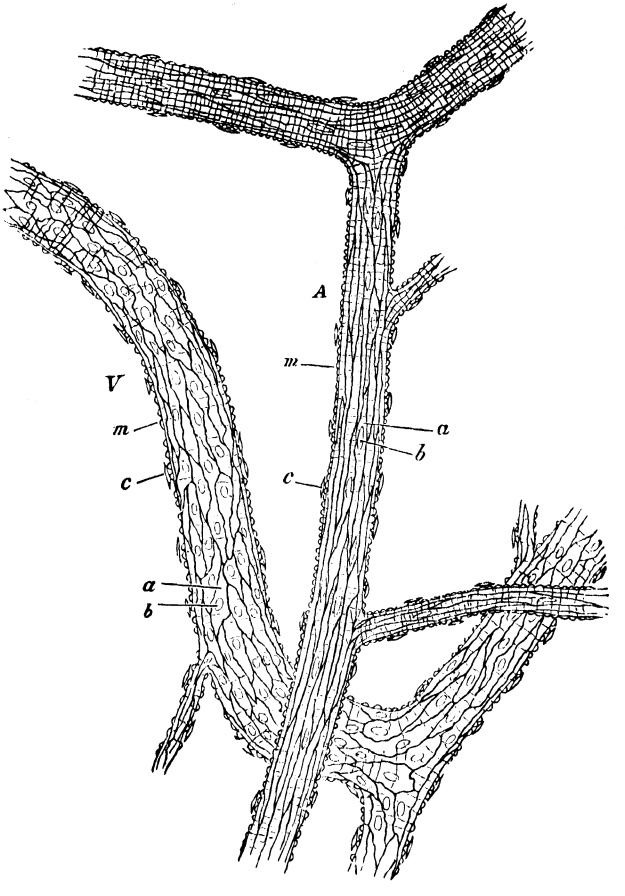

FIG. 318.—A SMALL ARTERY, *A*, AND VEIN, *V*, FROM THE SUBCUTANEOUS CONNECTIVE TISSUE OF A RAT, TREATED WITH NITRATE OF SILVER. (E. Sharpey-Schafer.) × 175.

a, *a*, endothelial cells with *b*, *b*, their nuclei; *m*, *m*, transverse markings due to staining of intercellular substance between the muscle-fibres; *c*, *c*, nuclei of connective-tissue corpuscles attached to exterior of vessel.

CAPILLARIES.

When traced to their smallest branches the arteries and veins are eventually seen to be continued into a network of the smallest blood-vessels or capillaries. The walls of these are composed only of flattened endothelium-cells (fig. 319) continuous with those that line the arteries and veins; these cells can be exhibited by staining with nitrate of silver. The cell-outlines are not shown in developing capillaries; in these, silver nitrate shows no elective staining. This is the case also in the adult with the capillaries of the villi, those of the choroid coat of the eye (Eberth), and those of the kidney-glomeruli (Ranvier): in all these places the lining cells form a syncytium.

Capillaries vary in size, averaging 8 μ to 10 μ in diameter. They also

vary greatly in the closeness of their meshes and their arrangement in different parts, which is mainly determined by the disposition of the tissue-elements. These points are best studied in injected preparations, and will be described when the structure of the several organs is considered.

Usually the arterioles pass gradually into the capillary network and the capillaries unite to form small veins which, on receiving others, gradually increase in size. But in certain situations the arrangement is different. Thus in the spleen the capillaries have imperfect walls and the blood passes into the interstices of the spongy tissue of the organ, from which it is collected by sinus-like veins which also have incomplete walls. In erectile tissue the arterioles open, without the medium of capillaries, into large cavernous spaces bounded by fibrous and plain muscular

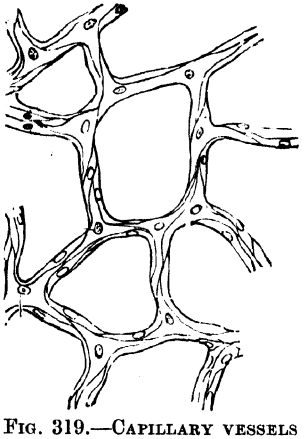

FIG. 319.—CAPILLARY VESSELS FROM THE BLADDER OF THE CAT, MAGNIFIED. (After Chrzonszczewsky.)

The outlines of the cells are stained by nitrate of silver.



FIG. 320.—BLOOD-VESSELS IN THE WEB OF THE FROG'S FOOT SHOWING AN ARTERIOLE COMMUNICATING THROUGH THE CAPILLARY NETWORK WITH A VENULE. (Allen Thomson.)

a, arteriole; *v*, venule.

tissues and lined by endothelium: the veins lead out of these spaces, so that there are no true capillaries, except such as are distributed to the walls of the spaces. In the sympathetic ganglia, the capillaries open abruptly into large sinus-like venules. And in the liver and a few other organs, as will presently be explained, the connexion between afferent and efferent vessels is effected, not by true capillaries, but by sinus-like spaces between the tissue-elements, the 'sinusoids' of Minot.

In transparent parts of animals the blood may be seen flowing through the capillary network from the arteries into the veins (fig. 320). The current is very rapid in the small arteries, somewhat less rapid in the veins, slowest in the capillaries. The flow in any vessel is fastest in the centre, slowest nearest the wall (inert layer). In this layer the leucocytes are carried along and they may be observed—especially where there is commencing inflammation of the part, as in the mesentery in consequence of exposure—to adhere to the inner surface of the blood-vessel, and here and there to pass through the coats of the small vessels and appear as *migratory* or *wander-cells* in the surrounding connective tissue. The blood-platelets are also seen in the inert

layer, and if the vessel is injured or the part is inflamed, tend to adhere to the injured part and to one another.

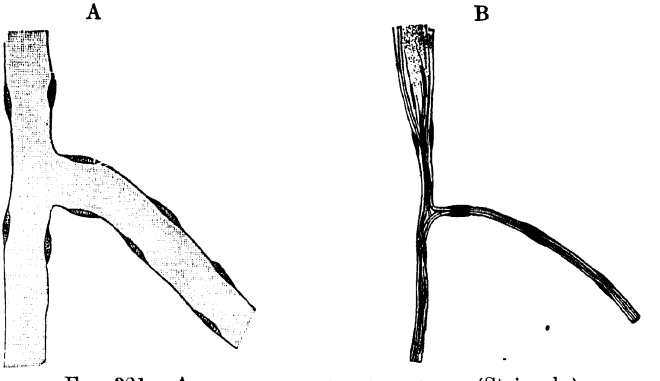

FIG. 321.—A LIVING CAPILLARY VESSEL. (Steinach.)
A, as seen previous to excitation; B, contracted condition resulting from strong excitation.

Contractility of capillaries.—As was first shown by Stricker, the cells which form the walls of the capillaries possess contractility, for it is found that when these vessels are directly stimulated—even after isolation—they

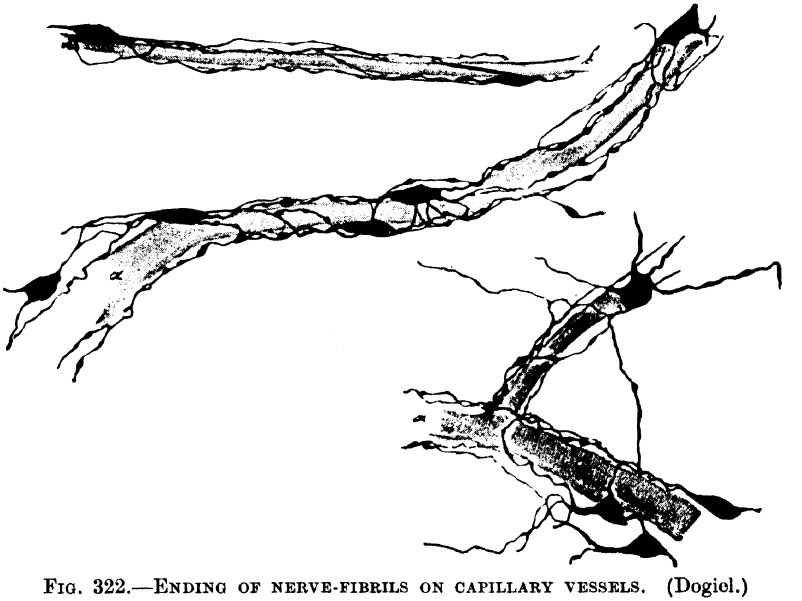

FIG. 322.—ENDING OF NERVE-FIBRILS ON CAPILLARY VESSELS. (Dogiel.)

may diminish in calibre to complete extinction of the lumen (fig. 321). They are also capable of undergoing dilatation (Krogh) even when not subjected to internal pressure: a very light stimulation will often produce this result. These results can also be brought about by the action of drugs.

Some of the phenomena may be produced reflexly through the agency of nerve-fibres, with which the capillaries of most parts are abundantly supplied (fig. 322).

The contractility of the capillaries has been ascribed by some authors to certain cells (Rouget cells) which are seen here and there lying against the vessel-wall (fig. 323). The Rouget cells are said to contain fibrils like those

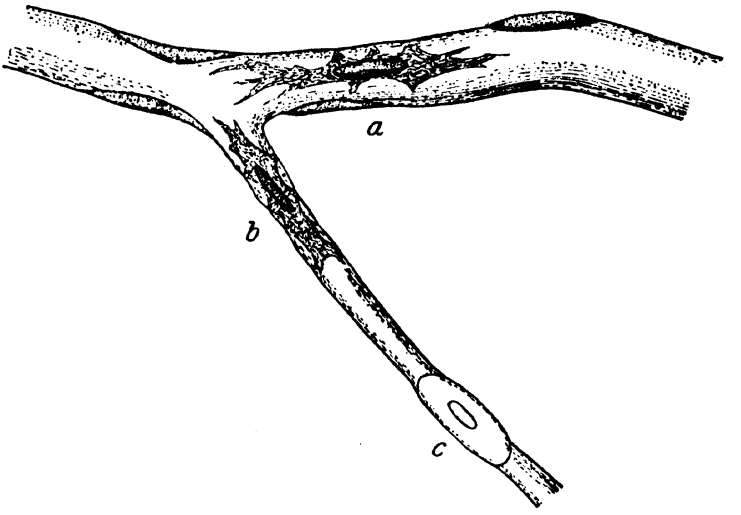

FIG. 323.—CELLS OF ROUGET ON THE WALL OF A CAPILLARY OF SALAMANDER-TADPOLE. (Vimtrup.)

a, an expanded; *b*, a partially contracted 'Rouget' cell; *c*, an erythrocyte.

of plain muscle-cells (Bensley and Vimtrup), but this has been denied (Benninghoff). Florey and Carleton found that the capillary would contract independently of the Rouget cells, which they consider to be of connective-tissue nature. The fact that the capillaries are abundantly supplied with nerves which are in close contact with the endothelium renders their contractility the more probable. Their condition is also influenced by autacoid substances; either brought to them by the blood—such as the active principle of the posterior lobe of the pituitary (Krogh), which causes them to contract—or formed locally, such as histamine (Lewis), which causes them to dilate.

DEVELOPMENT OF BLOOD-VESSELS.

The heart and blood-vessels show themselves very early. They are always developed in connective tissue or in the mesenchyme which precedes it, the first vessels being formed in the vascular area which surrounds the early embryo. Their development may be studied in the embryo chick or mammal, in the omentum of the new-born rabbit, and in the serous membranes and subcutaneous connective tissue of fœtal animals. The cells which are to form the vessels (*vaso-formative cells, angioblasts*) branch and unite

with one another to form a syncytium ; cavities form in this and extend into the branches. In the meantime the nuclei multiply and become distributed along the branches, cell-areas being at a later stage marked out around the nuclei. In this way intercommunicating vessels—capillaries in which blood-corpuscles may have become also developed (see pp. 47 to 50)—are produced. These presently connect with previously formed vessels, which extend themselves by sending out sprouts, at first solid, and afterwards hollowed out. Even the larger blood-vessels and the heart itself appear to be developed in the same way as the capillaries, in so far that the endothelium is first formed, and the muscular and other tissues are subsequently added; but whether they are produced as clefts in the

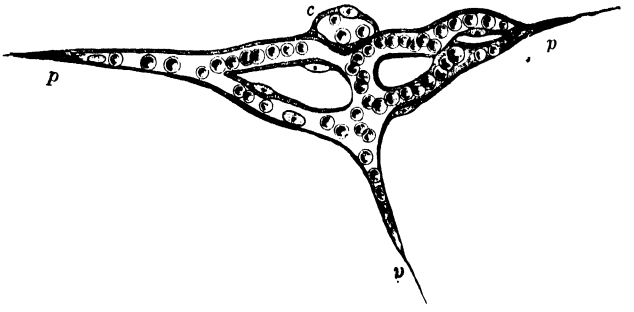

FIG. 324.—ISOLATED CAPILLARY NETWORK FORMED BY THE JUNCTION OF A HOLLOWED-OUT SYNCYTIUM, CONTAINING COLOURED BLOOD-CORPUSCLES IN A CLEAR FLUID. (E. Sharpey-Schafer.)

c, a hollow cell the cavity of which does not yet communicate with the network ; *p*, *p*, *p*, pointed processes, extending in different directions for union with neighbouring capillaries.

mesoblastic tissue, which become bounded by flattened cells, as some believe, or whether as a hollowed-out syncytium in the manner just described, has not been certainly determined.

SINUSOIDS.

These are sinus-like blood-spaces between the cells of certain tissues (Sedgwick Minot). They may when fully developed bear a superficial resemblance to blood-capillaries, but differ essentially from these in their mode of development, as well as in their relationship to the connective tissue and cells of the organs in which they occur. For, whereas capillary blood-vessels are developed in embryonic connective tissue and are always accompanied by areolar tissue, sinusoids make their appearance independently in the form of large blood-spaces, connected usually with the venous system. Into these spaces, the walls of which are formed of only a single layer of endothelial cells, the tissue-elements of the developing organ (Wolffian body, liver, suprarenals, etc.) grow, invaginating the thin wall and forming cell-trabeculæ within the sinus (fig. 325), so that the cells of the organ are brought directly into contact with the invaginated endothelium,

and are only separated by this from the blood contained within the sinus. But the connexion may be yet closer than this, for, as happens in the

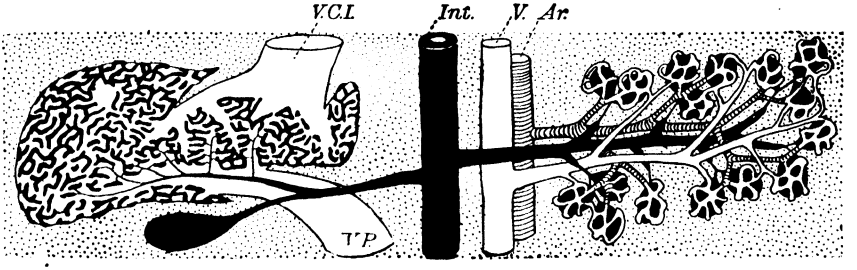

FIG. 325.—DIAGRAM TO ILLUSTRATE THE DEVELOPMENT OF BLOOD-CAPILLARIES (RIGHT SIDE) AND SINUSOIDS (LEFT SIDE) RESPECTIVELY. (F. T. Lewis.)

Int, intestinal entoderm with outgrowth on the left to form the liver and gall-bladder, and on the right to form the pancreas. *V.C.I.*, vena cava inferior; *V.P.*, vena portæ; *V*, vein, and *Ar*, artery supplying pancreas. It is seen that the sinusoids or apparent capillaries of the liver are formed by the breaking up of a large blood-space into channels by the growth into it of cell-columns derived from the hepatic outgrowth of the entoderm.

liver, the invaginated endothelium may largely disappear, so that the blood within the sinus is in actual contact with the cells of the organ, flowing

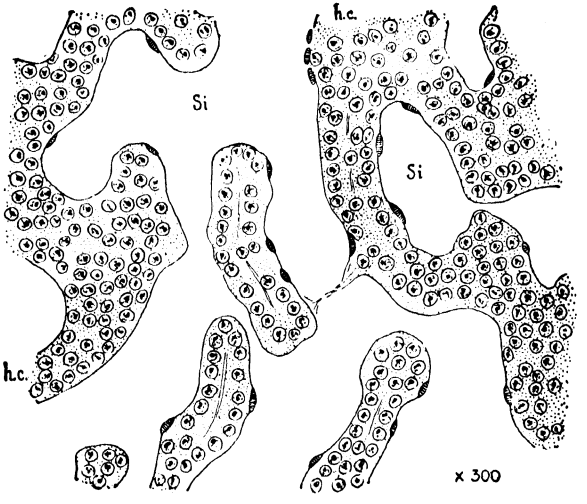

FIG. 326.—DEVELOPING LIVER OF CHICK, TO SHOW HOW THE HEPATIC TRABECULÆ ENCROACH ON THE LUMINA OF THE SINUS-LIKE VEINS AND BREAK THEM UP ULTIMATELY INTO THE CAPILLARY-LIKE CHANNELS CALLED SINUSOIDS. (Sedgwick Minot.)

h.c., hepatic trabeculæ; *Si*, sinuoids.

in the irregular interstices between them (fig. 326, 327). As development proceeds these interstices come to resemble blood-capillaries in general

arrangement (fig. 328); but the resemblance is superficial, and the intimate relationship between the blood and the tissue-elements, which are both

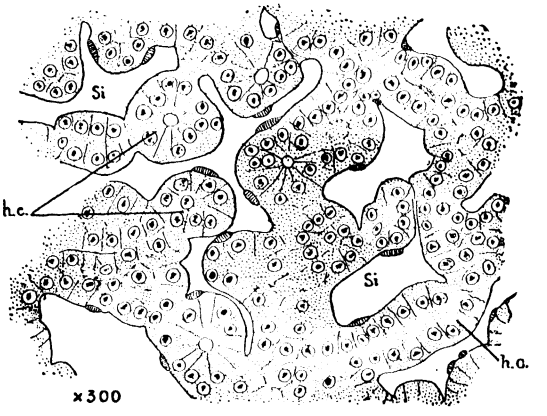

FIG. 327.—LIVER OF EMBRYO CHICK OF ELEVEN DAYS. (Sedgwick Minot.)
h.c., hepatic trabeculæ; *Si*, sinusoids.

enclosed within the original sinus, is quite different from that which obtains with the ordinary capillaries.

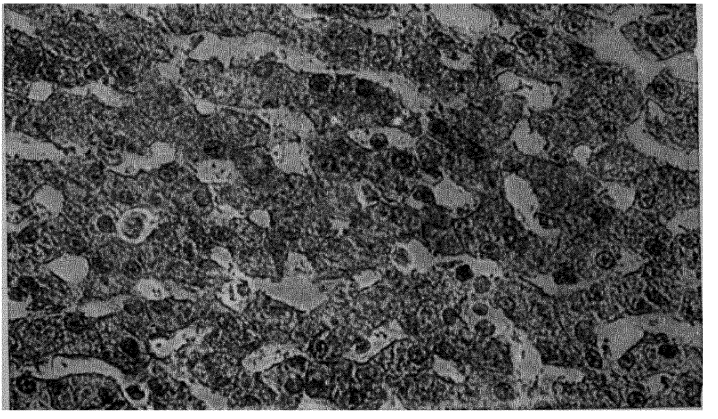

FIG. 328.—SECTION OF DOG'S LIVER, STAINED WITH HÆMATOXYLIN, SHOWING THE SINUSOID NATURE OF THE BLOOD-CHANNELS BETWEEN THE LIVER-CELLS. (E. Sharpey-Schafer.) × 200. Photograph.
It will be observed that in most places the blood-sinuses are directly bounded by the liver-cells, the endothelium being deficient, except for a few scattered cells—the cells of Kupffer.

LYMPHATIC SYSTEM.

To the lymphatic system belong not only the *lymph-vessels* and *lymph-glands*, but also the *serous membranes*.

The larger lymph-vessels somewhat resemble the veins in structure

(fig. 329), except that their coats are much thinner and valves much more numerous. In smaller lymphatics, which in the fresh condition have a clear, transparent appearance and are very thin (fig. 330), the wall is formed, first, by a lining of endothelium-cells (lymphatic endothelium), which are elongated



FIG. 329.—SECTION OF LARGE LYMPHATIC VESSEL. (Evans.)

c, *c*, capillary vessels distributed to the muscular coat (tunica media).

in the direction of the axis of the vessel; and, secondly, by a layer of circularly and obliquely disposed muscular fibres (fig. 331). Numerous valves generally characterise lymphatic vessels, and as, like the veins, their walls are bulged out beyond the valves, the vessels usually have a moniliform appearance. Occasionally there are fewer valves and the outline of the vessel is more even: in this case there is less muscular tissue in the wall of the vessel. In the smallest vessels (so-called *lymph-capillaries*, which are, however, considerably larger than the blood-capillaries) there is nothing but endothelium remaining;

the cells of this are frequently not more elongated in one direction than in another; they always have a characteristic wavy outline (fig. 332).

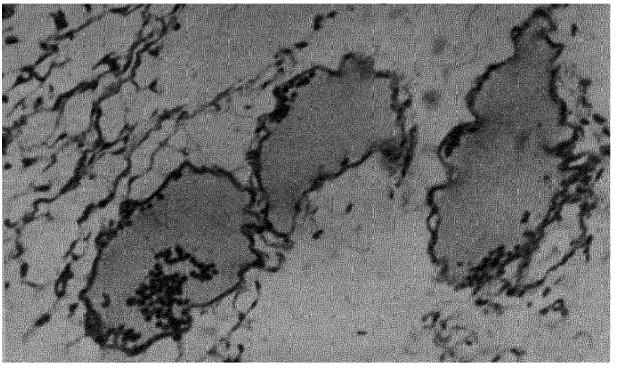

FIG. 330.—SECTION OF SMALL LYMPH-VESSELS IN LOOSE AREOLAR TISSUE. (H. M. Carleton.) × 270.

The vessels are filled with coagulated lymph; they also contain lymph-corpuscles.

The lymphatics receive numerous nerve-fibres, which are amyelinate, and end in a ramification of the finest fibrils distributed to the coats of the vessels (fig. 333).

The lymphatics of the mesentery contract rhythmically in the rat and

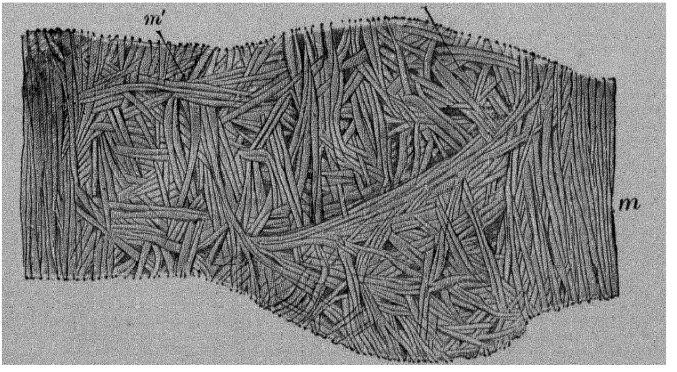

FIG. 331.—SUPRAVALVULAR DILATATION OF A LYMPHATIC OF THE MESENTERY OF A CAT. SILVER NITRATE PREPARATION. (Ranvier.)

m, circular muscle-fibres; *m'*, *m'*, irregular arrangement of muscle at the dilation.

guinea-pig, although the amount of plain muscle in their wall is not large. In most animals the lacteals do not exhibit rhythmic contractility, although they react to stimuli applied either directly or through nerves (sympathetic). The smaller lacteals of the squirrel have no plain muscle, but nevertheless

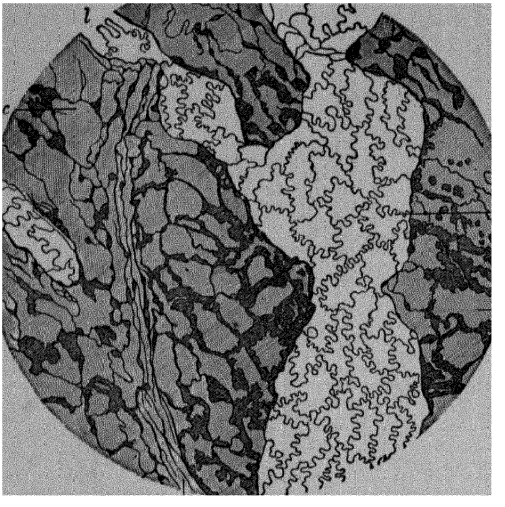

FIG. 332.—A SMALL PART OF THE LYMPHATIC PLEXUS OF THE PLEURAL LAYER OF THE DIAPHRAGM. (Ranvier.) Magnified 110 diameters.

l, lymphatics with characteristic endothelium; *c*, cell-spaces of the connective tissue here and there abutting against the lymphatic.

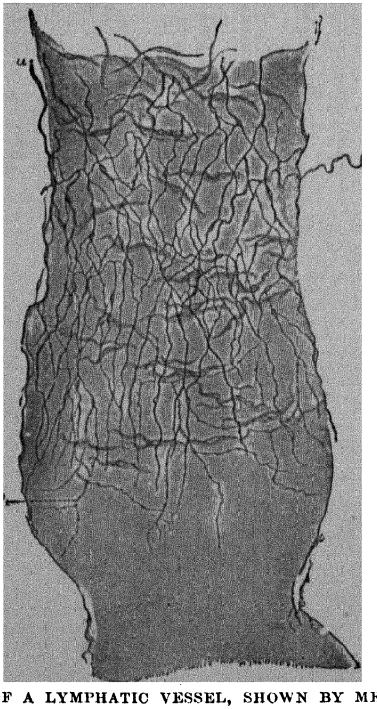

FIG. 333.—NERVES OF A LYMPHATIC VESSEL, SHOWN BY METHYLENE-BLUE. (Dogiel.)

a, *a*, amyelinate fibres passing to the vessel; *b*, part of their terminal ramification.

react to stimuli: hence it may be assumed that the endothelium is contractile (Carleton and Florey).

Lymphatics begin either as *plexuses*: this is the case in serous membranes



FIG. 334.—LYMPHATIC PLEXUS OF CENTRAL TENDON OF DIAPHRAGM OF RABBIT, PLEURAL SIDE. NITRATE OF SILVER PREPARATION. (Klein.)

a, larger vessels with lanceolate cells and numerous valves; *b*, *c*, lymph-capillaries with wavy-bordered cells. The cell-spaces of the connective tissue are not represented in this figure.

and aponeuroses (fig. 334): or as *lacunar spaces*, as is the case with many of the viscera, and with all the lymphatics of Amphibia. They frequently accompany the blood-vessels of a part: the smaller arteries and veins being often entirely surrounded by lymph-vessels. The serous cavities may be

regarded as large lymph-lacunæ: in some there are open communications with lymph-vessels.

In order to show the structure of lymph-vessels, it is usual to stain a tissue with nitrate of silver. For exhibiting their distribution they may generally be injected by sticking the nozzle of a fine injection cannula into any organ which contains them, and forcing coloured fluid under gentle pressure into the interstices of the connective tissue.

In silvered preparations the lymphatics always appear in the form of clear channels in the stained ground-substance of the connective tissue, and their walls are in close connexion with the cells and cell-spaces of that tissue (figs. 332, 335). But no open communication is observable between the commencing lymph-vessels and the interstices of the connective tissue, although from the readiness with which they can be injected from the latter there must be a ready means of passage of the interstitial lymph into the commencing lymphatics.

DEVELOPMENT OF LYMPH-VESSELS.

The investigations of Ranvier, confirmed by Miss Sabin, F. T. Lewis, and others, have shown that the lymphatics grow at certain places from the venous system, and gradually spread from these spots to all parts of the embryo. In man this connexion with the venous system only persists at two places, viz. the opening of the thoracic duct and that of the right lymphatic duct into the great veins at the root of the neck.

SEROUS MEMBRANES.

The **serous membranes,** which may be studied in connexion with the lymphatic system, are delicate membranes of connective tissue which line the internal cavities of the body, and are reflected over many of the thoracic and abdominal viscera; in passing to these they form folds (such as the mesentery), within which blood-vessels, lymphatics, and nerves are conducted to the viscera.

The inner surface of a serous membrane is lined by a continuous layer of *pavement epithelium*, or *endothelium* (fig. 336), which is very distinct in nitrate of silver preparations. This endothelium has a vertically striated free border (see p. 78); its cells are connected by intercellular bridges. In some places there are apertures between the endothelium-cells which lead directly into subjacent lymphatic vessels. These apertures are called *stomata*; they are generally surrounded by special cells (fig. 337). They are numerous upon the peritoneal surface of the diaphragm, but are nowhere better studied or more easily seen than in the peritoneal membrane at the back of the abdominal cavity in the frog. This membrane lies between and at the sides of the kidneys, and serves to separate the peritoneal cavity from the large lymph-space just behind it. If the membrane is prepared by the nitrate of silver method (p. 232, § 4), the stomata and the cells which bound them are shown as well as the serous and the lymphatic endothelium.

The endothelium of a serous membrane rests upon a homogeneous basement-membrane, which is especially well marked in the serous membranes

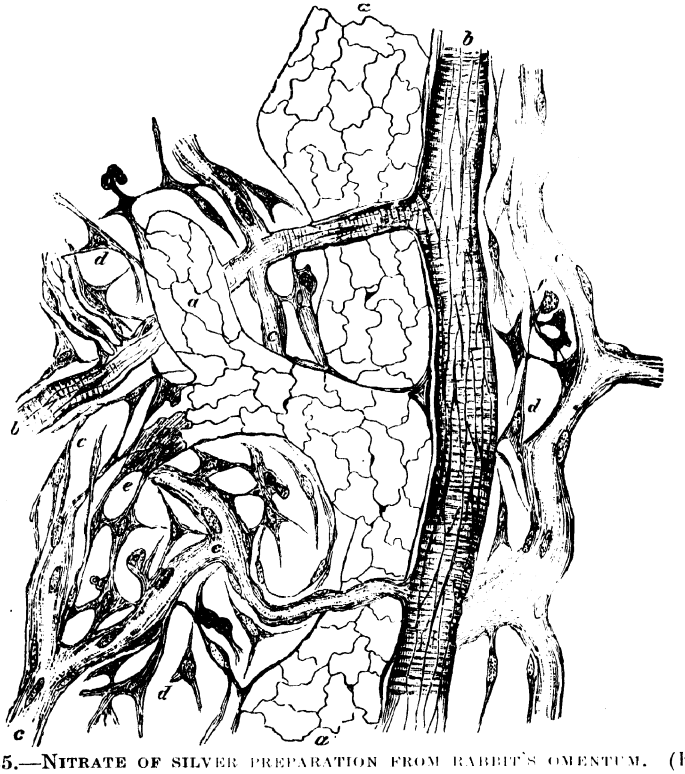

FIG. 335.—NITRATE OF SILVER PREPARATION FROM RABBIT'S OMENTUM. (Klein.)

ymph-vessel; *b*, *b*, small arteries; *c*, capillary vessels; those on the right passing into a small vein; *d*, connective-tissue cells—which, in this instance, have been stained by the silver treatment. They are seen (*c*) to be continuous with the cells of the lymphatic rootlets, and also to be attached to the walls of the capillaries.

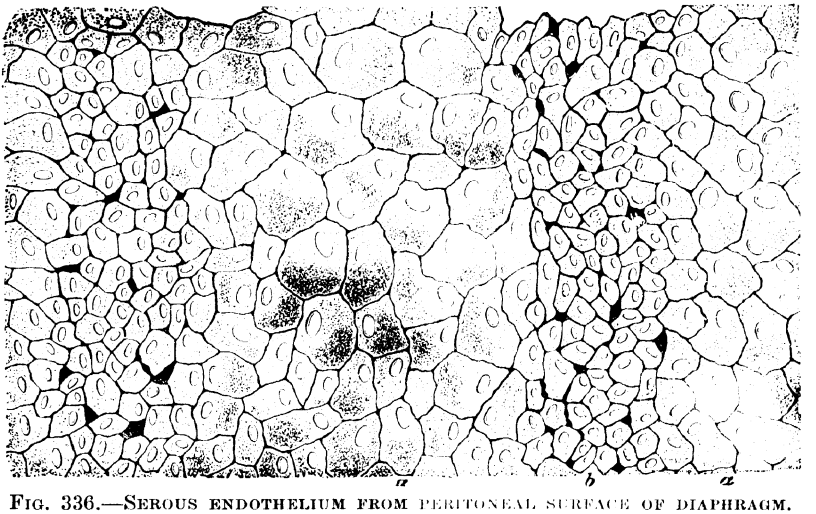

FIG. 336.—SEROUS ENDOTHELIUM FROM PERITONEAL SURFACE OF DIAPHRAGM. NITRATE OF SILVER PREPARATION. (Klein.)

a, larger; *b*, smaller cells. Between the latter are seen small irregular spaces (pseudo-stomata).

of man. The rest of the thickness of the membrane is composed of connective tissue, with a network of fine elastic fibres near the inner surface (see fig. 448).

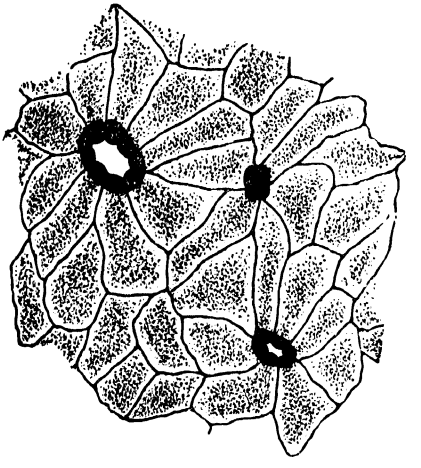

FIG. 337.—ENDOTHELIUM FROM THE POSTERIOR PART OF THE FROG'S PERITONEUM, SHOWING THREE STOMATA LEADING INTO THE CISTERNA LYMPHATICA MAGNA. (After Ludwig and Schweigger-Seidel.)

DEVELOPMENT OF SEROUS MEMBRANES.

The serous cavities are originally formed in the embryo as a cleft in the mesoderm (pleuro-peritoneal split, cœlom) which becomes lined with endothelium, and, later, separates into peritoneum, pleura, and pericardium. Outside the endothelium the cœlomic wall is eventually differentiated into the other tissues of the serous membrane.

LESSON XXII.

LYMPH-GLANDS, SPLEEN, TONSILS, THYMUS.

1. SECTIONS of a lymph-gland which has been hardened in 'susa' or 10 p.c. formol, stained in bulk, and embedded in paraffin. Or sections may be stained with hæmatoxylin and eosin, or with Van Giesen. Notice (1) the fibrous and muscular capsule, with trabeculæ extending inwards from it through the cortex, and anastomosing with one another in the medulla, (2) the dense lymphoid tissue forming spheroidal masses in the cortex (cortical nodules) and rounded cords in the medulla. Notice also the clearer channel or lymph-sinus which everywhere intervenes between the fibrous tissue and the lymphoid tissue. Observe the fine fibres and branched cells which bridge across the channel.

Make a general sketch, under a low power, of a portion of the cortex together with the adjoining part of the medulla, and, under a high power, drawings of small portions of cortex and medulla.

The reticular tissue of the lymph-glands has already been studied (pp. 103 to 105).

2. Sections of a hæmal lymph-gland. These may be found in the neck of the sheep or ox, in the neighbourhood of the large blood-vessels. Stain with hæmatoxylin and eosin or with alcoholic eosin and methylene-blue.

3. Sections of spleen hardened in 'susa' or 10 per cent. formol and stained with alcoholic eosin and methylene-blue or with iron-hæmatoxylin. Notice the trabeculæ extending into the substance of the organ from the capsule. Notice also that the glandular substance is of two kinds: (1) lymphoid tissue accumulated around the small arteries and here and there massed to form lymphoid nodules —the Malpighian corpuscles—and (2) the pulp—consisting of a reticulum of fibrils and branching cells: this tissue contains blood in its interstices. The reticulum is better seen if the blood has been washed out of the organ by perfusion with Ringer's solution through the splenic artery.

Sketch part of a section under a low power and a small portion of the pulp under a high power.

4. In sections of tonsil prepared similarly to those of lymph-gland, notice the large amount of lymphoid tissue, partly collected into nodules. Observe also that the stratified epithelium which covers the mucous membrane is infiltrated with lymph-corpuscles. The tonsil is beset with pit-like recesses, with mucus-secreting glands opening into the pits.

5. Lymphoid nodules of mucous membranes. In other mucous membranes besides that of the back of the mouth and pharynx, collections of lymphoid tissue occur which resemble those of the tonsils; such nodules form the solitary glands of the stomach and intestines and the agminated glands of the small intestine. They are also found in the trachea and bronchial tubes and in the œsophagus. These structures will be studied later in sections of the organs in question.

6. Sections of the thymus gland of an infant or fœtus. Notice that the masses of lymphocyte-like cells which mainly form the lobules of the gland are separated by septa of connective tissue, and that the lobules show a distinction into two parts, cortex and medulla. There are no lymph-paths within the lobules. Observe the differences of structure of the cortex and medulla, and especially notice the concentric corpuscles in the medulla. In the adult the same structures can be

seen, but there is a considerable development of adipose tissue in the connective tissue of the organ.

Make a sketch of one of the lobules under a low power and of a small part of the medulla under a high power, including one or two concentric corpuscles. Measure the latter.

LYMPH-GLANDS.

A lymph-gland is composed of lymphoid tissue, arranged as **cortex** and **medulla.** A framework of fibrous tissue encloses the lymphoid tissue, but is everywhere separated from it by a sinus-like channel, bridged across by

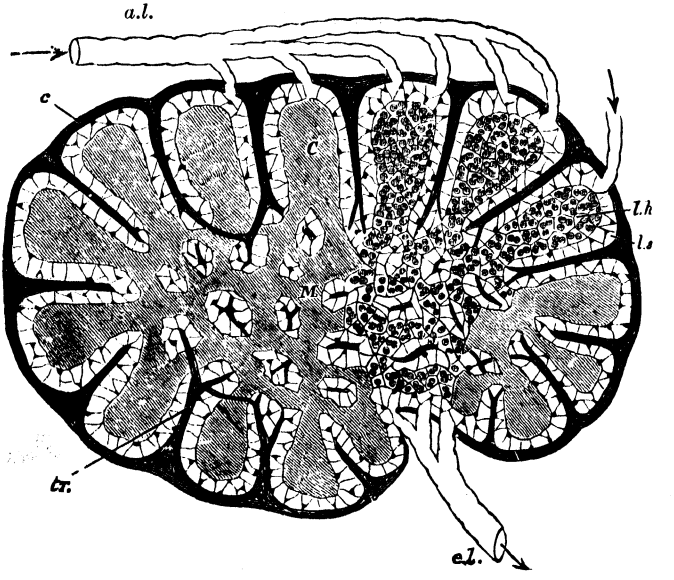

FIG. 338.—DIAGRAM OF A SECTION OF LYMPH-GLAND. (W. Sharpey.)

a.l., afferent; *e.l.*, efferent lymphatics; *C*, lymphoid nodules of cortical substance; *M*, lymphoid reticulating cords of medullary substance; *l.h.*, lymphoid tissue; *l.s.*, lymph-sinus; *c*, capsule sending trabeculæ, *tr*, into the substance of the gland.

cells and fibres, known as the **lymph-channel.** The framework consists of a **capsule** (fig. 338, *c*), and of **trabeculæ** (*tr*) which pass at intervals inwards from the capsule, and after traversing the cortex of the gland, divide and reunite with one another to form a network in the medulla. At one part of the gland there is usually a depression (**hilum**); at the bottom of this the medulla comes to the surface and its trabeculæ are again continuous with the capsule. Both capsule and trabeculæ contain plain muscular tissue, in some animals in considerable amount.

The proper glandular substance (*l.h.*) is composed of a fine reticulum with the meshes thickly occupied by lymph-corpuscles (lymphoid tissue). It occupies all the interstices of the gland, forming comparatively large rounded masses in the cortex (**lymphoid nodules,** *C*), which may be two or three deep,

and smaller reticulating cord-like masses (**lymphoid cords,** *M*) in the medulla.

The lymph-channel is bridged across by fibres derived from the capsule and trabeculæ, which pass to the lymphoid tissue and merge into its reticulum (figs. 123, 339). The fibres are often largely concealed by branching cells (fig. 122), which were at one time thought to constitute the whole reticulum. In some animals (*e.g.* ox) these cells contain pigment, giving the medulla a dark colour. They are highly phagocytic and may contain disintegrating red cells, or reddish granules derived from the disintegration of red cells. They

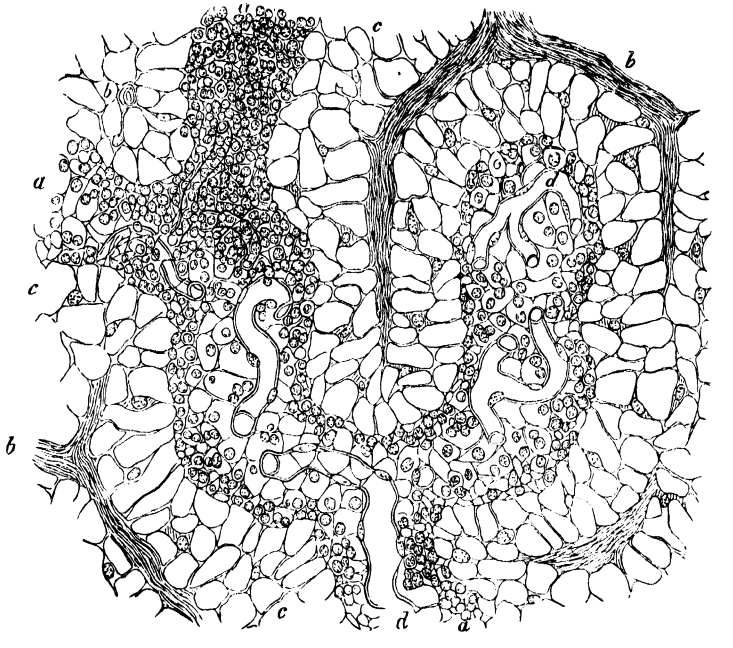

FIG. 339.—SECTION OF THE MEDULLARY SUBSTANCE OF A LYMPH-GLAND. (v. Recklinghausen.) × 300.

a, lymphoid cords; *c*, lymph-channels; *b*, trabeculæ; *d*, capillary blood-vessels.

also take in foreign particles which may have been conveyed in the lymph to the gland. Thus it is common for the lymph-glands at the root of the lung to contain particles which have been inhaled in the form of dust.

The branched cells of the reticulum are continued over the trabeculæ, and at the entrance and exit of the lymphatics are continuous with the endothelium of these vessels. They represent therefore a lymphatic endothelium bounding the lymph-spaces, but like the corresponding endothelium of the small veins of the spleen they have become branched and form part of the supporting reticulum of the organ.

The phagocytic function of the branched cells of the reticulum is shared by

certain large cells which are sometimes found lying loose in the lymph-channel and are probably derived from the branched cells. These cells resemble the large phagocytes found in the pulp of the spleen (see p. 256), and like those may ingest erythrocytes.

Giant-cells with lobed or multiple nuclei are also occasionally seen in lymph-glands.

The reticulum, with its enveloping branched cells, forms part of the reticulo-endothelial system which has already been described (p. 105).

Afferent lymph-vessels (fig. 338, *a.l.*) enter the lymph-sinuses of the cortex after ramifying in the capsule; the lymph is conveyed slowly along

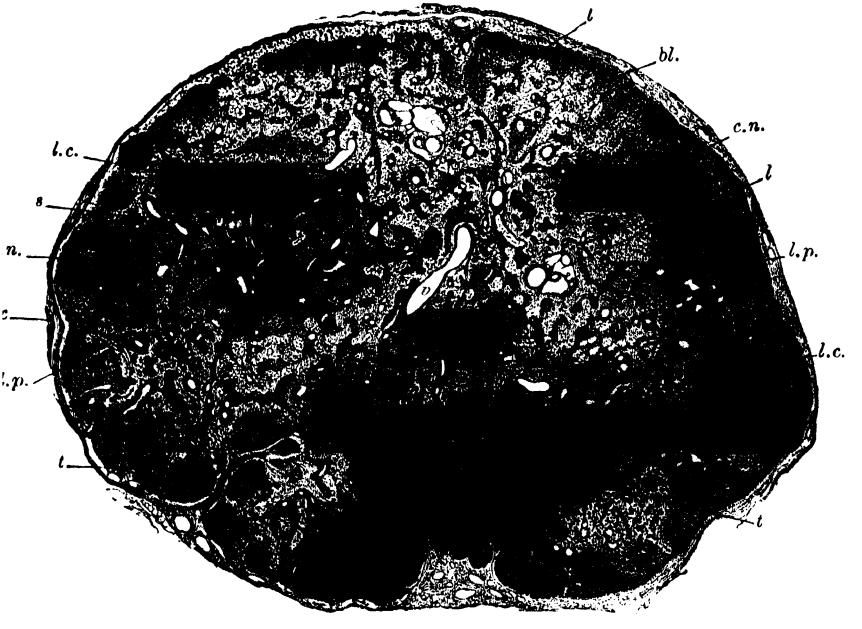

FIG. 340.—SECTION OF A LYMPH-GLAND FROM THE NECK OF AN EIGHT-YEAR-OLD CHILD. (v. Ebner.) × 13.

c, capsule; *c.n.*, cortical nodules, some with germ-centres; *l.c.*, lymphoid cords of medulla (dark); *l.p.*, lymph-path (light); *s*, cortical sinus; *t*, trabeculæ; *v*, vein; *l*, efferent lymph-vessels, accompanying and partly surrounding blood-vessels, *bl.*

the channels of the cortical and medullary part towards the hilum. At the hilum it is gathered up by an efferent vessel or vessels (*e.l.*) taking origin in the lymph-sinuses of the medulla.

The outgoing lymphatics always contain many more lymph-corpuscles than those which enter the gland, for lymph-corpuscles are constantly being formed by karyokinetic division of pre-existing cells in the glandular substance, especially in the centre of each cortical nodule (*germ-centre* of Flemming); they gradually find their way through the close reticulum of the lymphoid tissue into the lymph-channels. The cells which thus

subdivide to form the lymphocytes are larger than the rest and are distinguished by the term *lymphoblasts*.

In some lymph-glands the fibrous trabeculæ are very slightly developed so that the gland seems in section to be a mass of lymphoid tissue, pervaded by lymph-channels and with rounded nodules (germ-centres) scattered about, especially in the cortex (fig. 340). This condition obtains with most of the lymph-glands of man and is also found in some other mammals. In most, such as the cat, dog, and ox, the trabeculæ are well developed, and contain much muscular tissue; the lymph-channels are correspondingly well marked off.

Lymphoid tissue occurs in a nodular form not only in lymph-glands but in a large number of places, such as the mucous membrane of the alimentary canal and the bronchial tubes. When (water-soluble) vitamin B is deficient in the diet lymphoid structures generally, and especially those of the alimentary canal, tend to become atrophied (Cramer). Atrophy also results from the application of X-rays, to which lymphocytes are particularly sensitive, their multiplication being arrested by it and its prolonged application producing actual destruction.

The leucocytes of the germ-centres frequently show, in sections, peculiar darkly staining bodies—the *stainable bodies* of Flemming—the nature of which has not been determined.

An artery passes into each gland at the hilum; its branches are conveyed at first along the fibrous trabeculæ of the medulla, but soon become surrounded by lymphoid tissue, in which they break up into capillaries (fig. 339, *d*). The blood is returned by veins which are conducted along the fibrous trabeculæ, joining to form larger vessels which eventually emerge at the hilum.

Nerve-fibres pass to lymph-glands: they appear to be distributed chiefly as amyelinate fibres to the plain muscular tissue of the blood-vessels, capsule and trabeculæ.

HÆMAL LYMPH-GLANDS.

In many animals a certain number of lymph-glands are observable which have a red colour. They were first described by H. Gibbes in 1889 and are most easily found in the sheep. In man, these hæmal lymph-glands are found in the retro-peritoneal tissue and in the mediastinum thoracis. On section, what correspond to the lymph-channels in ordinary lymph-glands are seen to be occupied by blood (fig. 341); while the remainder of the gland has the ordinary structure of a lymph-gland. The blood passes into the sinuses from arterial capillaries, which appear, as in the spleen, to open into the tissue interstices, from which at other parts small veins arise in like manner. Like the spleen these hæmal glands show numerous large phagocytes which contain red blood-corpuscles in various stages of transformation into pigment-granules.

Ordinary lymph-glands are confined to mammals, but Vincent and Harrison found hæmal lymph-glands in birds.

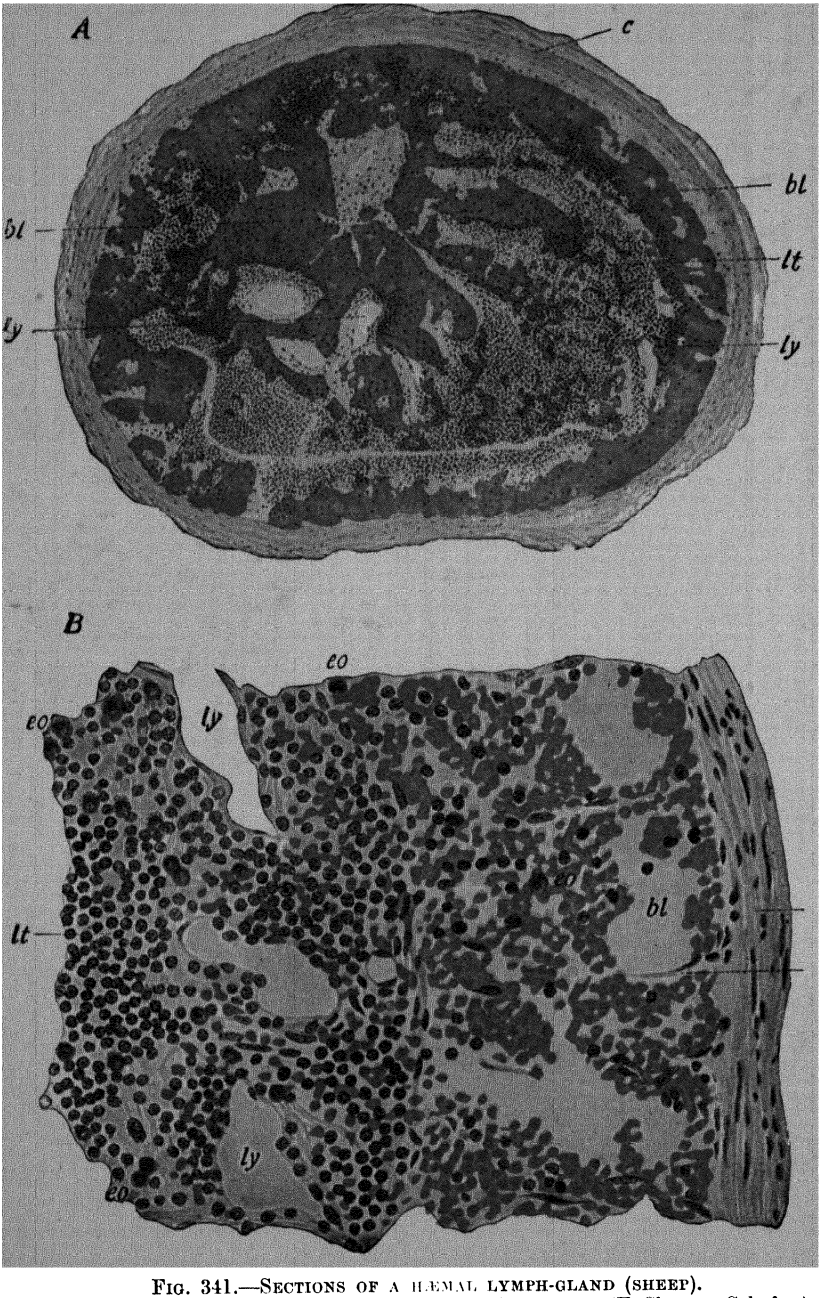

FIG. 341.—SECTIONS OF A HÆMAL LYMPH-GLAND (SHEEP).
A, magnified 50 diameters; *B*, magnified 350 diameters. (E. Sharpey-Schafer.)

c, capsule with plain muscle-fibres; *tr*, trabeculæ passing in from capsule; *bl*, sinuses containing blood; other red corpuscles are seen in the interstices of the lymphoid tissue, *lt*; *ly*, lymph-sinuses; *eo*, eosinophil leucocytes among the lymphocytes of the lymphoid tissue.

THE SPLEEN.

The spleen is the largest of the so-called ductless glands. It is functionally connected with the blood, white blood-cells being formed, and red cells being destroyed within it. It also forms a reservoir for blood, being greatly dilatable and contractile.

Like the lymph-glands, the spleen is invested with a fibrous and muscular **capsule** (figs. 342, 343, *c*), which is, however, stronger and has far more plain

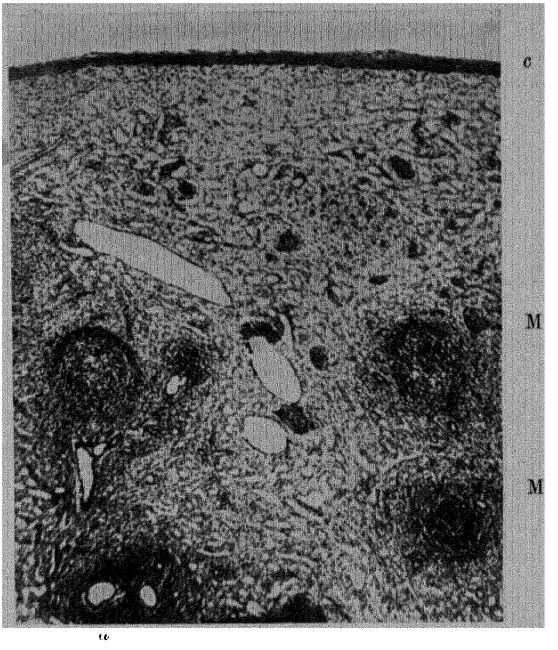

FIG. 342.—SECTION OF SPLEEN: HUMAN. (E. Sharpey-Schafer.) × 50. Photograph.

The part illustrated includes capsule, *c*; pulp with venous sinuses and larger venous vessels; three Malpighian corpuscles (M), and two or three arteries (*a*), with their surrounding ellipsoids.

muscular tissue than that of the lymph-glands. Outside the capsule is a covering derived from the peritoneum. The capsule sends bands or trabeculæ into the organ; these join with a network of similar trabeculæ which pass into the gland at the hilum along with the blood-vessels. In the interstices of the framework thus constituted lies a soft pulpy substance containing a large amount of blood, and therefore of a deep red colour (**pulp of the spleen**), dotted within which are here and there to be seen small round bodies, whiter than the pulp in the fresh organ but darker in stained sections, the **Malpighian corpuscles** (M, M). These are composed of lymphoid tissue gathered up into globular or cylindrical masses enveloping the smaller arteries, while the red pulp surrounding them, which forms the bulk of the organ, is composed of a close network of reticular tissue (fig. 344), partly covered by flattened and

branched cells (figs. 345, 346) and containing in its meshes blood-corpuscles both red and white.

The Malpighian corpuscles frequently but not always show a clearer central nodule or *germ-centre*, characterised by the presence of numerous karyokinetic figures; and the 'stainable bodies' of Flemming, which have been noticed under lymph-glands, are also seen in some.

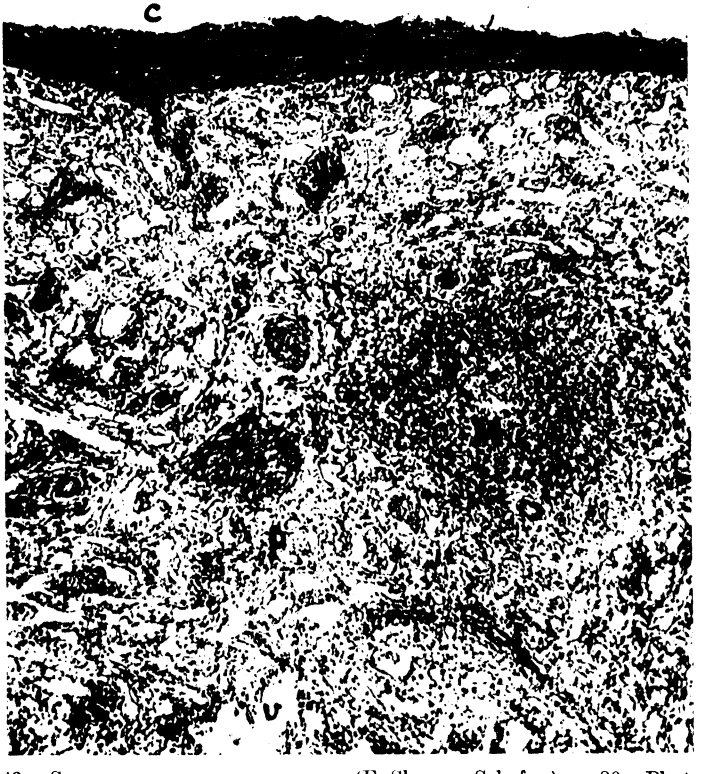

FIG. 343.—SECTION OF SPLEEN: HUMAN. (E. Sharpey-Schafer.) × 80. Photograph.
c, capsule; *v*, a venous sinus of the pulp; *tr*, a trabecula cut obliquely; M, a Malpighian corpuscle; P, pulp.

Three kinds of cells occur in the spleen-pulp, as follows: (1) large amœboid phagocytic *splenic cells* (*macrophages*) (fig. 346); (2) *giant-cells* with multiple nuclei (fig. 347); (3) *reticulum cells* which assist in forming the network (fig. 345), and are attached to the endothelium-cells of the blood-channels. In addition the pulp contains all the corpuscular elements of blood: the number of corpuscles both red and white being rather greater per cubic millimetre than in the blood of the general circulation. The macrophages are frequently found to contain red blood-cells in various stages of transformation into pigment. They occur in the interstices of the pulp, in the venous sinuses, and in the emergent veins (fig. 346).

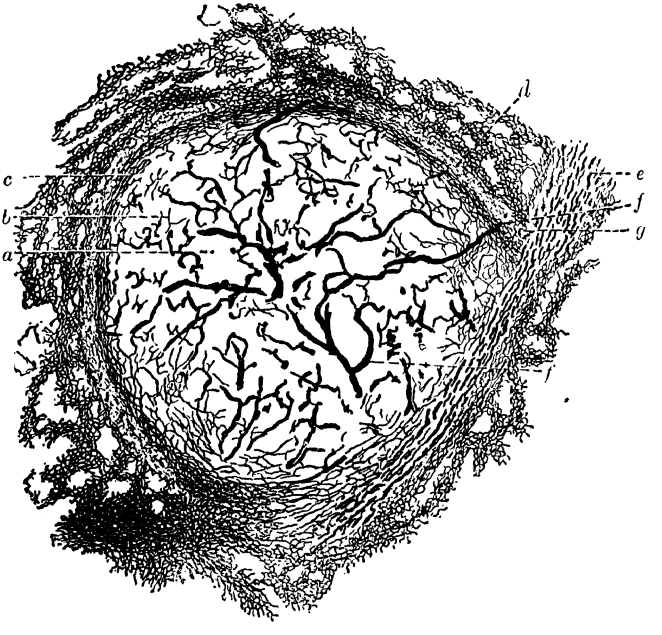

FIG. 344.—RETICULUM OF SPLEEN, GOLGI METHOD. (Oppel.) Low power.
a, Malpighian corpuscle; *b*, part of its reticulum; *c*, condensed reticulum at its margin; *d*, continuation into reticulum of pulp with its venous spaces; *e*, wall of arteriole; *f*, *f*, blood-vessels of Malpighian corpuscle; *g*, reticulum of arteriole expanding into that of the Malpighian corpuscle.

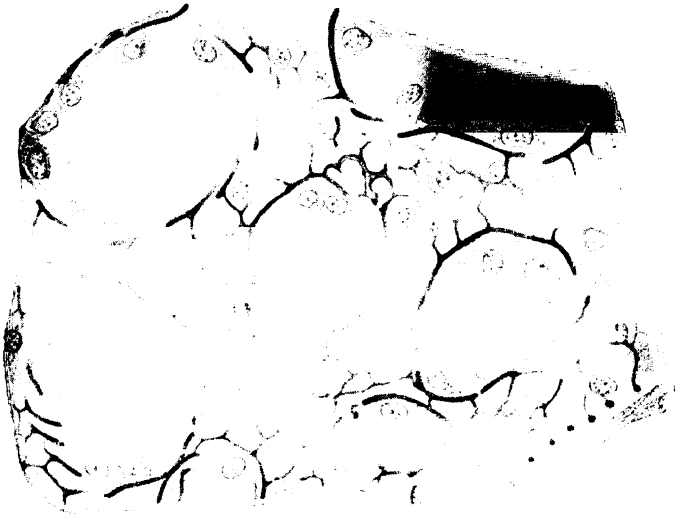

FIG. 345.—SMALL VEINS OF SPLEEN-PULP WITH RETICULAR TISSUE: HUMAN. (Hoyer.) High power.
The venous sinuses, which are invested by encircling fibres, show gaps in their walls whereby they communicate with the interstices of the pulp. Notice the prominent endothelium-cells.

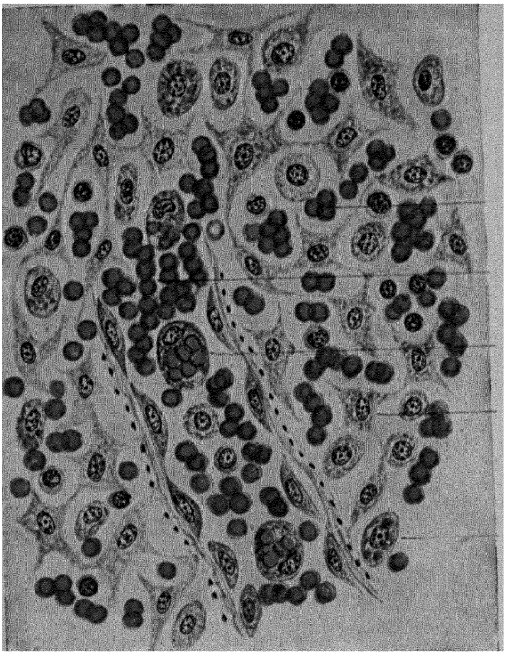

FIG. 346.—THIN SECTION OF SPLEEN-PULP OF CHILD, HIGHLY MAGNIFIED, SHOWING THE MODE OF ORIGIN OF A SMALL VEIN IN THE INTERSTICES OF THE PULP. (E. Sharpey-Schafer.) × 400.

a, blood in pulp; *a'*, blood in vein; *b*, phagocyte in vein; *c*, branched cell of pulp; *d*, phagocytic splenic cell.

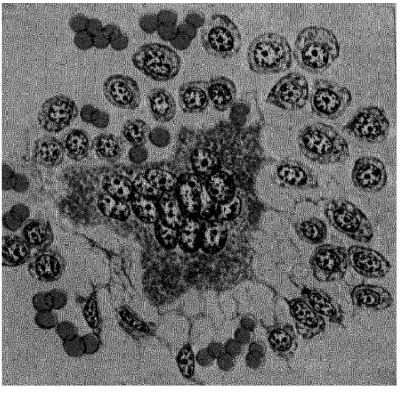

FIG. 347.—A MULTI-NUCLEATED GIANT-CELL FROM THE SPLEEN OF A KITTEN. (E. Sharpey-Schafer.) × 400.

The giant-cells are most frequent in young animals. The reticular cells of the sponge-work appear to be of the same nature as the endothelium-cells of the terminal capillaries and veins of the pulp. They are connected by branches with one another and with the endothelium-cells of the vessels. The large amœboid phagocytes (spleen-cells) are said to be budded off from them. Both the reticular cells and the large phagocytes belong to the reticulo-endothelial system of Aschoff (p. 105).

Nucleated coloured corpuscles (erythroblasts) are found in the embryo, and occasionally after birth, in the spleen-pulp. The blood of the splenic vein is at all times relatively rich in leucocytes, and also, it is said, in platelets.



FIG. 348.—SECTION OF SPLEEN: HUMAN. (E. Sharpey-Schafer.) × 150. Photograph.
a, an arteriole with its 'ellipsoid' investment of lymphoid tissue; *v*, venous spaces of the pulp; *tr*, a trabecula.

The arteries, which are at first conducted from the hilum along the trabeculæ into the interior of the organ, presently leave the trabeculæ, and their external coat becomes gradually converted into a thick sheath of lymphoid tissue which invests them for the remainder of their course; this sheath in places becomes swollen into the Malpighian corpuscles already mentioned. The smaller arteries distribute a few capillaries to the Malpighian corpuscles, and then break up into tufts (*penicilli*, Ruysch) of capillary arterioles which open into the interstices of the pulp. The arterioles are 'end-arteries,' *i.e.* the ramifications do not anastomose. The arteries are accompanied by branches of the splenic nerve, each branch of artery and nerve being distributed to its own special zone of the organ, so that if during

life only one of the branches of the nerve is stimulated, the corresponding zone of the organ undergoes contraction; this involves not merely the blood-vessels, but also the corresponding segment of the capsule (Tait and Cashin).

The arterioles forming the penicilli are remarkable in that they are surrounded, near their terminations in the pulp, by spindle-shaped investments of concentric lamellæ of connective tissue with numerous lymphocytes in the meshes of the tissue. These investments are known as *ellipsoids* (figs. 348, 349). They function as valves, allowing the blood to percolate from

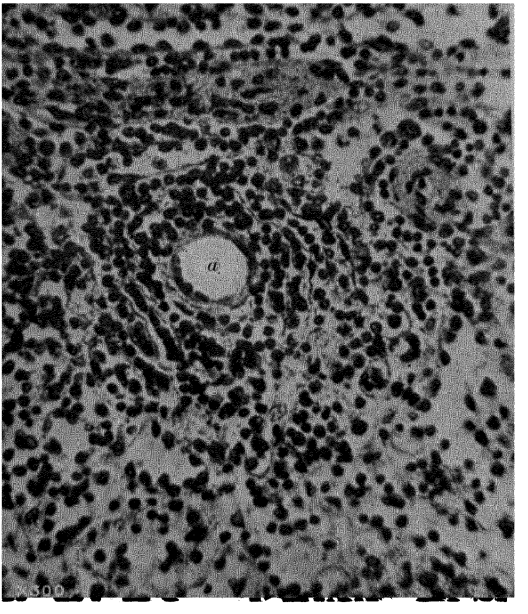

FIG. 349.—ARTERIOLE OF SPLEEN-PULP (MAN) WITH ITS ADVENTITIA REPLACED BY LYMPHOID TISSUES FORMING THE COMMENCEMENT OF AN 'ELLIPSOID.' (E. Sharpey-Schafer.)

tr, a trabecula; *a*, section of arteriole; *v*, venous sinuses.

the arterioles into the pulp, whence it passes into the venous sinuses, but preventing any back flow. Thus it is impossible to inject the arteries of the organ from the splenic vein: the injecting material does not go beyond the pulp. Each ellipsoid is usually surrounded by a number of venous sinuses.

If Indian ink is injected into the blood of a living animal the carbon particles are held up in the phagocytes of the reticulo-endothelial system (pp. 105, 106). This is conspicuously the case with the spleen, in which such particles are in the first case caught in the ellipsoids: from here they are taken, probably by amœboid leucocytes, into the pulp, eventually becoming engulfed by the large phagocytic cells of the reticular tissue and by the endothelial cells of the venous sinuses.

Passing into the pulp, beyond the Malpighian corpuscles, and communicating with its interstices are the capillary vessels which form the terminations of the arteries; whilst venous channels—characterised in

the human spleen by an encirclement of reticulum-fibres (figs. 345, 350), and by the presence of a layer of highly characteristic, elongated and prominent endothelium-cells (fig. 350)—course through the pulp and bring the blood which has passed into its interstices from the arterial capillaries towards the larger veins of the organ, which run along the trabeculæ and are conducted by them to the hilum.

The splenic vein is very much larger than the corresponding artery. It is supplied by special amyelinate vasomotor nerves which join the left phrenic nerve in the mid-cervical region and accompany it to the diaphragm. This they perforate and deviating towards the cœliac ganglion pass to the splenic vein; entering the spleen with it, they are distributed to the branches of the vein. Stimulation of any one of these nerves causes prolonged localised contraction of the vein to which it is distributed and consequent engorgement with blood of that part of the spleen from which the vein emanates. Stimulation of all produces engorgement and dilatation of the whole organ.

The nerves of the spleen include, besides efferent fibres to the blood-vessels, capsule and trabeculæ, mostly derived from the sympathetic, also afferent fibres, stimulation of which causes, reflexly, alterations in its volume, as well as reflex contractions of the ventral abdominal musculature (Cleland and Tait).

The lymphatics of the spleen run partly in the trabeculæ and capsule, and partly in the lymphoid tissue ensheathing the arteries. They join to form larger vessels which emerge at the hilum. There are no lymphatics in the spleen-pulp itself.

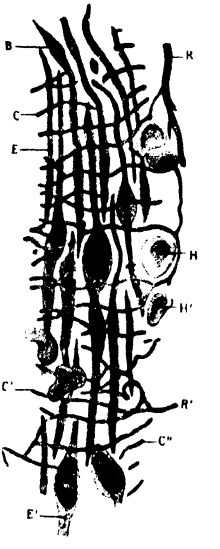

FIG. 350.—ENDOTHELIUM-CELLS OF VENOUS SINUSES OF SPLEEN. (J. Jolly.) × 1000.

R, R', fibres of reticulum of pulp; C, C', C'', fibres of reticulum encircling a venous sinus; E, E', endothelial cells of sinus; B, a broadened portion of the endothelium-cell serving for attachment to the fibres of the reticulum; H, H', erythrocytes.

DEVELOPMENT OF THE SPLEEN.

The spleen first appears, at about the fifth week of fœtal life, as a mass of mesenchyme cells attached to the mesenteric fold of the stomach. Within the mass, spaces containing blood appear and the trabecular framework is formed, continuous with the capsule externally. The reticulum of the pulp and the Malpighian bodies become differentiated later, but details regarding their formation are lacking.

THE TONSILS AND OTHER LYMPHOID STRUCTURES.

The tonsils are two lymphoid organs placed one on each side of the pharynx, between the pillars of the fauces. They are covered on their free surface with stratified epithelium; this surface is pitted with apertures which lead into recesses or crypts in the substance of the organ (fig. 351). These recesses are all lined by a prolongation of the stratified epithelium of the

surface and into them the ducts of numerous small mucous glands open. The body of each tonsil is composed of lymphoid tissue, which, besides being diffused throughout the organ, is at intervals aggregated into nodules,

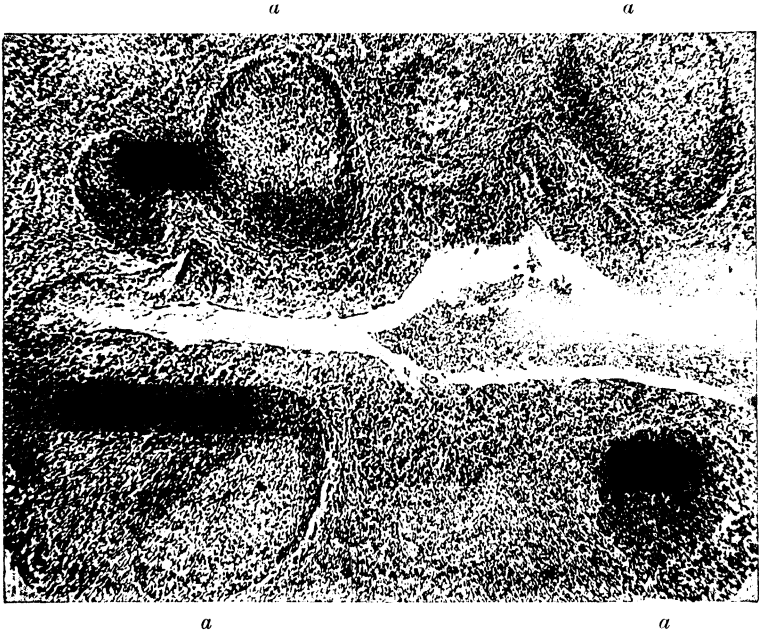

FIG. 351.—SECTION OF TONSIL: HUMAN. (E. Sharpey-Schafer.) × 50.
Photographed from a preparation by M. Heidenhain.
a, *a*, lymphoid nodules; *b*, a recess lined by stratified epithelium which is permeated by leucocytes. Opposite *b*, a mass of leucocytes which have escaped into the cavity of the recess.

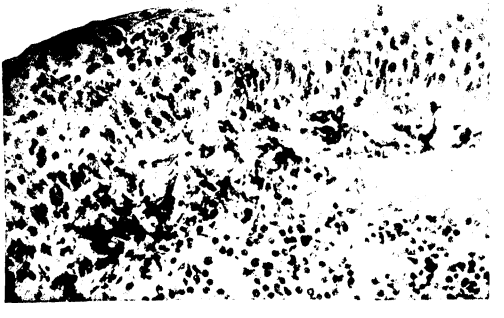

FIG. 352.—PART OF A SECTION OF RABBIT'S TONSIL SHOWING INFILTRATION OF THE EPITHELIUM BY LEUCOCYTES. (E. Sharpey-Schafer.) Photograph.

in which the lymph-cells are more closely arranged than elsewhere. In the centre (*germ-centre*) of these nodules active multiplication of large lymph-cells occurs; this is, in fact, the cause of the formation of such nodules, as in the other organs (spleen, lymph-glands) in which they are found. The epithelium

which covers the tonsils is itself infiltrated with lymph-corpuscles (figs. 351, 352), many of which wander out on to the free surface, and become mingled with the saliva as the so-called salivary corpuscles.

The lymphoid tissue of the tonsils has numerous blood-vessels, and also lymph-vessels.

The mucous membrane of the neighbouring part of the pharynx, that of the back of the tongue, and that of the upper part of the pharynx, near the orifices of the Eustachian tubes and behind the posterior nares, shows crypts and masses of lymphoid tissue (**post-nasal adenoids**) similar in structure to those of the tonsils.



FIG. 353.—SECTION OF A LYMPHOID NODULE OF THE INTESTINE. (Cadiat.)

a, middle of the nodule with the lymphoid tissue partly fallen away from the section; b, epithelium of the intestine; c, c, villi: the epithelium is broken away; d, crypt of Lieberkühn; e, f, muscularis mucosæ.

Lymphoid tissue occurs in various other parts of the body in addition to the lymph-glands and tonsils, although it may not, as in these structures, constitute the bulk of the organ. Thus it is found in many mucous membranes, such as those of the alimentary and the respiratory tracts, both in a diffuse form and also collected into nodular masses which are like the cortical nodules of a lymph-gland. In the intestine (fig. 353) such nodules constitute the so-called **solitary glands** and **Peyer's patches.** In the vermiform appendix the mucous membrane is thickly beset with similar nodules. The lymphatics of the mucous membrane form plexuses of sinus-like vessels which partly enclose the nodules (figs. 521, 522). In the spleen, as we have seen, a large amount of lymphoid tissue is found ensheathing the smaller arteries; this is expanded in places into the nodular masses known as Malpighian corpuscles. Lymphoid tissue also occurs in considerable amount in the serous membranes, especially in young animals; in the adult it is here largely replaced by adipose tissue.

DEVELOPMENT OF LYMPHOID TISSUE.

Lymph-glands are developed in connexion with plexuses of lymph-vessels, an accumulation of reticular tissue and lymph-cells taking place, according to Klein, either external to and around the lymphatics (*perilymphatic formation*); or within them, some of the lymphatics being dilated into a sinus, and the formation of lymphoid tissue occurring within the sinus (*endolymphatic formation*) (fig. 354, A and B). When the development of lymphoid tissue occurs outside the lymph-vessels this may form a considerable accumulation before the appearance of lymph-paths within the tissue. Blood-vessels are early developed amongst the lymphatic



FIG. 354.—DEVELOPING LYMPHOID NODULES FROM THE GUINEA-PIG. (Klein.)

A, perilymphatic nodule: *a*, lymphatic; *c*, its endothelium; *e*, lymph-corpuscles; *b*, accumulation of lymphoid tissue on one side of it; *d*, blood-capillaries within this.

B, endolymphatic nodule consisting of an enlarged lymphatic vessel, *d*, within which is a capillary network, *c*, *c*, an artery, *b*, and a vein, *a*; *e*, lymphoid tissue within the lymphatic. In both cases the cells of the reticulum of the lymphoid tissue are joined to the lymphatic endothelium, *f*.

plexuses, and by these, according to Gulland, the first lymph-corpuscles of the lymphoid tissue are brought to the gland.

The marginal sinus of a lymph-gland is produced by the fusion of a number of lymph-vessels which surround the commencing accumulation of lymphoid tissue, while in the situation of the future hilum other lymph-vessels grow into the glandular substance and form channels which subdivide it into cords and nodules (Kling). The branched cells of the lymph-path are derived from the lymphatic endothelium.

The axillary lymph-glands were found by Stiles to increase in number and size during lactation, diminishing again after lactation has ceased. In the developing tonsils Gulland occasionally found nests of epithelial cells detached from the surface epithelium, somewhat like those found permanently in the thymus.

THYMUS.

The thymus gland is an organ which in man is normally found in a fully developed condition only in the fœtus and child. It is composed of a number of lobules (fig. 355) varying in size, partly separated from one another by septa of connective tissue, along which the blood-vessels pass to and from the lobules. Each lobule shows plainly, when examined with a low power,

a distinction into an outer cortical and an inner medullary portion. The **cortex** of each lobule is imperfectly divided into nodules by the septa above mentioned. It is superficially similar in structure to the lymphoid tissue of the lymph-glands and tonsils, with which it also agrees in exhibiting numerous indications of mitotic cell-division, but without definite germ-centres. Besides lymphocyte-like cells (*thymocytes*) it contains peculiar granular cells, the nature of which is not clear. The **medulla** is more open in its texture with fewer corpuscles than the cortex. Its reticulum is formed by large, transparent, branched cells (fig. 356), massed together in places. Connective-tissue fibres are not wholly absent from it. Within the medulla,



FIG. 355.—SECTION OF PART OF LOBULE OF THYMUS OF CHILD. (E. Sharpey-Schafer.) × 60. Photograph.

c, cortex; *m*, medulla; *b*, *b*, blood-vessels in connective-tissue trabeculæ.

but never in the cortex, are found peculiar concentrically laminated bodies (*concentric corpuscles of Hassal*, figs. 357, 358). These are 'nests' of flattened epithelial cells arranged concentrically around one or more central cells; the last having often undergone a degenerative process. Sometimes the corpuscles are compound, two or three being grouped together and similarly enclosed by flattened cells.

Nucleated red blood-corpuscles (erythroblasts), similar to those seen in red marrow, have been described in the thymus. Occasionally cysts lined by ciliated epithelium are found (fig. 358, *c*). In some animals isolated cross-striated muscle-cells are seen in the medulla. Multi-nucleated giant-cells have also been described in it.

The lobules, especially the cortex, are abundantly supplied with capillary blood-vessels. In man the arteries penetrate to the junction of cortex and medulla, and then give off most of their capillaries radiating outwardly into the cortical substance; others pass inwards to supply the medulla.



FIG. 356.—SECTION OF MEDULLA OF THYMUS OF HUMAN FŒTUS, SHOWING BRANCHED CELLS FORMING A RETICULUM WITH A FEW SMALL THYMUS CELLS IN ITS MESHES. (Hammar.)

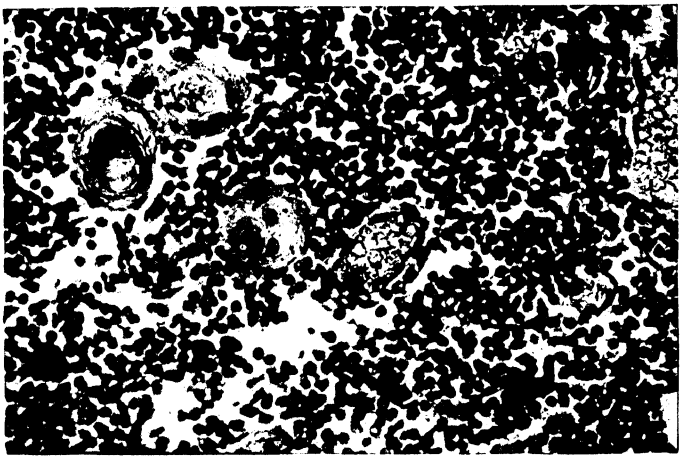

FIG. 357.—MEDULLA OF THYMUS OF A CHILD. (E. Sharpey-Schafer.) × 300. Photograph.

The small darkly stained cells are thymocytes. The section includes two concentric corpuscles and some blood-vessels full of corpuscles.

Veins pass away both from the surface of the lobules and to a less extent directly from the medulla. The mode of distribution of the lymphatics has not been definitely ascertained; none are seen within the lobules. Nevertheless, large lymph-vessels, containing many lymphocytes, issue from the interstitial connective tissue of the organ, but how they commence is not known.

The medullary substance is continuous throughout the gland, adjacent lobules being interconnected by their medulla.

In the human subject the thymus gland undergoes after childhood a process of regression, its lobules ceasing to grow and becoming surrounded and concealed by a quantity of adipose tissue which develops in the interstitial connective tissue of the gland. Eventually the glandular tissue

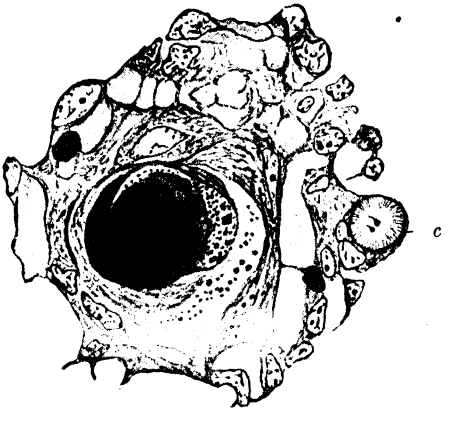

FIG. 358.—A CONCENTRIC CORPUSCLE OF THYMUS WITH PART OF THE ADJOINING RETICULUM. (Hammar.)

c, a small ciliated cyst.

atrophies, so that in advanced age very little remains. In exceptional cases this regressive or involution process does not occur. In these subjects there is usually also a more pronounced development of the lymphoid tissue of the body generally; the condition is denoted by the expression *status lymphaticus*.

DEVELOPMENT OF THYMUS.

The thymus first appears as cell-masses in the walls of the third and fourth branchial clefts. The thymus-rudiment is hence entodermal in origin. The outgrowths lose their connexion with the clefts and fuse in the mid-line to form a long tubular organ (fig. 359), which later becomes solid. Outgrowths occur at irregular intervals to form the lobules (fig. 360): these outgrowths appear as accumulations of lymphoid tissue.

The origin of the lymphocyte-like cells is debatable. In fishes they appear to be developed from the entoderm-cells and recent work suggests that this may be true in mammals. Hammar found that, like lymphocytes, they are easily destroyed by X-rays.

The concentric corpuscles are considered by most authorities to represent remains

of the epithelium of the primitive branchial outgrowths, although some have described them as being formed from the endothelium-cells of obliterated blood-vessels. In any case they appear to have an intimate connexion with the reticulum



FIG. 359.—DEVELOPING THYMUS, SHOWING THE ORGAN AS A BRANCHING EPITHELIAL TUBE. (Prenant, Bouin, and Maillard.)

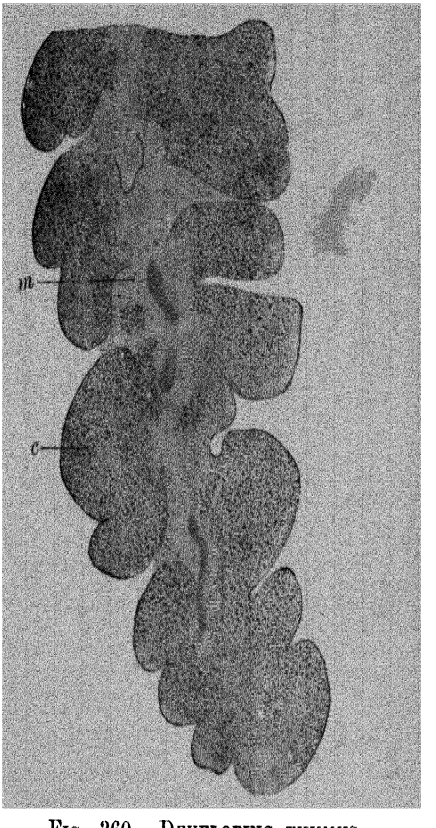

FIG. 360.—DEVELOPING THYMUS AT AN ADVANCED STAGE. (Prenant, Bouin, and Maillard.)

The lumen of the tube is obliterated; its cells are greatly thickened and the distinction of cortex (*c*) and medulla (*m*) is apparent.

of the medulla, which is undoubtedly of epithelial origin. They are said to increase in number with age. They occur in all vertebrates, but are most numerous in mammals.

LESSON XXIII.

ENDOCRINE GLANDS.

SUPRARENAL CAPSULES, THYROID, PARATHYROIDS, PITUITARY, AND PINEAL.

1. In a section of a fresh suprarenal capsule, placed in or even merely rinsed with a strong solution (8 per cent.) of potassium bichromate, notice the deep brown coloration of the medulla (action of chromic acid on adrenaline). On the other hand a section of fresh gland treated with nitrate of silver solution exhibits a darkly stained cortex and an unstained medulla. This is due to the presence in large amount of a special 'reducing substance' in the cells of the cortex.

After fixation with 2 per cent. potassium bichromate, followed by alcohol, thin sections may be stained with hæmatoxylin and eosin or by the iron-hæmatoxylin method. Notice the general arrangement and extent of the cortical and medullary parts of the organ. Make a general sketch under a low power. Afterwards sketch carefully under a high power a group of cells from each part of the organ.

2. Cramer's method. Suspend a thin slice of a fresh suprarenal in a wet gauze bag in a closed vessel containing 2 per cent. osmic acid solution, and keep for 1½ hours at 37° C. Then transfer to 50 per cent. alcohol, and after a few hours pass through absolute alcohol and xylol into paraffin. Mount sections directly in dammar without further staining.

This method is valuable for showing the adrenaline granules in the medulla. The lipoids of the cortex are also stained, but these can, if desired, be removed from sections by immersion for half an hour in turpentine. A mixture of potassium bichromate with osmic acid also stains the adrenaline granules, but the best results are obtained by the osmic vapour method.

3. Sections of the thyroid body fixed with susa or Zencker, stained with eosin and hæmatoxylin. Notice the vesicles lined with cubical epithelium and occupied by a 'colloid' substance. Sketch one or two vesicles. Measure several. The sections may include a parathyroid. If they do not, special sections of parathyroid must be prepared.

4. Sections (sagittal) through the pituitary body (cat) fixed with susa. Notice the (epithelial) anterior lobe separated by a cleft from the posterior lobe. The anterior part of the posterior lobe is also covered by an epithelial layer, amongst the cells of which colloid matter may be seen. This material can also be traced in the tissue of the posterior lobe as far as the infundibulum of the third ventricle. To show it clearly Flemming's solution (see Appendix) should be used as fixative.

The preparation should include, along with the pituitary body, the adjacent part of the base of the brain, in order to show the stalk and the pars tuberalis.

5. Sections (sagittal) through the pineal gland of a new-born child or kitten. The gland should be obtained from a brain hardened with 10 per cent. formol. (The pia mater must not have been removed, since the pineal gland is liable to be detached with it.) The sections may be stained with alcoholic eosin and methylene-blue.

THE SUPRARENAL CAPSULES (ADRENALS).

The suprarenal capsules and the other organs enumerated belong to the class of bodies known as internally secreting or endocrine glands.



FIG. 361.—A VERTICAL SECTION OF THE SUPRARENAL BODY OF A FŒTUS, TWICE THE NATURAL SIZE, SHOWING THE DISTINCTION BETWEEN THE MEDULLARY AND CORTICAL SUBSTANCE. (Allen Thomson.)

v, issuing vein; *r*, summit of kidney.

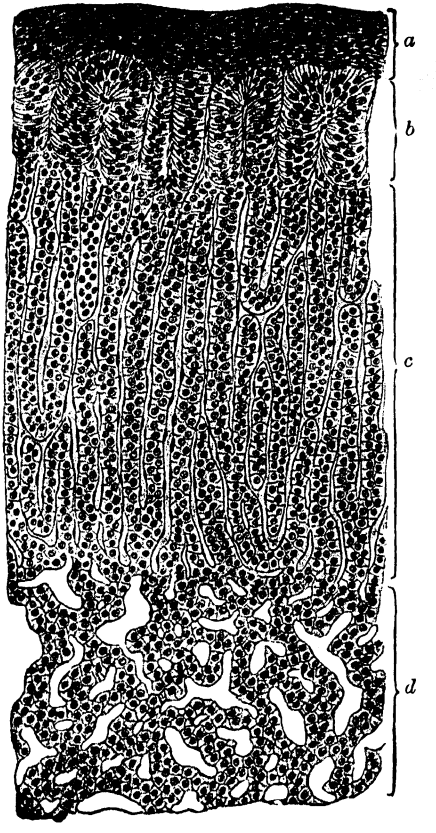

FIG. 362.—VERTICAL SECTION OF CORTEX OF SUPRARENAL OF DOG. (Böhm and v. Davidoff.) Magnified about 150 diameters.

a, capsule; *b*, zona glomerulosa; *c*, zona fasciculata; *d*, zona reticularis.

A section through the fresh suprarenal (fig. 361) shows a **cortex** which is striated vertically to the surface, of a yellowish colour, and a **medulla** which is soft and highly vascular, of a dark red colour. The whole organ is invested by a fibrous **capsule** (fig. 362, *a*), which sends septa inwards through the cortical substance, subdividing this for the most part into columnar groups of cells (*zona fasciculata*, *c*). Immediately beneath the capsule, however, the groups are more rounded, and the cells tend to assume a columnar form (*zona glomerulosa*, *b*), while next to the medulla they have a reticular arrangement (*zona reticularis*, *d*). The cells of the zona reticularis are pigmented in some animals.

The cells which form the cortical substance are mostly polyhedral in form; each contains a clear round nucleus, and numerous yellowish lipoid globules or granules, sometimes crystalline in appearance, in the cytoplasm.

The distribution of the lipoids in the cortex is unequal and changes with the functional conditions of the organ; the significance of the changes is not fully

understood. Exposure of animals to temperatures a little above that of the body may cause disappearance of lipoids from the cortex, while exposure to cold is associated with the whole cortex becoming charged with lipoid (W. Cramer). Deprivation of food increases the amount of lipoid in the cortex and also of adrenaline in the medulla.

No arteries and veins penetrate between the cells of the cortex; but the blood-vessels run in the fibrous septa between the cell-columns, which they surround with a capillary network. In the zona reticularis the capillaries widen out and occupy sinuses continuous with those of the medulla (fig. 362, *d*). Lymphatics also run in the septa above mentioned and communicate with

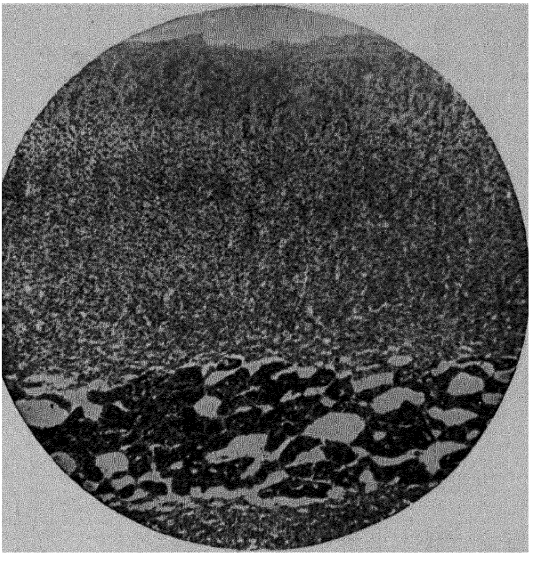

FIG. 363.—SECTION OF SUPRARENAL, SHOWING MARKED DISTINCTION BETWEEN CORTEX AND MEDULLA. (E. Sharpey-Schafer.) × 40. Photograph.

fine canaliculi between the cells of the cortex. Deposits of yellow granules may sometimes be seen in the connective tissue of the cortex.

The cells of the medulla (figs. 363, 364) are more irregularly disposed than those of the cortex. They are supported by a network of elastic fibres. They lie in very close relation to the large capillary blood-spaces (sinusoids) which pervade the medulla, and they pass their secretion (adrenaline) directly into the blood. Their protoplasm is granular, the granules stain darkly with osmic vapour and give the reactions of adrenaline.

The cells of the medulla are characterised by being stained brown by chromic acid and its salts, provided the organ is fresh (*chromaphil reaction*). A similar staining is found to occur in some of the cells of small glandular bodies (*chromaphil bodies, paraganglia*) (fig. 365) which occur irregularly at the back of the abdomen, being especially frequent near the lower end of the aorta. A certain number of such cells are also found in sympathetic ganglia (Kohn).

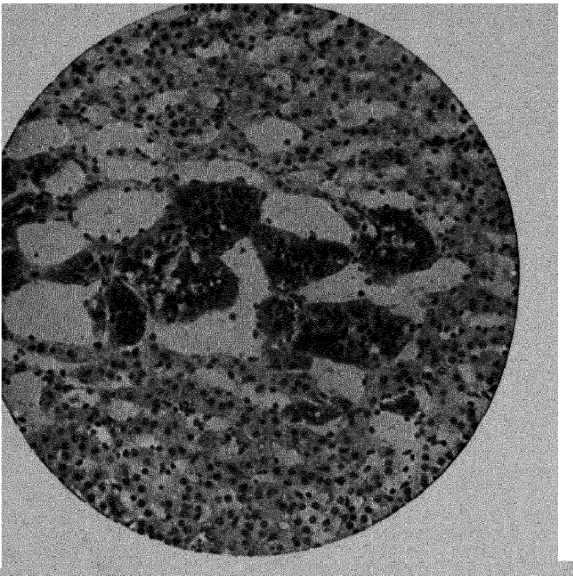

FIG. 364.—PART OF THE SAME SECTION AS THAT SHOWN IN FIG. 363, INCLUDING PORTIONS OF THE ZONA RETICULARIS AND MEDULLA. (E. Sharpey-Schafer.) × 150. Photograph.

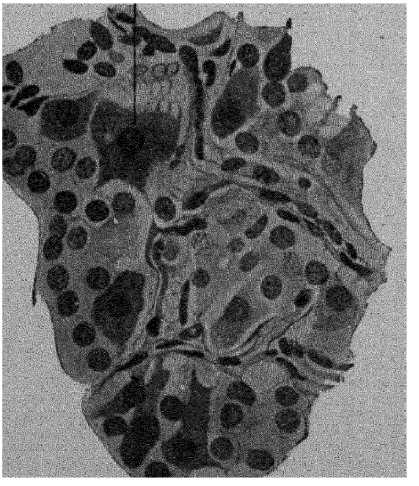

FIG. 365.—SECTION OF PARAGANGLION FROM A NEW-BORN CHILD. (Zuckerkandl.)

This chromaphil reaction depends on the presence of adrenaline in the cells where it occurs.

Stimulation of the sympathetic supply to the gland causes the adrenaline to be secreted into the blood, fresh adrenaline being formed in the cells of the medulla, especially in those near its centre. If the secretion is excessive the adrenaline may disappear from the peripheral part of the medulla (W. Cramer). This happens in thyroid-fed animals and sometimes in animals (mice) exposed to temperatures above that of their body (fig. 366). It occurs after administration of adrenaline itself hypodermically: such administration being equivalent to sympathetic

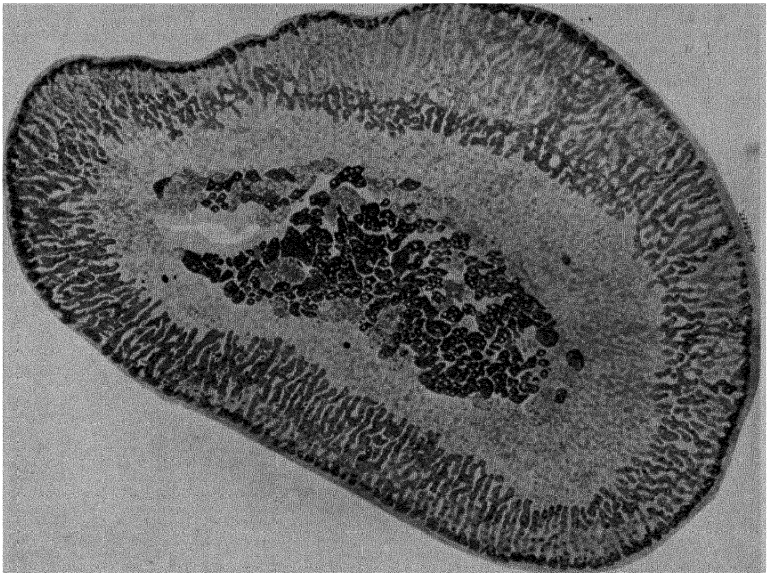

FIG. 366.—SUPRARENAL OF MOUSE WHICH HAD BEEN KEPT AT A TEMPERATURE OF 37° C. FOR TWO DAYS. (W. Cramer.) × 50.

The lipoids of the cortex have disappeared in patches and the adrenaline is absent from the peripheral part of the medulla.

stimulation. The adrenaline also disappears as the result of a fall in body temperature when accompanied by exercise (Vincent).

The existence of adrenaline has been noted occasionally in cells of the zona reticularis of the cortex.

The blood supply of the suprarenals is very abundant (fig. 367). The dark red colour of the medulla in the fresh gland is due to the blood contained in the large sinusoid spaces by which it is pervaded; the sinuses receive the blood after it has traversed the capillaries of the cortex, which receives numerous branches of the suprarenal artery entering the gland at its surface. A few arterioles pass straight to the medulla through the cortex. One large vein usually passes out at the hilum in the anterior surface of the gland. Investing the large issuing veins are longitudinal bundles of

plain muscular fibres; but the walls of the sinuses have no other tissue but the endothelium, and even this may be deficient. Numerous nerves, after traversing the cortical substance, are distributed throughout the medulla, where they form a close plexus around its cells. There are no nerve-cells within the gland.

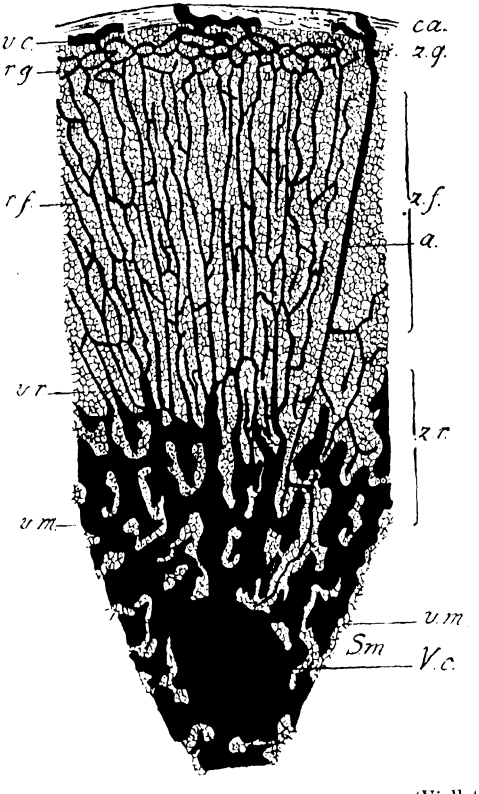

FIG. 367.—SECTION OF INJECTED SUPRARENAL. (Vialleton.)

ca, fibrous capsule of suprarenal; *z.g.*, zona glomerulosa of cortex; *z.f.*, zona fasciculata; *z.r.*, zona reticularis; *S.m*, suprarenal medulla; *v.c.*, vessels ramifying at surface; *r.g.*, *r.f.*, network of capillaries of zona glomerulosa and zona fasciculata; *v.r.*, sinusoids of zona reticularis; *v.m.*, sinusoids of medulla; *V.c.*, central vein of medulla; *a*, an artery passing straight through the cortex to the medulla.

DEVELOPMENT.

The medulla of the suprarenal is developed from cells which become detached from the rudiments of the sympathetic ganglia, and are therefore of neuro-ectodermal origin. The cortex is developed from the cœlomic epithelium and is hence derived from the mesoderm. The immigration of cells of sympathetic origin into the gland begins about the fourth week of fœtal life and is said to continue until the tenth year after birth.

In the human fœtus the suprarenals are unusually large. This is mainly owing to the development of a very vascular layer of the cortex next to the medulla known as the *boundary zone* (fig. 368, B). Its cells contain no lipoid granules. At birth it forms a considerable part of the organ, the cortex proper being relatively thin, but

by the end of the first year the boundary zone has disappeared and is replaced by the ordinary cortex. It is not present in the anencephalous fœtus.

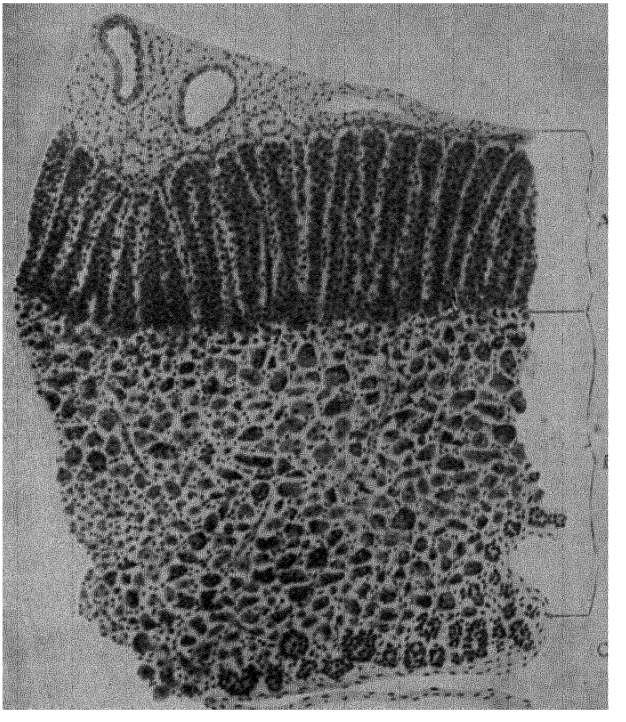

FIG. 368.—SECTION OF SUPRARENAL OF CHILD, 12 DAYS OLD. (Elliott and Armour.) Low-power view.

A, outer part of cortex; B, boundary zone; C, medulla. Just below is the central vein.

THE CAROTID GLANDS.

These are minute gland-like organs without ducts, lying at the bifurcation of the carotid artery. According to de Castro these organs are not endocrine but are sensory in function. They are perhaps concerned with the regulation of blood-pressure. The polyhedral cells, of which they are formed, are collected into spheroidal clumps or nodules, each supplied by a special arteriole and venule (fig. 369). The blood-capillaries have a sinusoid character (fig. 370). Among the cells of the carotid gland are some which stain dark brown with chromic acid like those of the medulla of the suprarenal capsules. This has been interpreted as evidence that the carotid gland belongs to the chromaphil system. But, apparently, this is not the case, for although the carotid gland cells are secretory in type they contain no adrenaline, nor are they innervated by the sympathetic system. Each cell has a well-marked Golgi apparatus,

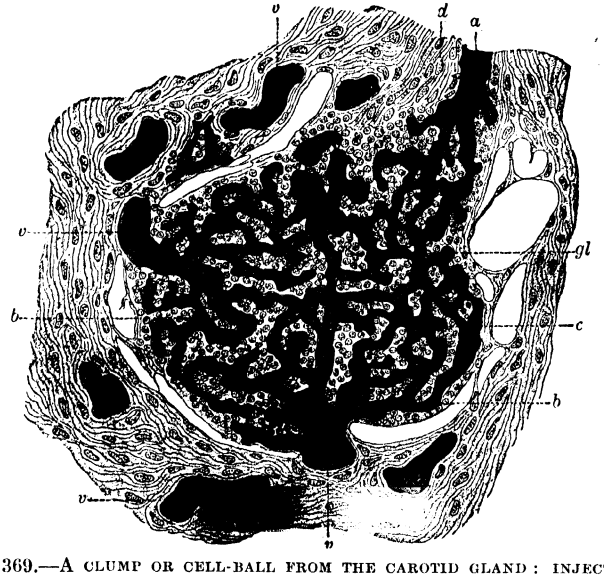

FIG. 369.—A CLUMP OR CELL-BALL FROM THE CAROTID GLAND: INJECTED. (Schaper.)

a, arteriole; *v*, venules; *c*, sinus-like capillary within nodule; *gl*, group of gland-cells; *b*, boundary of nodule surrounded by lymph-space; *d*, internodular connective tissue of gland.

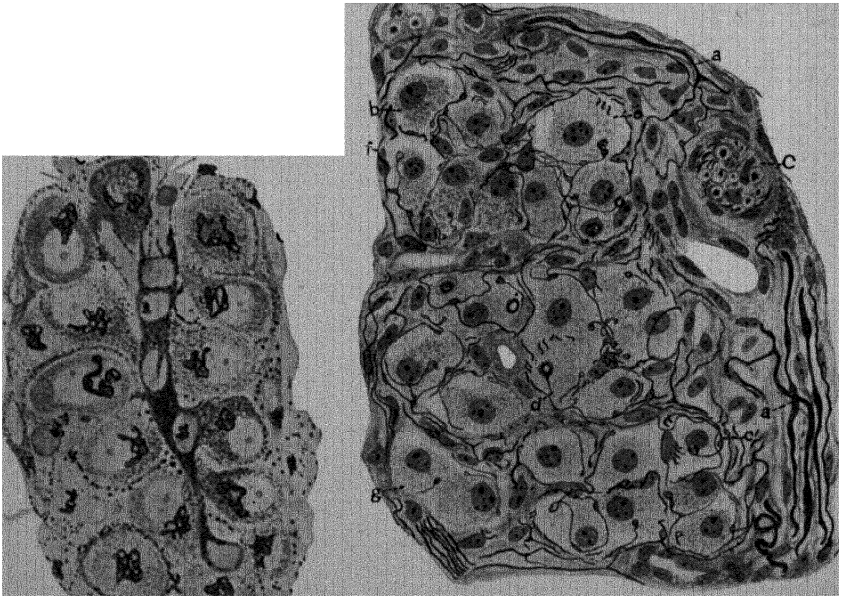

FIG. 370.—CELLS OF CAROTID GLAND CLOSELY SURROUNDING A SINUSOID BLOOD-VESSEL. (de Castro.)

Each cell shows a Golgi reticulum lying between the nucleus and the sinusoid.

FIG. 371.—A CLUMP OF CELLS OF THE CAROTID GLAND, SHOWING NERVE-FIBRES DISTRIBUTED TO THE CELLS. (de Castro.)

a, myelinate fibre dividing, as it approaches its termination, into two fine branches; *b*, cell closely surrounded by nerve-fibrils; *c*, section of a small nerve composed of several myelinate fibres; *f*, a nerve-fibril apparently ending within the cytoplasm of a cell; *g*, a nerve-fibril ending between two cells.

usually placed between the nucleus and the side of the cell in contact with a blood-vessel. The nerve-supply, which is very abundant, comes from the ninth cranial nerve, fine fibrils of which ramify between the cells over the blood-vessels (fig. 371). Section of the ninth nerve causes cytological changes in the gland-cells.

THE COCCYGEAL GLAND.

The coccygeal gland, which lies ventral to the apex of the coccyx in man, is a small median organ, about $2\frac{1}{2}$ mm. in diameter. It is composed of irregular

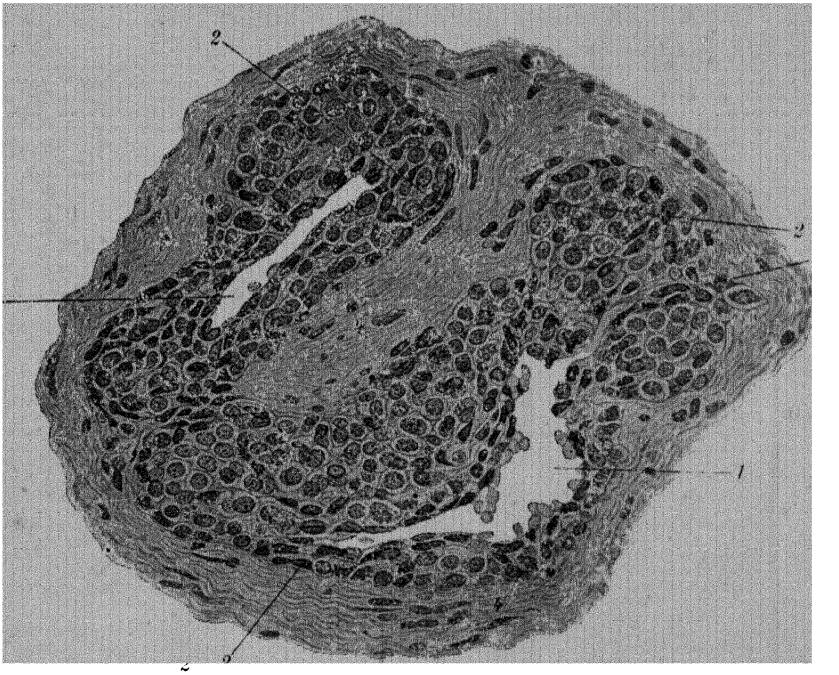

FIG. 372.—SECTION OF COCCYGEAL GLAND. (Walker.)
1, 1, blood-sinusoids; *2, 2*, gland-cells; *3*, connective tissue of the gland.

masses, more or less united, of epithelium-like cells, embedded in a vascular fibrous stroma. The vessels are sinusoids and are closely beset by the cells of the gland (fig. 372). It is stated that some of the cells are chromaphil and they may therefore secrete adrenaline. The gland receives numerous nerves, mostly derived from the sympathetic. Its mode of development and function are unknown.

THE THYROID BODY.

The thyroid body or gland consists of a framework of connective tissue enclosing numerous rounded or oval vesicles (fig. 373) lined with cubical epithelium-cells. Each epithelium-cell has many mitochondria and a

reticular apparatus of Golgi, which is generally situated in the part of the cytoplasm between the nucleus and the cavity of the vesicle. The vesicles are not provided with basement-membranes. The cavities of the vesicles are occupied by a peculiar viscous liquid (colloid). This is coagulated by alcohol and many other fixatives: it may then be stained with dyes. The colloid of the thyroid is unique in the fact that it contains organically combined iodine in the form of a substance (thyroxin) which can be isolated from the gland and also prepared synthetically. Colloid has been found in the lymphatics of the gland, and may sometimes be detected in the interstices of the connective tissue. The amount of colloid accumulated in the vesicles at any

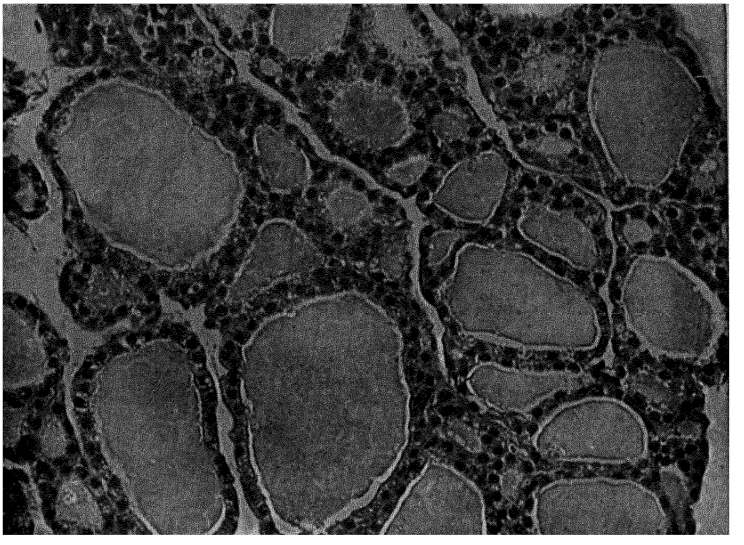

FIG. 373.—SECTION OF THYROID OF CAT. (E. Sharpey-Schafer.) × 400. Photograph.

The vesicles are occupied by colloid, which has partly shrunk away from the epithelium. Some of the vesicles are cut so as to show only small sectors.

one time varies considerably (figs. 373, 374, 375). The circumstances which influence its variations are not fully understood, although it may be stated that any excessive accumulation of colloid generally denotes inactivity on the part of the gland; actively secreting glands usually contain but little colloid, and this of a more fluid nature.

During activity, which may be induced by exposure to cold, both the mitochondria and the Golgi apparatus are greatly enlarged; the whole cell at the same time becomes swollen and the colloid which has accumulated in the vesicles during rest is discharged. Exposure of animals (mice) to heat produces the opposite effect, the mitochondria becoming almost invisible and the Golgi apparatus reduced in size (Cramer and Ludford).

According to the observations of Uhlenhuth in Amblystoma the colloid

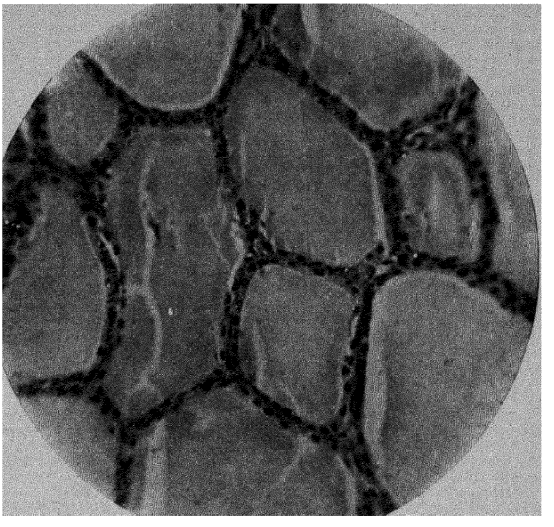

FIG. 374.—THYROID (RAT) IN INACTIVE CONDITION, WITH THE VESICLES DISTENDED WITH COAGULATED COLLOID AND THE CELLS FLATTENED. (Chalmers Watson.) × 250.

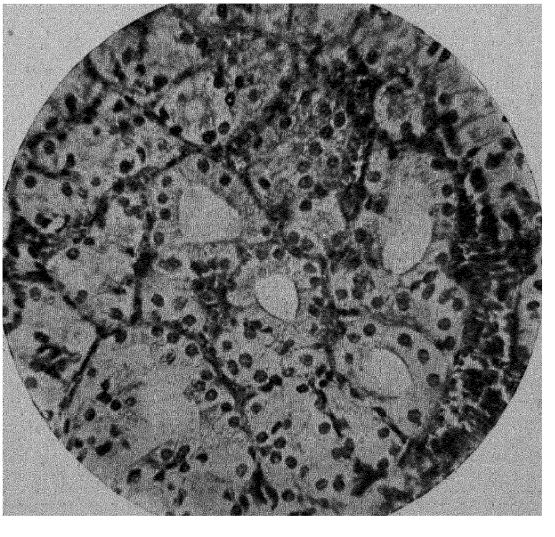

FIG. 375.—THYROID (RAT) IN ACTIVELY SECRETING CONDITION, WITH THE VESICLES SMALL AND CONTAINING LITTLE OR NO COAGULATED COLLOID AND THE EPITHELIUM-CELLS COLUMNAR OR CUBICAL. (Chalmers Watson.) × 250.

is formed within the cells as a clear colourless unstainable material, which is extruded into the vesicles and progressively modified so as to become

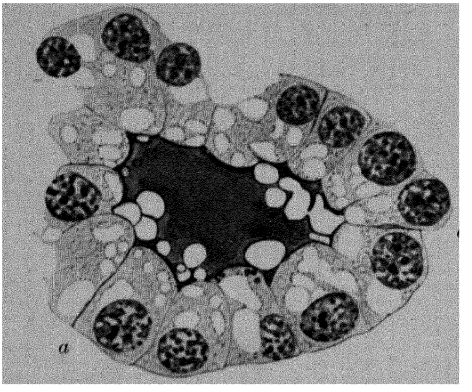

FIG. 376.—A THYROID VESICLE OF SALAMANDER, FIXED WHILST IN PROCESS OF SECRETION. (Uhlenhuth.) × 600.

The secretion is seen to be formed within the cells, in which it has the appearance of vacuoles, and to be passed from them into the cavity of the vesicle. Here it undergoes a chemical change into colloid matter, which is deeply stained by the method of preparation here employed. At *a*, *a*, colloid is seen passing away from the vesicle between its lining cells into the intervesicular tissue of the gland from which it is taken up into the lymph and blood. [The section was stained with polychrome methylene-blue and acid fuchsin, and in the actual specimen the colloid is not stained uniformly but is blue near the centre and red near the periphery.]

stainable with basic and subsequently with acid dyes (fig. 376). It is believed to pass from the vesicles into the lymph-spaces of the gland through clefts between the epithelium-cells. There is no evidence that it is secreted directly into the blood-vessels, although it may be taken up from the connective-tissue spaces into the veins. But most of it probably passes into the blood by way of the lymph.



FIG. 377.—VESSELS OF THYROID OF DOG; INJECTED. (E. Sharpey - Schafer.) Photographed under a low power.

The thyroid is one of the most vascular organs in the body, the blood-vessels being very numerous in proportion to the size of the gland. The capillaries form close plexuses round the vesicles (fig. 377), and even penetrate between the lining epithelium-cells.

There is frequently to be found in connexion with the thyroid, generally embedded in its substance, a small mass of tissue which resembles the thymus in structure, and, like it, contains concentric corpuscles. This *accessory thymus* is developed from the fourth pair of branchial clefts.

DEVELOPMENT.

The thyroid is formed like an ordinary gland, by a solid outgrowth of buccal epithelium, subsequently becoming hollowed to form a duct—ductus thyreoglossus.

Later, the now branched solid outgrowth grows down into the region of the neck, losing its connexion with the mouth. The vesicles of the future gland appear to be formed by accumulation of secretion from groups of cells separated by vascular tissue, each cell of the group pouring its colloid secretion into a common centre.

PARATHYROIDS.

In close proximity to or embedded in the substance of the thyroid are always to be found four very small glandular organs differing in structure

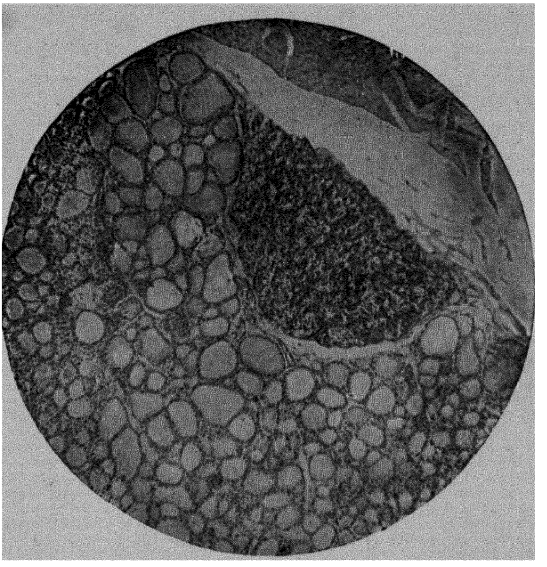

FIG. 378.—SECTION OF THYROID AND PARATHYROID OF RAT. (E. Sharpey-Schafer.) × 50.

The vesicles of the thyroid are filled with colloid. The parathyroid is partly embedded in the thyroid.

from the thyroid proper (fig. 378). These bodies are formed of masses or columns of epithelium-cells (fig. 379), some of which are much larger than the rest and are filled with oxyphil granules (Welsh). Numerous sinusoid blood-channels run between the columns and come into close relationship with the cells. The secretion formed by the cells is passed directly into the blood-vessels. Here and there a vesicle filled with a material resembling colloid may be seen. This colloid, when it occurs, is not, however, of the same chemical nature as that of the thyroid, it for contains no iodine.

Each parathyroid is enclosed within a capsule, which contains abundance of plain muscular tissue (Pépère).

DEVELOPMENT.

The parathyroids are developed, like the thymus (p. 267), as epithelial outgrowths from the third and fourth branchial clefts of the embryo : but they never normally

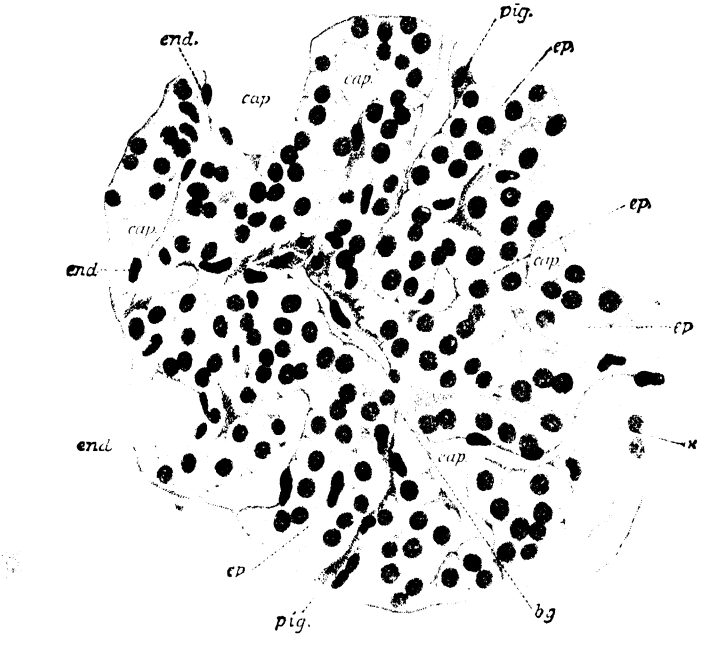

FIG. 379.—SECTION OF PARATHYROID. (Kohn.) Highly magnified.

ep., secreting epithelium-cells; *cap*, sinusoids; *end.*, endothelium of sinusoids, deficient in many places; *pig.*, endothelium-cells containing pigment (perhaps corresponding with the Kupffer cells of the liver); *x*, cell with two nuclei; *bg*, wall of sinusoid, surface view.

accumulate lymphocyte-like cells and are never tubular in character. They lose all connexion with the walls of the clefts from which they arise. Although they retain an epithelial structure, they nevertheless become highly vascularised, the so-called 'capillaries' being really sinusoids (fig. 379).

THE PITUITARY BODY.

The pituitary body (*hypophysis cerebri*) is in man about the size of the kernel of a cobnut; it lies in the sella turcica, and is connected with the third ventricle by the infundibulum. It consists of four parts: *pars anterior*, *pars intermedia*, *pars nervosa*, and *pars tuberalis*.

When the gland is removed from the body the pars tuberalis, which is adherent to the base of the brain and is only united with the rest of the gland by a narrow stalk, remains in position, so that the separated gland consists of pars anterior, pars intermedia, and pars nervosa only.

Between the pars anterior and pars intermedia there is in most animals a cleft-like space containing glairy fluid (in man this cleft disappears in the adult or is replaced by isolated cysts). It is easy to separate the gland at the cleft into two lobes, anterior and posterior; the pars anterior forms an *anterior lobe*, the pars intermedia and the pars nervosa together form a *posterior lobe*.

The **pars anterior** is the largest part of the organ (figs. 380, 381), and is

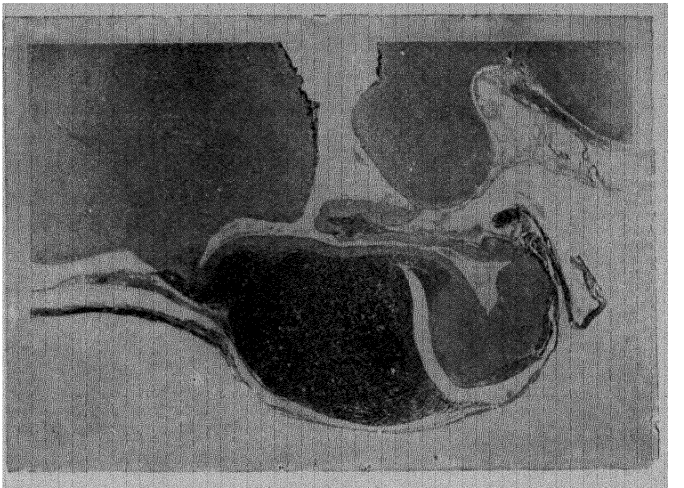

FIG. 380.—SAGITTAL SECTION THROUGH BASE OF BRAIN AND PITUITARY BODY OF CAT. (P. T. Herring.) Magnified. Photograph.

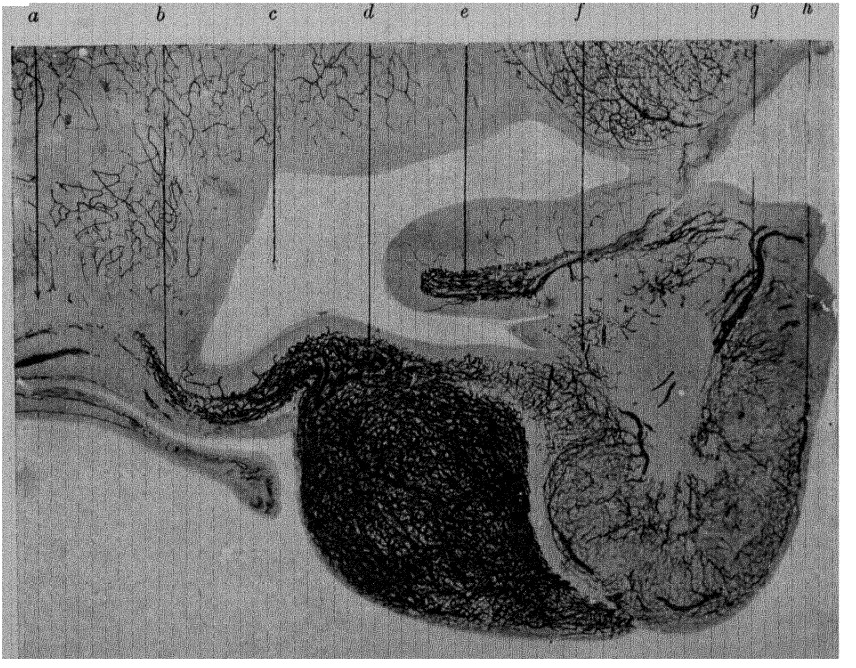

FIG. 381.—BASE OF BRAIN AND PITUITARY OF CAT: INJECTED. (P. T. Herring.) Magnified. Photograph.

a, chiasma; *b*, pars tuberalis; *c*, ventricle; *d*, anterior lobe; *e*, an extension of pars tuberalis; *f*, posterior lobe (pars intermedia and pars nervosa) separated from anterior lobe by cleft; *g*, artery entering posterior lobe; *h*, vein leaving it.

extremely vascular. Its capillaries have a sinusoid character; the cells (fig. 382) are set closely round them. In photographs of injected preparations the pars anterior appears almost black on account of the number of vessels it contains (fig. 381). This is also the case with the pars tuberalis.

The cells of the pars anterior are of two kinds, clear and granular. The clear cells are known as *chromaphobe cells*, the granular as *chromaphil cells*. The granular cells again are of two kinds, distinguishable from one another by the staining properties of their granules. In most, the granules are oxyphil and stain with eosin; these constitute about 37 per cent. of the cells in man (Rasmussen); the rest contain basiphil granules (11 per cent.). It is generally supposed that the chromaphil cells are much more numerous

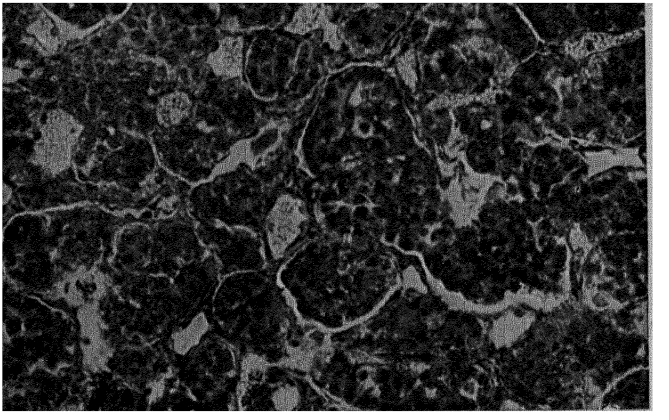

FIG. 382.—SECTION OF PARS ANTERIOR OF PITUITARY: HUMAN. (E. Sharpey-Schafer.) × 300. Photograph.

The blood-vessels are seen as light channels between the darkly stained cell-groups.

than the chromaphobe, but Rasmussen finds that this is not the case, the chromaphobes constituting about 52 per cent. of the total number. Occasionally the cells of the pars anterior are set round closed vesicles containing colloid, although this is more common in the pars intermedia. Such vesicles are conspicuous after thyroidectomy; also in myxœdema (Hale-White). They are probably temporary in nature, and not permanent structures like the thyroid vesicles.

The pars anterior is enlarged in tall subjects; greatly so in giants and in the affection known as acromegaly, the oxyphil cells especially being large and numerous. During pregnancy also the oxyphils are found to become increased in size and number.

The **pars intermedia** is less vascular than the pars anterior: when thin it has no blood-vessels at all. It extends in some animals (cat) around the pars nervosa. Its cells are clear, without obvious granules, and here and there are set round colloid-containing vesicles (fig. 383). At the margins of the cleft which separates them in the middle of the gland the junction

between pars intermedia and pars anterior is not sharply defined. On the other hand the pars intermedia is well marked off from the pars nervosa, except in certain places. At those places its cells are continued into the pars nervosa, either singly or in groups. They there appear to undergo a peculiar degeneration resulting in the formation of hyaline or granular 'colloid' masses, which retain their cell-nuclei for some time. These colloid bodies (termed from their discoverer 'Herring's bodies') can be followed through the tissue of the pars nervosa (fig. 384), and are eventually set free in the extension of the third ventricle which projects downwards and backwards into the pars nervosa. This 'colloid' is increased after thyroidectomy,



FIG. 383.—SECTION OF PITUITARY OF CAT PASSING THROUGH THE INTRAGLANDULAR CLEFT. (E. Sharpey-Schafer.) × 200. Preparation by M. Kojima.

a, pars anterior with numerous large sinus-like capillaries (seen as clear spaces); *b*, cleft; *c*, pars intermedia showing several vesicles; *d*, pars nervosa.

but it is not identical with that of the thyroid, for it contains no iodine (Simpson and Hunter). It apparently becomes dissolved in the cerebro-spinal fluid, and under favourable circumstances may be detected in that fluid by physiological tests.

The **pars nervosa,** in spite of its designation, contains in the adult no cells of distinctly nervous character, but is mainly formed of neuroglia elements and of ependyma fibres (fig. 384). It has far fewer blood-vessels than the pars anterior and pars tuberalis, but more than the pars intermedia. It receives a certain number of nerve-fibres which arise from large cells in the grey matter just behind the optic chiasma. Some of these fibres penetrate into the glandular substance of the pars intermedia and pars anterior, and have been traced to the cells of those parts as well as to their blood-vessels.

Within the pars nervosa the hyaline and granular masses of colloid are seen as above described on their way towards the infundibulum.

Baracque (1911) found, in new-born infants, tubulo-racemose glands in the posterior lobe, secreting colloid into the cleft. This is confirmed by D. Lewis and F. C. Lee (1927), who also note in various parts of the posterior lobe of man the occurrence of basiphil cells, like those seen in the pars anterior.

The **pars tuberalis** (Tilney) forms an extension of the epithelial part of the gland along the stalk which connects the pituitary body with the base of the

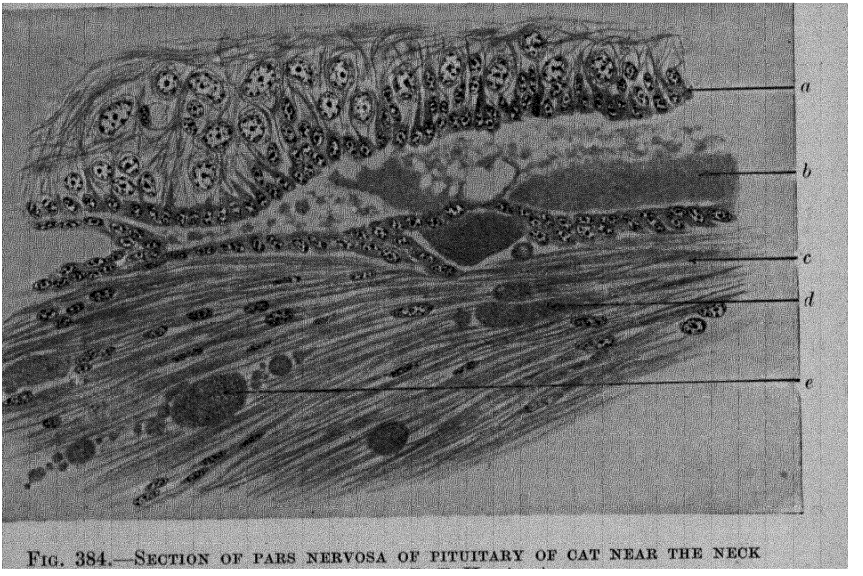

FIG. 384.—SECTION OF PARS NERVOSA OF PITUITARY OF CAT NEAR THE NECK OF THE GLAND. (P. T. Herring.)

a, ependyma cells lining an extension of the infundibulum into the gland; *b*, hyaline masses of colloid within this extension; *c*, ependyma fibres of pars nervosa; *d*, *e*, hyaline and granular colloid passing between these fibres towards the infundibulum.

brain and third ventricle. It ensheaths the stalk and spreads over the lower surface of the base of the brain, especially over the tuber cinereum—hence the name. In man it appears to consist of solid strands of epithelial cells, but in animals (ox, cat) it exhibits a vesicular structure (fig. 385); the vesicles being lined by cubical epithelium and occupied by a colloid-like material. The pars tuberalis is extraordinarily vascular in all animals, including man. Some observers have described colloid masses, like the 'Herring's bodies' of the pars nervosa, as passing from the pars tuberalis into the adjacent nervous tissue at the base of the brain.

This part of the pituitary is developed later than the rest of the gland, from which in some animals (*e.g.* frog) it is entirely separate. Although its functions are at present uncertain, it is evident from the peculiarity of its structure and its extreme vascularity that it must play an important part in the physiology of the organ.

DEVELOPMENT.

The *pars anterior* and *pars intermedia* are ectodermal in origin, being developed as a hollow protrusion of the buccal epithelium. The young gland at first consists of a number of tubules, lined by epithelium and united by connective tissue. The lumen of the tubules, however, becomes obliterated in the adult, the tubules being converted into solid cell-masses.

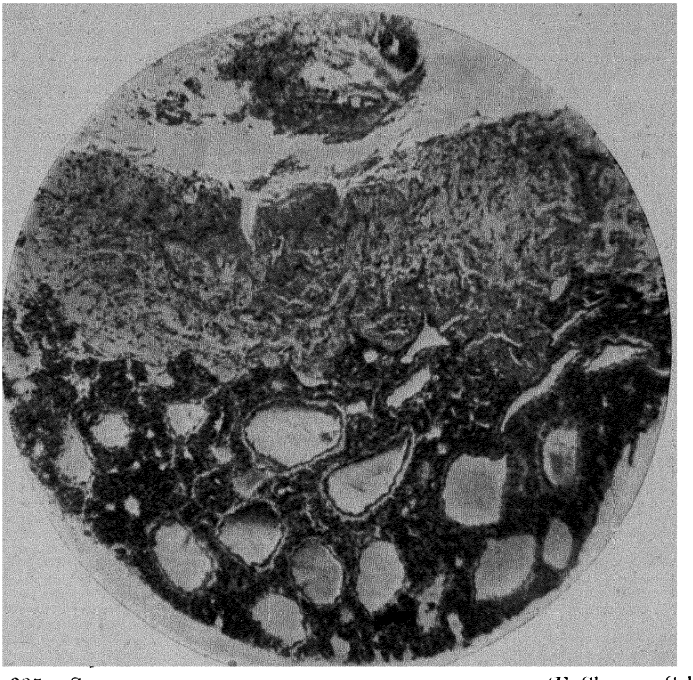

FIG. 385.—SECTION OF PARS TUBERALIS OF OX PITUITARY. (E. Sharpey-Schafer.) × 60. Photograph.

In the upper part of the figure is a section of the base of the third ventricle. The intimate attachment of the pars tuberalis to this is very apparent.

The *pars tuberalis* is formed as two vesicles growing out from the pars anterior: they eventually fuse. The pars tuberalis then spreads around the neural stalk of the hypophysis and beneath the tuber cinereum.

The *pars nervosa* is also ectodermal in origin, but is derived from the neural, not from the buccal, ectoderm. It arises as a downgrowth from the floor of the third ventricle. Contact of this rudiment with the pars anterior occurs at the fifth week of fœtal life in man.

PINEAL GLAND.

The pineal gland (*epiphysis cerebri*) appears in the adult as a small reddish body, rounded or conical, attached by a short stalk just above the entrance of the aqueduct of Sylvius into the third ventricle and lying in the groove between the anterior pair of corpora quadrigemina. It is less than half the size of the pituitary body.

The structure of the pineal is best studied in the young subject; as age

advances its distinctive cells become less numerous. A number of calcareous nodules are then found within it, known as *corpora amylacea* (brain sand):

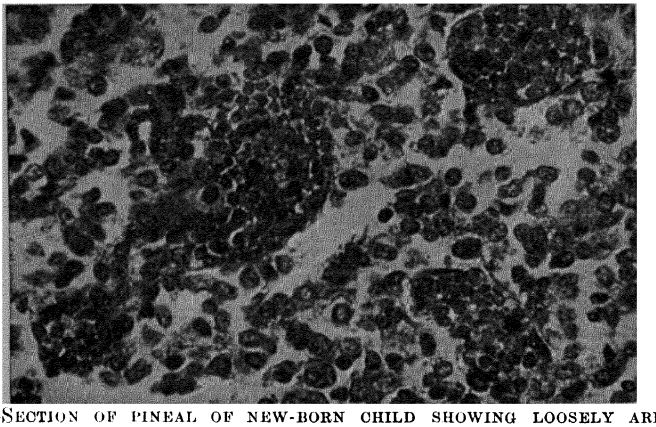

FIG. 386.—SECTION OF PINEAL OF NEW-BORN CHILD SHOWING LOOSELY ARRANGED CELL-TRABECULÆ WITH LARGE BLOOD-VESSELS BETWEEN THEM. (E. Sharpey-Schafer.) The vessels are full of blood-corpuscles which appear dark in the photograph. × 400.



FIG. 387.—CELLS OF PINEAL GLAND: HUMAN ADULT. (Del Rio-Hortega.) Highly magnified.

these are not special to the pineal but occur in the pia mater and in its extensions in various parts of the nervous system.

The young gland shows in section masses or trabeculæ of cells with large sinus-like blood-vessels between them (fig. 386): while neuroglia cells and fibres are present in abundance in the intertrabecular tissue and also between the gland-cells. Nerve-cells are almost or completely absent.

The gland-cells are of two kinds. The majority have oval nuclei and fine oxyphil granules; in the remainder the nuclei are spherical and the granules basiphil. Most of the cells have processes, many ending in knobs; some are attached to the blood-vessels. They exhibit a great variety of form (fig. 387). Cells with large oxyphil granules such as frequently occur in the pituitary are not seen in the pineal, nor are vesicles containing colloid observed.

The cells contain mitochondria, chiefly in the form of short rods. Some of the cells are pigmented.

After puberty the gland undergoes regressive changes. These consist chiefly in diminution in number of the cells and increase in amount of the supporting connective tissue and neuroglia-fibres, with greatly diminished vascularity.

DEVELOPMENT.

The pineal is developed as an outgrowth of the neural ectoderm of the roof of the third ventricle. In certain reptiles the evagination which produces it is closely associated with another evagination passing to the surface of the skull in the middle line and developing into an unpaired median eye. This has been termed the pineal eye, but is not homologous with the gland itself. In mammals there are many variations in the extent and general structure of the pineal evagination. An account of these, with numerous illustrations, has been given by Herring (see his paper in the *Quarterly Journal of Experimental Physiology*, 1927, vol. xvii).

LESSONS XXIV. AND XXV.

THE SKIN.

1. SECTIONS of skin from the palmar surface of a finger. The skin is hardened in saturated solution of picric acid or in 10 per cent. formol, followed by alcohol. The sections are made vertically to the surface, and should extend as far as the subcutaneous tissue. Notice the layers of the epidermis and their different behaviour to staining fluids. Notice also the papillæ projecting from the corium into the epidermis and look for tactile corpuscles within them. In very thin parts of the sections the fine intercellular channels in the deeper parts of the epithelium (see Lesson VII.) may be seen with a high power. The convoluted tubes of the sweat glands are visible here and there in the deeper parts of the corium, and in thick sections the corkscrew-like channels by which the sweat is conducted through the epidermis may also be observed. Make a sketch showing the general structure under a low power, and other sketches to exhibit the more important details under a high power. Measure the thickness of the epidermis and the height of the papillæ.

2. Sections of the skin of the scalp (*a*) vertical to the surface and parallel to the slope of the hair-follicles, and (*b*) parallel to the surface, and across the hair-follicles. Stain and mount in the usual way.

3. Examine the structure of hairs from different parts of the body, from different individuals, and, if possible, from different races. Compare with hairs of various domestic or other animals. The hairs may be mounted dry, the cover-glass being fixed by gummed paper with a hole cut in the centre.

4. Vertical sections of the nail and nail-bed. To cut such hard structures as the nail it is best, after fixing with picric acid or formol followed by 75 per cent. alcohol, to soak the tissue in strong gum arabic for a few days, then place it in an appropriate position upon a cork or upon the object-carrier of a microtome, and plunge the whole into 70 per cent. alcohol. This renders the gum hard, and enables sections to be cut of sufficient fineness. A plane iron should be used with the microtome (Cathcart's), since the hardness of the nail will turn the edge of a razor. To remove the gum the sections are placed in water for a few hours; they may then be stained and mounted. Notice the ridges (not papillæ) of the corium, projecting into the epidermis. Observe the distinction of the epidermis into Malpighian layer and nail proper.

5. Mount a section from a portion of skin in which the blood-vessels have been injected, and notice the distribution of the capillaries to the sweat glands, to the hair-follicles, and to the papillary surface of the corium. Observe that the epidermis is devoid of blood-vessels.

6. The cells composing the nails and hairs can be isolated by warming a small piece of nail or hair in strong sulphuric acid; after this treatment the cells are readily separated from one another by pressure upon the cover-glass.

7. Sections of mammary gland during lactation (cat). The gland may be fixed in susa or 10 per cent. formol and the sections stained with hæmatoxylin and eosin. To show the fat-globules within the cells, the gland should be fixed in 2 per cent. bichromate of potassium for ten days and a thin piece then transferred to Marchi's fluid (see Appendix) for a few days; after which sections are cut and mounted in dammar, with or without further staining with hæmatoxylin. Sections of mammary gland which is not secreting should also be studied.

The **skin** is composed of two parts, *epidermis* and *cutis vera* (*derma*) (figs. 388, 389).

The **epidermis,** or scarf skin, is a stratified epithelium (fig. 390). It is composed of a number of layers of cells, the deeper of which are soft and protoplasmic, and form the *rete mucosum* of Malpighi, while the superficial layers are hard and horny, this horny portion sometimes constituting the greater part of the thickness of the epidermis. The deepest cells of the *rete mucosum*, which are set on the surface of the cutis vera, are columnar in shape, those immediately above the basal layer are polyhedral. Many of the deeper cells show mitoses, an indication that the epidermis is regenerated from these cells. The deepest cells of the rete mucosum, especially in the darker parts of the skin, exhibit pigment granules. These are abundant in the darker races of mankind. Pigment may also be found

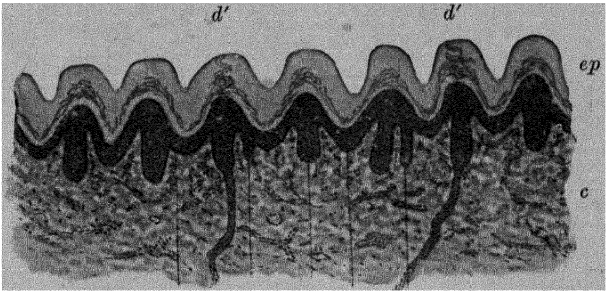

M d M'' M' M d M''

FIG. 388.—SECTION OF SKIN OF HEEL. (Blaschko.)

ep, epidermis, showing ridges cut across; *c*, cutis vera; *d*, *d*, ducts of sweat glands; *d'*, *d'*, their openings at the surface of the papillary ridge; *M*, Malpighian layer of epidermis thickened opposite the ridges, where it dips down into the cutis vera (at *M'*, *M''*), leaving papillary prominences of the cutis between.

in the branched cells which are often seen lying between the cells of the rete mucosum, and in similar cells in the cutis vera, especially where there is much pigment in the epidermis. Between all the cells of the rete mucosum there are fine intercellular clefts separating the cells from one another, but bridged across by fibres which pass from cell to cell (fig. 78), and also through the substance of the cells (fig. 79). The intercellular channels probably serve for the passage of lymph to maintain the nutrition of the cells.

The superficial layer of the rete mucosum is formed of somewhat flattened cells filled with granules or droplets of a material (*eleïdin*) staining deeply with carmine and hæmatoxylin. These cells form an irregular layer termed *stratum granulosum* (figs. 389, 390, 391, *c*). This is not sharply marked off from the rete mucosum next to it, for many of the cells of this show similar granules, although they fill the cells less completely. Superficial to the stratum granulosum is a layer in which the cell-outlines are indistinct and the cells contain flakes or larger droplets of a hyaline material (*kerato-hyalin*), staining less intensely than the granules in the last layer, and tending to run together (fig. 391, *b*). This layer has a clear appearance in section, and is known as the *stratum lucidum*. Immediately superficial to the stratum

lucidum is the *horny part* (*stratum corneum*) of the epidermis. It is composed of a number of layers of epithelium-cells, the nuclei of which are no longer

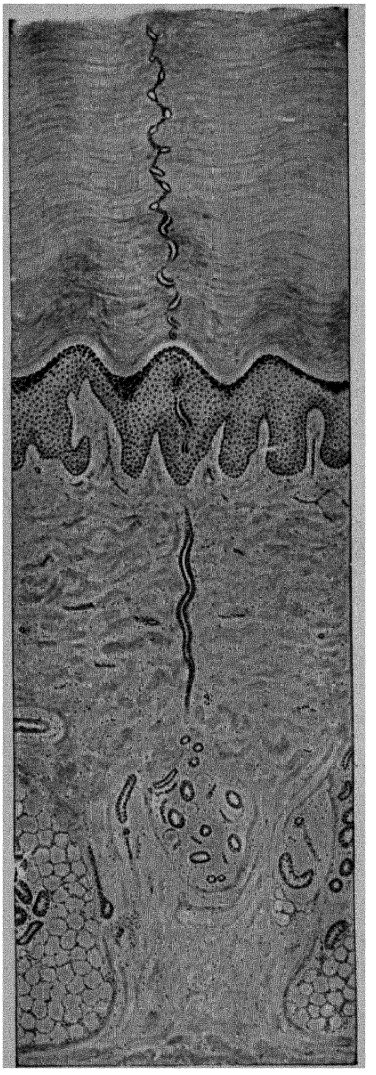

FIG. 389.—VERTICAL SECTION THROUGH THE SKIN OF THE SOLE OF THE FOOT. (E. Sharpey-Schafer.) × 25.

visible. These cells, near the surface, take the form of thin horny scales which eventually become detached. In certain parts which have a thick epidermis and are not covered with hair (*e.g.* the palms and soles), the superficial part of the epidermis is a layer mainly formed by a number of greatly swollen cells (fig. 394, *sw*), forming collectively what has been termed the *epitrichial layer*. In the embryo in the second and third months of

intrauterine life it covers the whole body, but is thrown off where hairs are developed (see p. 296).

The growth of the epidermis takes place by a multiplication of the cells of the deeper layers. The newly formed cells, as they grow, push towards the surface those previously formed, and in their progress the latter undergo a chemical transformation, their fibrillated protoplasm being converted into

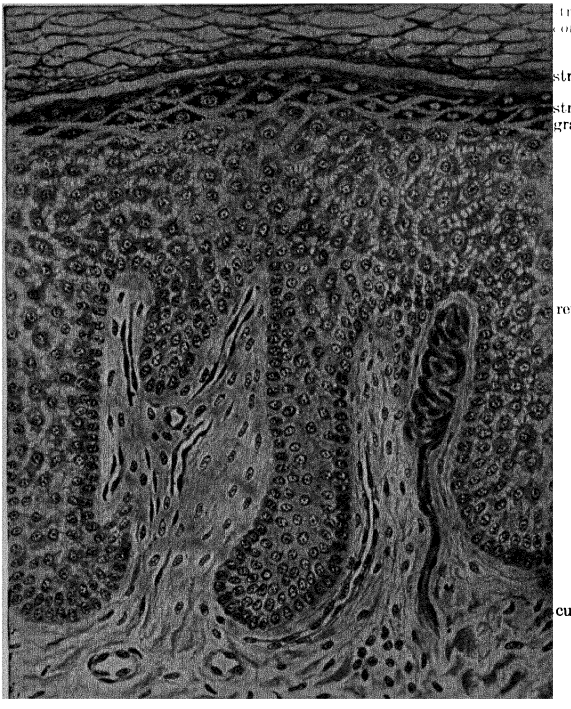

FIG. 390.—VERTICAL SECTION THROUGH THE SKIN OF THE PALMAR SIDE OF THE FINGER, SHOWING TWO OR THREE PAPILLÆ AND THE DEEPER LAYERS OF THE EPIDERMIS. (E. Sharpey-Schafer.) × 200.

One of the papillæ contains a tactile corpuscle; the others blood-vessels.

horny material: this change seems to occur just at and above the stratum granulosum (see fig. 391). The granules of elëidin occupying the cells of the stratum granulosum are chemically transformed into the *keratin* of the more superficial strata.

The **cutis vera** or **derma** is composed of dense connective tissue, which becomes more open and reticular in texture in its deeper part, where it merges into the subcutaneous tissue. It is thickest over the posterior aspect of the trunk, whereas the epidermis is thickest on the palms of the hands and soles of the feet. The superficial or vascular layer of the corium bears microscopic *papillæ*; these project into the epidermis, which is moulded over and attached to them; they contain abundant elastic fibres. Most of the

dermic papillæ have looped capillary vessels projecting into them from the network in the cutis vera, but some, especially those of the palmar surface of the hand and fingers, and the corresponding parts in the foot, contain tactile corpuscles, to which myelinate nerve-fibres pass (fig. 390).

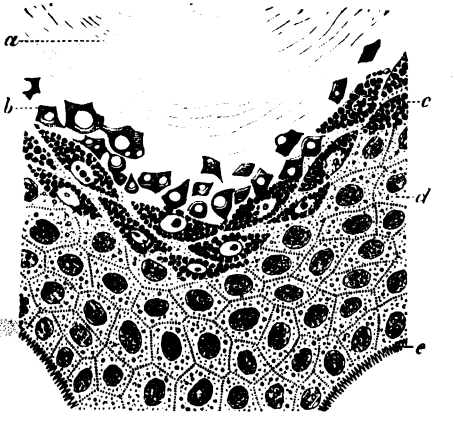

FIG. 391.—PORTION OF EPIDERMIS FROM A SECTION OF THE SKIN OF THE FINGER, COLOURED WITH PICROCARMINE. (Ranvier.)

a, stratum corneum; *b*, stratum lucidum with flakes of kerato-hyalin; *c*, stratum granulosum, the cells filled with drops of eleïdin; *d*, prickle-cells; *e*, dentate projections by which the deepest cells of the epidermis are fixed to the cutis vera.

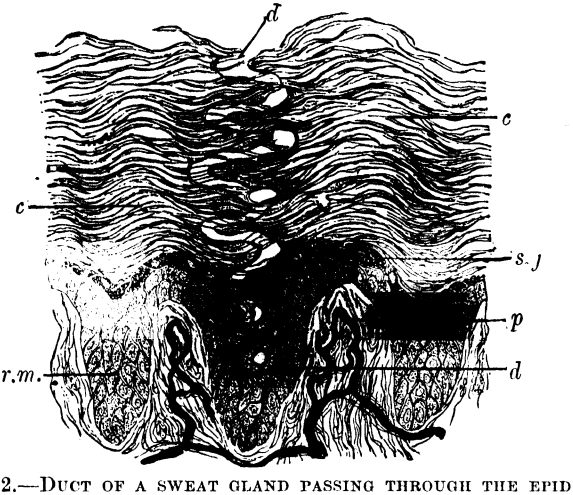

FIG. 392.—DUCT OF A SWEAT GLAND PASSING THROUGH THE EPIDERMIS. (Heitzmann.) Magnified 200 diameters.

p, papillæ with blood-vessels injected; *r.m.*, rete mucosum between the papillæ; *c*, *c*, stratum corneum; *s.g.*, stratum granulosum; *d*, *d*, sweat-channel through epidermis.

In some parts of the body (scrotum, penis, nipple and its areola) involuntary muscular tissue occurs in the deeper portion of the cutis vera; and, in addition, wherever hairs occur, small bundles of this tissue are attached to the hair-follicles (p. 307).

The blood-vessels of the skin are distributed almost entirely to the surface, where they form a close capillary network, sending up loops into the papillæ as already noted (figs. 392, 393). Special branches are also sent to the various appendages of the skin, viz. the sweat glands and hair-follicles, with their sebaceous glands and muscles. Numerous vessels pass to the adipose tissue which is usually present in the deeper parts of the cutis.



FIG. 393.—SECTION OF SKIN WITH BLOOD-VESSELS INJECTED. (v. Brunn.)

a, papillary layer of derma; *a'*, subpapillary plexus; *b*, reticular layer of derma; *b'*, subdermic plexus; *c*, vessels of panniculus adiposus.

No blood-vessels pass into the epidermis, but it receives nerves which ramify between the cells of the rete mucosum in the form of fine varicose fibrils (fig. 394). In some parts these are enlarged at their extremity and along their course into menisci lying between the deeper epidermis cells. Such terminations are seen in the skin over the pig's snout (fig. 285, p. 214) and in the root-sheaths of hairs (fig. 405). They also occur in the neighbourhood of the entrance of sweat-ducts into the epidermis (Ranvier).

The lymphatics originate near the surface in a network of vessels, placed a little deeper than the blood-capillary network. They receive branches from the papillæ, and pass into larger vessels, which are valved, and run in the deeper or reticular part of the corium. From these the lymph is carried away by still larger vessels, coursing in the subcutaneous tissue.

For the modes of ending of nerves in the skin, see Lesson XIX.

DEVELOPMENT OF THE SKIN.

The cutis vera is entirely formed from mesoderm, but the epidermis and the nails, hairs and cutaneous glands are all ectodermic in origin. The ectoderm is at first single-layered but differentiates into two layers during the first month of fœtal life. The inner becomes many-layered and develops into the future epidermis.

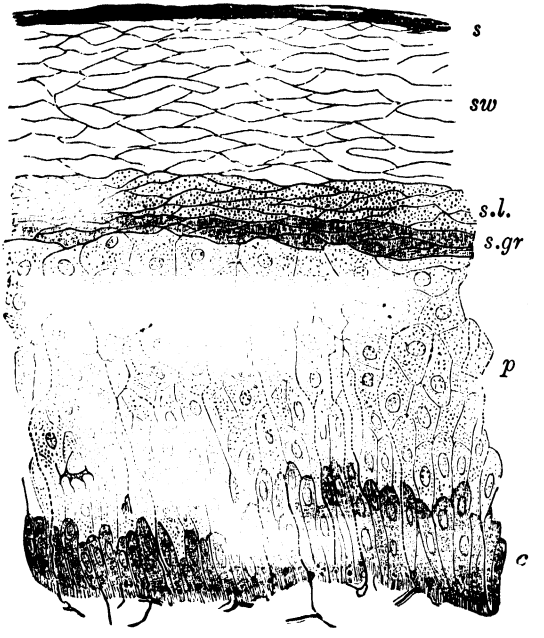

FIG. 394.—SECTION OF EPIDERMIS. (Ranvier.)

s, superficial horny scales; *sw*, swollen horny cells; *s.l.*, stratum lucidum; *p*, prickle-cells, several rows deep; *c*, elongated cells forming a single stratum near the corium; *s.gr*, stratum granulosum of Langerhans just below the stratum lucidum. Part of a plexus of nerve-fibres is seen in the superficial layer of the cutis vera. From this plexus fine varicose nerve-fibrils may be traced passing up between the epithelium-cells of the Malpighian layer.

The outer layer is known as the *epitrichium*. It also thickens and its cells become vesicular, persisting in this condition until the sixth month of intra-uterine life. Most of the cells are then shed and mingle with the secretion of the sebaceous glands. A waxy covering—the *vernix caseosa*—is thus formed. It covers the embryonic epidermis until birth and serves to protect it against infiltration by the amniotic fluid. But in some situations the epitrichium persists as a superficial layer which covers the epidermis.

The **appendages of the skin** are the *nails*, the *hairs*, the *sebaceous glands*, and the *sweat glands*. They are all developed as thickenings and downgrowths of the Malpighian layer of the epidermis.

THE NAILS.

The **nails** are thickenings of the deeper part of the stratum corneum developed over a specially modified portion of the skin (fig. 395), which is

known as the *matrix* or *bed of the nail*; the depression at the posterior part of the nail-bed from which the nail grows forward being known as the *nail groove*. The distal part of the nail projects beyond the rest as the *free border*; this is the thickest part of the nail, the thinnest being at the bottom of the



FIG. 395.—LONGITUDINAL SECTION THROUGH THE ROOT OF THE NAIL AND ITS MATRIX. (E. Sharpey-Schafer.) × 10.

a, root of nail; *b*, Malpighian layer of matrix; *c*, ridges in cutis of nail-bed; *d*, epitrichial layer of epidermis continuous with *e*, eponychium; *f*, bone (terminal phalanx) of finger.

nail groove. The substance of the nail is composed of clear horny cells, somewhat like the cells of the stratum lucidum of the rest of the epidermis, except that they are much more keratinised. Each contains the remains of a nucleus. The horny nail proper rests immediately upon a Malpighian layer or rete mucosum similar to that found in the epidermis generally, but destitute of a defined stratum granulosum. Nevertheless, the more superficial cells of the rete mucosum contain a large number of special granules; these appear to represent those of the stratum granulosum of the epidermis. The granules are, however, not composed of eleïden, but of a material (*onychogenic substance*, Ranvier) which stains brown instead of red with carmine; a similar material occurs in the cells which form the fibrous substance and cuticula of the hairs. The cutis of the nail-bed is beset with longitudinal ridges (fig. 396) instead of the papillæ which are present over the remainder of the skin; these ridges, like the rest of the superficial part of the cutis, are extremely vascular.

The nail-bed receives many nerve-fibres. The deeper of these end in Pacinian corpuscles, while others ramify in the ridges of the cutis, and some penetrate among the epithelium-cells of the Malpighian layer.

DEVELOPMENT.

The nails show in the fœtus at about the third month (fig. 397), a groove being formed at this time in the corium, and the nail-rudiment appearing in it as a development of onychogenic substance in some of the cells of the epithelium which lies

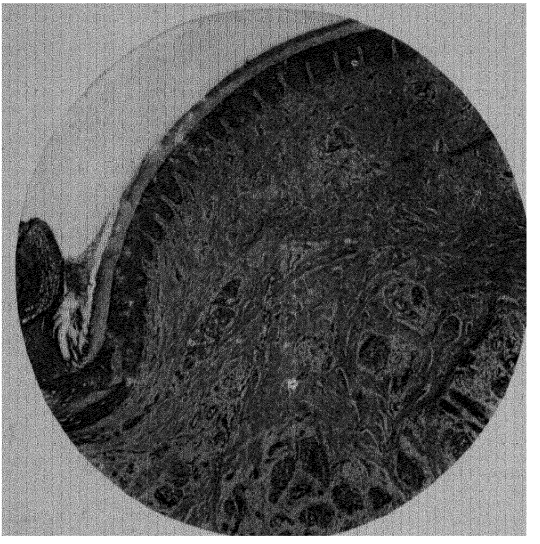

FIG. 396.—TRANSVERSE SECTION ACROSS NAIL TAKEN NEAR ONE EDGE. (E. Sharpey-Schafer.) × 50. Photograph.

The apparent papillæ are really sections of ridges or laminæ of the cutis vera projecting into the Malpighian layer of the nail.

over the bed (fig. 398). The nail becomes free in the sixth month, its end being at first thin; but as it grows forward over the bed it receives additions on its under

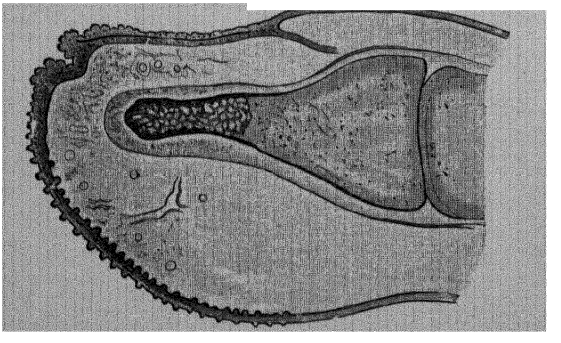

FIG. 397.—SECTION THROUGH END OF FINGER OF HUMAN EMBRYO AT THE TIME OF THE COMMENCEMENT OF FORMATION OF THE NAIL. (Kölliker.)

Notice the ossification of the terminal phalanx beginning at the tip of the cartilage. In the thickened epidermis over this the commencing nail is seen as a dark line.

surface, so that after a time the distal end becomes thicker. The epitrichial layer of the cuticle which originally covered the developing nail becomes detached after

the fifth month; all that represents it afterwards being the narrow border of cuticle (*ep*

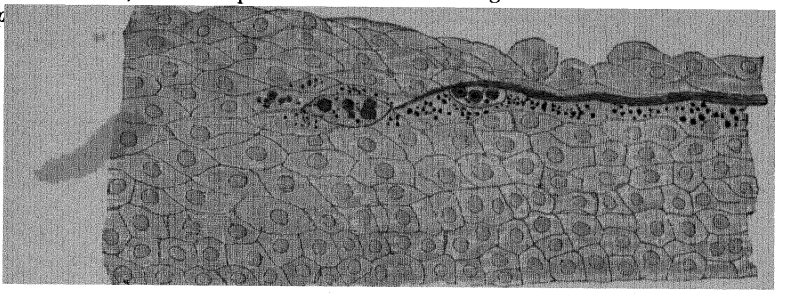

FIG. 398.—FIRST APPEARANCE OF NAIL SUBSTANCE IN THE FORM OF GRANULES OF ONYCHOGENIC MATERIAL IN SOME OF THE CELLS COVERING THE NAIL-BED. (Kölliker.)

HAIRS.

The **hairs** are growths of the epidermis, developed in deep pits—the *hair-follicles*—which extend downwards into the thickness of the cutis vera, and even into the subcutaneous tissue (fig. 399). The hair grows from the bottom of the follicle, the part which lies within the follicle being known as the *root*.

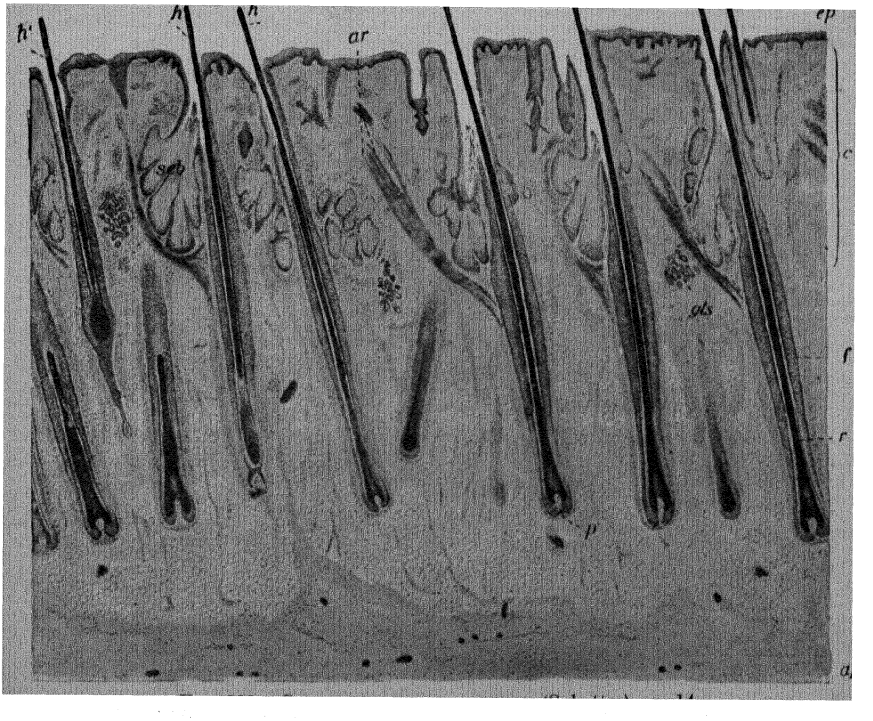

FIG. 399.—SECTION OF HUMAN SCALP. (Sobotta.) × 14.

h, *h*, ordinary or bulb-hairs; *h'*, club-hair; *ar*, arrector pili muscle; *f*, hair-follicle; *r*, root of hair; *p*, papilla; *ep*, epidermis; *c*, cutis vera; *ap*, aponeurosis below subcutaneous tissue; *gls*, sweat glands; *seb*, sebaceous glands.

The substance of a hair is mainly composed of a pigmented, horny, *fibrous material* (fig. 400, *f*), which can be separated by the action of sulphuric acid into long tapering fibrillated cells, the nuclei of which are still visible. The fibrous substance of the hair is covered by a layer of delicate imbricated scales, termed the *hair-cuticle* (*c*). In many hairs, but not in all, the centre is occupied by an axial substance (*medulla*, *m*), formed of angular cells which contain granules of elëidin, and frequently have a dark appearance from the presence of minute air-bubbles. The latter may also occur in interstices in the fibrous substance. When air is present, the hair looks dark by transmitted, white by reflected light; but when a dark appearance is due to pigment, the hair looks dark by both transmitted and reflected light.

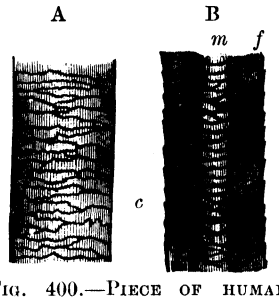

FIG. 400.—PIECE OF HUMAN HAIR. (E. Sharpey-Schafer.) Magnified.

A, seen from the surface; B, in optical section; *c*, cuticle; *f*, fibrous substance; *m*, medulla, the air having been expelled by Canada balsam.

The *root* has the same structure as the body of the hair, except at its deep extremity, which is enlarged to form the hair-bulb; this enlargement is composed mainly of soft growing cells, and fits over a vascular *papilla*, which projects up into the bottom of the follicle.

The lanugo hairs and the hairs which immediately succeed them (primary hairs) have no medulla. Some hairs which are found throughout life are also destitute of medulla. These are termed 'non-medullary' or 'lanugo' hairs.

Structure of hair-follicle (figs. 401 to 403). The follicle, like the skin itself, of which it is a recess, is composed of two parts: one epithelial, the other connective tissue. The epithelial or epidermic part of the follicle closely invests the hair-root, and is often dragged out with it; hence it is known as the *root-sheath*. It consists of an outer layer of soft columnar and polyhedral cells, like the Malpighian layer of the epidermis, but without stratum granulosum —the *outer root-sheath*; and of an inner, thinner, horny stratum next to the hair—the *inner root-sheath*. The inner root-sheath itself consists of three layers, the outermost being composed of horny, fibrillated, oblong cells the nuclei of which are obscure (*Henle's layer*), the next of polyhedral nucleated cells containing elëidin (*Huxley's layer*), and the third—the *cuticle of the root-sheath*—a layer of downwardly imbricated scales, which fit over the upwardly imbricated scales of the hair itself. In the more superficial part of the hair-follicle the layers of Huxley and Henle are indistinguishable, the cells of both being clear and keratinised; lower down where distinguishable they show a tendency to dovetail into one another. At the bottom of the follicle no differentiation into layers can be made out in the root-sheath, which is here formed by a uniform mass of soft cells capping and enveloping the papilla.

In the greater extent of the follicle the outer root-sheath is several layers thick, but as the bottom of the follicle is approached it becomes thinner, and is finally reduced to a single stratum of cells which, in the papillary part, becomes flattened out into a very thin layer (fig. 401, I).

The connective tissue or dermic part of the hair-follicle is composed internally of a *vascular layer*, which is separated from the root-sheath by a basement-membrane termed the *hyaline layer* of the follicle. The vascular layer corresponds to the superficial layer of the cutis vera. Its fibres and cells have a regular circular arrangement around the follicle, the cells being

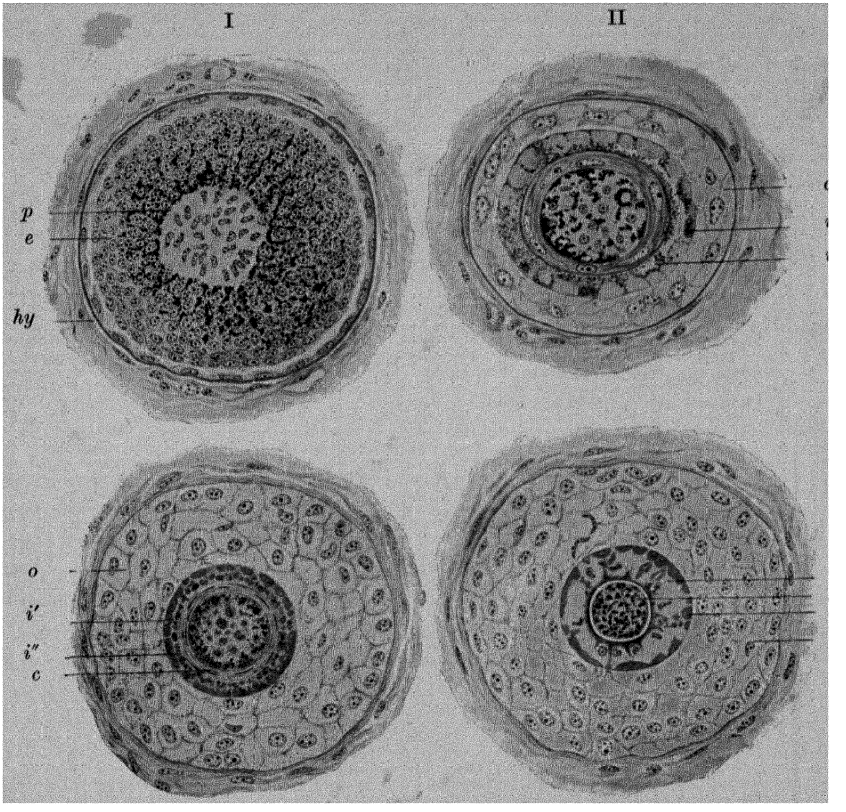

FIG. 401.—SECTIONS ACROSS HAIR-FOLLICLES FROM THE SCALP OF AN INFANT. (E. Sharpey-Schafer.)

I. Through papilla. II. Just above papilla. III. About middle of follicle. IV. Near orifice of follicle. In I :—*p*, papilla; *e*, epithelium surrounding papilla, with pigment in cells; *hy*, hyaline layer of dermic coat with thin outer root-sheath just within it. In II., III., IV. :—*o*, outer root-sheath; *i'*, layer of Henle, and *i''*, layer of Huxley of the inner root-sheath; *c*, cuticle of root-sheath; *h*, hair.

flattened against the hyaline layer. Externally the dermic coat of the follicle has a more open texture, corresponding to the deeper part of the cutis, and contains the larger branches of the arteries and veins. In the large tactile hairs (whiskers) of animals the veins near the bottom of the follicle are dilated into sinuses, forming a kind of erectile structure.

The hair-follicle receives nerve-fibres which pass into the papilla, and others which enter the root-sheath. These are derived from the nerves of

the corium and form ring-like arborisations in the upper part of the hair-follicle; while below the rings there is usually a sheaf of vertical palisade-like endings (fig. 404). The terminations between the cells of the outer

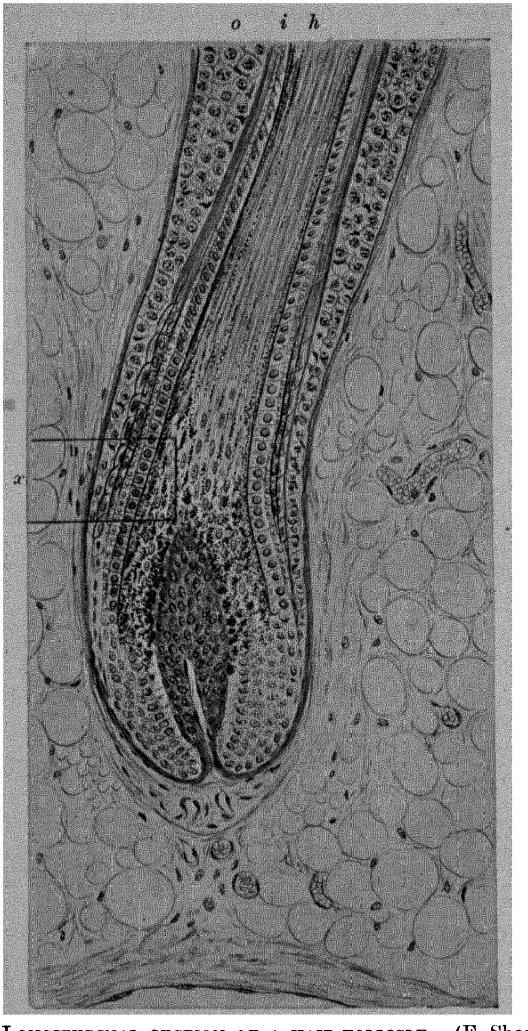

FIG. 402.—LONGITUDINAL SECTION OF A HAIR-FOLLICLE. (E. Sharpey-Schafer.) × 200.

o, outer; *i*, inner root-sheath; *h*, hair; *x*, part shown magnified in fig. 403. The follicle is embedded in the panniculus adiposus.

root-sheath may take the form of tactile disks (fig. 405). Nerves are especially well developed in connexion with the whiskers of animals.

The hair grows from the bottom of the follicle by multiplication of the soft cells which cover the papilla, these cells becoming elongated and pigmented to form the fibres of the fibrous substance, and otherwise modified

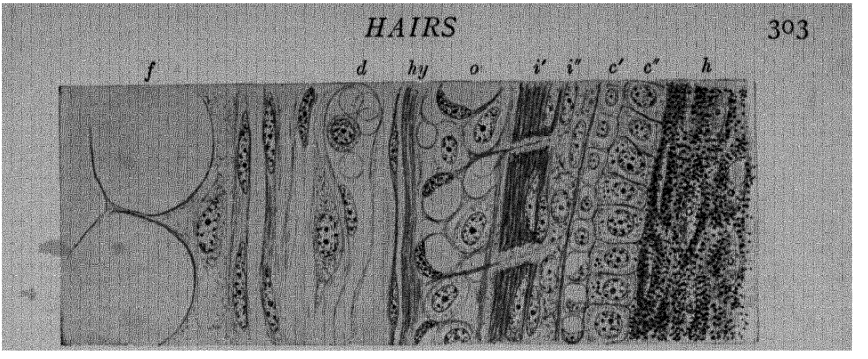

FIG. 403.—A SMALL PORTION OF THE SECTION SHOWN IN FIG. 402 ENLARGED TO EXHIBIT THE STRUCTURE OF THE SEVERAL LAYERS. (E. Sharpey-Schafer.)

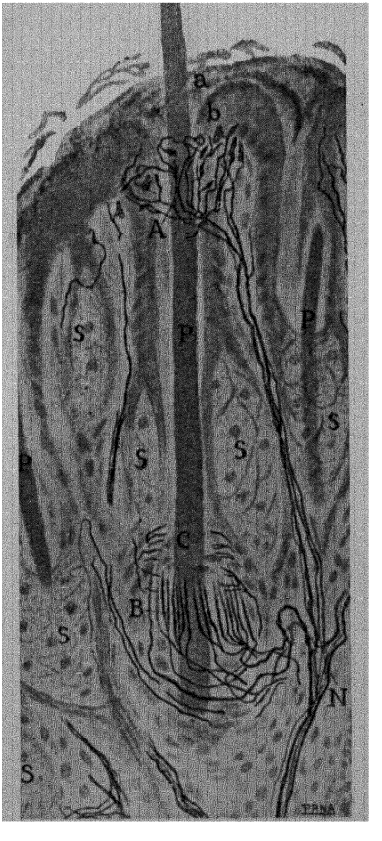

FIG. 404.—NERVES OF HAIR-FOLLICLE AND ADJACENT CUTANEOUS STRUCTURES: MOUSE. (J. F. Tello.)

N, branch of nerve sending fibres to terminate around the mouth of the follicle at A, and others (at B and C) to form palisade-like and annular endings around the lower part of the follicle; a, horny layer of epidermis; b, Malpighian layer; S, S, sebaceous glands; P, P, roots of hairs.

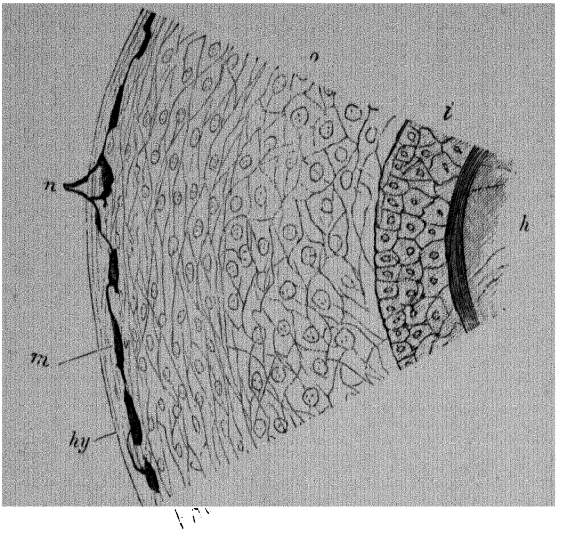

FIG. 405.—NERVE ENDING IN OUTER ROOT-SHEATH OF TACTILE HAIR OF RABBIT. (Ranvier.)

n, nerve-fibre; *m*, tactile disk; *o*, outer root-sheath; *i*, inner root-sheath; *h*, hair; *hy*, hyaline membrane.

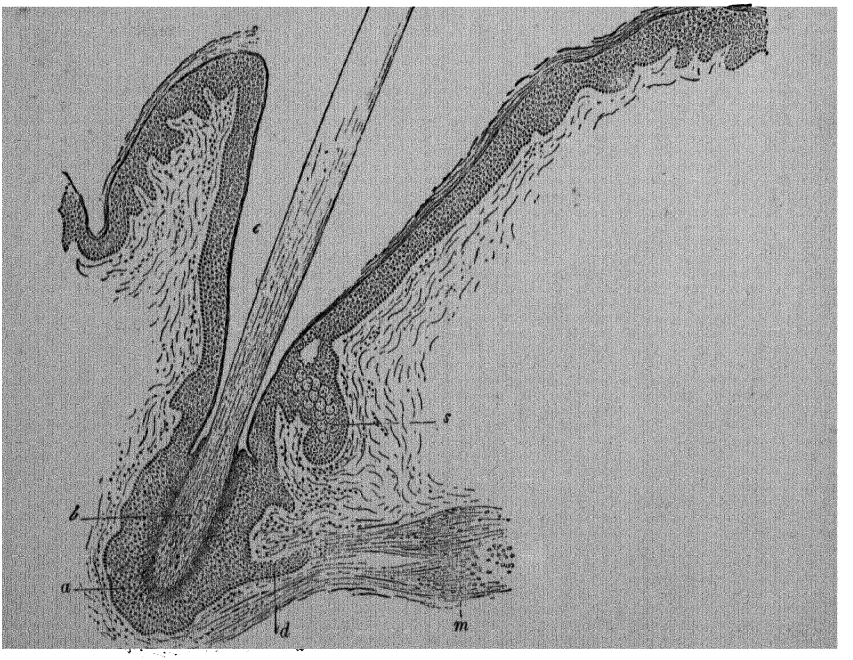

FIG. 406.—SECTION THROUGH FOLLICLE OF A CLUB-HAIR. (Ranvier.)

a, epithelium at bottom of follicle (which has no papilla); *b*, bulbous portion of hair; *c*, neck of hair-follicle somewhat opened in preparing the section; *s*, sebaceous gland; *d*, epithelial projection at attachment of arrector pili; *m*, arrector pili.

to produce the medulla (when present) and cuticle of the hair and the several layers of the root-sheath. The cells which form the medulla of the hair and the inner root-sheath are filled with granules of eleïdin, but those which form the fibrous substance and cuticula of the hair have granules which stain brown with carmine, and appear similar to the granules in the corresponding cells of the nail-matrix (Ranvier) (see p. 297).

Besides the hairs which have been described, and which are provided with a vascular papilla, from the cells covering which the hair and its inner root-sheath grow (*growing* or *bulb-hairs, papillated hairs*), there are other hairs unprovided with a papilla and the follicle of which ceases at the level of attachment of the arrector pili muscle (*non-growing* or *club-hairs, non-papillated hairs*, figs. 399, 406). These are hairs which have become detached from their papilla and have ceased to grow; they are more easily pulled out than the growing hairs, and after a time tend to fall out spontaneously. In their follicles the whole of the lower part of the hair, including the original papilla and the soft growing cells which cover it, may entirely disappear, the hair being now attached at its sides and below to the root-sheath (fig. 406). A hair which has thus ceased to grow is eventually lost, but its place is presently supplied by a new hair, which becomes developed in a downgrowth from the old follicle, a new papilla being formed at the extremity of the downgrowth (figs. 407, 408). If not previously detached, the old hair drops out from the follicle as the new one grows up to replace it.

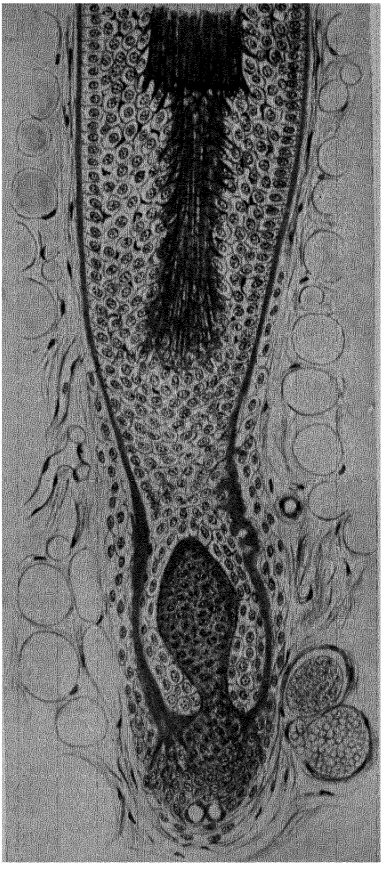

FIG. 407. — LONGITUDINAL SECTION THROUGH THE FOLLICLE OF A HAIR WHICH HAS CEASED TO GROW AND THE ROOT OF WHICH IS UNDERGOING ABSORPTION. (E. Sharpey-Schafer.) × 200.

The detachment of the non-papillated hairs is preceded by an absorption of the root of the hair and of the investing inner root-sheath. This absorption appears to be effected by the cells of the outer sheath, which multiply at the expense of the keratinised parts of the hair-root and undermine its attachment to the follicle (fig. 407). The root of such a hair when pulled out is of less diameter than the shaft.

Hairs grow at the rate of about half an inch a month. When a hair is pulled out, the new hair is not apparent at the surface for some weeks after. During this period active karyokinesis occurs among the cells at the bottom of the follicle, some of which gradually arrange themselves to produce the new hair.

Hairs are found all over the body except on the palms of the hands and the soles of the feet (including the fingers and toes), the dorsal surface of the distal phalanges of the fingers and toes, the glans penis and some other parts of the external sex-organs. They usually slant. In the negroid races the hair-follicles are even considerably curved and the hairs are oval or flattened in section. In

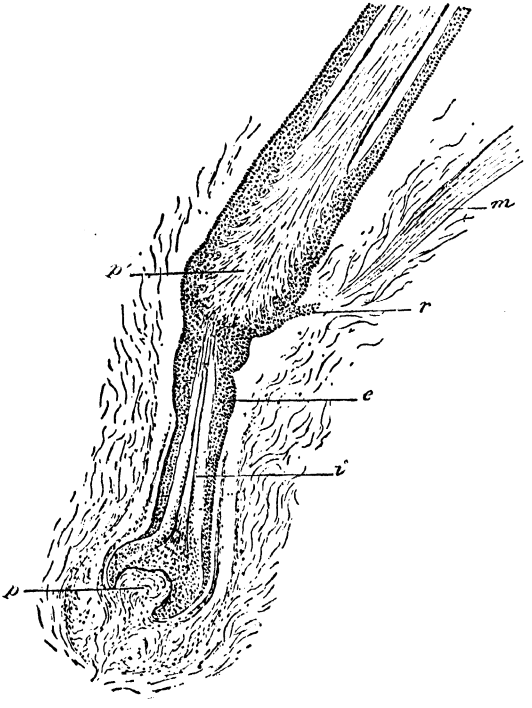

FIG. 408.—FORMATION OF A NEW HAIR IN A DOWNGROWTH FROM A FOLLICLE IN WHICH THE OLD HAIR IS BECOMING SHED. (Ranvier.)

p, papilla of new hair; *i*, *e*, its inner and outer root-sheaths; *p'*, root of old hair; *r*, epithelial projection at attachment of arrector pili (*m*).

other races differences also occur both in their shape in section and in size; the straight-haired races usually have the thickest hairs. On the scalp the hairs are set in groups, as is seen in a horizontal section; they are most numerous here (200 to 300 per square centimeter).

On the side to which the hair slopes a small patch of thickened epidermis is usually to be found, developed over an enlarged papilla of the cutis vera: while on the opposite side of the hair is a flat area of skin with thickened scale-like epidermis, which may represent a vestige of the reptilian scale (Pinkus). The hair-rudiments when they first appear (as at *a*, fig. 409) are singularly like certain tactile patches which are found in the skin of amphibia and some reptiles, and it is possible that hairs have become developed phylogenetically from these patches.

It is well known that the tactile sensibility of many parts of the skin is intimately

associated with the hairs, although parts devoid of hairs also have a highly developed sense of touch.

Muscles of the hairs.—A small muscle composed of bundles of plain muscular tissue is attached to each hair-follicle (*arrector pili*, fig. 399, *ar*); it passes from the superficial part of the corium, on the side to which the hair slopes, obliquely downwards, to be attached near the bottom of the follicle to a projection formed by a localised hypertrophy of the outer root-sheath. When the muscle contracts, the hair becomes more erect, and the follicle is dragged upwards so as to cause a prominence on the general surface of the skin, while the part of the corium from which the little muscle arises is correspondingly depressed; the roughened condition known as 'goose skin' being in this way produced. There is always a sebaceous gland in

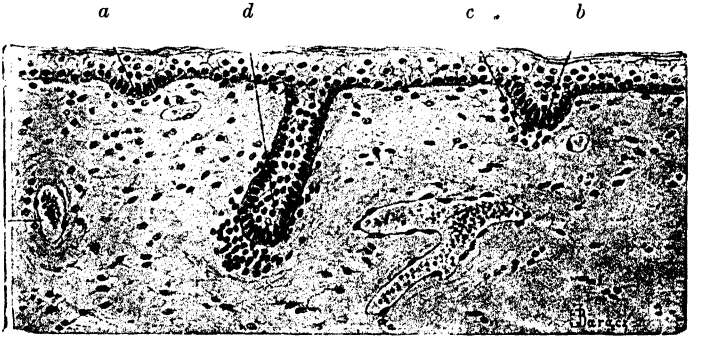

FIG. 409.—HAIR-RUDIMENTS IN A SECTION OF THE SCALP OF A HUMAN FŒTUS. (Szymonowicz.) × 230.

a, commencing downgrowth of epidermis; *b*, further stage of downgrowth; *c*, connective-tissue cells beginning to accumulate to produce the dermic coat of the follicle; *d*, hair-follicle more advanced in development; *e*, section of a blood-vessel.

the triangle formed between the arrector pili, the mouth of the hair-follicle, and the epidermis, so that the contraction of the arrector generally causes the secretion of the gland to be extruded. These small muscles are supplied by nerve-fibres derived from the sympathetic.

DEVELOPMENT.

The hairs are originally developed in the embryo as small solid downgrowths from the Malpighian layer of the epidermis (fig. 409). The hair-rudiment, which gives rise not only to the hair proper but also to the epithelium-cells of the hair-follicle, is at first composed entirely of soft growing cells, the outermost and deepest having a columnar shape; but presently those in the centre become differentiated, so as to produce a minute hair invested by the inner root-sheath, its base resting upon a papilla which has become enclosed by the extremity of the hair-germ and which is continuous with the connective tissue of the cutis (fig. 410). As the minute hair grows, it pushes its way through the layers of the epidermis, which it finally perforates, the epitrichial layer being thrown off. During the whole process the follicle is growing more deeply into the cutis vera, carrying the papilla down with it.

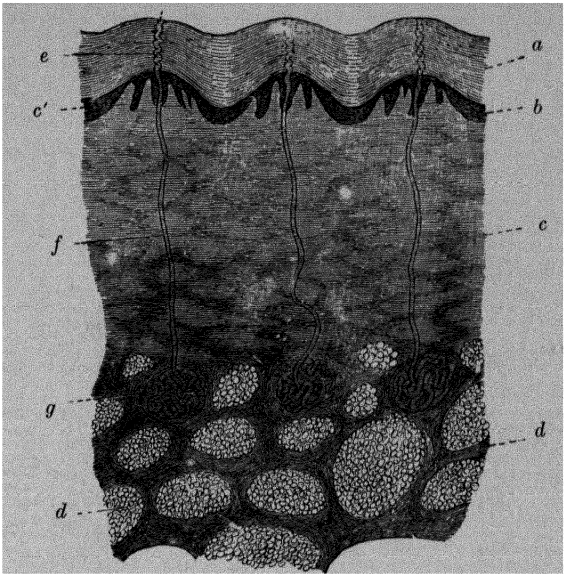

FIG. 412.—SECTION OF SKIN OF PALM, SHOWING POSITION OF SWEAT GLANDS. (Kölliker.) Diagrammatic.

a, *b*, epidermis; *c*, cutis vera; *c'*, papillæ of cutis; *d*, subcutaneous adipose tissue; *e*, channel passing through epidermis; *e'*, its orifice; *f*, duct of gland passing through cutis vera; *g*, coiled tubes of sweat gland.

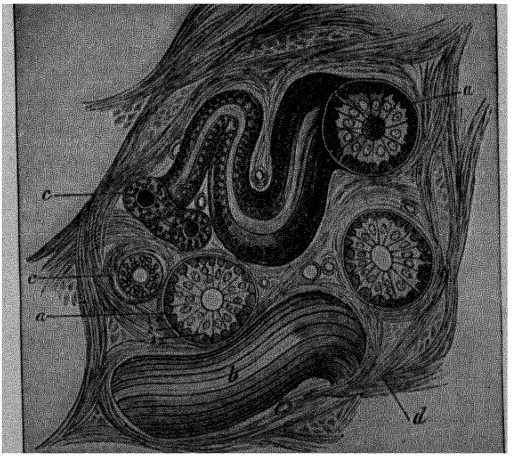

FIG. 413.—SECTION OF A SWEAT GLAND: MAN. (E. Sharpey-Schafer.)

a, *a*, secreting tube in section; *b*, a coil seen from above; *c*, *c*, efferent tube; *d*, intertubular connective tissue with blood-vessels. In section of secreting tube:—1, basement-membrane; 2, muscular fibres cut across; 3, secreting epithelium of tubule.

There may be two or more sebaceous glands attached to each hair-follicle. The mode of secretion is remarkable: the secretory product is formed by the actual disintegration of the epithelium-cells themselves.

The sebaceous glands are developed as outgrowths from the outer root-sheaths of the hairs (fig. 410, *s*).

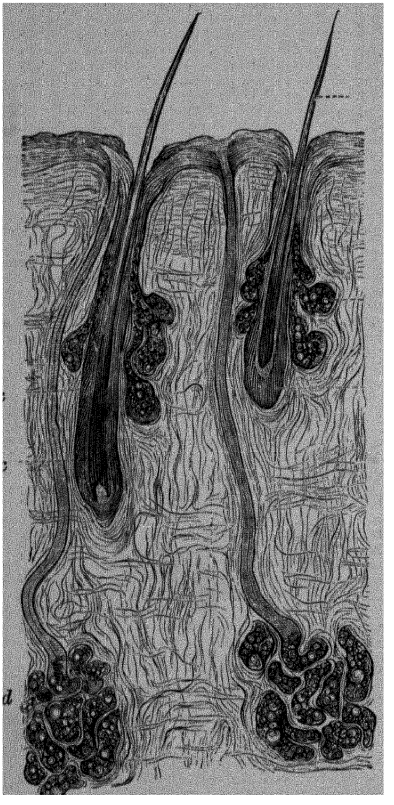

FIG. 414.—CERUMINOUS GLANDS OF THE EXTERNAL AUDITORY MEATUS, WITH HAIRS AND SEBACEOUS GLANDS.

a, hair; *b*, sebaceous gland; *c*, *c*, hair-follicles; *d*, ceruminous glands.

Sweat glands are abundant over the whole skin, but are most numerous on the palm of the hand and on the sole of the foot. They are composed of coiled tubes, which lie in the deeper part of the integument and send their ducts up through the cutis to open on the surface by corkscrew-like channels in the epidermis (fig. 412). See also fig. 392.

The *secreting part of the gland* is formed of a convoluted tube composed of a basement-membrane lined by a single layer of cubical or columnar epithelium-cells, and with a layer of longitudinally or obliquely disposed plain muscle-fibres between the epithelium and basement-membrane (fig. 413). The secreting tube is considerably larger than the duct; which begins within the gland and usually makes several convolutions before leaving the gland to traverse the cutis vera. The duct has an epithelium consisting of two or three layers of cells, within which is a well-marked cuticular lining; there is no muscular coat. The passage through the epidermis has no proper wall, but is merely a channel excavated between the epithelium-cells. Very large sweat glands occur in the axilla and round the anus. In these secretion is effected by the disintegration of the free ends of the cells, which project into the lumen of the alveolus. In type they are intermediate between the smaller sweat and the sebaceous glands, resembling the mammary gland in its mode of secretion.

The sweat glands receive nerve-fibres, and each gland has a special cluster of capillary blood-vessels.

The **ceruminous glands of the ear** (fig. 414) are modified sweat glands, but the secretion is of a fatty nature, instead of being watery like that of the ordinary sweat glands. Closely associated with the ceruminous glands are large sebaceous glands (fig. 415).

DEVELOPMENT.

The sweat glands are developed, like the hairs, as downgrowths of the Malpighian layer of the epidermis into the corium. They are distinguishable from the hair-

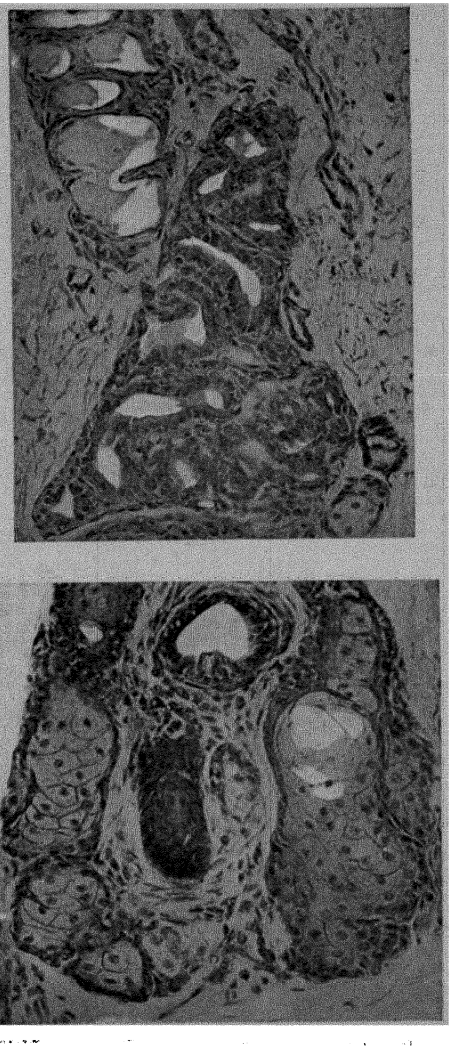

FIG. 415.—CERUMINOUS GLANDS OF THE EXTERNAL EAR: HUMAN. (E. Sharpey-Schafer). Photographs.

A. Section of a ceruminous gland. The duct has a spiral course and is therefore cut several times; it is partly filled with cerumen.

B. Section of duct of a ceruminous gland accompanied by the secreting tubules of large sebaceous glands.

rudiments by the fact that the cells of the outermost layer are not columnar in shape, but spheroidal or polyhedral. The sweat-gland rudiments which are thus formed

become eventually coiled up at their extremities and converted into hollow tubes. The muscular fibres of the tubes as well as the secreting epithelium-cells are ectodermal structures.

THE MAMMARY GLANDS.

The **mammary glands** are large compound racemose glands serving for the secretion of milk. Each mamma actually represents a group of glands, which open by numerous ducts upon the apex of the nipple. The ducts are dilated into small reservoirs just before reaching the nipple. The nipple contains a considerable amount of plain muscular tissue, lying between

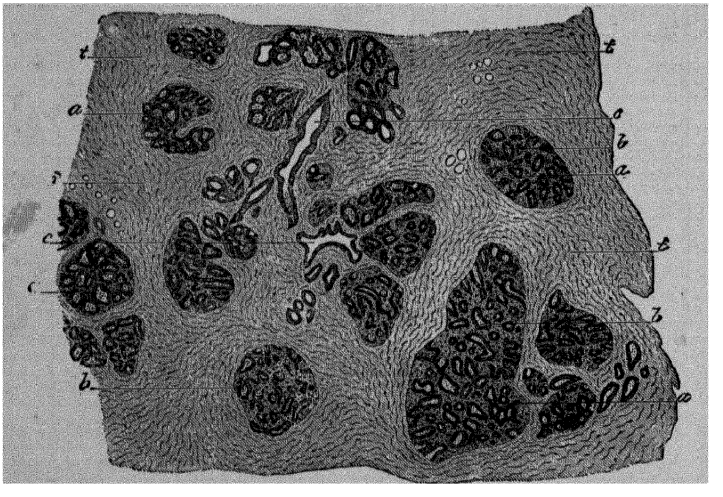

FIG. 416.—SECTION OF MAMMARY GLAND OF WOMAN DURING LACTATION. (de Sinéty.)
a, *b*, groups of acini; *c*, *c*, ducts variously cut; *t*, connective-tissue stroma of gland.

and around the ducts. Traced backwards, the ducts are found to commence in groups of saccular alveoli (fig. 416), the walls of which are lined by a single layer of epithelium which is columnar when the milk is being produced within the cells, but becomes flattened out as it is discharged and fills the alveolus. Milk globules may be seen forming within the columnar cells and also lying free within the alveoli (fig. 418). The distal part of each cell disintegrates during lactation, the nucleus and the rest of the cytoplasm remaining attached to the wall of the alveolus. The contrast between alveoli distended with milk and those which have been emptied of the secretion is striking (fig. 417). The emptying is brought about by contraction of plain muscle-cells in the alveolus (Bertkan), lying just inside the basement-membrane (as in the sweat glands). The muscle is stimulated to contract by intravenous injection of certain animal extracts (pituitary, corpus luteum).

At the commencement of lactation large cells containing fat-particles appear in the secretion (*colostrum corpuscles*). These are either detached portions of the secreting epithelium-cells or, as some believe, leucocytes.

In man there is a large amount of connective tissue (or adipose tissue) between the groups of acini, but in most mammals the whole organ is mainly formed of the secreting alveoli.

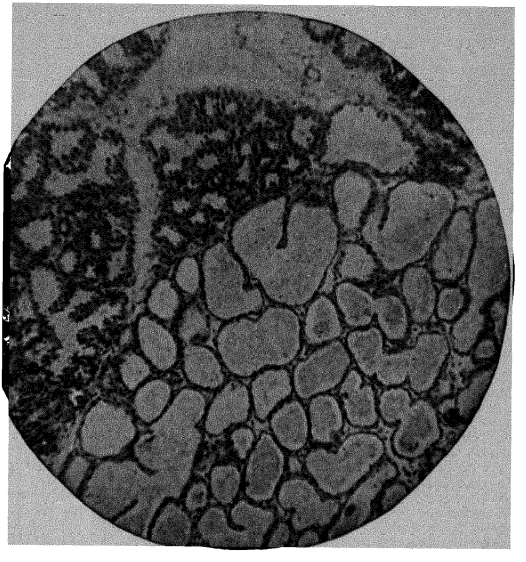

FIG. 417.—SECTION OF TWO ADJACENT MAMMARY GLANDS OF LACTATING CAT, ONE OF WHICH IS FULL OF MILK, WHILE THE OTHER HAS BEEN EMPTIED OF ITS SECRETION. (E. Sharpey-Schafer.) × 50. Photograph.

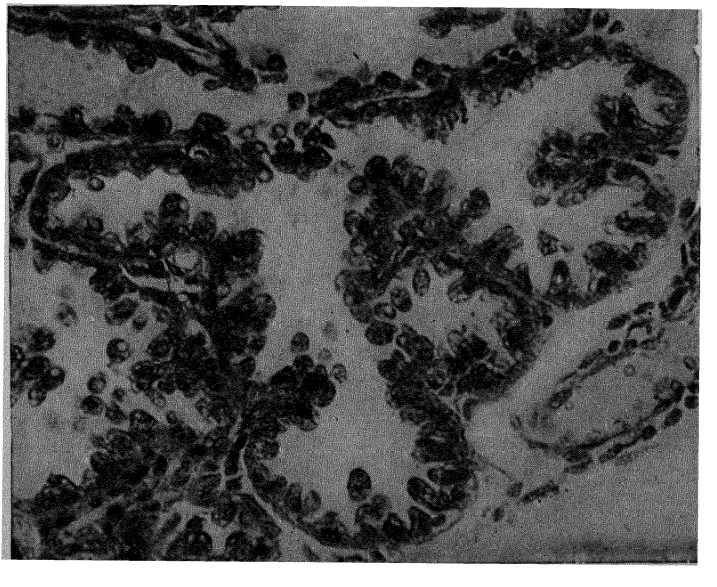

FIG. 418.—ALVEOLI OF MAMMARY GLAND OF LACTATING CAT. (E. Sharpey-Schafer.) × 400. Photograph.

Vessels and nerves.—The blood is distributed to a capillary network which surrounds the alveoli. There are numerous lymphatics within the gland; most of these, in man, carry their lymph to the axillary lymph-glands. The mammary glands also receive many nerves, mainly from the intercostals, but these do not appear directly to influence the outpouring of the secretion.

DEVELOPMENT.

The mammary glands are developed in the same manner as the sweat glands, excepting that the secreting part does not become convoluted and tubular. In the virgin mamma they show very few and small groups of alveoli, scattered in

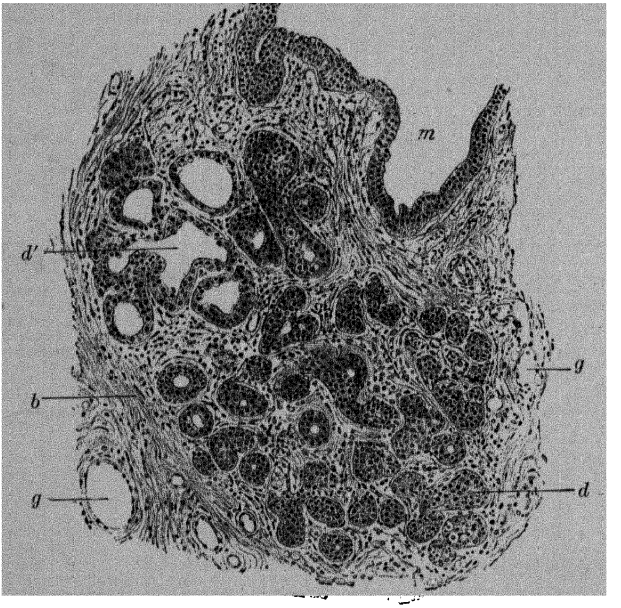

FIG. 419.—SECTION SHOWING DEVELOPING ALVEOLI IN HUMAN MAMMARY GLAND. (v. Ebner.) × 110.

m, part of a large duct; *d*, undeveloped alveoli; *d'*, partially developed alveoli; *g*, *g*, blood-vessels; *b*, connective tissue of gland.

abundant, thick connective tissue, but as pregnancy advances the gland-ducts bud out extensively, and many more alveoli are formed and undergo enlargement, until the greater part of the connective tissue in the mammary region is permeated by them. In most animals the whole mamma becomes occupied by secreting alveoli during active lactation. In the human subject, however, there are, even during full lactation, considerable portions of the mamma between the groups of alveoli, composed of connective tissue, generally with a large amount of adipose tissue, and even in sections of the lactating gland alveoli may be seen in various stages of development (fig. 419). After lactation is over the alveoli undergo a process of retrogression.

In the male the mammary gland consists of scanty ducts embedded in dense fibrous tissue. There are no alveoli, but under some circumstances development of glandular tissue and secretion of milk may occur as in the female.

After the gland has ceased to secrete the alveoli atrophy, becoming reduced to mere excrescences on the endings of the ducts; the calibre of the ducts also diminishes. As a consequence the fibrous tissue of the gland becomes very apparent; this is particularly the case in the human subject.

LESSON XXVI.

THE HEART.

1. In formol-fixed sections through the wall of the auricle note the relative thickness of the epicardium, myocardium, and endocardium. Observe the blood-vessels and nerves under the epicardium, often embedded in fat; here and there a ganglion may be seen under this membrane. Notice also the elastic networks under both the epicardium and endocardium. Make a general sketch of such a section.

2. In sections through the wall of the ventricle the same points are to be noticed. The muscular fibres are variously cut. In those cut longitudinally, the branching of the fibres and their union both laterally and end-wise may be seen. Notice also that, although the fibres are cross-striated, this is less distinct than in voluntary muscle, and that the nuclei lie in the middle of the fibres. Transverse markings may also be seen passing across the fibres between the nuclei; this is usually taken as indicating a division into cells. The endocardium is thin, especially over the columnæ carneæ.

3. Section through one of the valves of the heart.[1]

4. If a portion of endocardium of the sheep's heart is spread out on a slide and examined in Ringer, a network of large beaded fibres may be seen with a low power or even with a lens; they are also seen in sections. These are the fibres of Purkinje; they are formed of large, square-looking cells usually containing two nuclei, and having cross-striated muscular substance at their periphery.

5. The lymphatics of the heart may be injected with Berlin-blue or with any coloured solution by sticking the nozzle of a hypodermic syringe into the muscular substance, and forcing the fluid into the interstices. The commencing lymphatics thus injected lead to efferent vessels which pass under the epicardium towards the base of the heart.

6. The epithelium which covers the epicardium, and that which lines the endocardium, may be studied in preparations of the fresh organ rinsed with distilled water, then treated with nitrate of silver, again rinsed, and subsequently exposed to the light and hardened in 90 per cent. alcohol. Surface-sections are made and mounted in dammar after passing through clove oil.

Myocardium.—The muscular tissue of the heart (fig. 420) forms the main thickness of the ventricles and also of parts of the auricles. It is composed of a network of fibres formed of transversely striated cells, the structure and histogenesis of which have already been studied (Lesson XVI).

In the interstices of the muscular bundles there is a considerable amount of areolar tissue in which run numerous blood-capillaries and lacunar lymphatics.

[1] The appearances which are to be studied in sections 1, 2, and 3 can all be obtained in one preparation, viz. a vertical section including a portion of auricle and ventricle and a flap of the intervening auriculo-ventricular valve.

Epicardium.—The myocardium is covered externally by a layer of serous membrane—the epicardium or cardiac pericardium (fig. 421)—composed,

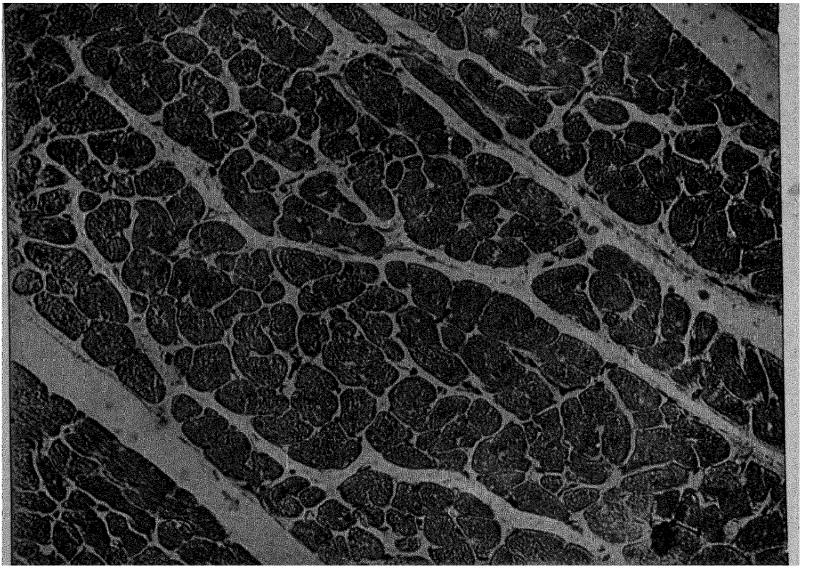

FIG. 420.—SECTION OF MYOCARDIUM. (E. Sharpey-Schafer.) × 200. Photograph.

Most of the fibres are cut across. Notice the irregular outlines of the fibres and the manner in which they blend laterally with one another; the nuclei in the middle of the fibres; the interstitial connective tissue subdividing the muscular tissue into larger and smaller bundles.

like other serous membranes, of connective tissue and elastic fibres, the latter being most numerous in its deeper parts. Underneath the epicardium run the main blood-vessels, nerves, and lymphatic vessels of the heart embedded in

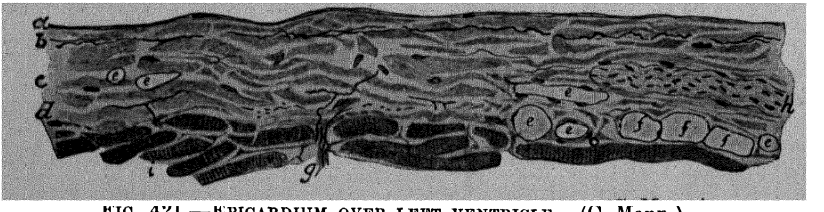

FIG. 421.—EPICARDIUM OVER LEFT VENTRICLE. (G. Mann.)

a, endothelium of serous membrane; *b*, elastic fibres; from *a* to *b* is the superficial layer; *c*, middle layer, consisting of fibrous tissue with a few elastic fibres; *d*, deep layer continuous with the connective tissue of the myocardium (*i*); *e*, blood-vessels; *f*, fat-cells; *g*, *h*, nerves.

areolar and adipose tissue, this tissue being continuous with that which lies between the muscular bundles; the free surface of the membrane is covered by serous endothelium.

Endocardium.—The lining membrane of the cavities of the heart, known as the endocardium (figs. 422, 423), has a structure not very unlike the

epicardium. It is lined by a pavement-epithelium (endothelium), like that of a serous membrane, and consists of connective tissue with elastic fibres in its deeper part, between which there may, in some parts, be found a few plain muscular fibres. Fat is sometimes met with under the endocardium.



FIG. 422.—ENDOCARDIUM OF RIGHT AURICLE. (G. Mann.)

a, lining endothelium; *b*, fibrous tissue; *c*, elastic tissue: these make up the internal layer; *d*, middle layer; *e*, outer elastic layer; *f*, connective tissue (with numerous elastic fibres) continuous with that of the myocardium (*h*); *g*, muscle-bundles.

In some animals a network of large beaded trabeculæ can be distinctly seen under the endocardium. The trabeculæ are formed of clear cells joined both end to end and laterally, and generally containing in their centre two nuclei, while the peripheral part of the cell is formed of cross-striated muscular tissue; the trabeculæ are known as the *fibres of Purkinje* (fig. 424). These

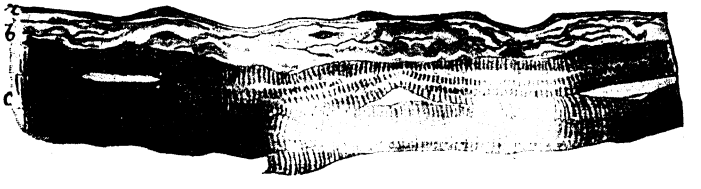

FIG. 423.—ENDOCARDIUM COVERING ONE OF THE COLUMNÆ CARNEÆ OF THE RIGHT VENTRICLE. (G. Mann.)

a, endothelium; *b*, connective tissue with elastic fibres; *c*, muscular fibres of myocardium.

are formed of cells which have undergone differentiation into striated muscle at their periphery only. They are especially well marked in the sheep's heart. Although best marked in the ventricles, a somewhat similar tissue occurs under the endocardium of the auricles. In man the fibres of Purkinje are not so distinct from the ordinary cardiac muscle as in the sheep, but the innermost muscular fibres of the ventricles are different from the ordinary fibres, usually having more clear protoplasm around the

nuclei. The larger size is not a necessary character of the fibres belonging to the Purkinje system, for some are smaller than the ordinary fibres.[1]

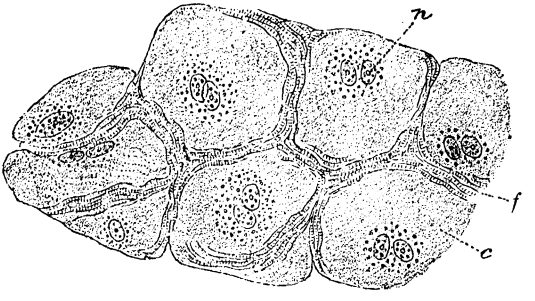

FIG. 424.—FRAGMENT OF THE NETWORK OF PURKINJE FROM THE VENTRICULAR ENDOCARDIUM OF THE SHEEP. (Ranvier.)
c, clear cell-body; *n*, nuclei; *f*, striated fibrils.

Muscular connexion between auricles and ventricles.—Muscular fibres, showing less differentiation than the rest of the cardiac muscle, and in some respects like the Purkinje fibres, were first described by Stanley Kent (1892) as affording a bridging connexion in mammals between the muscle of the



FIG. 425.—TEASED PREPARATION FROM MONKEY'S HEART SHOWING CHARACTER OF FIBRES CONNECTING AURICLE AND VENTRICLE. (Stanley Kent.)

auricles and that of the ventricles (fig. 425). Such fibres are for the most part collected into a circumscribed fasciculus known as the *auriculo-ventricular* or *A-V bundle* (W. His, jun., 1893). This bundle, formed of small parallel fibres which intercommunicate (fig. 426), extends from a plexiform mass of

[1] For an account of the Purkinje system of fibres and the literature relating to them, the article by T. Wingate Todd in Cowdry's *Special Cytology*, 1928, pp. 853 to 886, may be consulted.

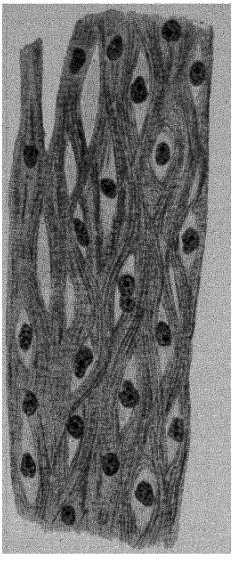

FIG. 426.—FIBRES OF UPPER END OF A-V BUNDLE: DOG. (Tawara.)

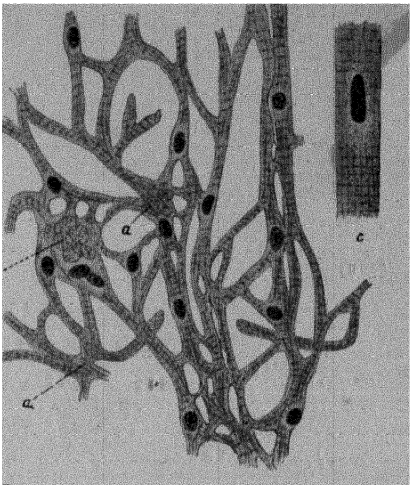

FIG. 427.—NETWORK OF FIBRES FORMING PART OF THE NODE OF TAWARA IN WHICH THE A-V BUNDLE COMMENCES.

a, *a*, junctions of fibres; *b*, fibres cut across; *c*, an ordinary muscle-fibre of the auricle drawn to the same scale.



FIG. 428.—LONGITUDINAL SECTION OF PART OF RIGHT VENTRICLE: DOG—SHOWING THE PURKINJE FIBRES IN WHICH THE FIBRES OF THE A-V BUNDLE END. (Tawara.)

a, endothelium of endocardium.



FIG. 429.—SUBENDOCARDIAL FIBRES OF RIGHT VENTRICLE: MAN—IN WHICH THE FIBRES OF THE A-V BUNDLE TERMINATE. THESE FIBRES REPRESENT THE PURKINJE FIBRES OF ANIMALS. (Tawara.)

a, a cross-marking (so-called cell junction); *b*, subendocardial connective tissue.

very small fibres known as the *node of Tawara* (fig. 427) on the septal wall of the right auricle, through the fibrous tissue which separates the auricles from the ventricles into the septum between the ventricles. Here it bifurcates; a branch passing to each ventricle. Over the inner surface of the ventricle, underneath the endocardium, the bundle is continuous with the network of special muscular fibres described in the sheep by Purkinje (figs. 424, 428, 429). Of the two main branches of the bundle that to the left ventricle is the larger. The bundle and all its branches are invested by a special connective-tissue sheath which can be injected with coloured fluid:

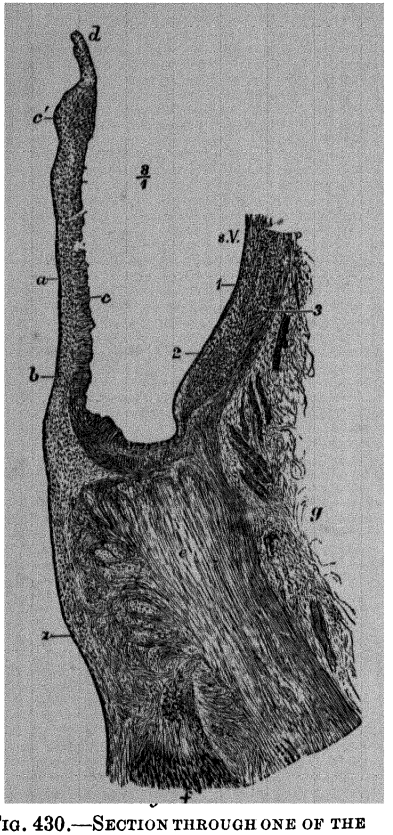

FIG. 430.—SECTION THROUGH ONE OF THE FLAPS OF THE AORTIC VALVE, AND PART OF THE CORRESPONDING SINUS OF VALSALVA, WITH THE ADJOINING PART OF THE VENTRICULAR WALL. (From a drawing by Victor Horsley.)

a, endocardium prolonged over the valve; *b*, sub-endocardial tissue; *c*, fibrous tissue of the valve, thickened at *c'* near the free edge; *d*, section of the lunula; *e*, section of the fibrous ring; *f*, muscular fibres of the ventricle attached to it; *g*, loose areolar tissue at the base of the ventricle; *s.V.*, sinus of Valsalva; 1, 2, 3, inner, middle, and outer coats of the aorta.

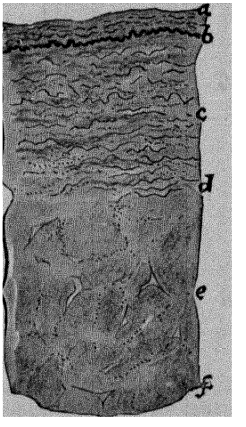

FIG. 431.—SECTION (LONGITUDINAL) OF AORTIC VALVE: HUMAN. (G. Mann.) 1, PART CONTINUOUS WITH ENDOCARDIUM; 2, PART CONTINUOUS WITH AORTIC WALL.

a, endothelium; *b*, elastic layer; *c*, fibrous layer with many elastic fibres; *d*, line of junction of ventricular and aortic portions; *e*, compact fibrous tissue with fine elastic fibres; *f*, endothelium and elastic lamina.

this affords the best means of demonstrating the whole system (Aagard). Besides the extension in the ventricles there is a prolongation of the same tissue under the endocardium of the right auricle and in this is found another plexiform mass (*node of Keith and Flack*) which lies close to the entrance of the superior vena cava and has a special vascular supply. It has been shown by T. Lewis that the heart-beats start from this node.

The auriculo-ventricular bundle serves the purpose of propagating the contractions of the auricles to the ventricles and thus maintaining the regularity of sequence. When the bundle is severed experimentally or by disease this propagation is no longer possible; the ventricles then beat irregularly and with a much slower rhythm than the auricles.

Both the A-V bundle and the node of Keith and Flack contain many elastic fibres (Rénon and Geraudel). They also have a special vascular

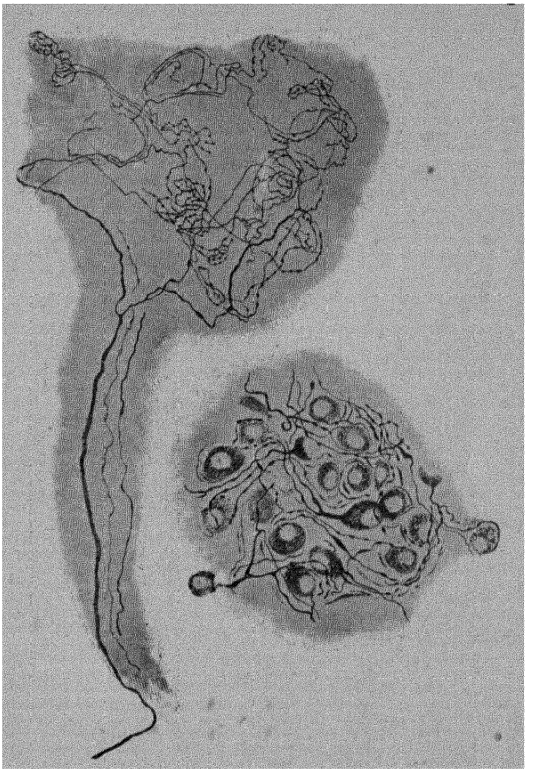

FIG. 432.—A, ENDING OF A-MYELINATE NERVE-FIBRES IN A SMALL GANGLION OF THE HEART.
The ganglion-cells are not represented.
B, A SMALL GANGLION FROM THE HEART, SHOWING GANGLION-CELLS AND THEIR PROCESSES. (Dogiel.)

supply. Many of the nerve-branches which supply the heart terminate in or near the node of Keith and Flack.

The **valves** of the heart are formed of folds of endocardium strengthened by fibrous tissue (figs. 430, 431). This tissue forms a thickening near the free edge of the valve (fig. 430, *c'*). At the base of the auriculo-ventricular valves the muscular tissue of the auricle may be found passing a short distance into the valves. In the fœtus these valves are at first largely muscular.

Nerves are seen underneath the epicardium of both auricles and

ventricles and pass into the myocardium; they have small ganglia on their course (fig. 432). The axons of the ganglion-cells pass to the muscular substance, and after dividing into fine fibrils, end in enlarged extremities, applied directly to the muscular fibres (fig. 297, p. 220). Others pass directly to the muscular substance without connexion with ganglion-cells. Afferent nerve-fibres are also abundant under the epicardium. They end in diffuse arborisations and in special terminal organs, like those of Golgi-Mazzoni (p. 211). Yet other myelinate nerve-fibres, probably afferent,

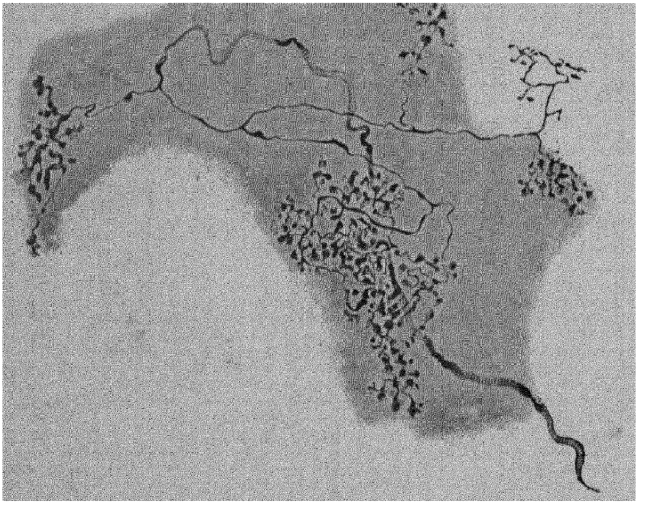

FIG. 433.—TERMINATION OF AN AFFERENT NERVE-FIBRE IN THE ENDOCARDIUM. (Dogiel.)

terminate in complex ramifications in the endocardium (fig. 433). Nerve-fibres also accompany the coronary vessels and are distributed to their walls.

The blood-vessels of the heart (coronary vessels) are abundant, the arteries being relatively large and the capillary network close. The nodes are supplied by special arterioles, but the system of Purkinje fibres is less vascular than the rest of the myocardium. The (coronary) veins are thin-walled, retaining the capillary structure (endothelium only) in vessels of as much as 0·25 mm. in diameter. The blood-vessels are accompanied by numerous lymph-vessels, which form plexuses under the cardiac pericardium and endocardium. The lymphatics of the myocardium occupy lacunar spaces in the interstitial connective tissue between the muscle-fibres and can be readily demonstrated by injecting coloured fluid into the substance of the myocardium; the fluid passes from these spaces into lymph-vessels of the epi- and endo-cardium.

LESSON XXVII.

THE LARYNX, TRACHEA, AND LUNGS.

1. In sections of the trachea and larynx, notice the columnar ciliated epithelium, the basement-membrane (especially thick in the human trachea and larynx), the lymphoid tissue of the mucous membrane, the elastic tissue external to this, and lastly, the fibrous membrane containing the cartilages. In the deeper parts of the mucous membrane, in which there is much loose areolar tissue, look for sections of small mucous glands, ducts of which may be seen passing to the surface. At the back of the trachea notice the plain muscular fibres transversely arranged; there are larger mucous glands external to these in some places.

2. In thin sections of lung notice the alveoli collected into groups (infundibula or air-sacs). Find sections of bronchial tubes, some cut longitudinally and passing at their extremities into the alveolar passages, others cut across. In each tube notice the ciliated epithelium internally; next to this the mucous membrane containing numerous elastic fibres and often thrown into folds; then the layer of circular muscular fibres, and, outside this, loose fibrous tissue in which, in the larger bronchial tubes, pieces of cartilage may be seen embedded. Small mucous glands may also be observed in the fibrous tissue sending their ducts through the other layers to open on the inner surface. Notice that a branch of the pulmonary artery always accompanies a bronchial tube, whereas the pulmonary veins take a separate course through the tissue.

In the sections of the alveoli the capillary vessels are cut across or lengthways as the case may be; and in places where the thin wall of an alveolus is seen flat in the section, the close network of blood-capillaries may be observed. In sections stained with orcëin the elastic fibres are displayed. Within the alveoli large nucleated corpuscles may here and there be observed with dark particles in their protoplasm. Similar cells are seen between the alveoli. Make a sketch of part of the wall of one or more bronchial tubes and of one or two of the alveoli.

3. The shape and arrangement of the alveoli is best seen in casts, which can be scraped or squeezed out of slices of a lung moderately distended with carmine-coloured gelatine and kept in 50 per cent. alcohol.

4. In fairly thick sections of fresh lung which has been filled with a mixture of gelatine and nitrate of silver solution the epithelium of the alveoli can be studied. The sections are made with the freezing microtome, and mounted in dilute glycerine; the preparation is warmed after the cover-glass is applied in order to melt the gelatine. On exposure to sunlight the silver becomes reduced in the intercellular spaces, thus outlining the epithelium-cells.

5. Mount a moderately thick section of lung injected with carmine gelatine. Study the general arrangement of the vessels with a low power, and the network of capillaries of the alveoli with a high power. Sketch the capillary network of one or two adjoining alveoli.

THE TRACHEA AND LARYNX.

The **trachea** or **windpipe** is a fibrous and muscular tube the wall of which is rendered somewhat rigid by C-shaped hoops of cartilage embedded

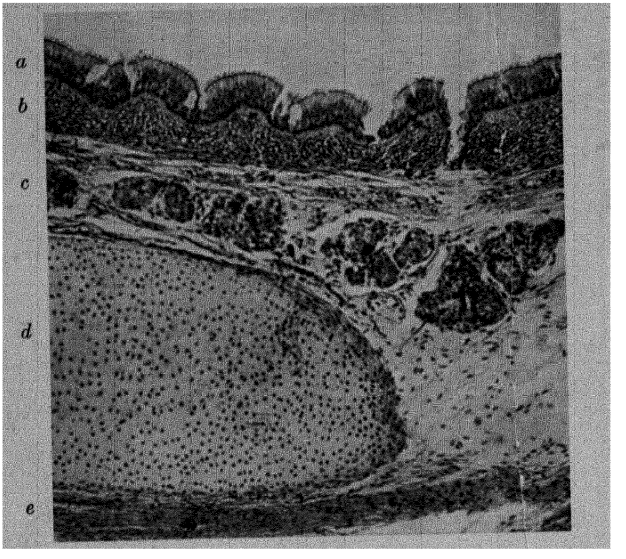

FIG. 434.—TRANSVERSE SECTION OF TRACHEA OF CHILD, INCLUDING PORTION OF A CARTILAGINOUS RING AND PART OF THE MUSCLE AT THE BACK OF THE TUBE. (E. Sharpey-Schafer.) × 75.

a, ciliated epithelium; *b*, mucous membrane; *c*, submucous areolar tissue, containing small mucous glands; *d*, cartilage; *e*, fibrous tissue, with (on right of section) the trachealis muscle inserted into it.

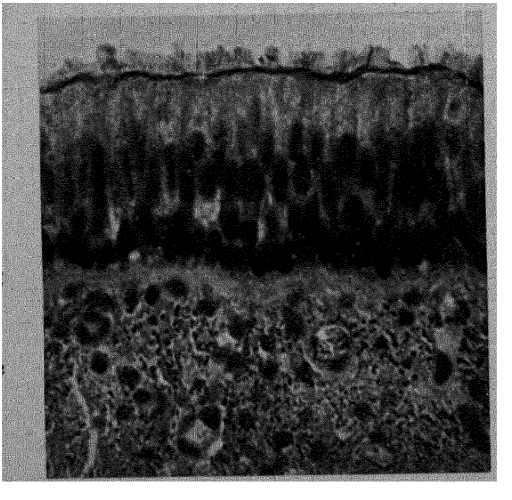

FIG. 435.—CILIATED EPITHELIUM OF TRACHEA: CHILD. (E. Sharpey-Schafer.) × 435.

a, cilia; *b*, zone of nuclei of ciliated cells; between the nucleus and the free border striation may be seen in some places; *c*, zone of nuclei of deep-lying cells; *d*, basement-membrane; *e*, superficial part of corium of mucous membrane, showing blood-vessels and elastic fibres cut across. The nuclei belong to connective-tissue cells and leucocytes.

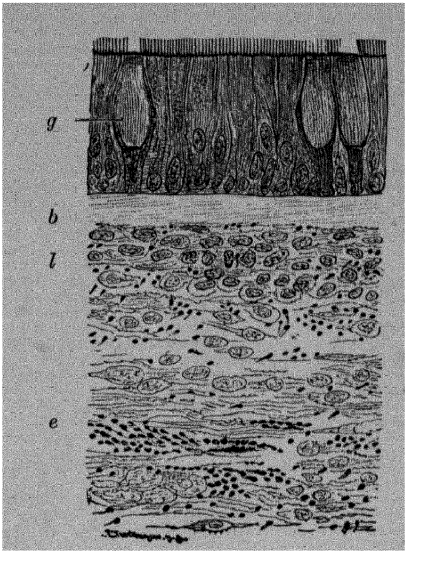

FIG. 436.—MUCOUS MEMBRANE OF LARYNX: MAN. (Merkel.)

g, a goblet-cell among the ciliated epithelium-cells; *b*, basement-membrane; *l*, lymphoid tissue; *e*, elastic fibres, cut across.

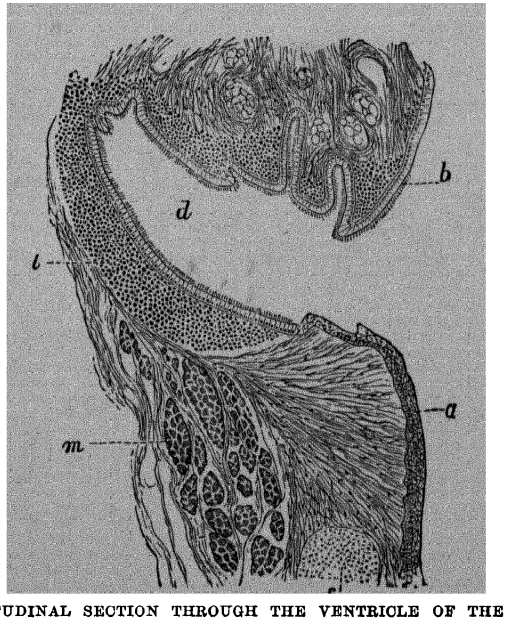

FIG. 437.—LONGITUDINAL SECTION THROUGH THE VENTRICLE OF THE LARYNX OF A CHILD. (Klein.)

a, true vocal cord; *b*, false vocal cord; *c*, nodule of cartilage; *d*, ventricle of Morgagni; *l*, lymphoid tissue; *m*, thyro-arytenoid muscle.

in the fibrous tissue. The muscular tissue, which is of the plain variety, forms a flat band, the fibres of which run transversely at the back of the tube. The trachea is lined by a *mucous membrane* (fig. 434), with ciliated epithelium (fig. 435) upon its inner surface. During life the cilia are covered with mucus; this is generally precipitated over them by the fixative employed. The direction in which the cilia beat is towards the vocal cords; inhaled particles (*e.g.* dust) are thus largely got rid of, being caught in the mucus and carried towards the glottis. The epithelium-cells, already described (Lesson VIII.), have goblet-cells among them (fig. 436); they are in two layers and rest upon a thick basement-membrane. The corium of the mucous membrane consists of areolar and lymphoid tissue, and contains numerous blood-vessels and lymphatics. In its deepest part is a well-marked layer of longitudinal elastic fibres. Many small glands—mucous and mixed mucous and serous—are found in the wall of the trachea. They may lie either within the mucous membrane or in the submucous areolar tissue, or at the back of the trachea, outside the transverse muscular fibres.

The two main divisions of the trachea, the right and left *bronchi*, are precisely similar in structure to the main tube.

The **larynx** resembles the trachea so far as the structure of the mucous membrane is concerned. It also is lined by ciliated epithelium, but over the true vocal cords and upon the epiglottis, as well as here and there in the part of the larynx just above the glottis, stratified epithelium is found; taste-buds may occur in this epithelium, except over the vocal cords. Numerous nerves end in the epithelium (see fig. 284, p. 213).

The true vocal cords are composed of fine elastic fibres, and are covered by stratified epithelium.

Lymphoid tissue is especially abundant in the mucous membrane of the ventricle of Morgagni (fig. 437, *d*). A large number of mucous glands open into this cavity and into that of the sacculus which communicates with it.

The cartilages of the trachea, as well as the thyroid, cricoid, and arytenoid cartilages of the larynx, are hyaline; all these are liable to ossify as age advances. The epiglottis and the cartilages of Santorini and of Wrisberg are composed of elastic fibro-cartilage and do not ossify. The uppermost part of the arytenoid, the tip of the vocal process of the same cartilage, and sometimes the median portion of the thyroid cartilage are also composed of elastic cartilage.

THE LUNGS.

The lungs are formed by the ramifications of the *bronchial tubes* and by their terminal expansions; these last form groups or lobules of sacculated dilatations (*air-sacs*, *infundibula*), beset everywhere with small irregularly hemispherical bulgings, known as the *pulmonary alveoli* or *air-cells*.

The **bronchial tubes** (figs. 438 to 441) are lined (except the terminal bronchi) by ciliated epithelium resting on a basement-membrane. External to this is the corium of the mucous membrane, containing a large number of longitudinal elastic fibres and some lymphoid tissue. Outside this again

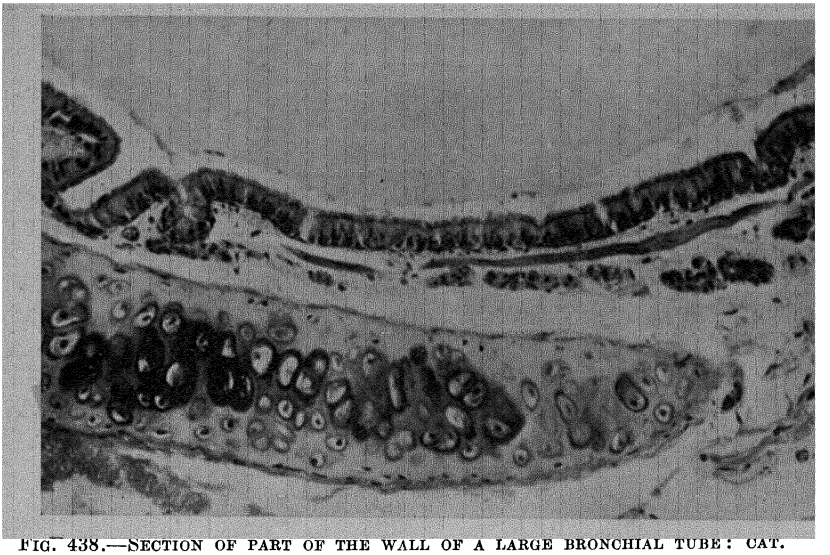

FIG. 438.—SECTION OF PART OF THE WALL OF A LARGE BRONCHIAL TUBE: CAT. (E. Sharpey-Schafer). × 150. Photograph.

a, ciliated epithelium: on the left is the opening of a gland duct; *b*, elastic layer of mucous membrane; *c*, muscular layer; *d*, mucous glands in areolar tissue; *e*, fibrous layer with plate of cartilage.

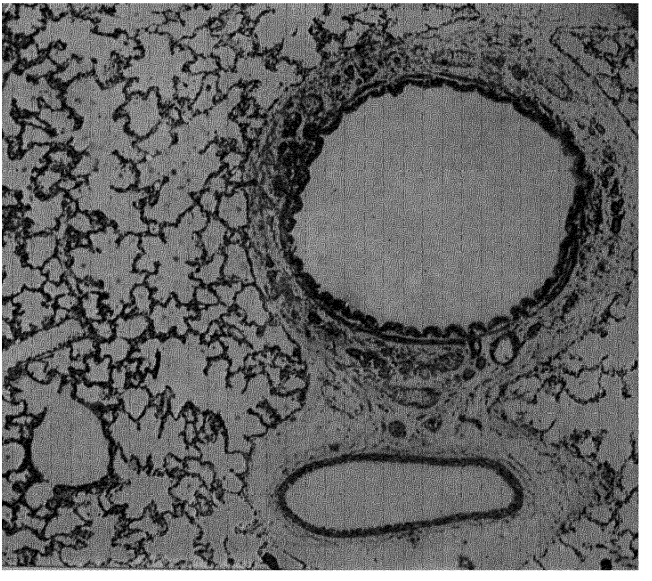

FIG. 439.—SECTION OF LUNG (DOG) SHOWING A MODERATE-SIZED BRONCHIAL TUBE WITH THE BRANCH OF THE PULMONARY ARTERY ACCOMPANYING IT. (E. Sharpey-Schafer.) × 50. Photograph.

Some of the adjacent pulmonary tissue is included in the section, and presents a characteristic appearance.

is a layer of plain muscular fibres encircling the tube. This c muscle does not, however, form a continuous sheet but show the circular bundles; the gaps being bridged by obliquely r which join with the circular to produce a sort of reticulate Miller). Next to the muscular layer comes a loose fibrous tis in the large and medium sized tubes (figs. 438, 440), plates of embedded. Mucous glands are also present in this tissue.



FIG. 440.—PART OF THE SECTION SHOWN IN THE PRECEDING FIGURE. (E. Sharpey-Schafer.) × 200.

In the bronchial tube, the epithelium, the muscular layer, mucous glands and two small pieces of cart can be seen. The corrugations of the mucous membrane are caused by post-mortem contraction of muscular layer.

The extremities of the small bronchial tubes expand into passage *respiratory bronchioles*; these give off as branches the *alveolar passage*. The walls of both are beset with alveoli. The alveolar passages lead into irregularly spherical alveolated dilatations (*atria*) with which a number of blind and often funnel-shaped diverticula completely covered with alveoli communicate; these are the *infundibula* or *air-sacs* (Waters). The arrangement of the parts, according to the investigations of W. S. Miller, is as follows (fig. 443): Two or more *air-sacs*, or groups of *alveoli*, open from a common chamber (*atrium*), and three to six atria are connected with the ending of

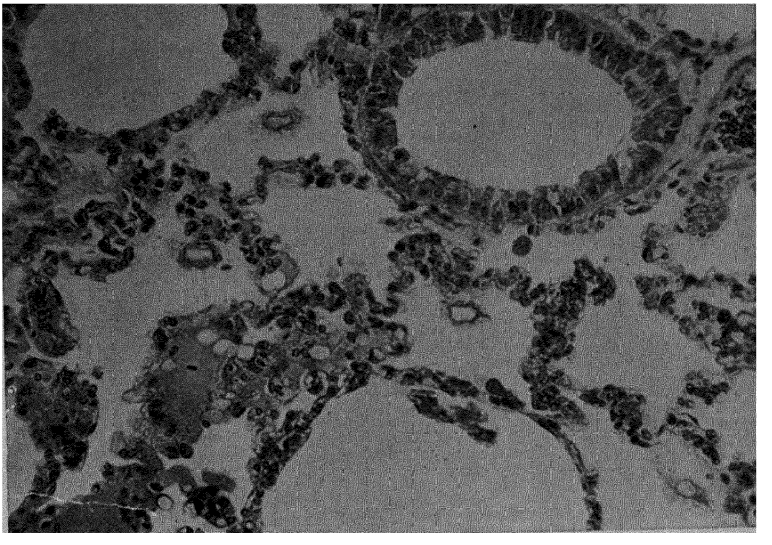

FIG. 441.—SECTION OF A SMALL BRONCHIAL TUBE (RABBIT). (E. Sharpey-Schafer.) × 300. Photograph.

The section also shows a respiratory bronchiole (below), an atrium (above and on the left), and several collapsed alveoli. The tissue on the left and below is infiltrated with lymph.

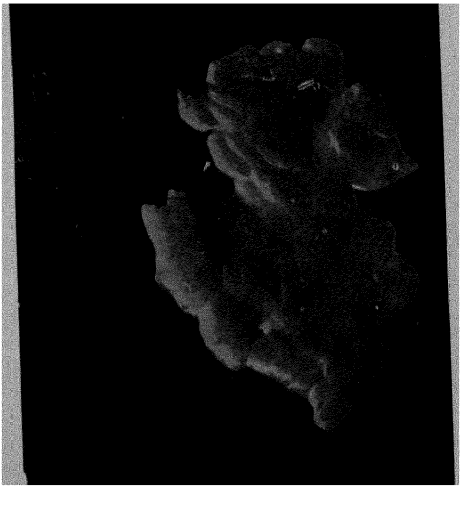

FIG. 442.—GELATINE CAST FROM LUNG OF YOUNG CAT. (E. Sharpey-Schafer.) × 75. Photographed by reflected light.

The figure shows two or three terminal groups of alveoli (infundibula or air-sacs), connected with their common atrium.

an *alveolar passage*. The latter lead out of the *respiratory bronchioles*, which are expanded continuations of the smallest bronchial tubes.

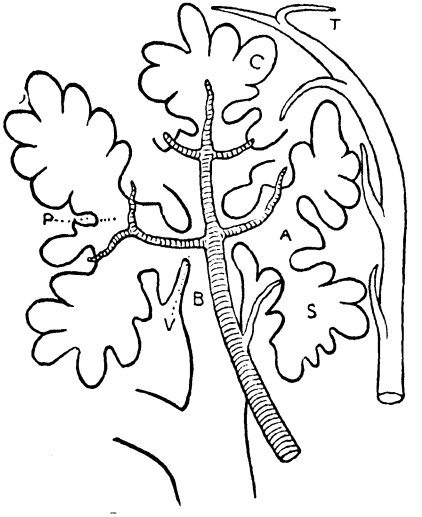

FIG. 443.—DIAGRAM OF THE ENDING OF A BRONCHIAL TUBE. (W. S. Miller.)
B, terminal bronchiole (alveolar passage); V, vestibule; A, atrium; S, air-sac or infundibulum; C, air-cell or alveolus; P, ending of pulmonary arteriole; T, commencement of pulmonary venule.

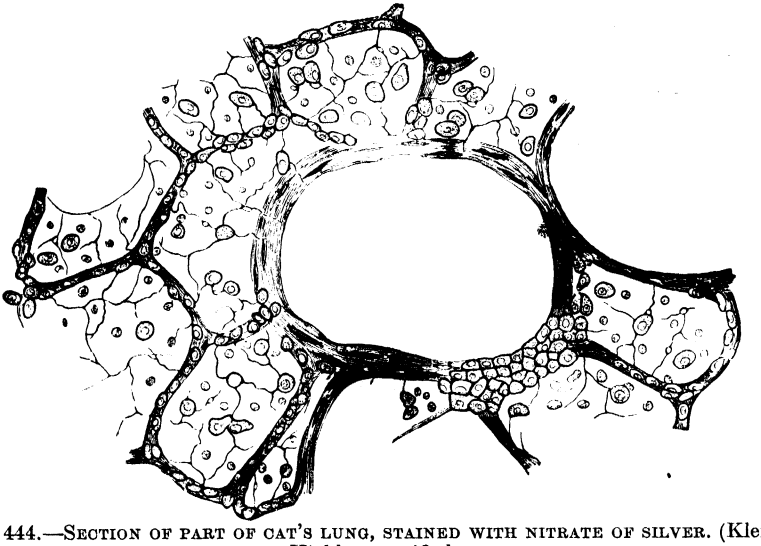

FIG. 444.—SECTION OF PART OF CAT'S LUNG, STAINED WITH NITRATE OF SILVER. (Klein.)
Highly magnified.
Both cubical and large flattened cells of the alveoli are shown. In the middle is a section of an alveolar passage with a patch of cubical epithelium-cells at one side.

The epithelium changes in character as we trace the small bronchi into the respiratory bronchioles; from columnar and ciliated it becomes cubical and non-ciliated, and there are patches of the respiratory epithelium (see

below) not only in the alveoli which occur scattered over the respiratory bronchioles but also elsewhere in the wall of the latter. The plain muscular tissue of the small bronchi is continued as a distinct layer on the walls of the

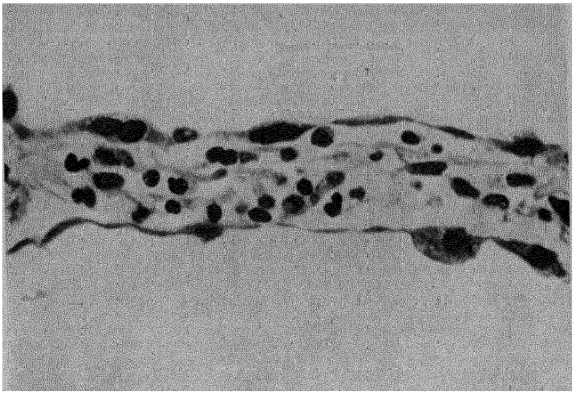

FIG. 445.—SECTION OF THE WALL OF AN ALVEOLUS OF HUMAN LUNG. (W. S. Miller.) × 500. Photograph.

The lung was slightly œdematous, and the epithelium-cells are separated in places from the tissue of the alveolus with its capillaries and are thus rendered very evident.

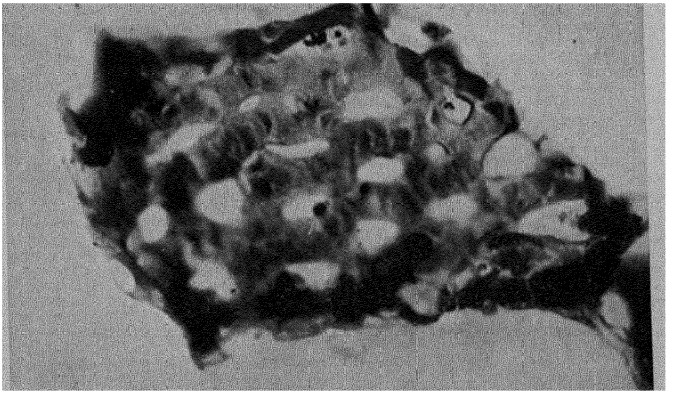

FIG. 446.—AN ALVEOLUS OF RABBIT'S LUNG SHOWING THE VASCULAR NETWORK, THE PULMONARY CAPILLARIES BEING FULL OF BLOOD. (E. Sharpey-Schafer.) × 700. Photograph.

It will be seen that the area covered by the vessels is much greater than the area of the interstices.

respiratory bronchioles, but not on those of the alveolar passages and atria, although some muscle-cells occur round the mouths of the atria and even of the alveoli.

The **alveoli** are lined by large, irregular, flattened cells (fig. 444), the nuclei

of which can only with difficulty be demonstrated in the adult lung, although easily shown in the lung of the fœtus and infant. They form an extremely delicate layer (*respiratory epithelium*), separating the blood-capillaries from the air within the alveoli (fig. 445). Among the flattened cells are here and there groups of smaller and thicker (cubical) epithelium-cells. The capillary network of the alveolus is very close (fig. 446), and the capillary vessels of adjacent alveoli are in complete continuity. Besides the epithelium a delicate connective tissue forms the wall of each alveolus. Elastic fibres are numerous around the mouths of the alveoli; a certain number course over the wall of each alveolus (fig. 447).



FIG. 447.—ELASTIC FIBRES OF LUNG, STAINED WITH ORCËIN. (E. Sharpey-Schafer.) × 200. Photograph.

Large dust-containing phagocytes may be seen both attached to the alveolar wall and free in the alveolar cavity. They are especially common in the lungs of town-dwellers, in which the pulmonary lymphatics and bronchial glands are also charged with black particles conveyed thither by these 'dust-cells.'

Blood-vessels.—Branches of the pulmonary artery accompany the bronchial tubes, to be distributed to the capillary networks upon the alveoli; from these networks the blood is returned by the pulmonary veins. An arteriole runs with each terminal bronchiole, and, dividing into as many branches as there are atria (fig. 443), is distributed to the capillary networks of all the air-cells with which the bronchiole is connected (Miller). From these networks one or two venules collect the blood, usually coursing (independently of the arteriole) on the outer border of the group of infundibula;

they unite with other venules to form efferent veins. The venules of the superficial lobules are connected with a vascular network at the surface of the lung underneath the pleura. This network is also supplied from the bronchial arteries. The veins, pursuing a separate course through the tissue of the lung, join with others to form larger vessels which pass to the root of the lung. Branches from the bronchial arteries are distributed to the walls of the bronchial tubes, and to the connective tissue of the lung, including that of the pleura. Bronchial veins accompany the bronchial arteries to the larger tubes, but most of the blood brought to the lungs by the bronchial arteries is returned by the pulmonary veins. Connective tissue (interstitial tissue) intervenes everywhere in small quantity between the infundibula and forms a distinct layer, containing much elastic tissue, covering the surface of the lung underneath the serous membrane (subserous tissue). In some animals (*e.g* guinea-pig) the subserous layer contains plain muscular tissue, which is especially developed near the lung-apex; it has not been detected in man.

In the guinea-pig (and opossum) the pulmonary arteries have a very thick musculature, which is, however, not continuous throughout, but is interrupted at irregular intervals by portions of artery devoid of muscular coat, giving a varicose appearance to the vessels when isolated from the surrounding lung-tissue. In ruminants the muscular coat has a spiral arrangement.

The **lymphatics** of the lung accompany the bronchial tubes, the branches of the pulmonary artery, and the branches of the pulmonary vein; they also form a network in the pleura. The atria and air-sacs have no lymphatics in their walls (Miller). The bronchial lymphatics are less superficial than the corresponding blood-vessels. The larger tubes have two plexuses; one within, the other outside the cartilages. The smaller have only one set. The lymphatics of the bronchi are connected with those of the arteries and veins by lateral branches curving off at the divarications of the tubes; at these points there is often an accumulation of lymphoid tissue which may take the form of definite nodules. The larger arteries and veins have two accompanying lymphatics, the smaller only one. All the lymphatics tend towards the hilum, and enter lymphatic glands at the root of the lung. Those in the pleura have been said to communicate, by means of stomata between the endothelial cells of the serous membrane, with the cavity of the pleura; this is denied by Miller. The lymphatics of the pleura are abundantly furnished with valves.

Nerves.—The lung receives numerous nerves both from the vagi and sympathetic. They have small ganglia on their course, in which many of the myelinate fibres (of the vagi) end, to be continued by postganglionic fibres to the pulmonary tissues. Terminal fibres have been traced to the mucous membrane of the bronchi and to the alveoli; they are probably both afferent and efferent. Efferent fibres pass to the muscular tissue of the bronchi and blood-vessels, where they are described as ending in spindle-shaped enlargements, in close contact with the muscle-cells (Larsell, 1922).

THE PLEURA.

The **pleura,** which covers the surface of the lung, has the usual structure of a serous membrane (fig. 448). It is provided with a special network of

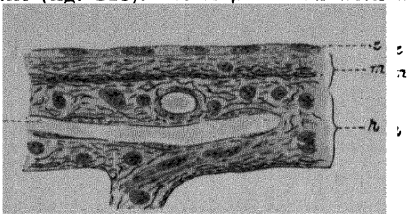

FIG. 448.—SECTION OF PLEURA : OX. (Favaro.) × 270.
e, endothelium ; *m*, substance of membrane with numerous elastic fibres ; *h*, subpleural layer ; *l*, lymph-vessel.

blood-vessels, supplied partly from the pulmonary vessels of the superficial lobules, partly from the bronchial arteries. It also has many lymphatic vessels.

DEVELOPMENT OF THE LUNG.

The lung is developed in the same manner as a secreting gland, to which up to a certain period of formation it bears a close resemblance (fig. 449). Its alveoli correspond with the secreting alveoli of a racemose gland, and the cells lining them

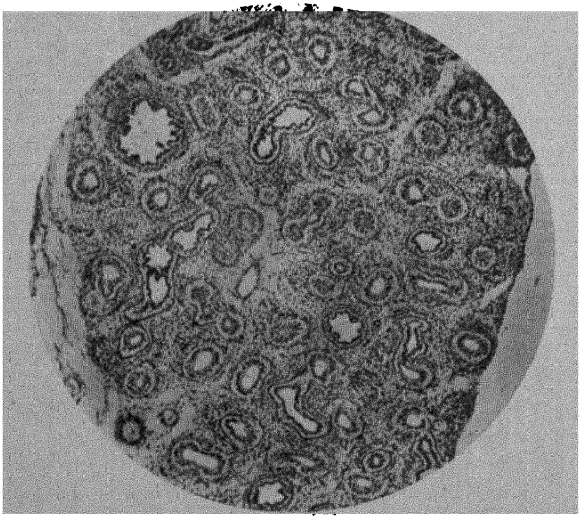

FIG. 449.—LUNG OF SIX WEEKS HUMAN EMBRYO. (H. M. Carleton.) × 45.
Preparation by W. Chesterman.

are of some thickness and of protoplasmic nature. At the time of birth the distal alveoli on the walls of the atria and infundibuli are largely undeveloped and the respiratory exchanges occur mainly in the alveoli of the respiratory bronchioles. After a time the ordinary alveoli become formed and are brought into activity, but the process is gradual and even in a child a few years old the alveoli are still proportionately less developed and more shallow than in after-life (Broman, 1927).

LESSON XXVIII.

STRUCTURE AND DEVELOPMENT OF THE TEETH.

1. STUDY first with the low power and afterwards with the high power a longitudinal section of a human tooth which has been prepared by grinding. It is better to purchase this specimen, for the process of preparation is difficult and tedious without the aid of special apparatus. Examine carefully the enamel, the dentine, and the cement. The dark appearance of the dentinal tubules and of the lacunæ in the cement is due to their containing air in the dried specimen. Measure the diameter of the enamel prisms and of some of the dentinal tubules. Make sketches from each of the tissues.

2. Section of a tooth *in situ*, which has been decalcified after fixation, and stained. In this section the mode of implantation of a tooth, as well as the structure of the pulp, can be made out. Make a general sketch under a low power, and under a high power draw a small piece of the pulp showing the processes of the odontoblasts extending into the dentinal tubules.

3. Preparations with the soft parts *in situ* can also be made without decalcification. After fixation of the soft parts and staining of tissues in bulk (this requires several days), the specimen is dehydrated with absolute alcohol and impregnated with xylol followed by Canada balsam. This is allowed to become hard, after which sections can be cut from it with a fine saw, and subsequently ground until transparent, when they are mounted in Canada balsam. This method needs special apparatus and skill.

4. The development of the teeth and the formation of their tissues are studied in sections made across the snout and lower jaw of fœtal and young animals. Either the preparations are stained in bulk or the individual sections may be stained.

TISSUES OF THE TEETH.

A **tooth** consists of three calcified tissues: *enamel*, which is of epithelial origin, *dentine*, and *cement* or *crusta petrosa*. The dentine forms the main substance of a tooth, the enamel covers the crown, and the cement is a layer of bone which invests the root (figs. 450 to 453).

Enamel is formed of elongated hexagonal *prisms* (figs. 453, 454) often with rounded angles: they are set vertically, or with a slight curvature, upon the surface of the dentine. The prisms are separated by an interprismatic substance which is also calcified. They are marked at tolerably regular intervals with slight transverse shadings producing an indistinct cross-striated appearance (fig. 454). The cross-striation appears to be due to the manner in which the calcific matter has been deposited in successive layers and is often accentuated by slight varicosities upon the prisms. Sometimes coloured lines run through the enamel across the direction of its prisms. The enamel prisms have when first laid down a fibrous structure, but this

macerated tooth prepared by grinding and mounted dry. Under these conditions the cavities are occupied by air only, for the uncalcified animal matter has been destroyed in the process of maceration. Such interglobular spaces are most common near the surface of the dentine immediately within the

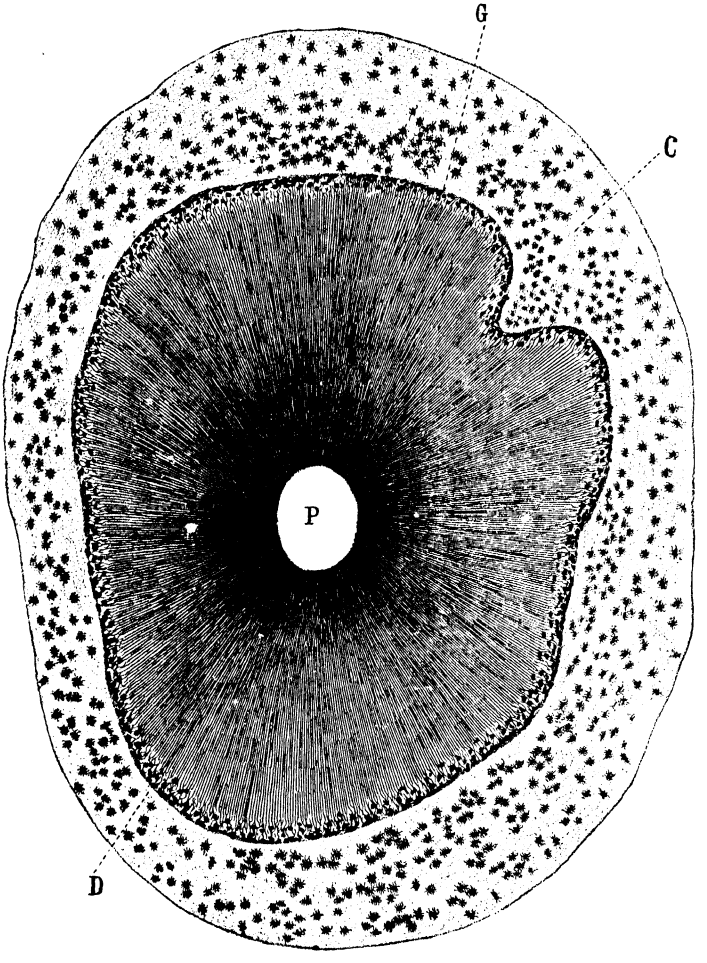

FIG. 452.—CROSS-SECTION OF ROOT OF CANINE TOOTH: HUMAN. (Sobotta.) × 25.
D, dentine; G, its granular layer; C, cement; P, pulp-cavity.

crusta petrosa, where they give a granular effect to the dry section (*granular layer*, fig. 452, G, and fig. 456, *2*). But they are also well seen in the course of certain lines or clefts traversing the dentine across the direction of the tubules, indicating stages of calcification of dentine (*incremental lines*, fig. 456; one is shown magnified in fig. 458), and such interglobular spaces, which are larger than those at the periphery of the dentine, may in the unmacerated

tooth be seen to have the dentinal tubules passing through them. After decalcification the dentine can be separated into layers along these incremental lines.

The animal matter of dentine resembles that of bone and the connective tissues generally in having its ground-substance pervaded by fibres which yield gelatine on boiling. These fibres, which have been especially investigated by v. Ebner and Howard Mummery, are difficult of demonstration in the fully calcified dentine; but in developing dentine and in dentine which is attacked by caries, they are more easily shown. They run for the most part parallel with the surface.

The **crusta petrosa** or **cement** (figs. 452, 456) is a layer of lamellated bone which covers the dentine beyond the enamel. Except in situations where it is very thin it exhibits lacunæ and canaliculi, but in normal human teeth there are no Haversian canals. The crusta petrosa is covered with periosteum (*dental periosteum*), which also lines the socket. The fibrous bundles of this periosteum extend on the one side into the crusta petrosa, on the other into the bony wall of the socket for the tooth, and thus serve to fix the tooth very securely.



FIG. 453. — SECTION THROUGH THE ENAMEL OF A TOOTH. (Rauber.) × 200.

a, projection of dentine, showing some of its tubules; *b*, penetrating into the enamel; *c*, *c*, enamel fibres cut longitudinally; *d*, *d*, prisms cut transversely; *e*, cuticle of the enamel.

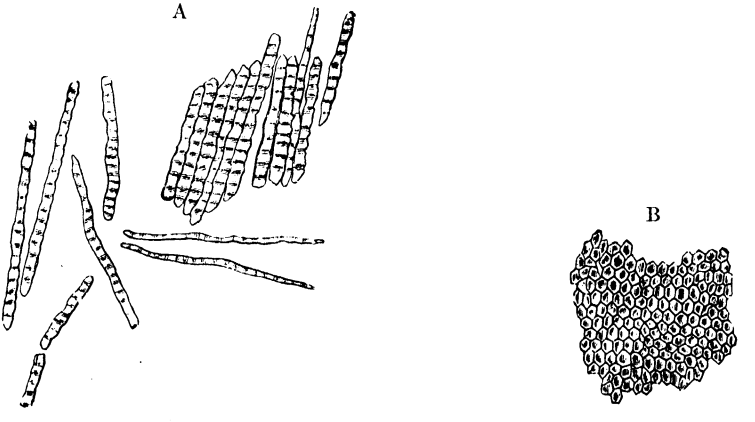

FIG. 454.—ENAMEL PRISMS. (Kölliker.) × 350.

A, Fragments and single fibres of enamel, isolated by the action of hydrochloric acid. B, Surface of a small fragment of enamel, showing the hexagonal ends of the fibres.

distance from the odontoblasts; here the axis-cylinders form an interlacement known as the *plexus of Raschkow*; from this plexus numerous fibrils pass between the odontoblasts and join another very fine plexus which lies between them and the dentine, the *marginal plexus* of Mummery. From the nerves of the pulp fibrils pass to the dentine and, as Mummery has shown, enter the dentine tubules along with the processes of the odontoblasts; they pass along the tubules as very fine beaded fibrils, to end in arborisations at the surface of the dentine beneath the enamel and cement. Here and there a fibril may even pass a certain distance between the enamel prisms.

As age advances nodules of dentine may be formed in the interior of the pulp. Such nodules sometimes surround blood-vessels, and thus give to this secondary dentine an appearance resembling bone. It has been on that account termed *osteodentine*.

DEVELOPMENT OF THE TEETH.

The development of teeth has a certain similarity to that of hairs. The first change which foreshadows their development takes the form of a continuous thickening of the epithelium along the line of the gum; this thickening grows into the corium of the mucous membrane to form the *common dental rudiment* or *lamina* (fig. 460, A). At regular intervals there is a further thickening and growth from the common rudiment into the tissue of the mucous membrane, each of these special rudiments, which are ten in number, swelling out below into a flask-shaped mass of cells, the *special dental rudiment* (fig. 460, B) of a milk-tooth. The intermediate parts of the dental lamina long remain, forming a common epithelial strand uniting the several special dental rudiments to one another, and to the epithelium covering the gum (fig. 460, C, D, *f*). A vascular *papilla* is continued from the corium into the bottom of each special rudiment (fig. 460, C, D, *p*); this papilla has the shape of the crown of the future tooth. Each special dental rudiment, with its included papilla, presently becomes almost entirely cut off from the epithelium of the mouth, and surrounded by a vascular connective-tissue membrane—the *dental sac*. The papilla becomes transformed into the dentine and pulp of the future tooth, and the enamel is deposited upon its surface by the epithelium-cells of the dental rudiment (fig. 461). The dental papilla is mesodermic in origin; the enamel organ is derived from the buccal ectoderm. The root of the tooth, with its covering of cement, is formed at a later period, when the tooth is beginning to grow up through the gum, by a gradual elongation of the base of the papilla. As shown first by O. Hertwig, there is a downgrowth of epithelium either from the lower part of the enamel rudiment, or, according to Mummery's observations, from other epithelium-cells which lie outside the enamel organ and are probably of similar origin. This downgrowth, which is termed the *epithelial sheath*, determines the form of the root and the formation of dentine in it, for it is always present where dentine is to be laid down. After completion of the dentine it becomes attenuated and broken up, and is eventually for the most part absorbed.

Formation of the enamel.—Before the enamel appears, the dental rudiment undergoes a peculiar transformation of its previously polyhedral

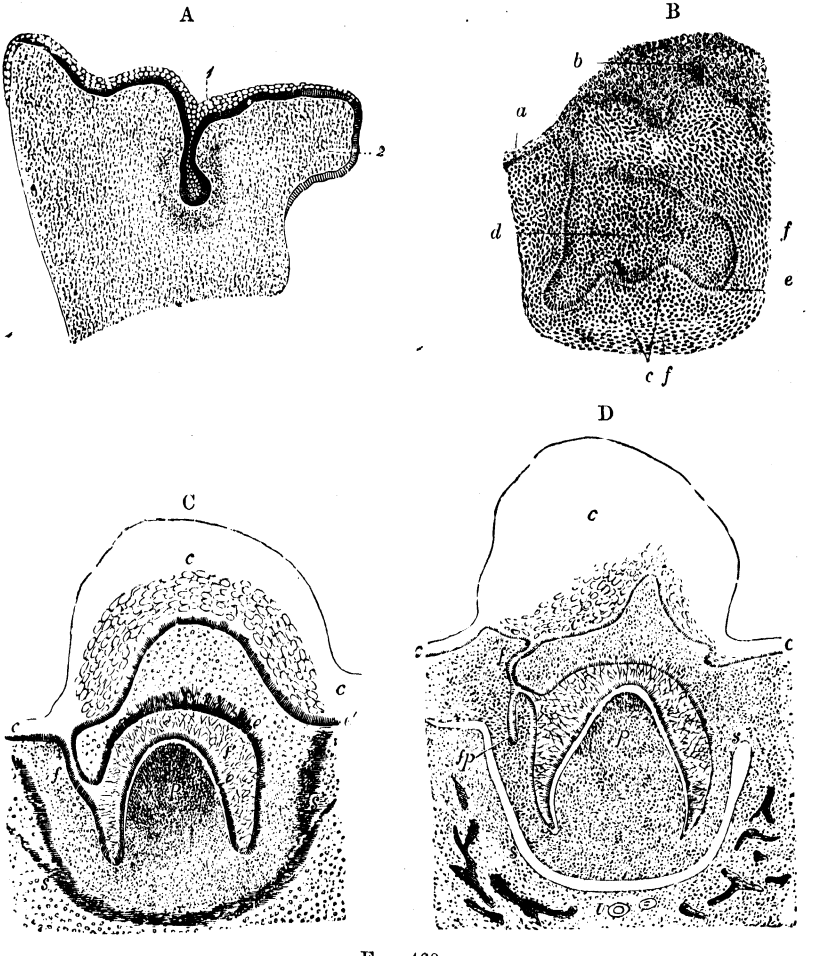

FIG. 460.

A. SECTION ACROSS THE UPPER JAW OF A FŒTAL SHEEP, 3 CM. LONG. (Waldeyer.)

1, common dental lamina dipping down into the mucous membrane where it is half surrounded by a horse-shoe-shaped more dense-looking tissue, the rudiment of the dentine and dental sac; *2*, palatine process of the maxilla.

B. SECTION FROM FŒTAL CALF SIMILAR TO THAT SHOWN IN A, BUT PASSING THROUGH ONE OF THE SPECIAL DENTAL RUDIMENTS, HERE BECOMING FLASK-SHAPED. (Röse.)

a, epithelium of mouth, thickened at *b*, above special dental rudiment; *c*, papilla; *d*, special dental rudiment; *e*, enamel epithelium; *f*, dental sac.

C AND D. SECTIONS AT LATER STAGES THAN A AND B, THE PAPILLA HAVING BECOME FORMED AND HAVING BECOME PARTLY SURROUNDED BY THE EPITHELIAL RUDIMENT. (Kölliker.)

c, epithelium of gum, sketched in outline; *f*, neck of dental rudiment; *f'*, enamel organ; *e*, its deeper columnar cells; *e'*, projections into the corium; *p*, papilla; *s*, dental sac forming. In D the dental rudiment (*fp*) of the corresponding permanent tooth is seen; *v*, blood-vessels.

epithelium-cells into four layers of modified cells (fig. 462). The innermost is a layer of columnar cells (*ameloblasts*) (fig. 462, *a*), immediately covering

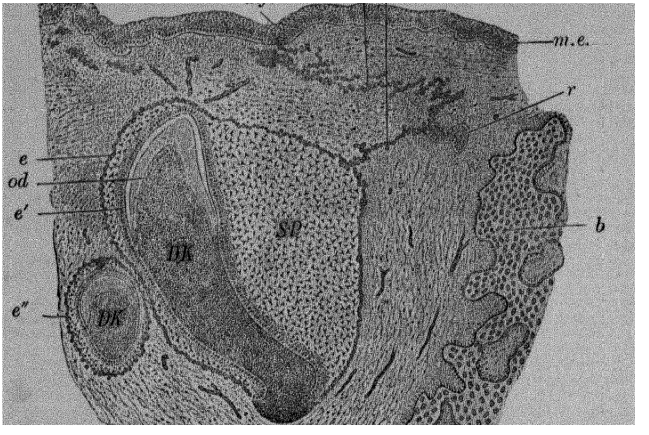

FIG. 461.—SECTION OF A DEVELOPING INCISOR TOOTH OF A HUMAN EMBRYO. (Röse.) THE SECTION ALSO INCLUDES THE RUDIMENT OF THE ADJACENT TOOTH.

DK, dental papilla; *od*, odontoblasts; *b*, bone of jaw; *e*, *e'*, outer and inner layers of enamel organ; *SP*, enamel pulp; *d.f.*, dental furrow; *c*, remains of common dental lamina; *n*, neck or bridge of cells connecting this with the enamel organ; *m.e.*, mouth-epithelium; *e''*, enamel organ of adjacent tooth rudiment; *r*, reserve rudiment of permanent tooth.

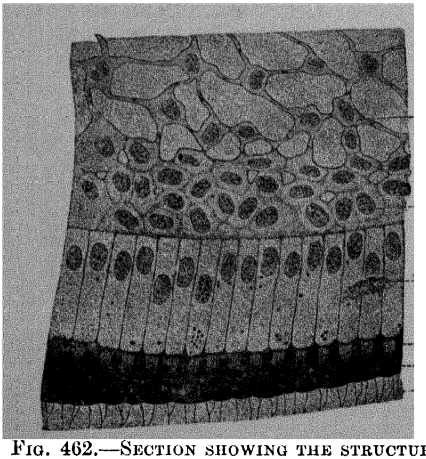

FIG. 462.—SECTION SHOWING THE STRUCTURE OF THE PART OF THE ENAMEL ORGAN WHICH LIES NEXT TO THE DENTINE. (Röse.)

d, dentine; *e*, newly formed enamel stained black by osmic acid; *T*, Tomes' processes from the ameloblasts, *a*; *str. int.*, stratum intermedium of enamel organ; *p*, branched cells of enamel pulp.



FIG. 463.—DEVELOPING ENAMEL SHOWING AMELOBLASTS AND THE FIBROUS SUBSTANCE PRODUCED BY THESE CELLS, WHICH FORMS THE BASIS OF THE ENAMEL PRISMS. (Photograph by Leon Williams.)

a, portions of the ameloblasts; *f*, fibrous basis of enamel prisms; *e*, calcified part of enamel.

the surface of the dentine. The ameloblasts form the enamel prisms: the latter are preceded by a fibrous formation (fig. 463, *f*) followed by a

deposition of calcareous salts in the form of small globules. (Such globules are always formed when lime salts are deposited in colloidal solutions.) These changes take place altogether external to the formative cells or ameloblasts; indeed according to some there is a fine homogeneous membrane between the ameloblasts and the forming enamel (*membrana preformativa* of Huxley). Processes from the ameloblasts penetrate this membrane and are attached to the forming enamel prisms (*enamel processes* of J. Tomes, fig. 462, *T*). These processes are fibrillated.

The outermost cells form a single layer of cubical or polyhedral epithelium (*external epithelium*) (fig. 461, *e*). Most of the other cells of the dental rudiment

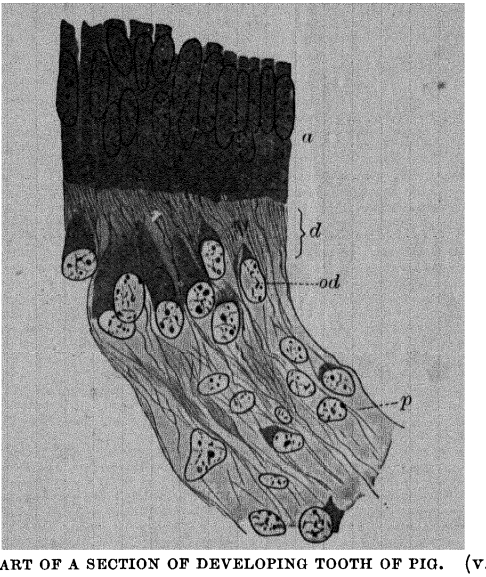

FIG. 464.—PART OF A SECTION OF DEVELOPING TOOTH OF PIG. (v. Korff.)

a, ameloblasts; *d*, fibres of the first formed layer of dentine; *od*, odontoblasts; *p*, pulp. The fibres of pulp are seen to be in continuity with those which enter into the formation of the dentine.

become transformed into branching corpuscles (fig. 461, *SP*; fig. 462, *p*) intercommunicating by their processes, and thus forming a network. But between the ameloblasts and the reticulum of branched cells of the so-called enamel pulp is a stratum of polyhedral cells (*stratum intermedium*). Both these and the cells of the external epithelium merge into the reticulum. The whole dental epithelial rudiment, thus modified, is known as the *enamel organ*. In the later stages of enamel formation the reticulum atrophies and eventually disappears.

The enamel organ contains no blood-vessels, although they are richly distributed in the developing connective tissue covering it.

Formation of dentine.—Dentine is formed at the surface of the papilla. There is here found a well-marked layer of odontoblasts (fig. 464, *od*; fig. 465, *c*). These produce a layer of fibrillated matrix which forms a cap to the papilla, and presently becomes calcified by the deposition of

globules of calcareous matter. Processes of the odontoblasts remain in the dentine as it is forming; in this way the dentine tubules originate. Most of their finer branches are formed later, as in the case of the canaliculi of bone, no doubt by an extension of their protoplasm. Such extension may even penetrate between the enamel prisms. In marsupials this occurs to an unusual extent, giving the enamel the appearance of being pervaded by tubules (Mummery). Subsequently a second layer of dentine is formed within the first by a repetition of the same process (fig. 465), and others succeed this so that the papilla gradually becomes calcified. A part, however, remains unaltered in the centre of the tooth, and with its covering of odontoblasts forms the pulp.

The ten milk-teeth are produced in each jaw in the manner described. These, however, become lost within a few years after birth, and are replaced

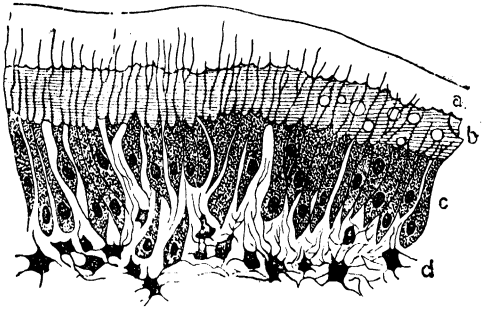

FIG. 465.—PART OF SECTION OF DEVELOPING TOOTH OF YOUNG RAT, SHOWING THE MODE OF DEPOSITION OF THE DENTINE. (E. Sharpey-Schafer.) Highly magnified.

a, outer layer of fully calcified dentine; *b*, uncalcified matrix, with a few nodules of calcareous matter; *c*, odontoblasts with processes extending into the dentine; *d*, pulp. The section is stained, the uncalcified matrix being coloured, but not the calcified part.

by permanent teeth in much the same way that a new succession of hairs occurs. A small outgrowth takes place at an early period from the dental rudiment close to each of the milk-teeth (fig. 460, D, *fp*); this eventually becomes the rudiment of the corresponding permanent tooth. It gradually enlarges, acquires a papilla, forms an enamel organ; in short, passes through the same phases of development as the rudiment of the milk-tooth; and when the milk-tooth drops out of the jaw in consequence of the absorption of its roots (by osteoclasts) the permanent tooth, the root of which now becomes developed, grows up into its place.

There are six permanent teeth in each jaw which do not succeed milk-teeth; these are the permanent molars. They are developed from an extension backwards on each side of the jaw of the original epithelial thickening or common dental rudiment and by the downgrowth from this into the corium of three successive special rudiments at comparatively long intervals of time. From these special rudiments the tissues of the permanent molars become formed in a manner exactly similar to that in which the milk-teeth are developed.

LESSON XXIX.

THE TONGUE AND THE GUSTATORY ORGANS. THE MUCOUS MEMBRANE OF THE MOUTH. THE PHARYNX AND ŒSOPHAGUS.

1. SECTIONS of the tongue (man or monkey) vertical to the surface. The sections should be taken from different parts and include all three kinds of papillæ.
2. Sections of injected tongue.
3. Sections of a papilla foliata of the rabbit; these show taste-buds *in situ*.
4. The cells composing the taste-buds are studied in teased osmic preparations of a papilla foliata. The nerve-endings are seen in sections of papillæ foliatæ which have been treated by the osmic-bichromate-silver method (see Appendix).
5. Sections of the pharynx and of the œsophagus. Susa fixation should be employed for 1 and 5.

THE TONGUE.

The **tongue** is mainly composed of cross-striated muscular fibres, running some longitudinally, others transversely. It is covered by a mucous membrane; the epithelium, like that of the rest of the mouth, is stratified, and conceals microscopic papillæ (fig. 466) like those of the skin. Besides these microscopic projections, the upper surface of the organ is beset with large papillæ, which give it a rough appearance. These, termed the *lingual papillæ*, are of three kinds: (1) About twelve or thirteen comparatively large circular projections, each of which is surrounded by a narrow groove (fossa), external to which the mucous membrane is raised above the general level (vallum). These papillæ lie in a V-shaped line with the apex of the V towards the back of the tongue; they receive filaments of the glossopharyngeal nerve, and have taste-buds in the epithelium which covers their sides, and (in man but not in most mammals) in that of the side of the vallum as well. They are known as the *papillæ vallatæ* or *circumvallate papillæ* (figs. 467, 470). (2) The remainder of the papillary surface of the tongue is covered by *conical papillæ*, so named from the conical pointed cap of epithelium which is borne by each; in man this cap is fringed with fine epithelial filaments, hence they are termed *filiform* (fig. 468). In the cat tribe the conical papillæ are claw-shaped and recurved: they are hard and horny, and in the process of licking they produce the effect of scraping. (3) Scattered here and there amongst the conical papillæ are larger papillæ, the *fungiform* (fig. 469). These are very vascular, and have a redder appearance than the rest; they lie partly embedded in little depressions of the mucous membrane. They have a certain number of taste-buds in their epithelium and receive branches from one or other of the taste-nerves.



FIG. 466.—SECTION OF MUCOUS MEMBRANE OF MOUTH, SHOWING THREE MICROSCOPIC PAPILLÆ AND STRATIFIED EPITHELIUM. THE BLOOD-VESSELS HAVE BEEN INJECTED. (Toldt.)

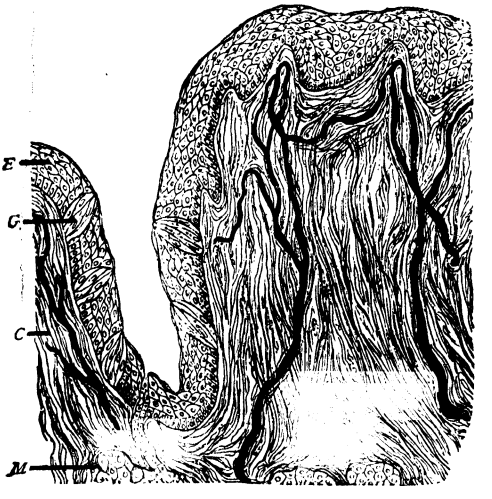

FIG. 467.—SECTION OF CIRCUMVALLATE PAPILLA HUMAN. THE FIGURE INCLUDES ONE SIDE OF THE PAPILLA AND THE ADJOINING PART OF THE VALLUM. (Heitzmann.) × 150.

, epithelium ; *G*, taste-bud ; *C*, corium with injected blood-vessels ; *M*, gland with duct.

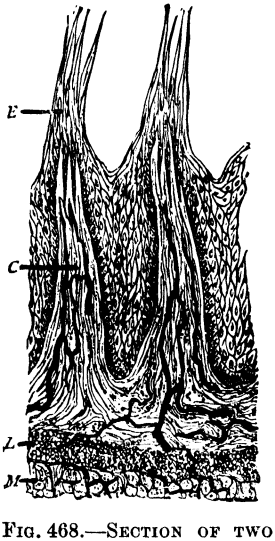

FIG. 468.—SECTION OF TWO FILIFORM PAPILLÆ: HUMAN. (Heitzmann.)

E, epithelium; *C*, corium; *L*, lymphoid tissue; *M*, muscular fibres of tongue.

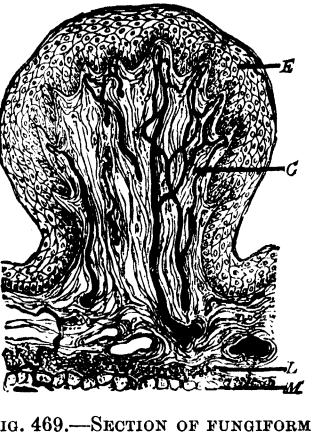

FIG. 469.—SECTION OF FUNGIFORM PAPILLA: HUMAN. (Heitzmann.) Letters as in previous figure.

Small tubulo-racemose glands (*lingual glands*) may be seen between the superficial muscular fibres sending their ducts to the surface. Most of these glands secrete mucus, but those which open into the trenches of the circumvallate papillæ, and a few others elsewhere, yield a more watery secretion containing serum albumin (*serous glands of tongue, glands of v. Ebner*).

The mucous membrane at the back of the tongue contains a large amount of lymphoid tissue, continuous with that of the tonsils (p. 261) and having a similar arrangement and structure.

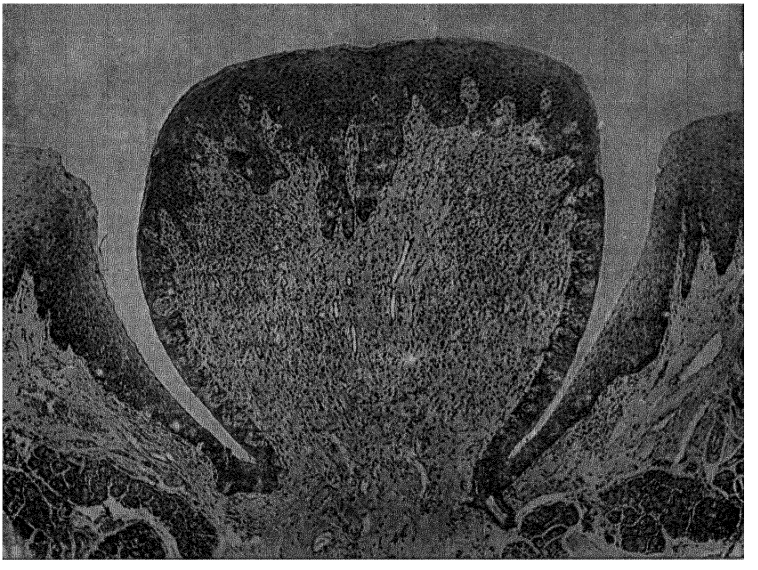

FIG. 470.—SECTION OF CIRCUMVALLATE PAPILLA OF MONKEY. (E. Sharpey-Schafer.) × 50. Photograph.

Notice the irregularly papillated, flat surface of the papilla: the deep trench surrounding it: the taste-buds in the epithelium at the sides of the papilla, but none on the opposite side of the trench: the serous glands below it (the duct of one of these is seen opening into the bottom of the trench).

TASTE-BUDS.

The minute gustatory organs, known as *taste-buds* or *taste-bulbs*, may be seen in sections which pass through the papillæ vallatæ or the papillæ fungiformes; they are also present here and there in the epithelium of the general mucous membrane of the tongue, especially at the back and sides; some are found upon the under surface of the soft palate, on the gums, and on the anterior and posterior surfaces of the epiglottis. But they are most easily studied in the *papillæ foliatæ* of the rabbit (fig. 471), two small oval areas lying on each side of the back of the tongue, and marked transversely with a number of ridges or laminæ with intervening trenches. Sections across the laminæ show numerous taste-buds embedded in the thick epithelium which clothes their sides (fig. 472).

The taste-buds are ovoid clusters of epithelium-cells which lie in cavities

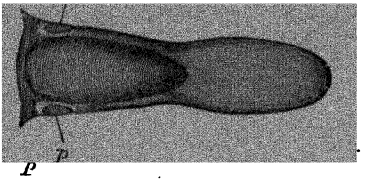

FIG. 471.—TONGUE OF RABBIT, SHOWING THE SITUATION OF PAPILLÆ FOLIATÆ, *p*, *p*. (E. Sharpey-Schafer.)

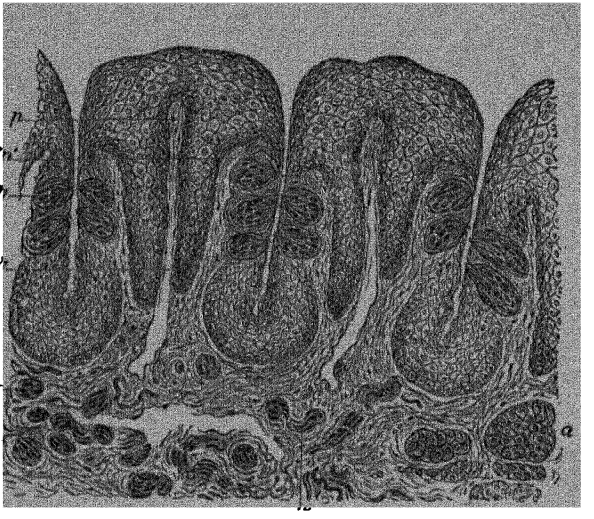

FIG. 472.—VERTICAL SECTION OF PAPILLA FOLIATA OF THE RABBIT, PASSING ACROSS THE LAMINÆ. (Ranvier.)

p, central lamina formed of corium; *v*, section of a vein, which traverses the lamina; *p'*, lateral lamina in which the nerve-fibres run; *g*, taste-bud; *n*, sections of nerve-bundles; *a*, serous gland.

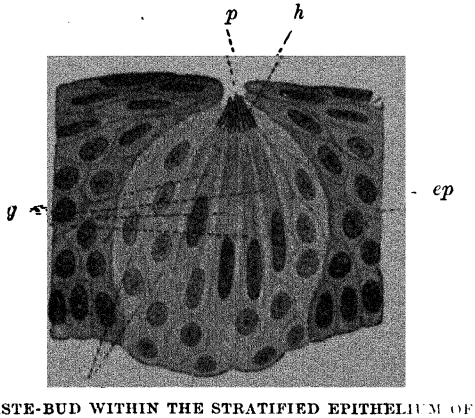

FIG. 473.—A TASTE-BUD WITHIN THE STRATIFIED EPITHELIUM OF THE TONGUE. (Sobotta.) × 500.

g, gustatory cells; *s*, sustentacular cells; *ep*, epithelium; *p*, gustatory pore; *h*, hairlets.

in the stratified epithelium (fig. 473). The base of the taste-bud rests upon the corium of the mucous membrane, and receives a branch of the glosso-



FIG. 474.—VARIOUS CELLS FROM TASTE-BUD OF RABBIT. (Engelmann.) × 600.

a, four gustatory cells from central part; *b*, one sustentacular cell, and two gustatory cells, in connexion; *c*, three sustentacular cells.

pharyngeal nerve; the apex is narrow and communicates with the cavity of the mouth by a small pore in the superficial epithelium (*gustatory pore*, fig. 473, *p*).

The cells which compose the taste-bud are of two kinds, viz.: (1) The *gustatory cells* (fig. 474, *a*). These are long delicate bipolar cells, tapering towards both ends. Each is composed of cell-body or nucleated enlargement and of two processes, one distal, the other proximal. Of these the distal is nearly straight, and passes towards the apex of the taste-bud, where it terminates in a small, highly refracting cilium-like appendage (*taste-hairlet*), which projects into the gustatory pore above mentioned; the cell-body does not itself quite reach the pore. The proximal process is more delicate than the other, and is often branched and varicose. The nerve-fibres to the taste-bud (fig. 475) terminate in ramifications amongst these cells (G. Retzius). (2) The *sustentacular cells* (fig. 474, *c*). These are elongated cells, mostly flattened, and pointed at their ends; they lie between the gustatory cells, which they thus appear to support, and in addition they form a sort of envelope or covering to the taste-bud. Between the cells of the taste-bud leucocytes are often seen, having probably wandered hither from the adjacent mucous membrane. Connective-tissue fibrils penetrate between the taste-bud and the stratified epithelium in which it is embedded (Drasch).

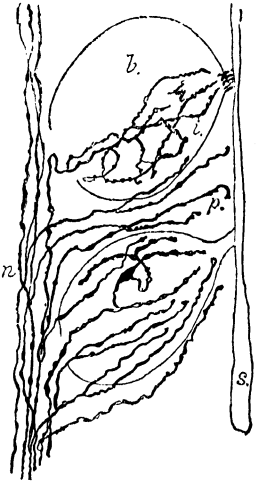

FIG. 475.—NERVE-ENDINGS IN TASTE-BUDS. (G. Retzius.)

n, nerve-fibres; *b*, taste-buds in outline; *i*, ending of fibrils within taste-bud; *p*, ending in epithelium between taste-buds; *s*, sulcus of papilla foliata into which the gustatory pores open.

MOUTH, PHARYNX, AND ŒSOPHAGUS.

The **mucous membrane of the mouth** is lined by a stratified epithelium (fig. 476) into which vascular papillæ, and, in some parts, papillæ containing end-bulbs, project. The corium is formed of connective tissue and contains within and beneath it a large number of small secretory glands (*buccal glands*). Most of these secrete mucus, but some are of the mixed type (see under Salivary Glands in next Lesson): this is the case, for example, with the glands of the lips. The ducts of the buccal glands open everywhere upon the surface of the membrane. The large ducts belonging to the salivary glands also open into the mouth.

The **pharynx** is composed of a *fibrous membrane* which is encircled by striated muscles (the *constrictors*), and lined by *mucous membrane* with which

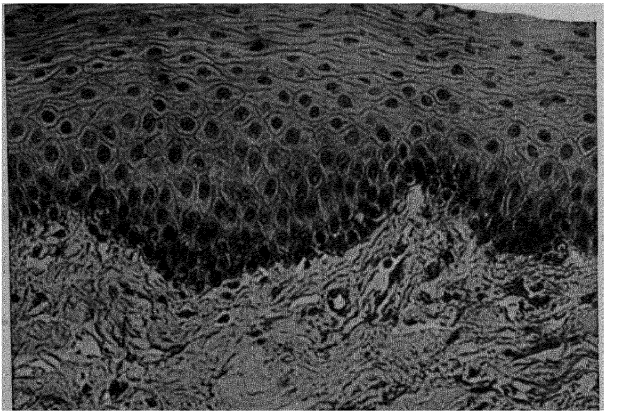

FIG. 476.—SECTION OF THE STRATIFIED EPITHELIUM OF THE FAUCES OF THE RABBIT × 240. Photograph.

the fibrous membrane is connected by areolar tissue. The mucous membrane is covered on its inner surface in the upper part of the pharynx with ciliated epithelium; this is continuous above and in front with that of the nostrils, and through the Eustachian tube with that of the tympanum. Below the level of the soft palate the epithelium is stratified, like that of the mouth and gullet into which it passes. In certain parts the mucous membrane contains a large amount of lymphoid tissue, and everywhere numerous mucous glands open on its surface.

The **œsophagus** or **gullet**, which passes from the pharynx to the stomach, consists of an outer *connective-tissue covering*, a *muscular coat*, a lining *mucous membrane*, and intervening connective tissue forming the *submucous areolar coat* (fig. 477). The muscular coat is composed of striated muscle in about its upper third only, in the middle third this gradually gives place to non-striated: at the lower end the latter only occurs. There are two layers of

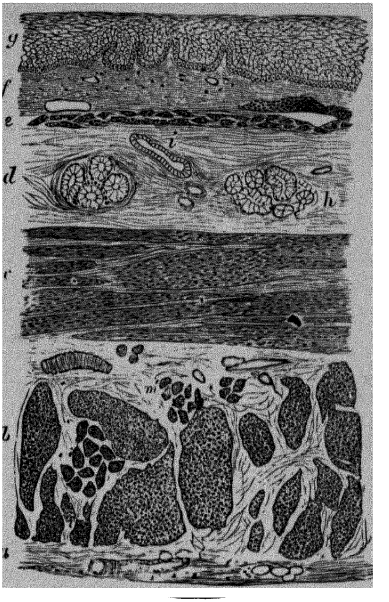

FIG. 477.—SECTION OF HUMAN ŒSOPHAGUS. (Drawn by Victor Horsley.)

The section is transverse, and from near the middle of the gullet. *a*, fibrous covering; *b*, cross-section of bundles of plain muscle belonging to the longitudinal muscular layer; *c*, bundles of plain muscle of the circular muscular layer; *d*, submucous or areolar layer; *e*, muscularis mucosæ; *f*, mucous membrane with papillæ; *g*, stratified epithelium; *h*, mucous gland; *i*, gland duct; *m'*, striated muscular fibres cut across.

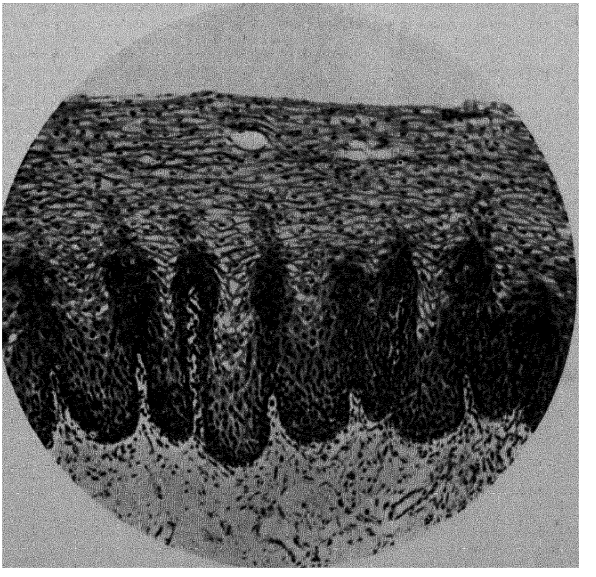

FIG. 478.—SECTION OF HUMAN ŒSOPHAGUS SHOWING THE STRATIFIED EPITHELIUM WITH PAPILLÆ EXTENDING INTO IT FROM THE CORIUM. (E. Sharpey-Schafer.) × 80. Photograph.

the muscular coat—an outer layer, in which the bundles of fibres run longitudinally, and an inner, in which they have a circular arrangement. The mucous membrane is lined by a stratified epithelium, into which papillæ from the corium project (fig. 478). The corium is formed of areolar tissue ; its limits are marked externally by a narrow layer of longitudinally disposed plain muscular fibres, the *muscularis mucosæ*. This is separated from the proper muscular coat by the areolar coat, which contains the larger branches of the blood-vessels and lymphatics, and also the mucous glands of the membrane. The ducts of these glands are large and, before passing through the epithelium covering the surface, they are usually surrounded by an accumulation of lymphoid tissue. Lymph-cells from this infiltrate the epithelium of the duct and pass out into its lumen.

Besides the mucous glands, there are met with in some mammals (including man) both at the upper or pharyngeal part of the œsophagus and at the lower or gastric end a certain number of small tubulo-racemose glands of a different character. They are confined to the mucous membrane, not penetrating the muscularis mucosæ, and their ducts open upon and not between the papillæ of the mucous membrane. They closely resemble the tubulo-racemose cardiac glands of the stomach (see fig. 498, p. 367), and it is usually found that the epithelium of the surface in the immediate neighbourhood of their ducts is similar to that lining the stomach.

There are two gangliated nerve-plexuses in the œsophagus, one in the muscular coat and one in the submucous coat ; they resemble in position and structure those of the intestine (p. 376).

LESSON XXX.

THE SALIVARY GLANDS.

1. SECTION of submaxillary gland. The gland may be hardened in alcohol or 10 per cent. neutral formol followed by alcohol and stained with hæmatoxylin-eosin, with iron-hæmatoxylin or with alcoholic eosin and methylene-blue. Notice acini filled with clear (mucus-secreting) cells, the nuclei of which usually lie near the basement-membrane and, in the human submaxillary, other acini lined entirely with granular cells. Notice here and there, outside the clear cells, semilunes or crescents of small darkly stained granular-looking cells. Observe also the sections of the ducts with their striated columnar epithelium. If possible find a place where one of the ducts is passing into alveoli. Sketch under a high power.

2. Sections of parotid and sublingual glands prepared in a similar way. Notice the differences between the three glands.

3. Small pieces of both submaxillary and parotid gland of the dog or cat may be examined fresh in 2 per cent. salt solution. In the submaxillary gland notice that the alveolar cells are swollen out with large granules or droplets of mucigen, which swell up in water to form large clear vacuoles. Dilute acids and alkalies produce a similar change more rapidly. The cells of the parotid gland are also filled with granules, but they are smaller. Their granules swell and dissolve with dilute acids and alkalies. Make a sketch from each preparation under a high power.

The granules are not seen in preparations fixed in alcohol, but osmic acid preserves them; they are well seen in sections from picric acid fixed glands.

4. To study the changes which the alveolar cells undergo during secretion, pilocarpine is administered to an animal in sufficient amount to produce copious salivation; after half an hour the animal is killed and its salivary glands are examined as in § 3.

The salivary glands may be looked upon as typical of secreting glands in general. They are composed of a number of *lobules* bound together loosely by connective tissue. Each small lobule is formed of a group of irregularly saccular or tubular *alveoli* from which a small duct passes, and this unites with others to form larger ducts. A main duct eventually leaves the gland to open upon the inside of the mouth.

The alveoli are enclosed by a basement-membrane, which has flattened branched cells on its inner surface, next to the epithelium (fig. 479). The nature of these cells is not clear, but it is possible that they are plain muscle-cells and thus capable of contraction upon the contents of the alveolus, like those met with in the mammary gland and in sweat glands. The basement-membrane may be shown by teasing the fresh gland substance in water (Langley). This membrane is continued along the ducts. Within it is the epithelium, which in the alveoli is composed of polyhedral cells, looking wedge-shaped in section (fig. 480, *a*), but in the ducts is regularly columnar,

except in that part of the duct which immediately opens into the alveoli (*junctional part*); in this it is flattened (*d'*). The columnar epithelium of

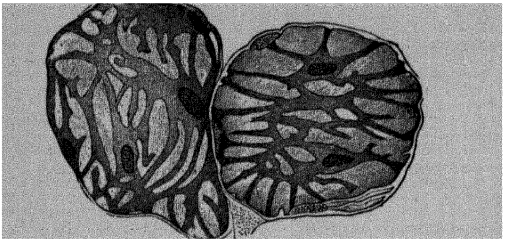

FIG. 479.—MEMBRANA PROPRIA OF TWO ALVEOLI WITH BRANCHED CELLS LYING IMMEDIATELY WITHIN IT. (V. EBNER.) × 600.

The preparation was from a mucous gland of the rabbit.

the ducts is peculiar, in that the cells are not sharply marked off from one another and show a distinction into two unequal zones, an outer, larger zone, with mitochondria arranged in a striated manner perpendicular to the basement-membrane, and an inner, smaller one with distinct secretion-

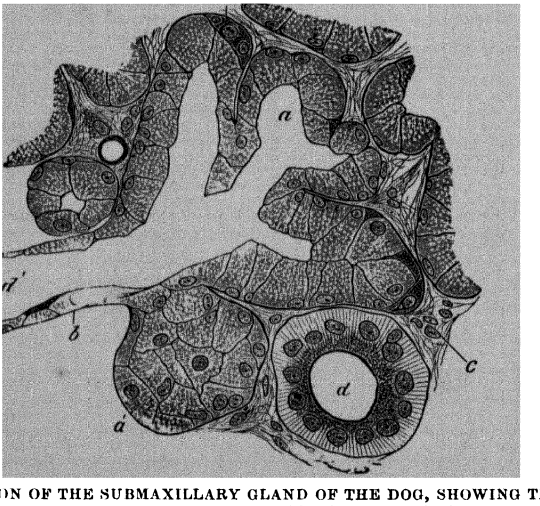

FIG. 480.—SECTION OF THE SUBMAXILLARY GLAND OF THE DOG, SHOWING THE COMMENCEMENT OF A DUCT IN THE ALVEOLI. (E. Sharpey-Schafer.) × 425.

a, one of the alveoli, several of which are in the section shown grouped around the commencement of the duct, *d'*; *a'*, an alveolus, not opened by the section; *b*, basement-membrane in section; *c*, interstitial connective tissue of the gland; *d*, section of a duct which has passed away from the alveoli, and is now lined with characteristically striated columnar cells; *s*, crescentic group of darkly stained cells at the periphery of an alveolus.

granules (fig. 480, *d*, and fig. 486). The larger ducts are lined by clear cubical or short columnar epithelium, which may show more than one layer of cells.

The cells of the alveoli differ according to the substance they secrete. In alveoli which secrete mucus, such as those of most of the smaller glands which open on the mucous membrane of the mouth, and contribute to the

production of saliva (fig. 481), and some of the alveoli of the submaxillary and sublingual glands, the cells, if examined in normal saline solution or after hardening with alcohol, are clear and swollen. But if examined rapidly

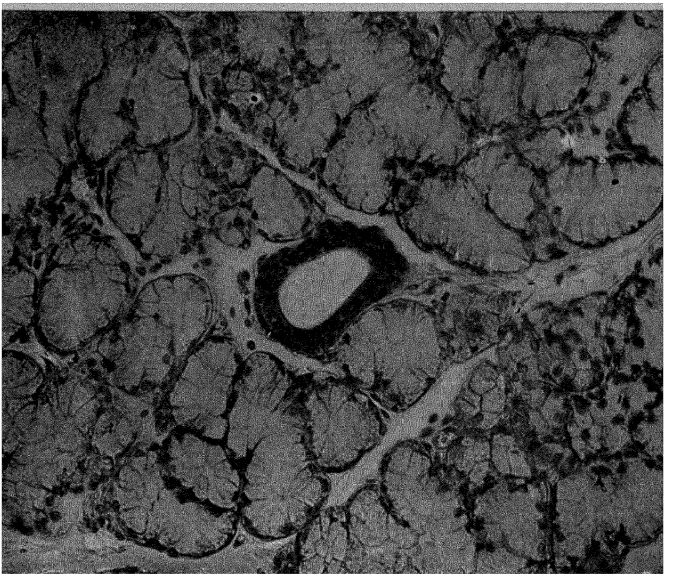

FIG. 481.—MUCOUS SALIVARY GLAND (ONE OF THE SMALL GLANDS OF THE BUCCAL MUCOUS MEMBRANE.) (E. Sharpey-Schafer.) × 200. Photograph.
In the middle of the figure is seen the section of a duct.

in serum, or in solutions of salt of from 2 to 5 per cent., they are often seen to be occupied by large and distinct globules (fig. 482, *a*, *b*) (Langley) which become swollen up under the influence of dilute acid (*a'*, *b'*). These globules

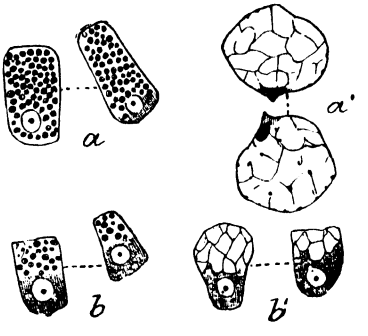

FIG. 482.—MUCOUS CELLS FROM FRESH SUBMAXILLARY GLANDS OF THE DOG. (Langley.)
a, from a resting or loaded gland; *b*, from a gland which has been secreting for some time; *a'*, *b'*, similar cells which have been treated with dilute acid.

can be rendered visible by certain methods of staining. In many cells the

globules appear blended into a clear substance (*mucigen*) which distends the cell. When the gland is stimulated to activity the mucigen is dissolved out and discharged as *mucin* into the lumen of the alveolus and into the ducts.

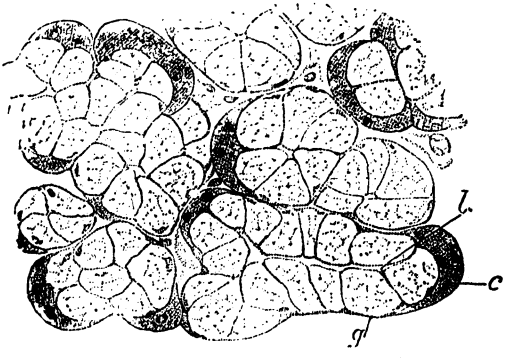

FIG. 483.—SUBMAXILLARY (DOG) AFTER A PROLONGED PERIOD OF INACTIVITY. (Ranvier.)
l, lumen of alveolus; *g*, mucus-secreting cells; *c*, crescent.

After such discharge, the cells, instead of having a clear appearance, look finely granular, and are much smaller; they also stain more deeply with hæmatoxylin (compare figs. 483 and 484). These cells are the *mucous cells*. In many mucous alveoli certain of the cells do not contain mucigen, but small albuminous granules or globules; these cells often form crescentic

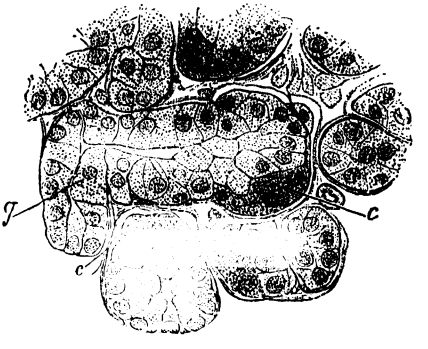

FIG. 484.—SUBMAXILLARY (DOG) AFTER A PERIOD OF ACTIVITY. (Ranvier.)
The mucus-secreting cells, *g*, have discharged their secretion, and are smaller and stain better; the cells of the crescents, *c*, are enlarged.

groups which lie next to the basement-membrane (figs. 483, *c*, and 485). These groups are the so-called *crescents of Gianuzzi*; their constituent-cells are known as *marginal* or *serous cells*. Special diverticula pass from the lumen of the alveoli between the mucous cells to penetrate to the crescents and to branch amongst and within their constituent-cells; these diverticula are shown by the Golgi method of staining (figs. 488, 494). The cells of the crescents are generally regarded as being serous both in type

and in secretion. Some authors, however, consider that they are concerned in the formation of mucin, although not themselves true mucous cells.



FIG. 485.—HUMAN SUBLINGUAL. (E. Sharpey-Schafer.) Preparation by M. Heidenhain. × 200. Photograph.

Most of the alveoli shown in the figure are serous, but some are mixed, containing chiefly mucous cells but also crescentic groups of serous cells.

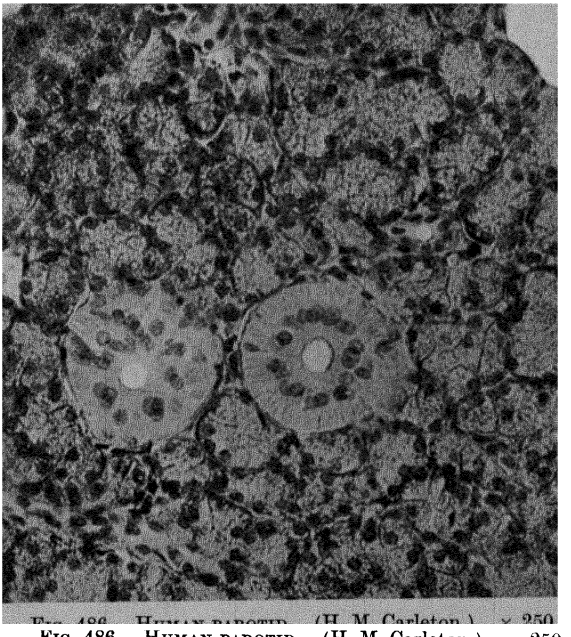

FIG. 486.—HUMAN PAROTID. (H. M. Carleton.) × 250.

The serous cells are characteristic of purely *serous alveoli* (fig. 486), in which none of the cells secrete mucus. In these, when the gland has been

long at rest, the cells are filled with apparent granules, which do not swell with water nor form mucin; they appear to consist of protein, and pro-

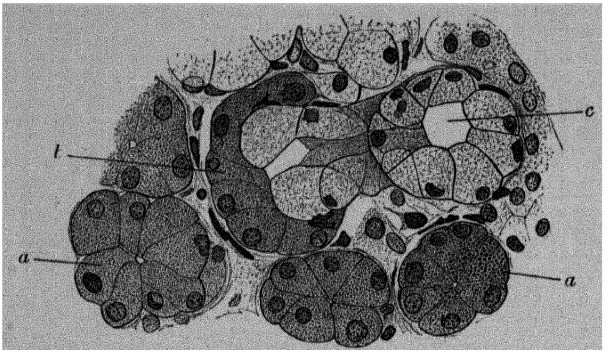

FIG. 487. HUMAN SUBMAXILLARY. (Kölliker.) × 500.

a, *a*, serous alveoli; *b*, a crescent of Gianuzzi surrounding mucous cells; *c*, lumen of a mucous alveolus.

bably yield to the secretion of the gland its ferment (ptyalin) and its albumin. The granular substance within the cell is not the ferment, but the ferment is formed from it when the secretion is poured out. Hence it has been termed *zymogen* (mother of ferment). As Langley showed, the outer part of each cell becomes clear and free from granules after secretion (fig. 489). When the gland is stimulated naturally the change is found to occur in certain cells and not in others.

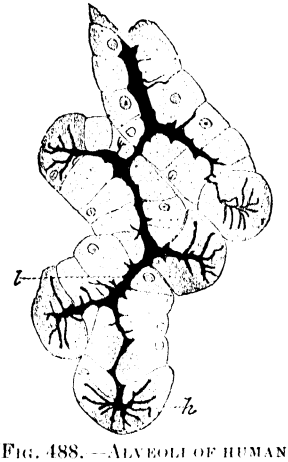

FIG. 488. — ALVEOLI OF HUMAN SUBLINGUAL GLAND PREPARED BY GOLGI METHOD. (E. Müller.)

l, lumen stained, with lateral diverticula passing between and into mucus-secreting cells; *b*, longer diverticula penetrating into the 'crescent' cells.

Serous cells of a special type have been described by Bensley and others in some mammals (*e.g.* rabbit). These cells, which are found amongst ordinary serous cells, contain much larger granules or globules (fig. 490). Their significance is unknown.

The cells lining the ducts of the ordinary glands are also occupied by granules which are found to alter in number and size with varying states of secretion (fig. 491).

The parotid glands are composed in nearly all mammals of serous alveoli only. In man, however, a few mucous alveoli are found around the main duct (Stormont).

The submaxillary gland in man and most mammals is mixed (fig. 492): both serous and mucous alveoli (the latter having crescents) are present, although serous alveoli preponderate. In the guinea-pig the alveoli of the submaxillary are all of the serous type.

The human sublingual gland is likewise mixed, but mucous alveoli are the more numerous: many of these show crescents at their margins.

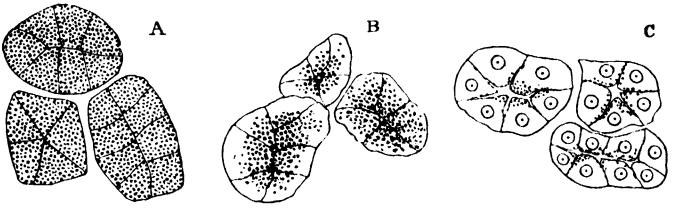

FIG. 489.—ALVEOLI OF A SEROUS GLAND. A, AT REST. B, AFTER A SHORT PERIOD OF ACTIVITY. C, AFTER A PROLONGED PERIOD OF ACTIVITY. (Langley.)

In A and B the nuclei are obscured by the granules of zymogen.

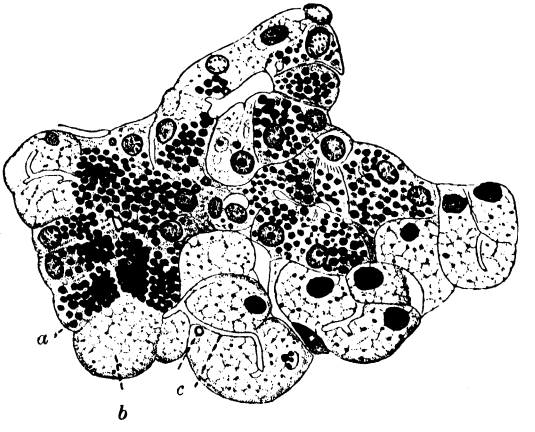

FIG. 490.—SUBMAXILLARY GLAND OF RABBIT. (E. Müller.)

The cells, which are all serous, are in different functional states, as indicated by the condition and staining of the granules. *a*, cell filled with darkly stained granules; *b*, clear cell; *c*, secretory canaliculi penetrating into the cells.



FIG. 491.—CELLS FROM DUCT OF PAROTID.

A, prior to secretion; B, after secretion. (Mislawski and Smirnow.)

When the glands are unravelled and examined with the microscope it is found that the mucous and serous alveoli are somewhat different in shape,

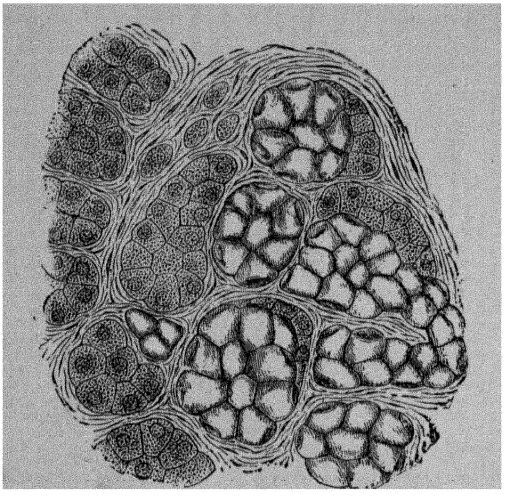

FIG. 492.—PART OF THE HUMAN SUBMAXILLARY GLAND. (R. Heidenhain.)
To the right of the figure is a group of mucous and mixed alveoli; to the left a group of serous alveoli.

the mucous alveoli being larger, more uniform in shape, and linked on to the ducts by shorter and wider intermediate or junctional portions (compare

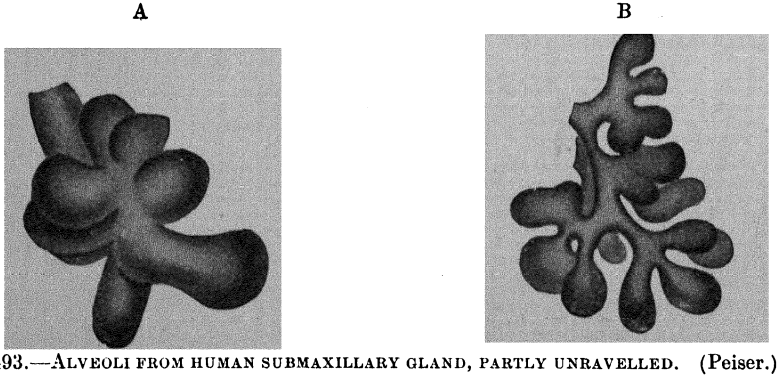

FIG. 493.—ALVEOLI FROM HUMAN SUBMAXILLARY GLAND, PARTLY UNRAVELLED. (Peiser.)
A, from a 'mucous' portion; B, from a 'serous' portion of the gland.

fig. 493, A, which is from a mucous part of the human submaxillary, with fig. 493, B, from a serous part).

The largest ducts have a wall of connective tissue outside the basement-membrane, and also a few plain muscle-cells. They are lined for some distance from their orifice in the mouth by a continuation of the stratified epithelium of the buccal mucous membrane.

The blood-vessels of the gland form a capillary network around each alveolus. The lymphatics commence in the form of lacunar vessels in the areolar tissue between the alveoli. Lymph-nodules are occasionally found in the interstitial connective tissue. The nerves of the gland are derived both from cerebro-spinal nerves and sympathetic; the former pass through

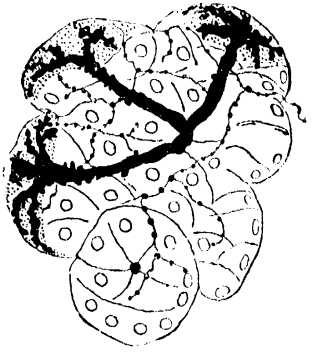

FIG. 494.—ALVEOLI OF THE SUBMAXILLARY GLAND OF THE DOG. (G. Retzius.) Golgi method.

The extensions of the lumen into the crescents of Gianuzzi are shown, and also the endings of nerve-fibrils amongst the cells of the alveoli.

ganglia before proceeding to their distribution. They ramify as fine varicose fibrils amongst the alveolar cells (fig. 494); many are distributed to the blood-vessels.

DEVELOPMENT

The salivary glands are developed as buds from the epithelium of the bucca cavity, at first solid but gradually becoming hollowed out. To begin with they are simple, but undergo ramification as they extend into the mucous membrane and submucous tissue.

LESSON XXXI.

THE STOMACH.

1. VERTICAL longitudinal sections through the cardia, including the lower end of the œsophagus and the adjacent cardiac portion of the stomach. These are intended to show the abrupt transition of the stratified epithelium of the œsophagus into the columnar epithelium of the stomach, and also the character of the gastric and œsophageal glands in the immediate neighbourhood of the cardia.

2. Sections of the fundus of the stomach cut perpendicularly to the surface of the mucous membrane.

In these sections the general arrangement of the coats of the stomach is studied. Sketches are to be made under a low power illustrating this arrangement, and under a high power showing the structure of the glands.

Measure the whole thickness of the mucous membrane, the thickness of the muscular coat, the size of the columnar epithelium-cells of the surface, and that of the cells in the deeper parts of the glands.

3. Sections of the mucous membrane of the fundus, cut parallel to the surface. These will show better than the others the arrangement of the cells in the glands.

4. Vertical sections of the mucous membrane from the pyloric region of the stomach. In a section taken longitudinally through the pylorus, the transition of the gastric glands into the glands of Brünner of the duodenum will be manifest. Make a sketch under a low power of one of the pyloric glands in its whole length, filling up some of the details with the high power.

For 1, 2, 3 and 4 the tissue is fixed with 10 per cent. formol, or with susa.

5. The arrangement of the blood-vessels is studied in sections of the wall of a stomach the vessels of which have been injected.

The wall of the **stomach** consists of four coats, which, enumerated from without in, are as follows, viz. : *serous*, *muscular*, *areolar* or *submucous*, and *mucous* (fig. 495).

The *serous coat* is a layer derived from the peritoneum. It is deficient along the lines of the lesser and greater curvatures.

The *muscular coat* consists of three layers of plain muscular fibres arranged in bundles: those of the outer layer running longitudinally, those of the middle layer circularly, and those of the inner layer obliquely. The longitudinal and circular bundles become thicker and stronger towards the pylorus; at the pylorus itself the circular layer is greatly thickened to form a sphincter muscle. The oblique fibres are best developed at the cardia where they form a sling-like bundle partially embracing that aperture (McSwiney). As the bundles of oblique fibres are traced forwards they become thinner and, curving downwards, blend with the circular fibres of the middle layer. There is a gangliated nerve-plexus between the longitudinal and circular layers of muscle, corresponding with the plexus of Auerbach of the intestine (p. 377).

The *areolar* or *submucous coat* is a layer of areolar tissue, serving to unite

the mucous membrane loosely to the muscular coat; in it ramify the larger branches of the blood-vessels and lymphatics.

The submucous coat contains a gangliated nerve-plexus, similar to and corresponding with the plexus of Meissner of the intestine.

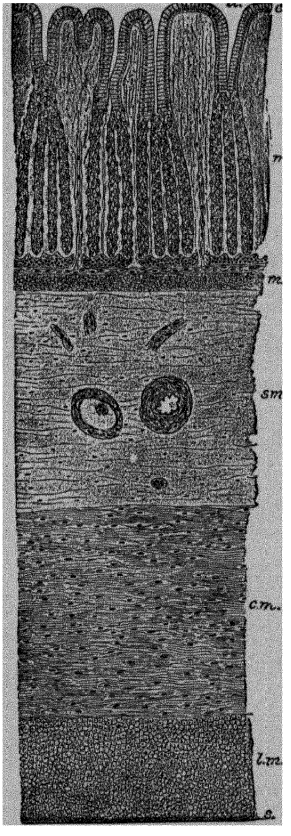

FIG. 495.—DIAGRAM OF SECTION THROUGH THE COATS OF THE STOMACH. (F. Mall.)

m, mucous membrane; *e*, epithelium; *d*, orifice of gland duct; *m.m.*, muscularis mucosæ; *sm.*, submucosa; *c.m.*, circular muscular layer; *l.m.*, longitudinal muscular layer; *s*, serous coat.

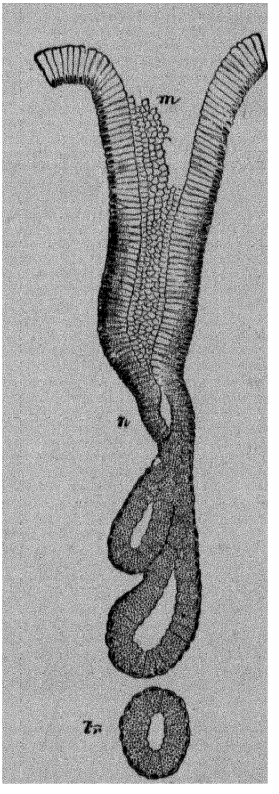

FIG. 496.—A SINGLE GLAND SEEN IN LONGITUDINAL SECTION: FROM THE PYLORIC REGION. (Ebstein.)

m, mouth or duct of gland; *n*, neck; below this two secreting tubules; *tr.*, transverse section of a secreting tubule.

The *mucous membrane* is in man a soft thick layer, generally corrugated in the empty condition of the organ. Its inner surface is covered by columnar cells, all of which secrete mucus. This can be seen, after special staining methods, as a cloud of globules at the free end of the cell. The cells also contain two groups of filamentous mitochondria—one at the free, the other at the attached, pole of the cells. There is also a Golgi-apparatus lying close to, or around, the nucleus.

The columnar surface-cells are prolonged into the ducts of the glands (fig. 496), but when these divide to form the tubules the cells become shorter, and lose their mucus-secreting character, although an occasional cell of the same character may be seen lower down. On the other hand, both oxyntic and central cells (see below) are sometimes seen between the columnar epithelium-cells of the ducts. Where the œsophagus passes into the stomach the stratified epithelium lining the gullet gives place abruptly to the columnar epithelium of the stomach (fig. 497).

In some animals (*e.g.* rat) the stratified epithelium of the œsophagus is continued over a more or less extensive tract of the gastric mucous membrane, but always ends by a similar sharply defined line.

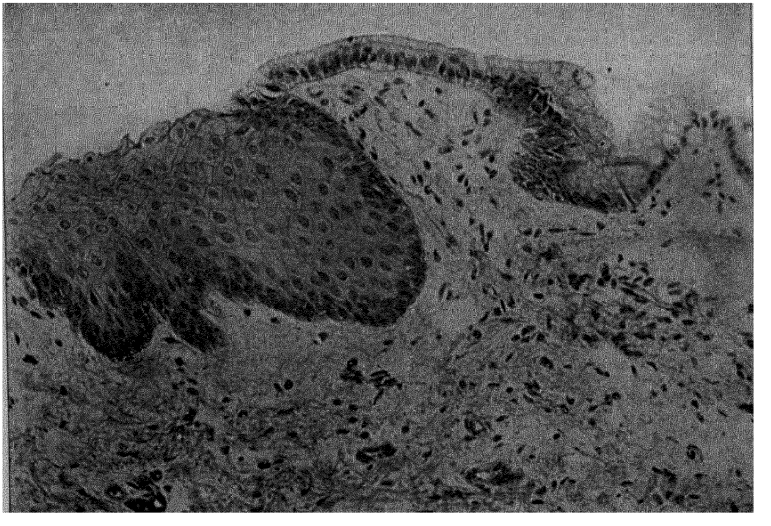

FIG. 497.—SECTION OF THE WALL OF THE STOMACH OF THE DOG AT THE PLACE WHERE THE STRATIFIED EPITHELIUM OF THE ŒSOPHAGUS IS CONTINUED INTO THE COLUMNAR EPITHELIUM OF THE GASTRIC MUCOUS MEMBRANE. (E. Sharpey-Schafer). × 200. Photograph.

The thickness of the gastric mucous membrane is due to the fact that it is largely made up of tubular glands opening upon the inner surface; but, as in all hollow viscera, the thickness or thinness depends to a large extent upon the state of distension. Between the glands the mucous membrane is formed of reticular tissue with many leucocytes and basiphil connective-tissue cells in its meshes. Externally the mucous membrane is bounded by the *muscularis mucosæ*, consisting of an outer longitudinal and an inner circular layer of plain muscular fibres. The inner layer sends strands of muscle towards the surface between the glands.

Gastric glands.—These are formed of a basement-membrane lined with epithelium. Each gland consists of *secreting tubules*, from one to four in

number, opening at the surface into a larger tube, the *duct* of the gland. The duct is in all cases lined by mucus-secreting epithelium of the same character as that which covers the inner surface of the mucous membrane, but the epithelium of the secreting tubules is different from this, and also differs somewhat in the glands of different regions of the organ. The following varieties of gastric glands are met with :—

(1) *Glands of the cardia.*—These are comparatively few in number. They are usually found only close to the œsophageal opening (cardia) and are of two kinds : (*a*) simple tubules, similar in their general structure to the

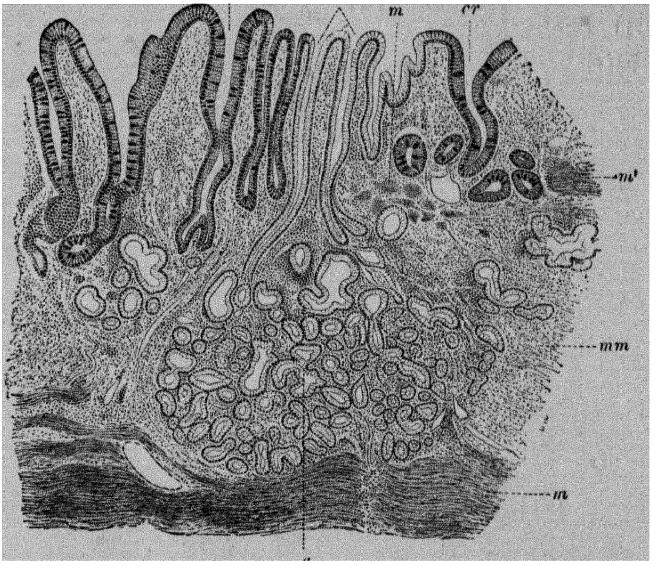

FIG. 498.—GLANDS OF HUMAN STOMACH NEAR THE CARDIAC. (J. Schaffer.) × 45.

c, cardiac glands ; *d*, their ducts ; *cr*, glands similar to crypts of Lieberkühn, with goblet-cells ; *mm*, mucous membrane ; *m*, muscularis mucosæ ; *m'*, muscular tissue within mucous membrane.

crypts of Lieberkühn of the intestine, and (*b*) small tubulo-racemose glands (fig. 498). The latter are commonest in man ; the former occur in considerable number in certain animals. The secreting tubules of the racemose glands are lined by cells which are granular in appearance and of a short columnar form, and of the same nature throughout the length of the tubule, except near the orifice (duct), where they give place to columnar mucus-secreting cells.

(2) *Glands of the fundus* (figs. 499, 500, 501, 502).—In these glands the tubules are usually relatively long and the duct short. The epithelium of the tubules is mainly composed of two kinds of cells, termed from their relative position in the tubules the *central* and the *parietal* cells.

Central cells.—These are of two types. Those of the first type, which are the best known, are not stained by hæmatoxylin, although in aniline-blue

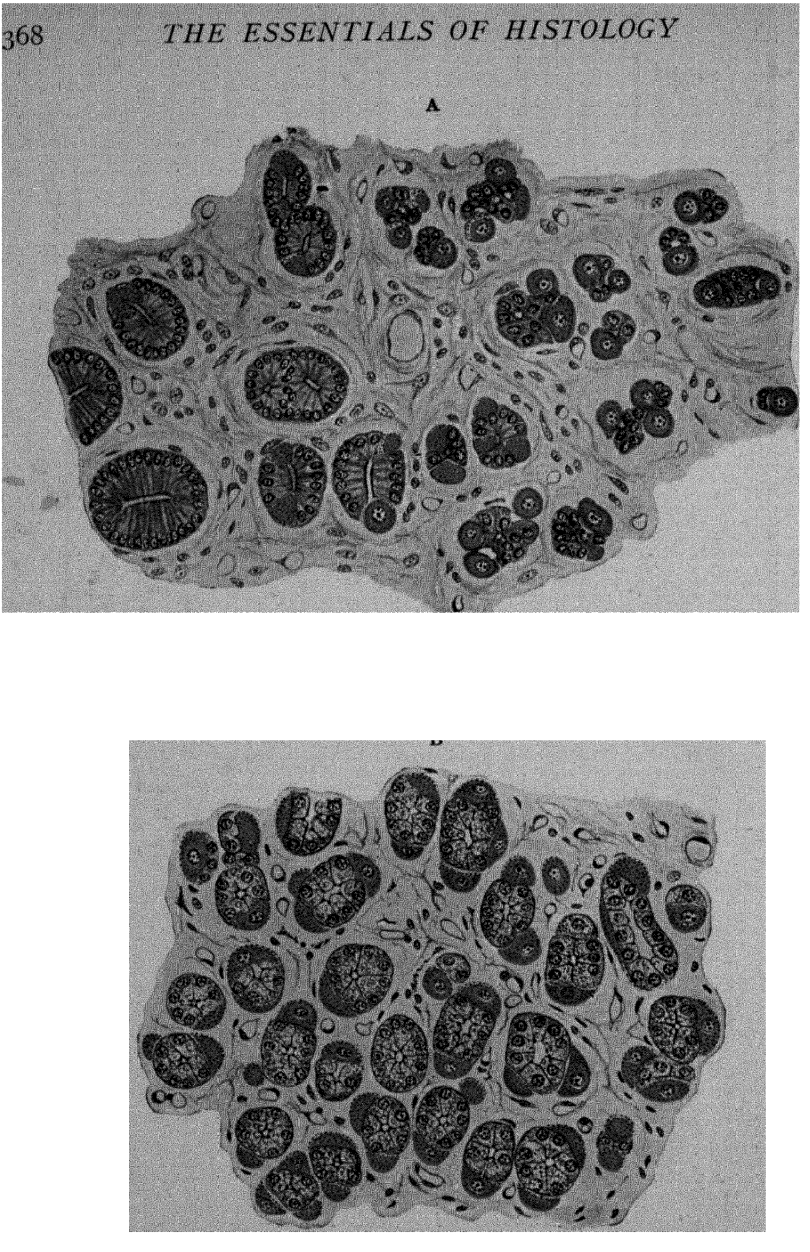

FIG. 499.—SECTIONS OF THE MUCOUS MEMBRANE OF THE FUNDUS OF THE DOG'S STOMACH ACROSS THE LONG AXIS OF THE GLANDS.

A, Section close to but not quite parallel with the surface, including on the left the gland-ducts and on the right the commencing gland-tubules. Notice the rounded oxyntic or acid-forming cells of the glands. They already begin to appear between the columnar cells of the ducts.

B, Deeper part, showing the lumina of the gland-tubules surrounded by principal or pepsin-yielding cells, with the oxyntic cells altogether outside them.

stained sections their cytoplasm shows itself strongly basiphil. The nucleus is spherical and generally near the middle of the cell. In the fresh resting gland and with certain methods of fixation, the cytoplasm is seen to contain distinct granules (zymogen) most numerous near the inner zone (fig. 500). In addition to the zymogen granules filamentous and rodded mitochondria are present. There is also a small Golgi-apparatus, variable in appearance After a period of secretory activity the granules diminish in number, and the clear outer zone encroaches upon the granular inner zone (Langley), as in the analogous cases of the pancreas and parotid glands. It is believed that the granules in question contain pepsin ogen, which is converted into pepsin when discharged. These cells (of the first type) may therefore be appropriately termed the *peptic cells* of the fundic glands.

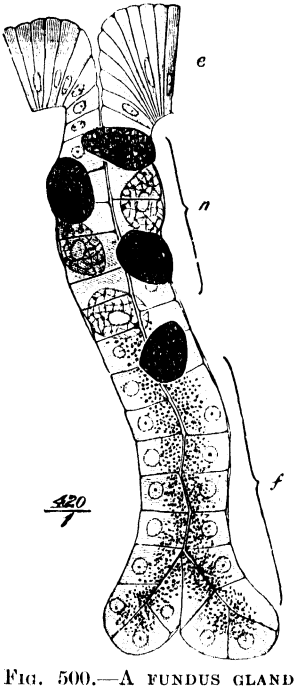

FIG. 500.—A FUNDUS GLAND OF SIMPLE FORM FROM THE BAT'S STOMACH. Osmic acid preparation. (Langley.)

e, columnar epithelium of the surface; *n*, neck of the gland with central and parietal cells; *f*, base occupied only by principal or central cells, which exhibit the granules accumulated towards the lumen of the gland.

The central cells of the second type are quite different in appearance and staining reactions from those just described. They are larger and clearer and are coloured blue by Mallory, like mucin-containing cells; whereas the cytoplasm of the peptic cell is coloured yellowish brown by that stain. They occur either in a scattered form wedged in between the other cells, or there may be a number together, occupying a considerable length of a tubule (as in fig. 501, B, *m*). The cytoplasm has no obvious granules: the nucleus is either flattened against or wedged into the attached end of the cell. To this second type of central cell the name *mucoid cell* is given (R. K. S. Lim).

Parietal cells.—Scattered along the tubule, lying between the central cells and the basement-membrane, are a number of large spheroidal or ovoidal cells, each with a round nucleus near its centre. These are the *parietal* cells; also known as *oxyntic*, having been so named by Langley because they are believed to produce the acid of the gastric secretion. Each of these cells is penetrated by a network of minute passages, communicating with the lumen of the gland by a fine canal, which passes between the central cells (fig. 502). Their mitochondria are very distinct and numerous: most of them take the form of short rods. The Golgi-apparatus forms a net around the nucleus. The oxyntic cells are sometimes present in the neck of the gland or even at the surface of the stomach; in these places they are wedged in between the ordinary epithelium-cells (fig. 499, A).

(3) *Glands of the pyloric canal* (figs. 496, 503).—In the glands of the pyloric canal the ducts are much longer than those of the fundus glands, and the secreting tubules possess cells of only one kind.[1] These appear to correspond with the 'mucoid' cells of the fundus glands which have been above described as possessing flattened basal nuclei. They have an indistinctly

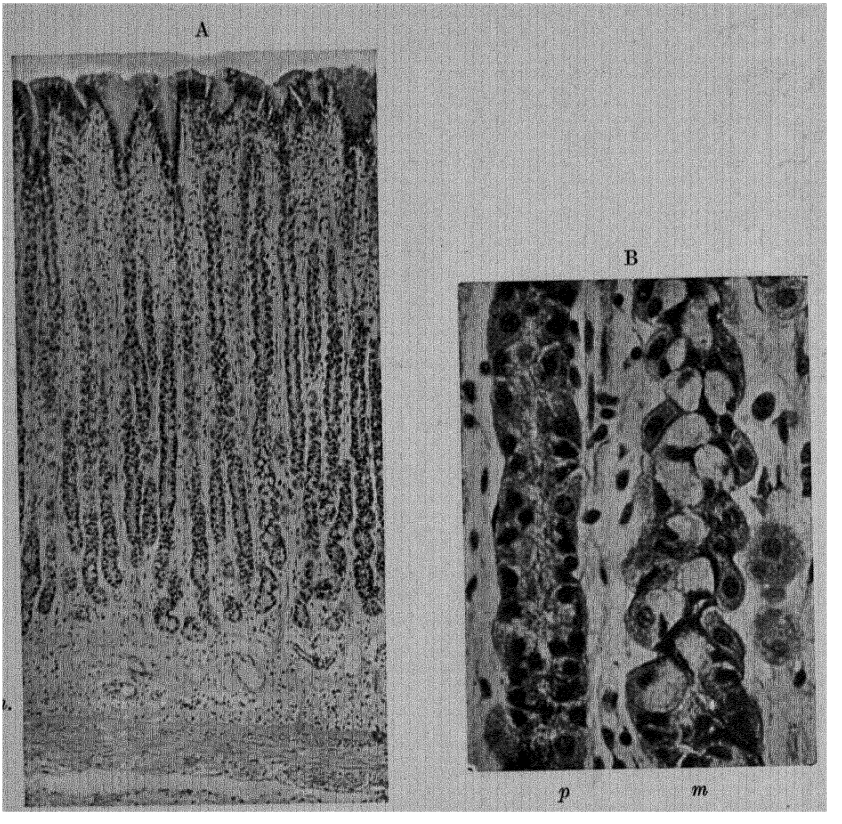

FIG. 501.—PHOTOGRAPHS OF A VERTICAL SECTION OF THE MUCOUS MEMBRANE OF THE FUNDUS OF THE CAT'S STOMACH, SHOWING THE GLANDS CUT LONGITUDINALLY. From preparations by R. K. S. Lim.

A, magnified 75 diameters; *mm.*, muscularis mucosæ. B, a portion of A magnified 400 diameters. *p*, a gland containing 'peptic' cells; *m*, a gland containing 'mucoid' cells; both show oxyntic cells at the periphery.

granular appearance and are said to yield pepsin to the gastric juice; but are different from the 'peptic' cells of the fundus glands. They are also quite unlike the epithelium of the surface and ducts, which is formed, as elsewhere, of long tapering cells, the outer part of which is filled with mucigen, and the nuclei of which are ovoid and centrally situated.

At the pylorus itself the gastric glands, which are of the same type as

[1] In man it is, however, only quite near the pylorus that parietal cells are altogether absent. They have been occasionally seen in Brünner's glands of the duodenum.

those of the pyloric canal, become considerably lengthened and enlarged, and are continued into the submucous tissue (the muscularis mucosæ being here deficient); they present transitions to the glands of Brünner, which lie in the submucous tissue of the duodenum (fig. 504).



FIG. 502.—PART OF TUBULE OF A FUNDUS GLAND, WITH THE LUMEN AND SECRETORY CANALICULI STAINED BLACK; THE GLAND-CELLS ARE ALSO SHOWN. (Zimmermann.)

c, central cells; *p*, *p*, parietal or oxyntic cells; *l*, lumen of tubule prolonged into arborescent canaliculi which penetrate into the parietal cells.



FIG. 503.—PYLORIC GLANDS, HUMAN. (E. Sharpey-Schafer.) × 60. Photograph. Preparation by Martin Heidenhain.

The blood-vessels of the stomach are abundant; they pass to the organ along its curvatures. The arteries traverse the muscular coat, giving off branches to the capillary network of the muscular tissue; they then ramify in the submucous coat. From the arterial branches here, small tortuous arterioles pierce the muscularis mucosæ, and break up into capillaries near the bases of the glands (fig. 505). The capillary network extends between the glands to the surface, close to which it terminates in a plexus of relatively large venous capillaries which encircle the mouths of the glands. From this plexus straight venous radicles pass through the mucous membrane, pierce the muscularis mucosæ, and join a plexus of veins in the submucous coat. From these veins blood is carried away from the stomach by efferent veins, which accompany the entering arteries.

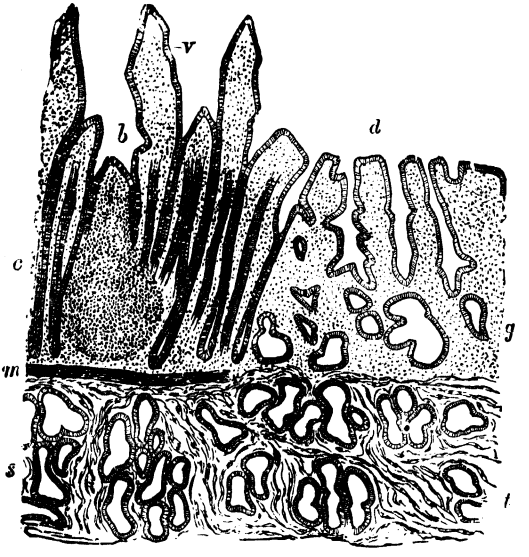

FIG. 504.—SECTION THROUGH THE PYLORUS, INCLUDING THE COMMENCEMENT OF THE DUODENUM. (Klein.)

v, villi of duodenum; *b*, apex of a lymphoid nodule; *c*, crypts of Lieberkühn; *s*, secreting tubules of Brünner's glands; *d*, ducts of pyloric glands of the stomach; *g*, secreting tubules of pyloric glands in mucous membrane; *t*, deeper lying tubules in submucosa, corresponding to secreting tubules of Brünner's glands of duodenum; *m*, muscularis mucosæ, deficient at the pylorus.



FIG. 505.—PLAN OF THE BLOOD-VESSELS OF THE STOMACH. (Modified from Brinton.)

a, small arteries passing to break up into the fine capillary network, *d*, between the glands; *b*, coarser capillary network around the mouths of the glands; *c*, *c*, veins passing vertically downwards from the superficial network; *e*, larger vessels in the submucosa.



FIG. 506.—LYMPHATICS OF THE HUMAN GASTRIC MUCOUS MEMBRANE, INJECTED. (C. Lovèn.)

The tubules are only faintly indicated: *a*, muscularis mucosæ; *b*, plexus of fine vessels at base of glands; *c*, plexus of larger valved lymphatics in submucosa.

The lymphatics (fig. 506) arise in the mucous membrane by a plexus of large vessels dilated at intervals, and looking in sections like clefts in the interglandular tissue. From this plexus the lymph is carried into large valved vessels in the submucous coat, and, from these, efferent vessels run through the muscular coat to reach the serous membrane, underneath which they pass away from the organ. The muscular coat has its own network of lymphatic vessels. These lie between the two principal layers; their lymph is poured into the efferent lymphatics of the organ.

The nerves are mostly derived from the vagi, but branches of the sympathetic also pass to the organ. They are connected with gangliated plexuses in the muscular and submucous coats, similar to the plexuses of Auerbach and of Meissner of the intestine (p. 377).

LESSONS XXXII. AND XXXIII.

THE SMALL AND LARGE INTESTINE.

PORTIONS of intestine from different parts should be fixed in 10 per cent. neutral formol. It is best to distend them slightly with this, before immersing them in more formol. This applies not only to the intestine but to all hollow viscera. Susa may be used in place of formol.

1. Sections of the duodenum, jejunum, and ileum, vertical to the surface. The three parts of the intestine may be embedded in the same paraffin block, and the sections stained and mounted together. Choose a part of the duodenum not far from the pylorus and a part of the ileum which includes a Peyer's patch. Observe the nodules of lymphoid tissue which constitute the patch and which extend into the submucous tissue. Notice the leucocytes in the superjacent epithelium. Notice also the sinus-like lymphatic or lacteal vessel which encircles the base of each nodule. In the duodenum, study the glands of Brünner in the submucous tissue. Make a general sketch of each section under a low power and draw a villus under the high power. The general arrangement and structure of the intestinal wall is to be studied in these sections.

2. Sections parallel to the surface of the intestine, and therefore across the long axis of the villi and glands of the mucous membrane. In order to keep the sections of the villi together, that they are not lost in the mounting, it is necessary either to embed in celloidin or, if paraffin is used, to employ an adhesive method of mounting (see Appendix). Sketch a villus and some of the crypts of Lieberkühn.

3. To study the process of fat-absorption, kill a frog two or three days after feeding with bacon fat. Slightly distend a short length of small intestine with a mixture of 2 parts Müller's fluid and 1 part osmic acid solution (1 per cent.), and put the piece into a fairly large quantity of the same mixture. Also place a very small shred of the fresh mucous membrane into 0·5 per cent. osmic acid solution. After forty-eight hours teased preparations may be made from this preparation, in the same manner as directed in Lesson VIII., § 1. The piece in Müller and osmic acid is left for ten days or more in the fluid. Sections are then made by the freezing method and mounted in glycerine.

4. Fat-absorption may also be studied in the mammal (rat, cat) by treating similarly a small piece of intestine, the animal having been killed three or four hours after a meal containing fat.

5. Sections of small intestine the blood-vessels of which have been injected. Sketch the arrangement of the vessels of a villus.

6. Stain a short piece of intestine of a rabbit or guinea-pig with chloride of gold. It should be washed through with Ringer's solution and distended with a 1 per cent. solution of gold-chloride, being then placed in a larger quantity of the same solution. After half an hour it may be cut open, washed with water and placed in a large amount of water faintly acidulated with acetic acid and exposed to sunlight. Twenty-four hours later, by which time it should be stained, tear off broad strips of the longitudinal muscular coat, and mount them in glycerine. It will generally be found that portions of the nervous plexus of Auerbach remain adherent to the strips; the plexus can in this way be studied.

From the remainder of the piece of intestine tear off with forceps the fibres of the circular muscular layer on the one side, and the mucous membrane on the other side, so as to leave only the submucous tissue and the muscularis mucosæ, which is to be mounted flat in glycerine; it contains the plexus of Meissner. Sketch a small portion of each plexus under a high power.

The plexuses can also be shown by the methylene-blue method and by the reduced silver method of Cajal (see Appendix).

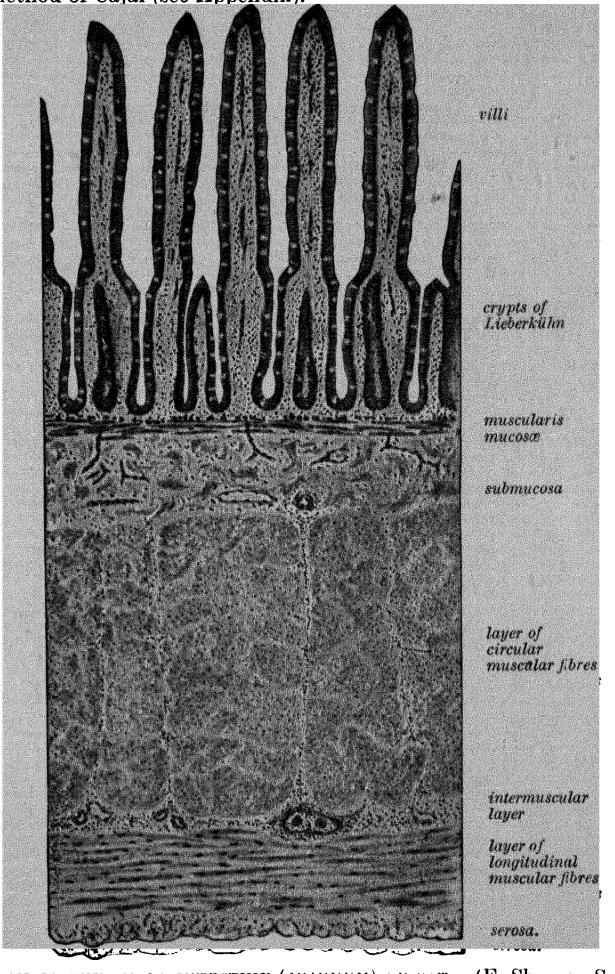

FIG. 507.—SECTION OF THE SMALL INTESTINE (JEJUNUM) OF CAT. (E. Sharpey-Schafer.) × 40.

7. Sections of large intestine from different parts (cæcum, colon, rectum) perpendicular to the surface, also sections of the vermiform appendix (human). Make sketches under a low power.

8. Sections of the mucous membrane of the large intestine parallel to the surface, and therefore across the glands. Sketch some of the glands and the interglandular tissue under a high power.

9. The arrangement of the blood-vessels of the large intestine is studied in sections of the injected organ.

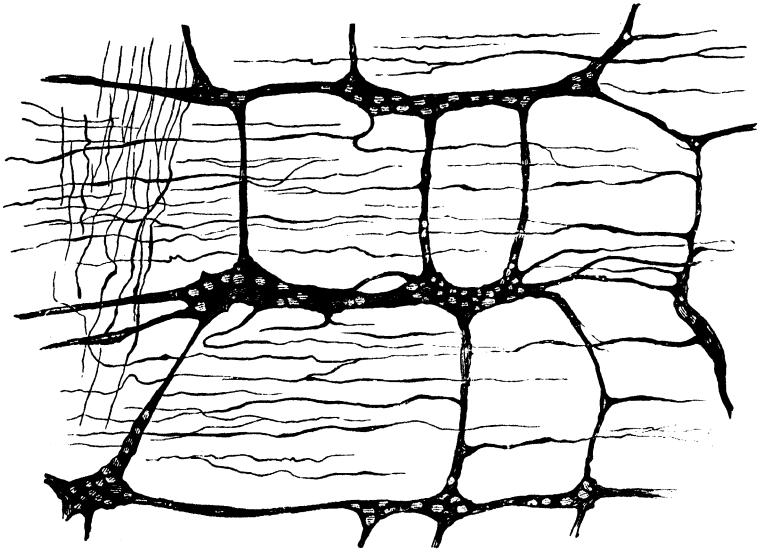

FIG. 508.—AUERBACH'S PLEXUS FROM THE MUSCULAR COAT OF THE INTESTINE. (Cadiat.)

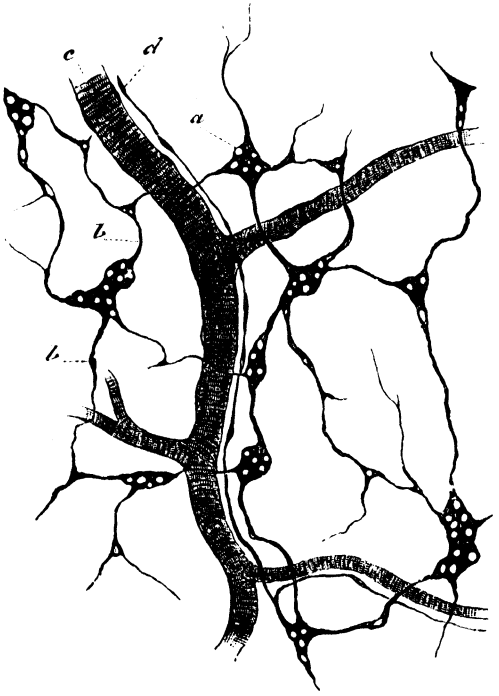

FIG. 509.—MEISSNER'S PLEXUS FROM THE SUBMUCOUS COAT. (Cadiat.)

a, ganglion; *b*, *b*, nervous cords; *c*, a blood-vessel; *d*, an entering sympathetic nerve.

THE SMALL INTESTINE.

The wall of the **small intestine** consists of four coats (fig. 507).

The *serous coat* is complete except over part of the duodenum. It leaves the intestine at the line of attachment of the mesentery, between the folds of which the blood- and lymph-vessels and nerves pass to and from the organ.

The *muscular coat* is composed of two layers of muscular tissue, an outer thinner longitudinal and an inner thicker circular. Between them lies a

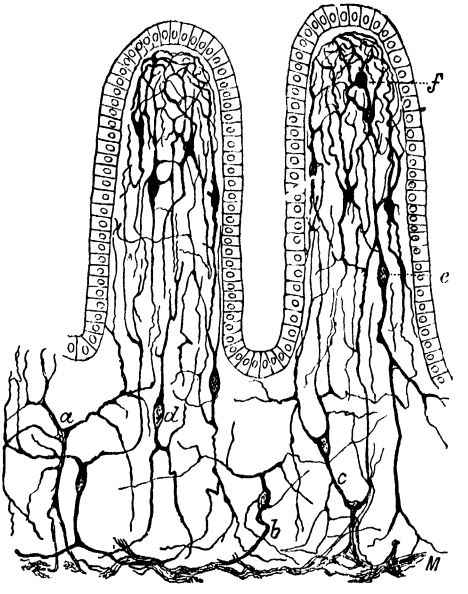

FIG. 510.—NERVES OF THE MUCOUS MEMBRANE OF THE SMALL INTESTINE. (R. y Cajal.)
M, part of Meissner's plexus; *a-f*, small cells and nerve-fibres in the tissue of the mucous membrane and villi.

network of lymphatic vessels, and also the close gangliated plexus of amyelinate nerve-fibres known as the *plexus myentericus* of Auerbach. The ganglia of this plexus may sometimes be seen in vertical sections of the intestinal wall (figs. 507, 513), but the plexus, like the one in the submucous coat immediately to be described, can only be properly displayed in preparations made by special methods (fig. 508).

The *submucous coat*, like that of the stomach, is composed of loose areolar tissue. In it the blood-vessels and lacteals ramify before entering or after leaving the mucous membrane. It contains a gangliated plexus of nerve-fibres—the *plexus of Meissner*—which is finer than that of Auerbach and has fewer cells (fig. 509). Its branches are chiefly supplied to the muscular fibres of the mucous membrane, but also to the glands and villi (fig. 510).

The cells of these 'enteric' gangliated plexuses are in many respects different from those of ordinary sympathetic ganglia. They appear to be of two distinct kinds.

One kind has a number of much branched and comparatively short dendrons and an unbranched process recognisable as the axon; the other kind is characterised by the presence of a number of long processes very little branched and hardly distinguishable from axons. C. J. Hill states that the first type of cell is intercalary; the second type, with long dendrons, is motor. It is the only one found in Meissner's plexus, but both kinds are present in Auerbach's.

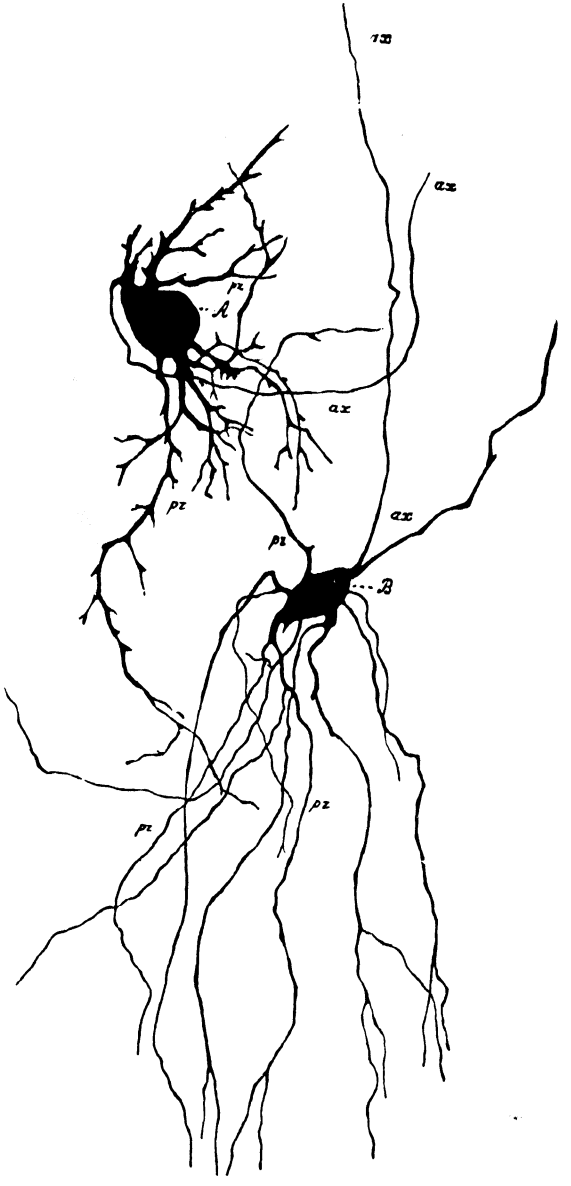

FIG. 511.—TYPICAL NERVE-CELLS FROM ENTERIC GANGLIA. (Dogiel.)

A, cell with numerous minute ramified dendrons; *B*, cell with numerous almost unbranched axon-like dendrons; *ax*, axons; *pz*, dendrons.

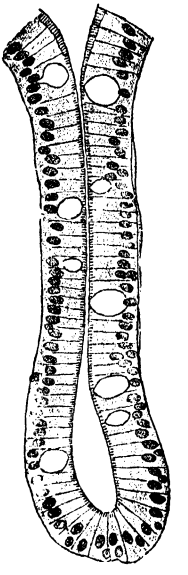

FIG. 512.—A CRYPT OF LIEBERKÜHN FROM THE HUMAN INTESTINE. (Flemming.)

The *mucous membrane* is bounded next to the submucous coat by a double (outer longitudinal and inner circular) layer of plain muscular fibres (*muscu-*

laris mucosæ). Bundles from this pass towards the inner surface of the gut and also run up into the villi. The mucous membrane proper is per-

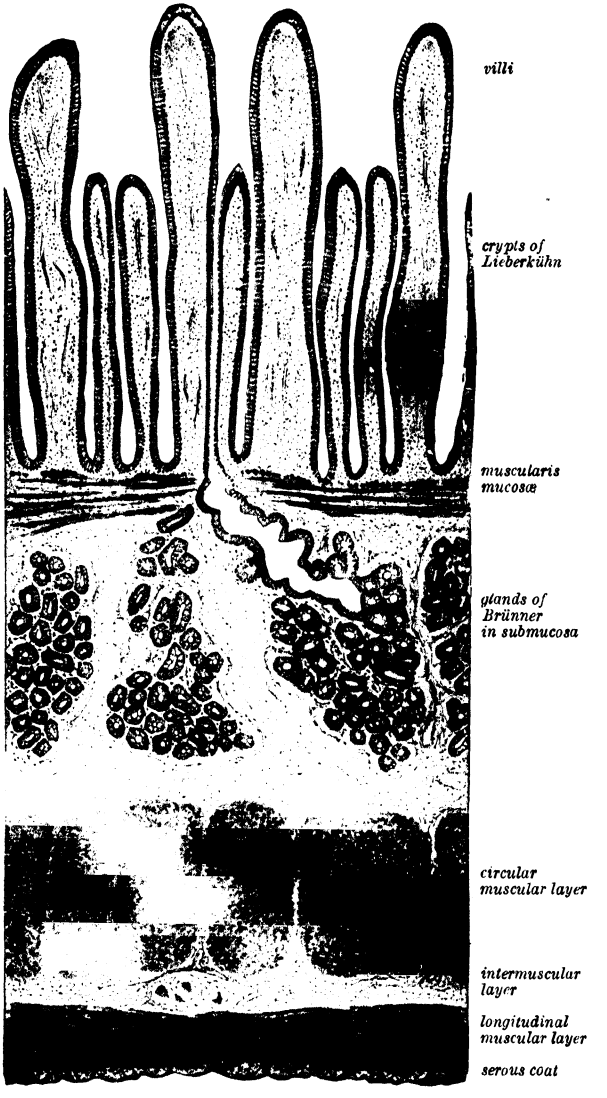

FIG. 513.—SECTION OF DUODENUM OF CAT, SHOWING BRÜNNER'S GLANDS. (E. Sharpey-Schafer.) × 60.

vaded with simple tubular glands—the *crypts of Lieberkühn* (figs. 507, 512, 513)—which are lined throughout by columnar epithelium, with scattered goblet-cells, like that which covers the general surface and the villi. At the fundus of each crypt are a few cells containing well-marked oxyphil granules

(*cells of Paneth*). Similar cells may also occur in other parts of the glands and even on the villi.

Yet another type of cell is found in the crypts, but not confined to them, and is also represented amongst the ordinary epithelium cells of the stomach, large intestine, glands of Brünner, and pancreatic duct. They were described by Kultschitzky (1897) and are known as *Kultschitzky cells*. They are characterised by possessing granules which are strongly basiphil, and are often accumulated between the nucleus and fixed end of the cell but sometimes fill the whole cell. They have been noticed in various animals, including man, and are thought to be of pathological importance, giving origin to certain tumours of the intestine and appendix.

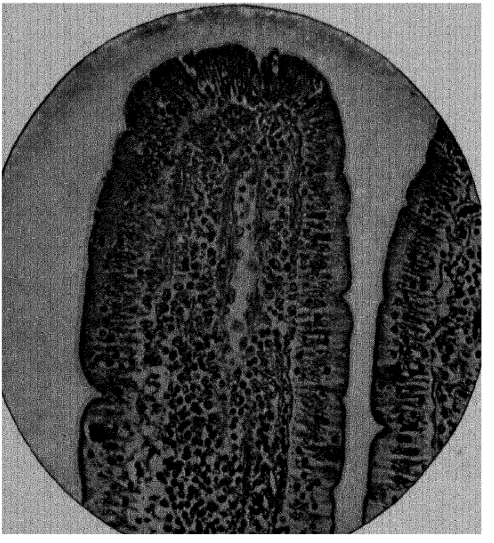

FIG. 514.—LONGITUDINAL SECTION OF A VILLUS: CAT. (E. Sharpey-Schafer.) × 200. Photograph. Preparation by Martin Heidenhain.

At one part the lacteal is cut longitudinally. Some leucocytes are seen within it: others are observable between the columnar epithelium-cells of the surface and many occupy the interstices of the reticular tissue.

The cells of the crypts may show evidences of karyokinesis; it is stated that the epithelium of the general surface becomes regenerated from that of the glands. The mucous membrane between the glands is mainly composed of reticular tissue, with numerous leucocytes; the latter are aggregated here and there into nodules of lymphoid tissue. These nodules constitute, when they occur singly, the so-called *solitary glands* of the intestine; when agglomerated, the *agminated glands* or *patches of Peyer*. The latter occur chiefly in the ileum.

The *glands of Brünner* which have been already noticed (p. 371), occur in the duodenum. They are small racemose glands, situated in the submucosa (fig. 513); they send their ducts to the inner surface of the mucous membrane either between the crypts of Lieberkühn or into them.

The **villi** with which the whole of the inner surface of the small intestine is closely beset are tongue-shaped, finger-shaped or filiform projections of the mucous membrane, and are composed, like that, of reticular tissue covered

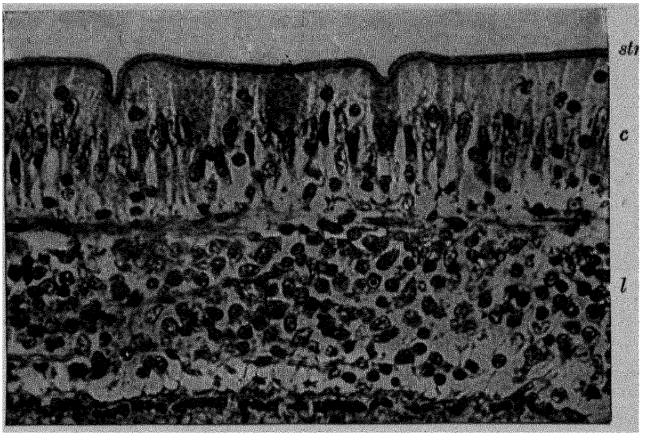

FIG. 515.—PART OF THE WALL OF THE VILLUS SHOWN IN FIG. 514. × 400.

c, columnar epithelium-cells; leucocytes are seen between them; *str*, their striated border; *l*, lymphoid tissue of villus. One or two goblet-cells are seen between the columnar cells.

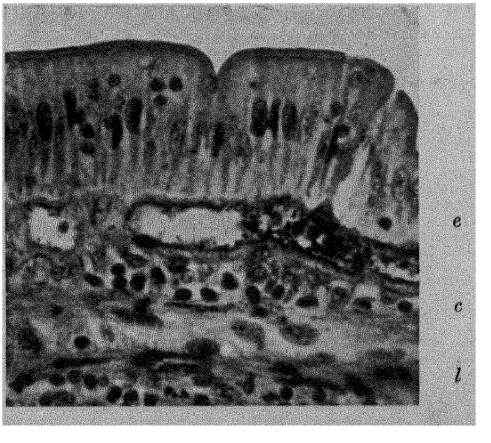

FIG. 516.—SECTION OF A VILLUS (CAT), SHOWING THE CLOSE RELATIONSHIP OF THE BLOOD-CAPILLARIES TO THE EPITHELIUM. (E. Sharpey-Schafer.) × 400.

e, columnar epithelium-cells, with some leucocytes between them; *c*, blood-capilliary cut lengthways; *l*, lacteal. Numerous leucocytes are also seen in the tissue of the villus and in the lacteal.

with columnar epithelium (figs. 514 to 518). The characters of this epithelium have been described (Lesson VIII.). Between and at the base of the epithelium-cells many leucocytes occur, as well as in the meshes of the reticular tissue. The epithelium rests upon a basement-membrane. In the middle of the villus is a lymphatic (lacteal) vessel which may be enlarged

near its commencement; the enlargement is replaced in some animals by a network of small vessels. Surrounding the lacteal are fine bundles of plain muscular tissue prolonged from the muscularis mucosæ (see p. 379). The network of blood-capillaries (figs. 516, 517, 519, 520) lies for the most part quite near the surface under the basement-membrane; it is supplied with

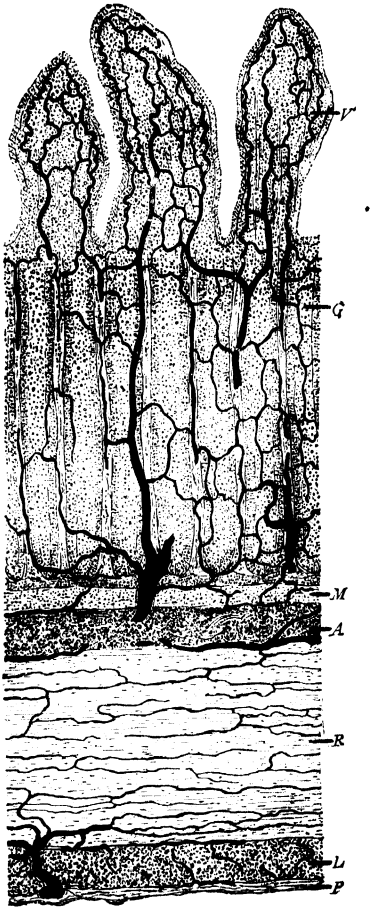

FIG. 519.—SMALL INTESTINE (VERTICAL TRANSVERSE SECTION), WITH THE BLOOD-VESSELS INJECTED. (Heitzmann.)

V, a villus; *G*, glands of Lieberkühn; *M*, muscularis mucosæ; *A*, areolar coat; *R*, circular muscular coat; *L*, longitudinal muscular coat; *P*, peritoneal coat.

blood by a small artery which joins the capillary network at the base of the villus; the corresponding vein generally arises near the free end of the villus.

The lymphatics (lacteals) of the mucous membrane (fig. 521), after receiving the central lacteals of the villi, pour their contents into a plexus of large, valved lymphatics which lie in the submucous tissue and form sinuses around the bases of the lymphoid nodules (fig. 522). From the submucous

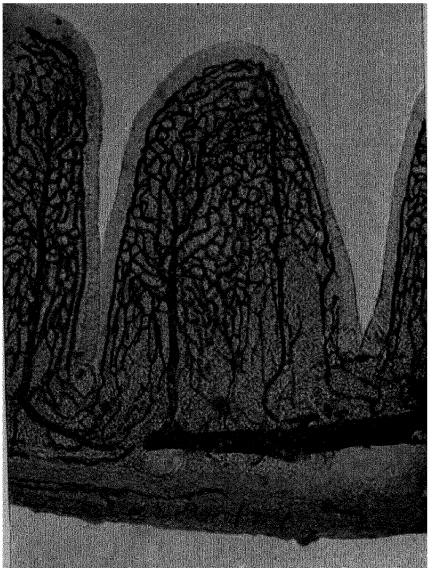

—VILLUS OF RAT WITH BLOOD-VESSELS INJECTED. (E. Sharpey-S
× 210. Photograph.

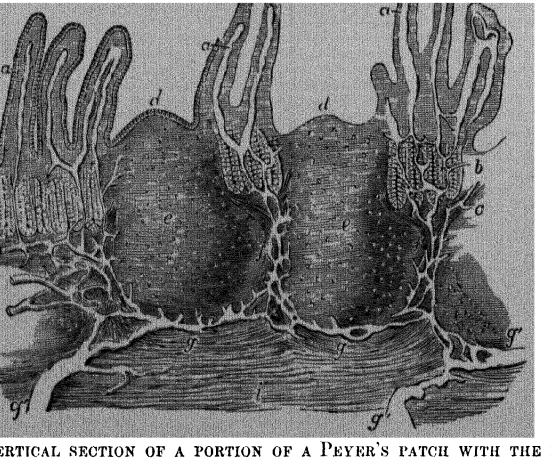

FIG. 521.—VERTICAL SECTION OF A PORTION OF A PEYER'S PATCH WITH THE LACTEAL VESSELS INJECTED. (Frey.) × 32.

The specimen is from the lower part of the ileum; *a*, villi, with their lacteals shown white; *b*, some of the tubular glands; *c*, the muscular layer of the mucous membrane; *d*, cupola or projecting part of lymphoip nodule; *e*, central part; *f*, reticulum of lacteals occupying the lymphoid tissue between the nodules, joined above by the lacteals from the villi and mucous membrane, and passing below into *g*, the sinus-like lacteals surrounding the nodules, which again pass into the large efferent lacteals, *g'*; *i*, part of the muscular coat.

tissue efferent vessels pass through the muscular coat, receiving the lymph from an intramuscular plexus of lymphatics, and are conveyed away between the layers of the mesentery.

Absorption.—*Proteins.*—Mingazzini found the columnar cells of the villi to undergo extensive changes during absorption of proteins, becoming vacuolated and swollen at first, but afterwards becoming reduced in size again.

Fats.—To study the process of fat transference in the intestine it is convenient to stain the preparation with osmic acid. It can then be observed (figs. 523, 524) that in animals which have been fed with food containing fat, particles of fat are present (1) in comparatively large globules in the outer

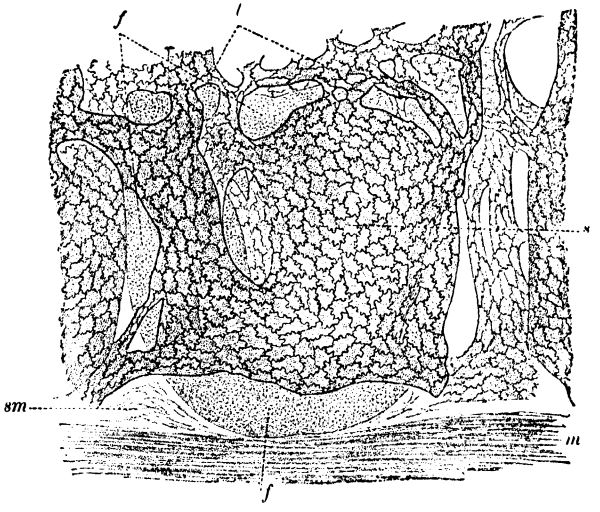

FIG. 522.—LYMPHATICS OF A PEYER'S PATCH, INJECTED WITH SILVER NITRATE. (Kölliker.) × 85.

f, a lymphoid nodule or follicle; *f'*, its base, resting upon the muscular coat, *m*; *sm*, submucosa; *l*, lymph-vessels; *s*, sinus-like enlargement of lymph-vessel surrounding follicle.

part of the columnar epithelium-cells, and in the form of much smaller globules in their deeper part (fat is never present in the striated border of the cell),[1] (2) in fine granules in the interstitial tissue of the villus, but here often confined to the amœboid leucocytes, which abound in this tissue; (3) in fine granules or larger globules within the central lacteal of the villus. Leucocytes are present not only in the reticular tissue of the villus, but also in considerable numbers between and at the base of the epithelium-cells (figs. 515, 516); and they can also be seen within the commencing lacteal; in the last situation they are undergoing disintegration (figs. 517, 525).

Since the leucocytes are amœboid, it may be deduced from these observations that the mechanism of fat-absorption consists of the following:—

[1] In mammals the epithelium-cells containing fat-globules are chiefly those near the tip of each villus.

(1) formation of fat in the columnar epithelium-cells of the surface; (2) ejection of fat-granules from the epithelium into the intercellular spaces; (3) ingestion of fat by leucocytes, these taking it up after it has passed out of the epithelium-cells; (4) migration of leucocytes carrying fat-particles

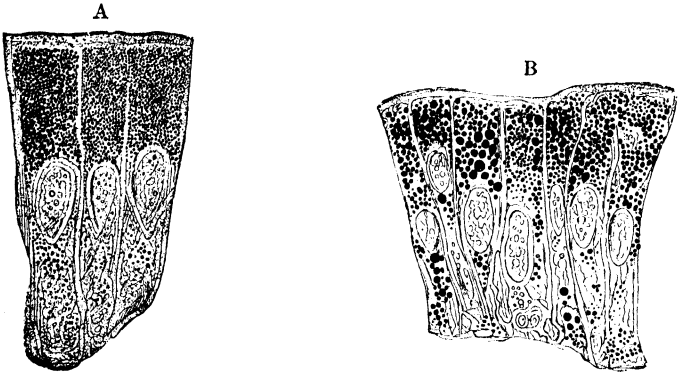

FIG. 523.—TWO STAGES IN THE DEPOSITION OF FAT IN THE INTESTINAL EPITHELIUM OF THE FROG. (Krehl.)

In A the fat is in very fine particles; in B most of it is aggregated into distinct globules. The black staining is due to the action of osmic acid.

through the tissue of the villus and into the central lacteal; (5) disintegration and solution of the immigrated leucocytes, with setting free of their contents.

The fat of the food first becomes saponified by the action of the digestive juices, and reaches the epithelium-cell in the form of dissolved soap; the

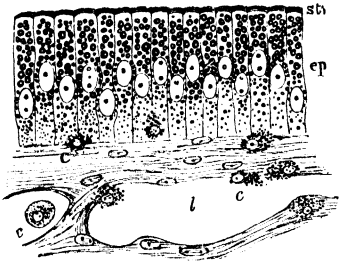

FIG. 524.—MUCOUS MEMBRANE OF FROG'S INTESTINE DURING FAT-ABSORPTION. (E. Sharpey-Schafer.)

ep, epithelium; *str*, striated border; *c*, leucocytes; *l*, lacteal. The fat-particles have been stained black by osmic acid.

fat which is seen and stained by osmic acid within the cells has become reformed by a process of synthesis.

It is a common mistake to assume that fat is emulsified in the intestine. If the intestinal contents are examined during digestion of fat, the latter is seen not as a milky emulsion, but in the form of larger and smaller oil drops distributed irregularly in the mixed juices.

In young sucking animals (puppy, kitten) the fat which is undergoing absorption

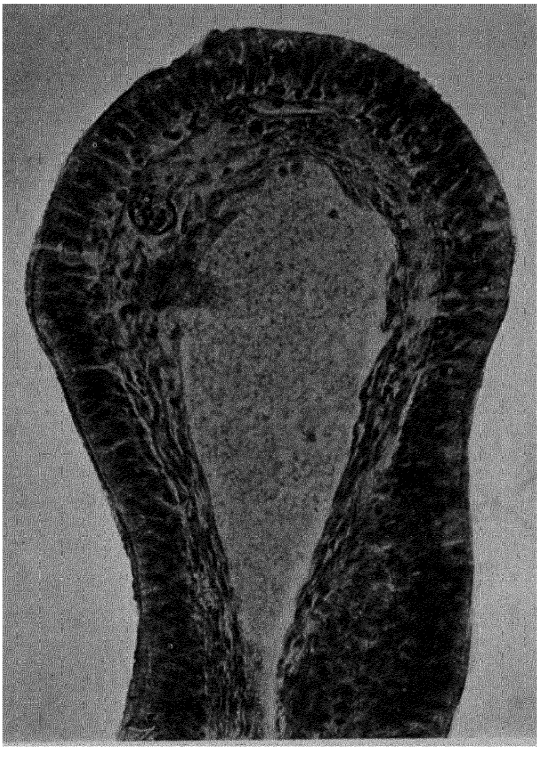

FIG. 525.—LACTEAL WITHIN VILLUS-LIKE FOLD OF THE MUCOUS MEMBRANE OF SMALL INTESTINE OF FROG. (E. Sharpey-Schafer.) × 200.

The lacteal is distended with chyle in which several leucocytes in various stages of disintegration are seen.



FIG. 526.—COLUMNAR EPITHELIUM CELLS OF VILLI DURING FAT ABSORPTION. (Mottram, Cramer and Drew.)

A. From an animal the diet of which was deficient in vitamin B.
B. From an animal fed with a diet rich in vitamin B.

is sometimes seen not only in epithelium-cells and leucocytes, but also in the form of streaks, stained black by osmic acid, in the interstices of the reticular tissue of the villi.

It has been noticed (Mottram, Cramer and Drew, 1922) that the process of fat absorption is influenced by vitamins in the food. If the latter is deficient in vitamin B, fat is liable to accumulate in the epithelium-cells, in which it appears in the form of large droplets. But if abundance of vitamin B is supplied with the food (as when milk is the chief article of diet) absorption of fat is hastened and in place of accumulating in the epithelium-cells it passes quickly out from them and through the tissue of the villi into the lacteals (compare fig. 526, A and B).

The Golgi apparatus also appears to be concerned with the absorption of fat, for Cramer and Ludford (1925) noticed that when fat *plus* vitamin B is given with the food the Golgi apparatus enlarges and almost reaches the striated border of the columnar cell; they were unable to see changes in the mitochondria.

In guinea-pigs fed on bran (which contains 4 to 5 per cent. of fat) the absorbed fat in the lacteals within the villi is found forming large drops of oil (Lorrain Smith and Rettie, 1928). These distend the lacteal, which seems to act as a temporary reservoir for the fat. The appearances are like those just described as accompanying deficiency in vitamin B.

The migration of leucocytes into the lacteals of the villi is not a special feature of absorption of fat, but occurs also when absorption of other matters is proceeding (fig. 517); the transference of fat-particles is merely an incident in the general phenomenon of migration which accompanies the process of absorption. Radium emanation, which arrests the movements of leucocytes, is found to interfere with absorption (Cramer).

The lymphoid tissue in the small intestine is increasingly developed from above down; goblet-cells also become more numerous. The ileum is characterised by its Peyer's patches; the structure of the jejunum grades imperceptibly from that of the duodenum to that of the ileum.

THE LARGE INTESTINE.

The **large intestine** has the usual four coats, except near its termination, where the serous coat is absent. In man and some other mammals the *muscular coat* is peculiar in the fact that along the cæcum and colon the longitudinal muscular fibres are gathered up into three thickened bands shorter than the rest: this produces puckerings in the wall of the gut.

The *mucous membrane* of the large intestine is beset with simple tubular glands somewhat resembling the crypts of Lieberkühn of the small intestine, and lined by columnar epithelium similar to that of the inner surface of the gut, but containing many more mucus-secreting cells (fig. 527). The blind extremity of each gland is usually slightly dilated. These glands of the large intestine are not strictly homologous with the crypts of the small intestine, for whereas the latter are developed as depressions in the general surface between the villi, the glands of the large intestine are formed by the growing together of villus-like projections of the surface. The interglandular tissue is a reticular tissue and is beset here and there with solitary glands, especially in the cæcum.

The mucous membrane of the vermiform appendix (fig. 528) is characterised by the patchy distribution of the crypts; its sub-mucosa by the abundant lymphoid nodules.

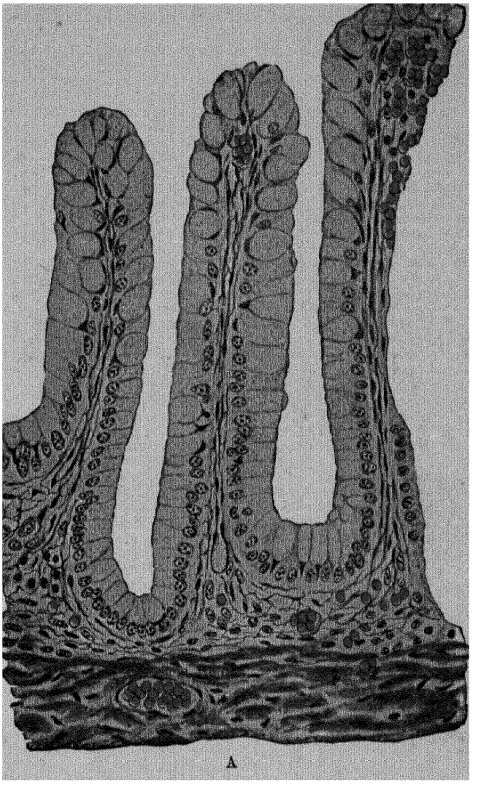

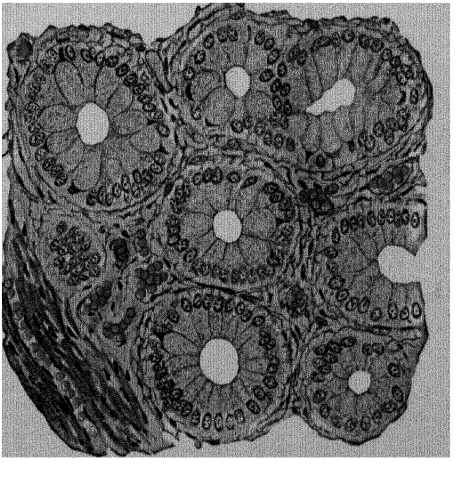

FIG. 527.—GLANDS OF THE LARGE INTESTINE OF CHILD. (E. Sharpey-Schafer.) × 300.
A, in longitudinal section; B, in transverse section.

The arrangement of the blood-vessels and lymphatics in the large intestine is like that in the stomach. The nerves of the large intestine also resemble those of the stomach and small intestine in their mode of distribution.

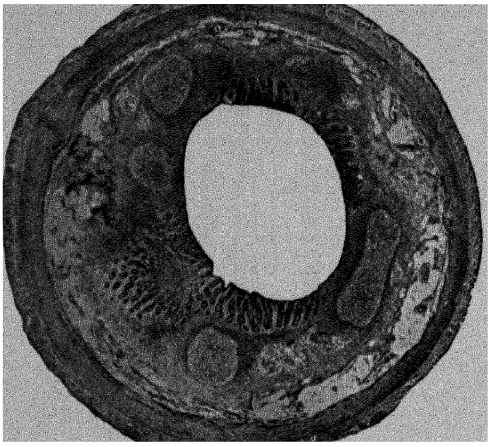

FIG. 528.—TRANSVERSE SECTION OF VERMIFORM APPENDIX. (G. Mann.)

Anus.—At the lower end of the rectum the circular muscular fibres of the gut become thickened a little above the anus to form the *internal sphincter* muscle.

In the anal region there are a number of compound racemose mucous glands opening on the surface of the mucous membrane (*anal glands*). The anal canal has columnar epithelium, but the anal orifice itself has a lining of stratified epithelium continuous with that of the skin.

LESSON XXXIV.

THE LIVER.

1. THE best fixatives for liver are susa and Zenker. Sections are cut from paraffin. They should be very thin. They may be stained with iron-hæmatoxylin. Sketch the general arrangement of the cells in a lobule under the low power; and under the high power make detailed drawings of some of the hepatic cells and also of a portal canal. If from the pig, the outlines of the lobules are observed to be well marked off by connective tissue.

Notice that the hepatic cells are in intimate contact with the blood-sinusoids. Some cells are occasionally found to contain red blood-corpuscles; all contain granules, many of them mitochondrial in nature. Notice within the sinus-like capillaries partly detached cells (the *stellate cells of Kupffer*). These, which are phagocytic, frequently contain erythrocytes in process of destruction.

2. Glycogen.—To observe glycogen within the liver-cells, kill a rabbit or rat about six hours after a meal of carrot, and at once throw a thin piece of the liver into 96 per cent. alcohol. When hardened the piece may be embedded in paraffin in the usual way, or sections may be cut free hand without embedding. Some of the sections so obtained are to be treated with a 1 per cent. solution of iodine in 2 per cent. potassium iodide for five minutes. They may be mounted in a nearly saturated solution of potassium acetate, the cover-glass being cemented with gold size and they can thus be kept for a time, but the stain will eventually fade.

Other sections may be stained with a solution of carmine in carbonate of potassium; this is said to colour the glycogen better and more permanently (Champy).

3. Iron.—In sections of alcohol-hardened liver treated first with potassium ferrocyanide solution and afterwards with hydrochloric acid and alcohol (1 to 10), then passed through absolute alcohol into xylol, and finally mounted in dammar, some granules will be stained blue (Prussian blue), indicating the presence of iron. A simpler method is to place the sections in an aqueous solution of hæmatoxylin (1 to 300), with or without previous treatment with alcohol containing 10 parts per cent. hydrochloric acid (to set free organically combined iron), after which they are passed through alcohols and xylol and mounted in the ordinary way in dammar.

4. Blood-vessels.—Study with the low power a thick section to show the general arrangement of the blood-vessels, and with a high power a very thin section, which may be lightly stained with hæmatoxylin. In this the injection, if complete, will everywhere be seen to have penetrated into canaliculi within the liver-cells themselves. Make a general sketch of a lobule under the low power and draw a small part of the network of blood-vessels and intracellular canaliculi under the high power. The intracellular canaliculi can also be seen here and there in uninjected preparations.

5. Bile-canaliculi.—Take a small piece of liver which has been several weeks in 2 per cent. bichromate of potassium solution and plunge it in 1 per cent. nitrate of silver, changing this after half an hour. Leave the piece of liver in the silver solution overnight. It may then be transferred to alcohol, and after complete

dehydration embedded and cut in paraffin in the usual way and the sections mounted in dammar. In many parts of such sections the bile-canaliculi are stained.

6. The bile-canaliculi can also be brought to view at the periphery of the lobules by injection with solution of Berlin blue from the hepatic duct. Or, throughout the whole of the lobule, by injecting about 60 c.c. of saturated sulphindigotate of soda solution, in three successive portions at intervals of half an hour, into the blood-vessels of an anæsthetised cat or rabbit. Two hours after the last injection the animal is killed, and the blood-vessels are washed out with saturated solution of potassium chloride. The liver is then fixed with absolute alcohol.

The chromate of silver method is easier and surer than the injection methods.

Sections stained with iron-hæmatoxylin may also show bile-canaliculi between the cells.

7. Tease a piece of fresh liver in serum or Ringer's solution for the study of the appearance of the hepatic cells in the recent or living condition.

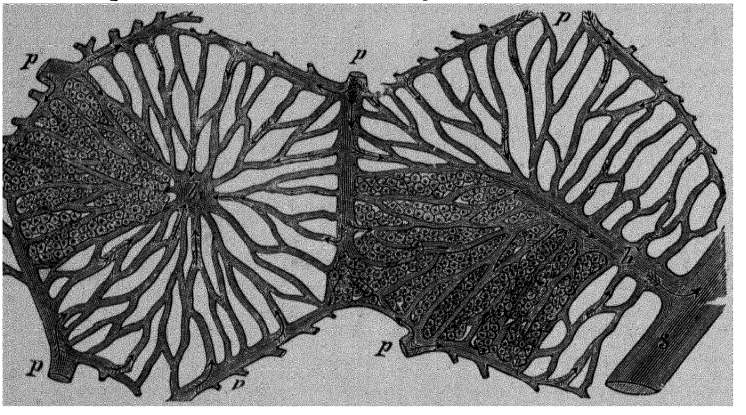

FIG. 529.—DIAGRAMMATIC REPRESENTATION OF TWO HEPATIC LOBULES.

The left-hand lobule is represented with the central or intralobular vein cut across; in the right-hand one the section takes the course of the vein. *p*, interlobular branches of the portal vein; *h*, intralobular branches of the hepatic veins; *s*, sublobular vein. The arrows indicate the direction of the course of the blood. The liver-cells are represented in a part only of each lobule.

The **liver** is a solid glandular organ, made up of the *hepatic lobules*. These are polyhedral cell-masses (fig. 529) about 1 mm. ($\frac{1}{25}$ inch) in diameter, separated from one another by connective tissue. In some animals, *e.g.* the pig, this separation is complete, and each lobule is isolated, but in most animals, including man, it is incomplete. There is also a layer of connective tissue underneath the serous covering of the liver, forming an external capsule to the organ. Each lobule is penetrated by a fine network of reticular tissue which helps to support the columns of cells within the lobule (fig. 530).

The afferent blood-vessels of the liver (portal vein and hepatic artery) enter its under surface, where also the bile-duct passes away from the gland. The branches of these three vessels accompany one another in their course through the organ, and are enclosed by loose connective tissue (*capsule of Glisson*), in which are lymph-vessels, the whole being termed a *portal canal* (fig. 531). The smaller branches of the vessels penetrate to the intervals between the hepatic lobules, and are known as the *interlobular vessels*. The blood leaves the liver at the back of the organ by the hepatic veins; the branches of these run through the gland unaccompanied by other vessels

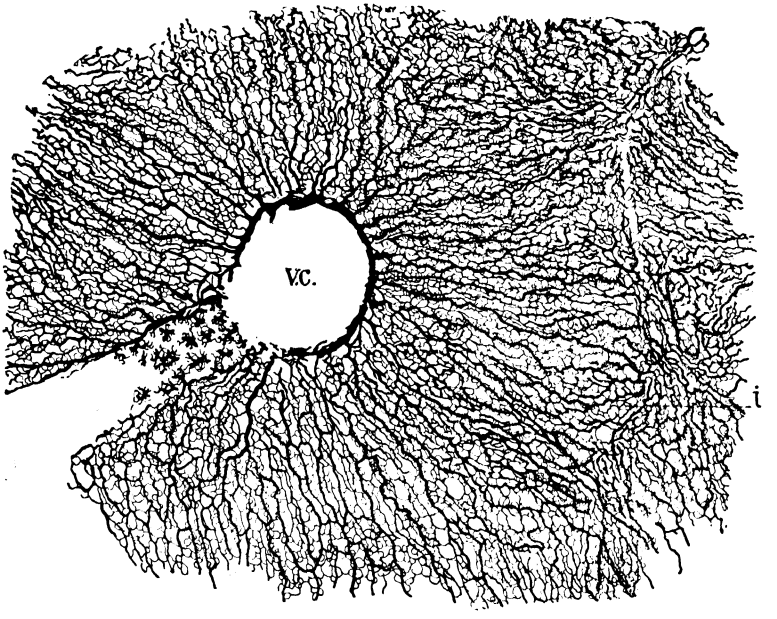

FIG. 530.—RETICULUM OF A LIVER-LOBULE. (Oppel.)
V.C., central vein; i, interlobular interval.

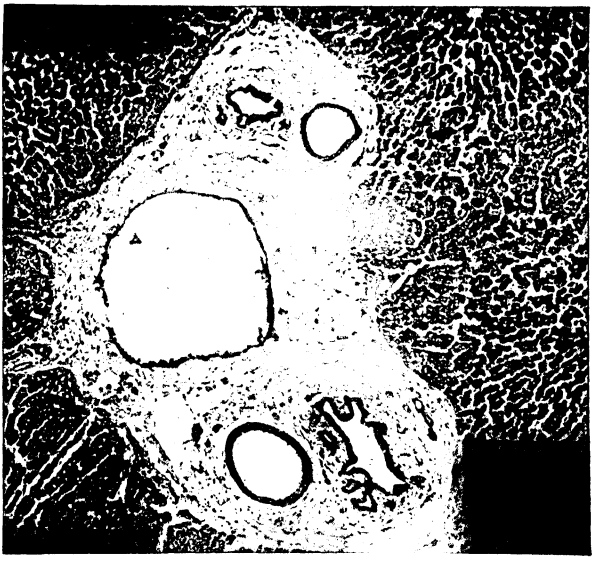

FIG. 531.—SECTION OF A PORTAL CANAL: DOG. (E. Sharpey-Schafer.) × 50. Photograph.
The large vessel is a branch of the portal vein; the irregular tubes are sections of branches of the hepatic duct; near them are sections of branches of the hepatic artery. All the vessels are enclosed by the connective tissue of the capsule of Glisson; in this tissue several lymph-vessels are seen as clear spaces. The whole is surrounded by liver-lobules.

(except lymphatics) and can also be traced to the lobules, from each of which they receive a minute branch (*central* or *intralobular vein*) which passes from the centre of the lobule, and opens directly into the (*sublobular*) branch of the hepatic vein.

Each hepatic lobule is a mass of cells pierced everywhere with a network of sinusoid blood-vessels, often called hepatic capillaries (figs. 328, 532).



FIG. 532.—SECTION OF LIVER: HUMAN. (E. Sharpey-Schafer.) × 400. The figure includes the peripheral part of a lobule.

1, interlobular connective tissue; 2, peripheral cells of lobule containing fat globules; 3, 3, stellate cells of Kupffer; 4, bile canaliculi; 5, blood corpuscles in the sinusoids; 6, 7, plasmatic intracellular canaliculi.

At the periphery of the lobule these receive blood from the interlobular branches of the portal vein (fig. 529, *p*), and converging to the centre of the lobule unite to form the intralobular branch of the hepatic vein (*central vein of lobule*). The interlobular branches of the hepatic arteries join the sinusoids a short distance from the periphery of the lobule. The blood in the sinusoids is in direct contact with the liver-cells (the endothelium being deficient) and the blood-plasma can pass into canaliculi within the cytoplasm of the cells. Conspicuous cells occur at intervals on the walls of the sinuses, where they lie in contact with the liver-cells. These are the so-called *stellate cells of Kupffer;* which were, however, originally described by Browicz. They are highly phagocytic, like the phagocytic cells of the blood-sinuses of the spleen, and they ingest erythrocytes, which can be seen within them, often partly disintegrated. They also tend to take in fine suspended particles, such as quartz or carbon particles of Indian ink, which may be injected into the blood.

The Kupffer cells resemble other phagocytic cells of the reticulo-endothelial system, as described by Aschoff (see p. 103). They are generally regarded as the remains of the endothelium, but this has not been proved. In any case they are liable to become detached from the walls of the sinusoids and carried away by the blood-stream.

The **liver-cells** which everywhere lie between and surround the blood-sinusoids, are polyhedral, granular cells, each containing one or two spherical nuclei. The cytoplasm of the cells is pervaded by an irregular network of canaliculi (figs. 533, 534); these in preparations of well-injected liver become filled with the injection material, which has passed by open channels into them from the blood-vessels. They thus form a system of intercommunicating intracellular canaliculi which receive blood-plasma directly from the vessels instead of through lymph-spaces as is usual in most organs. Such a communication was conjectured to exist by Browicz (1897), who found that under certain pathological conditions not only hæmoglobin but whole red blood-corpuscles, and even groups of blood-corpuscles in process of breaking down, are to be found in the interior of the liver cells. Browicz also found that in the dog's liver both hæmoglobin and hæmatoidin may be found in the form of crystals within both cytoplasm and nuclei of normal liver cells. The existence of intracellular canals communicating with the sinusoids was described by Schafer in 1902. This observation was confirmed and extended by Herring and Simpson, who showed that it is possible in all animals to inject them along with the blood-vessels.



FIG. 533.—FROM A SECTION OF RABBIT'S LIVER INJECTED FROM THE PORTAL VEIN, SHOWING INTRACELLULAR CANALICULI COMMUNICATING WITH THE INTERCELLULAR BLOOD-SINUSOIDS. (E. Sharpey-Schafer.) × 400.

Intracellular plasma-canaliculi were first described by J. H. and E. H. Fraser (1895) in the frog's liver. In mammals they may be seen within the cells of the uninjected liver (fig. 532, *6*, *7*). Their plasma-content has been erroneously described as protein matter deposited temporarily in the cells during absorption. It is interesting to observe the intimacy of the relation between blood and liver-cell in view of the activity of the liver in many metabolic processes.

In cases of delayed chloroform poisoning, in which fat globules form within the liver-cells, the fat passes out of the cells into the sinusoids directly through these plasma-canaliculi. From the sinusoids it is conveyed by the hepatic veins to the vena cava inferior and thus into the pulmonary circulation in which it may produce fat-emboli.

After a mixed meal many of the liver-cells contain fat. Masses of glycogen can also be seen within them (fig. 535) if the liver is hardened in alcohol and treated in the manner described in section 2, p. 391. The cells contain, besides granules of a mitochondrial nature which often take the form of

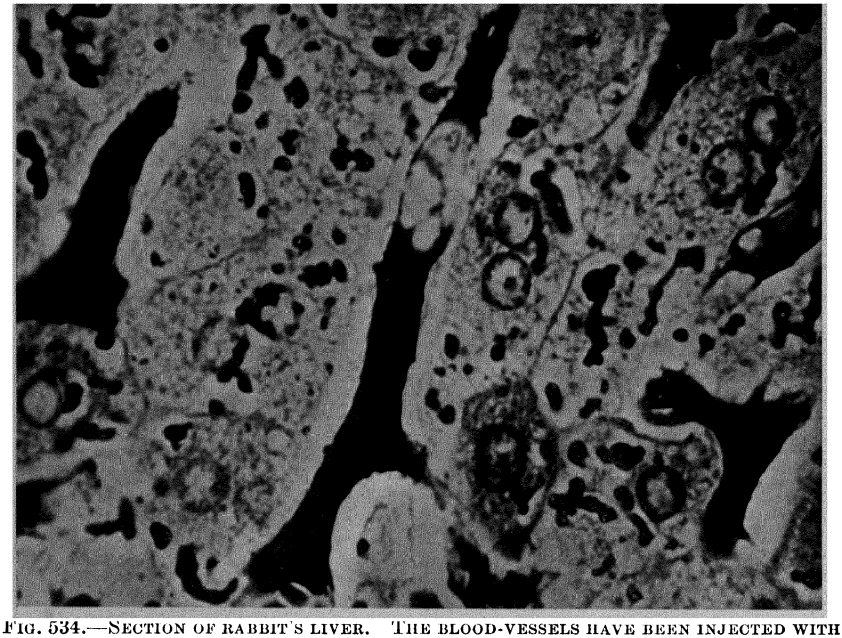

FIG. 534.—SECTION OF RABBIT'S LIVER. THE BLOOD-VESSELS HAVE BEEN INJECTED WITH CARMINE GELATINE. (E. Sharpey-Schafer.) × 975.

The red injection mass, which comes out black in the photograph, is not only contained in the sinusoids but is also seen occupying intercommunicating canaliculi in the interior of every liver-cell; these canaliculi even surround the cell-nuclei. The alcohol used to fix or harden the preparation has caused the gelatine injection in the sinusoids to shrink away from the liver-cells; this shrinkage has ruptured the communications with the intra-cellular canaliculi except here and there.

Notice that there is no endothelium lining the sinusoids, the liver-cells being in direct contact with the blood-stream.



FIG. 535.—LIVER-CELLS CONTAINING GLYCOGEN. (Barfurth.)

short rods, pigment-granules which can be stained by potassium ferrocyanide and hydrochloric acid or by pure hæmatoxylin (presence of free iron). Part of the iron within the cells is in organic combination; this can be set free by treatment for a short time with alcohol to which 10 per cent. hydrochloric acid has been added (A. B. Macallum).

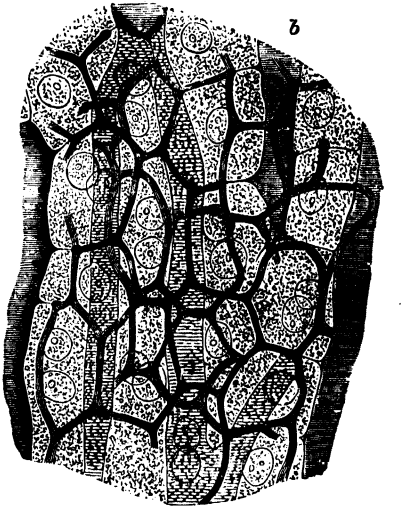

FIG. 536.—SECTION OF RABBIT'S LIVER WITH THE INTERCELLULAR NETWORK OF BILE-CANALICULI INJECTED. (Hering.) Highly magnified.

Two or three layers of cells are represented; *b*, blood-sinusoids.

Bile-ducts.—The smallest ducts commence between the liver-cells in the form of *intercellular bile-channels*, the so-called *bile-canaliculi*, which lie between the cells, and receive the contents of the secretion-vacuoles (see below). The bile-canaliculi form a network, the meshes of which correspond in size to the cells (fig. 536); the network is incomplete, some of the channels ending blindly. At the periphery of the lobule the intercellular bile-canaliculi pass into the smallest interlobular bile-ducts (fig. 538). The bile-canaliculi are always bounded by liver-cells, never placed between a cell and a blood-sinus.

The liver-cells may show during secretory activity very fine short canals which communicate with the network of bile-canaliculi; these fine canals generally commence within

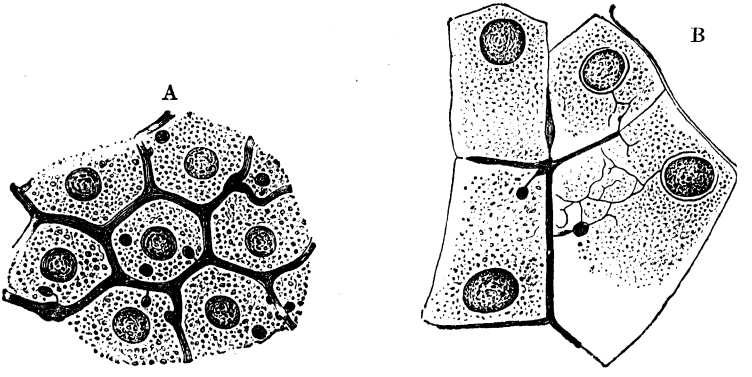

FIG. 537.—SKETCHES ILLUSTRATING THE MANNER IN WHICH BILE PASSES FROM THE HEPATIC CELLS INTO THE INTERCELLULAR BILE-CHANNELS. (R. Heidenhain, after Kupffer.)

A, from liver of rabbit the bile-ducts of which had been injected backwards from the hepatic duct.

B, from liver of frog naturally injected with sulphindigotate of soda, which when injected into the blood is excreted by the liver.

the cell by dilatations (secretion-vacuoles) (fig. 537); probably they are not permanent structures.

The actual bile-ducts, which carry bile away from the lobules, are lined by columnar epithelium. This resembles that of the small intestine, the

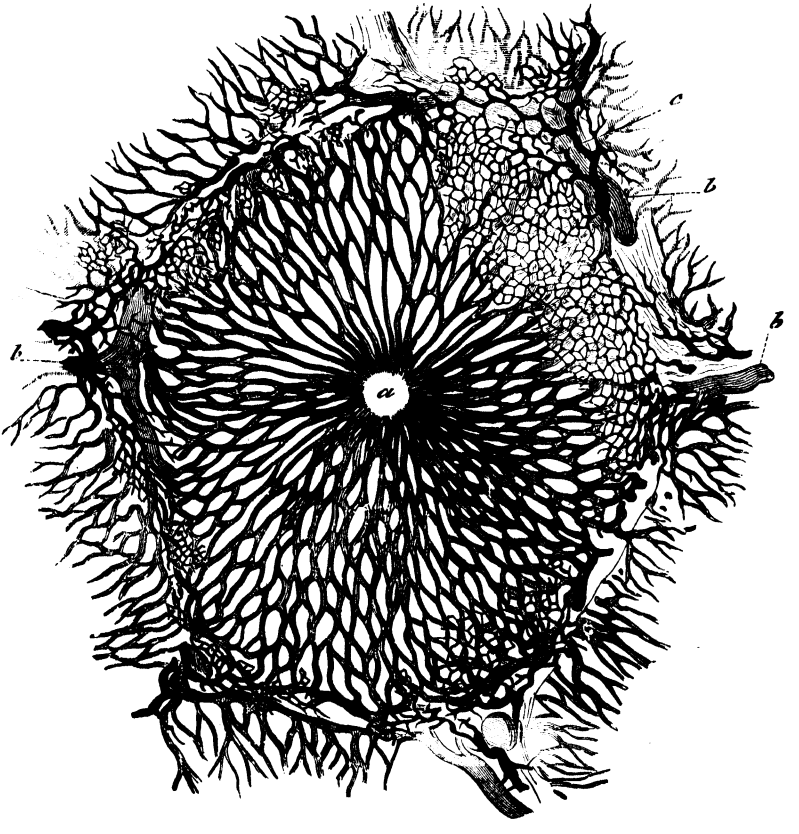

FIG. 538.—LOBULE OF RABBIT'S LIVER: VESSELS AND BILE-DUCTS INJECTED. (Cadiat.)

a, central vein connected by the network of sinusoids with *b*, *b*, peripheral or interlobular veins; *c*, interlobular bile-duct commencing in a network of intercellular bile-canaliculi within the lobule. The injection of the bile-canaliculi has only penetrated a short distance into the lobule.

cells having, like that, a striated border. Outside this epithelium is a basement-membrane, and in the larger ducts some fibrous and plain muscular tissue. Many of the large ducts are beset with blind diverticula; the main duct has small acinous glands in its wall. The ducts which lie between (at the periphery of) the lobules and receive the bile-canaliculi from them are lined by cubical or flattened cells; these have no striated border.

The liver-cells, the cells of the bile-ducts and those of the gall-bladder are all liable to contain fat droplets during absorption of a meal containing fat; no doubt the fat in the cells has been formed by re-synthesis of absorbed fatty acids and glycerol, as in the case of the intestinal epithelium.

As Herring and Simpson first showed, there are no lymphatics actually within the lobules; there is in fact no space for them between the liver-cells and the blood in the sinusoids. There are, however, numerous lymph-vessels accompanying the interlobular branches of the portal vein, and others, less numerous, accompanying the tributaries of the hepatic veins. But no direct communication through the lobules exists between the two sets of lymphatics, although they communicate freely both at the periphery of the lobules and near their exit from the liver. Most of the liver-lymph is drained away by the lymphatics accompanying the portal vein.

The nerves of the liver reach the organ through the splanchnics. They are distributed both to the vessels and liver-cells.

The development of the liver has already been mentioned in connexion with the formation of its sinusoids (pp. 239 to 241).

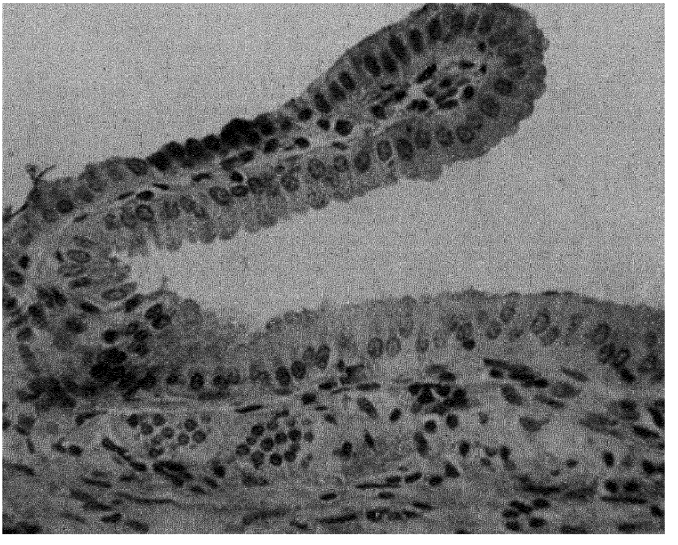

FIG. 539.—SECTION OF THE WALL OF THE GALL-BLADDER: MAN. (E. Sharpey-Schafer.) ×355. Photograph. Preparation by C. F. W. Illingworth.

THE GALL-BLADDER.

The **gall-bladder** is in its general structure similar to the larger bile-ducts. It is lined by columnar epithelium like that of the small intestine; outside this its wall is formed of fibrous and muscular tissue. The mucous membrane is thrown into permanent reticulating folds (fig. 539), which become larger and more numerous near the neck of the gall-bladder.

LESSON XXXV.

THE PANCREAS.

1. Sections of pancreas fixed in susa or in 10 per cent. neutral formol followed by alcohol. The sections may be stained with alcoholic eosin and hæmatoxylin or with Mallory's solution (acid fuchsin, orange G, and aniline blue). This is the best method for exhibiting the zymogen granules within the cells. Notice the islets of Langerhans between the alveoli; they are generally most numerous near the splenic end of the pancreas.

Make sketches under both low and high power.

2. If the pancreas is taken from a rat which has been fed with the addition of ox-thyroid to its ordinary food during seven days, the cells of the alveoli exhibit numerous mitoses. These are entirely absent in the pancreas of the normal animal.

3. Tease a small piece of fresh pancreas in serum or salt solution or in dilute glycerine after treatment with osmic acid. Notice the zymogen granules in the alveolar cells, chiefly accumulated in the half of the cell which is nearest the lumen of the alveolus, leaving the outer zone of the cell clear.

Sketch a small portion of an alveolus under a high power.

4. The endings of the ducts in the alveoli, and the termination of nerve-fibres amongst the gland-cells are shown in preparations made by the silver-chromate method (see Appendix).

The **pancreas** is a racemose gland, resembling the serous salivary glands so far as its general structure is concerned, but differing from them in the fact that the alveoli are longer and more tubular in character. Moreover, the connective tissue of the gland is looser, and there occur scattered throughout the glandular substance small irregular masses of clear epithelium-cells unfurnished with ducts (*islets of Langerhans*) (figs. 540, 541). The presence of these islets is characteristic of the pancreas. There are good grounds for the belief that they are concerned with the production of *insulin*.

The islets contain two kinds of cell, distinguishable from one another by the chemical nature and staining properties of their granules. The granules of the one kind are insoluble in alcohol and are oxyphil: the cells containing them are termed α cells. Those of the other kind are soluble in 96 per cent. alcohol (in this respect resembling *insulin*) and are basiphil: the cells containing them are termed β cells (Lane). Some of the islet-cells are devoid of granules. The islet-cells contain mitochondria, and each has a well-marked reticular Golgi apparatus. The islets are well shown in the fresh gland by R. Bensley's method of staining *in vivo* with neutral red or Janus green which colour them selectively. In the human pancreas there are as many as from ten to twenty islets in each milligramme, which would give from a million to a million and a half in the whole pancreas (Clark). The islet tissue is thus seen to constitute a very significant part of the organ.

In teleostean fishes the islet-tissue forms a separate organ, but attached to the rest of the pancreas.

The cells which line the alveoli are columnar or polyhedral in shape. When examined in the fresh condition, or in sections fixed and stained by

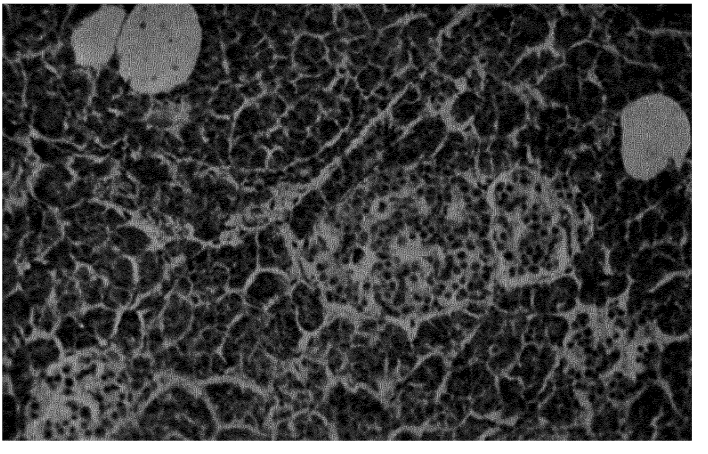

FIG. 540.—PANCREAS: HUMAN. (H. M. Carleton.)
Besides the alveoli, sections of three islets are seen. The clear spaces are fat-cells.

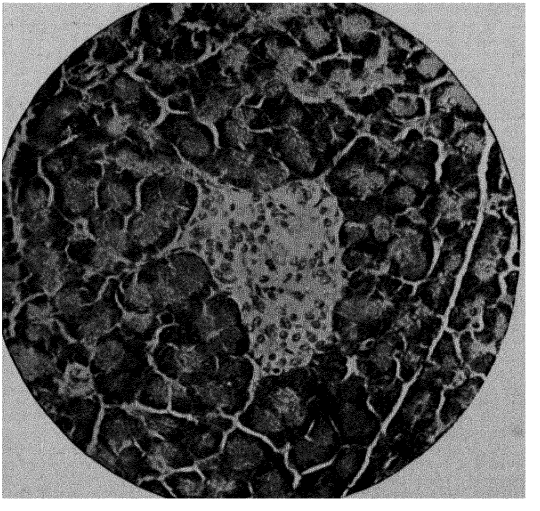

FIG. 541.—AN ISLET OF LANGERHANS IN PANCREAS OF DOG. (Kojima.) × 300.

appropriate methods, their protoplasm is seen to be filled in the inner two-thirds with granules, the outer third being clear; it may appear striated (figs. 542, 544). After a period of activity the clear part of the cell becomes

larger, and the granular part smaller (fig. 543). In hæmatoxylin-stained sections the outer part is coloured more deeply than the inner (fig. 541). This

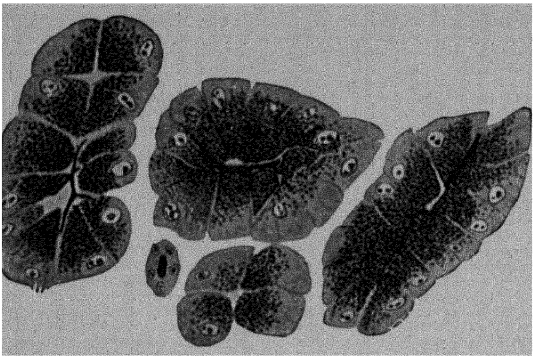

FIG. 542.—ALVEOLI OF DOG'S PANCREAS, CELLS LOADED: OSMIC PREPARATION. (Babkin, Rubasckin, and Ssawitsch.)

is due to the concentration in this part of a mass of thread-like mitochondria. In specially fixed and stained specimens the mitochondria (fig. 12, p. 9) are discrete, but with ordinary methods only the darkly staining mass, referred

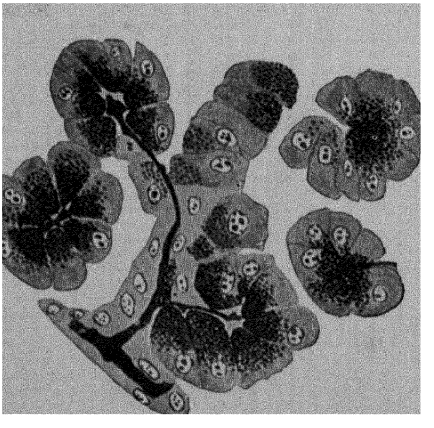

FIG. 543.—ALVEOLI OF DOG'S PANCREAS AFTER A PERIOD OF ACTIVITY PRODUCED BY APPLICATION OF ACID TO MUCOUS MEMBRANE OF DUODENUM. (Babkin, Rubasckin, and Ssawitsch.)

to above, can be seen. In sections stained by Mallory (see Appendix) the granules of the inner zone are coloured intensely red, and stand out black in photographs. The granules are always most abundant in the alveoli immediately surrounding the islets (Kojima).

Under normal circumstances the pancreas-cells do not exhibit karyokinesis or show any evidence of multiplication. But in rats fed with thyroid gland in addition to their ordinary food numerous mitoses can be seen throughout the gland, indicating rapid cell-division (Kojima). The islet-cells never show mitoses.

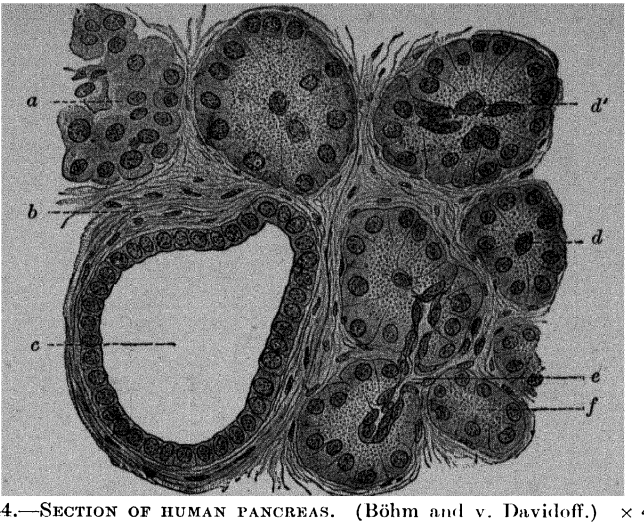

FIG. 544.—SECTION OF HUMAN PANCREAS. (Böhm and v. Davidoff.) × 450.

a, part of an islet of Langerhans; *b*, connective tissue; *c*, larger duct; *d*, lumen of alveolus; *d'*, alveolus with centro-acinar cells; *e*, small duct passing into alveoli; *f*, inner granular zone of alveolus.

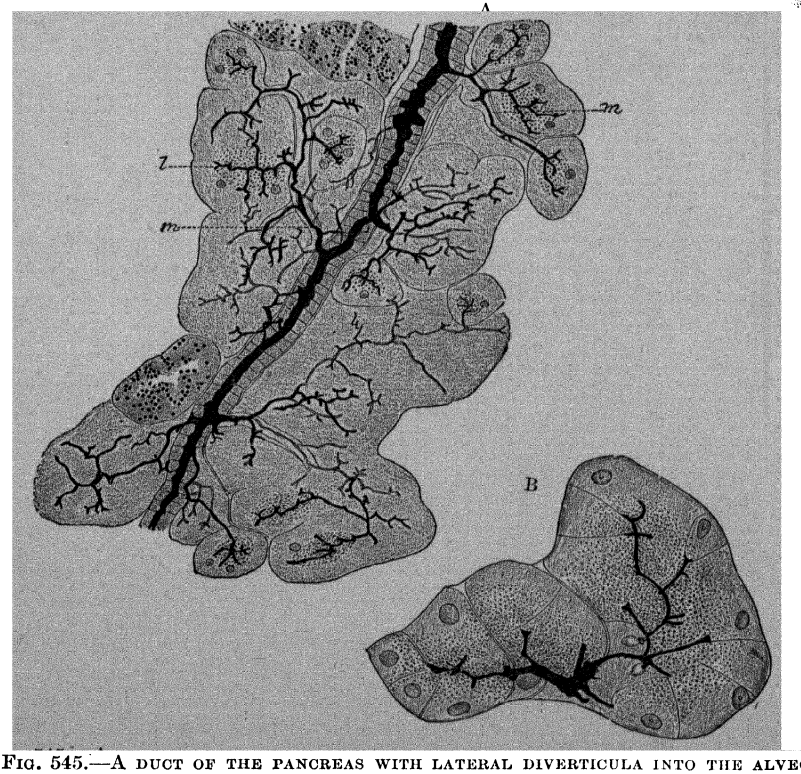

FIG. 545.—A DUCT OF THE PANCREAS WITH LATERAL DIVERTICULA INTO THE ALVEOLI: GOLGI METHOD. (E. Müller.)

In A the duct is shown cut longitudinally and giving off ductules, *m*, *m*, to the alveoli, where they extend between the cells, *l*. In B the details of their termination are shown more highly magnified. Portions

In the centre of each acinus there may generally be seen a few spindle-shaped cells (*centro-acinar cells*); they appear to be continued from the cells

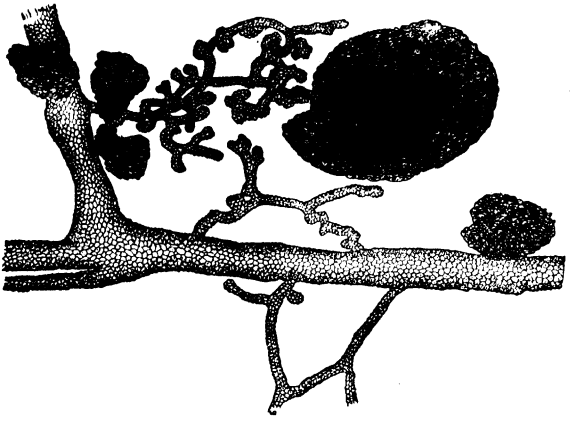

FIG. 546.—ISLETS FROM PANCREAS OF GUINEA PIG STILL CONNECTED WITH PANCREATIC DUCTS BY BRANCHED CELL-CORDS. (R. Bensley.) × 77.

Two or three of the islets are sessile on the ducts.

which line the smallest ducts (fig. 544, *e*). Sometimes they are more conspicuous, and fill the parts of the alveoli which are nearest to the duct; in these cases the mass of cells which they form is liable to be mistaken for a Langerhans' islet. Diverticula from the lumen of the alveolus penetrate



FIG. 547.—INJECTION OF BLOOD-VESSELS OF AN ISLET OF THE PANCREAS. (Kühne and Lea.)

between the alveolar cells (fig. 545) as in serous glands generally. The islets may remain connected with the ducts, from which they were originally developed as solid strands of epithelium cells (fig. 546).

Like all secreting glands the pancreas is very vascular. Each alveolus has a network of capillaries closely surrounding it, but always outside its

basement-membrane. The capillaries of the islets are large and irregular and resemble sinusoids (fig. 547).

The pancreas has many nerves, with numerous small ganglia distributed upon their course. Some nerve-fibres end by ramifying amongst the cells of the alveoli, as in the salivary glands; many are distributed to the islets (fig. 548). In addition numerous nerve-fibres pass to the blood-vessels. In the cat, which has Pacinian bodies in its mesentery, these terminal

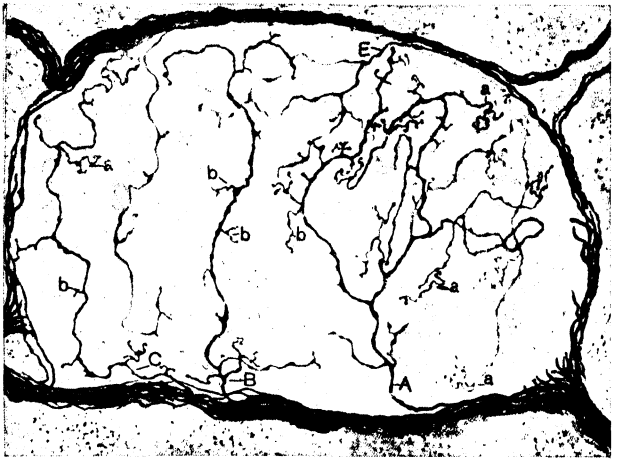

FIG. 548.—NERVES DISTRIBUTED TO AN ISLET OF LANGERHANS OF THE MOUSE. Golgi preparation. (F. de Castro.)

organs are also found abundant in the substance of the pancreas, but this is a mere accident, resulting from the fact that the pancreas in this animal—as in many others—has a thin extension between the layers of the mesentery, and in the cat the last-named membrane always contains Pacinian corpuscles.

DEVELOPMENT.

The pancreas is formed from an outgrowth (at first solid, afterwards becoming hollowed) of the entoderm of the small intestine, much in the same way that the salivary glands are developed from the ectoderm of the mouth. The islets of Langerhans make their appearance as buds from the developing ducts, but they remain solid and do not acquire a lumen like the alveoli; their connexion with the ducts does not always become lost, but they become isolated in the midst of the glandular substance of the organ.

LESSON XXXVI.

THE KIDNEY, URETER, AND BLADDER.

1. SECTIONS passing through the whole kidney of a small mammal, such as a mouse or rat. These sections show the general arrangement of the organ and the disposition of the tubules and Malpighian corpuscles.

2. Thin sections of the human kidney, if it can be obtained perfectly normal; or failing this, of the kidney of the dog or cat, may next be studied. Some of the sections should be cut parallel with the rays of the medulla; others across their direction. The characters of the epithelium of the several parts of the uriniferous tubules and the structure of the glomeruli are to be made out in these sections.

3. Separate portions of the uriniferous tubules may be studied in teased preparations from a kidney which has been macerated in strong hydrochloric acid for a few hours. This renders it possible to unravel the tubules for some distance.

4. Thick sections of a kidney in which the blood-vessels have been injected. Examine these with a low power of the microscope. Follow the course of the arteries of the cortex sending their branches to the glomeruli, and observe the pencils of capillaries which run from the deeper glomeruli between the straight uriniferous tubules of the boundary zone. Notice the efferent vessels from the rest of the glomeruli breaking up into the network of capillaries distributed to the convoluted tubules.

5. Section across the lower part of the ureter and another across the upper part near the pelvis of the kidney.

6. Section of the urinary bladder vertical to the surface. The organ should be moderately distended by the fixative.

In the sections of the ureter and of the urinary bladder, notice the transitional epithelium resting on a mucous membrane composed of areolar tissue, without glands in most animals; also the muscular coat outside the mucous membrane. In the ureter there is a layer of connective tissue outside the muscular coat, and at the upper part of the bladder a covering of serous membrane.

The above tissues may be fixed in susa or 10 per cent. formol.

THE KIDNEY.

The kidney is a compound tubular gland. To the naked eye it appears formed of two portions—a *cortical* and a *medullary*. Next to the cortex there is a somewhat undefined zone known as the *boundary zone*, characterised by the large number of blood-vessels it contains. The cortex is subdivided in man into about twelve conical portions (*pyramids of Malpighi*), the base of each pyramid being in contact with cortical substance, while the apex projects in the form of a *papilla* into the dilated commencement of the ureter (*pelvis of the kidney*).[1] Both cortex and medulla are

[1] In many animals (*e.g.* dog, cat, rabbit, monkey) the whole kidney is formed of only a single pyramid; in others the pyramids are even more numerous than in man. In some animals the pyramids form distinct portions of kidney substance united by connective tissue and blood-vessels.

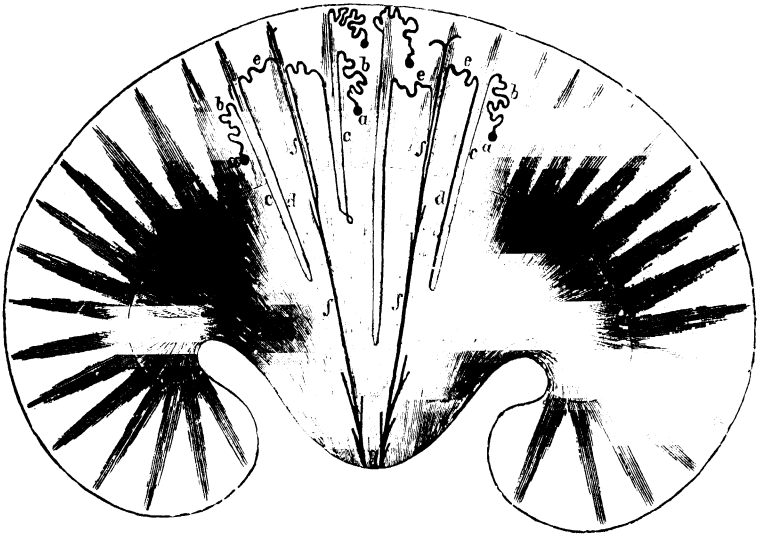

FIG. 549.—DIAGRAM OF THE COURSE OF THE TUBULES IN A UNIPYRAMIDAL KIDNEY, SUCH AS THAT OF THE RABBIT. (Toldt.)

a, Malpighian bodies; *b*, first convoluted tubule; *c*, *d*, looped tube of Henle; *e*, second convoluted tubule *f*, collecting tube; *g*, ducts of Bellini.

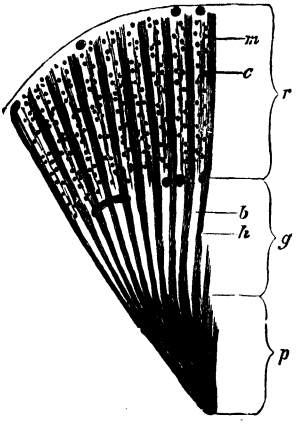

FIG. 550.—SECTION THROUGH PART OF A DOG'S KIDNEY. (Ludwig.)

p, papillary, and *g*, boundary zones of the medulla; *r*, cortical layer; *h*, bundles of tubules in the boundary layer, separated by spaces, *b*, containing bunches of vessels (not here represented), and prolonged into the cortex as the medullary rays, *m*; *c*, intervals of cortex, composed chiefly of convoluted tubules, with irregular rows of glomeruli, between the medullary rays.

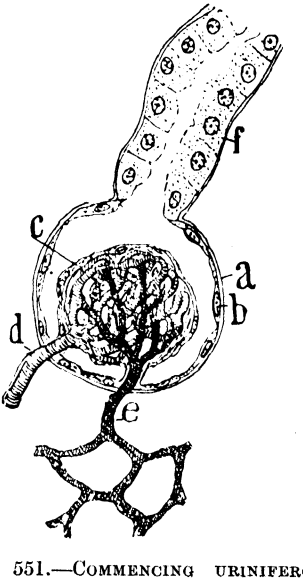

FIG. 551.—COMMENCING URINIFEROUS TUBULE OF THE KIDNEY, SHOWING ITS RELATION TO A GLOMERULUS. (R. y Cajal.) Diagrammatic.

a, capsule of glomerulus; b, its epithelial lining; c, epithelium covering glomerulus; d, afferent vessel of glomerulus; e, efferent vessel breaking up into capillaries; f, convoluted tubule passing away from the glomerulus.

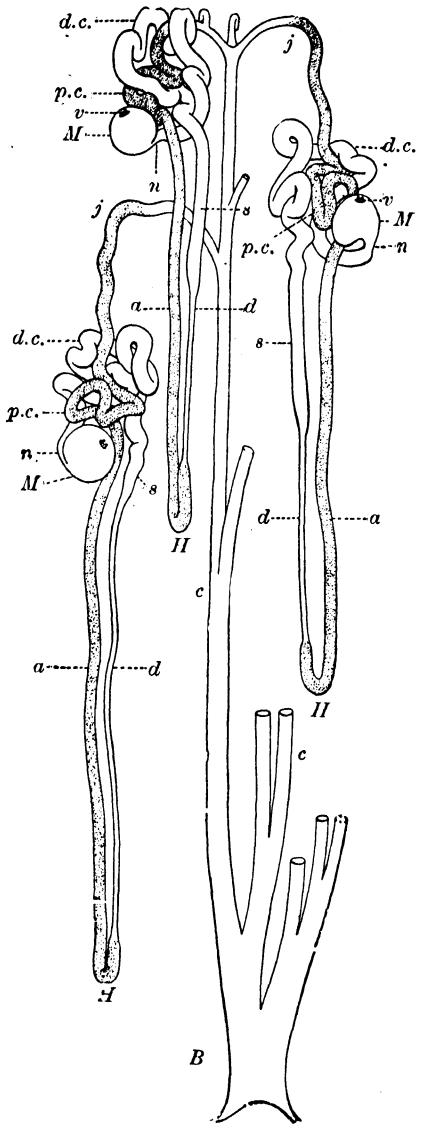

FIG. 552.—PLAN OF THE ARRANGEMENT OF THE URINIFEROUS TUBULES. (Huber.)

M, Malpighian corpuscles; *v*, point of entrance of vessels of glomerulus; *n*, neck; *d.c.*, distal convoluted tubule, which arises from the Malpighian corpuscle; *s*, spiral tubule into which it is continued; *d*, narrow descending limb of loop of Henle; *H*, loop of Henle (this is sometimes formed by the narrow part of the looped tubule, but is here represented as formed by the wider part); *a*, wider ascending limb of loop of Henle; this passes back to the neighbourhood of the same Malpighian corpuscle, often becoming irregular and zigzag at its upper end. Here it becomes continuous with the proximal convoluted tubule, *p.c.*, which eventually passes into the junctional tubule, *j*, by which it is connected with a collecting tubule, *c*. *B*, duct of Bellini, receiving a number of conjoined collecting tubules and opening at a papilla. The number of divisions of the collecting tubes is far greater than represented in the diagram.

composed entirely of tubules—the *uriniferous tubules*—which have a straight direction in the medulla and a contorted arrangement in the cortex, but groups of straight tubules also pass from the medulla through the thickness of the cortex as the so-called *medullary rays* (figs. 549, 553, 554).

The uriniferous tubules begin in the cortical part of the organ in dilatations, each enclosing a tuft or glomerulus of convoluted capillary blood-vessels (*corpuscles of Malpighi*), the dilated commencement of the tubule being known as the *capsule* (figs. 551, 552). The capsule is lined by flattened epithelium; outside the epithelium its wall is formed by a basement membrane continuous with that of the tubules. The *glomerulus* is lobulated (figs. 553, 559), the lobules being united by the branches of the afferent and efferent vessels; it is covered by a flattened epithelium reflected from that lining the capsule (fig. 553); this epithelium dips in between the lobules and comes in close contact with the capillaries (v. Möllendorf). The glomeruli near the medulla are larger than the rest and have more lobules. The capillary-wall in all the glomeruli is a syncytium, showing no cell-outlines in silver preparations (Drasch).

The *tubule* leaves the capsule by a *neck* (fig. 552, *n*) which is, however, rarely narrower than the rest of the tubule in mammals. In some animals (*e.g.* frog) the

neck is long, and has ciliated epithelium. The tubule is at first convoluted (*first or distal convoluted tubule*).[1] It then becomes nearly straight or slightly spiral only (*spiral tubule*) and rapidly narrowing passes down into the medulla towards the dilated commencement of the ureter as the *descending limb of the looped tubule of Henle.* It does not at once, however, open directly into the pelvis of the kidney, but before reaching the end of the papilla it turns round in the form of a loop (*loop of Henle*), and passes

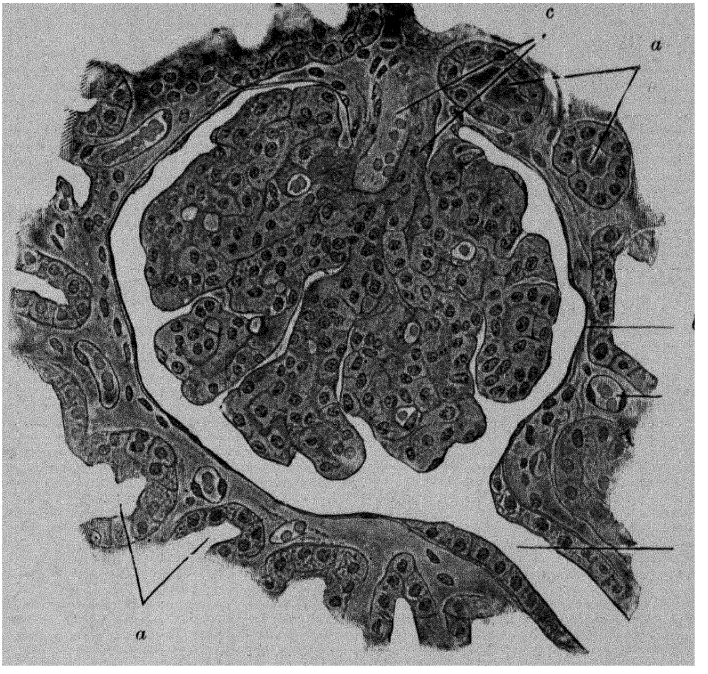

FIG. 553.—A MALPIGHIAN CORPUSCLE FROM THE KIDNEY OF THE MONKEY. (Szymonowicz.) × 350.

a, *a*, sections of convoluted tubules; *a'*, commencement of convoluted tube from capsule; *b*, capsule; *c*, afferent and efferent vessels of glomerulus.

upwards again towards the cortex, parallel with its former course, and larger than before (*ascending limb of looped tubule of Henle*). Arrived at the cortex it approaches close to the capsule from which the tubule took origin, but at a point opposite to the origin, viz. near the afferent and efferent vessels of the glomerulus (Golgi). It then becomes larger and irregularly zigzag (*zigzag or irregular tubule*), and again somewhat convoluted (*second or proximal convoluted tubule*). Eventually it straightens out again and narrowing into

[1] Many authors speak of this first convoluted tubule as the 'proximal' one, and the second as 'distal.' But this is manifestly incorrect since the blind extremity of a uriniferous tubule corresponds with that of a finger of a glove and is therefore the *distal* end.

a small vessel (*junctional tubule*), joins a *straight or collecting tubule*. The last-named unites with others to form larger collecting tubes which pass through the medullary substance of the kidney to open at the papilla as the *ducts of Bellini* (fig. 552). It is roughly computed that each duct of Bellini

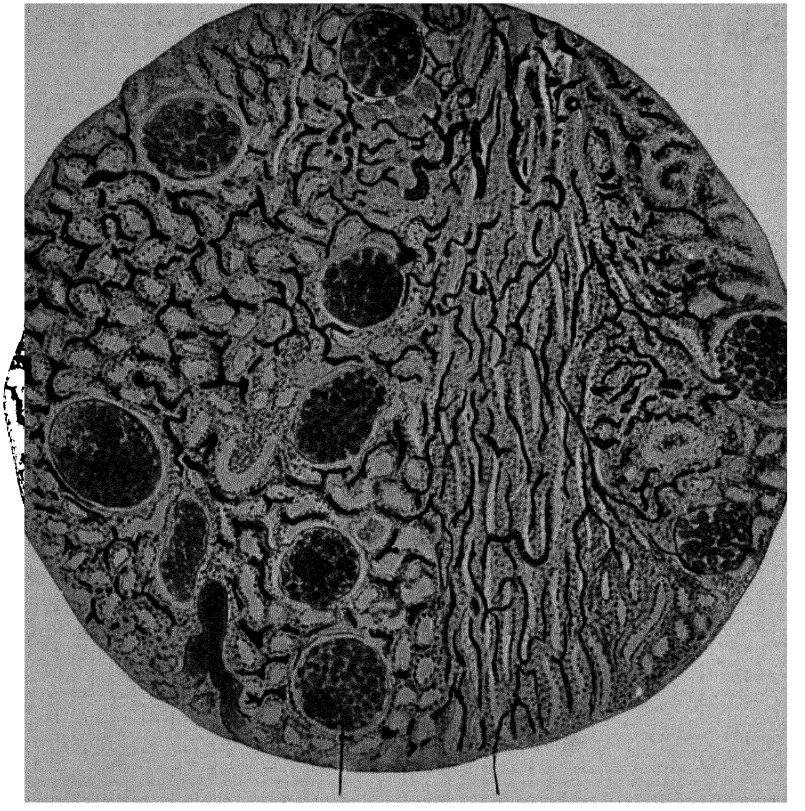

FIG. 554.—PART OF A SECTION THROUGH THE CORTEX OF A HUMAN KIDNEY, THE BLOOD-VESSELS OF WHICH HAVE BEEN INJECTED. (Disse.)

gl., a glomerulus; *m.r.*, section of a medullary ray.

of ducts of Bellini this would give about 4½ million glomeruli in the human kidney (Traut, 1924).

The tubules are throughout bounded by a basement-membrane, which is lined by epithelium; the characters of the epithelium-cells vary in the different parts of a tubule. In the *capsule* (fig. 553), as already noted, the epithelium is flattened and is reflected over the glomerulus. In some animals (*e.g.* mouse) the thicker epithelium of the convoluted tube is prolonged a little way into the capsule. In the *first* (*distal*) *convoluted* and *spiral tubules* the

epithelium is thick, and the cells contain abundant mitochondria; these have a tendency to be arranged in longitudinal rows as in the cells of the salivary ducts (rodded appearance, fig. 555). Granular mitochondria are also present. The cells often exhibit a brush of cilium-like processes projecting into the lumen, but these are not vibratile. In the narrow *descending limb of the looped tubules*, and sometimes in the *loop* itself, the cells are clear and flattened (fig. 556); mitochondria are absent or rare; the lumen is relatively large; but usually in the *loop* and always in the *ascending limb* the cells again acquire rod-shaped or granular mitochondria and may nearly fill the lumen. The arrangement of the mitochondria in lines perpendicular to the basement-membrane is still more marked in the *zigzag tubules*, and a similar structure is present also in the second or proximal *convoluted tubules* into which these pass. On the other hand, the *junctional tubule* has a larger lumen and in it the striated epithelium gives place to clear flattened cells. The *collecting tubes* have also a very distinct lumen and are lined by clear cubical or columnar epithelium-cells (fig. 561, *s*), in which mitochondria are scanty or absent.

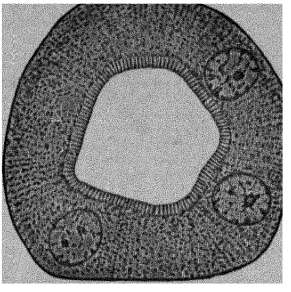

FIG. 555.—SECTION OF A CONVULUTED TUBULE OF THE RABBIT'S KIDNEY, SHOWING THE STRIATED ARRANGEMENT OF THE MITOCHONDRIA IN THE EPITHELIUM. (Szymonowicz.)

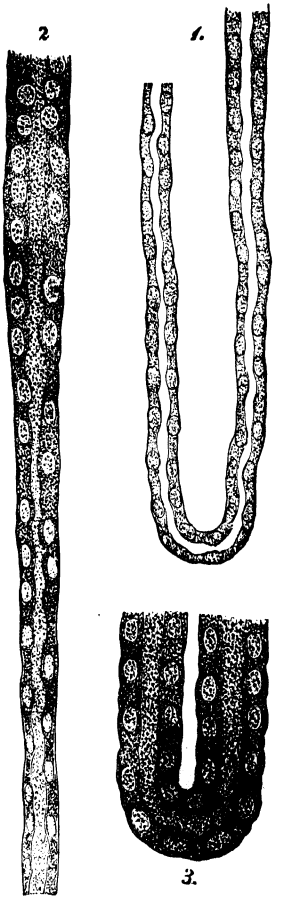

FIG. 556.—1. LOOP OF HENLE, FORMED BY THE NARROW OR DESCENDING LIMB OF THE LOOP. 2. PASSAGE OF SPIRAL LIMB INTO THE NARROW DESCENDING TUBE OF HENLE. 3. LOOP FORMED BY THE BROAD OR ASCENDING LIMB. (Kölliker.) × 400.

All from the pig's kidney. Isolation after treatment with hydrochloric acid.

Herring has pointed out that in sections of the kidney of Elasmobranch fishes (*Raia batis*) droplets of secretion may be seen emerging from the free ends of the epithelium-cells of the uriniferous tubules (fig. 557) and passing

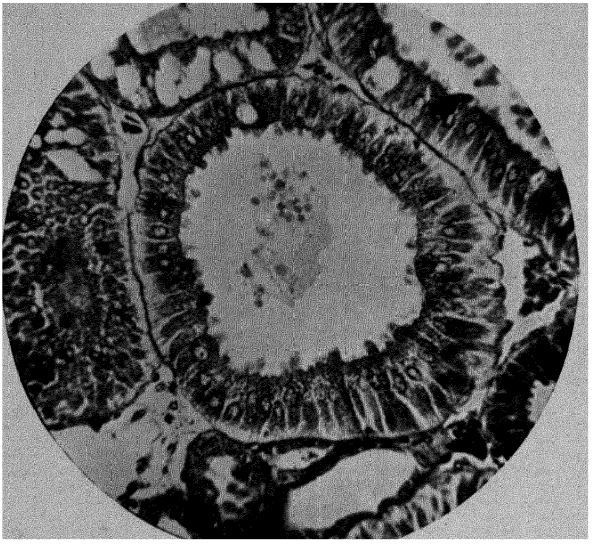

FIG. 557.—SECTION OF A URINIFEROUS TUBULE OF RAY SHOWING DROPLETS OF SECRETION FIXED AS THEY ARE PASSING OUT OF THE EPITHELIUM-CELLS INTO THE LUMEN OF THE TUBULE. Photographed from a preparation by P. T. Herring. × 200.

PORTION OF TUBULE.	NATURE OF EPITHELIUM.	POSITION OF TUBULE
Capsule	Flattened, reflected over glomerulus, where its cells are said to form a syncytium	Labyrinth of cortex.[1]
First or distal convoluted tubule	Cubical, granular, with appearance of fibrillation ('rodded'), the cells interlocking	Labyrinth of cortex.
Spiral tubule . .	Like the last	Medullary ray of cortex.
Descending limb of looped tubule	Clear flattened cells . . .	Boundary zone and partly papillary zone of medulla.
Loop of Henle . .	Like the last (or may be like the ascending limb)	Papillary zone of medulla.
Ascending limb of looped tubule	Cubical, granular; the cells sometimes imbricated	Medulla, and medullary ray of cortex.
Zigzag tubule . .	Cells strongly 'rodded'; varying height, lumen small	Labyrinth of cortex.
Second or proximal convoluted tubule	Similar to distal convoluted tubule, but cells are longer, with larger nuclei, and are more refractive	Labyrinth of cortex.
Junctional tubule .	Clear flattened and cubical cells .	Labyrinth, passing to medullary ray
Straight or collecting tubule	Clear cubical and columnar cells .	Medullary ray and medulla.
Duct of Bellini . .	Clear columnar cells becoming cubical near the mouth	Opens at apex of papilla.

[1] The part of the cortex between and surrounding the medullary rays is so named.

into the lumen. By microchemical tests it can be shown that such droplets contain urea (J. D. S. Cameron), which is well known to be an important constituent of the blood and lymph of these fishes.

The table on the opposite page gives an enumeration of the parts which compose a uriniferous tubule, and the nature of the epithelium in each part.

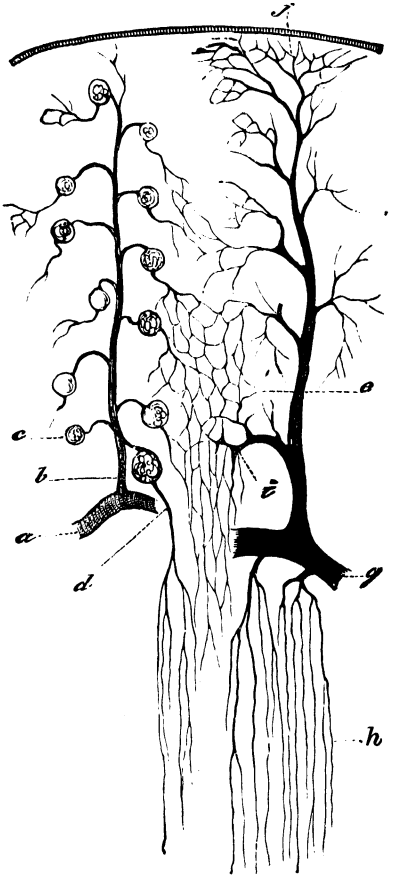

FIG. 558.—DIAGRAM OF BLOOD SUPPLY OF KIDNEY. (Modified from Cadiat.)

a, arterial arch; *b*, cortical artery; *c*, glomeruli, with afferent vessels entering them from the cortical artery and efferent vessels leaving them to break up into the capillary network (*e*) around the tubules; *d*, efferent vessel of one of the glomeruli near the medulla, furnishing capillaries to the medullary tubules; *g*, venous arch; *h*, venous capillaries of medulla; *i*, cortical vein; *j*, vena stellula.

The renal artery divides into branches on entering the organ; these branches pass towards the cortex, forming arched vessels between the cortex and the medulla. The arteries contain much elastic tissue in their inner and outer coats (fig. 298). In the former is a well-marked fenestrated membrane (fig. 304). The corresponding branches of the renal vein are more distinctly arched. From the arterial arches there pass through the

cortex the *cortical* or *interlobular arteries*, which give off at intervals (in some animals from one side only) small arterioles (*afferent vessels of the glomeruli*),

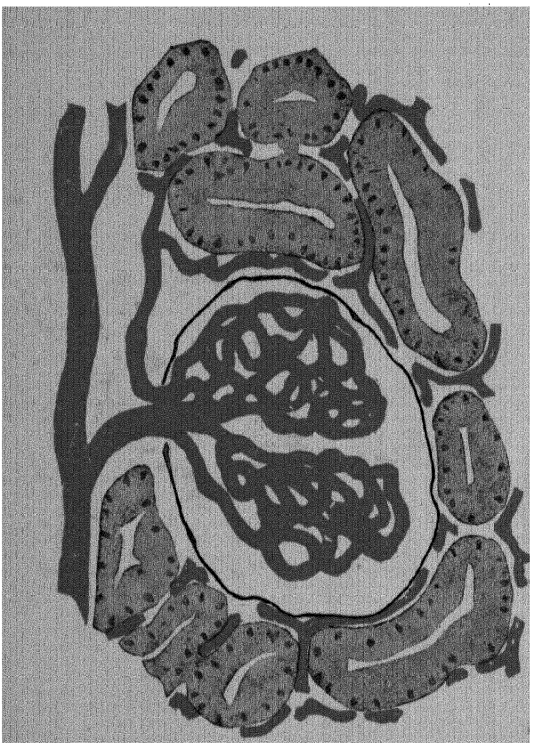

FIG. 559.—FROM AN INJECTED KIDNEY. (Prenant and Bouin.)

Cortical arteriole on the left giving off an afferent vessel to the glomerulus. From this a (smaller) efferent vessel comes off and joins the capillaries surrounding the tubules.

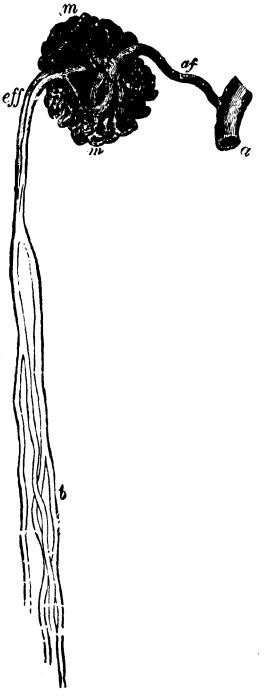

FIG. 560.—A GLOMERULUS FROM THE PART OF THE CORTEX OF THE HORSE'S KIDNEY NEAREST THE MEDULLA: INJECTED. (Bowman.) × 70.

a, cortical artery; *af*, afferent vessel of glomerulus; *m*, *m*, glomerulus; *eff*, efferent vessel breaking up into a pencil of capillaries, *b*, which pass down between the tubules of the medulla.

each of which enters the dilated commencement of a uriniferous tubule, within which its capillaries form a glomerulus (fig. 559). From the glomerulus a somewhat smaller *efferent vessel* passes out, and this at once again breaks up into capillaries, which are distributed amongst the tubules of the cortex. The blood is collected by veins which run parallel with the cortical arteries but not in juxtaposition with them. These veins join the venous arches between the cortex and medulla. They also receive blood from certain other veins which arise by radicles having a somewhat stellate arrangement near the capsule (*venæ stellulæ*).

The medulla derives its blood-supply from the efferent vessels of the glomeruli which are near the medulla (figs. 558, 560). It is doubtful if any

vessels come off directly from the arterial arches to supply the medulla, although the existence of such vessels was formerly assumed. But Morrison

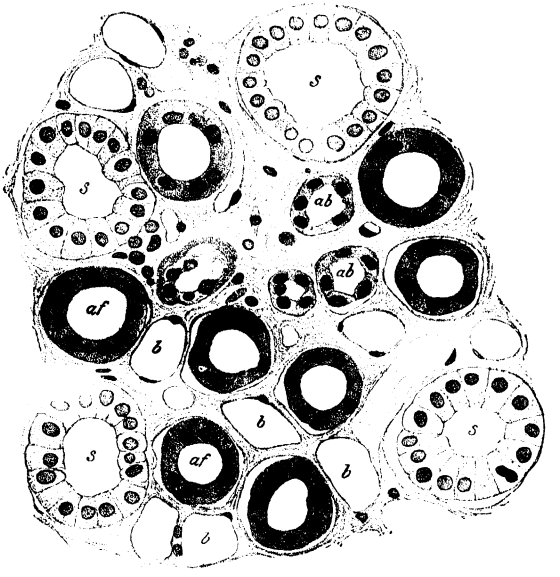

FIG. 561.—SECTION ACROSS THE MIDDLE OF A PYRAMID OF MALPIGHI: HUMAN. (Kölliker.) × 325.

ab, narrow descending tubes of Henle; *af*, wider ascending tubes of Henle; *b*, capillaries; *s*, collecting tubes.

(1926) states that in forty-two cases in man which he examined he was unable to find any such, nor was he more successful in other mammals. This obser-

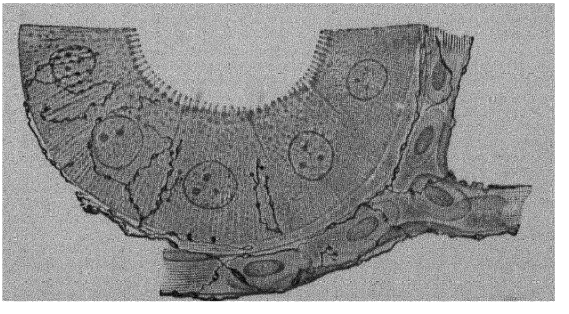

FIG. 562.—NERVE-FIBRILS ENDING OVER CAPILLARY BLOOD-VESSELS AND AMONGST THE EPITHELIUM-CELLS OF A CONVOLUTED TUBE OF THE FROG'S KIDNEY. (Smirnow.)

vation, which is confirmed by Moore (1928), necessarily implies that the circulation in the kidney is wholly glomerular, as indeed Bowman supposed to be the case. The vessels supply a capillary network with elongated meshes which pervades the medulla, and which terminates in a plexus of

somewhat larger venous capillaries in the papilla. From these capillaries the venules of the medulla collect the blood, and pass, accompanying the straight arterioles, into the venous arches between the cortex and medulla. The groups of small arteries and veins (*vasa recta*) in the part of the medulla nearest to the cortex alternate with groups of the uriniferous tubules; this arrangement confers a striated aspect, blood-red in the fresh kidney, upon that part of the medulla (*boundary zone*).

Between the uriniferous tubules, and supporting the blood-vessels, is a

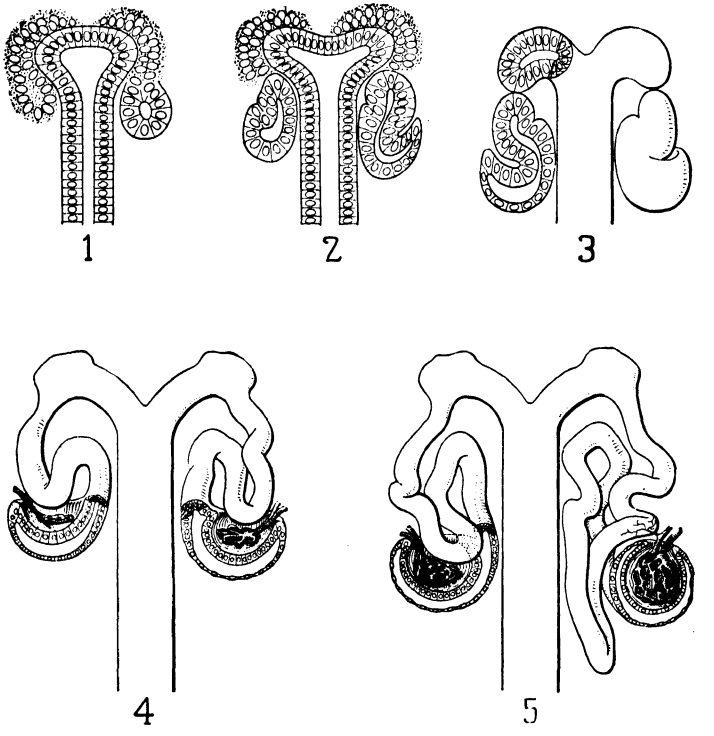

FIG. 563.—FIVE DIAGRAMS TO ILLUSTRATE THE MODE OF DEVELOPMENT OF THE URINIFEROUS TUBULES AND THE GLOMERULI. (Huber.)

Each of the five (except 3) exhibits two stages.

variable amount of connective tissue, greatest in quantity in the papillæ (fig. 561); it contains cleft-like lymphatics.

Nerve-fibrils ramify amongst the epithelium-cells of the tubules (fig. 562) but most of the nerves to the kidney are distributed to its blood-vessels.

DEVELOPMENT OF THE URINIFEROUS TUBULES.

The ducts of Bellini and the collecting tubules are derived as hollow sprouts from the enlarged upper end of the ureter, which in its turn is formed as a bud from the Wolffian duct of the embryo. The rest of the uriniferous tubule, including the Malpighian corpuscle, is formed from a hollow S-shaped island of cells

which become differentiated in the mesoderm near the blind end of a collecting tubule. The lower part of the S forms a spoon-shaped structure, within the bowl of which the vessels of the glomeruli are developed; the sides of the bowl then grow round and completely enclose them. The upper part of the S forms a convoluted tubule which before long makes connexion with the previously blind end of the forked collecting tubule. At first there is no sign of the looped tubule, but this presently grows down from the convoluted tubule, very much as if a part of this tube had been drawn out towards the papilla. The several stages of formation of the uriniferous tubule are shown in the diagrams marked 1 to 5 in fig. 563. These diagrams exhibit nine stages of development of the tubules, since in every one, except diagram 3, an earlier stage is represented upon the left-hand side, and a later upon the right-hand side.

THE URETER AND BLADDER.

The **ureter** (fig. 564) is a muscular tube lined by mucous membrane. The *muscular coat* consists of two layers of plain muscular tissue, an outer

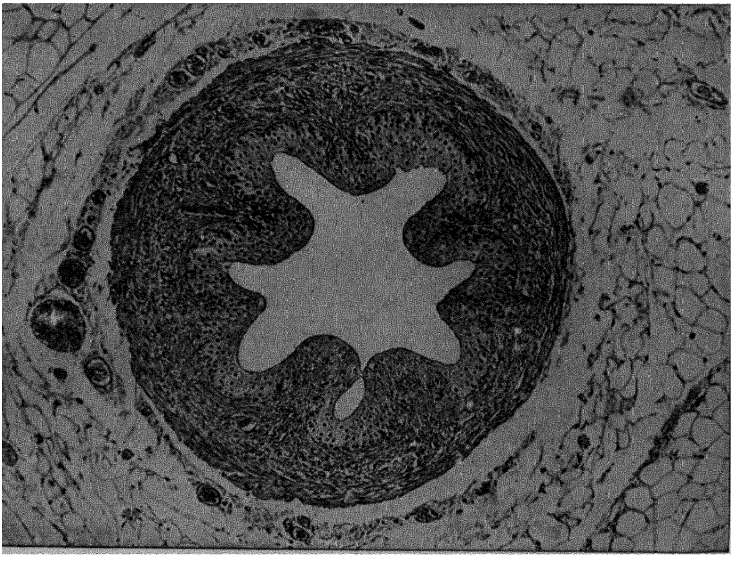

FIG. 564.—SECTION ACROSS URETER: DOG. (E. Sharpey-Schafer.) × 90. Photograph.

circular, and an inner longitudinal. In the lower part there are some longitudinal bundles external to the circular. Outside the muscular coat is a layer of connective tissue in which the blood-vessels and nerves ramify before entering the muscular layer.

The *mucous membrane* is composed of areolar tissue, and is lined by transitional epithelium, like that of the bladder.

The **urinary bladder** has a muscular wall lined by a thick mucous membrane and covered in part by a serous coat.

The *muscular wall* consists of three layers, but the innermost is incomplete. The principal fibres run longitudinally and circularly; the circular

fibres are collected into a layer of some thickness which immediately surrounds the commencement of the urethra. The *mucous membrane* is lined by a transitional epithelium (fig. 565). The shape and structure o



FIG. 565.—SECTION OF PART OF WALL OF BASE OF BLADDER: HUMAN. (Lendorf.) × 230
The section passes through a glandular invagination of the epithelium. *ep*, epithelium; *c*, corium.

the cells have already been studied (p. 77). Many of the superficial cell have two nuclei. Gland-like invaginations of the epithelium are occasionally found near the base of the bladder in man (fig. 565); in the bladder of som animals well-marked glands constantly occur.

The nerves to the bladder join gangliated plexuses; they are distributed t the muscular tissue and blood-vessels: some are said to enter the epithelium

LESSON XXXVII.

THE MALE GENERATIVE ORGANS.

1. SECTIONS across penis (child or monkey). The blood-spaces of the organ should be injected with the fixative so as the better to exhibit the arrangement of the structures which constitute the erectile tissue. Notice the large venous sinuses of the corpora cavernosa and the smaller spaces of the corpus spongiosum; surrounded by the latter is seen the (flattened) tube of the urethra.

2. Section of prostate gland (child or monkey), fixed in susa or formol. Notice the glandular spaces, the plain muscular tissue and the character of the urethral epithelium.

3. Section of testicle and epididymis. The sections may be made from testicles (rat, cat, man) fixed in susa or formol; they can be stained with hæmatoxylin and eosin or with iron-hæmatoxylin. In these sections notice the strong capsule surrounding the gland, the substance of which consists of tubules which are cut in various planes; and the epithelium of the tubules, which is in different phases of development in different tubules. Observe the strands of polyhedral interstitial cells, much more abundant in some animals than in others, lying in the loose tissue between the tubules; also the lymphatic clefts in that tissue. Notice in sections through the epididymis the ciliated epithelium, and spermatozoa within the tube.

Sketch carefully under a high power the contents of some of the seminiferous tubules to illustrate the mode of formation of spermatozoa.

4. Section of vesicula seminalis, fixed in susa or formol and stained with hæmatoxylin and eosin or with iron-hæmatoxylin. Notice the two-layered epithelium, the more superficial cells long and columnar but not ciliated; the deeper cells short and swollen out by clear fluid.

5. Examination of spermatozoa. Spermatozoa may be examined in Ringer's solution and their movements studied on the warm stage. To display their structure a very high power of the microscope is necessary. They may be preserved and stained as 'film' or 'smear' preparations (p. 33, §11).

THE PENIS, URETHRA AND PROSTATE.

The **penis** (fig. 566) is mostly formed of erectile tissue collected into three principal masses—the two *corpora cavernosa*, one on each side but conjoined in the middle line, and the *corpus spongiosum* inferiorly. The corpus spongiosum is expanded at the extremity of the penis to form the glans. It is traversed throughout by the urethra, which extends from the bladder to the apex of the glans. Each of these masses is bounded by a strong capsule of fibrous and plain muscular tissue, containing many elastic fibres and sending in strong septa or trabeculæ of the same tissues, which form the boundaries of the cavernous spaces of the erectile tissue (fig. 567).

Blood-vessels.—The arteries of the tissue run in the trabeculæ; the capillaries open into the cavernous spaces which, on the other hand, are

connected with efferent veins. The arteries can sometimes in injected specimens be observed to form looped or twisted projections into the cavernous spaces into which they open directly (*helicine arteries*). The arteries of the cavernous tissue often show localised thicknesses of the inner coat. Many of the veins have longitudinal muscle-fibres in the inner coat which form pad-like projections into the lumen.

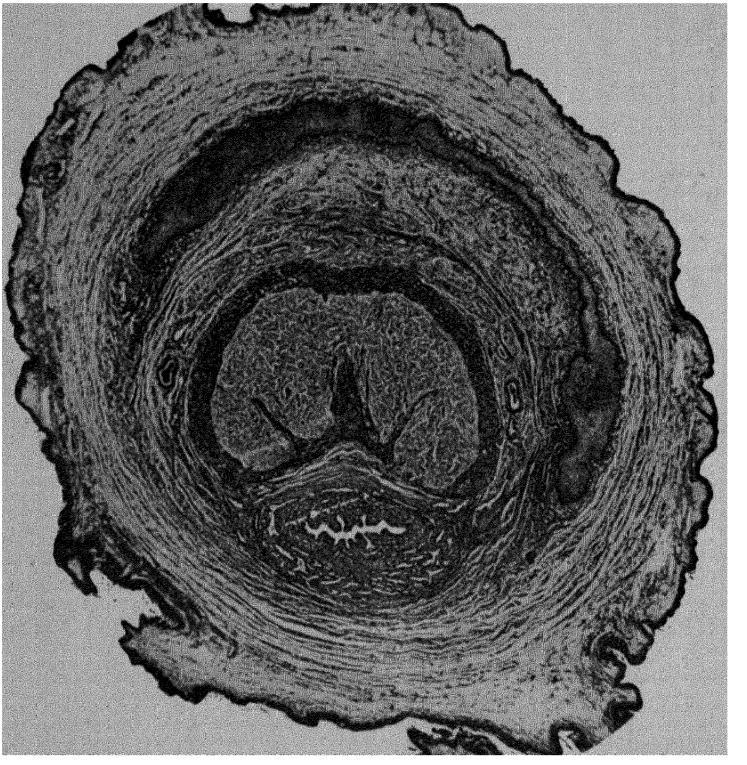

FIG. 566.—TRANSVERSE SECTION OF PENIS: CHILD. (H. M. Carleton.) × 10.

The conjoined corpora cavernosa, enclosed by their capsule, occupy the middle of the section: below them is the irregular lumen of the urethra surrounded by corpus spongiosum, which is continued round the corpora cavernosa. Outside this is the skin of the body of the penis, and separated from it above and on the right side by an invagination of epidermis is the prepuce, which is continuous below with the integument of the body of the organ.

The integument, especially that of the glans, contains numerous special nerve-end organs of the nature of end-bulbs. Pacinian bodies are found in the subcutaneous tissue of the body of the penis.

Lymph-vessels are numerous in the integument of the organ and in the submucous tissue of the urethra.

Urethra.—The lumen of the urethra appears in sections across the penis in the form of an irregular cleft in the middle of the corpus spongiosum (figs. 566, 568). It is lined in the prostatic part by transitional, but elsewhere

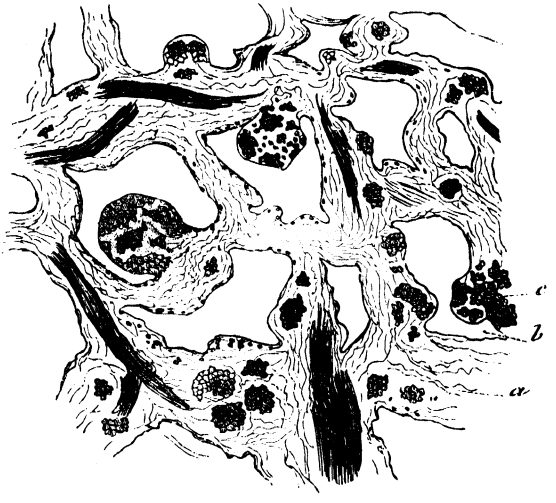

FIG. 567.—SECTION OF ERECTILE TISSUE. (Cadiat.)

a, trabeculæ of connective tissue, with elastic fibres, and bundles of plain muscular tissue, some cut across (*c*); *b*, blood-sinuses.

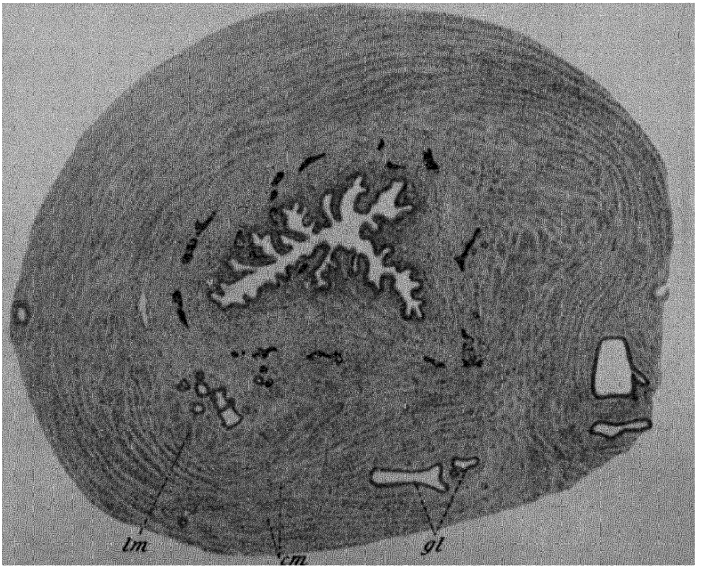

FIG. 568.—SECTION ACROSS MEMBRANOUS PART OF MALE URETHRA. (Sobotta.) × 18.

lm, longitudinal muscle fibres; *cm*, circular muscle fibres; *gl*, glands of Littré.

by a columnar epithelium (consisting of more than one layer of cells), except near its orifice, where the epithelium is scaly stratified. The urethral epithelium rests upon a very vascular mucous membrane. Outside this is a coat of submucous tissue, with two layers of plain muscular fibre—an inner longitudinal and an outer circular. Some of the fibres are cross-striated. Outside the muscular coat is a close plexus of small veins connected with, and forming part of, the corpus spongiosum.

The *mucous membrane* of the urethra is beset with small mucous glands (fig. 568), simple and compound (*glands of Littré*). There are also a number of oblique recesses termed *lacunæ*. Besides these small glands and glandular recesses, two compound racemose glands open into the bulbous portion of

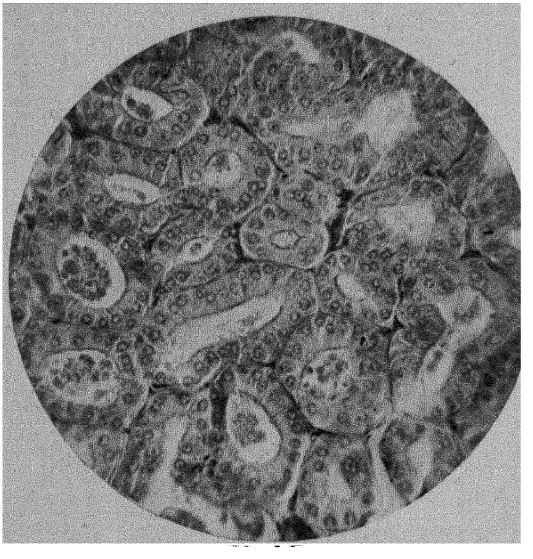

FIG. 569.—COWPER'S GLAND: CHILD. (H. M. Carleton.) × 150.
Preparation by F. Haynes.

the urethra in the male (*Cowper's glands*). Their acini (fig. 569) are lined by clear columnar cells like those of the glands of Littré, and yield a mucus-like secretion.

The **prostate,** which surrounds the commencement of the urethra in the male, is a muscular and glandular mass, the glands of which are composed of wide tubular alveoli (fig. 570); their folded walls are lined by non-ciliated columnar epithelium, with smaller cells lying between them and the basement-membrane. Their ducts open upon the floor of the urethra. In older subjects the alveoli often contain colloid concretions, which may undergo calcification. The muscular tissue is abundant and of the plain variety.

The prostate is pierced by the two common ejaculatory ducts which open one on each side of a median elevation of the mucous membrane of the floor of the urethra. Between these orifices is an aperture leading into the prostatic utricle (*uterus masculinus*). The blood-vessels and nerves of the

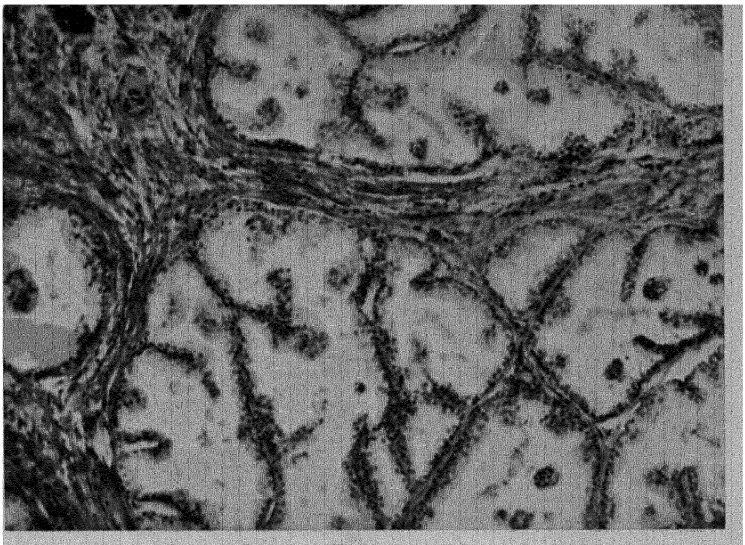

FIG. 570.—PROSTATE: HUMAN. (E. Sharpey-Schafer.) × 90. Photograph.

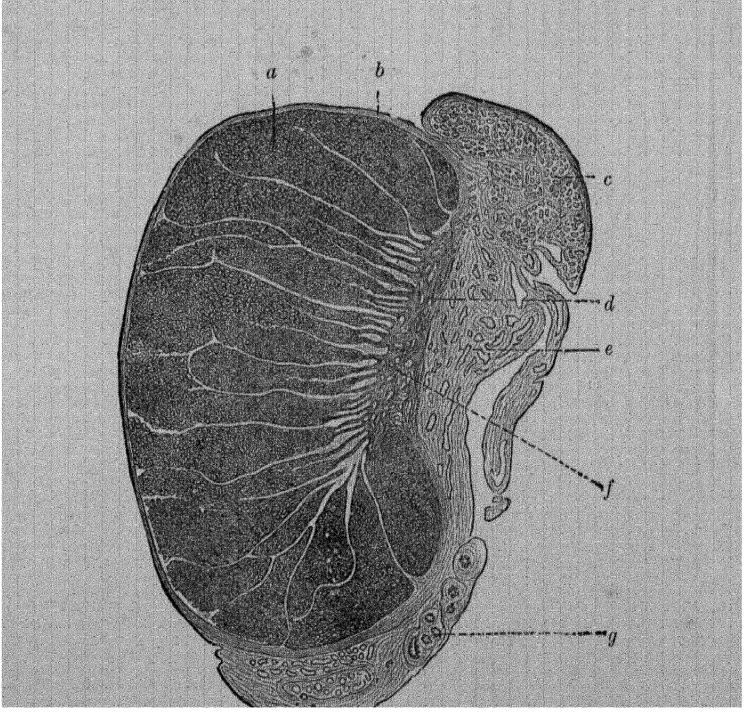

FIG. 571.—SECTION OF HUMAN TESTIS AND EPIDIDYMIS. (Böhm and v. Davidoff.)

a, glandular substance divided into lobules by septa of connective tissue; *b*, tunica albuginea; *c*, head of epididymis; *d*, rete testis; *e*, middle part or body of epididymis; *f*, mediastinum giving origin to the septa; *g*, sections of the commencing vas deferens.

prostate are numerous. The nerves are provided with small ganglia and are distributed partly to the muscular tissue, partly to the glands; others, which are sensory, pass to the capsule and to the wall of the urethra. The sensory nerves end in plexuses and in terminal corpuscles like simple Pacinian bodies.

The Testicle.

The **testicle** is enclosed by a strong fibrous capsule, the *tunica albuginea* (figs. 571, 572, 573). This is covered externally with a layer of serous epithelium reflected from the *tunica vaginalis*. From its inner surface there proceed fibrous processes or *trabeculæ*, which imperfectly subdivide the organ into lobules. Posteriorly the capsule is prolonged into the interior

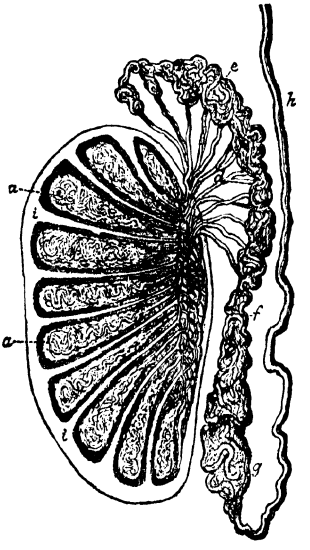

Fig. 572.—Plan of testis and epididymis.

a, seminiferous tubules; *b*, straight tubules; *c*, rete testis; *d*, efferent tubules; *e*, head; *f*, middle part; *g*, lower end of epididymis; *h*, vas deferens; *i*, tunica albuginea.

of the gland in the form of a mass of fibrous tissue, which is known as the *mediastinum testis*. Attached to the posterior margin of the body of the gland is a mass (*epididymis*) which when investigated is found to consist of a single convoluted tube, receiving at its upper end the *efferent ducts* of the testicle and prolonged at its lower end into a thick-walled muscular tube, the *vas deferens*, which conducts the secretion to the urethra.

The glandular substance of the testicle is wholly made up of *convoluted seminiferous tubules* (*tubuli contorti*), which when unravelled are of very considerable length. Each commences near the tunica albuginea, and after many windings terminates, usually after joining one or two others, in a *straight tubule*. The straight tubules (*tubuli recti*) pass into the mediastinum, and there form by their union a network of intercommunicating vessels of varying size, which is known as the *rete testis* (fig. 574). From the rete a limited

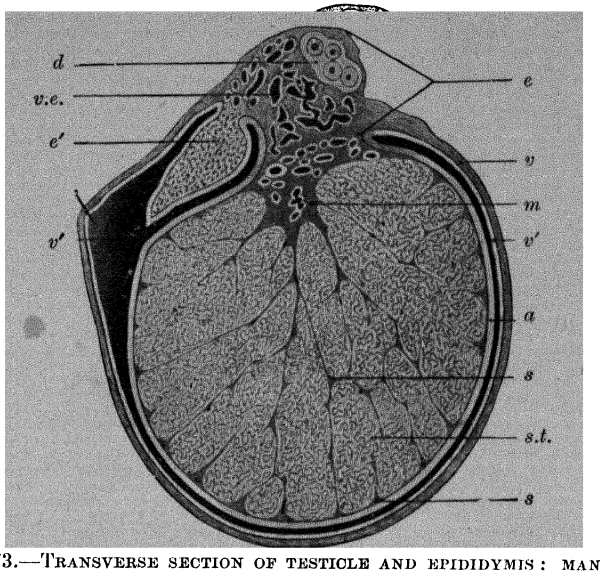

FIG. 573.—TRANSVERSE SECTION OF TESTICLE AND EPIDIDYMIS: MAN. (Eberth.)

a, tunica albuginea; *s.t.*, seminiferous tubules; *s*, *s*, trabeculæ dividing the gland into lobules; *v*, tunica vaginalis; *v'*, cavity of tunica vaginalis; *m*, mediastinum testis; *e*, epididymis; *e'*, caput epididymis; *d*, vas deferens (cut four times); *v.e.*, vasa efferentia.

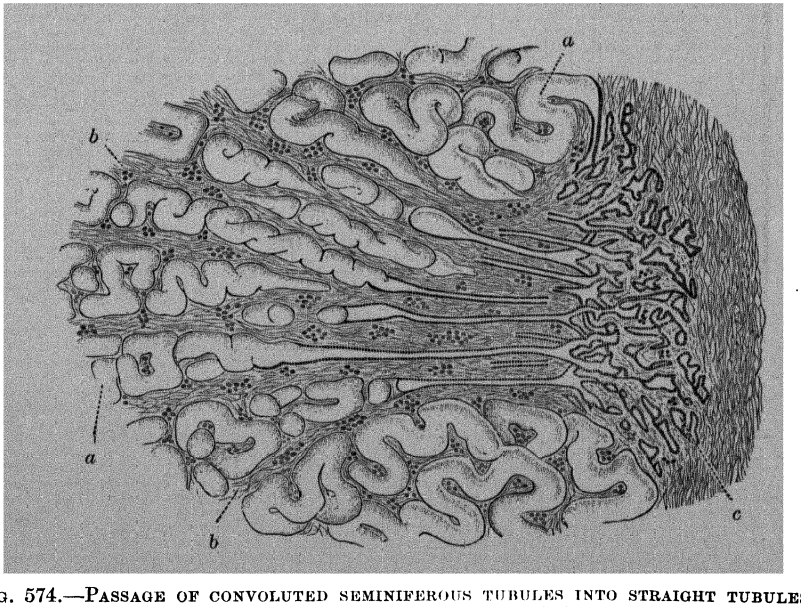

FIG. 574.—PASSAGE OF CONVOLUTED SEMINIFEROUS TUBULES INTO STRAIGHT TUBULES AND OF THESE INTO THE RETE TESTIS. (Mihalkowicz.)

a, *a*, seminiferous tubules; *b*, *b*, fibrous stroma continued from the mediastinum testis; *c*, rete testis.

number of *efferent ducts* or *tubules* (*vasa efferentia*) arise, and after a few convolutions pass into the tube of the epididymis.

The *straight tubules* which lead from the convoluted seminiferous tubes into the rete testis are lined by only a single layer of clear flattened or cubical epithelium cells. The tubules of the *rete* also have a simple epithelial lining; both in these and in the straight tubules a basement-membrane is absent, the epithelium being supported directly by the fibrous connective tissue of the mediastinum.

The *efferent tubules* which pass from the rete to the epididymis are lined by columnar ciliated epithelium. In man their lumen is irregular in section; the inner surface is pitted with glandular depressions lined by short clear non-ciliated cells.

In the embryo the seminiferous tubules, which grow from the germinal epithelium, intercommunicate and form a network — but subsequently the side branches disappear and only the main stems persist as the seminiferous tubules. But even in the adult anastomoses between the tubules may occur.

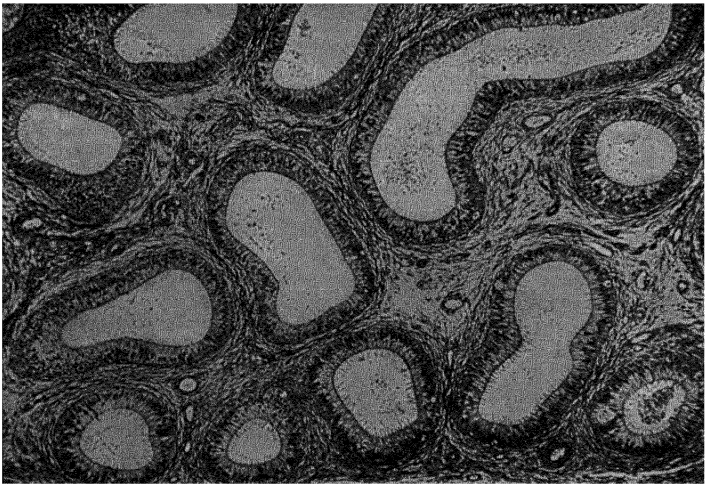

FIG. 575.—FROM A SECTION OF THE EPIDIDYMIS: HUMAN. (E. Sharpey-Schafer.) × 60. Photograph. Preparation by M. Heidenhain.

Epididymis.—This is composed of a single convoluted tube 6 to 8 metres long which receives the vasa efferentia above, and below is continued into the vas deferens. The tube is lined by long columnar cells with oval nuclei, having at their bases smaller polyhedral cells with spherical nuclei (figs. 575, 576). The columnar cells are provided with bunches of cilia projecting into the lumen of the tube; it is alleged that these cilia are not always vibratile. The cells exhibit a well-marked Golgi-apparatus (see fig. 10, p. 8).

The **vas deferens** is a thick-walled tube, having an outer layer formed of longitudinal bundles of plain muscular tissue, and an inner equally

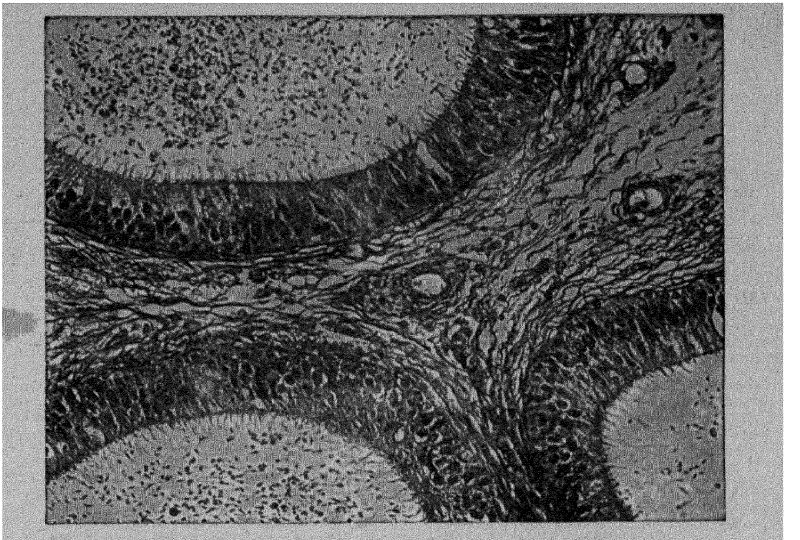

FIG. 576.—EPIDIDYMIS: HUMAN. (E. Sharpey-Schafer.) × 200. Photograph. Preparation by M. Heidenhain.

The tubules contain spermatozoa.

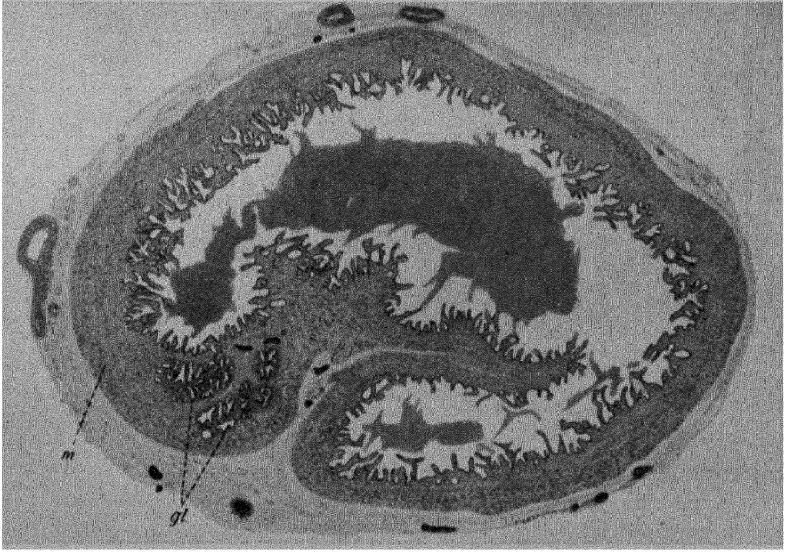

FIG. 577.—SECTION OF SEMINAL VESICLE: MAN. (Sobotta.) × 12.

m, muscular coat; *gl*, gland-like invaginations of mucous membrane.

thick layer of circular bundles of the same tissue; within this again is a thinner layer of longitudinal muscle. There is a good deal of connective and elastic tissue between the muscular bundles. The tube is lined by a mucous membrane, the inner surface of which is covered by columnar non-ciliated epithelium.

The **vesiculæ seminales** are glandular structures (fig. 577), consisting on each side of a main part, with several accessory parts, each part being composed of a convoluted tube of considerable length when unravelled. The duct joins the corresponding vas deferens. The tubules are lined by long non-ciliated columnar epithelium cells. The tubules, which are convoluted, are held together by connective tissue containing many blood-vessels and

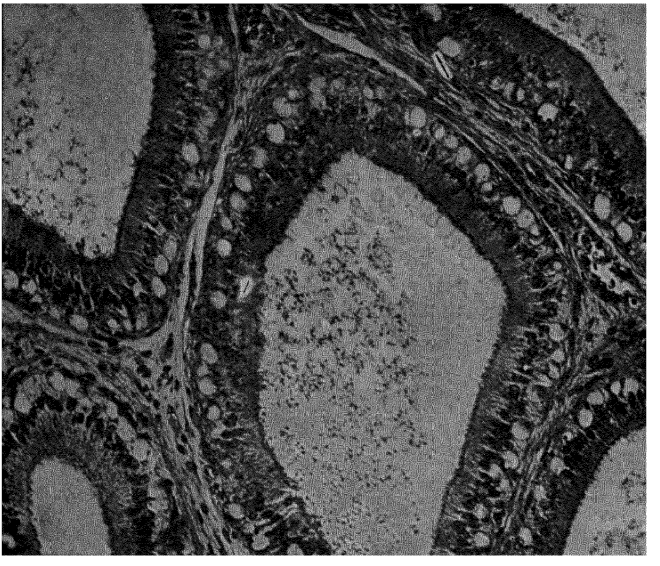

FIG. 578.—VESICULA SEMINALIS OF OX. (E. Sharpey-Schafer.) × 200. Photograph. Drops of secretion are seen at the free ends of some of the cells.

lymphatics. Between the bases of the epithelium-cells is a row of bladder-like cells occupied by clear fluid and having a very characteristic appearance in stained sections (fig. 578). The columnar cells yield a secretion which is poured out from them in the form of droplets which accumulate to form a clear or opalescent fluid filling the tubes. This fluid, in some animals (*e.g.* guinea-pig), has the property of coagulating when it is ejected into the vagina. The seminal vesicles do not contain spermatozoa.

Intertubular tissue.—The connective tissue between the tubules of the testicle is generally of very loose texture, and contains numerous lymphatic clefts, which form an intercommunicating system of commencing lymphatic sinuses. Lying in this intertubular tissue strands of polyhedral epithelium-like cells (*interstitial cells*, figs. 579, 580) of a yellowish colour can be

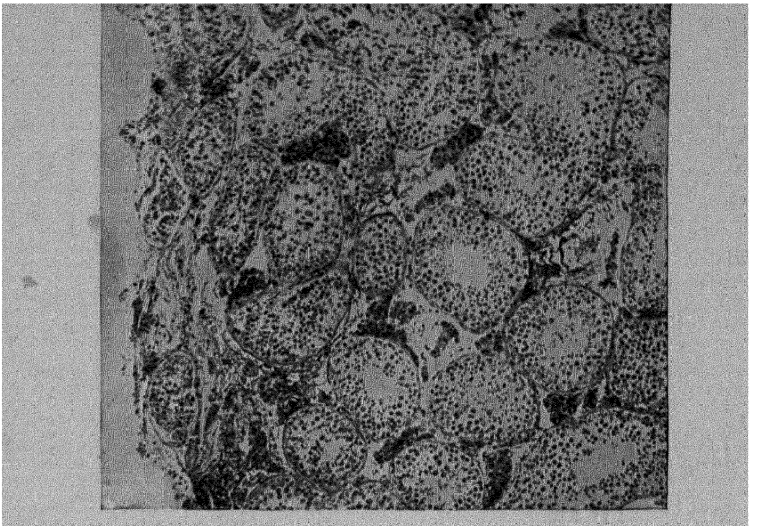

FIG. 579.—HUMAN TESTICLE. (E. Sharpey-Schafer.) × 50. Photograph. Preparation by M. Heidenhain.

The masses of interstitial cells are stained dark in this section.

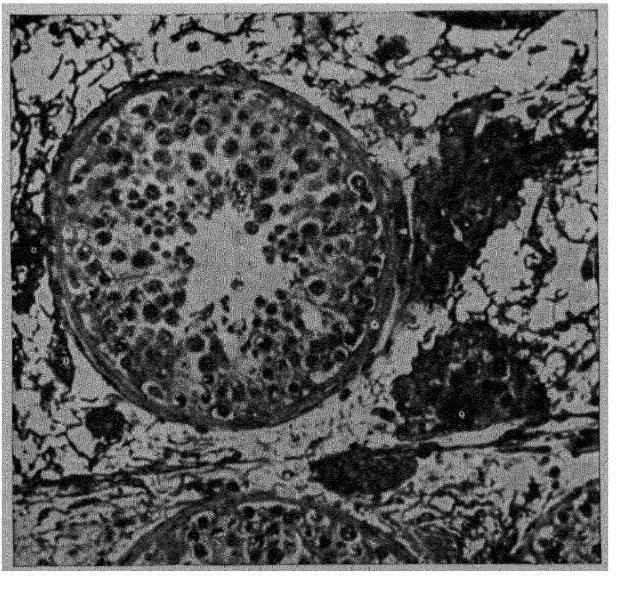

FIG. 580.—PART OF THE SAME PREPARATION AS THAT SHOWN IN FIG. 599, BUT MAGNIFIED 200 DIAMETERS. (E. Sharpey-Schafer.)

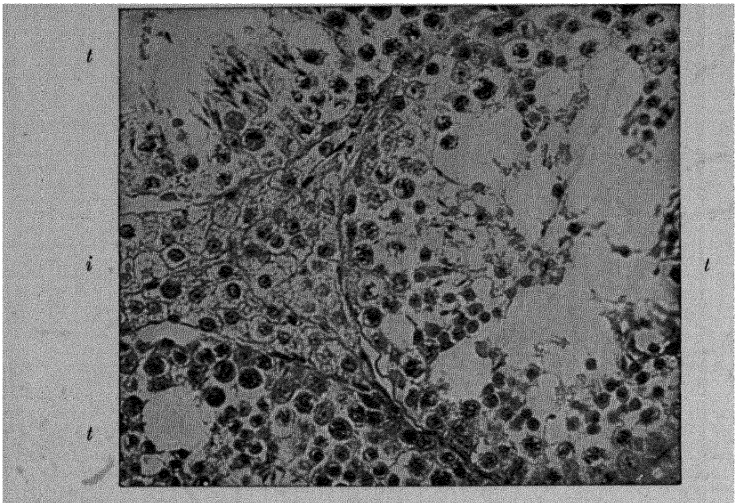

FIG. 581.—FROM A SECTION OF TESTICLE OF CAT. (E. Sharpey-Schafer.) × Photograph.

i, mass of interstitial cells, lying between three tubules (*t*).

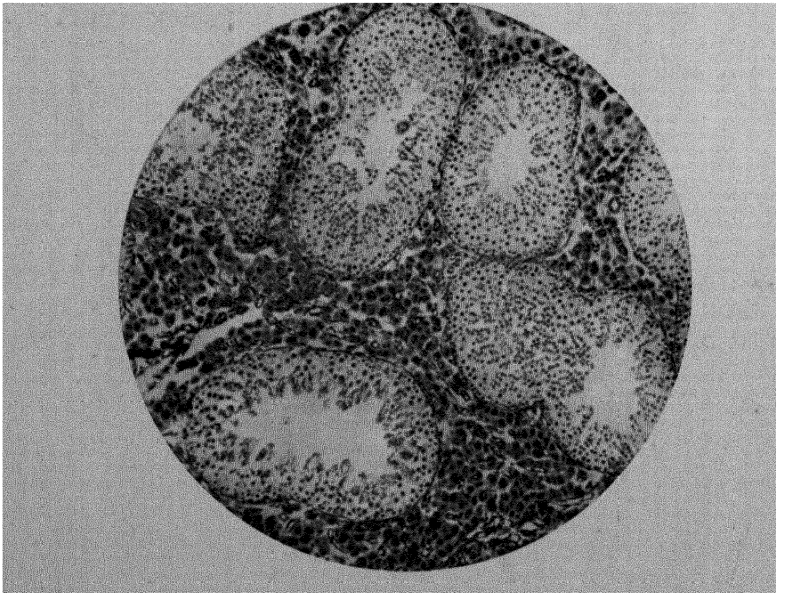

FIG. 582.—SECTION OF TESTICLE OF BOAR, SHOWING MASSES OF INTERSTITIAL CELLS BETWEEN THE TUBULES. (E. Sharpey-Schafer.) × 80. Photograph.

seen; they are abundant in some species of animals (cat, boar, figs. 581, 582) less abundant in others (mouse, rat, fig. 585). They accompany the blood-vessels before these break up to form the capillary networks which cover the walls of the seminiferous tubules.

The interstitial cells contain in many animals yellowish-brown lipoid or fatty globules (staining with osmic acid), and sometimes needle-shaped crystals of protein (fig. 583). Similar fatty globules may occur in the Sertoli cells of the seminiferous tubules; they are believed to pass into those cells from the interstitial tissue.



FIG. 583.—AN INTERSTITIAL CELL OF HUMAN TESTICLE, CONTAINING REINKE'S CRYSTALS. A DOUBLE CENTRIOLE IS SEEN CLOSE TO THE NUCLEUS. (Eberth.)

The **seminiferous tubules.**—The seminiferous tubules are formed of a connective-tissue membrane, which has a lamellar structure. The lamellæ are covered by flattened cells; fibres, chiefly elastic, occupy the substance of each lamella (fig. 584). In the adult the tubules contain several layers of epithelium-cells, but in the child there

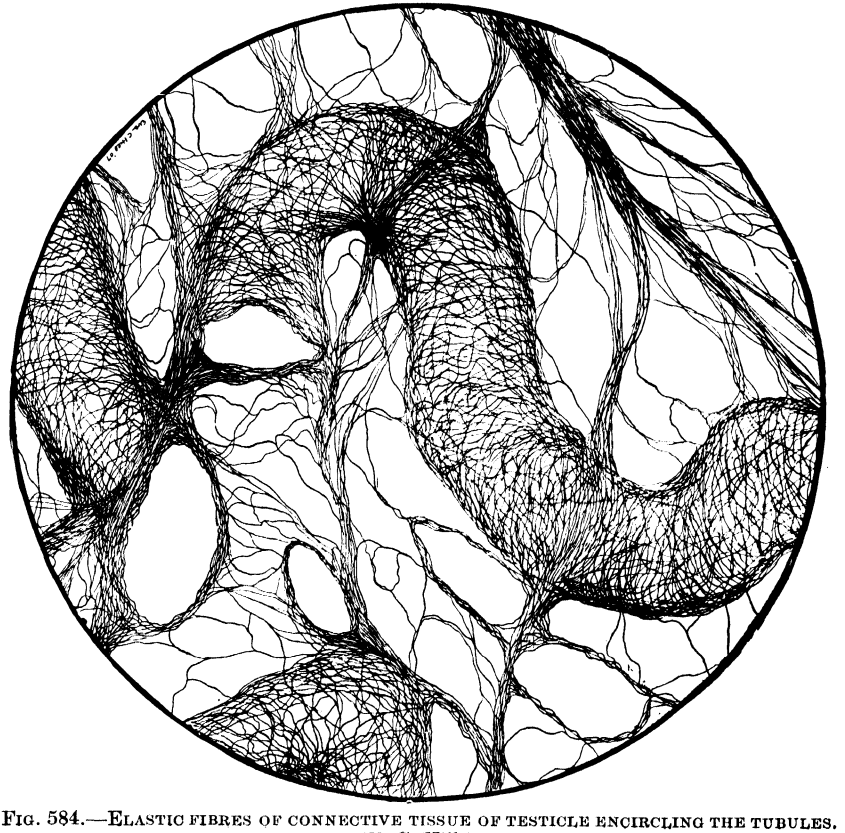

FIG. 584.—ELASTIC FIBRES OF CONNECTIVE TISSUE OF TESTICLE ENCIRCLING THE TUBULES. (E. C. Hill.)

is no clear distinction into layers, the cells being all more or less similar. Of the layers seen in the tubules of the adult testicle, the one next to the basement-membrane is a stratum of clear cubical cells (*spermatogons*,

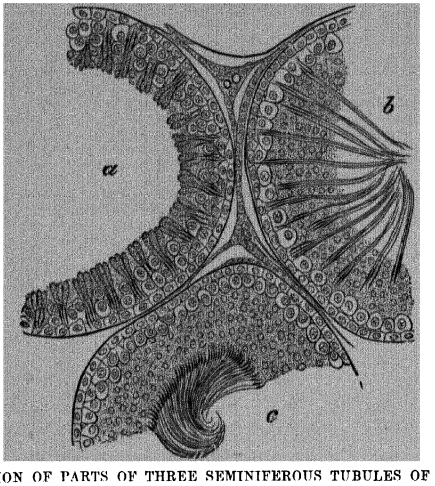

FIG. 585.—SECTION OF PARTS OF THREE SEMINIFEROUS TUBULES OF THE RAT, AS SEEN UNDER A LOW POWER.

a, with the spermatozoa least advanced in development; *b*, more advanced; *c*, containing fully developed spermatozoa. Between the tubules are seen strands of interstitial cells with blood-vessels and lymph-spaces.

fig. 586, *spg*), the nuclei of which for the most part exhibit the irregular nework which is characteristic of the resting condition, but in some tubules show indications of division. Here and there between the spermatogons

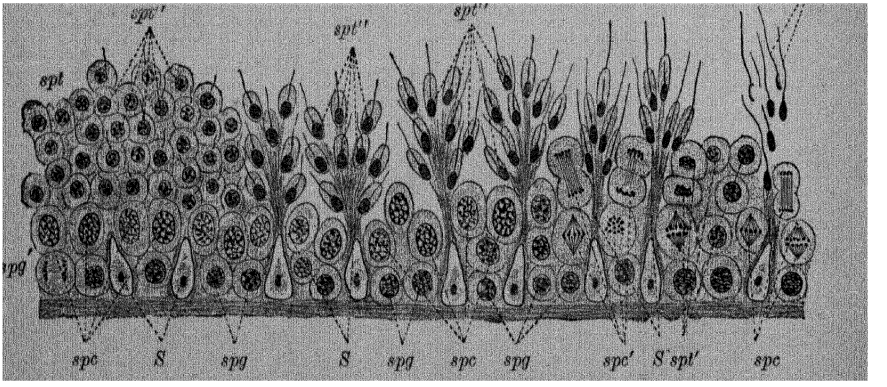

FIG. 586.—DIAGRAM SHOWING THE PHASES OF SPERMATOGENESIS IN A LONGITUDINAL SECTION OF A TUBULE: MAN. (Sobotta.)

spg, spermatogons; *spg'*, a spermatogon in mitosis; *spc*, spermatocytes; *spc'*, others dividing; *spt*, spermatids; *spt'*, others about to undergo reduction-division; *spt''*, others developing into spermatozoa; *sp*, spermatozoa; *S* cells of Sertoli.

some of the lining epithelium-cells are enlarged, and project between the more internal layers, being eventually connected with groups of developing spermatozoa. These enlarged cells are the *cells of Sertoli* (fig. 586, *S*: fig. 588).

Next to this lining epithelium is a zone of larger cells (*spermatocytes*, fig. 586, *spc*), the nuclei of which are usually in mitotic division (see pp. 15 to 18 and figs, 25, 26). Next to them, and most internal, are to be seen as the result of this division a large number of small protoplasmic cells with simple spherical nuclei (*spermatids*, fig. 586, *spt*). From some of these a tail-filament is beginning to sprout (*spt.*") In other parts the spermatids are becoming elongated with the nucleus at one end; these

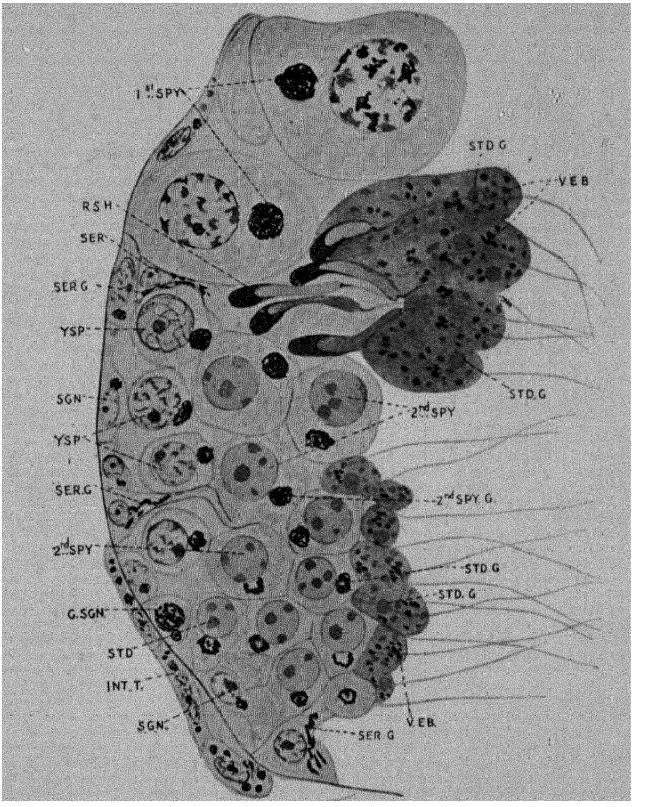

FIG. 587.—SPERMATOGENESIS: GUINEA-PIG. (Gatenby and Wigoder.)

YSP, young spermatocytes; 1st SPY, Golgi reticulum in primary spermatocytes; 2nd SPY, nuclei of secondary spermatocytes; 2nd SPY. G., Golgi apparatus of secondary spermatocyte; SER, cell of Sertoli; SER. G., its Golgi apparatus; SGN, spermatogon; G. SGN, its Golgi reticulum; STD, spermatids; STD. G., their Golgi apparatus; RSH, head of developing spermatozoon; VEB, von Ebner's granules in spermatids; INT. T., interstitial tissue.

elongated cells are gradually converted into spermatozoa. They lie in groups, their heads projecting between the deeper cells and are connected with one of the Sertoli cells of the lining epithelium, their tails projecting into the lumen of the tubule. But as the spermatozoa become mature they gradually shift altogether towards the lumen, where they eventually become free from the Sertoli cells (*sp*). During the time that one set of spermatozoa has been forming, another set of spermatocytes is

produced by the division of the spermatogons, and after the discharge of the first set of spermatozoa the process of division of spermatocytes to form spermatids and development of spermatozoa from these is repeated as before.

The **spermatozoa.**—Each spermatozoon (sperm-cell) consists of three parts, a head, a middle part or body, and a long tapering tail (figs. 589, 590). In man the *head* is of a pointed oval shape, somewhat flattened, especially towards its apex; in some animals it bears a small barb-like projection at

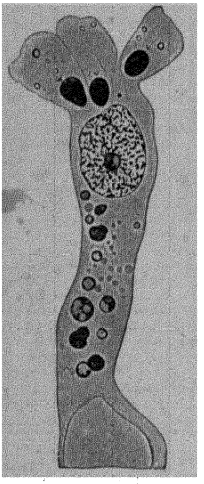

FIG. 588. A CELL OF SERTOLI WITH WHICH THE SPERMATIDS (THREE OF WHICH ARE SHOWN) ARE BEGINNING TO BE CONNECTED: HUMAN. (Bramman).

The cell contains globules staining with osmic acid; similar but smaller globules are also seen in the spermatids. The 'ring' formed around the tail-filament by one of the particles of the centrosome (see text) is shown in each of these spermatids close to the 'head.'

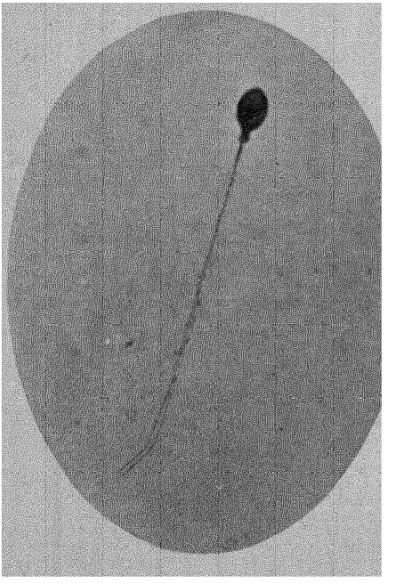

FIG. 589.—HUMAN SPERMATOZOON. (W. Chesterman.) × 1000. Photograph.

this extremity. The apical part is covered by a cap of a somewhat different appearance from the rest—the *head-cap* or *acrosome*. The *body* is in man short and cylindrical; it has a spiral fibre passing round it. An axial fibre, itself fibrillated, passes from a knob close to the head right through the body and tail. The *tail* is the longest part of the spermatozoon, and when examined with the microscope in the fresh condition is seen to be in continual rhythmic lateral or spiral motion, like a cilium. The extremity of the tail (end-piece) forms a distinct part of the spermatozoon; it is often bifid (fig. 589). Human spermatozoa are about 50 μ ($\frac{1}{500}$ inch) long.

In different animals the shape of the head and the extent of middle-piece and tail vary greatly (fig. 591). In the rat and mouse (fig. 593) the head is curved; it is set obliquely on the middle-piece. This is of considerable extent, and has a closely wound spiral filament encircling it. In the newt the head is long and tapering, and the tail has a membranous expansion, attached in a spiral manner along its whole length. Such an expansion has also been described in the human spermatozoon, and appears to be indicated in fig. 589. In decapod Crustacea, which possess no cilia, the spermatozoa are stellate and motionless (fig. 591, *l*); in nematoid worms they are amœboid (fig. 591, *k*). Occasionally two distinct kinds of spermatozoa are met with in the same species of animal, one kind being far the larger in size (giant spermatozoa) but much less numerous. Such giant spermatozoa have been observed in man.

Although the tail of the spermatozoon is usually considered to be a cilium, it exhibits greater complexity of structure than ordinary cilia. Spermatozoa also differ from cilia in being more highly resistant to the effects of putrefaction and of chemical reagents, including even strong acids and alkalies.

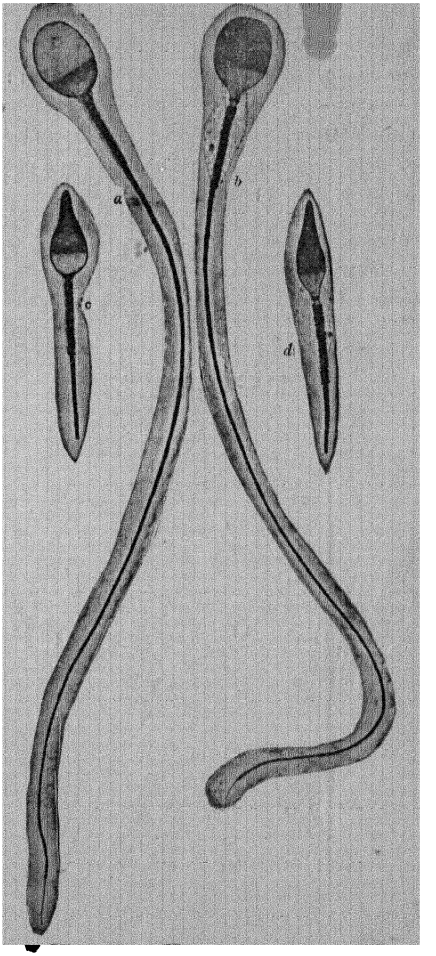

FIG. 590.—HUMAN SPERMATOZOA. (Broman.) × 2000.

a and *b*, shown in face, as seen in different foci of the microscope; *c* and *d*, profile view.

Spermatogenesis. — Spermatozoa are developed from the small cells (spermatids) which form the innermost stratum of the seminal epithelium, and these are themselves produced by double division of the large spermatocytes of the second layer. It is probable that fresh spermatocytes are formed by division of some of the lining epithelium-cells or spermatogons. The cycle of changes therefore which takes place is as follows: 1. Division of a lining epithelium-cell or spermatogon into two, one of which grows larger, becomes a spermatocyte, and passes into the second layer, while the other remains in the first layer. 2. Division of the spermatocyte. 3. Further division of the daughter-spermatocytes thus produced. The four cells (spermatids) which result from this double division possess only one-half the somatic number of chromosomes in their nuclei, 'reduction' having been effected in the final cell-divisions by which the spermatids are produced (p. 15). 4. Elongation of the spermatids and their gradual conversion into spermatozoa. As they undergo this conversion their grouping becomes

more evident, and each group is found to be connected with a cell of Sertoli (fig. 586, *S*); this probably ministers to their nutrition. The Sertoli cell undergoes a gradual process of elongation, so that the spermatozoa by the time they are fully developed are brought to the lumen of the tube, in which they then become free. In the meantime other alternate groups of spermatids from which the next crop of spermatozoa will be derived are being formed in the same manner, passing through the same cycle of changes. So that different phases of development may be observed even in different parts of the same tubule; in different tubules of the same testicle every phase may be traced. The diagram on p. 432 (fig. 586) illustrates the cycle of changes described.

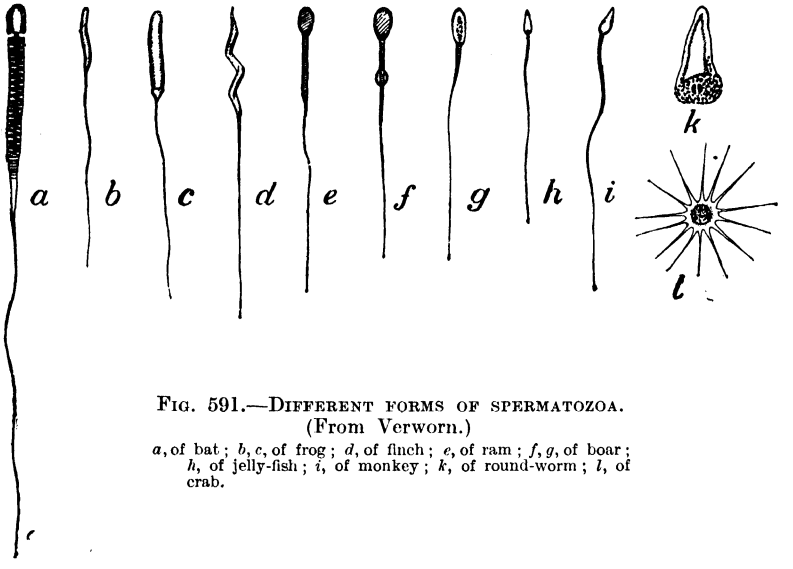

FIG. 591.—DIFFERENT FORMS OF SPERMATOZOA.
(From Verworn.)
a, of bat; *b*, *c*, of frog; *d*, of finch; *e*, of ram; *f*, *g*, of boar; *h*, of jelly-fish; *i*, of monkey; *k*, of round-worm; *l*, of crab.

Each spermatid becomes converted into a spermatozoon in the following manner (figs. 592, 593). The nucleus forms the chief part of the head, while the tail develops as an outgrowth of the centrosome and cytoplasm. The tail-filament appears within the protoplasm, growing out from the centriole of the cell, which lies close to the nucleus (fig. 592). The centriole is double; one of its two particles forms an annular expansion or ring, which as development proceeds, moves down the tail-filament until it reaches the place where this leaves the cytoplasm; here it ultimately forms the limit of the body or middle-piece of the spermatozoon. The Golgi bodies come to lie against the anterior pole of the nucleus; a vacuome is formed here and from it the acrosome of the spermatozoon is produced. As development proceeds this may become indistinguishable from the rest of the head. Fitting over the posterior part of the head, like the cup of an acorn, is a conical band (fig. 590); this is formed, according to Gatenby and Wigoder, out of part of the Golgi apparatus. The spiral fibre of the middle-piece is developed

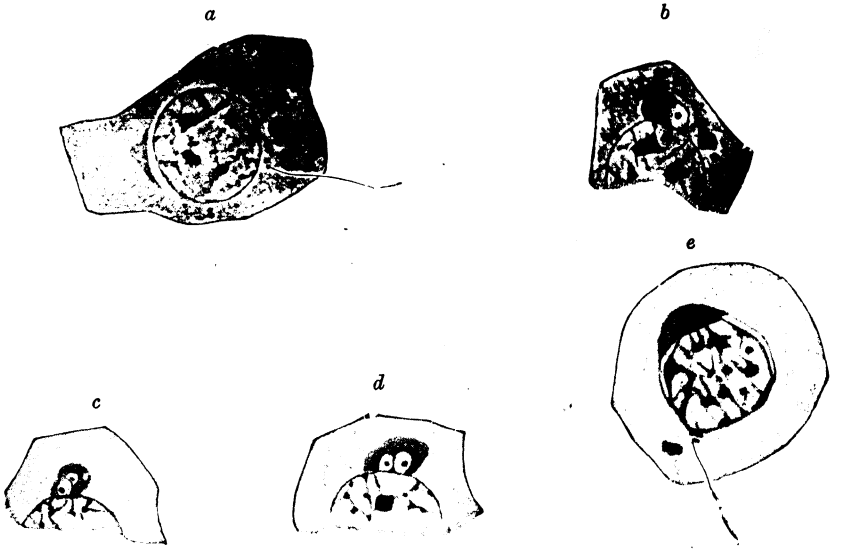

FIG. 592.—CHANGES IN SPERMATIDS IN THE COMMENCING FORMATION OF SPERMATOZOA. (Niessing.)

The tail-filament is seen (in *a* and *e*) to extend from the diplosome, which lies close to the nucleus. The head-cap (shown in *e*) is produced by a transformation of a special part of the archoplasm which becomes vacuolated (*b*, *c*, *d*).

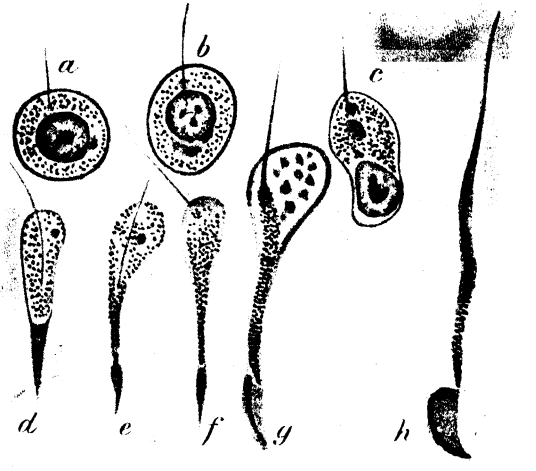

FIG. 593.—CELLS FROM THE TESTICLE OF THE MOUSE IN PROCESS OF TRANSFORMATION INTO SPERMATOZOA. (Benda.)

The 'mitochondria' are darkly stained and are seen in the successive stages (*a* to *g*) to be arranging themselves so as to constitute the spiral filament of the spermatozoon (*h*).

from mitochondria (fig. 593). A portion of the protoplasm of each spermatid containing a number of particles (seminal granules of v. Ebner) becomes detached and disintegrated before the spermatozoon is fully matured.

A few spermatocytes undergo incomplete division; the resulting spermatids are large (giant spermatids, p. 435) and contain either one large nucleus or two or more nuclei which ultimately blend to form the head of the spermatozoon. In these cases a corresponding number of centrosomes is seen; from each of these centrosomes a tail-filament may become developed.

LESSON XXXVIII.

THE FEMALE GENERATIVE ORGANS.

1. SECTIONS of ovary of (*a*) non-pregnant and (*b*) pregnant animal (rabbit or cat). If from a pregnant animal the organ will be largely occupied by corpora lutea. Study the sections with a low power, observing the small and large Graafian follicles, each enclosing an ovum, scattered through the stroma; also the corpora lutea and degenerating follicles. Measure Graafian follicles of different sizes. Make a general sketch of a section under the low power. Then sketch carefully one or two of the follicles with their contents under a high power.

2. Sections of human ovary. Notice the far larger proportion of stroma as compared with other animals and the relatively smaller number of Graafian follicles. If a corpus luteum is present notice its folded wall and the cells composing this. Corpora albicantia may also be seen.

3. Take the fresh ovary of a sheep and with a needle or fine scalpel-point prick one of the largest and most prominent of the Graafian follicles. The organ must be held just over a slide so that on pricking the follicle the fluid contents may spurt out on to the glass. Examine the drop of liquor folliculi with a low power for the escaped ovum, which will be surrounded by follicular cells. When found place a piece of thick hair in the drop, cover with cover-glass and examine with high power.

4. Section across Fallopian tube. Sketch a section under the low power.

5. Section across a cornu of a bicorned uterus of a bitch, cat or rabbit. Observe the thickness of the muscular and mucous coats respectively. Notice the columnar epithelium lining the organ (partly ciliated) and extending into the glands of the mucous membrane. Draw a part of a section under the low power.

6. Sections of human uterus (*a*) of body, (*b*) of cervix.

7. Section of placenta stained with alcoholic-eosin and methylene-blue. Notice the venous spaces occupied by maternal blood, and within the spaces sections of the fœtal villi.

8. Section of vagina. Notice the stratified epithelium which lines it and which is continued over the projecting part of the os uteri. If the section is taken through the anterior wall, the urethra may be included in it.

Suitable fixatives for these organs are susa and formol.

THE OVARY.

The ovary is a small solid organ, mainly composed of a *stroma* of fibrous tissue, with many spindle-shaped cells, particularly abundant in the human ovary (fig. 596). It also contains, near its attachment to the broad ligament, a number of plain muscular fibres, and receives here numerous and large blood-vessels and lymphatics. It is covered by a layer of small columnar epithelium-cells (*germinal epithelium*), between which may here and there be seen a few larger spheroidal cells, with large round nuclei. In the young subject the epithelium occasionally dips down into the subjacent stroma (fig. 601).

Scattered throughout the stroma are vesicles of different sizes, the smallest being near the surface of the organ, the larger ones placed more deeply in

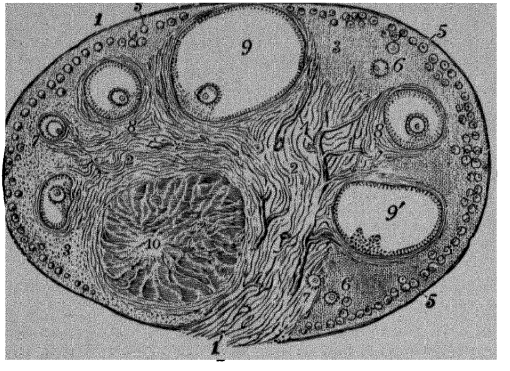

FIG. 594.—OVARY OF CAT. (Schron.) × 9.

1, tunica albuginea; *1'*, hilum; *2*, stroma showing a fibrous and vascular structure; *3*, peripheral stroma; *4*, blood-vessels; *5*, young Graafian follicles lying near the surface; *6*, *7*, *8*, more advanced follicles which are embedded more deeply in the stroma; *9*, an almost mature follicle containing the ovum in its deepest part; *9'*, a follicle from which the ovum has fallen out in preparing the section; *10*, corpus luteum.

the stroma, although, as they increase in size, they extend towards the surface (fig. 594).

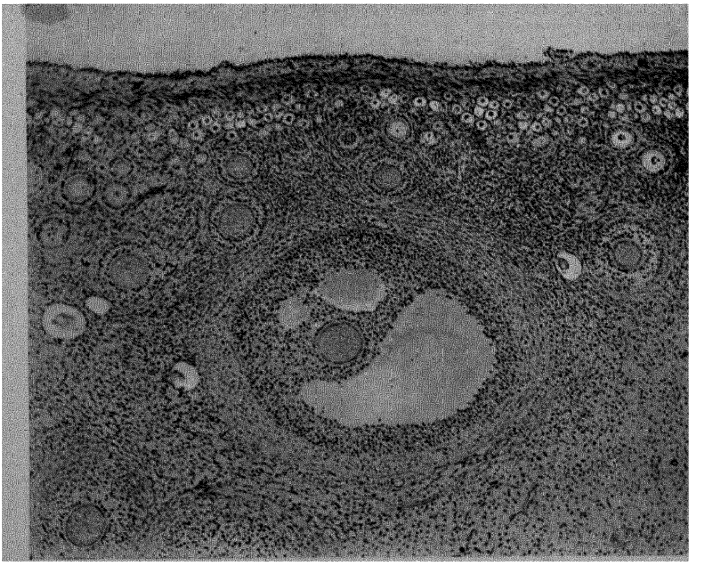

FIG. 595.—SECTION OF OVARY OF RABBIT. (E. Sharpey-Schafer.) × 60. Photograph.

One large Graafian follicle and a number of smaller follicles are seen, the smallest forming a layer near the surface. Notice the tunica albuginea covering the surface; itself covered by columnar epithelium.

These vesicles are the **Graafian follicles.** Each Graafian follicle has a proper wall (*theca folliculi*) formed externally of a connective tissue layer

derived from the stroma, with a special inner layer containing large cells: both strata are highly vascular. Each follicle contains an *ovum* and *epithelium*. In the smallest follicles the ovum is small, and the epithelium of the follicle is formed of a single layer of cells which may be flattened against the ovum (figs. 596, 601). In somewhat larger follicles the epithelium-cells are in two layers, and are columnar in shape (fig. 600, E). In still larger ones, each of the two layers is formed of several strata of cells, and fluid has begun to collect between the layers at one part. Of the two layers, the one which lines the cavity of the follicle is termed the *membrana granulosa*, while the mass of cells which more immediately surrounds the ovum is known as the *cumulus* or *discus proligerus*. All the cells of the follicles, including the ova, possess a well-developed Golgi apparatus (Rio del Hortega).



FIG. 596.—SECTION OF PART OF HUMAN OVARY SHOWING SMALL GRAAFIAN FOLLICLES EMBEDDED IN A FIBRO-CELLULAR STROMA. (Sellheim.)

In the largest follicles the fluid has much increased in amount, so that the follicle has become gradually larger and more tense. Finally it reaches and projects from the surface of the ovary; here it eventually bursts, and the liquor folliculi, with its contained ovum, is set free. The existence of plain muscular tissue has been described in the wall of the Graafian follicle (Guttmacher). The contraction of this may be the actual cause of the bursting of the follicle.

Follicular degeneration.—The number of ova present before birth is many times the number found at puberty. A further decrease (only accountable for to a very slight extent by the shedding of ripe ova) occurs throughout life. This disappearance of follicles by degeneration (atresia) is especially marked during the cessation of ovulation during pregnancy. The ovum of an atresic follicle may show karyokinesis; sometimes it segments. The nucleus and cytoplasm degenerate, but the zona pellucida persists for a long time as a pleated hyaline body. Degenerative phenomena appear in the follicular walls also, the fluid is absorbed and the follicle becomes eventually replaced by the ingrowing connective tissue of

the theca. After the menopause a pronounced atresia of Graafian follicles occurs (fig. 597).

Liquor folliculi.—The fluid of the Graafian follicles at first accumulates at one or more places between part of the membrana granulosa and the cells of the discus proligerus immediately surrounding the ovum and gradually spreads so as to separate these two parts of the epithelial contents of the follicle, but leaving them connected at one side. This fluid—the *primary liquor folliculi* of Robinson—is at first enclosed within a sort of protoplasmic network derived from the cells. Robinson

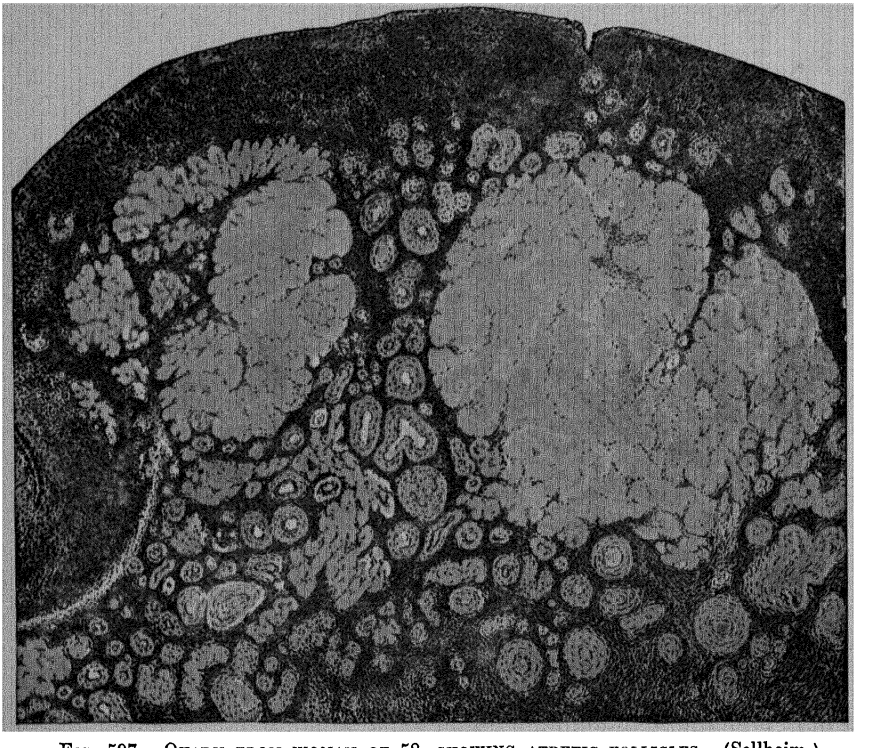

FIG. 597.—OVARY FROM WOMAN OF 58, SHOWING ATRETIC FOLLICLES. (Sellheim.)

has shown (in the ferret) that after insemination a second formation of liquid of a somewhat different and more fluid character makes its appearance between the cells of the discus proligerus, and this in its turn gradually increases in amount and spreads round the follicle, but without mixing with the first accumulation, although they may be in close contact with one another. There is in fact a thin membrane surrounding the primary liquor folliculi and separating them from one another. The *secondary liquor folliculi* as it accumulates pushes this membrane before it and penetrates between the primary liquor and the follicular epithelium until it reaches the superficial part of the follicle, where rupture ultimately occurs. The primary and secondary liquor folliculi together with the ovum and discus proligerus are then all extruded, and the empty cavity of the follicle becomes filled with a more tenacious fluid—the *tertiary liquor folliculi* of Robinson—which helps to plug the narrowing aperture. The follicular epithelium, which is left behind, then undergoes development to form the corpus luteum.

The **ovarian ova** (*oocytes*) are large spherical cells, about 0·2 mm. ($\frac{1}{125}$ inch) in diameter. When fully formed (fig. 598), as in the largest Graafian follicles, each ovum is surrounded by a thick transparent membrane (*zona pellucida seu radiata*). Within this is the cytoplasm of the oocyte containing a few inclusions (droplets of yolk and fat). Lying in the cytoplasm, generally eccentrically, is the large clear round nucleus (*germinal vesicle*), which invariably has a well-marked nucleolus (*germinal spot*), sometimes more than one.

The zona pellucida is penetrated by fine pores through which pass

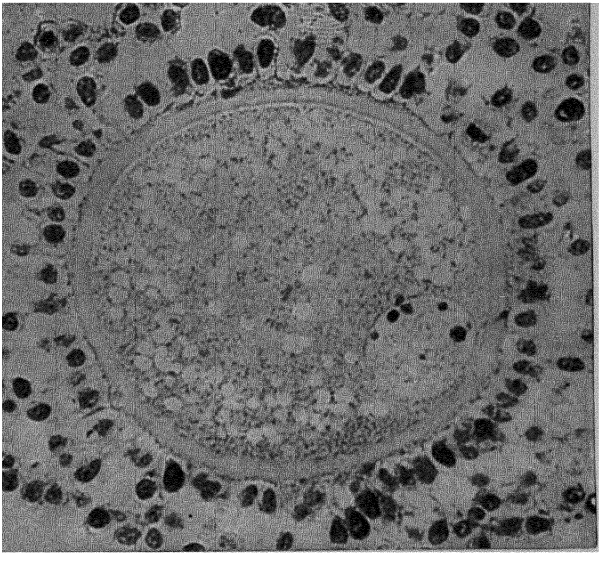

FIG. 598.—OVARIAN OVUM OF RABBIT. (E. Sharpey-Schafer.) × 400. Photograph.

The ovum is enclosed within a clear thick membrane (zona pellucida) outside of which, and adhering to it, are epithelial cells of the Graafian follicle. The protoplasm of the ovum shows numerous fine granules and a number of large clear yolk globules. The nucleus (germinal vesicle) lies near the periphery; it contains several stained globules, the largest of which may be looked upon as the nucleolus (germinal spot).

filaments from the cells of the discus proligerus which are in immediate contact with it (G. Retzius).

Oogenesis.—Both the ova and the epithelium of the Graafian follicles originate from the germinal epithelium of the embryo. This forms at first a simple layer covering the stroma, but later becomes thickened and multiple. After a time rounded cords of epithelium-cells (*egg-tubes of Pflüger*, fig. 599; fig. 600, A) grow inwards into the stroma, while this at the same time grows outwards into the thickened epithelium. The cords presently become broken up by ingrowths of stroma into isolated nests of epithelium-cells (fig. 600, B), each of which may be taken to represent a Graafian follicle. Some of the cells become enlarged to form primitive ova; usually there is one such enlarged cell in each nest, the remaining cells forming the epithelium of the

follicle (fig. 600, C). It would appear that while the protoplasm of the ovum remains connected with the cells of the discus proligerus by fine processes which pass through pores in the zona pellucida, on the other hand the epithelium-cells of the follicle are themselves interconnected by protoplasmic bridges, so that the whole forms a syncytium.

New formation of follicles from the germinal epithelium may, according to Kingery, occur in the mouse up to the time of sexual maturity. In the ferret, according to Robinson, new follicles are formed throughout the whole of the functional life of the ovary.

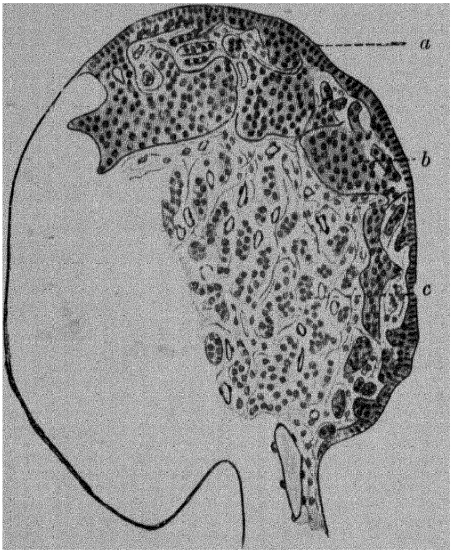

FIG. 599.—OVARY OF 28-DAY RABBIT, SHOWING THICKENED GERMINAL EPITHELIUM GROWING INTO STROMA. (Felix and Bühler.)

a, germinal epithelium; *b*, a thickened downgrowth from this epithelium; *c*, stroma of ovary.

The stroma cells adjacent to the follicles become grouped around the latter; they eventually form the *theca externa* of the follicles.

The stroma of the ovary contains, besides the spindle-shaped connective-tissue-cells and plain muscular fibres already mentioned, a number of large epithelium-like *interstitial cells* (fig. 604). Some of these are derived from the germinal epithelium (Lane-Claypon); others have originated from cells of the walls of degenerating follicles.

The blood-vessels of the ovary are large and numerous. The smaller vessels are abundantly distributed in the walls of the Graafian follicles, over which they form a close network and throughout the substance of the corpora lutea. The ovary also receives many nerve-fibres, but their ultimate destination is not known.

Corpora lutea.—These are yellowish nodules, which are developed out of the Graafian follicles after the ova have been extruded. They consist of

columns of large cells (*luteal cells*) containing lipoid globules, with intervening trabeculæ of vascular fibrous tissue. In most animals the trabeculæ

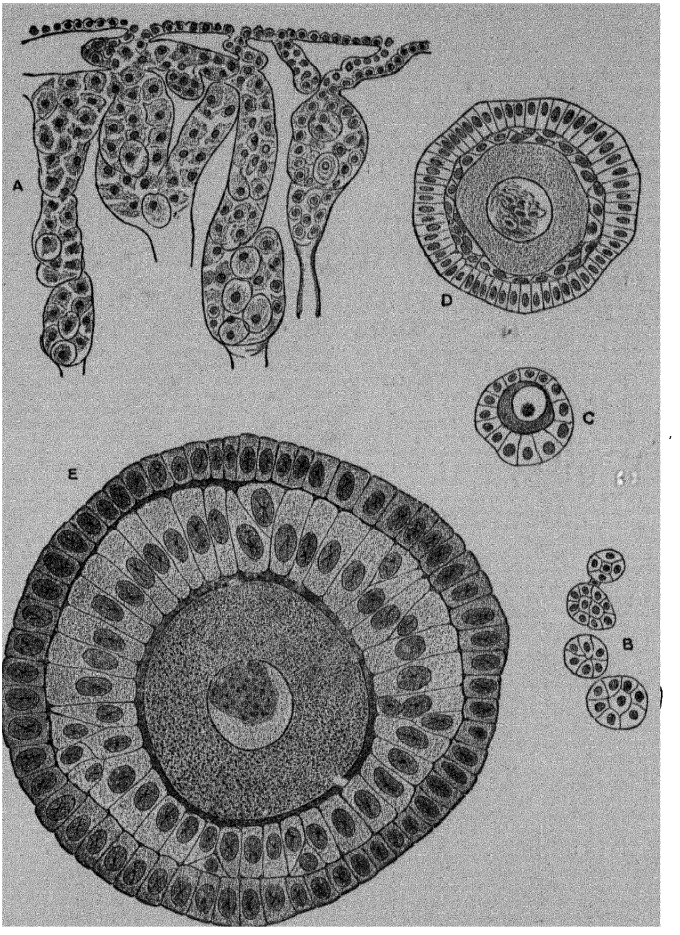

FIG. 600.—VARIOUS STAGES IN THE DEVELOPMENT OF THE GRAAFIAN FOLLICLES OF THE RABBIT. (E. Sharpey-Schafer.)

A, from ovary of young rabbit, showing 'egg-tubes' of Pflüger growing in from germinal epithelium; some of the tubes contain primitive ova; B, primitive Graafian follicles formed from the breaking up of an egg-tube; C, a young Graafian follicle, with a single layer of follicle epithelium; D, a somewhat older follicle, with the second layer forming within the first; E, a more advanced follicle, showing two complete layers of columnar epithelium surrounding the ovum within the follicle.

converge to a central strand of connective tissue occupying the axis of the nodule (figs. 602, 603). The columns of cells are not unlike those of the cortex of the suprarenal capsule. In the human subject the cells of the corpus luteum are massed into pleats or folds, arranged perpendicularly to the wall of the follicle, with vascular connective tissue in the interspaces. Numerous

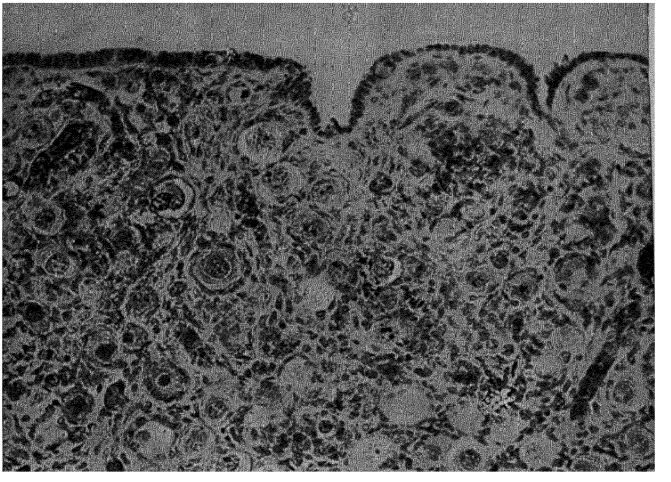

FIG. 601.—SECTION OF OVARY OF HUMAN FŒTUS, SHOWING NUMEROUS PRIMITIVE GRAAFIAN FOLLICLES EMBEDDED IN THE STROMA. (E. Sharpey-Schafer.) × 200. Photograph.

Each primitive Graafian follicle consists of a primitive ovum surrounded by a single layer of flattened follicular epithelium-cells.

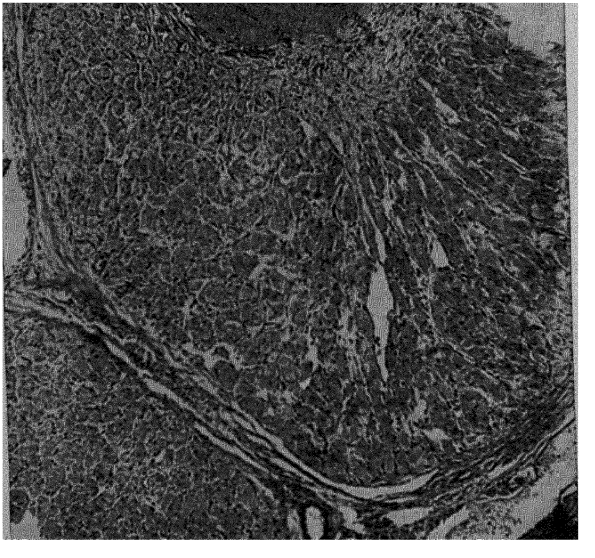

FIG. 602.—CORPUS LUTEUM OF RABBIT FORMED OF TRABECULÆ OF LARGE LUTEAL CELLS WITH SINUSOIDAL VESSELS BETWEEN THE COLUMNS. (E. Sharpey-Schafer.) × 60. Photograph.

A blood-clot (*bl*) is seen near the middle of the corpus luteum. Just below this is a kind of cicatricial fibrous tissue formed by organisation of part of the clot.

capillary blood-vessels, of a sinus-like character, ramify amongst the luteal cells.

The lutein cells are derived from the membrana granulosa after the follicle has burst and expelled the liquor folliculi along with the ovum and its discus proligerus. There is often a central extravasation of blood. But as would appear from the work of Aschoff and others, much of this is formed *not* when the follicle ruptures but during subsequent periods, when the ovary becomes congested.

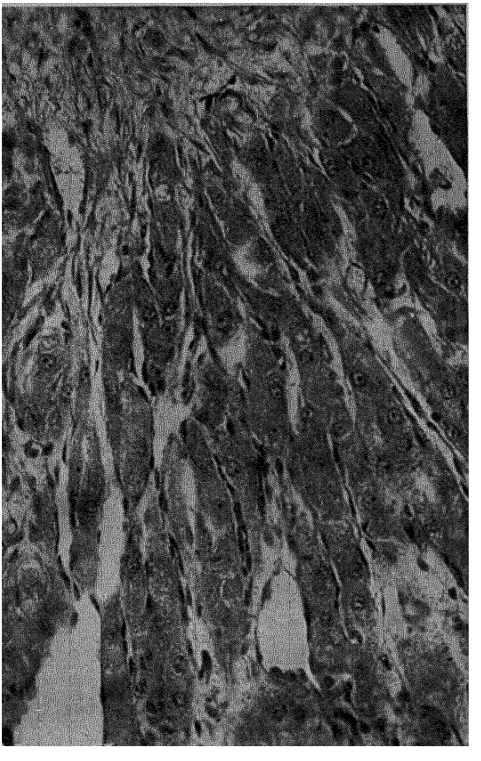

FIG. 603.—A PART OF THE SECTION SHOWN IN THE PREVIOUS FIGURE. (E. Sharpey-Schafer.) × 200. Photograph.

The columns of luteal cells and the cicatricial tissue to which they converge are well seen in this figure.

It was formerly thought that the luteal cells were derived from the theca and stroma, all the granulosa cells being extruded with the ovum. Recent work, however, points to the membrana granulosa as being in most, if not in all, mammals the only source of luteal tissue; but in a few, such as the sow, the theca cells may, it is thought, also assist in its formation.

Special characteristics of the human ovary.—In Man and other Primates, all the follicles are formed before puberty. As already explained, they decrease in number with age. The follicles degenerate after the menopause,

and the ovary eventually becomes converted into a mass of fibrous tissue, in which the atretic corpora lutea are still visible (fig. 597).

Menstruation and ovulation are not coincident in man. Ovulation is about fourteen days after the commencement of menstruation. A corpus luteum may be formed without the Graafian follicle coming to maturity and bursting. In that case, after a certain amount of development of luteal tissue,

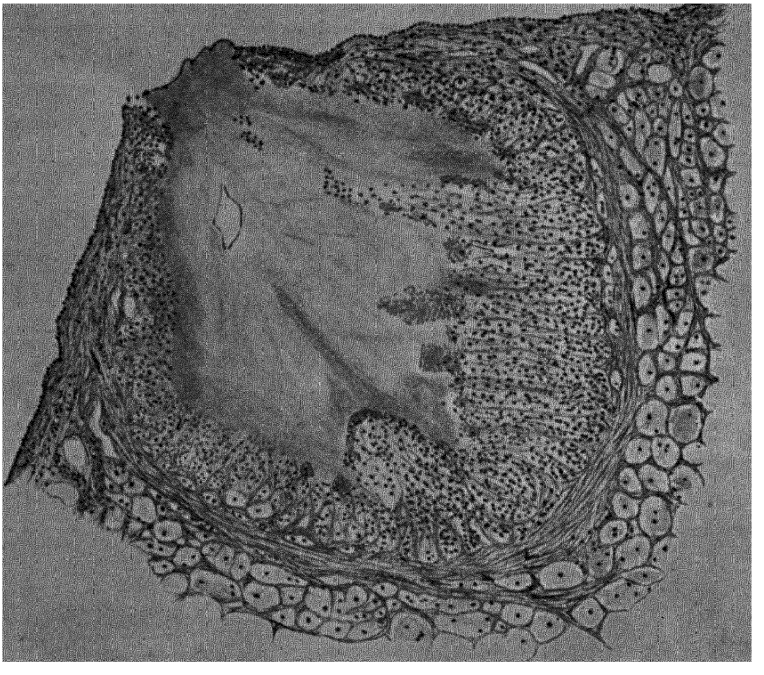

FIG. 604.—EARLY DEVELOPMENT OF CORPUS LUTEUM OF RABBIT. (L. F. Messel.)[1]

The place of rupture of the follicle is still widely open. The membrana granulosa is arranged in columns, with vascular connective tissue ingrowths from the theca folliculi between the columns. There is some hæmorrhage into the follicle. Large cells are seen in the stroma outside the theca.

sometimes with extravasation of blood into the cavity of the follicle, the latter undergoes a process of regression, and is eventually transformed into a mass of dense fibrous tissue—the corpus albicans—within which an iron-containing pigment (derived from the blood-clot) may be found.

Häggström (1921) examined the ovaries of an unmarried woman of twenty-two, who had died from CO poisoning, with regard to the number and condition of the Graafian follicles. The ovaries were of unequal size. The smaller had about 17,000 follicles, the larger about 25,000. Most of the follicles were very small: only 219 were over 100 μ in diameter. Liquor folliculi had begun to form in only 21 follicles. Five follicles had each 2 ova. About 2 per cent. of the ova had each

[1] From F. A. H. Marshall, "The Physiology of Reproduction," 1922.

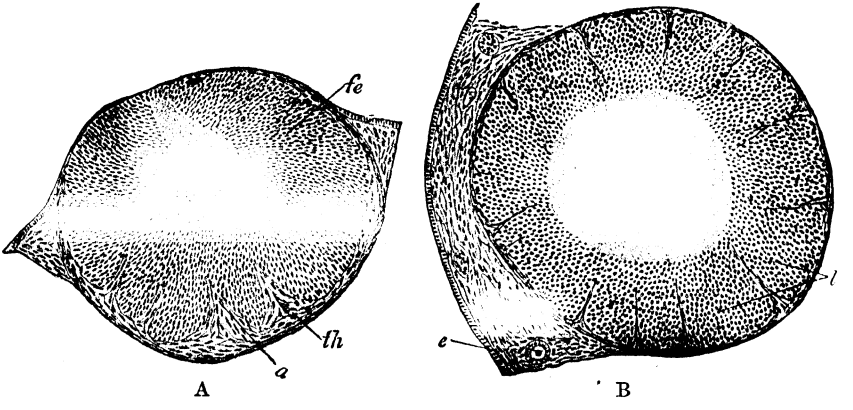

FIG. 605.—THREE STAGES IN THE FORMATION OF THE CORPUS LUTEUM IN THE MOUSE. (Sobotta.)

A. Follicular epithelium hypertrophied (*fe*), and vascular processes (*a*) of the internal theca (*th*) growing into it.

B. The vascular processes are arranged radially and subdivide the epithelium—now converted into a mass of luteal cells—into lobule-like masses (*l*); *e*, epithelium of surface of ovary.

C. The lobule-like masses are more columnar, and the luteal mass almost fills the follicle, leaving, however, a central mass occupied by coagulated fluid.


C

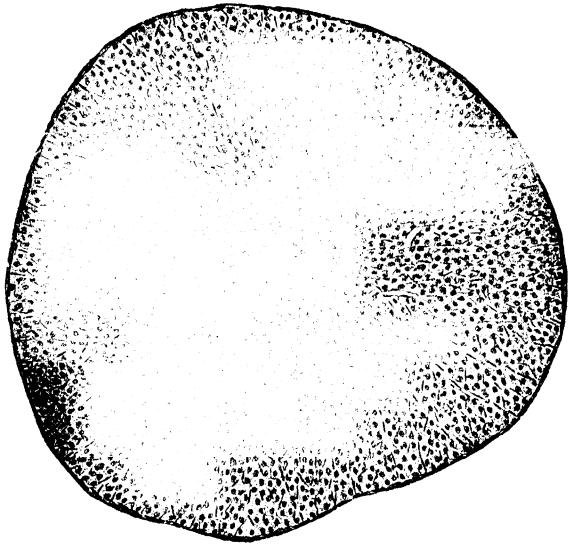

FIG. 606.—MORE ADVANCED STAGE IN THE DEVELOPMENT OF THE CORPUS LUTEUM OF THE MOUSE. (Sobotta.)

The luteal tissue is now highly vascular, and the central mass is nearly obliterated.

2 nuclei. The smaller ovary had 4 corpora lutea, the larger 5. There were 1(corpora albicantia in the smaller, 48 in the larger ovary. It is clear therefor(that far more ova are formed than are discharged during life, and that many mor(Graafian follicles become atretic than come to maturity.

THE FALLOPIAN TUBES

The **Fallopian tubes** or **oviducts** are lined by a very vascular mucous membrane which is covered with ciliated epithelium, and has numerous

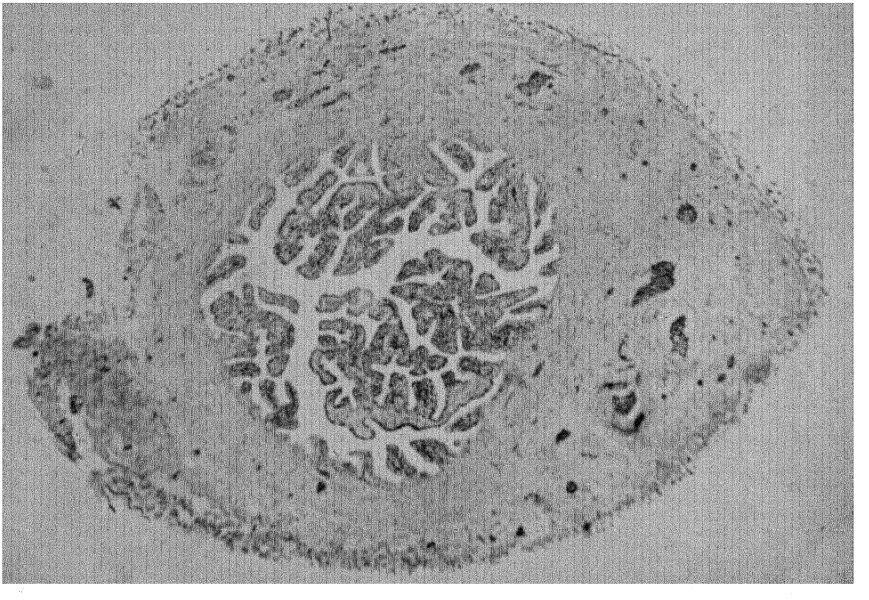

FIG. 607.—TRANSVERSE SECTION OF FALLOPIAN TUBE: HUMAN. (E. Sharpey-Schafer.) × 36. Photograph.

longitudinal folds or rugæ with depressions between (fig. 607). After the menopause the cilia disappear. Externally the tube is covered by a serous coat, within which is a thin longitudinal stratum of plain muscular fibres overlying circular fibres of the same tissue; these layers are not distinctly marked off from one another.

The Fallopian tube commences near the ovary with an open end, the margins of which are spread out into a number of processes termed *fimbriæ*. One or two of these fimbriæ are directly attached to the surface of the ovary in the manner shown in fig. 609. Each Fallopian tube terminates distally in the uterus, opening on each side at the upper angle of the body of the uterus. In animals which possess a bicorned uterus, the Fallopian tube is directly continued (enlarged) into the corresponding cornu.

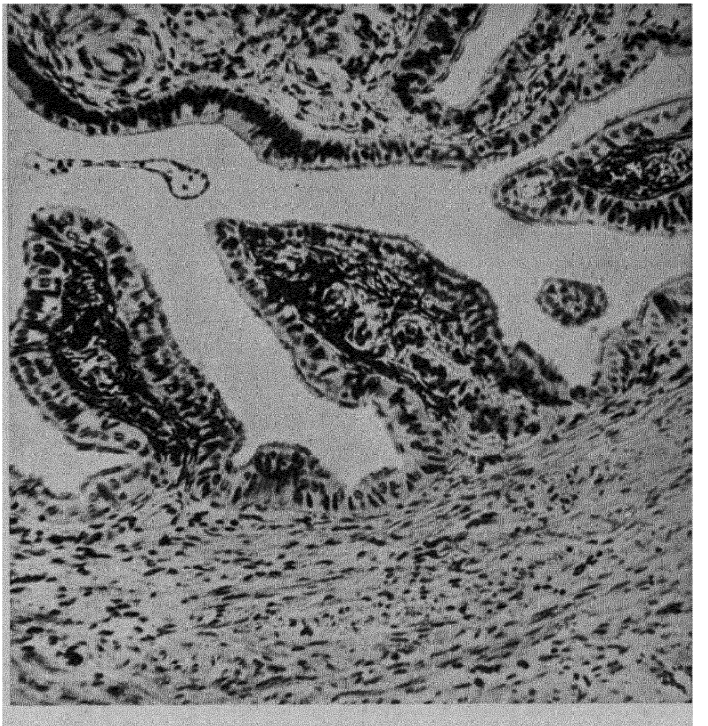

608.—A SMALL PORTION OF THE SECTION SHOWN IN THE PREVIOUS F
(E. Sharpey-Schafer.) × 150.



FIG. 609.—SECTION OF OVARY OF GUINEA-PIG AT THE PLACE OF ATTACHMENT OF THE FIMBRIATED END OF THE FALLOPIAN TUBE. (E. Sharpey-Schafer.) × 200. Photograph.

Notice the ciliated epithelium covering the fimbriæ, continued into the much smaller non-ciliated cells of the ovarian surface. Observe also the numerous and large blood-vessels of the fimbriæ.

THE UTERUS.

The **human uterus** is composed of two parts, the body and the cervix. The body is formed of the following layers (fig. 610):—

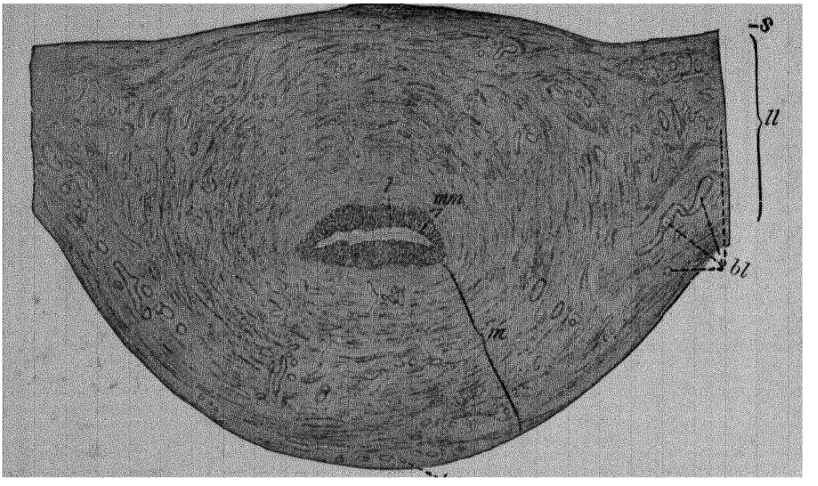

FIG. 610.—SECTION OF HUMAN UTERUS. (Sobotta.) Twice the natural size.
s, serous layer; *lm*, longitudinal muscular fibres; *m*, circular muscle; *mm*, mucous membrane; *l*, cavity of uterus; *ll*, ligamentum latum; *bl*, blood-vessels.

1. A *serous layer*, derived from the peritoneum, which covers the greater part of the fundus.

2. A *muscular layer*, which is of great thickness and is formed of plain muscular fibres disposed in three, more or less blended, strata. Of these the outer is thin and has its fibres arranged partly longitudinally, partly circularly.

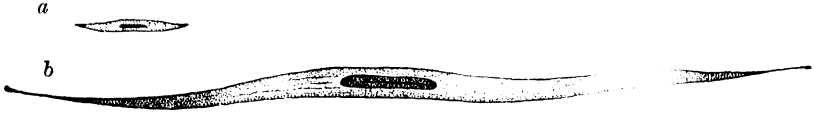

FIG. 611.—MUSCLE-CELLS FROM THE HUMAN UTERUS: (*a*) IN THE VIRGIN CONDITION; (*b*) IN ADVANCED PREGNANCY. Drawn to the same scale. (Sellheim.)

The middle, on the other hand, is thick; its fibres run in different directions, and it contains the ramifications of the larger blood-vessels. The inner layer, again, is thinner and has both longitudinal and circular fibres, many of the latter being prolonged internally into the deeper part of the mucous membrane; the extremities of the uterine glands extend between and amongst the muscle-fibres. In pregnancy there is a great increase in the size of the muscle-cells (fig. 611).

3. A *mucous membrane* (fig. 610, *mm*), composed of soft connective tissue containing a large number of spindle-shaped cells. It is lined by a partly ciliated epithelium and contains long, simple, tubular glands, which take a curved or convoluted course in passing through the membrane (fig. 612, *gl*, and fig. 613). Their epithelium is continuous with that which covers the inner surface of the mucous membrane and is ciliated for some distance within the glands. In the cervix the mucous membrane is marked by longitudinal and oblique ridges; the glands are shorter but more complex than those of the body of the uterus, and are lined by columnar mucus-secreting cells. The glands often contain concretions known as *Nabothian ova*. Near

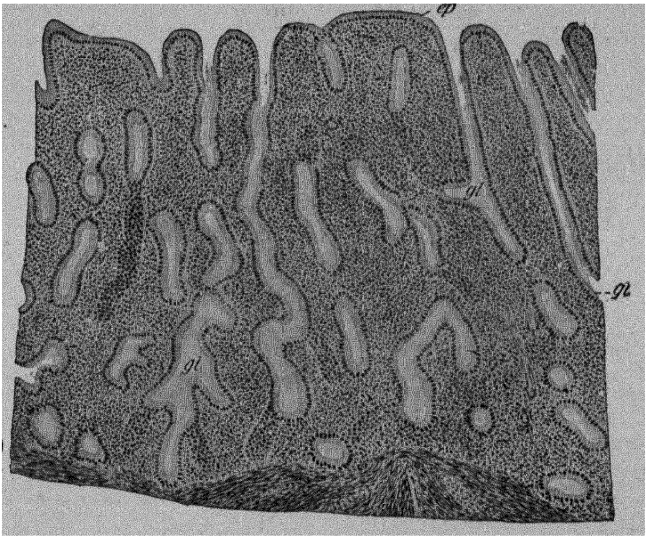

FIG. 612.—SECTION OF THE UTERINE MUCOUS MEMBRANE. (Sobotta.) × 150.
ep, epithelium of cavity; *gl*, glands; *m*, part of muscular wall.

the os uteri the epithelium becomes non-ciliated columnar; at the margin of the os uteri this passes into a stratified epithelium which overlies vascular papillæ of the corium. The mucous membrane has many and large blood-vessels; it also contains a considerable number of lymph-vessels.

In most mammals the uterus of which is composed of two cornua the arrangement of the muscular tissue is simpler than in the human uterus (which was originally double in the embryo and has been formed by the fusion of two such tubes). Fig. 613 exhibits the structure of a cornu of the uterus of the rabbit showing the convoluted glands extending through the mucous membrane; the thick innermost muscular layer which occupies the deepest part of the mucosa; the large blood-vessels in the submucous layer, and the two strata of the true muscular coat outside the main vessels.

Changes accompanying menstruation.—At the commencement of each menstrual period the mucous membrane of the uterus becomes thickened

and extremely congested with blood. Eventually the blood-vessels near the surface become ruptured and the superficial part of the membrane becomes disintegrated and thrown off (fig. 614). These changes are accompanied by a considerable escape of blood into the cavity of the uterus and thence into the vagina. The return to the normal condition then begins and the renewal from the uterine glands of the disintegrated membrane proceeds rapidly. Should pregnancy supervene, the process of renewal results at certain parts in the formation of a greatly thickened mucous membrane,

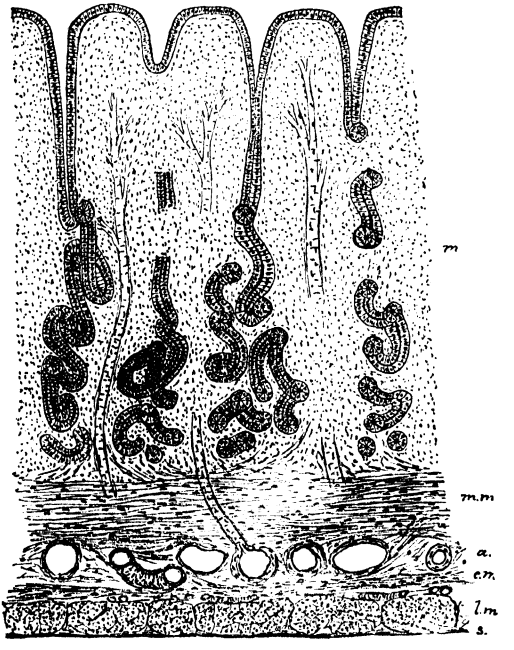

FIG. 613.—SECTION OF A CORNU OF THE RABBIT'S UTERUS. (E. Sharpey-Schafer.)

s. serous layer; *l.m.*, longitudinal muscular fibres; *c.m.*, circular muscular fibres of the muscular coat; *a*, areolar tissue with large blood-vessels; *m.m.*, muscularis mucosæ; *m*, mucous membrane.

with long convoluted glands: this is known as the *decidua*. The muscular layer also becomes enormously hypertrophied during pregnancy; the hypertrophy is due to enlargement of the individual muscle-cells (p. 452).

The phenomenon of *heat* in animals is attended by changes in the uterus which are somewhat analogous to those occurring during menstruation in the human subject. The whole series of alterations—including the changes preparatory, accompanying, and succeeding the periodical blood-flow from the uterus—is known as the *œstrous cycle*.

Structure of the placenta.—When the developing ovum reaches the uterus it becomes embedded in the thickened mucous membrane (decidua) to which it attaches itself firmly by means of its outer layer or chorion, processes of which penetrate into the decidua. The chorion and its processes are covered by a thick syncytium



FIG. 614.—SECTION OF MUCOUS MEMBRANE OF HUMAN UTERUS DURING MENSTRUATION, SHOWING MASSES OF BLOOD ESCAPED FROM RUPTURED CAPILLARIES INTO THE INTER-GLANDULAR TISSUE; AT ONE PLACE (*) THE BLOOD HAS BROKEN THROUGH THE SURFACE EPITHELIUM. (Sellheim.)



FIG. 615.—DIAGRAM TO ILLUSTRATE THE EMBEDDING OF THE OVUM IN THE DECIDUA AND THE FIRST FORMATION OF THE FŒTAL VILLI IN THE FORM OF A SYNCYTIAL TROPHOBLAST (DERIVED FROM THE OUTER LAYER OF THE OVUM) WHICH IS INVADING SINUS-LIKE BLOOD-SPACES IN THE DECIDUA. (T. H. Bryce.)

termed the trophoblast; this burrows its way into the uterine mucous membrane and gives off villus-like branching processes—chorionic villi—which enter large vascular sinuses in the decidua, where they become bathed with arterial maternal blood (fig. 615). In the meantime tissue conveying blood-vessels has grown into the chorionic villi from the mesoderm of the fœtus bringing to them fœtal blood by way of the umbilical arteries. Later the original epithelial covering of the villi becomes attenuated and only a thin syncytial layer of cells separates the tissue of the villus containing fœtal capillaries from the maternal blood in the sinuses. Some of the villi remain hanging freely into the sinuses, others are attached to their wall or to fibrous septa and trabeculæ which extend across the sinuses and serve partially to separate these into loculi (fig. 616). The maternal blood is conveyed to the

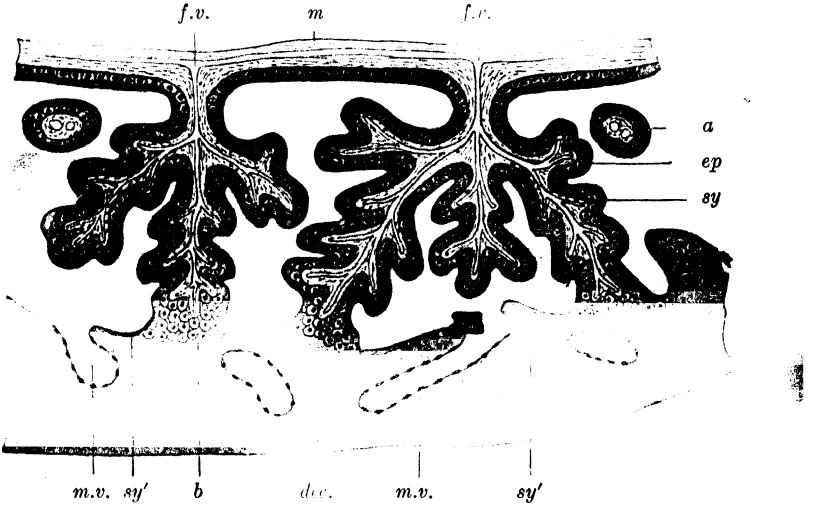

FIG. 616.—DIAGRAM OF A FURTHER STAGE IN THE FORMATION OF THE PLACENTA, SHOWING THE FŒTAL VILLI WITHIN THE BLOOD-SPACES OF THE PLACENTA AND PARTLY ATTACHED TO THE DECIDUAL WALL. (T. H. Bryce.)

The villi are now occupied by a core of vascular mesoderm. They are covered by a syncytium (continued on to the decidua, *dec.*), within which is a layer of epithelium-cells; *f.v.*, fœtal vessels; *m.v.*, maternal vessels; *m*, chorion; *a*, a villus cut across; *b*, attachment of a villus; *sy*, syncytial covering to villi continued at *sy'* on to decidua; *ep*, epithelial layer under syncytium.

sinuses of the decidua by small spiral arteries and is taken away by corresponding veins.

A section across the discharged placenta or afterbirth shows it to be bounded on the fœtal side by the chorion, covered by the smooth amnion, and on the maternal side by the thin and somewhat uneven detached part of the decidua—a separation having occurred in the substance of the decidua when the placenta becomes detached from the uterus. Between these two boundaries is a spongy mass which, in sections examined under the microscope, appears to be formed (fig. 617) of a continuous blood-space in which an enormous number of fœtal villi and fibrous trabeculæ of varying thickness are seen, cut in various directions. Each villus (fig. 618) is composed of jelly-like connective tissue covered by a syncytial layer of epithelium. Within the larger villi arterioles and venules are seen and, in some, capillaries as well; within the smaller only capillaries. Some villi are observed which appear to be undergoing a fibrous change (fig. 617).

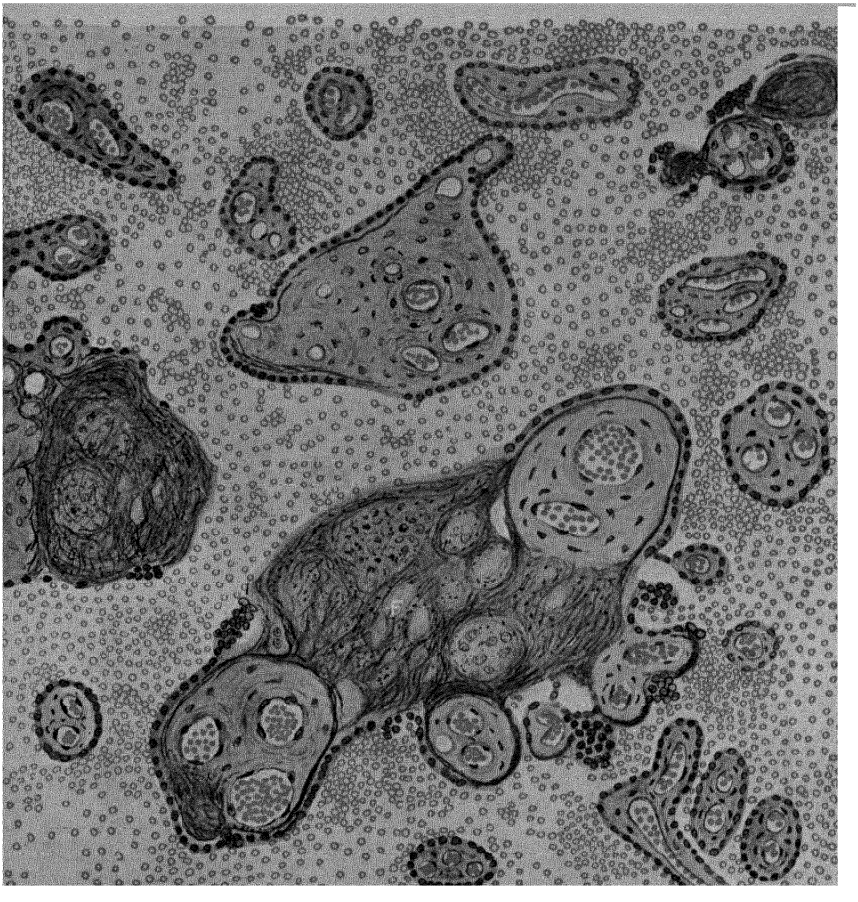

FIG. 617.—SECTION OF A PLACENTA AT FULL TIME. (T. H. Bryce.) From a preparation by J. H. Teacher.

One or two of the villi show a fibrous change. For the sake of distinction the fœtal blood-corpuscles are represented as solid dots, the maternal as circles.

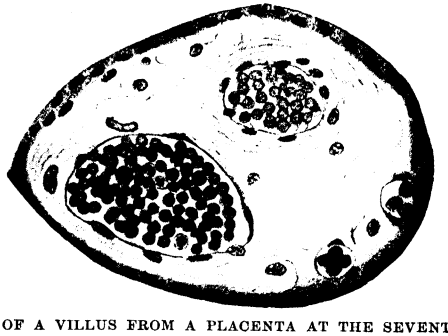

FIG. 618.—SECTION OF A VILLUS FROM A PLACENTA AT THE SEVENTH MONTH. Highly magnified. (T. H. Bryce.)

THE CLITORIS, VAGINA, AND URETHRA.

The **clitoris** is similar in structure to the penis, being mainly composed of erectile or cavernous tissue arranged in structures corresponding generally

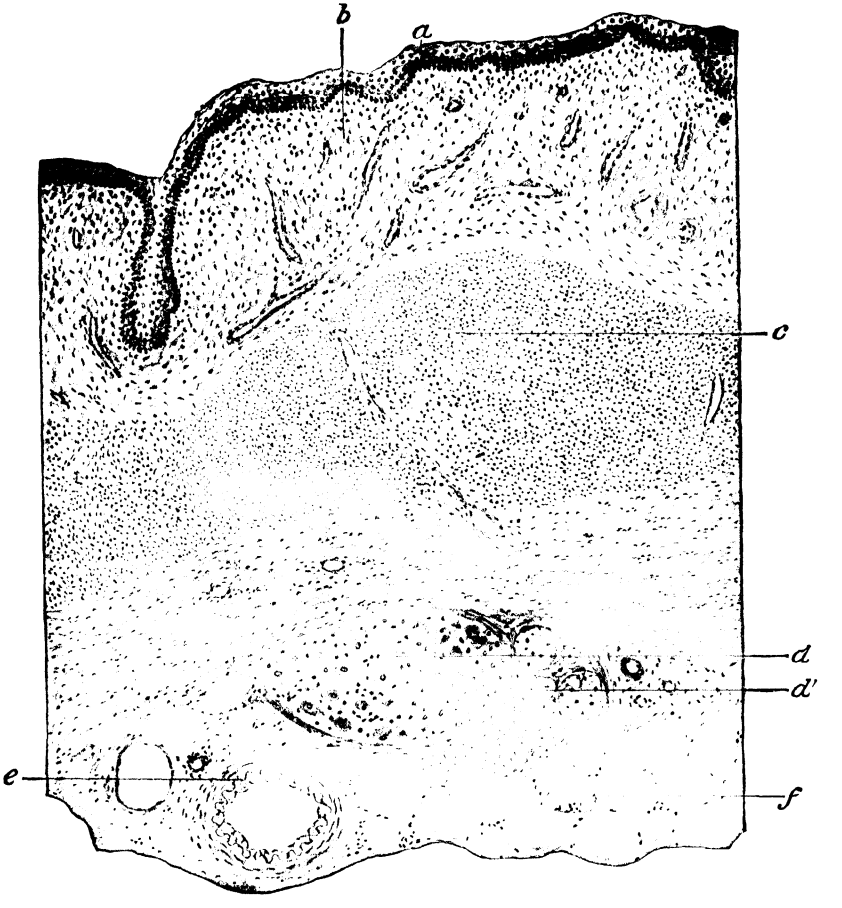

FIG. 619.—SECTION OF VAGINA OF MONKEY. (Marshall.)

a, stratified epithelium; *b*, corium of mucous membrane; *c*, muscular layer: the fibres cut across; *d*, a small ganglion; *d'*, nerve-bundles; *e*, a small artery; *f*, fat-cells.

with the corpora cavernosa and corpus spongiosum but much less developed. There are also two oval masses of erectile tissue, one on each side of the vaginal orifice; as well as an intermediate collection of plexiform veins which join these masses with the corpus spongiosum. The clitoris is not traversed by the urethra as in the male organ.

The **vagina** is lined by a mucous membrane furnished with a low stratified

epithelium (fig. 619, *a*) with broad papillary elevations. Outside the epithelium is the *corium* (*b*) composed of a very vascular, dense, connective tissue. There are no glands in the mucous membrane. Outside the corium is a well-marked *muscular coat* (*c*) formed of plain muscle, the fibres having mainly a longitudinal direction. They are continued from the fibres of the uterus. Outside the muscular coat is a *fibrous layer.*

Bartholin's glands, which correspond with Cowper's glands in the male, lie on each side of the vagina near its upper end. Their ducts open into diverticula at the side of the orifice of the vagina. Bartholin's glands are of the compound racemose type, with mucous alveoli, lined with clear columnar cells.

In rodents (*e.g.* mouse, rat, guinea-pig) the secretion of the vagina furnishes unmistakable indications of the commencement and progress of œstrus. If a smear of the secretion is made upon a microscopic slide and stained, little is seen in the an-œstral (di-oestral) condition beyond a few scaly epithelium cells and leucocytes. With the commencement of œstrus (first stage) the leucocytes disappear and a large number of squamous cells, some without nuclei, others with small nuclei, are seen. A little later (second stage) the fluid from the vagina is crowded with large rounded cells with conspicuous nuclei which, as well as the cytoplasm, stain deeply. There are still a few squamous cells but usually no leucocytes. In the third stage of œstrus, the large rounded cells are still present but less numerous, and there are a few scaly cells, but the secretion is full of polymorph leucocytes which also invade the epithelium cells, some of which are crowded with them. The fourth and last stage resembles the third except that there are generally many red-cells mingled with the leucocytes. After this the secretion gradually reassumes the an-œstral condition. The whole series of changes occupies in the guinea-pig from fifteen to twenty hours.

The **urethra** in the female runs from the bladder parallel with the anterior wall of the vagina, with the fibrous layer of which it partly blends. As in the male sex, the wall of the urethra is formed of three coats, *mucous*, *submucous*, and *muscular*. The *mucous membrane* is lined throughout by stratified epithelium, except quite near the bladder where the epithelium is transitional. The *submucous coat* contains cavernous tissue, or at least a close plexus of veins. The *muscular coat* has two layers of plain muscle, an inner longitudinal and an outer circular; there are also a few longitudinal striated muscle-fibres, chiefly confined to the anterior aspect of the tube.

Numerous small acinous glands, similar to those of the prostate in the male, open on to the mucous membrane.

LESSON XXXIX.

THE SPINAL CORD.

1. SECTIONS of the spinal cord from the cervical, dorsal, and lumbar regions. If the human spinal cord cannot be obtained sufficiently fresh, that of a dog, cat, rabbit, or monkey may be used. It is to be hardened by suspending it immediately after removal from the body in a tall jar of formol (10 per cent.). After a day or two it may be transferred to 95 per cent. alcohol. Sections are made either by the paraffin or celloidin method: the former is preferable for small cords. Paraffin sections may be stained by Nissl's method, which brings to view the nerve-cells and also stains the axis-cylinders of the nerve-fibres. If it is desired to stain by the Weigert-Pal method, which colours the myelin-sheaths of the nerve-fibres, the cord should be fixed in a large quantity of $2\frac{1}{2}$ per cent. potassium bichromate solution in which it may be left for about a month, after which sections are cut by a freezing microtome. (For the details of staining see Appendix.)

Notice the relative extent of the grey as compared with the white matter in the different regions of the cord.

Sketch a section from each region under a low power. Sketch also a small portion of the white substance, two or three nerve-cells, and the central canal with its lining epithelium and surrounding neuroglia under the high power.

Measure the diameter of some of the nerve-fibres in the central columns, in the lateral columns, and in the dorsal columns.

2. The early development of the spinal cord may be studied in sections of chick embryos at various ages.

GENERAL STRUCTURE OF THE SPINAL CORD.

The **spinal cord** is composed of grey matter in the centre and of white matter externally. It is invested by three membranes, termed respectively *pia mater*, *arachnoid*, and *dura mater* (fig. 620). The pia mater is everywhere in contact with the surface of the cord; by its means the blood-vessels are distributed to the organ. The pia mater is in fact largely formed of small arteries and veins supplying the nervous substance, to which it is closely bound down by their capillary branches. Covering its outer surface is a layer of endothelium cells.

Next to the pia mater and separated from it by a considerable space, termed the subarachnoid space, is the arachnoid membrane. In some parts the arachnoid lies close to the dura mater; in others it is separated from it by a space containing fluid, known as the subdural space. The fluid in these spaces and in the corresponding spaces around the brain is known as cerebro-spinal fluid (see p. 542). The arachnoid is a non-vascular areolar structure, very delicate in texture and covered with endothelium cells.

The dura mater, which immediately lines the vertebral canal, is a strong fibrous membrane. It is covered on its inner surface with a continuous layer

of endothelium. All three membranes are continued into the connective-tissue sheaths of the issuing spinal nerves.

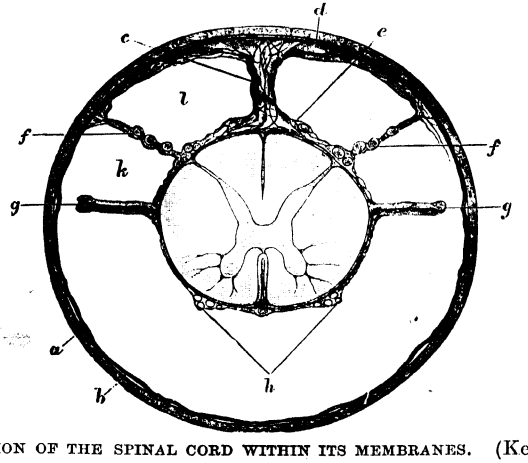

FIG. 620.—SECTION OF THE SPINAL CORD WITHIN ITS MEMBRANES. (Key and Retzius.)
a, dura mater; *b*, arachnoid; *c*, septum of arachnoid; *d*, *e*, trabeculæ of arachnoid; *f*, bundles of dorsal root; *g*, ligamentum denticulatum; *h*, bundles of ventral root; *k*, *l*, subarachnoid space.

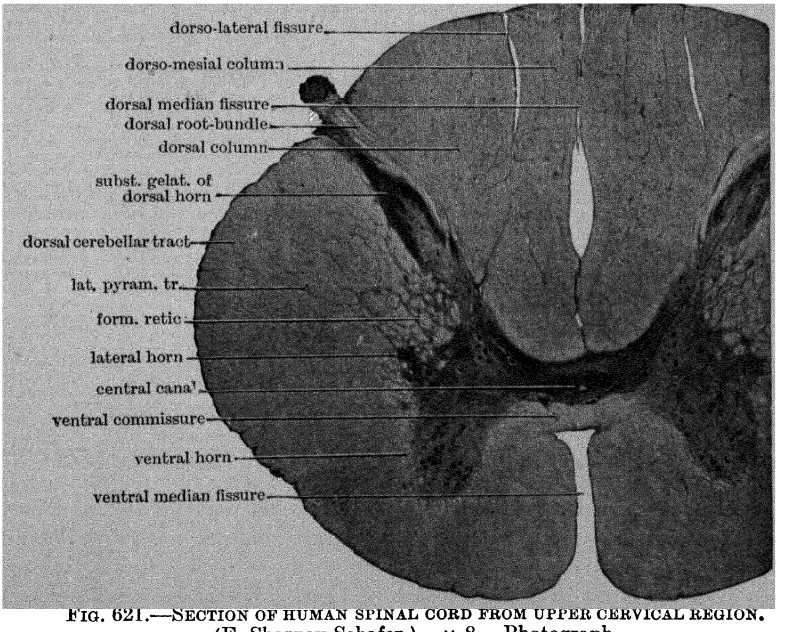

FIG. 621.—SECTION OF HUMAN SPINAL CORD FROM UPPER CERVICAL REGION.
(E. Sharpey-Schafer.) × 8. Photograph.

At the middle of the ventral (anterior) and dorsal (posterior) surfaces the pia mater dips into the substance of the cord in the *ventral* and *dorsal median fissures*, so as to divide it almost completely into two lateral halves (fig. 621). These are, however, united by an isthmus or bridge, composed

ventrally of transversely crossing white fibres (*white commissure*), dorsally of grey matter (*grey commissure*); in the middle of the grey commissure is a minute canal lined by ciliated epithelium (*central canal*).

Each lateral half of the spinal cord contains a crescent of grey matter, joined to the corresponding crescent of the opposite side by the grey commissure. Of the two horns of the crescent the dorsal is the narrower and comes near the surface of the cord: close to it the bundles of the dorsal nerve-roots enter the cord. The bundles of the ventral nerve-roots emerge from the corresponding horn.

According to Ingbert about 1,300,000 nerve-fibres enter the cord by the dorsal roots, and about one-third that number leave it by the ventral roots.

The dorsal root-fibres are derived from the cells of the spinal ganglia, which lie outside the cord; the ventral root-fibres from cells within the grey matter, chiefly from cells in the ventral horn, but also from cells in the middle and dorsal parts of the grey matter and (especially in the thoracic region) from cells in the intermedio-

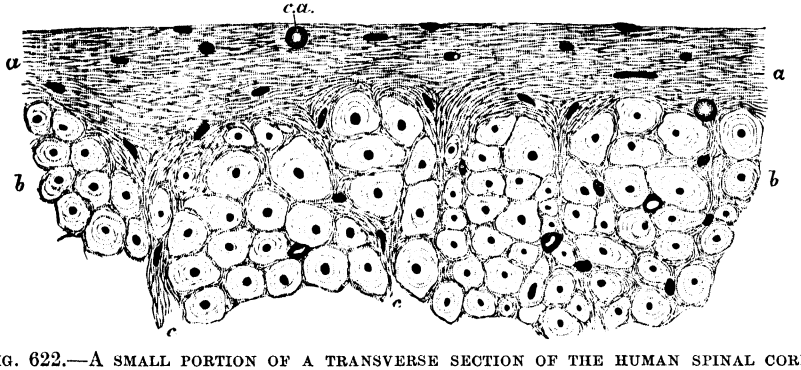

FIG. 622.—A SMALL PORTION OF A TRANSVERSE SECTION OF THE HUMAN SPINAL CORD IN THE REGION OF THE LATERAL COLUMN, TO SHOW THE SUPERFICIAL NEUROGLIA (E. Sharpey-Schafer.) Highly magnified.

a, *a*, superficial neuroglia; *b*, *b*, transverse section of part of the lateral column of the cord, in which the dark points are the axis-cylinders, and the clear areas the myelin sheaths of the nerve-fibres. The superficial neuroglia is seen to exhibit the appearance of a fine net-work, in which numerous nuclei and one or two *corpora amylacea* (*c.a.*) are embedded, and to extend inwards (*c*, *c*) among the nerve-fibres.

lateral cell-column (lateral horn). The latter probably furnish the autonomic (sympathetic) fibres of the ventral roots, while the cells of the ventral horn furnish the fibres which are distributed to the voluntary muscles.

The **white matter** of each half of the cord is subdivided by the approach of the dorsal horn to the surface into two unequal columns—*ventro-lateral* and *dorsal*. A distinction is sometimes drawn between ventral and lateral portions of the ventro-lateral column, although there is no line of demarcation between them. In the upper part of the cord the dorsal column is subdivided by a septum of connective tissue into two—the *dorso-mesial column* (*funiculus gracilis*), and the *dorso-lateral column* (*funiculus cuneatus*).

The white matter is composed of longitudinally coursing, myelinate nerve-fibres, which in sections stained with toluidin-blue appear as clear circular areas with a stained dot, the axis-cylinder, near the middle (fig. 622); while in sections stained by the Weigert-Pal method they appear as dark

circles with a clear centre. The nerve-fibres vary in size in different parts; on the whole those nearest to the surface of the cord are larger than those

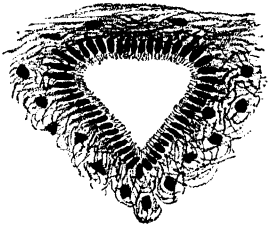

FIG. 623.—SECTION OF THE CENTRAL CANAL OF THE SPINAL CORD OF A CHILD, SHOWING ITS CILIATED EPITHELIUM AND THE SURROUNDING CENTRAL NEUROGLIA. (E. Sharpey-Schafer.) Moderately magnified.

nearest to the grey matter; but there is a bundle of very small fibres opposite the tip of the posterior horn.

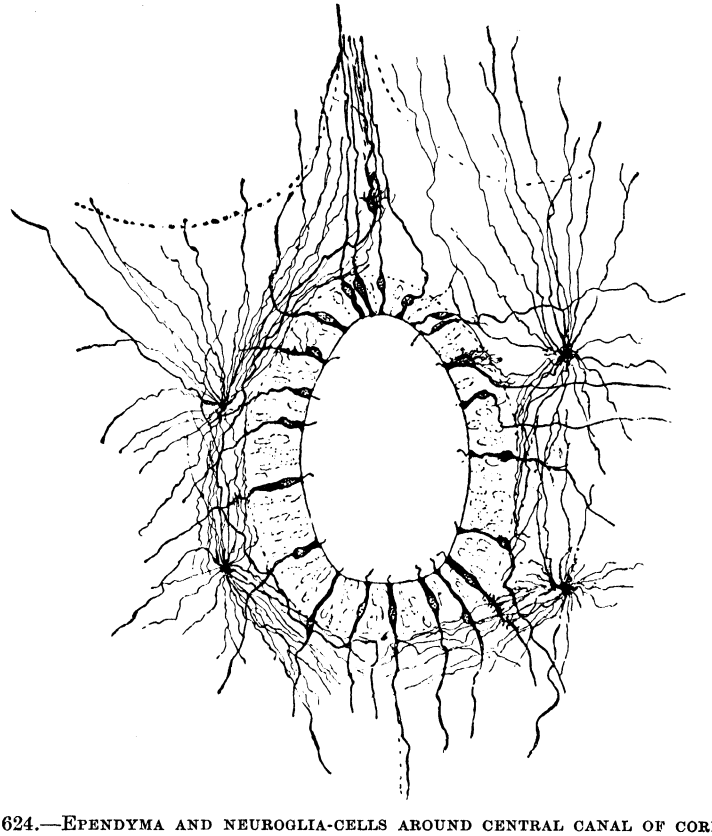

FIG. 624.—EPENDYMA AND NEUROGLIA-CELLS AROUND CENTRAL CANAL OF CORD. (Lenhossék.) Golgi method.

The myelinate fibres are supported by *neuroglia*, composed of neuroglia cells and fibres. The neuroglia is accumulated in greater amount at the

surface of the cord underneath the pia mater, particularly, in the human cord, near the entrance of the dorsal roots (fig. 622); and it extends into the grey matter, in which it is especially abundant in the *substantia gelatinosa* at the apex of the dorsal horn and around the central canal.

The **grey matter,** besides neuroglia, contains an interlacement of nerve-fibres and the arborisations of the dendrons of the nerve-cells, the nucleated bodies of which are embedded in it.

The **central canal** of the spinal cord, which is occupied by cerebro-spinal fluid, is continued above the cord into the fourth ventricle of the brain.

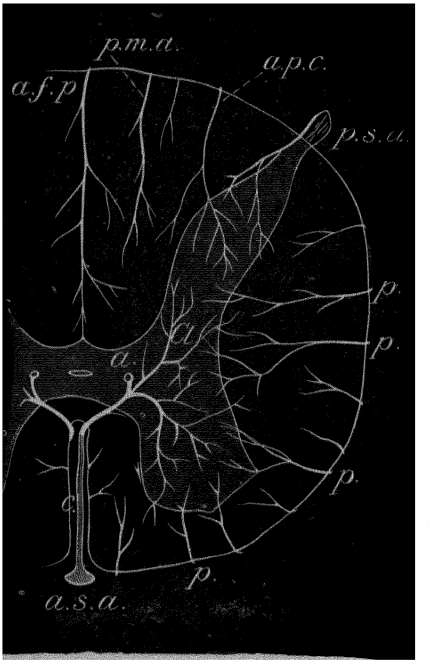

FIG. 625.—DIAGRAM SHOWING DISTRIBUTION OF ARTERIES TO THE WHITE AND GREY MATTER OF THE CORD. (Obersteiner.)

It is lined by columnar ciliated epithelium-cells (*ependyma*) surrounded by a quantity of neuroglia (figs. 623, 624). The cells are best seen in the spinal cord of animals and in the child; in the human adult they have frequently become proliferated so as to block the central canal, and cilia are no longer present. In the early embryo their fixed extremities extend through the whole thickness of the cord to reach the pia mater. This condition is permanent in many of the lower vertebrata.

Blood-vessels of the spinal cord.—The blood-supply of the grey matter is derived mainly from a series of arterioles, which come off from the medially situated ventral spinal artery (fig. 625, *a.s.a.*), pass into the ventral median fissure, and at the bottom of this divide each into two branches (*a*), one for the grey matter of each lateral half

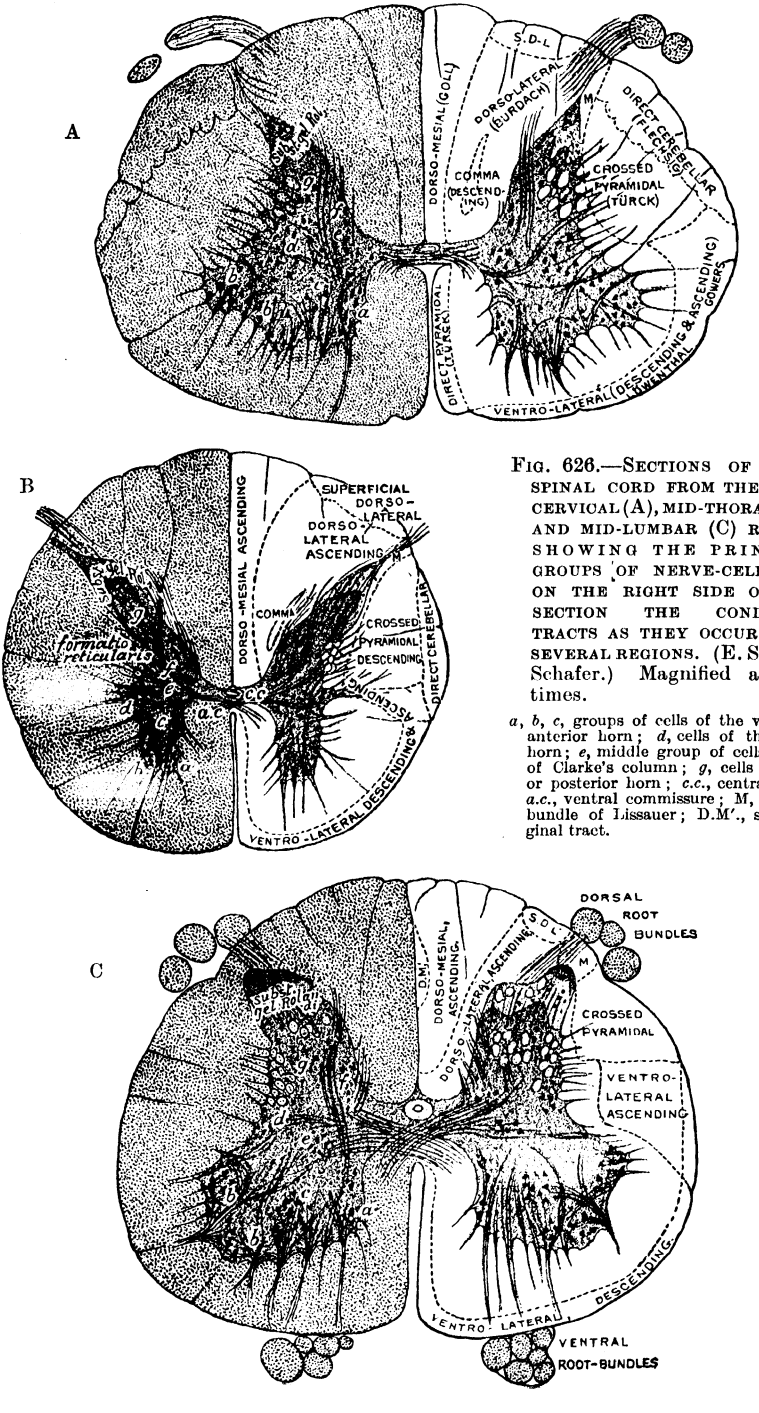

FIG. 626.—SECTIONS OF HUMAN SPINAL CORD FROM THE LOWER CERVICAL (A), MID-THORACIC (B), AND MID-LUMBAR (C) REGIONS, SHOWING THE PRINCIPAL GROUPS OF NERVE-CELLS, AND ON THE RIGHT SIDE OF EACH SECTION THE CONDUCTING TRACTS AS THEY OCCUR IN THE SEVERAL REGIONS. (E. Sharpey-Schafer.) Magnified about 4 times.

a, *b*, *c*, groups of cells of the ventral or anterior horn; *d*, cells of the lateral horn; *e*, middle group of cells; *f*, cells of Clarke's column; *g*, cells of dorsal or posterior horn; *c.c.*, central canal; *a.c.*, ventral commissure; M, marginal bundle of Lissauer; D.M'., septomarginal tract.

of the cord. In the grey matter is a very close capillary plexus which is supplied not alone by the vessels just mentioned, but also by small arterioles (*p*) which, converging from the small arteries of the pia mater, pass through the white matter and supply this as they traverse it. These arterioles join with branches of the above-mentioned ventral spinal artery and of the dorsal spinal arteries (*p.s.a.*), which run on each side along the line of the dorsal roots to form the capillary plexus. The capillary plexus of the white matter is far less dense than that of the grey matter. Its meshes are chiefly longitudinal.

The veins of the spinal cord accompany the arteries. Two longitudinal venous vessels, accompanying corresponding anastomotic arterioles, are seen, one on either side of the central canal, in most transverse sections of the cord.

CHARACTERS OF THE SPINAL CORD IN ITS SEVERAL REGIONS.

In the *cervical region* (fig. 626, A), the white matter, especially that of the lateral columns, occurs in largest proportion. The grey matter in the cervical enlargement is also in considerable amount, and it encroaches, especially in the upper part of the region, in the form of a network (*formatio reticularis*) upon the adjacent part of the lateral white column (fig. 621). The ventral horns are thick and the dorsal slender. The dorso-mesial column is distinctly marked off from the dorso-lateral.

In the *thoracic region* (B) the grey matter is small in amount, and both horns are slender. The whole cord is of smaller diameter than in either the cervical or lumbar region. The columns of nerve-cells known as Clarke's column and the intermedio-lateral column are well marked.

In the *lumbar region* (C) the crescents of grey matter are very thick, and the white substance, especially the lateral columns, relatively small in amount. The isthmus lies nearly in the centre of the cord, whereas in the cervical and dorsal regions it is nearer the ventral surface.

In the part of the spinal cord from which the *sacral* and *coccygeal* nerve-roots take origin grey matter largely predominates, the crescents form thick irregular masses, and the grey isthmus is also of considerable thickness.

LESSON XL.

CENTRAL NERVOUS SYSTEM.

THE SPINAL CORD (*continued*).

1. TRACTS in the spinal cord. The conducting tracts of the spinal cord may be studied in two ways, viz.: (1) by preparing sections of embryonic cords (from the 5th to the 9th month), the sections being stained by the Weigert-Pal process; (2) by preparing sections from the cord of an animal in which semi-section has been performed about 15 days before the animal is killed. After removal the cord is first partly hardened by placing it for a fortnight in Müller's fluid or in 2½ per cent. potassium bichromate solution. Thin pieces taken from below and from above the level of the section are then placed in a solution consisting of two parts of Müller's fluid and 1 part of 1 per cent. osmic acid (Marchi's method).

2. Grouping of cells in the cord. These are studied in sections stained by Nissl's method (see Appendix for methods).

TRACTS OF NERVE-FIBRES IN THE WHITE COLUMNS.

The course of the nerve-tracts in the spinal cord, and in other parts of the central nervous system, can be made out by the method of Flechsig, which involves the study of sections of the developing cord; for it is found that the formation of myelin occurs sooner in some tracts than in others, so that it is easy to make out the distinction between them. Thus, the peripheral nerves and nerve-roots become myelinated in the first half of the fifth month of fœtal life. Of the tracts of the spinal cord, those of Burdach and Goll (see below) are the first to be myelinated, then the tracts of Flechsig and Gowers, all of these being afferent or centripetally conducting, while the pyramid tracts, which are efferent or centrifugally conducting, do not receive their myelin sheath until after birth.

Flechsig found that the fibres of the dorsal roots are myelinated in at least three stages, and that the dorso-lateral tract shows a corresponding differentiation into three chief parts: the *ventral*, *middle*, and *dorsal root-zones*. Probably this differentiation corresponds with functional differences of the fibres.

Another method (that of Waller, p. 192) consists in investigating the course pursued by degeneration of the nerve-fibres in consequence of lesions produced accidentally or purposely. Those tracts in which degeneration of fibres occurs below the lesion are termed 'descending' tracts; those in which it occurs above the lesion are termed 'ascending.' This method,

when combined with the staining process devised by Marchi, is of great value, since it enables even single fibres to be traced far from their source.

Further, the cells whence the fibres of any tract arise can be identified, after a lesion of the tract, by the chromatolysis or degeneration of Nissl-granules which nerve-cells undergo after section of their axons (see p. 192).

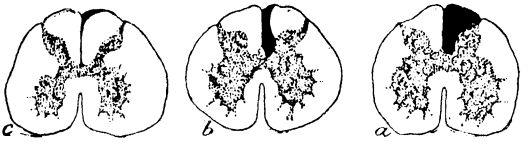

FIG. 627.—DIAGRAM SHOWING THE SITE OF DEGENERATION IN THE DORSAL COLUMN WHICH RESULTS FROM UNILATERAL SECTION OF THE DORSAL ROOTS OF THE SECOND SACRAL TO THE SIXTH LUMBAR NERVES OF THE DOG. (Singer.)

a, sixth lumbar segment; *b*, fourth lumbar; *c* from the mid-thoracic region.

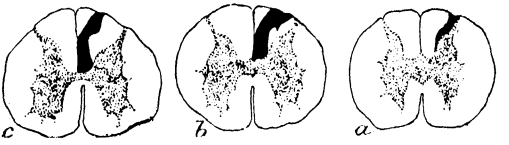

FIG. 628.—DEGENERATIONS FOLLOWING UNILATERAL SECTION OF THE DORSAL ROOT OF THE ELEVENTH AND TWELFTH THORACIC NERVES OF THE DOG. (Singer.)

a, at level of twelfth thoracic; *b*, of third thoracic; *c*, from mid-cervical region.

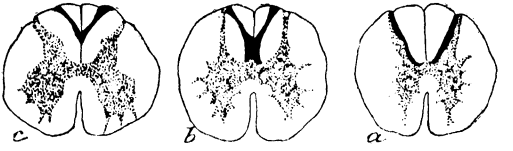

FIG. 629.—DEGENERATIONS FOLLOWING BILATERAL SECTIONS OF THE DORSAL ROOTS OF THE SECOND THORACIC TO FIFTH CERVICAL NERVES OF THE DOG. (Kahler.)

a, at level of first thoracic; *b*, at sixth cervical; *c*, at first cervical.

Tracts of the dorsal column.—1. *Tract of Goll.*—Most of the fibres of the *dorso-mesial column* belong to a tract known as the *tract of Goll* (fig. 630, 6). This consists of fibres derived from the dorsal nerve-roots of the sacral, lumbar, and lower thoracic nerves, which, after having entered the dorso-lateral columns, shift, as they ascend, towards the dorsal median fissure and form a distinct tract, marked off from the rest of the dorsal column in the cervical region by a slight furrow and a septum of pia mater (fig. 621). The tract ends amongst the cells of the *nucleus gracilis* of the medulla oblongata.

2. *Tract of Burdach.*—The *dorso-lateral column* is also mainly composed of fibres of the dorsal nerve-roots, which run for a certain distance in it before entering the grey matter of the cord or of the medulla oblongata. As each mass of dorsal root-bundles enters the column close to the apex of the horn it, so to speak, pushes the root-fibres which have already entered nearer to the median fissure; hence those derived from the lowest nerve-roots are

nearest that fissure (tract of Goll), while those derived from the highest remain near the horn (tract of Burdach) (figs. 627 to 629). Many of the fibres of both tracts pass into the grey matter either immediately on entering the cord or in their course upwards; the rest are continued into the medulla oblongata, and those of the tract of Burdach end by arborising amongst the cells of the *nucleus cuneatus*.

3. *Comma tract.*—Besides the tracts of Burdach and Goll, which are wholly composed of long 'ascending' fibres having their cells of origin in the ganglia on the dorsal roots, there are a few fibres which have a shorter 'descending' course in the dorsal columns. These are thought by some authors to arise from descending branches of the dorsal root-fibres, by others

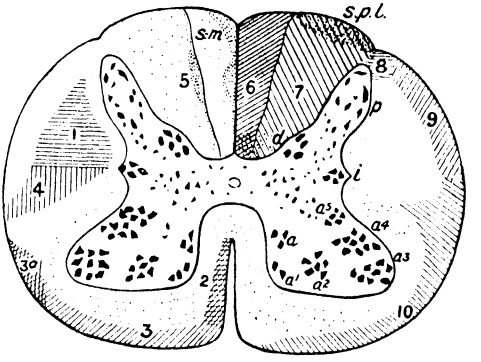

FIG. 630.—DIAGRAM SHOWING THE ASCENDING (RIGHT SIDE) AND DESCENDING (LEFT SIDE) TRACTS IN THE SPINAL CORD. (E. Sharpey-Schafer.)

1, Crossed pyramid-tract; 2, direct pyramid-tract; 3, ventro-lateral descending; 3*a*, bundle of Helweg; 4, rubro-spinal; 5, comma; 6, dorso-mesial; 7, dorso-lateral; 8, tract of Lissauer; 9, dorsal cerebellar; 10, ventro-lateral ascending or ventral cerebellar; *s-m*, septo-marginal; *s.p.l.*, superficial dorso-lateral fibres (dorsal root-zone of Flechsig); *a* to a^5, groups of cells in the ventral horn; *i*, intermedio-lateral group or cell-column in the lateral part of the grey matter; *p*, cells of dorsal horn; *d*, dorsal nucleus of Stilling (cell-column of Clarke). The scattered dots indicate the situation of 'endogenous' fibres (arising in grey matter of cord) having for the most part a short course. There are many more of these fibres near the grey matter (not indicated in the diagram).

from cells in the grey matter of the cord. They form the so-called *comma tract* (fig. 630, 5).

Proprio-spinal or endogenous fibres of the dorsal column.—These comprise a few fibres (*septo-marginal*), chiefly accumulated near the median fissure (*oval bundle*) and others near the dorsal surface (*median triangular bundle*), as well as others scattered in the column; they are derived from cells in the grey matter of the cord itself, and all take a 'descending' course in the dorsal column. There are, however, some fibres which arise in the grey matter and have an 'ascending' course: these are especially numerous in the ventral part of the column.

Tracts of the ventro-lateral column: descending tracts.—1. *Pyramid-tract* or *cortico-spinal tract.*—At the dorsal part of the lateral column there is a tract of moderately large 'descending' fibres running in the lateral column of the spinal cord from the opposite side of the brain, after having for the most part crossed at the decussation of the pyramids of the medulla oblongata

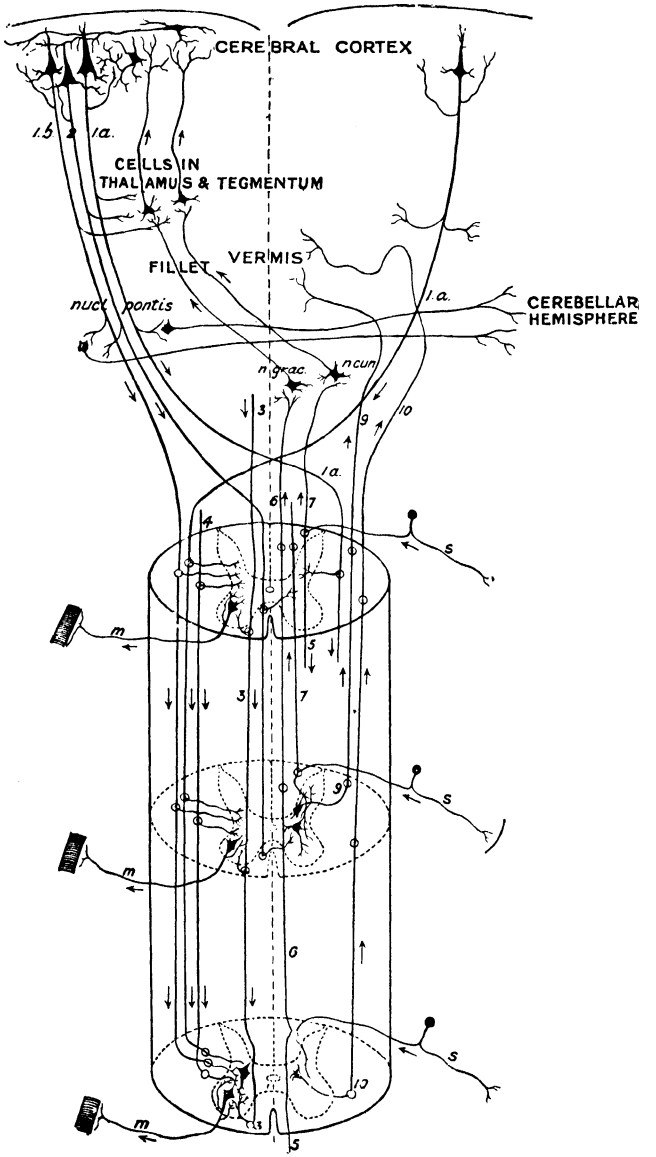

FIG. 631.—DIAGRAM SHOWING THE COURSE, ORIGIN, AND TERMINATION OF THE FIBRES OF THE PRINCIPAL TRACTS OF THE WHITE MATTER OF THE SPINAL CORD. (The numbers in this diagram refer to fibres of the tracts shown with corresponding numbers in fig. 630.)

'Descending' tracts:—*1a*, a crossing fibre of the lateral pyramid tract; *1b*, a non-crossing fibre of the pyramid-tract passing to the lateral column of the same side; *2*, a fibre of the direct pyramid-tract; *3*, a fibre of the ventro-lateral descending tract; *4*, a fibre of the rubro-spinal tract; *5*, fibres of the comma tract. 'Ascending' tracts:—*6*, a fibre of the dorso-mesial tract; *7*, fibres of the dorso-lateral tract; *9*, one belonging to the dorsal cerebellar; *10*, a fibre of the ascending ventro-lateral or ventral cerebellar tract. Also, *m*, motor nerve-fibres; *s*, sensory (afferent) nerve-fibres; *n.grac.*, a cell of nucleus gracilis; *n.cun.*, a cell of nucleus cuneatus; *nucl. pontis*, cells of nucleus of pons. The arrows indicate the direction of the nerve-impulses.

(fibres of *crossed lateral pyramid-tract*, fig. 630, 1 ; fig. 631, *1a*). Intermingled with the fibres of the crossed pyramid-tract in the lateral column are a few fibres of the pyramid which have not crossed in the medulla oblongata, and are therefore derived from the cerebral cortex of the same side (*uncrossed lateral pyramid-fibres*, fig. 631, *1b*). Certain large fibres, which lie in the ventral column next to the median fissure in the human subject, also belong to a portion of the same tract which has not undergone decussation (fibres of *direct pyramid-tract*, figs. 630, 631, *2*). The direct pyramid-tract is only found in man and the anthropoid apes; it varies considerably in extent. It is always most distinct in the cervical region, becoming gradually lost as it is traced down.

The pyramid-tracts are composed of ' descending ' fibres, which have their cells of origin in the cerebral cortex (precentral and paracentral gyri) and end by arborisations in the grey matter at the base of the dorsal horn of the spinal cord. In some mammals (rat, mouse, guinea-pig, sheep, kangaroo, squirrel, etc.) the pyramid-tracts are situated in the dorsal columns of the cord, in others, including the monkey, dog, cat, and rabbit, they run wholly in the lateral columns. The pyramid-tracts are very small in the lower mammals, and are not found at all in vertebrates below mammals.

It has been calculated that there are about 80,000 fibres of the pyramid-tract in each half of the human cord. The pyramid-tracts are generally regarded as the paths along which volitional impulses are conveyed from the cerebral cortex to the spinal cord. But experiments have shown that they are not the only cortico-spinal paths nor even the most important in many mammals, for the paralysis which results from their section is soon recovered from in most cases, whereas that resulting from section of the ventral column and adjacent part of the lateral column may be marked and permanent in animals, although such section in man may produce no motor paralysis. It appears to be the finer and more delicate movements which are permanently lost when the pyramid-tract is affected by disease in man.

2. *Tract of Loewenthal.*—Besides the pyramid-tracts there are four other ' descending ' tracts of fibres in the ventro-lateral column. One of these (the *ventro-lateral descending tract* or *tract of Loewenthal*, figs. 630, 631, *3*) lies on the side of the ventral median fissure, and extends along the margin of the cord in the ' root ' zone, even reaching the ventral part of the lateral column. These fibres are continued down, chiefly from the *dorsal longitudinal bundle* of the medulla oblongata and pons (*bulbo-spinal* and *ponto-spinal fibres*), partly from other sources which will be afterwards referred to. They end by arborisations in the ventral horn. Similar arborisations pass from the dorsal longitudinal bundle to the nuclei of the motor cranial nerves. This tract is mainly uncrossed.

3. *Rubro-spinal tract.*—Another ' descending ' tract in the ventro-lateral column lies just in front of the crossed pyramid-tract; this is the *rubro-spinal tract* (figs. 630, 631, *4*). Its fibres end by arborising in the grey matter of the middle of the crescent; the situation of its cells of origin is the red nucleus of the tegmentum on the opposite side of the mid-brain (p. 508). This tract is also known as *Monakow's bundle.* Some of its fibres may be derived from cells in the reticular formation of the pons and medulla oblongata.

4. *Tecto-spinal fibres.*—Intermingled with the fibres of the rubro-spinal tract (but far fewer in number in man) are fibres derived from the quadrigeminal bodies of the opposite side. These fibres form a part of the *tectospinal tract.* Another part of this tract (*ventral longitudinal bundle*) passes down the ventral column of the cord along with the fibres of the tract of Loewenthal.

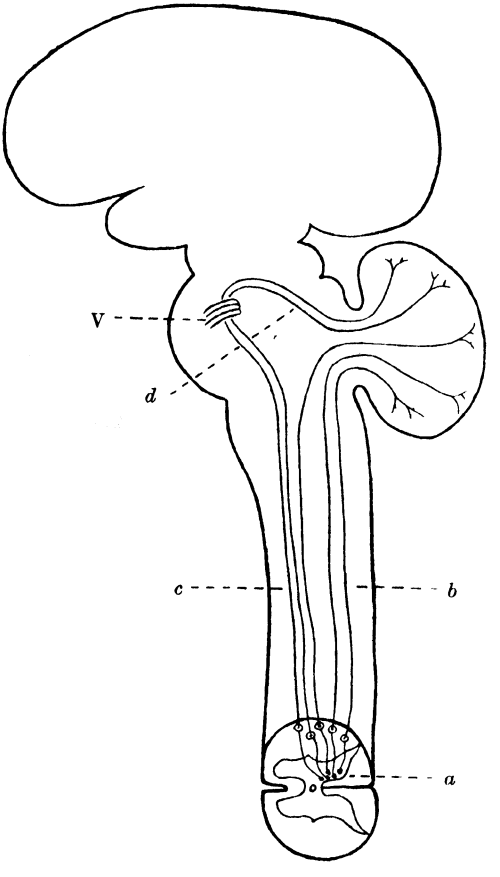

FIG. 632.—DIAGRAM SHOWING THE ORIGIN, COURSE, AND DESTINATION OF THE SPINO-CEREBELLAR FIBRES CONSTITUTING THE TRACTS OF FLECHSIG AND OF GOWERS. (E. Sharpey-Schafer.)

a, cells of Clarke's column in the dorsal horn of the spinal cord, giving origin to fibres which pass into both spino-cerebellar tracts; *b*, tract of Flechsig, passing above by way of the restiform body to the cerebellar vermis; *c*, tract of Gowers; *d*, passage of most of its fibres along the superior peduncle to the vermis of the cerebellum: they are seen turning sharply backwards immediately after passing the level of the place of exit of the 5th nerve (V). Some of the fibres of this tract leave it in the medulla oblongata and join the fibres of Flechsig which are passing to the cerebellum by its inferior peduncle. One such fibre is shown in the diagram.

5. *Olivo-spinal tract.*—This is a small triangular group of 'descending' fibres traceable from the neighbourhood of the olive in the medulla oblongata, and passing down the cervical cord in the ventral part of the lateral column (fig. 630, 3″); the exact origin and destination of its fibres is unknown. It is also known as the *bundle of Helweg.*

Ascending tracts of the ventro-lateral column.—1. *Tract of Flechsig.*—This is a well-marked tract, which is, however, only distinct in the cervical and dorsal regions, where it lies external to the crossed pyramid-tract. It consists of large fibres derived from the cells of Clarke's column (fig. 630, *d*) which pass into the lower or posterior part of the cerebellar vermis by the inferior peduncle of the same side (*dorsal spino-cerebellar tract*; *direct cerebellar tract*, fig. 626; also figs. 630, 631, *9*; 632, *b*).

2. *Tract of Gowers, ventro-lateral ascending tract.*—This is situated ventrally to the tract of Flechsig and the lateral crossed pyramid-tract in the lumbar region; while in the thoracic and cervical regions it forms a narrow band of fibres curving round close to the lateral surface of the cord,

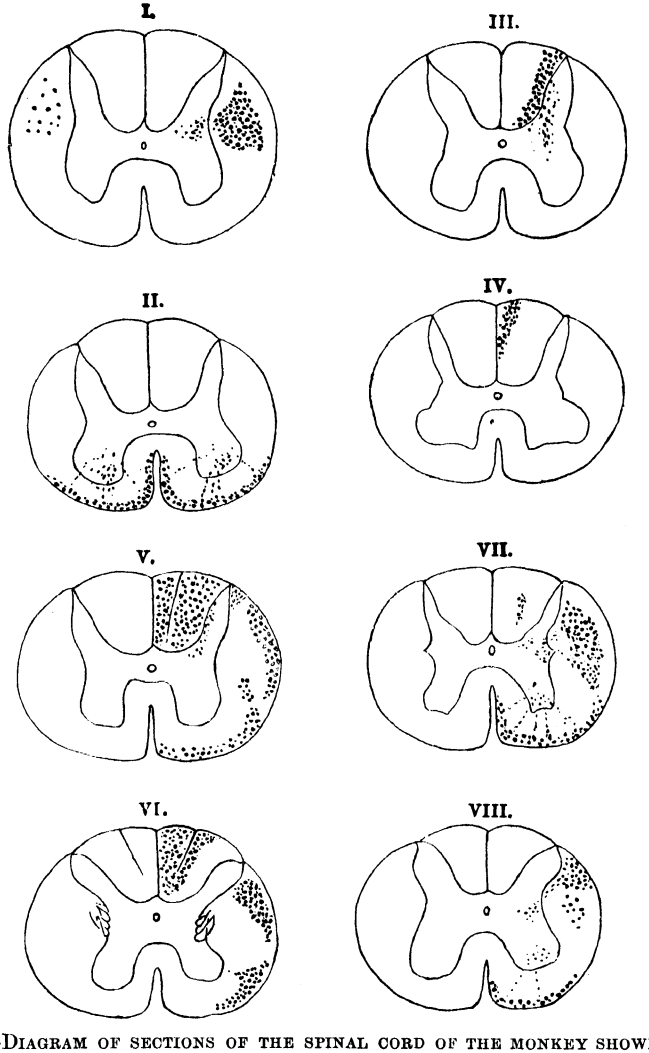

FIG. 633.—DIAGRAM OF SECTIONS OF THE SPINAL CORD OF THE MONKEY SHOWING THE POSITION OF DEGENERATED TRACTS OF NERVE-FIBRES AFTER SPECIFIC LESIONS OF THE CORD ITSELF, OF AFFERENT NERVE-ROOTS AND OF THE PRECENTRAL REGION OF THE CEREBRAL CORTEX. (E. Sharpey-Schafer.)

The degenerations are shown by the method of Marchi. The left side of the cord is at the reader's left.

I. Degenerations resulting from extirpation of the precentral area of the cortex of the left cerebral hemisphere. In man there would be some degenerated fibres in the left ventral column also, close to the ventral fissure.

II. Degenerations produced by section of the dorsal longitudinal bundles in the upper part of the medulla oblongata.

III. and IV. Result of section of dorsal roots of the first, second, and third lumbar nerves on the right side. Section III. is from the segment of cord between the last thoracic and first lumbar roots; Section IV. from the same cord in the cervical region.

V. to VIII. Degenerations resulting from (right) lateral section of the cord in the upper thoracic region. V. is taken a short distance above the level of the section; VI., higher up the cord (cervical region); VII., a little below the level of section; VIII., lumbar region.

and extending into the ventral column (figs. 630, 631, *10*). Its fibres are partly intermingled with those of the ventro-lateral descending tract. Most of the fibres of the tract of Gowers are connected with the upper or anterior part of the vermis of the cerebellum. They constitute the *ventral spino-cerebellar tract*, which passes to the cerebellum along with the superior cerebellar peduncle (fig. 632). Both in the cord and medulla oblongata it gives off fibres to join the tract of Flechsig and to pass in this to the cerebellum by the inferior peduncle. According to some authors the tract of Gowers gives off a few fibres to enter the opposite cerebellar hemisphere by the middle peduncle.

Some of the fibres included within the area of Gowers' tract are continued up to the corpora quadrigemina (*spino-tectal tract*). Others pass into the tegmentum of the crus cerebri, where they can be traced as far as the lower part of the thalamus (*spino-thalamic tract*).

Most of the fibres of Gowers' tract take origin from the cells of Clarke's column, of the same side of the cord, especially from its lower part. This is the case at least with the cerebellar fibres. But the tectal and thalamic fibres probably arise from cells situated in the middle and dorsal parts of the grey matter, partly on the same but chiefly on the opposite side of the cord.

3. *Tract of Lissauer.*—Lastly, there is another small tract of fibres which undergoes degeneration above the point of section of the cord. This is the *marginal bundle* of Lissauer (marked M in fig. 626). It is formed by fine fibres from the posterior roots. Many of these fibres are amyelinate. They have been thought to be derived from the small, darkly staining cells of the spinal ganglia (p. 189).

Other portions of the ventro-lateral columns near the grey matter which are differentiated by the method of Flechsig are probably short tracts uniting adjacent portions of the grey matter of the cord.

Proprio-spinal or endogenous fibres of the ventro-lateral column.—Sherrington has shown that in the dog the lateral column in the thoracic region of the cord contains a certain number of long fibres which take origin in the cervical, thoracic and upper lumbar segments and are traceable down to the lumbo-sacral enlargement. These must serve to convey excito-reflex impulses from the upper to the lower parts of the body. Probably similar fibres arise all along the cord from the cells of the lateral column and pass upwards as well as downwards.

A tract of endogenous fibres has been observed in man close to the ventral median fissure lying amongst the fibres of the direct pyramid-tract. This is the *ventral sulco-marginal tract* of Marie.

The ventro-lateral column contains also many endogenous fibres, both ascending and descending, derived from cells in the grey matter of the cord, which have only a short course, serving to connect adjacent segments.

GROUPS OF CELLS IN GREY MATTER OF CORD.

The nerve-cells which are scattered through the grey matter are in part disposed in definite groups. Thus there are several groups of large multipolar

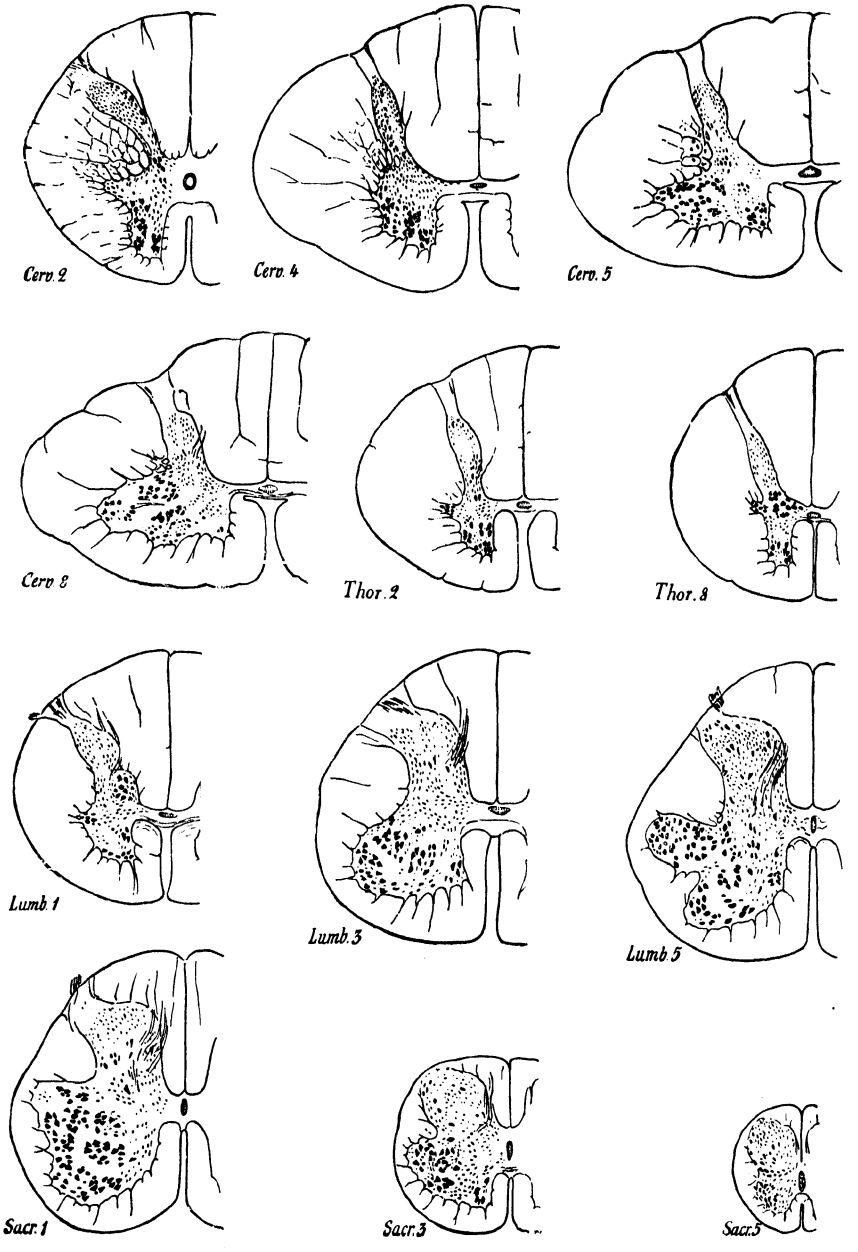

FIG. 634.—DIAGRAM OF SECTIONS OF HUMAN SPINAL CORD AT DIFFERENT LEVELS. (Edinger.)

The names refer to the origin of the corresponding nerve-roots. The relative shape and size of the cord and grey matter, the relative amounts of grey and white matter, and the size and position of the principal cell-groups are shown.

nerve-cells in the ventral horn in the cervical and lumbar enlargements (fig. 634), although in other regions of the cord the number of groups in this situation is reduced to two, a mesial and a lateral. The larger groups in the enlargements correspond with segments of the limb (Van Gehuchten); thus there appear to be groups associated with foot, leg, and thigh, and with hand, arm, and shoulder movements respectively. The groups from which the motor nerves to the shoulder and arm muscles arise appear in somewhat higher segments of the cervical cord than those belonging to the hand muscles. The same holds good, *mutatis mutandis*, for the lumbar cord in relation to the leg and foot. Further, the larger groups show subdivisions which may be related to particular movements, *i.e.* to particular groups of muscles. In the case of the diaphragm there is a special cell-group or cell-column on each side in the ventral horn of the cervical cord; from these cells the fibres of the phrenic nerve arise, so that in this case a cell-group is set apart for a special muscle.

The axis-cylinder processes of the ventral horn-cells mostly pass out into the corresponding ventral nerve-roots (fig. 631, *m*), but a few send their axons to the ventral column of the opposite side through the white commissure, or to the ventral or lateral column of the same side. It is noteworthy that in birds a few cells of the ventral horn send their axons into the dorsal roots. A well-marked group of large nerve-cells, best marked in the thoracic region, lies at the base of the dorsal horn (*dorsal nucleus of Stilling, Clarke's column*, fig. 630, *d*). The cells of Clarke's column send their axis-cylinder processes into the cerebellar tracts. If these tracts are cut experimentally, the cells of Clarke's column on the same side below the section undergo Nissl degeneration and eventually atrophy, but the degeneration does not affect all the cells unless both the tract of Flechsig and the tract of Gowers are severed (Ninian Bruce). There are a few small cells with short axons in Clarke's column which do not give rise to fibres of either of these long tracts.

Another group is seen on the outer side of the grey matter lying in a projection which is sometimes known as the *lateral horn* (*lateral cell-column, intermedio-lateral column*, fig. 630, *i*). This is most distinct in the thoracic region as far up as the second thoracic segment. The axons from its cells for the most part leave the cord along with the ventral roots, and probably furnish the outgoing visceral and vascular fibres (preganglionic autonomic fibres of Langley, see p. 172). Another group (*middle cell-column*) lies in the middle of the crescent (fig. 626, *e*). Cells are very numerous in the dorsal horn but are not collected into definite groups. Those of the substantia gelatinosa of Rolando send their nerve-fibre processes partly into the lateral, partly into the dorsal columns.

The cells which send their axons into the adjacent parts of the white columns but not into any special tract are sometimes termed the 'cells of the white columns.'

CONNEXION OF THE NERVE-ROOTS WITH THE SPINAL CORD.

The *ventral* (*anterior*) *roots* leave the ventral horn in a number of bundles. They take origin from cells in the ventral and lateral horns; according to

Golgi in part also from cells in the dorsal horn. The cells are surrounded by an interlacement of ramified nerve-endings derived from various sources, especially from axons of cells of the dorsal horn, from collaterals of the dorsal root-fibres (see below), and from those of the fibres of the adjacent white columns.

Whether the pyramid-fibres send any branches to end amongst the ventral horn cells is not certain; but Sherrington found a secondary degeneration of these cells in a chimpanzee from which he had removed the motor cortex cerebri of the opposite side; (see also p. 481).

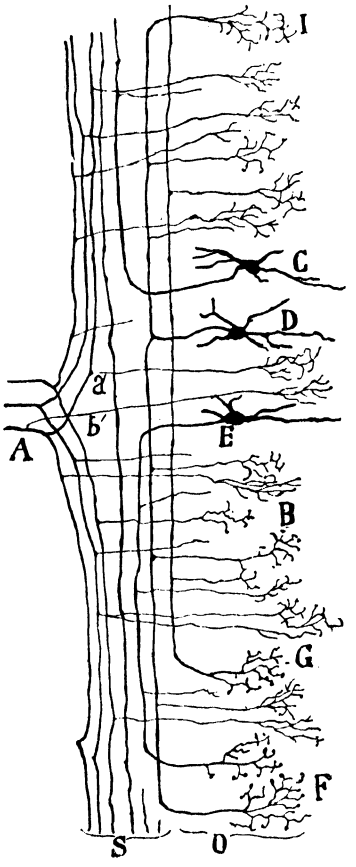

FIG. 635.—FROM LONGITUDINAL SECTION OF CORD OF CHICK EMBRYO, SHOWING ENTERING DORSAL ROOT-FIBRES AND THE PASSAGE OF COLLATERALS FROM THEM INTO THE GREY MATTER. ALSO THREE CELLS OF THE DORSAL HORN SENDING THEIR AXONS INTO THE WHITE MATTER. (R. y Cajal.)

A, entering root-fibres; S, dorsal white column; O, grey matter; C, D, E, cells of dorsal horn; B, F, G, I, arborisation of collaterals in grey matter.

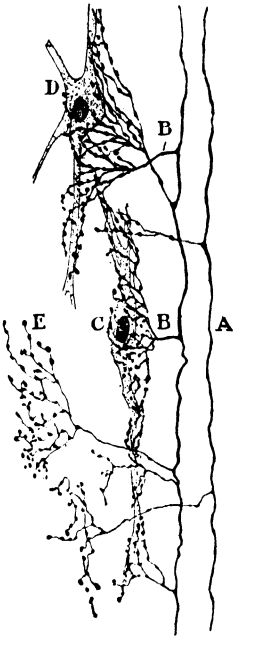

FIG. 636.—ARBORISATION OF COLLATERALS FROM THE DORSAL ROOT-FIBRES AROUND CELLS OF THE DORSAL HORN OF GREY MATTER. (R. y Cajal.)

A, fibres of dorsal column derived from dorsal root; B, collaterals; C, D, nerve-cells in grey matter surrounded by the arborisations of the collaterals; E, an arborisation shown separately.

The fibres of the *dorsal (posterior) roots* originate in the cells of the root ganglia and enter the dorso-lateral column, but the smallest fibres pass to the marginal bundle of Lissauer, and some go directly into the dorsal horn. On entering the spinal cord each fibre bifurcates (fig. 635), one branch passing

upwards, the other downwards. Both from the main fibre and from its branches collateral fibres (a, b) pass at frequent intervals into the grey matter, and end in arborisations of fibrils which envelop the cells both of the dorsal (fig. 636) and of the ventral horn (fig. 637), and, in the thoracic region, the cells of Clarke's column and those of the intermedio-lateral column. Many of

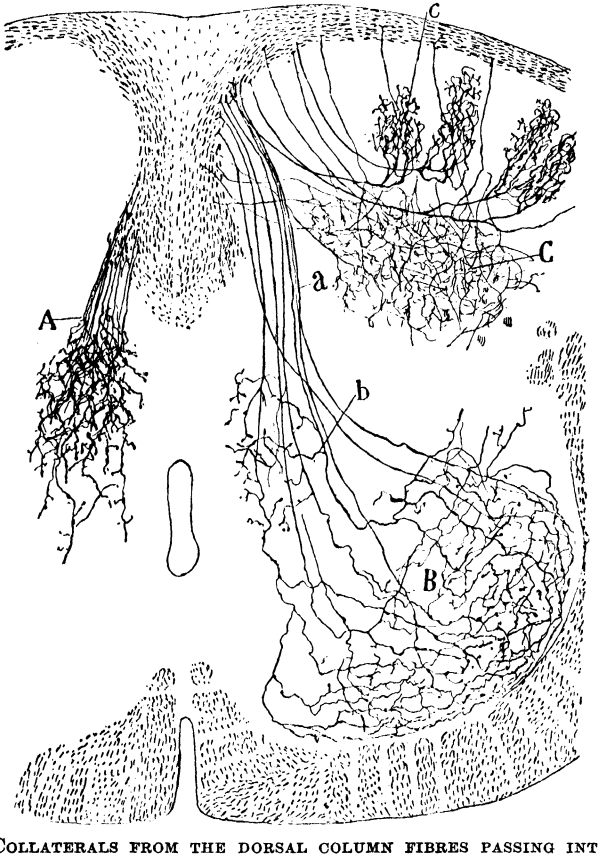

FIG. 637.—COLLATERALS FROM THE DORSAL COLUMN FIBRES PASSING INTO THE GREY MATTER: NEW-BORN MOUSE. (R. y Cajal.) Golgi method.

A, a bunch of collaterals ending amongst the cells of the middle cell-column; B, ending of collaterals, a, in the ventral horn; a few side branches of these collaterals, b, are passing to the middle cell-column; C, collaterals to dorsal horn; c, others to substance of Rolando.

the main fibres terminate in a similar manner in the grey matter, some after a short course only, others after a long course. But a considerable number of fibres pass upwards in the dorso-lateral and dorso-median columns to the medulla oblongata, where they end in terminal arborisations around the cells of the nucleus gracilis and nucleus cuneatus (fig. 631, *6*, *7*).

Kure has shown that the dorsal roots also contain numerous fine myelinate fibres originating in the grey matter of the cord and passing to the spinal ganglia where they form synapses with small cells. From these cells other fine myelinate fibres arise and pass into the mixed nerve to be distributed as autonomic (para-sympathetic) fibres.

LESSON XLI.

CENTRAL NERVOUS SYSTEM.

THE MEDULLA OBLONGATA.

SECTIONS of the medulla oblongata (made in the same way as with the spinal cord): (*a*) at the level of the decussation of the pyramids, (*b*) just above the decussation, (*c*) opposite the middle of the olivary body, and (*d*) through the uppermost part of the olivary body, or just above it.

Divisions of the brain.—The brain consists of three great morphological divisions associated with the three primary cerebral vesicles of the embryo; they are termed respectively the *hind-brain*, *mid-brain*, and *fore-brain*.

The *hind-brain* includes the parts around the fourth ventricle, viz. the medulla oblongata (myelencephalon) and the pons, consisting of a stem and of peduncles uniting it with the cerebellum (metencephalon): the medulla oblongata and pons-stem form a continuation of the spinal cord termed the 'spinal bulb.' The *mid-brain* includes the region of the corpora quadrigemina (mesencephalon). The *fore-brain* comprises the parts immediately above that region and centering around the third ventricle; its lower portion includes the thalami (thalamencephalon), its upper portion the corpora striata and cerebral hemispheres (telencephalon).

GENERAL STRUCTURE OF MEDULLA OBLONGATA.

The structure of the **medulla oblongata** can best be made out by the study of a series of sections taken from below upwards, and by tracing in these the changes which occur in the constituent parts of the spinal cord, taking note at the same time of any parts which may be superadded.

A section through the *region of the decussation of the pyramids* (fig. 638) has much the same form as a section through the upper part of the spinal cord; most of the structures of the cord can be recognised in it. A considerable alteration of the grey matter is, however, produced by the passage of the large bundles of the crossed pyramid-tract from the lateral column of the spinal cord on each side through the base of the ventral horn and across the ventral median fissure to the opposite ventral column of the medulla oblongata, where, together with the fibres of the direct pyramid-tract, which already lies in the ventral column of the cord, they constitute the prominent mass of white fibres which is seen on the ventral aspect of the medulla

oblongata, on each side of the middle line, known as the *pyramid*, from which the name of the tract is derived. By this passage of fibres through the grey matter the tip of the ventral horn is cut off from the rest and is pushed to the side; part of it appears as an isolated mass of grey matter, known as the *lateral nucleus*.

In sections a little higher, viz. *just above the decussation of the pyramids*, a wavy band of grey matter makes its appearance on the lateral aspect of each pyramid, corresponding with a prominence on the surface which is known as the *olive*. The wavy or plicated grey matter is termed the *olivary nucleus* (figs. 639, 641, 642).

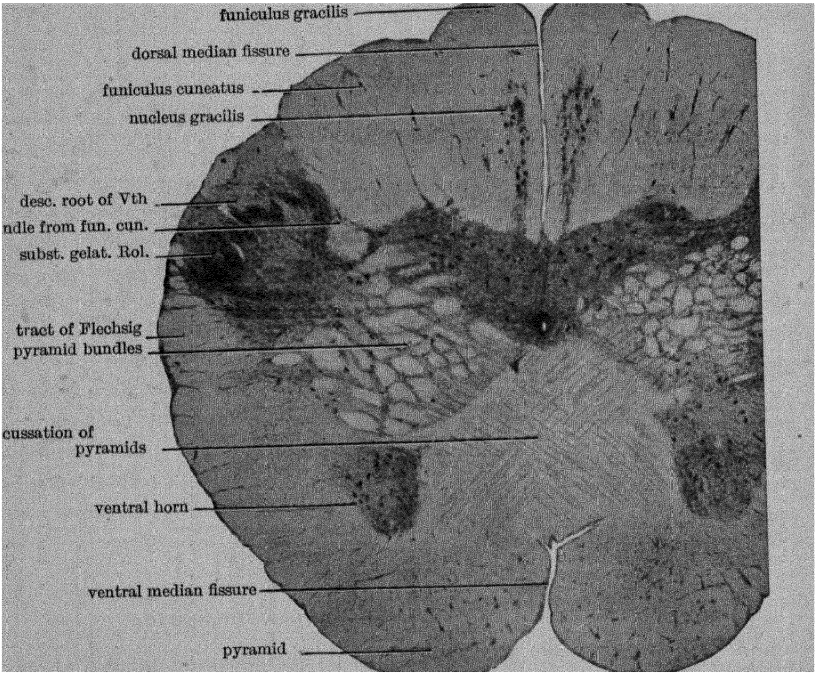

FIG. 638.—SECTION ACROSS THE LOWER PART OF THE MEDULLA OBLONGATA AT THE DECUSSATION OF THE PYRAMIDS. (E. Sharpey-Schafer.) × 6½. Photograph.

The *pyramids* of the medulla oblongata are formed of fibres which originate in the frontal region of the cerebral cortex, and can be traced from the axons of the large cells in the grey matter of that cortex. The fibres course through the white matter of the hemisphere, through the middle third or more of the internal capsule and crusta, and through the pyramid-bundles of the pons into these structures (pyramids) of the medulla oblongata. As we have just seen, they pass at the lower limit of the bulb chiefly to the opposite or crossed lateral column of the cord, but partly to the lateral column of the same side, and, in man and anthropoid apes, partly to the mesial part of the ventral white column. They collectively constitute the *tract of the pyramid*, which

is smaller in the medulla oblongata than in the pons, since many of its fibres leave the main tract whilst within the pons and pass across the middle line towards the grey matter which lies in the dorso-lateral part of the pons and medulla oblongata, especially in that portion of the grey matter with which the sensory fibres of the cranial nerves are connected. Sometimes such a bundle of fibres, after passing towards the sensory nuclei in the lateral part of the medulla oblongata, does not end in them, but again comes ventralwards and joins the main or central part of the pyramid-tract near its decussation (*bundle of Pick*).

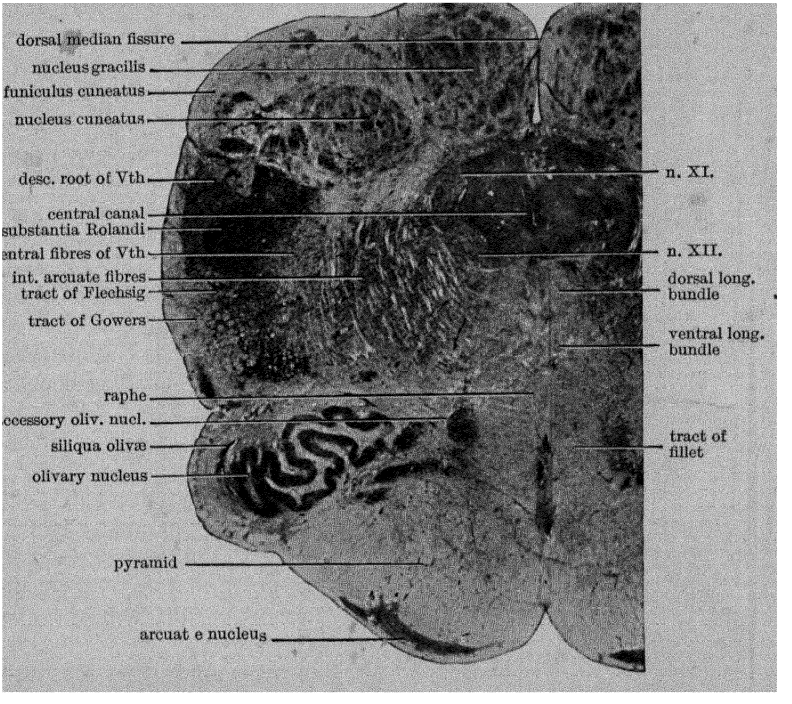

FIG. 639.—SECTION TAKEN IMMEDIATELY ABOVE THE DECUSSATION OF THE PYRAMIDS. (E. Sharpey-Schafer.) × 6½. Photograph.

It is not a little remarkable that although the fibres of the tract of the pyramid give off numerous collaterals to the grey matter of the cerebral cortex, the basal ganglia of the cerebrum, the substantia nigra of the mid-brain, the nuclei of the pons and the base of the dorsal horn of the spinal cord, no collaterals are seen to leave them in their course through the pyramids of the medulla oblongata, except a very few to the olivary nuclei. Various observers have professed to describe collaterals and terminations of the pyramid fibres as passing to the motor nuclei of the cranial nerves as well as to the motor cells in the ventral horn of the spinal cord, but statements to this effect must be received with caution, for although current in most text-books, they have not been substantiated by accurate observations. It is certain that most if not all of the fibres of the pyramid-tract end not in the ventral but in the dorsal part of the spinal grey matter.

In consequence of the increased development of the dorsal columns of white matter a change also occurs in the grey matter of the dorsal horns, which in the medulla oblongata are pushed towards the side, the V which they form with one another being thus opened out; at the same time the tip of each horn becomes enlarged and causes a prominence upon the surface of the medulla oblongata, which is known as the *tubercle of Rolando*. Below, this is continuous with the substantia Rolandi of the apex of the dorsal horn of the cord. Above, its grey matter is prolonged into the sensory nucleus of the fifth nerve. On its outer side and partly embracing it is a bundle of fibres seen in every section of the medulla oblongata, and traceable up to the pons Varolii. This is the *inferior* or *descending root of the fifth nerve*—formerly known as the 'ascending' root. Its fibres extend down as far as the upper cervical region of the spinal cord. Grey matter also soon becomes formed within the upward prolongations of the gracile funiculus (dorso-mesial column), and of the cuneate funiculus (dorso-lateral column), appearing at first as thin strands in the middle of the columns (fig. 638), but rapidly increasing in thickness (fig. 639) so as eventually to occupy almost the whole of them, forming the *nucleus gracilis* and the *nucleus cuneatus* respectively.

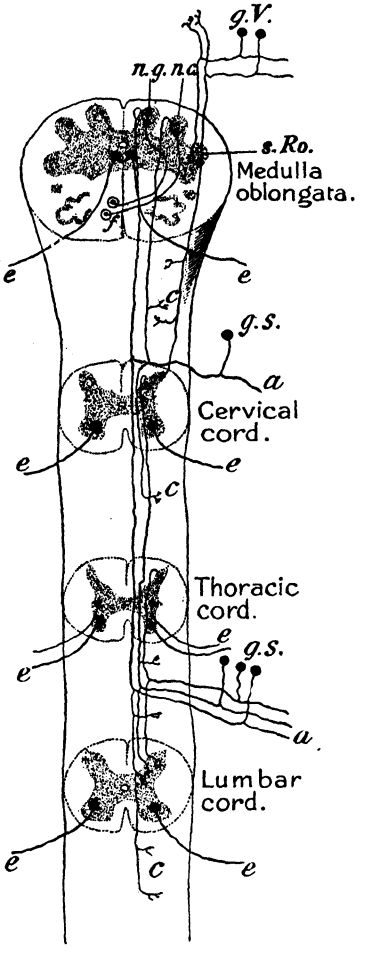

FIG. 640.—DIAGRAM TO SHOW THE COURSE OF THE DORSAL ROOT-FIBRES AFTER ENTERING THE CORD. (E. Sharpey-Schafer.)

a, afferent fibres before entering ganglion; *g.s.*, spinal ganglion-cells; *g.V.*, ganglion of fifth nerve; *c*, descending branches (forming comma tract) giving off collaterals to grey matter. The ascending branches are shown partly ending in grey matter of dorsal horn, partly in the nucleus gracilis (*n.g.*) and nucleus cuneatus (*n.c.*) of the medulla oblongata; *s.Ro.*, substantia Rolandi; *f*, fibres of fillet arising in nuclei of medulla oblongata and crossing the raphe to the opposite side; *e*, efferent nerve-fibres from motor nerve-cells.

It is in these nuclei that the fibres of Goll's and Burdach's tracts, which are continued up from the dorsal columns of the spinal cord, find their ultimate ending in complicated arborisations amongst the cells of the nuclei. These nuclei do not, however, receive all the ascending branches of the dorsal root-fibres, for a considerable number of these have already disappeared by entering the grey matter of the cord, in which they also end by arborisation amongst the cells. The cells of the nucleus gracilis and nucleus cuneatus are of small or moderate size

with long dendrons. Their axons pass as internal arcuate fibres through the reticular formation into the inter-olivary layer, cross the median raphe dorsal to the pyramids (fig. 640, *f*), and then turn upwards, constituting the *tract of the fillet*. This tract, which in its lowest part is thus formed by the nerve-fibres which belong to the second relay (second neurones) of one of the sensory spinal paths, is reinforced in the higher regions of the medulla oblongata and in the pons by fibres derived from cells of the sensory nuclei of the cranial nerves. The majority of its fibres end in the lateral nucleus of the thalamus, but some pass to both the anterior and posterior corpora

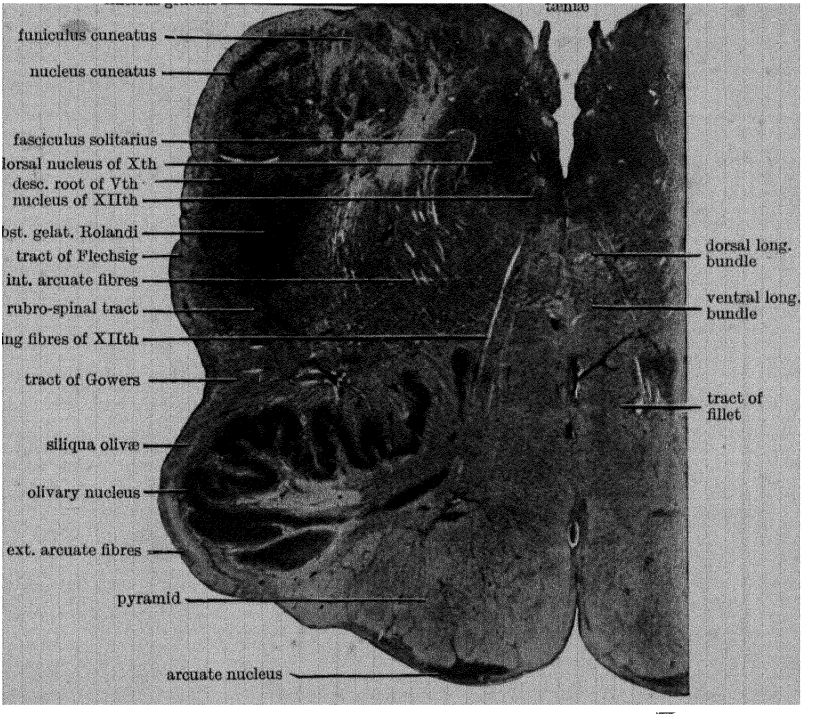

FIG. 641.—SECTION ACROSS THE MEDULLA OBLONGATA AT THE POINT OF THE CALAMUS SCRIPTORIUS OF THE FOURTH VENTRICLE. (E. Sharpey-Schafer.) × 6½. Photograph.

According to Van Gehuchten the fibres of the fillet which are derived from the nucleus cuneatus lie dorsally to those which are derived from the nucleus gracilis.

The continuation of the *central canal* of the spinal cord is still seen in the lower medulla oblongata (figs. 638, 639), but it comes nearer to the posterior surface and eventually opens out at the point of the calamus scriptorius of the fourth ventricle (fig. 641). The grey matter which surrounds it contains two well-marked groups of nerve-cells; the ventral of these is the lower part of the *nucleus of the hypoglossal* or twelfth nerve, the dorsal, with smaller cells, that of the *vago-accessory* or tenth and eleventh. But

most of the grey matter of the crescent becomes broken up, by the passage of bundles of nerve-fibres through it, into a well-marked *reticular formation*. And instead of the comparatively narrow isthmus which joins the two halves of the spinal cord, a broad *raphe* now makes its appearance; this is formed of fibres coursing obliquely and ventro-dorsally, together with some grey matter containing nerve-cells.

In a section at *about the middle of the olive* (fig. 642), it will be seen that a marked change has been produced in the form of the medulla oblongata

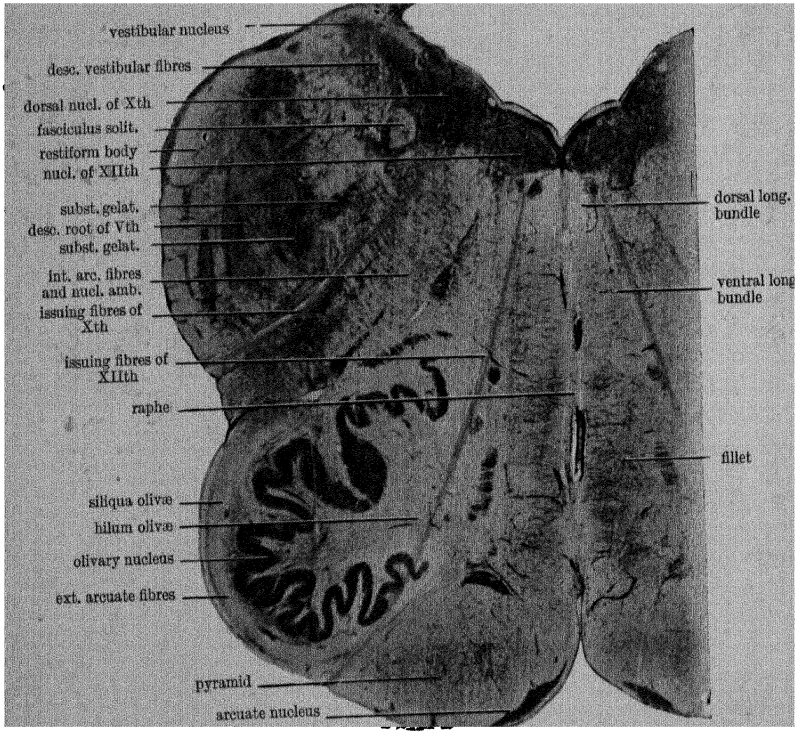

FIG. 642.—SECTION ACROSS THE MEDULLA OBLONGATA, AT ABOUT THE MIDDLE OF THE OLIVARY BODY. (E. Sharpey-Schafer.) × 6½. Photograph.

and the arrangement of its grey matter, by the opening out of the central canal into the fourth ventricle. This causes the grey matter, which lower down surrounded the central canal, to be spread out at the floor of the fourth ventricle, and the collections of nerve-cells from which the hypoglossal and vagus nerves respectively arise, now, therefore, lie in a corresponding situation near the ventricular floor. At this level the outer small-celled group which corresponds with the nucleus of the spinal accessory in the lower part of the bulb has become the *dorsal nucleus of the vagus or tenth nerve*, and yet higher up the *dorsal nucleus of the glosso-pharyngeal or ninth nerve*. The nerve-

bundles of the roots of these nerves can be seen in some of the sections (fig. 642) coursing through the thickness of the bulb and emerging, those of the hypoglossal just outside the pyramids, those of the vagus at the side of the medulla oblongata.

The dorsal part of the section is chiefly occupied by the grey matter of the floor of the fourth ventricle, and by fibres which are passing obliquely upwards and outwards towards the cerebellum, forming its inferior peduncle (*restiform body*). The grey matter forming the nucleus of the funiculus gracilis and of the funiculus cuneatus has now almost disappeared, but in place of these nuclei and near the outer part of the floor of the fourth ventricle are seen some masses of grey matter with a number of bundles of nerve-fibres among them. The grey matter is the lower part of the principal nucleus of the vestibular nerve (see p. 492), and the white bundles are formed of descending branches of the fibres of that nerve. Ventral to these is the descending root of the fifth, with its nucleus mesial to it.

The ventral part of the section is occupied by the pyramid, and dorsal to this by a reticular formation (*reticularis alba*), composed of longitudinally coursing bundles of fibres belonging to the *tract of the fillet* and to the *dorsal* and *ventral longitudinal bundles*, interlaced with internal arcuate fibres that are passing across the raphe from the nuclei of the contralateral dorsal columns into the fillet, and from the opposite olive into the restiform body.

The middle portion of the section consists for the most part of a similar reticular formation, but with more grey matter and nerve-cells (*reticularis grisea*). This is a development of the formatio reticularis of the cervical cord, and the longitudinally coursing white bundles in it are probably formed of fibres derived from cells in the upper part of the cord. The nerve-cells of the grey reticular formation in the medulla oblongata give origin to fibres which bifurcate and pass both upwards to the same formation in the pons, and downwards towards the upper part of the cord, probably serving to associate these parts. Some also are said to give origin to arcuate fibres, which either traverse the raphe, or remain on the same side and eventually enter the cerebellum through the inferior peduncle (Van Gehuchten).

Ventro-laterally is the *olive*, within which is developed a peculiar wavy lamina of grey matter containing a large number of nerve-cells; this is the *dentate nucleus of the olive*. The lamina is incomplete at its mesial aspect (*hilum olivæ*), and here a large number of fibres issue, and, passing through the raphe, course as internal arcuate fibres to the opposite restiform body, and thus to the cerebellum. Some, however, turn sharply round and course below the dentate nucleus, forming an investment and capsule to it (*siliqua olivæ*), before passing to the restiform body of the same side: the main connexion of the olivary nucleus is, however, with the cerebellar hemisphere of the opposite side. The olives receive numerous collaterals from the neighbouring white columns, including a few from the pyramids. Dorsal, or dorso-lateral to the olive, is the continuation upwards of the *ventral spino-cerebellar bundle* (tract of Gowers) of the spinal cord; the continuation of the *dorsal spino-cerebellar bundle* (tract of Flechsig), just dorsal to it, is now passing into the restiform body. Lastly a tract of fibres originating within the

thalamus passes over the lateral surface of the nucleus olivæ and ends within its grey matter (*thalamo-olivary tract, central tegmental tract* of Bechterew).

The cells of the olivary nucleus have numerous dendrons; their axons all pass towards the hilum, whence they emerge, and, for the most part, cross the raphe, pierce the opposite olivary nucleus, and pass, as already mentioned, into the restiform body (*olivo-cerebellar tract*).

Nerves arising from the medulla oblongata.—The twelfth, eleventh, tenth, ninth, and eighth nerves all take origin in the medulla oblongata, and their

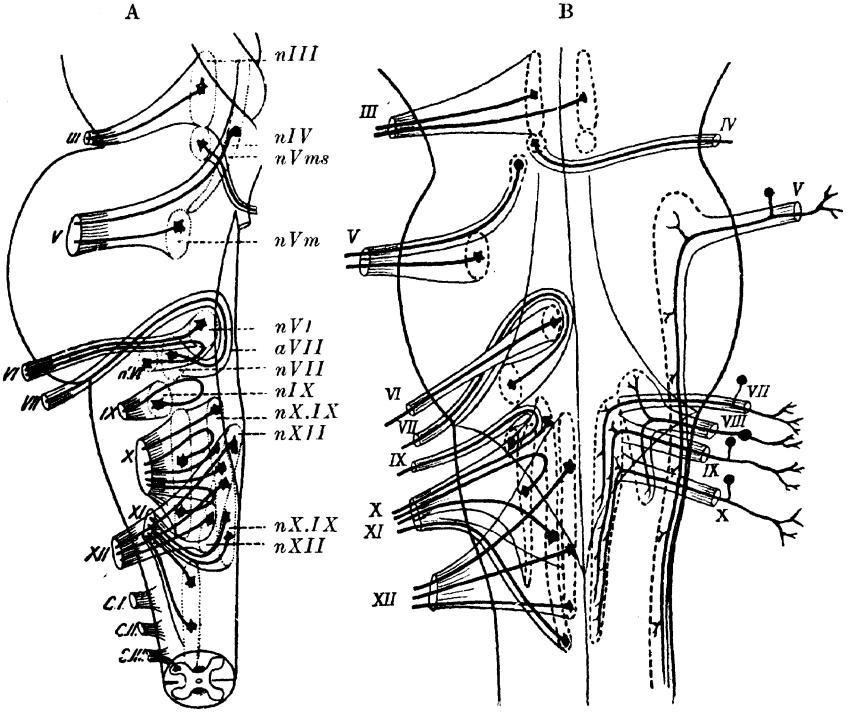

FIG. 643.—DIAGRAMS ILLUSTRATING THE ORIGIN AND RELATIONS OF THE ROOT-FIBRES OF THE CRANIAL NERVES. (E. Sharpey-Schafer.)

A, efferent fibres only; profile view.
B, shows on the left the motor nuclei and efferent fibres (except those of the fourth nerve), and on the right side the afferent fibres; view from the dorsal aspect. The parts are supposed to be transparent.

fibres may be seen emerging on each side, those of the twelfth ventrally between the pyramid and olive, and those of the other three nerves in succession from below up at the side of the medulla oblongata between the olive and restiform body.

The **twelfth** or **hypoglossal nerve** arises from a nucleus of large cells, similar to those of the ventral horn of the cord. This nucleus is situated in the lower part of the bulb ventro-lateral to the central canal (fig. 639); in the upper part near the floor of the fourth ventricle close to the middle line (figs. 641, 642). None of the fibres cross to the opposite side; according to Van Gehuchten, this is true of all the cranial nerves, except a few

fibres of the third nerve and the whole of the fourth nerve. The hypoglossal nucleus extends throughout the lower two-thirds of the bulb (fig. 643, *nXII*). It receives many collaterals from adjacent sensory tracts in the reticular formation and from the descending sensory fibres of the fifth, ninth, and tenth nerves, as well as from the dorsal longitudinal bundle. These form within the nucleus a plexus of fine fibrils which is highly characteristic. A similar plexus is seen in the oculo-motor nucleus.

Mesial to the hypoglossal nucleus, in the open part of the medulla oblongata, is the *nucleus of the fasciculus teres*, a column of moderate-sized cells which extends towards the lower margin of the pons and appears to receive fibres from the cerebellum (Edinger).

The **eleventh** or **spinal accessory nerve** begins to take origin from cells in the lateral part of the grey matter of the spinal cord as low down as the fifth cervical nerve. Its fibres from the cord (spinal fibres) are those to the (voluntary) sternomastoid and trapezius muscles. They pass from the cells of origin in the lateral part of the ventral horn (*motor nucleus*) at first dorsalwards; they then take a sharp bend outwards through the lateral column to emerge at the side of the cord and medulla oblongata. The fibres which join the vagus (bulbar fibres) take origin in a nucleus of relatively small cells lying dorso-laterally to the central canal of the medulla oblongata and behind the hypoglossal nucleus. This nucleus is continuous above with the corresponding nucleus of the vagus, and with it forms the *dorsal vago-accessory nucleus* (figs. 639, 641 to 643). Below, it extends nearly as far as the first cervical nerve; its upper part (vagal part) is in the floor of the fourth ventricle lateral to the hypoglossal nucleus, and reaches nearly as far as the lower border of the pons. Of the whole nucleus about the lower two-thirds, *i.e.* as far as the end of the calamus scriptorius, give origin to fibres of the accessory. These fibres, as already stated, join the vagus, to which they supply certain motor fibres, including those of the thyro-arytenoid muscle (Van Gehuchten). The twelfth and eleventh nerves are entirely efferent.

The **tenth** or **vagus nerve** (**pneumogastric**) contains both motor (efferent) and sensory (afferent) fibres. The efferent fibres arise (1) from the upper part of the dorsal vago-accessory nucleus just described, (2) from a nucleus of grey matter containing large cells situated in the reticular formation (figs. 642, 644, *n.amb.*). This nucleus begins near the lower limit of the bulb and extends nearly to the facial nucleus, which it resembles in general position; it is known as the *nucleus ambiguus* or *ventral nucleus of the tenth nerve*. The axons of its cells are directed at first dorsalwards and inwards and then turn sharply round in the lateral direction to join the rest of the issuing fibres of the nerve, coursing in the same manner as the spinal fibres of the accessory; indeed, this nucleus is continuous below with the column of cells from which those fibres take origin.

The sensory fibres of the vagus take origin in the *ganglion of the root* and the *ganglion of the trunk* (*jugular* and *plexiform ganglia*), from unipolar cells like those of the spinal ganglia (fig. 644, *g*). They enter the medulla oblongata, and then bifurcate, one branch, a short (ascending) one, passing

at once into an upper sensory nucleus, the other, a long one, descending. The upper sensory nucleus (*principal nucleus*), in which the short branches from the sensory root end, lies in grey matter near the floor of the ventricle, and is continuous with the grey matter which accompanies the *fasciculus solitarius* (figs. 641, 642, 644). This is formed by the descending fibres, with similar fibres of the ninth and those of the *pars intermedia* of the seventh, and is to be regarded as the *descending root of facial, vagus, and glossopharyngeal.* It is traceable to the lower limit of the medulla oblongata; the fibres end in a nucleus of grey matter lying along the mesial border of the root (*descending nucleus of facial, vagus, and glossopharyngeal*). This nucleus approaches the middle line as it descends, and in some animals terminates by joining its fellow of the opposite side over the central canal to form the *commissural nucleus* of Cajal.

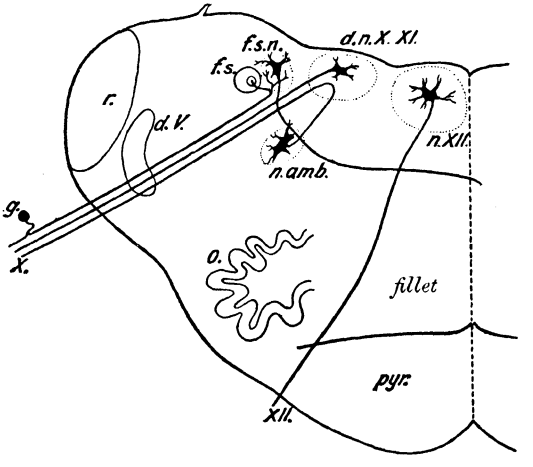

FIG. 644.—PLAN OF THE ORIGIN OF THE TWELFTH AND TENTH NERVES. (E. Sharpey-Schafer.)

pyr., pyramid; *n.XII.*, nucleus of hypoglossal; *XII.*, fibre of hypoglossal; *d.n.X.XI.*, dorsal nucleus of vagus and accessory; *n.amb.*, nucleus ambiguus; *f.s.*, fasciculus solitarius (descending root of vagus and glossopharyngeal); *f.s.n.*, its nucleus; *X.*, emerging motor fibres of vagus; *g*, cell in ganglion of vagus giving origin to a sensory fibre; *d.V.*, descending root of fifth; *r*, restiform body.

The **ninth** or **glossopharyngeal nerve** also contains both efferent and afferent fibres. The former have their cells of origin in a special nucleus (*motor nucleus of glossopharyngeal*) which occupies a position similar to that of the nucleus ambiguus, and lying near the anterior (upper) end of that nucleus, just below the nucleus of the facial. The afferent fibres of the nerve arise in the *jugular* (*upper*) and in the *petrosal ganglion* from unipolar cells like those of the spinal ganglia. Their central axons enter the medulla oblongata, and, like other sensory fibres, divide into two branches, ascending and descending. The course of these is like those of the vagus, the descending passing down in the fasciculus solitarius (extending to about one-third of its length according to A. Bruce), and ending by arborising in the grey matter accompanying it (*descending root and its nucleus*), while the ascending

branches pass nearly horizontally backwards and inwards to a nucleus (*principal nucleus*) beneath the inferior fovea of the fourth ventricle; this is

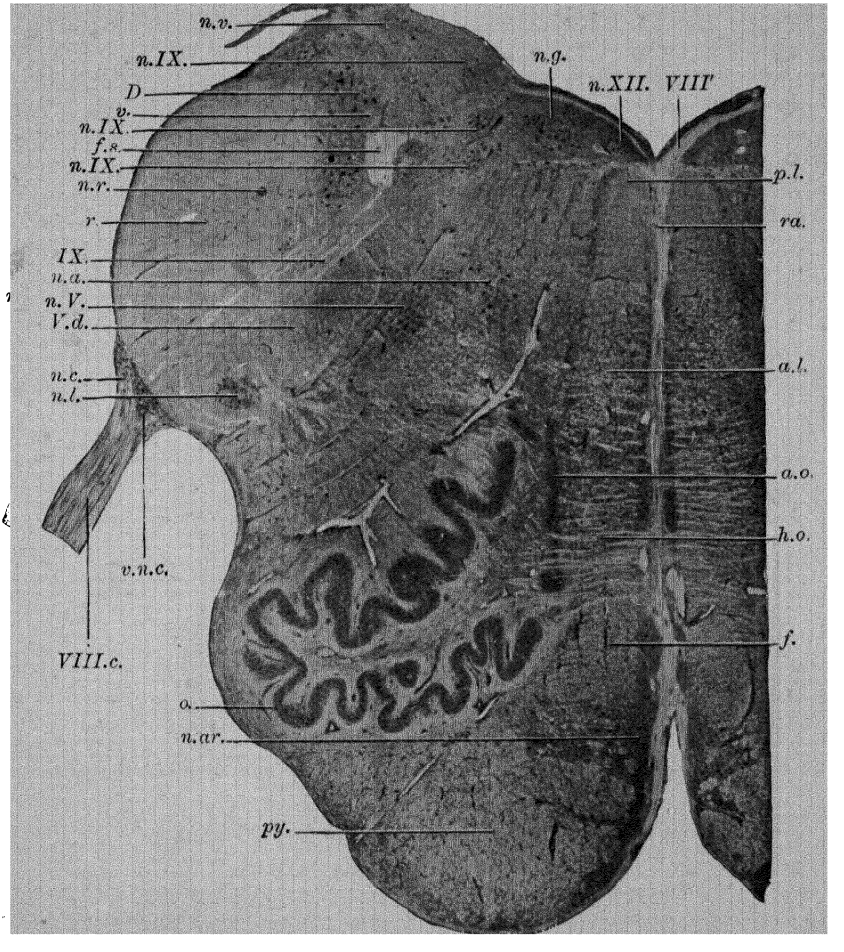

FIG. 645.—SECTION OF MEDULLA OBLONGATA AT THE LEVEL OF THE EIGHTH NERVE. (E. Sharpey-Schafer.) × about 6. Photograph.

n.v., part of vestibular nucleus; *n.IX.*, parts of nucleus of ninth nerve; *D*, nucleus of Deiters; *v*, descending fibres of vestibular nerve; *f.s.*, fasciculus solitarius; *n.r.*, small nucleus in restiform; *r*, restiform body *IX.*, fibres of ninth nerve; *n.a.*, nucleus ambiguus; *n.V.*, sensory nucleus of fifth nerve; *V.d.*, descending root of fifth; *n.c.*, part of dorsal cochlear nucleus; *VIII.c.*, cochlear division of eighth nerve; *v.n.c.*, ventral cochlear nucleus; *n.l.*, lateral nucleus; *o*, olivary nucleus; *n.ar.*, nucleus of arciform fibres; *py.*, pyramid; *n.g.*, grey matter in floor of fourth ventricle; *n.XII.*, nucleus of twelfth; *VIII'*, fibres of cochlear nerve entering raphe; *p.l.*, dorsal longitudinal bundle; *ra.*, raphe; *a.l.*, ventral longitudinal bundle; *a.o.*, accessory olivary nucleus; *h.o.*, fibres issuing from the hilum of the olive; *f*, fibres of fillet.

continuous with the upper end of the nucleus of the descending root. The arrangement of the roots is almost exactly a counterpart of that of the vagus shown in the diagram given in fig. 644.

According to Edinger the sensory nuclei of these nerves receive fibres from the cerebellum, constituting a *cerebello-bulbar tract*, which is much better marked in lower vertebrates than in man and mammals.

A section taken *through the uppermost part of the olivary prominence* will still show very much the same form and structural arrangements as that just described (fig. 645). The *nucleus of the hypoglossal* (figs. 645, 646, *n.XII*) is still visible in the grey matter of the floor of the ventricle near the middle line, but the nerve which is now seen connected with the lateral part is the *eighth* (fig. 646, *VIII*), the bundles of which, as they enter the bulb, embrace the inferior peduncle of the cerebellum (*corpus restiforme, c.r.*), which is now passing into that organ. The origin of the eighth nerve is thus subdivided

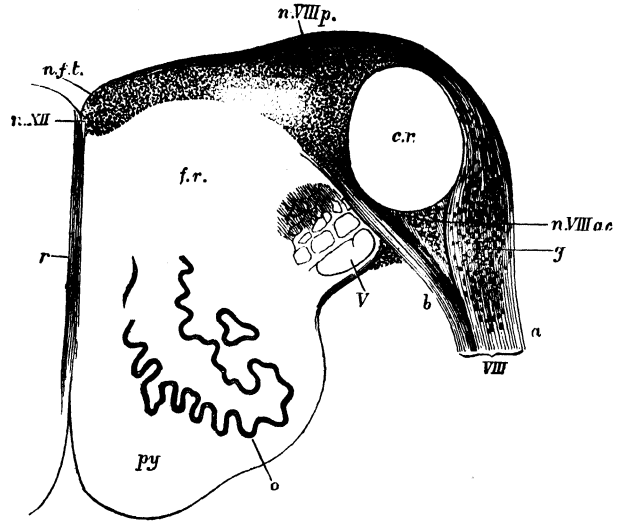

FIG. 646.—TRANSVERSE SECTION OF THE UPPER PART OF THE MEDULLA OBLONGATA. Four times the natural size. (Schwalbe.)

py, pyramid; *o*, olivary nucleus; *V*, descending root of the fifth nerve; *VIII*, root of the eighth nerve, formed of two parts, *a*, cochlear, and *b*, vestibular, which enclose the restiform body, *c.r.*; *n.VIIIp*, principal nucleus of the vestibular division; *n.VIIIac*, ventral or accessory nucleus of the cochlear division; *n.f.t.*, nucleus of the funiculus teres; *n.XII*, nucleus of the hypoglossal; *r*, raphe; *f.r.*, reticular formation.

into two principal parts, known respectively as the *dorsal* or *cochlear* and the *ventral* or *vestibular* divisions (fig. 646).

The eighth nerve.—The fibres of the cochlear division take origin in the *ganglion of the cochlea*; those of the vestibular division in the *ganglion of Scarpa*. These ganglia, which are situated at the periphery, the former within, the latter near the internal ear, are composed of bipolar cells, of which the peripheral axons end by ramifying amongst the cells of the sensory epithelium, and the central axons form the cochlear and the vestibular divisions of the eighth nerve, and pass into the medulla oblongata in the manner here described.

The fibres of the **dorsal** or **cochlear division (cochlear nerve)** bifurcate as they enter the medulla oblongata. Each fibre divides into a thick and a

thin branch. The thicker branches pass partly to a mass of ganglion-cells which is wedged in between the two roots and the restiform body, and is known as the *ventral* or *accessory auditory nucleus* (figs. 646, 647, *n.acc.*), applying themselves with a peculiar form of terminal arborisation to the cells of this nucleus, and partly over the restiform body to terminate in a prominent mass of grey matter which overlies that body, and also extends to the lateral part of the floor of the fourth ventricle at its widest part (*dorso-lateral nucleus, tuberculum acusticum*). The cells of the tubercle have a peculiar spindle shape and are set vertically to the surface. They begin to appear in the root itself, lying among the fibres of the nerve. Here they are sometimes spoken of as forming the 'ganglion of the root.' The thinner branches of the bifurcated cochlear fibres pass downwards for a certain distance and break up into a plexus of fine fibrils.

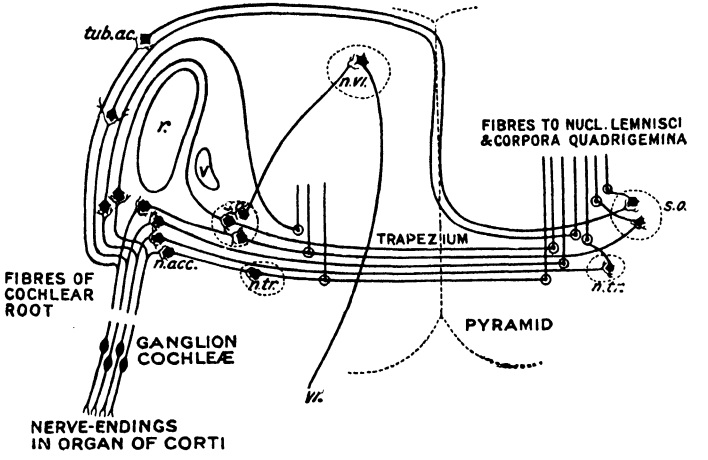

FIG. 647.—PLAN OF THE COURSE AND CONNEXIONS OF THE FIBRES FORMING THE COCHLEAR ROOT OF THE AUDITORY NERVE. (E. Sharpey-Schafer.)

r, restiform body; *V*, descending root of the fifth nerve; *tub.ac.*, tuberculum acusticum; *n.acc.*, accessory nucleus; *s.o.*, superior olive; *n.tr.*, nucleus of trapezium; *n.VI.*, nucleus of sixth nerve; *VI.*, issuing root-fibre of sixth nerve. The 'acoustic striæ' are seen at the dorsal part of the section.

These two nuclei, viz. the accessory nucleus and the acoustic tubercle, are the nuclei of ending of the cochlear fibres. From their nerve-cells new fibres arise which continue the auditory path centrally (see fig. 647). Those from the accessory nucleus enter the *trapezium*—which consists of transverse fibres running behind the pyramid-bundles of the pons Varolii—and pass in it partly to the superior olive and trapezoid nucleus of the same side of the pons, but mostly to the corresponding structures of the opposite side. Some end in those nuclei, but others merely traverse them, giving off numerous collaterals to them and other nuclei near by (see pons), and then turn upwards in the lateral part of the tract of the fillet to pass ultimately to the posterior corpora quadrigemina and mesial geniculate bodies; in tending towards these structures they form, with the fibres arising from the nuclei just mentioned, the *lateral fillet*, or *fillet of Reil*, which is conspicuous at the side of

the mid-brain. Some of the fibres from the cells of the accessory nucleus do not pass directly to the trapezium, but first curve round the restiform body (Held); these form the most dorsally situated fibres of the trapezium. Those which arise in the acoustic tubercle pass for the most part over the floor of the fourth ventricle, where they form part of a superficial strand of fibres known as the *medullary* or *acoustic striæ* (fig. 647), and entering the raphe, traverse it in a dorso-ventral direction; they then join the others from the accessory nucleus in their course to the superior olive and lateral fillet of which they constitute the deeper layer. A few fibres are directed into the fillet of the same side as their cells of origin.

Edinger states that, at least in the dog, all the fibres of the trapezium end in its nucleus or in the superior olivary nucleus, the central acoustic path being wholly continued, so far as the trapezium fibres are concerned, by fresh neurones, the cell-bodies of which lie in those nuclei, and the axons of which pass into the lateral fillet. On the other hand, from the cells in the tuberculum acusticum, the axons are said to be continued upwards in the opposite lateral fillet without the intervention of any corresponding nuclei. The lateral fillets pass above into the posterior corpora quadrigemina and mesial geniculate bodies.

The accessory nucleus also *receives* fibres through the trapezium, which end by ramifying amongst its cells. These are perhaps derived from the accessory nucleus of the opposite side. Both sets of fibres (from the accessory nucleus and tuberculum) give off collaterals near their origin, which terminate within these nuclei.

The **ventral** or **vestibular division (vestibular nerve)**, which enters a little in front of (above) the cochlear division, passes between the restiform body and the descending root of the fifth (fig. 648), to enter a mass of grey matter containing for the most part cells of small size, which is termed the *principal* or *dorsal nucleus* of the vestibular division. Here each of its fibres bifurcates with a Y-shaped division into an ascending and descending branch (fig. 648). The descending branches are collected into small bundles (*descending vestibular root*) which run downwards towards the lower part of the medulla oblongata, and gradually end by arborising around cells in the adjacent grey matter (*descending vestibular nucleus*), which is continued down from the principal nucleus. The ascending branches pass upwards on the inner side of the restiform body towards the nucleus tecti of the cerebellum. In their course they give off numerous collaterals which arborise around the large cells of two nuclei which occur in this part of the medulla oblongata and pons near the outer part of the floor of the fourth ventricle. These two nuclei are termed respectively the *nucleus of Deiters* and the *nucleus of Bechterew* (fig. 648).

Van Gehuchten states that the nucleus of Bechterew alone receives fibres from the ascending branches and that all the other nuclei (dorsal, descending, and nucleus of Deiters) are furnished with fibres from the descending branches.

The *nucleus of Deiters* is especially characterised by the large size of its cells and by the manner in which they are enveloped as by basket-work by the ramifications of the collaterals in question. From these cells fibres arise

which pass to the dorsal (posterior) longitudinal bundles of both sides: in these the fibres bifurcate (Cajal), one branch passing upwards to the oculomotor nucleus and giving off collaterals to the nucleus of the sixth nerve, and the other downwards, eventually reaching the ventral column of the spinal cord (ventro-lateral descending tract), and terminating by arborisations amongst the cells of the ventral horn (see p. 471). By means of the collateral fibres which supply the sixth and oculomotor nuclei it is probable that the conjugate movements of the two eyes are brought about, and by the fibres to the spinal cord the associated movements of the head and trunk. Fibres have also been described as passing from Deiters' nucleus to the nucleus tecti of the cerebellum. The nucleus of Deiters appears also to receive fibres

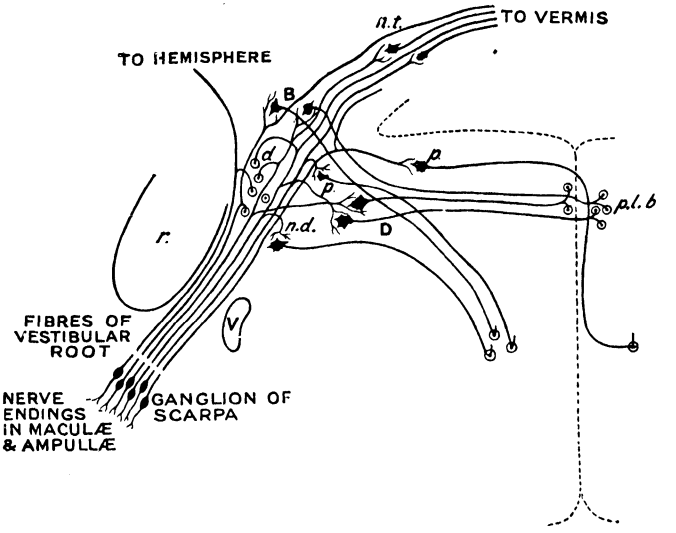

FIG. 648.—PLAN OF THE COURSE AND CONNEXIONS OF THE FIBRES FORMING THE VESTIBULAR ROOT OF THE AUDITORY NERVE. (E. Sharpey-Schafer.)

r, restiform body; *V*, descending root of fifth nerve; *p.*, cells of principal nucleus of vestibular root; *d*, fibres of descending vestibular root; *n.d.*, a cell of the descending vestibular nucleus; D, cells of nucleus of Deiters; B, cells of nucleus of Bechterew; *n.t.*, cells of nucleus tecti (fastigii) of the cerebellum; *p.l.b.*, fibres of the dorsal longitudinal bundle. No attempt has been made in this diagram to represent the actual positions of the several nuclei. Thus a large part of Deiters' nucleus lies dorsal to and in the immediate vicinity of the restiform body.

from the cerebellum and mid-brain. Owing to its connexion with the semicircular canals, the cerebellum, the oculomotor nuclei, and the nuclei in the ventral horn of the spinal cord, this nucleus must exercise important functions in connexion with co-ordination of head and eye movements and equilibration in general.

The fibres which originate in the *nucleus of Bechterew* pass into the reticular formation and become longitudinal, forming a part of the vestibulo-spinal path in the ventro-lateral column of the cord.

The **reticular formation** still occupies the greater part of each lateral half of the bulb between the grey matter at the floor of the fourth ventricle and

the pyramids, and a small portion of the *olivary nucleus* may still be seen. The descending root of the fifth nerve with its adjacent grey matter is conspicuous.

The **restiform body** is formed (1) of the fibres of the dorsal spino-cerebellar tract of the same side, which are derived below from cells of Clarke's column, and pass above into the middle lobe of the cerebellum, (2) of fibres from the opposite olivary nucleus, and (3) of fibres from the olivary nucleus of the same side. The olivary fibres pass mainly to the cerebellar hemisphere. According to some authorities the restiform body also contains fibres derived from the nucleus gracilis and nucleus cuneatus of the opposite side, as well as some from a nucleus which lies just outside the main mass of grey matter of the funiculus cuneatus, and is known as the *outer cuneate nucleus.*

Fourth ventricle.—The *floor* is covered by a layer of ciliated epithelium-cells, continuous below with those lining the central canal, and above, through the aqueduct, with the epithelium of the third and lateral ventricles. The epithelium rests upon, and its cells assist in forming, a layer of neuroglial tissue known as the *ependyma* of the ventricle. The fourth ventricle is roofed over by a layer of pia mater, with projecting choroid plexuses; the free surface being covered by an epithelial layer continuous at each side with the ciliated epithelium of the floor. The roof becomes somewhat thickened as it is continued into the ependymal layer of the floor of the ventricle; this thickened part (*tænia* or *ligula*, figs. 641, 642) is often left attached when the thin roof of the pia mater which covers the ventricle in is stripped away.

LESSONS XLII. AND XLIII.

THE PONS VAROLII, MESENCEPHALON, AND THALAMENCEPHALON.

1. SECTIONS through the lower, middle, and upper parts of the pons.

2. Sections across the region of the corpora quadrigemina, one at the level of the inferior, the other at the level of the superior, pair.

3. A section across the posterior part of the third ventricle passing through the thalami.

In all the above sections sketch under a low power the general outlines of the grey and white matter, inserting the positions of the chief groups of nerve-cells.

(The tissue is hardened and the sections are prepared, stained, and mounted in the same way as those of the spinal cord and medulla oblongata.)

PONS VAROLII.

Sections through the **lower part of the pons** (fig. 649) show much the same arrangement of grey and white matter as that met with at the upper part of the medulla oblongata, but the general appearance of the sections is much modified by the presence of a large number of transversely coursing bundles of nerve-fibres, most if not all of which are passing to the hemispheres of the cerebellum (fibres of middle peduncle of cerebellum). Some of the more ventral of these peduncular fibres often form a detached bundle which is known as the *tænia pontis*. In the interstices of the transverse bundles is a considerable amount of grey matter (*nuclei pontis*) from the cells of which the fibres of the middle peduncle of the opposite side are derived. Among the cells of the nuclei pontis many collaterals of the pyramid-tracts end, and the cortico-pontine fibres (see below) also terminate here; in this way is formed a connexion between the cerebral hemisphere of the one side and the cerebellar hemisphere of the opposite side. The continuation of the pyramids of the medulla oblongata in the pons takes the form of a number of separate bundles (fig. 649, *py.*) which run between the transverse bundles. These bundles are collectively much more bulky than the pyramids of the medulla oblongata, for, in addition to fibres of the pyramid-tract proper (*cortico-spinal*), derived from the precentral area of the cortex, they are largely composed (especially the dorso-lateral bundles) of other fibres (*cortico-pontine*) connecting the cortex with this part of the hind-brain. The pyramid-bundles are separated from the reticular formation by deeper transverse fibres, which belong to a different system from those of the middle peduncle. They form what has already been referred to as the *trapezium* (figs. 647, 649); a collection of fibres which forms part of the central auditory path; some appear to be

commissural between the auditory nuclei of the two sides. The fibres of the trapezium traverse a collection of nerve-cells lying ventral to the superior olivary nucleus, and known as the *nucleus of the trapezium* (fig. 647, *n.tr.*).

This nucleus is characterised by the peculiar chalice-like synapses which the entering axons of the larger acoustic fibres form with the cell-bodies (Held). According to Cajal these large fibres are continued directly from the root-fibres of the cochlear nerve, and are not derived from the cells of its accessory nucleus.

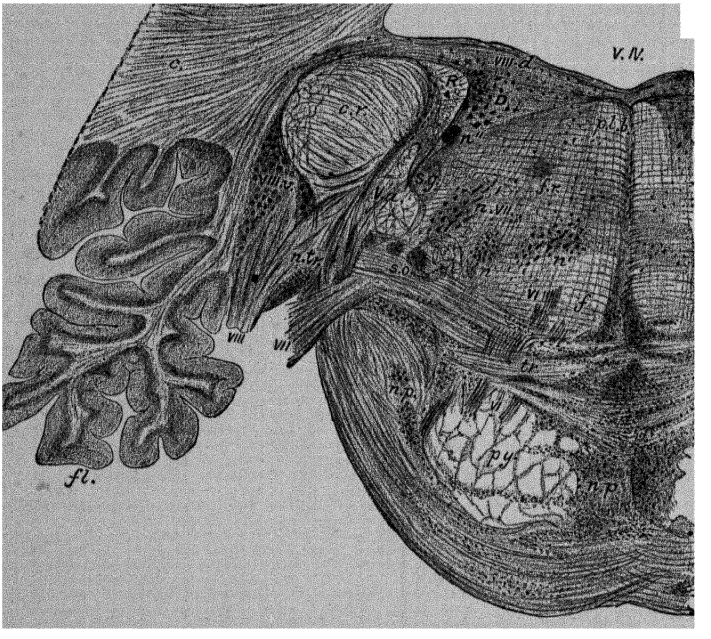

FIG. 649.—TRANSVERSE SECTION THROUGH THE LOWERMOST PART OF THE PONS. (E. Sharpey-Schafer.) × 4. Drawn from a photograph.

v.IV., fourth ventricle; *c*, white matter of cerebellar hemisphere; *c.d.*, corpus dentatum; *fl.*, flocculus; *c.r.*, corpus restiforme; *R*, bundle of Roller, composed of the descending branches of the vestibular nerve; *D*, nucleus of Deiters; *VIII.*, issuing root of auditory nerve; *VIII.d.*, principal or dorsal nucleus of the vestibular nerve; *VIII.v.*, nucleus of cochlear nerve; *tr.*, trapezium; *n.tr.*, its nucleus; *f*, fillet; *p.l.b.*, dorsal longitudinal bundle; *f.r.*, formatio reticularis; *n*, *n'*, *n''*, various nuclei within it; *V.a.*, descending root of fifth nerve; *s.g.*, substantia gelatinosa; *s.o.*, superior olive; *VII.*, issuing root of facial nerve; *n.VII.*, its nucleus; *VI.*, root-bundles of sixth nerve; *py.*, pyramid-bundles; *n.p.*, nuclei pontis.

The olivary nucleus is no longer seen, but there are one or two small collections of grey matter, more conspicuous in some animals than in man, which lie in the ventral part of the reticular formation, known as the *superior olivary nucleus*, the *pre-olivary nucleus*, and the *semilunar nucleus* (Cajal). All these nuclei, as well as the nucleus of the trapezium itself, are connected with the fibres of the trapezium which form the central auditory path; the fibres either ending in the nuclei in question or giving off to them numerous collaterals; while from the cells of the nuclei axons pass into the trapezium or into the adjacent lateral part of the fillet. On the other hand,

the superior olive is said to receive some fibres from the posterior colliculi of the corpora quadrigemina. The *nucleus of Deiters*, which begins to appear in the upper part of the medulla oblongata, where it has been already studied (p. 492), extends into the pons Varolii; here it lies near the floor of the fourth ventricle, a little mesial to the restiform body (fig. 649, *D*). The nerve-fibres connected with its cells pass towards the middle line and enter the *dorsal longitudinal bundle*. Here, as already stated, they divide, one branch passing upwards in the bundle and terminating by arborescence chiefly in the opposite oculo-motor nucleus: the other branch extending downwards in the medulla oblongata and cord. In the spinal cord they are found in the ventro-lateral descending tract: fibres from each nucleus of Deiters occur in both of these tracts (E. H. Fraser). They terminate by arborescences in the ventral horn of the spinal cord.

Nerves of the pons Varolii.—The nerves which enter or emerge from the grey matter of this region of the brain are part of the *eighth*, the *seventh*, the *sixth*, and somewhat higher up the *fifth* cranial nerve. Of these the eighth (already considered) and fifth are connected with groups of nerve-cells which occupy the grey matter opposite the external border of the floor of the ventricle; the sixth with a nucleus which is placed in the grey matter of the floor of the ventricle but nearer the middle line, and the seventh with a special nucleus which lies in the formatio reticularis.

The seventh or **facial nerve and the nerve of Wrisberg (pars intermedia).**—The motor fibres of the *seventh nerve* arise from the facial nucleus in the formatio reticularis. This nucleus is homologous with the nucleus ambiguus seen in sections of the medulla oblongata. It has been shown that the motor fibres to the stapedius arise from the mesial part of the nucleus and then in succession those to the external ear muscles, those to the mouth and face muscles, and, finally, from a group of cells situated dorsally to the rest, the motor fibres supplied to the superior branch of the facial (Marinesco, Van Gehuchten). From the nucleus of origin the fibres first pass obliquely backwards to the floor of the ventricle, then longitudinally upwards for a short distance (figs. 643, A; 650), and finally bend obliquely forwards and downwards to emerge between the transverse fibres at the side of the pons. None of the fibres of the seventh is derived from the nucleus of the sixth, as has sometimes been thought to be the case. As they curve over that nucleus the fibres of the seventh give off fine branches which cross the raphe; their destination is unknown. The nucleus of the facial receives collaterals from the adjacent sensory tracts in the formatio reticularis.

The facial is not a purely motor nerve, but has a ganglion upon it of the spinal type (*geniculate ganglion*) from which fibres arise (fig. 643, B) which pass centrally into the pars intermedia of Wrisberg. This last enters the pons between the seventh and eighth nerves, and its fibres bifurcate into ascending and descending branches like other sensory nerves; the descending branches pass into the solitary bundle and end like those of the glossopharyngeal in the upper part of its accompanying grey matter. The peripheral axons of the cells of the geniculate ganglion pass into the large superficial petrosal and chorda tympani—to which they furnish afferent,

probably gustatory, fibres. Other (efferent) fibres pass into the pars intermedia and ultimately into the chorda tympani from certain moderately large cells in the dorsal part of the facial nucleus. These are probably the secretory fibres of the chorda to the submaxillary and sublingual salivary glands.

The sixth nerve (abducens).—The fibres of the *sixth nerve* (figs. 643, 650), which are purely motor, leave the nucleus at its mesial aspect and turn forwards; passing between the pyramid bundles they emerge at the lower margin of the pons. A few fibres are derived from a small *ventral nucleus* lying near the nucleus of the facial; these run at first backwards and then turn forwards to join the others (Van Gehuchten) (fig. 650, *n'. VI.*).

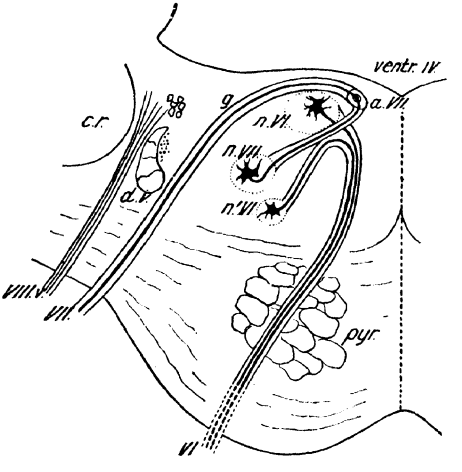

FIG. 650.—PLAN OF THE ORIGIN OF THE SIXTH AND SEVENTH NERVES. (E. Sharpey-Schafer.)

VI., sixth nerve; *VII.*, seventh nerve; *a.VII.*, ascending part of root of seventh shown cut across near the floor of the fourth ventricle; *g*, genu of seventh; *n.VI.*, chief nucleus of the sixth nerve; *n'.VI.*, accessory nucleus of sixth; *n.VII.*, nucleus of seventh; *d.V.*, descending root of fifth; *pyr.*, pyramid-bundles; *VIII.v.*, vestibular root of eighth nerve.

The **fifth** or **trigeminal nerve** emerges at the side of the pons in two roots, a smaller motor and a larger sensory (fig. 652).

The *motor root* is derived partly from fibres which arise in the upper part of the pons and lower part of the mesencephalon from large spherical unipolar nerve-cells lying at the side of the grey matter bounding the Sylvian aqueduct (*accessory* or *superior motor nucleus of fifth*, fig. 643, *nVms*; fig. 653, *m'n.V*), partly from the *motor nucleus proper* (figs. 643, *nVm*; 653, *m.n.V.*) which lies in the grey matter at the lateral edge of the fourth ventricle (figs. 651, 652). As they pass the motor nucleus proper the fibres from the superior or accessory nucleus give off into it a large number of collaterals which ramify between and around its cells.

The fibres of the *sensory root* are derived from the cells of the Gasserian ganglion which are homologous with the cells of the spinal ganglia. These fibres of the sensory root when traced into the pons are found to bifurcate, the ascending branches ending in a mass of grey matter (*principal sensory*

nucleus of the fifth, fig. 653, *p.s.n.V.*) lying just lateral to the motor nucleus, while the descending branches trend downwards into the medulla oblongata where they form the descending or spinal root of the fifth (fig. 653, *d.s.V.*); some even reach the upper part of the spinal cord. They lie immediately lateral to and in close connexion with the substantia gelatinosa Rolandi which forms the *inferior sensory nucleus* (*d.s.n.V.*); it is continued above

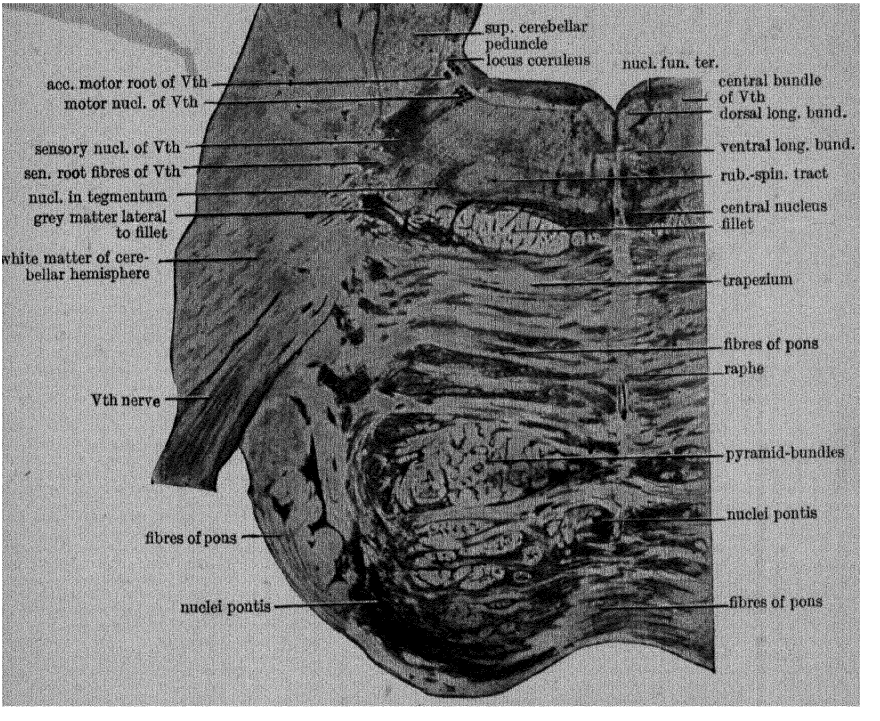

FIG. 651.—SECTION ACROSS THE MIDDLE OF THE PONS VAROLII. (E. Sharpey-Schafer.) × about 4. Photograph.

into the principal nucleus. The substantia gelatinosa which forms the sensory nucleus of the fifth contains numerous nerve-cells, both small and large; many of the small cells are grouped into nest-like clusters (*islands of Calleja*). The axons of the larger cells pass for the most part across the raphe to the formatio reticularis of the opposite side, where they reinforce the ascending fibres of the intermediate fillet, but some ascend in the fillet of the same side; others pass to a special *ascending bundle* of fibres on the opposite side of the raphe lying nearer the floor of the fourth ventricle, and in the tegmentum of the mid-brain lying lateral to the dorsal longitudinal bundle; hence it is continued upwards into the thalamus. Collaterals are given off from these ascending fibres to the adjoining grey matter, and

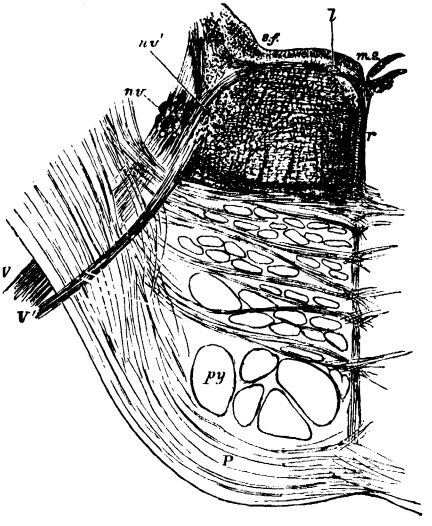

FIG. 652.—SECTION TAKEN SOMEWHAT OBLIQUELY THROUGH THE PONS FOLLOWING THE COURSE OF THE ISSUING ROOTS OF THE FIFTH NERVE. (E. Sharpey-Schafer.)

m.s., median sulcus; *l*, dorsal longitudinal bundle; *s.f.*, substantia ferruginea; *n.v*, sensory, and *n.v'*, motor nucleus of fifth; *V*, sensory, and *V'*, motor root of fifth; *r*, raphe; *py*, pyramid-bundles; *P*, transverse fibres of middle peduncle of cerebellum.

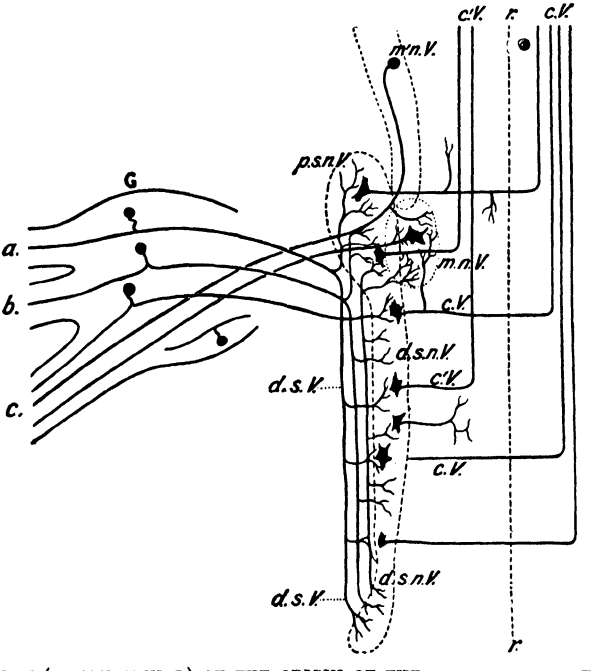

FIG. 653.—PLAN (LONGITUDINAL) OF THE ORIGIN OF THE FIBRES OF THE FIFTH NERVE.

G, Gasserian ganglion; *a*, *b*, *c*, three divisions of the nerve; *m'n.V.*, superior motor nucleus; *m.n.V.*, principal motor nucleus; *p.s.n.V.*, principal sensory nucleus; *d.s.n.V.*, descending sensory nucleus; *d.s.V.*, descending root; *c.V.*, *c'.V.*, central sensory tracts composed of fibres issuing from the sensory nuclei; *r*, plane of the raphe.

especially to the nucleus of the facial nerve. Branches also pass downwards into the formatio reticularis.

Tracts in the Pons.—1. The fibres of the *pyramid-tract* are much more numerous in the pons than in the medulla oblongata. They send numerous collaterals into the grey matter of the nuclei pontis (fig. 654, A.)

2. The *cortico-bulbar tract* lies mesial to the fillet (see p. 505). It consists

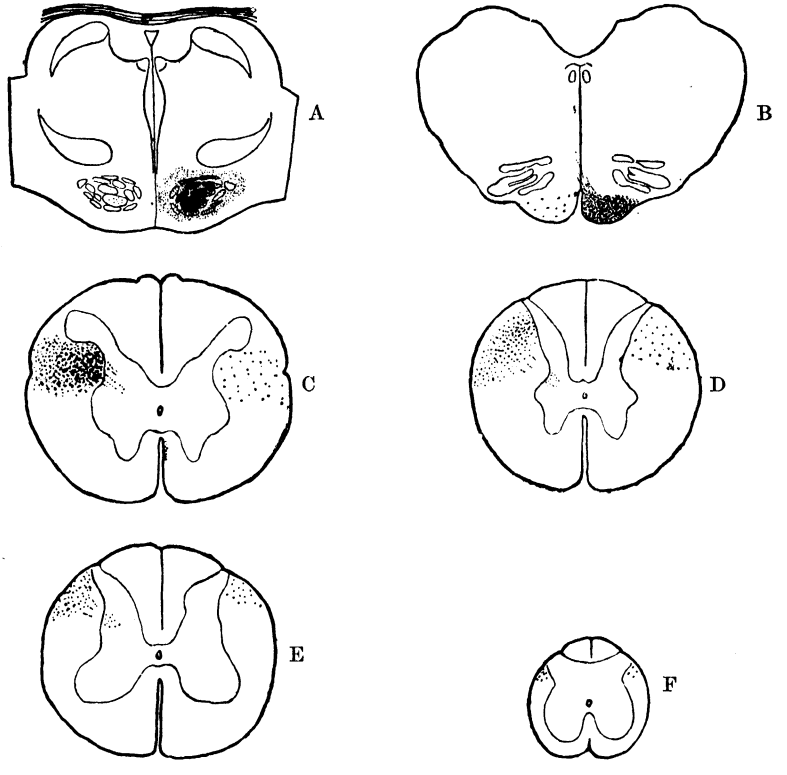

FIG. 654.—SECTION OF PONS (A), MEDULLA OBLONGATA (B), OF CERVICAL (C), THORACIC (D), LUMBAR (E), AND SACRAL (F) REGIONS OF SPINAL CORD OF MONKEY WHICH HAD SUFFERED REMOVAL OF THE PRECENTRAL GYRUS OF THE RIGHT CEREBRAL HEMISPHERE. (E. Sharpey-Schafer.)

The sections are stained by the Marchi method.

of fibres passing from the motor cortex towards the nuclei of the facial and hypoglossal. In the crusta of the mid-brain these fibres lie mesial to the ordinary pyramid-fibres, but they then leave the latter and pass into the ventral part of the tegmentum and are continued down in the formatio reticularis into the medulla oblongata.

3. The *dorsal* (*posterior*) *longitudinal bundle* forms another very distinct tract. It contains both ascending and descending fibres and runs just ventral to the grey matter of the floor of the fourth ventricle, near the middle line. As already noticed it connects Deiters' nucleus with the oculomotor nucleus,

the nucleus of the sixth, and the ventral horn-cells of the spinal cord; it probably receives some of its fibres from the axons of certain large cells of the formatio reticularis.

4. *Monakow's bundle* or *the rubro-spinal tract* has already been seen in the spinal cord (p. 471). Its fibres arise from the cells of the red nucleus of the mid-brain of the opposite side, crossing the raphe in Forel's decussation (p. 509, footnote). In the upper part of the pons it is dorsal to the mesial fillet, but lower down runs in the lateral part of the tegmentum, dorsal to the lateral fillet.

5. *The ventral longitudinal bundle* (*tecto-spinal tract*) consists of fibres which arise in the opposite superior quadrigeminal body. These cross the raphe in Meynert's decussation (p. 509), and run down ventral to the dorsal longitudinal bundle, giving off collaterals to the oculomotor nuclei and the nuclei of the fourth and sixth nerves as they descend. Its fibres eventually mix with those of the dorsal longitudinal bundle, and pass into the ventral column of the cord, joining the ventro-lateral descending tract (p. 471).

6. The *ponto-spinal lateral tract* is formed of fibres which arise from large cells of the reticular formation, and run down within the lateral area of this formation in the pons and medulla oblongata to reach the part of the lateral column of the cord which lies between the grey matter and the tracts of Monakow and Gowers. It is, however, mixed here with many fibres of different origin. The destination of its fibres is similar to those of the dorsal and ventral longitudinal bundles, viz.: the adjacent grey matter of the ventral horn.

7. The *vestibulo-spinal tract* is composed of fibres derived from the cells of the nuclei of Deiters and Bechterew, and is therefore similar in its origin to the fibres of the dorsal longitudinal bundle. The destination is in part also similar, for the fibres pass below into the ventral root zone of the cord and end in the grey matter of the ventral horn; but in their course downwards they lie in the lateral part of the medulla oblongata mixed up with those of Monakow's tract and the ponto-spinal tract, as well as with the ascending fibres of Gowers' tract.

8. The *central tract of the tegmentum* (Bechterew) runs in the pons exactly in the middle of the reticular formation of the tegmentum, but in the medulla oblongata it lies more ventrally near the olivary nucleus, beyond which it has not been traced. The origin of its fibres is not certainly known, but appears to be the thalamus; their destination is the olivary body of the same side (see p. 486, *thalamo-olivary tract*).

9. *Tract of the fillet* (fig. 655).—In the ventral part of the reticular formation is a very well-marked tract of fibres somewhat flattened dorso-ventrally in the pons; this is the *tract of the fillet*. Its fibres are partly derived from cells in the nuclei of the opposite funiculus gracilis and funiculus cuneatus of the medulla oblongata which have crossed the raphe as internal arcuate fibres; partly from cells in the nuclei which are connected with the terminations of the sensory cranial nerves.

In the mid-brain the fillet splits up into two distinct bundles of fibres termed respectively the *lateral* or *lower* and the *intermediate* or *upper fillet*,

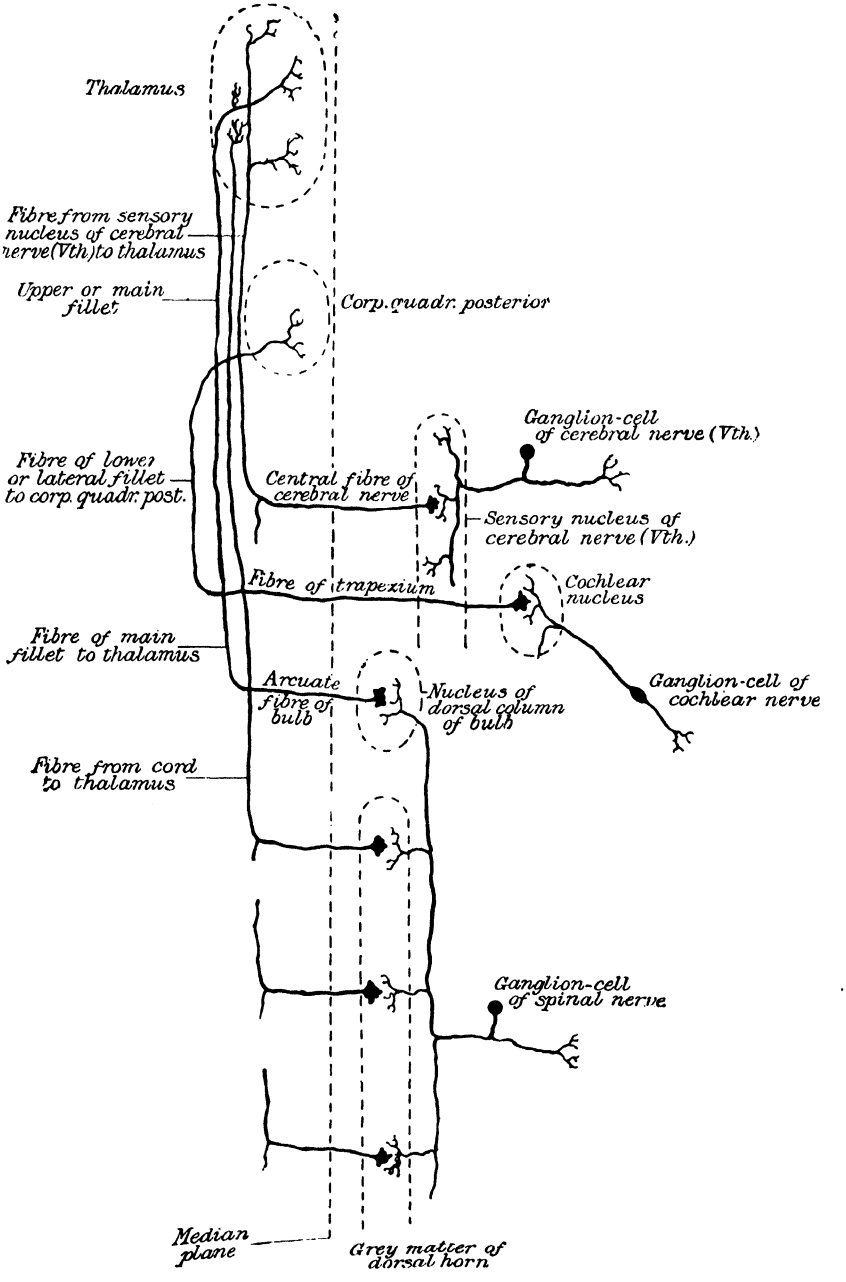

FIG. 655.—DIAGRAM OF SENSORY PATH TO MID-BRAIN AND THALAMUS. (E. Sharpey-Schafer.)

The fibres of the *lower fillet* are seen at the side of the mesencephalon (*fillet of Reil*), and are traceable partly to the grey matter of the inferior corpora quadrigemina (fig. 661), partly to the mesial geniculate body, in both of which they terminate; they are derived from the sensory nuclei of the medulla oblongata and pons (mainly from the acoustic nuclei). Those of the

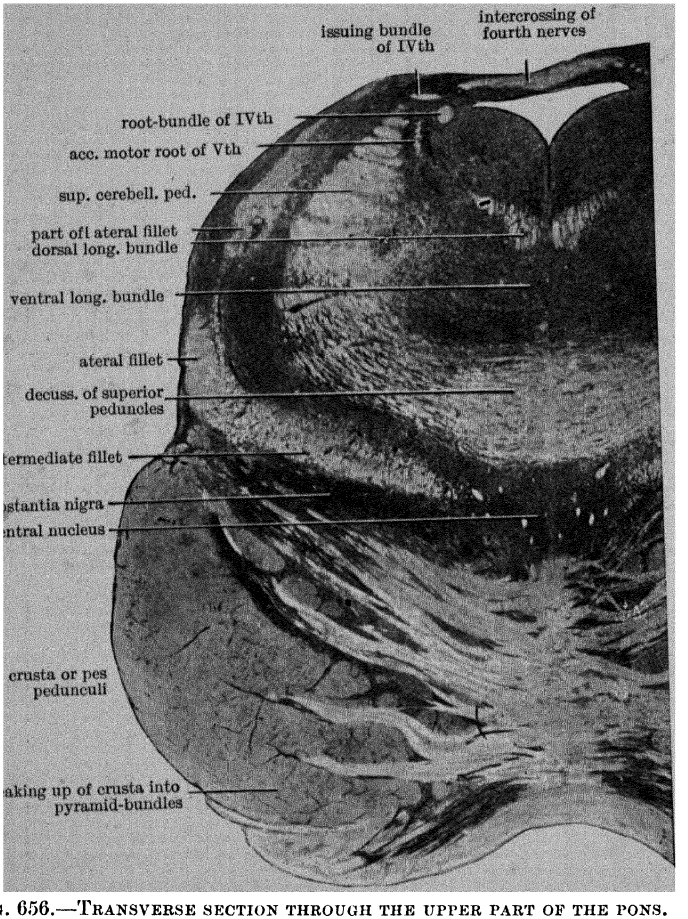

FIG. 656.—TRANSVERSE SECTION THROUGH THE UPPER PART OF THE PONS. (E. Sharpey-Schafer.) × about 3½. Photograph.

upper fillet go to the thalamus (fig. 666); they are chiefly the fibres from the cells of the opposite dorsal columns of the medulla oblongata (fig. 655).

Besides the ascending fibres of the tract of the fillet, this bundle includes a certain number of fibres which degenerate below a section of the tract and are therefore descending (centrifugal): their cells of origin appear to lie in the thalamus; these fibres are situated mesial to the true fillet of which they were formerly considered to be a part (being termed 'mesial' fillet): they form a *thalamo-bulbar tract*. Mesial to the tract just mentioned is a bundle, also consisting of descending fibres, belonging to the system of the pyramid-tract, and

containing fibres which eventually come into relation with certain of the cranial motor nuclei (Hoche). This constitutes the *cortico-bulbar tract* (see p. 501). In the crusta it lies dorso-lateral to the other pyramid-tract fibres.

10. Many of the fibres which continue the sensory path of the cranial nerves upwards lie in the formatio reticularis (tegmentum), somewhat dorsal to the tract of the fillet, forming a homologous but not clearly defined tract, which runs up through the pons and mid-brain to terminate in the subthalamic region and in the optic thalamus (*central tract of the sensory cranial nerves*). Another ascending tract is the special bundle of fibres from the sensory nucleus of the fifth to the thalamus previously referred to (p. 499).

At the **upper part of the pons** (fig. 656) the fourth ventricle narrows gradually towards the Sylvian aqueduct, and above on each side of it two considerable masses of longitudinal white fibres make their appearance. These are the *superior peduncles of the cerebellum*. They tend, as they pass forwards, gradually to approach the middle line; immediately below and in the region of the posterior colliculi of the corpora quadrigemina, they pass across this, decussating with one another, to enter the formatio reticularis of the opposite side.



FIG. 657.—THE CORPORA QUADRIGEMINA AND NEIGHBOURING PARTS OF THE BRAIN. (Edinger from G. Retzius.)

Brach. ant. cerebelli, the superior cerebellar peduncles, between them the anterior medullary velum partly covered by the lingula; *Tr.spino-cereb. ventr.*, tract of Gowers curving round the peduncle; *lemniscus*, the lateral fillet; *N.trochl.*, fourth nerve; *N.V.*, fifth nerve.

The fibres of the superior cerebellar peduncles take origin in the cerebellum, emerging from its dentate nucleus, from the cells of which they are derived. They cross the raphe in the mid-brain and terminate in the red nucleus of the (opposite) tegmentum; but some of them give off a descending branch within the peduncle after crossing: its destination is not known.

The *ventro-lateral ascending tract* of the spinal cord (p. 472) is continued up in the lateral column of the medulla oblongata dorso-lateral to the olive and through the ventral part of the pons Varolii lateral to the pyramid-bundles, but at about the level of the exit of the fifth nerve many of its fibres begin to pass obliquely towards the dorso-lateral part of the pons where the superior cerebellar peduncle is emerging from the cerebellar hemisphere. The tract in question (*ventral spino-cerebellar tract*) now curves over the lateral aspect of this peduncle (fig. 657, *Tr. spino-cereb. ventr.*), and

then takes a sharp backward turn, passing over the dorsal aspect of the peduncle to enter the middle lobe of the cerebellum in the superior medullary velum.

THE MID-BRAIN OR MESENCEPHALON.

In sections across the mesencephalon (figs. 659, 660, 662) the upward continuity of the parts which have already been described in the lower nerve-centres can still in great measure be traced.

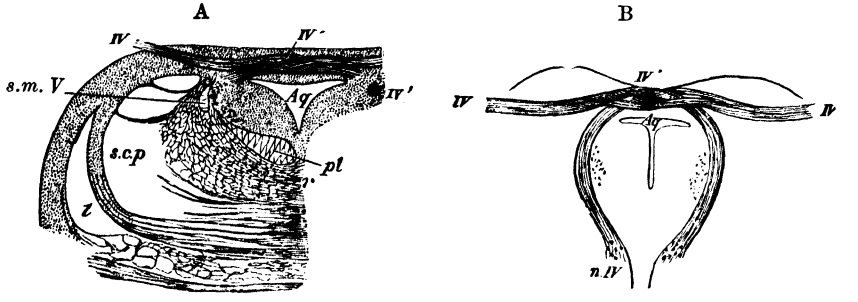

FIG. 658.—SECTION THROUGH THE ORIGIN OF THE FOURTH NERVE. (Schwalbe.)

A, transverse section at the place of emergence of the nerve-fibres. B, oblique section carried along the course of the bundles from the nucleus of origin to the place of emergence. *Aq*, Sylvian aqueduct, with its surrounding grey matter; *IV.*, the nerve-bundles emerging; *IV'*, decussation of the nerves of the two sides; *IV'*, a bundle passing by the side of the aqueduct to emerge a little lower down; *n.IV*, nucleus of the fourth nerve; *l*, lateral fillet; *s.c.p.*, superior cerebellar peduncle; *s.m.V.*, superior motor root of the fifth nerve; *pl.*, dorsal longitudinal bundle; *r*, raphe.

The **Sylvian aqueduct** (fig. 660, *Sy*), with its lining of ciliated epithelium, represents the central canal of the cord and the fourth ventricle of the medulla oblongata. In the grey matter which surrounds it (*central grey*

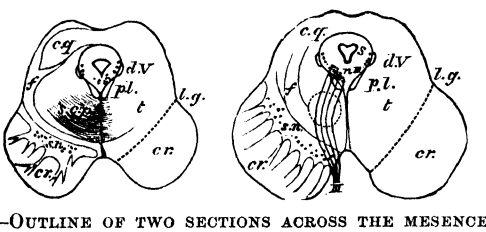

FIG. 659.—OUTLINE OF TWO SECTIONS ACROSS THE MESENCEPHALON. (E. Sharpey-Schafer.) Natural size.

A, through the middle of the inferior corpora quadrigemina. B, through the region of the superior corpora quadrigemina. *cr.*, crusta; *s.n.*, substantial nigra; *t*, tegmentum; *s*, Sylvian aqueduct, with its surrounding grey matter; *c.q.*, grey matter of the corpora quadrigemina; *l.g.*, lateral groove; *p.l.*, dorsal longitudinal bundle; *d.V*, superior root of the fifth nerve; *s.c.p.*, superior cerebellar peduncle; *f*, lateral fillet; *III*, third nerve; *n.III*, its nucleus. The dotted circle in B indicates the situation of the tegmental or red nucleus.

matter) there is seen in all sections of the region a group (column) of large nerve-cells (*oculomotor nucleus*) lying ventrally on each side of the middle line, close to the reticular formation. From the lowest cells of this column the root-bundles of the fourth nerve arise at the lower part of the mesencephalon and pass obliquely backwards and downwards around the central

grey matter, decussating with those of the opposite side to emerge just above the pons Varolii (figs. 656, 658). Higher up, in the region of the anterior colliculi, the bundles of the third nerve spring from a continuation of the same nucleus (fig. 662, *n.III.*), and these pass forwards and downwards with a curved course through the reticular formation, to emerge at the mesial

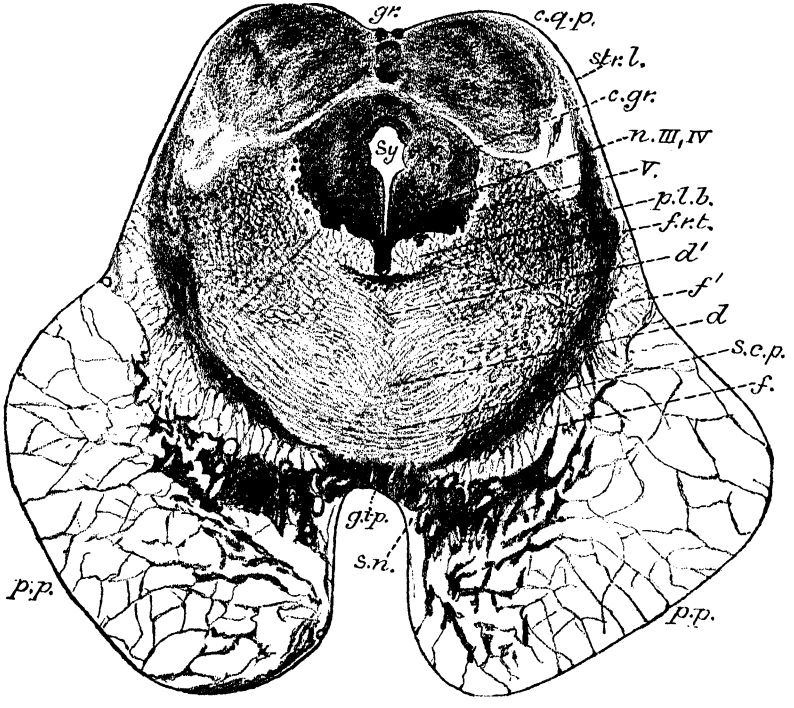

FIG. 660.—SECTION ACROSS THE MID-BRAIN THROUGH THE POSTERIOR PAIR OF CORPORA QUADRIGEMINA. (E. Sharpey-Schafer.) × about 3½. Drawn from a photograph.

Sy, aqueduct of Sylvius; *c.gr.*, central grey matter of the aqueduct; *n.III*, *IV*, group of cells forming part of the conjoined nucleus of the third and fourth nerves; *c.p.q.*, one of the posterior corpora quadrigemina; *gr.*, median groove separating it from that of the opposite side; *str.l.*, stratum lemnisci (layer of the fillet), forming its superficial layer; *f*, upper fillet; *f'*, lateral fillet; *V*, accessory motor root of fifth nerve; *p.l.b.*, dorsal longitudinal bundle; *f.r.t.*, formatio reticularis tegmenti; *d*, *d'*, decussating fibres of tegmenta (fountain-decussations of Forel and Meynert); *s.c.p.*, superior cerebellar peduncles, decussating; *p.p.*, pes pedunculi (crusta); *s.n.*, substantia nigra; *g.i-p.*, interpeduncular ganglion.

side of the crusta. According to Van Gehuchten, some of the fibres of the third nerve cross the middle line and emerge with the nerve of the opposite side.

The reticular formation of the pons is continued up into the mesencephalon and is here known as the **tegmentum.** It is composed as before of longitudinal and transverse or arcuate bundles of fibres with much grey matter intermingled. The transverse fibres include the decussating fibres of the *superior peduncles of the cerebellum* (fig. 659, A, *s.c.p.*), which are derived from cells in the dentate nucleus of the cerebellum, and on reaching the

opposite side bifurcate. Their ascending branches become gradually lost among a number of nerve-cells which collectively constitute what is known as the *red nucleus* or *nucleus of the tegmentum*, whilst the descending branches turn downwards in the reticular formation (see p. 505). But some of the fibres of the superior peduncle go on past the red nucleus to the ventral part of the thalamus. The red nucleus also receives fibres in its lateral aspect derived from the lenticular nucleus of the corpus striatum, and some which are said to come from the cerebral cortex; these fibres form a sort of capsule to the red nucleus before entering it.

Tracts in the tegmentum.—1. *Vestibulo-motor tract; dorsal (posterior) longitudinal bundle.*—This is well marked in the mid-brain, and gives off many collaterals and terminal fibres to the oculomotor nucleus which is immediately dorsal to it. The bundle largely consists of nerve-fibres derived from the cells of Deiters' nucleus (see p. 492), which on reaching the situation of the bundle either on the same or on the opposite side, bifurcate, one branch ascending, the other descending. But it receives fibres from other sources than Deiters' nucleus, *e.g.* from large cells of the sensory nucleus of the fifth, and from large cells in the reticular formation of the medulla oblongata, pons, and mid-brain. All these fibres, like those from Deiters' nucleus, bifurcate on joining the bundle, one branch passing upwards, the other downwards. Some fibres of the bundle are of different origin from the rest, arising beyond the oculomotor nucleus. These are very fine; they are descending fibres, and are traceable from the cells of the *nucleus of the dorsal longitudinal bundle*, which lies in front of the Sylvian aqueduct in the grey matter at the side of the third ventricle. Some of the fibres of the dorsal longitudinal bundle are traceable as far up as the thalamus.

The bundle gives collaterals not only to the oculomotor nucleus (fig. 661, *j*) but also to the nucleus of the sixth, and probably to the nuclei of other cranial motor nerves. Its descending fibres are eventually continued down the spinal cord in the ventro-lateral descending tract, and give off terminals and collaterals to the ventral horn.

2. *Rubro-spinal tract; Monakow's bundle.*—The cells of the red nucleus send their axons downwards and forwards. They form Monakow's bundle or the *rubro-spinal tract* which is continued below into the spinal cord.

3. *Tecto-spinal tract; ventral longitudinal bundle.*—Other longitudinal fibres of the tegmentum are those of the *fasciculus retroflexus* of Meynert lying mesially to the red nucleus and passing obliquely downwards and inwards from the ganglion of the habenula to the interpeduncular ganglion of the opposite side, and the *bundle of Münzer*, which passes from the posterior tubercle downwards into the lateral part of the reticular formation of the pons. But the longest and most important is the *ventral longitudinal bundle*, which passes lateral to the red nucleus and partly through it. Although the red nucleus receives many collaterals from this bundle, the fibres of the bundle are derived, according to Held and Cajal, from cells in the grey matter of the opposite anterior tubercle of the corpora quadrigemina; these cells send their axons sweeping round the central grey matter just central to the dorsal longitudinal bundle to cross in the raphe, where they form the

fountain-like decussation of Meynert (fig. 660, *d'*).[1] The downward continuation of the tecto-spinal tract has already been studied, but it should be stated that the prolongation of its fibres into the ventral column of the spinal cord is denied by Van Gehuchten, who traces them only as far as the medulla oblongata.

4. *Tract of the fillet.*—The continuation upwards of the fillet is also apparent in this part of the brain. Some of its fibres are seen passing in an oblique manner to the side of the mesencephalon, to enter the grey matter of the prominences of the posterior corpora quadrigemina.

This part is the *lower* or *lateral fillet* (see p. 504), formed chiefly by fibres derived from the accessory auditory, the inferior olivary, and the trapezoid nuclei of the opposite side, forming the *central acoustic tract.* Its fibres send numerous collaterals to the posterior tubercle (fig. 661) and a few to the anterior, and end by ramifying among the cells of the mesial geniculate body (Cajal). In its course it traverses the *nucleus of the fillet.* This consists of cells interpolated among its fibres (the greater number in the lower part near the superior olive); among the cells some of the fibres and many collaterals from them end. The axons of the cells trend inwards towards the raphe. The *upper fillet* is continued upwards in the ventral part of the tegmentum towards the thalamus (p. 504).

Lateral and ventral to the tegmentum is seen on either side the white mass known as the **crusta** or **pes pedunculi** (fig. 659, *cr.*; figs. 660 and 662, *p.p.*). This is formed by longitudinally coursing bundles of fibres lying on the ventral aspect of each half of the mesencephalon, and diverging above into the internal capsule of the cerebral hemisphere.

The fibres of the crusta are continued below into the so-called 'pyramid-bundles' of the pons—which contain, as we have seen, many other fibres than those of the pyramid-tract. This is also the case with the bundles of the crusta; in which the pyramid-tract proper—composed of fibres emanating from the precentral and paracentral gyri—is confined to the middle three-fifths (this, however, includes many cortico-pontine fibres), whilst the mesial fifth is mainly occupied by fibres passing from the lower frontal region to the pons, carrying impulses to the nuclei of the facial and hypoglossal; and the lateral fifth by fibres the origin and function of which are not certainly known. But it is probable that these last fibres are connected with the regions of the hemisphere behind the Rolandic fissure, especially, perhaps, with the temporal and occipital regions; and are passing from cells of those parts to end in the nuclei of the pons.

Substantia nigra.—The crusta is separated from the tegmentum by a layer of grey matter containing a number of very deeply pigmented nerve-cells (*substantia nigra*; figs. 660, *s.n.*, 662). The substantia nigra receives many collaterals from the adjacent pyramid bundles of the crusta (Sutherland Simpson). The crusta and tegmentum, together with the intervening substantia nigra, constitute the *cerebral peduncle* or *crus cerebri.*

[1] This is not to be confounded with the *fountain-like decussation of Forel* (fig. 660, *d*), which lies nearer the ventral part of the tegmentum, and is partly formed by the intercrossing of Monakow's bundle and partly by v. Gudden's bundle coming from the corpora mammillaria to end in the tegmentum.

Interpeduncular ganglion.—Between the cerebral peduncles, just where they diverge from the mass of transverse fibres of the pons, is seen close to the ventral surface of the brain a small mass of grey matter containing a large number of small nerve-cells with large and irregular dendrons, and axons which are directed dorsally into the tegmentum. This is the *interpeduncular ganglion* (fig. 660, *g.i-p.*). It receives on each side the ending of the *fasciculus retroflexus* of Meynert, coming from the *ganglion of the habenula*, a collection of nerve-cells near the superior and mesial part of the thalamus, close to the commencement of the third ventricle. Both these ganglia are much better marked in many of the lower animals than in man.

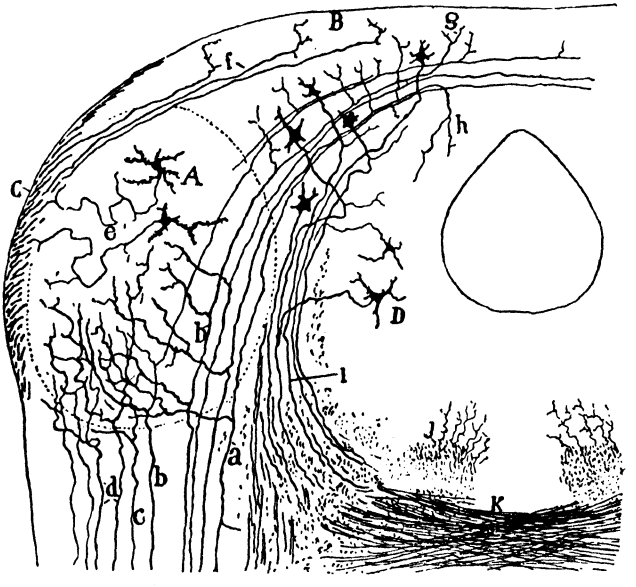

FIG. 661.—DIAGRAM SHOWING THE GENERAL STRUCTURE OF THE POSTERIOR CORPORA QUADRIGEMINA. (Cajal.)

A, principal mass of grey matter; B, C, cortical layer; D, grey matter around Sylvian aqueduct; K, decussation of superior peduncles of cerebellum; a,b, c, d, fibres of central acoustic path from lateral fillet; e, axons from cells of principal nucleus passing towards brachium; f, fibres from brachium passing into superficial layer; g, fibres from fillet passing into superficial layer; h, a fibre of fillet passing to central grey matter of aqueduct; j, collaterals from dorsal longitudinal bundle passing to oculomotor nucleus; l, axons of cells in superomesial part of colliculus curving round grey matter of aqueduct and forming the deep white layer.

CORPORA QUADRIGEMINA.

The prominences (*colliculi* or *tubercles*) of the corpora quadrigemina are formed mainly of grey matter. Connected laterally with each are bundles of white fibres forming the *brachia* of the geniculate bodies.

The **posterior (inferior) colliculi** consist of a *grey centre* enclosed by *superficial* and *deep white layers* (figs. 660, 661). The superficial white layer is derived mainly from the brachium. The fibres of the fillet divide as they approach the colliculus; one branch enters its grey matter while the other passes to the mesial geniculate body. In animals with a highly developed

sense of hearing all these parts are proportionately well-developed. The deep white layer is derived from cells of the grey centre, but many of the cells of the latter send their axons towards the superficial layer. The destination of the fibres of the deep white layer is not certainly known; some pass over the central grey matter of the aqueduct to the opposite side.

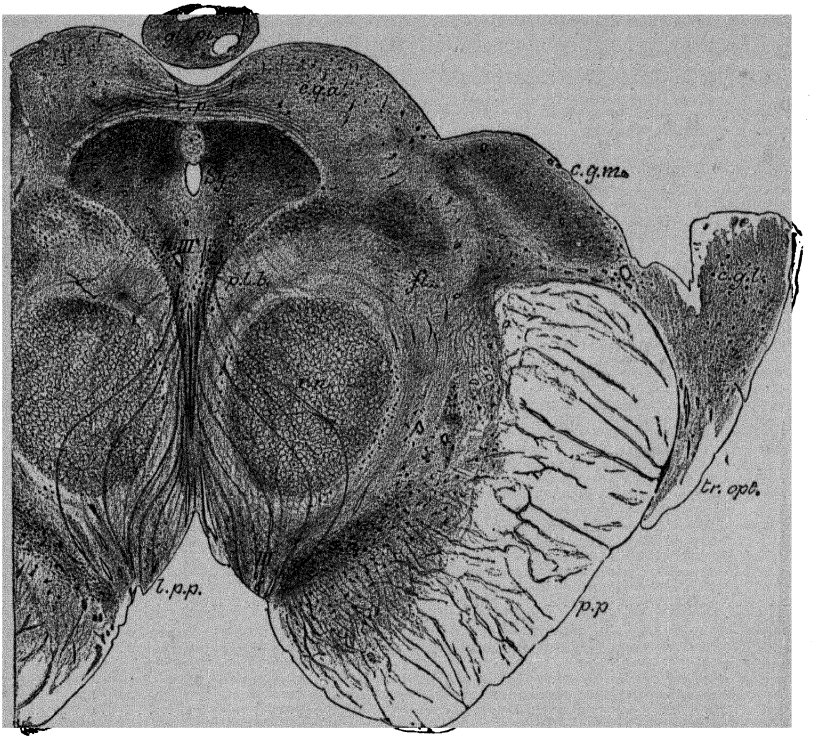

FIG. 662.—SECTION ACROSS THE MID-BRAIN THROUGH THE ANTERIOR CORPORA QUADRIGEMINA. (E. Sharpey-Schafer.) × about 3½. Drawn from a photograph.

c.p., posterior commissure of brain; *gl.pi.*, pineal gland; *c.g.a.*, grey matter of one of the anterior corpora quadrigemina; *c.g.m.*, mesial geniculate body; *c.g.l.*, lateral geniculate body; *tr.opt.*, optic tract; *p.p.*, crusta or pes pedunculi; *p.l.b.*, dorsal longitudinal bundle; *fi*, upper fillet; *r.n.*, red nucleus; *III*, issuing fibres of third nerve; *n.III*, its nucleus; *l.p.p.*, locus perforatus posticus; *Sy.*, Sylvian aqueduct.

In the **anterior (superior) colliculi** four layers can be distinguished (fig. 663), viz.: superficially, a *thin white layer* (A), containing nerve-fibres and a few nerve-cells disposed parallel to the surface; next to this a *grey cap* (B), containing many and various nerve-cells among which the terminations of the optic nerve (*h*, *h*) ramify; below this the *optic nerve layer* (C), which is formed of antero-posteriorly running fibres derived from the optic tract, and ending as just stated for the most part in the grey layer. The optic nerve layer also contains some nerve-cells. Lastly there is a deep white layer, the so-called *deep medulla*, of transversely disposed fibres (D) derived partly from the fillet but comprising many fibres which come from the cells of the colliculus itself,

and a few which are continued up from the ventro-lateral column of the spinal cord. This deep layer also contains a number of large dendritic cells among the fibres. The superior corpora quadrigemina receive through their brachia many of the fibres of the optic tracts, which in mammals enter the grey matter at the middle of its thickness and traverse it from before back, so that in transverse sections of the mid-brain they appear cut across. In birds they form a superficial white stratum covering the grey matter; this white stratum is not homologous with the superficial stratum of mammals, for the fibres in the latter are not derived directly from the optic tract. The

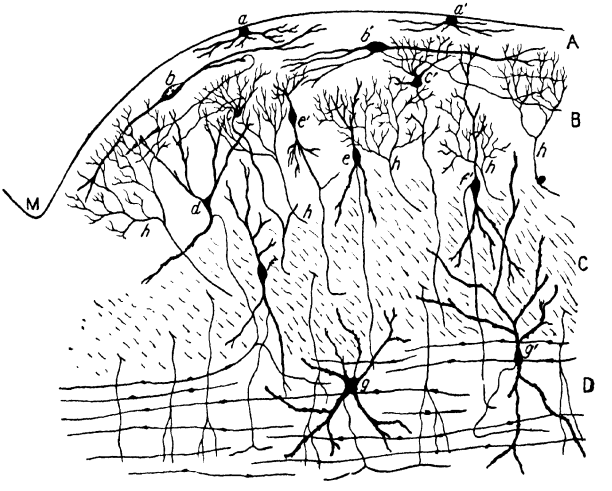

FIG. 663.—DIAGRAM SHOWING THE CHARACTERS OF THE CELLS IN THE GREY MATTER OF THE ANTERIOR CORPORA QUADRIGEMINA. (After Cajal.)

M, portion of dorsal median groove; A, superficial white layer; B, grey cap; C, optic fibre layer (upper grey-white layer); D, layer of the fillet (lower grey-white layer).

a, *a'*, marginal nerve-cells; their axons are not represented; *b*, *b'*, horizontal spindle-shaped cells of Golgi's type II.; *c*, *c'*, small cells with much branched dendrons and an axon extending to the optic fibre layer; *d*, *e*, *e'*, spindle and stellate cells of the grey cap, and *f*, *f'*, cells of the stratum opticum, sending their axons into the layer of the fillet; *g*, *g'*, cells of the layer of the fillet; *h*, *h*, fibres of the optic nerve layer ending in the grey and superficial white layers.

optic fibres are all derived from nerve-cells in the retina, and as they traverse the stratum opticum they pass obliquely into the grey matter (in a ventral direction in birds, in a dorsal direction in mammals) and end in arborisations among its cells. The cells of the grey matter are very various in form and size (fig. 663). Most of their axis-cylinder processes pass ventralwards. The destination of all is not certainly known, but some form the commencement of the ventral longitudinal bundle of the opposite side, and others run down on the same side towards the pons Varolii, intermingled with the ascending fibres of the fillet. A certain number of fibres which take origin in the cells of the anterior colliculi course over the central grey matter which surrounds the Sylvian aqueduct and sweep round this towards the fillet tract of the opposite side. These *commissural fibres* are continuous in front with those of the posterior commissure.

The nerve-fibres of the optic nerve and optic tract do not all enter the corpora quadrigemina. Many, indeed the majority, pass into the lateral geniculate bodies and optic thalami to form arborisations there (fig. 668). On the other hand, axons from the cells of these structures pass to the cortex of the brain (occipital region).

As has just been stated, many arcuate fibres issue from the grey matter of the corpora quadrigemina and pass obliquely downwards into the ventral part of the mesencephalon encircling the central grey matter. These fibres intercross in the raphe, where they constitute the fountain-decussation of Meynert (p. 509), and after crossing constitute the main mass of the ventral longitudinal bundles. These are continued into the ventral columns of the spinal cord; they give off collaterals to the motor nuclei of the eye-muscles, and probably to the motor nuclei generally. Other fibres which appear to belong to the same (*tecto-spinal*) system are traceable as a distinct tract into the lateral column of the cord (see p. 472).

In the cat, the anterior corpora quadrigemina receive a number of fibres from the pyramid-tract in the crusta of the same side, a few crossing over the aqueduct to the opposite colliculus (Boyce, Sutherland Simpson). But in most animals the fibres which pass from the cortex cerebri to the corpora quadrigemina enter these bodies through their respective brachia.

No fibres are given off from the cells of the corpora quadrigemina to the cortex cerebri.

Posterior (dorsal) commissure.—Immediately in front of the corpora quadrigemina, visible in the roof of this part of the mid-brain, is the *posterior (dorsal) commissure.* This consists of fibres which arise in a nucleus at each side of the Sylvian aqueduct, pass across the middle line dorsal to the central grey matter, and then turn ventralwards and caudalwards in the tegmentum lateral to the dorsal longitudinal bundle, which is partly reinforced by the fibres in question.

NERVES OF MID-BRAIN.

The optic nerves.—The only sensory nerves which are immediately connected with the mid-brain are the *second* or *optic.* These fibres take origin from the large nerve-cells of the ganglionic layer of the retina. Each optic nerve leaves the globe of the eye at its posterior aspect, passes through the optic foramen to the base of the brain, and joins the nerve of the opposite side to form the *optic chiasma* (fig. 668). Of the fibres which enter the chiasma, those from the inner (or nasal) two-thirds of the retina cross to the optic tract of the opposite side, while the remaining third, comprising the fibres from the temporal part of the retina, pass along the lateral border of the chiasma to the tract of the same side. In the optic tract they are continued to the parts of the brain where they have their terminal arborescences, viz. the external (lateral) geniculate body with the pulvinar thalami and the anterior corpora quadrigemina. A certain number of the fibres of the optic nerve bifurcate on reaching the chiasma; the branches pass one into each optic tract (Cajal).

The fibres which pass to the anterior corpora quadrigemina are much

finer than those to the corpora geniculata. The former furnish the path fo reflex movements of the pupil, etc., and the latter the path for visua impressions, since the lateral corpus geniculatum and the pulvinar thalam are directly connected with the visual cortex in the occipital lobe, whil no such direct connexion obtains between that cortex and the anterior corpor quadrigemina.

A small bundle of fibres (*transverse peduncular bundle*) leaves the opti tract as it enters the mid-brain and passes round the cerebral peduncle t lose itself in the mesial part of the tegmentum near the fillet. Its destina tion appears to be a small nucleus situated near the red nucleus. Its fibre degenerate after enucleation of the opposite eyeball.

The optic tracts and chiasma also contain the fibres of *v. Gudden's com missure*, which connects the posterior corpora quadrigemina; these fibre appear to have no relation to the visual function.

There are present in the optic nerve and tract a few fibres which originat in the nerve centres—where is not known—and terminate in the retina.

Motor nerves.—The motor nerves arising from the mid-brain are th third and fourth. The position of their nuclei and their mode of exit hav been already described (p. 506).

THE THALAMENCEPHALON.

The **thalamus** (figs. 664, 665, *th.*), which lies at the side of the thir ventricle, and forms part of the floor of the lateral ventricle, is covered o

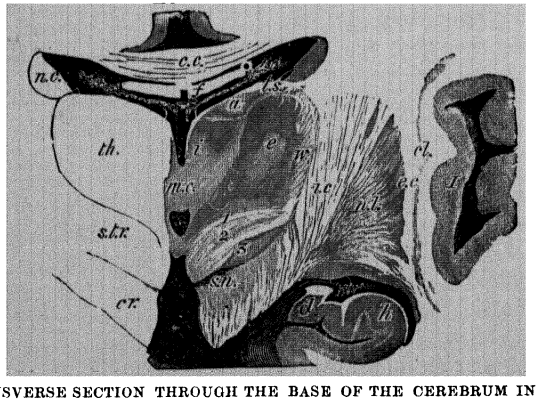

FIG. 664.—TRANSVERSE SECTION THROUGH THE BASE OF THE CEREBRUM IN THE REGIO OF THE MIDDLE COMMISSURE. (E. Sharpey-Schafer.) Natural size.

c.c., corpus callosum; *f*, fornix; *n.c.*, nucleus caudatus; *th*, thalamus; *s.t.r.*, subthalamic region; *cr*, crust passing into internal capsule, *i.c.*; *s.n.*, substantia nigra; *a*, *e*, *i*, various nuclei of thalamus; *w*, its lattice layer; *1*, *2*, *3*, parts of subthalamus; *n.l.*, nucleus lenticularis; *e.c.*, external capsule; *cl.*, claustrum *I*, insula; *m.c.*, middle commissure; above and below it is the third ventricle, communicating abov on each side through the foramen of Monro with the lateral ventricle. Below the fornix are seen th choroid plexuses; *t.s.*, stria terminalis; *h*, hippocampus; *d*, fascia dentata.

its free surface by a layer of white fibres. Laterally it is bounded by th internal capsule. Fibres from the latter pass into the thalamus and serv to connect it with the hemisphere.

The grey matter of the thalamus is partially subdivided (fig. 664) by an oblique white lamina into a smaller *mesial nucleus*; and a larger *lateral nucleus*; these contain a number of small nerve-cells. Anteriorly another portion of grey matter (*anterior nucleus*) is divided off in a similar way; this contains comparatively large nerve-cells. All these nuclei are formed of groups of cells having different connexions, many of which still require elucidation.

The thalamus receives the terminal branches of the fibres of the *upper fillet*, continued from the cells of the opposite nuclei of Goll and Burdach (spino-thalamic tract), those of the *central path of the fifth cranial nerve* of the opposite side, and some fibres from the *superior cerebellar peduncle* of the opposite side, besides the fibres of the *optic tract* which pass to the external geniculate body and the adjacent pulvinar.

From the cells of the thalamus nerve-fibres pass in every direction into the white matter of the hemisphere, and eventually to the cortex. From the outer part they tend especially towards the occipital region, assisting to form the *central visual tract* which passes to the visual cortex. From the inner and deeper part they converge towards the subthalamic region. Here many are collected into the ansa lenticularis (see p. 519), by which they are thought to pass into the nucleus lenticularis, while others, as already stated, enter the corona radiata and thus reach the cortex of the hemisphere. These fibres from the thalamus to the cortex probably form the third and the last link in the chain of sensory neurones, the second being formed by the neurones of the fillet and the first by the neurones of the sensory roots. On the other hand, the thalamus receives fibres both from the cortex and from the globus pallidus of the corpus striatum, to end amongst its cells.

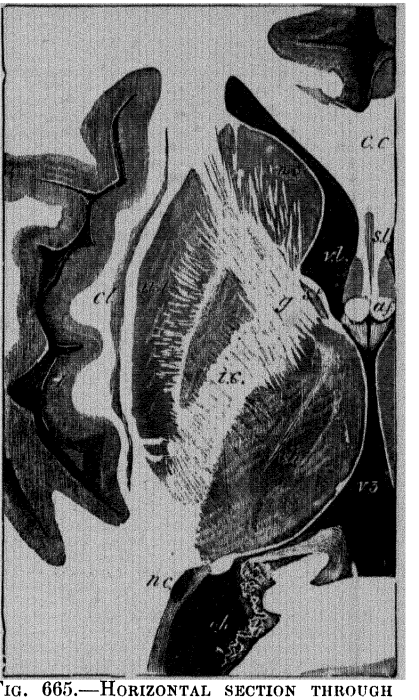

FIG. 665.—HORIZONTAL SECTION THROUGH THE OPTIC THALAMUS AND CORPUS STRIATUM. (E. Sharpey-Schafer.) Natural size.

v.l., lateral ventricle, its anterior cornu; *c.c.*, corpus callosum; *s.l.*, septum lucidum; *a.f.*, anterior pillars of the fornix; *v3*, third ventricle; *th.*, thalamus; *st.*, stria medullaris; *n.c.*, nucleus caudatus, and *nl.*, nucleus lenticularis of the corpus striatum; *i.c.*, internal capsule; *g*, its angle or genu; *nc'.*, tail of the nucleus caudatus appearing in the descending cornu of the lateral ventricle; *cl.*, claustrum; I, insula; *ch*, choroid plexus.

Corpora geniculata.—Attached to the thalamus below and behind are the *geniculate bodies* (fig. 667). Both of these at first sight appear to be connected with the optic tract, but only the lateral one actually receives optic

fibres, the mesial body receiving fibres from the central auditory tract through the lateral fillet. Of the geniculate bodies the *outer or lateral* has a lamellated structure consisting of alternating layers of grey and white matter, the white layers being composed partly of the entering optic fibres and partly of fibres emerging from the grey matter and passing to the central optic path, while the grey substance contains very numerous nerve-cells amongst which the fibres of the optic tract end in complex arborisations.

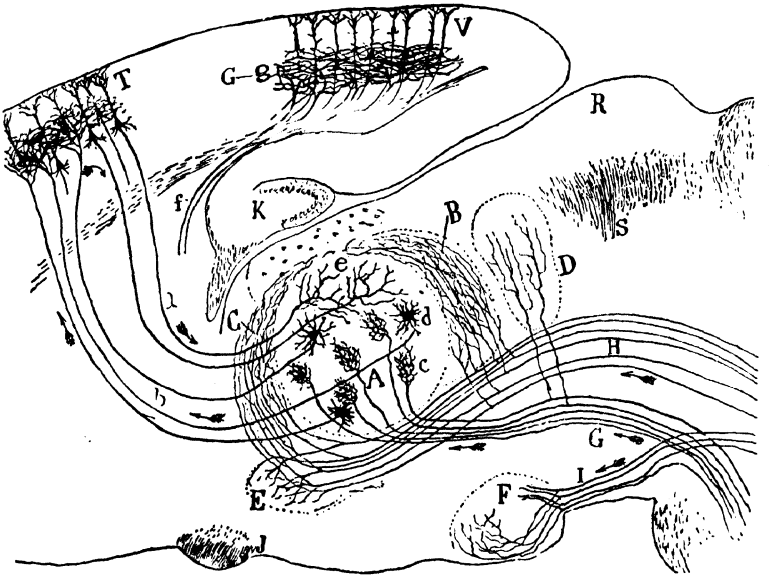

FIG. 666.—DIAGRAM OF THE CONNEXIONS OF THE THALAMUS WITH THE ASCENDING FIBRES OF THE FIFTH NERVE, AND OF THE UPPER FILLET ON THE ONE HAND AND WITH THE CORTEX CEREBRI ON THE OTHER. (R. y Cajal.)

A, B, C, D, E, various nuclei in thalamus; I, afferent fibres passing to mammillary body, F; G, tract of upper fillet ending in A (at *c*), and giving collaterals to D (posterior nucleus); H, central tract from sensory nucleus of fifth; T, cortex cerebri; V, visual cortex; R, anterior colliculus; J, optic chiasma; S, optic fibres; K, hippocampus.

a, fibres from cortex to thalamus, ending at e; b, fibres from cells in thalamus (d) to cortex; f, fibres from lateral geniculate body and thalamus to visual cortex, ending at g in stria of Gennari.

From these cells axons arise and join a bundle of fibres which enters the white matter of the hemisphere above and along with the internal capsule, and passes to the visual area of the cortex (*central visual tract*). Some of the fibres from the lateral geniculate body, as they enter the visual tract, send branches downwards towards the tegmentum.

The cells of the *mesial geniculate body* are collected into two main nuclei, dorsal and ventral. Most of the cells are small, but at one part there is a group of large cells. The axons appear to pass through the brachium and eventually to the cortex: chiefly to that of the temporal lobe.

The **ganglion of the habenula** (fig. 669, *g'*) is a collection of nerve-cells

which lies at the posterior part of the thalamus on each side, near the roof of the third ventricle. This ganglion receives on the one hand the fibres of the *habenula* or *stria medullaris*, and on the other hand gives off from its cells the fibres which form the *fasciculus retroflexus* or *Meynert's bundle* (fig. 689), passing downwards to the interpeduncular ganglion (p. 510). The two ganglia of the habenulæ are joined by a white commissure.

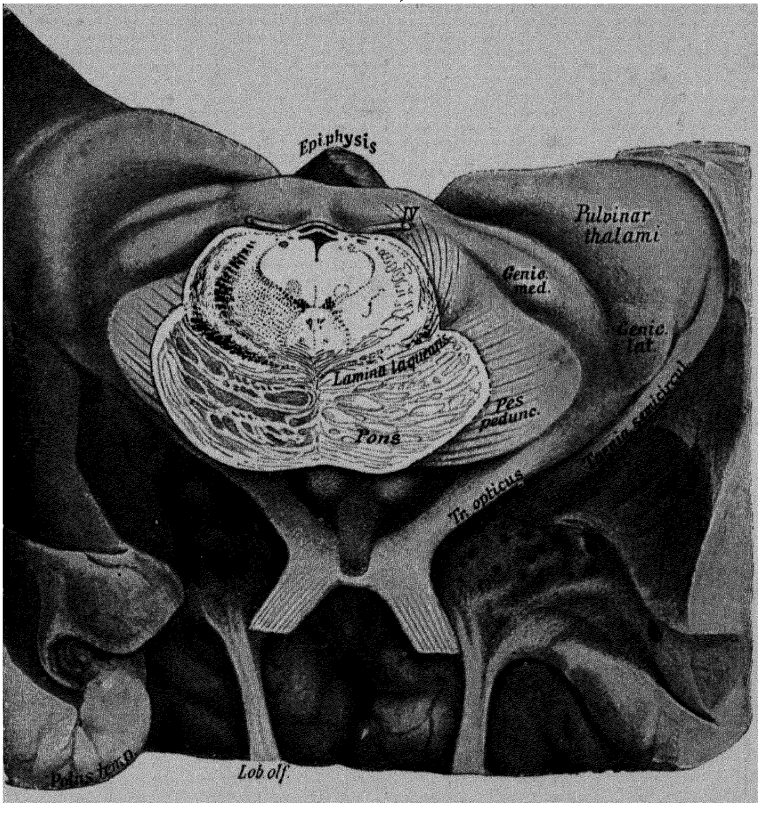

FIG. 667.—FIGURE SHOWING THE OLFACTORY TRACTS AND THEIR ROOTS, THE OPTIC CHIASMA AND OPTIC TRACTS, THE GENICULATE BODIES AND THE PULVINAR THALAMI. (Edinger.)

The pons is cut through at the anterior part, and the section shows the Sylvian aqueduct, the fillet (*lamina laquearis*), superior cerebellar peduncles, etc. The corpora mammillaria are partly concealed by the pons; between and in front of them is seen the infundibulum.

The **corpora mammillaria** (fig. 667) are seen at the base of the brain immediately below the posterior part of the third ventricle. Each is composed of white matter externally and grey matter internally. Each receives fibres from the anterior pillar of the fornix of the same side (fig. 689); these fibres arise from cells in the hippocampus and end in the mammillary body. According to Edinger some fibres from the olfactory tract pass directly to it.

The axons of its cells bifurcate; one branch, the coarser, passing into the anterior and upper part of the thalamus in the bundle of Vicq d'Azyr, and the other into the tegmentum of the mid-brain in v. Gudden's bundle (fig. 689). The corpora mammillaria form part of the central olfactory apparatus.

At the base of the brain (floor of the third ventricle), between the corpora mammillaria and in the neighbourhood of the infundibulum, are several collections of nerve-cells which, it has been suggested, influence the secretion of water by the kidneys, since injury to this part of the brain is liable to be accompanied by diabetes

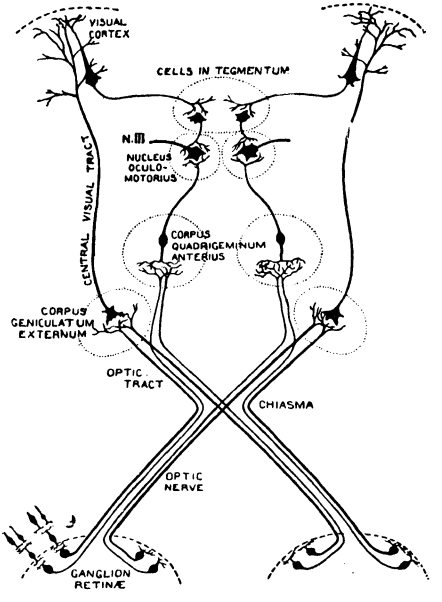

FIG. 668.—DIAGRAM TO SHOW THE PROBABLE COURSE AND RELATIONS OF THE OPTIC FIBRES. (E. Sharpey-Schafer.)

Only single fibres are shown emerging from the anterior quadrigeminal and external geniculate bodies, continuing the course of the two fibres from corresponding points in the retinæ. This is merely to simplify the diagram, and is not intended to assume that the retinal impressions are fused in those situations.

insipidus (Camus and Roussy). It is, however, probable that such a lesion would involve the pars tuberalis of the pituitary body and that this may account for the result in question.

Subthalamic region.—The tegmentum of the crus cerebri is prolonged below the thalamus, and between that and the internal capsule is represented by a mass of grey substance, with longitudinally and obliquely crossing white bundles, known under the name of *subthalamus* or *hypothalamus* (fig. 669). Its deepest part contains a lens-shaped mass of grey matter prolonged forwards from the substantia nigra known as the *corpus subthalamicum* of Luys. A mass of fibres sweeps round this and round the

internal capsule, passing between the thalamus and the nucleus lenticularis; this is called the *ansa lenticularis*. Its fibres arise, in large part, from the

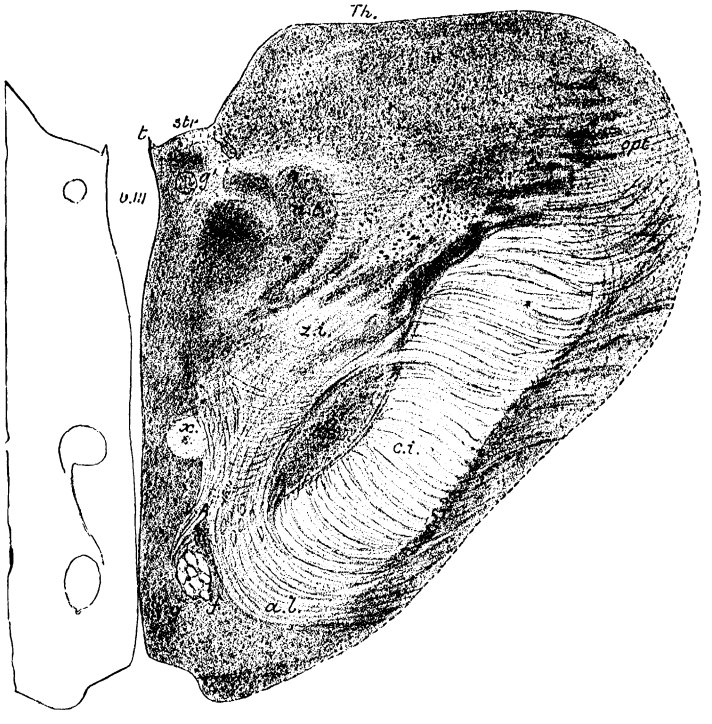

FIG. 669.—SECTION TAKEN OBLIQUELY THROUGH THE THALAMUS AND INTERNAL CAPSULE SHOWING SOME OF THE STRANDS OF FIBRES OF THE SUBTHALAMUS. (E. Sharpey-Schafer.) × 2½. Drawn from a photograph.

Th., thalamus; *v.iii*, third ventricle; *t.*, tænia, or attachment of epithelial roof of ventricle; *str.*, stria medullaris or habenula; *g'*, ganglion of the habenula; *n.t.*, mesial nucleus of thalamus; *opt.*, optic fibres passing into pulvinar of thalamus; *z.i.*, zona incerta, from which fibres are seen emerging and sweeping as the *ansa lenticularis*, *a.l.*, round the internal capsule, *c.i.*, to pass toward the lenticular nucleus; *c.s.*, corpus subthalamicum; *f*, anterior pillar of fornix passing backwards to corpus mammillare; *V.A.*, bundle of Vicq d'Azyr, passing upwards and forwards from corpus mammillare into thalamus; *g*, group of nerve-cells, probably belonging to the nucleus of the corpus mammillare; *x*, fasciculus retroflexus.

globus pallidus of the lenticular nucleus, and go to the hypothalamus and to the red nucleus (Wilson).

LESSONS XLIV. AND XLV.

THE CEREBELLUM AND CEREBRUM.

1. SECTIONS of the cerebellum vertical to the surface, (*a*) across the direction of the laminæ, (*b*) parallel with the laminæ.

2. Sections across the whole of one hemisphere of the cerebrum of a monkey or cat passing through the third ventricle.

3. Vertical sections of the human cerebral cortex :—one from the central gyri, another from the occipital lobe (calcarine region), another from the superior temporal gyrus and island of Reil, and one from the hippocampal gyrus and hippocampus.

4. Transverse sections of the olfactory tract and bulb.

In all these preparations make outline sketches under a low power of the arrangement of the grey and white matter, and the disposition of nerve-cells in the grey matter. Sketch some of the details under a high power.

The preparations are made in the same way as those of the spinal cord. Other preparations should be made by the Golgi and Cajal methods to exhibit the relation of the cells and fibres to one another. Such preparations have been already partly described (Lesson XVIII.).

THE CEREBELLUM.

The cerebellum is composed of a white centre and a grey cortex (fig. 670). Both extend into all the folds or laminæ, so that when the laminæ are cut across an appearance is presented of a white arborescence covered superficially by grey matter. The white matter is in largest amount in the middle of each cerebellar hemisphere. There is here present a peculiar wavy lamina of grey matter, similar to that in the olivary body, and known as the *nucleus dentatus* (fig. 670, *n.d.*). This receives on its outer surface numerous nerve-fibres from the cells of Purkinje of the cortex, which end by arborising around its cells. The latter give off axons which, emerging from the hilum of the nucleus, become the fibres of the superior cerebellar peduncles, and for the most part end in the opposite red nucleus (p. 508), but some pass beyond this into the subthalamic region. The dentate nucleus also receives collaterals from fibres of the inferior peduncle (Cajal).

Other isolated grey nuclei lie in the white matter of the middle lobe over the roof of the fourth ventricle and constitute collectively the *nuclei of Stilling*. The most important of these appears to be the *nucleus tecti seu fastigii* (fig. 671). This receives many of the ascending fibres of the vestibular nerve (p. 492) and collaterals from the spino-cerebellar tracts, and gives origin to a bundle of fibres which crosses to the opposite side and descends in the mesial part of the restiform body to the reticular formation of the medulla oblongata.

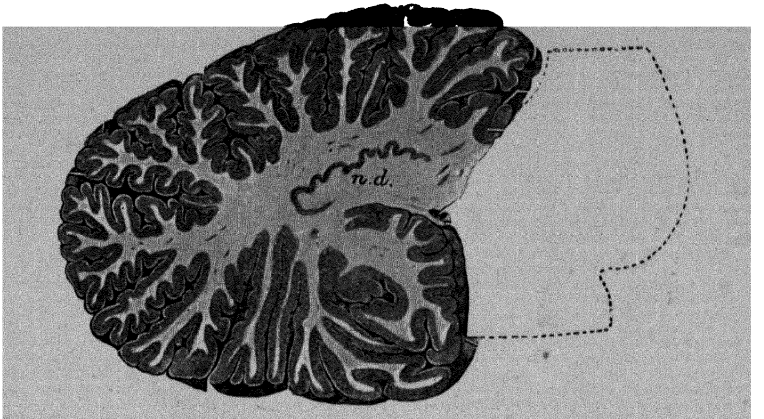

70.—SECTION THROUGH ONE OF THE HEMISPHERES OF THE CEREBELLUM, SHOW
HE LAMINATED ARBORESCENT APPEARANCE OF THE GREY MATTER AT THE SURI
ND THE NUCLEUS DENTATUS (*n.d.*) IN THE MIDDLE OF THE WHITE CEN
E. Sharpey-Schafer.) Photograph. The pons is indicated by a dotted outli

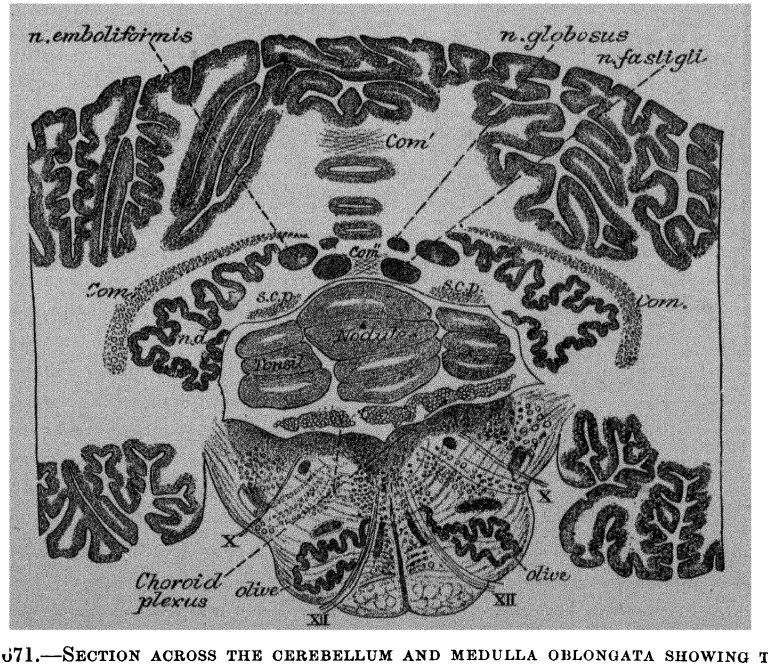

FIG. 671.—SECTION ACROSS THE CEREBELLUM AND MEDULLA OBLONGATA SHOWING THE POSITION OF THE NUCLEI IN THE WHITE CENTRE OF THE CEREBELLUM. (Stilling.)

n.d., nucleus dentatus cerebelli; *s.c.p.*, fibres of superior peduncle; *com*, *com'*, *com"*, commissural fibres; X, root-fibres of vagus; XII, root-fibres of hypoglossal nerve.

The **grey matter** of the cerebellum appears of essentially similar structure throughout the whole extent of the cortex. It consists of two layers. The *inner* or *granule layer* (fig. 672, *d*, and fig. 674, B) lies next to the white centre, and is composed of a large number of very small nerve-cells intermingled with a few larger ones and some neuroglia-cells. The *outer* or molecular layer (fig. 672, *b*, and fig. 674, A) is thicker, and is formed chiefly of fine nerve-fibres with small nerve-cells scattered through it. Into its outer part processes of the pia mater conveying blood-vessels pass vertically. Lying between the two layers of the grey matter is an incomplete stratum of large flask-shaped cells, termed the *cells of Purkinje* (figs. 672, *c*; 673, a, 674, *a*). Each of these cells gives off from its base a fine process (axon), which becomes the axis-cylinder of one of the myelinated fibres of the white centre, while from the opposite pole of the cell large ramified processes (dendrons) extend into the superficial layer of the grey matter.



FIG. 672.—SECTION OF CORTEX OF CEREBELLUM. (Sankey.)

a, pia mater; *b*, outer or molecular layer; *c*, cells of Purkinje; *d*, inner or granule layer; *e*, medullary centre.

The dendrons of the cells of Purkinje spread out in planes transverse to the direction of the lamellæ of the organ, so that they present a different appearance according to whether the section is taken along a lamella or across it (compare fig. 674, I and II). These dendrons are invested at their attachment to the cell and, for some extent along their branchings, by a basket-work formed by the terminal arborisations of certain fibres (*climbing or tendril fibres*) of the medullary centre (fig. 676; fig. 677, *cl.f.*). The body of the cell of Purkinje is further invested by a feltwork of fibrils formed by the arborisation of axis-cylinder processes of nerve-cells (*basket-cells*) in the outer layer of the grey matter (figs. 675; 677, *b*). Each cell has therefore a double investment of this nature, one covering the dendrons, the other investing the body of the cell and extending along the commencement of the axon.

The *granules of the inner layer* of grey matter are mostly small nerve-

cells, each with a few dendrons penetrating amongst the other granules, and an axon directed between the cells of Purkinje into the outer layer. After penetrating a variable distance into this layer the axon bifurcates, and its two branches pass in opposite directions at right angles to the main stem, and parallel to the direction of the lamella (fig. 674, I). What ultimately becomes of the branches is not known. In sections cut across

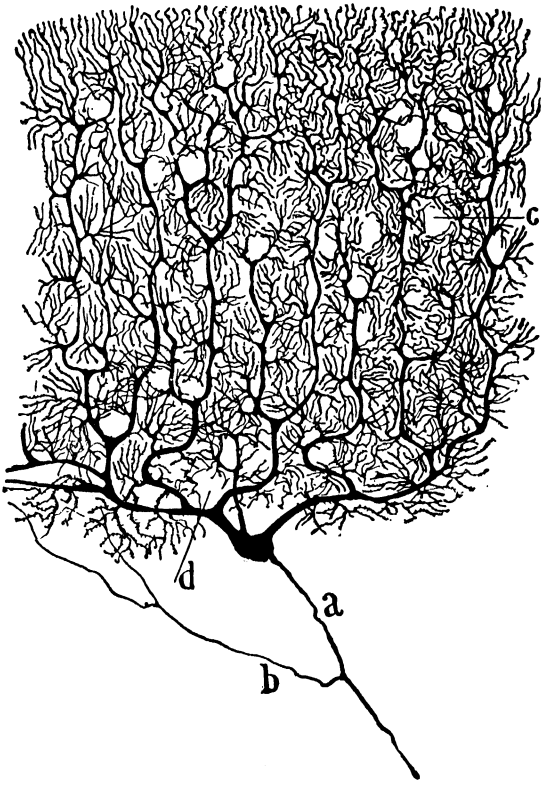

FIG. 673.—A CELL OF PURKINJE OF THE CEREBELLUM, SHOWN BY GOLGI'S METHOD. (R. y Cajal.)

a, axon ; b, collateral from axon ; c, d, arborisation of dendrons.

the lamella the cut ends of these fibres give a finely punctuated appearance to the outer layer (fig. 674, II).

Some of the cells of the granule layer are far larger than the others, and send their much-branching axons amongst the smaller granules. They are known as *cells of Golgi* (fig. 677, G). Certain other large 'granules' have been noticed by Cajal, occurring both in the granule layer, and in the white centre, with long axons passing into the white matter of the cerebellum. These are comparatively few in number.

Ramifying amongst the cells of the granule layer are peculiar fibres

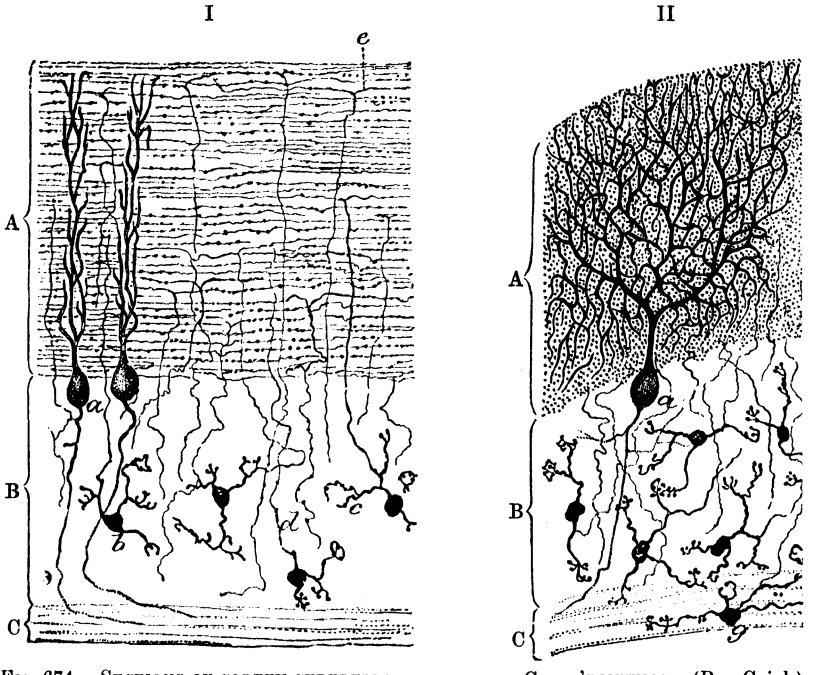

FIG. 674.—SECTIONS OF CORTEX CEREBELLI PREPARED BY GOLGI'S METHOD. (R. y Cajal.)

I.—Section made in the direction of a lamina. II.—Section taken across a lamina.
A, outer or molecular layer; B, inner or granule layer; C, medullary centre.
v, corpuscles of Purkinje; *b*, small granules of inner layer; *c*, dendron of a granule; *d*, nerve-fibre process of a granule passing into the molecular layer, where it bifurcates and becomes a longitudinal fibre (in II these longitudinal fibres are cut across and appear as dots); *e*, bifurcation of another fibre *g*, a granule lying in the white centre.



FIG. 675.—BASKET-CELL OF CEREBELLUM SHOWING THE ARBORISATIONS OF ITS AXON OVER THE CELLS OF PURKINJE. (R. y Cajal.)

A, row of Purkinje cells; B, basket-cell of molecular layer; d, its dendrons; c, its axon; a and b, endings of axon.

derived from the white centre, and characterised by having pencils of fine short branches at intervals, like tufts of moss (fig. 677, *m.f.*). These have been termed by Cajal the *moss-fibres*; they end partly in the granule layer, partly in the molecular layer.

The **neuroglia** of the cerebellum is peculiar in containing, besides the ordinary 'spider' and 'branched' neuroglia-cells (fig. 677, gl^1, gl^2), other large cells with long parallel processes which extend through the molecular layer to be attached to the surface of the lamellæ (gl^3). The cell-bodies lie at about the same level as those of Purkinje's cells.

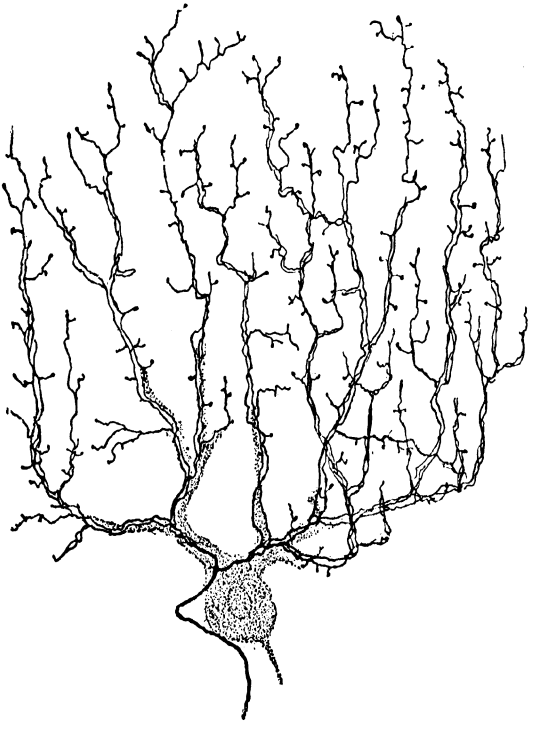

FIG. 676.—ENDING OF A 'TENDRIL' FIBRE OVER THE DENDRONS OF A PURKINJE CELL: HUMAN. (Cajal.)

Fibres of the cerebellar peduncles.—The peduncles of the cerebellum have been already studied in connexion with the medulla oblongata, pons, and mid-brain, but it may be convenient briefly to summarise what has there been stated. The *inferior peduncle* (restiform body) is composed mainly (1) of ascending fibres derived from the dorsal spino-cerebellar tract, running in its outer part; and (2) of fibres from both olivary nuclei, but chiefly from that of the opposite side. This peduncle is also said to receive fibres from the nuclei of the gracile and cuneate funiculi, from cells and nuclei of the reticular formation of the medulla oblongata, and from the sensory nuclei of the cranial nerves, especially of the vestibular nerve. Most of the fibres of the peduncle pass to the lower part of the vermis, crossing to the opposite side over the fourth ventricle, but before doing so they give off strong

collaterals to the hemisphere of the same side. Besides its ascending fibres the peduncle also contains a small bundle of fibres descending to the medulla oblongata from the nucleus tecti of the opposite side: this bundle bends round the superior peduncle to join the inferior peduncle, its fibres lying between those of the superior peduncle and Gowers' tract (Risien Russell). In the middle of the inferior peduncle

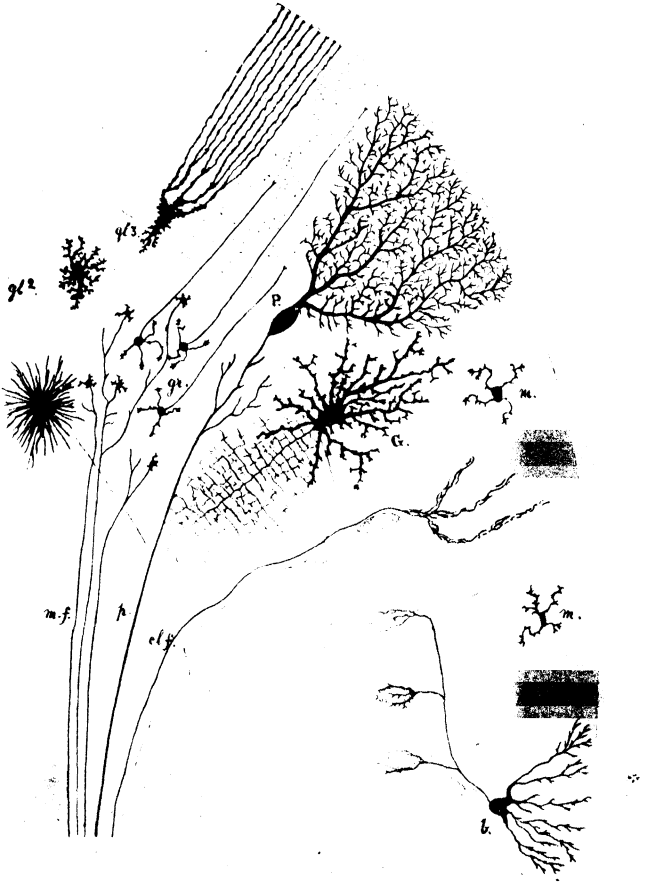

FIG. 677.—DIAGRAMMATIC SECTION OF CEREBELLUM TO SHOW THE CHARACTERS AND RELATIONS OF THE CELLS AND FIBRES MET WITH IN THE SEVERAL LAYERS AS EXHIBITED BY THE CHROMATE OF SILVER METHOD. (After Kölliker.)

P, a cell of Purkinje; G, a cell of Golgi; *b*, a basket-cell; *m*, *m*, other cells of the molecular layer; *gr.*, granules; *p*, a nerve-fibre of the white substance derived from a Purkinje cell; *m-f.*, 'moss'-fibres; *cl.f.*, a climbing fibre; gl^1, gl^2, gl^3, types of neuroglia-cells.

is a very small nucleus of grey matter (Déjerine) which is almost completely concealed amongst the mass of white fibres (fig. 645, *n.r.*).

The *middle peduncle* is formed of fibres from the cells of the nuclei pontis which are passing to the opposite hemisphere of the cerebellum.

The *superior peduncle* is formed of fibres which mostly take origin in the corpus dentatum cerebelli, but some are said to arise in the hemisphere and pass through this nucleus. The superior peduncles decussate in the mid-brain across the raphe,

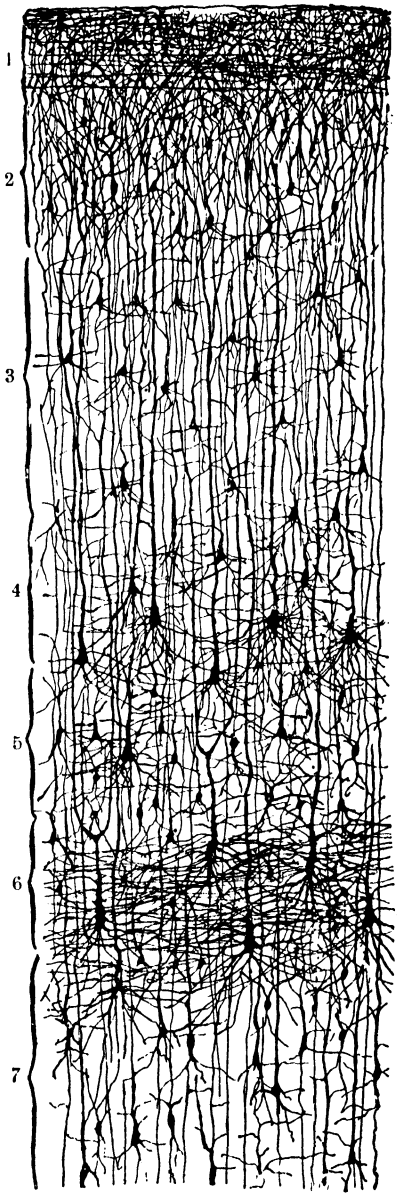

FIG. 678. — ASCENDING PARIETAL (POST-CENTRAL) CONVOLUTION : GOLGI METHOD. (R. y Cajal.)

1, plexiform layer; 2, small pyramids; 3, medium pyramids; 4, superficial large pyramids; 5, granules (small stellate cells); 6, deep large pyramids; 7, deep medium pyramids.

and their fibres then bifurcate into ascending and descending branches. The ascending branches pass forwards and end in the red nucleus, but some fibres go past this into the ventral part of the thalamus. The descending branches are traceable into the dorsal part of the reticular formation of the pons.

The superior peduncle, as it issues from the hemisphere, is joined by the tract of Gowers, which runs over it, and passes backwards along its mesial border to the vermis.

THE CEREBRUM.

The grey matter of the cerebral cortex is usually described as if composed of a number of layers, but the strata are not sharply differentiated and they vary in number and in relative development in different regions of the cortex. Most of the cells are of a long, irregularly conical shape: these are known as the *pyramidal cells* of the cortex, a name somewhat inappropriate as a term intended to describe their form (fig. 678). They vary considerably in size in different levels. The following eight strata are generally distinguishable, but in some parts of the cortex a larger number can be made out, whilst in other parts there are fewer.

1. A peripheral stratum (the *plexiform layer*) containing scattered nerve-cells and many neuroglia-cells (figs. 678, 679, 1). In the most superficial part of this layer, immediately under the pia mater, is a thin stratum of nerve-fibres running parallel with the surface; the layer also contains a large number of ramified fibres. Most of the fibres of this plexiform layer are derived from nerve-cells of the deeper parts of the cortex. Intermingled with the fibres

a few ramified cells, each with numerous dendrons and a long axon, are disposed parallel with the surface; the axons terminate by arborisations within the layer itself (*horizontal cells* of Cajal, fig. 679). Other cells with shorter axis-cylinder processes also occur in this layer.

2. A layer of closely set small pyramidal nerve-cells, several deep (*layer of small pyramids*, fig. 678, 2). This layer also contains other cells with short axons.

3. A layer of medium-sized pyramidal cells less closely set, with small granule-like cells amongst them (*layer of medium-sized pyramids*, fig. 678, 3).

4. A layer of larger pyramidal cells (*superficial large pyramids*, fig. 678, 4).

5. A layer of small irregular cells (*small stellate cells*, fig. 678, 5). The large pyramids may extend down into this layer.

6. A layer of still larger pyramids (*deep large pyramids*, fig. 678, 6). In the excitable region of the frontal cortex, which in man is confined to the precentral gyrus and paracentral lobule, pyramidal cells of very large size (giant-cells) occur within this layer, disposed in small clusters or 'nests' (Betz, Bevan Lewis). The fibres of the pyramid-tract arise from these giant-cells. In some parts of the cortex these large pyramids are either absent or occur among the cells of the next layer.

7. A layer of medium-sized pyramidal cells (*deep medium pyramids*, fig. 678, 7).

8. A layer of small scattered cells (fig. 679, 4), many of a fusiform shape (*polymorphous layer*). This layer lies next to the white centre. In the island of Reil it is considerably developed, and is separated from the rest of the grey matter by a layer of white substance. It is here known as the *claustrum*, and on that account the layer has been termed the *claustral layer*.

Some authorities describe the cortex as consisting only of three layers, viz.: the molecular layer, the layer of pyramids, and the layer of polymorphous cells; others of four, five, etc., up to nine. As a matter of fact, the complexity and the number of distinct layers vary in different regions.

Each pyramidal cell has several basal and one large apical dendron. This last extends to the plexiform layer, on approaching which it breaks up into numerous ramifications which have a general vertical direction and extend almost to the outer surface. The apical dendron is beset, both in its undivided part and in its branches, by minute spinous projections: similar 'spines' may also be seen upon the basal dendrons. The projections are believed by some authors to be retractile (amœboid) and to be the means of effecting (or breaking) nervous connexion with afferent fibres, since they are in some preparations prominent, in others hardly visible: sometimes the dendrons are entirely free from them, and have an even outline or may be slightly moniliform. Each pyramidal cell has a single axon, which is usually directed towards the medullary centre, of which it forms one of the fibres: but the axon sometimes curves back and passes outwards again, ending in an arborisation in one of the other layers. Intermingled with the pyramids and polymorphous cells are two other kinds of cells, viz.: (1) cells with axis-cylinder process ramifying near the cell-body; these occur in all the layers; and (2) small cells sending their axons towards the plexiform layer (Martinotti): these are found chiefly in the deeper layers of the grey matter.

From the white centre bundles of myelinate nerve-fibres pass in vertical streaks through the deeper layers of the grey matter to lose themselves among the pyramidal cells of the more superficial layers. Many large fibres, however, are seen running not vertically but obliquely into the grey

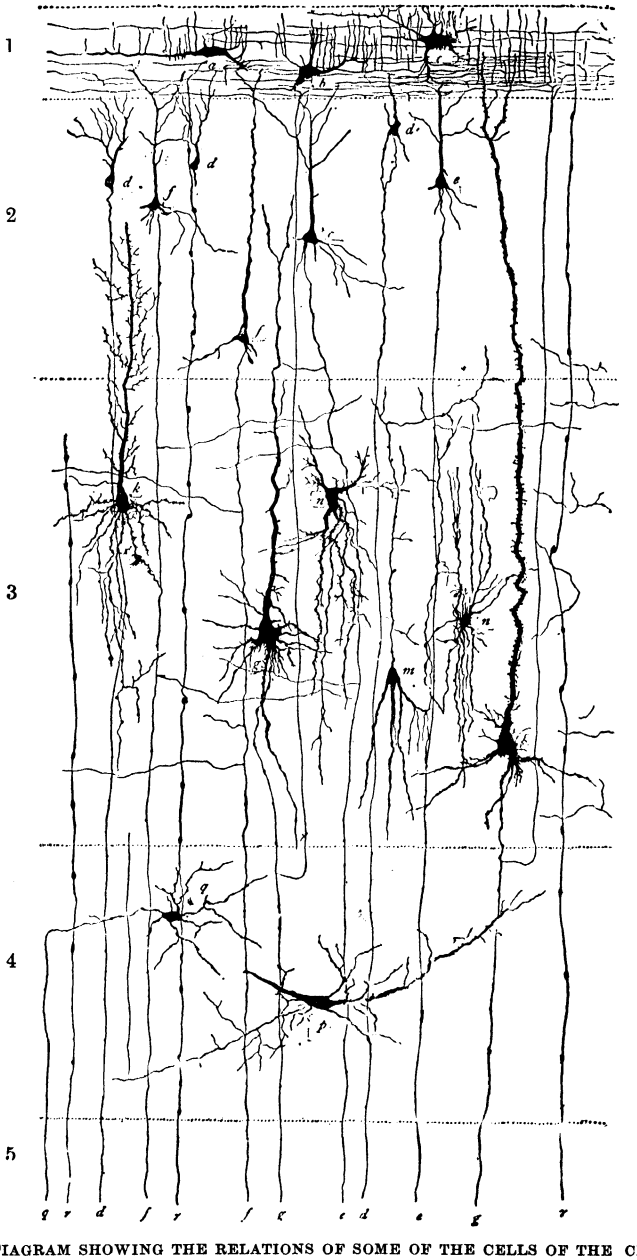

FIG. 679.—DIAGRAM SHOWING THE RELATIONS OF SOME OF THE CELLS OF THE CEREBRAL CORTEX. (Barker, after Starr, Strong, and Leaming.)

1, plexiform layer with horizontal cells of Cajal (*a*, *b*, *c*); 2, small (*d*, *e*) and middle size (*f*) pyramids; 3, large pyramids (*g*, *g*, *k*); also *m*, cell with axon passing towards the surface, but soon ramifying; *n*, *n*, cell of Golgi's second type, with axon ramifying in the adjacent grey matter; one of these belongs to the kind termed by Cajal 'double-brush' cells; 4, polymorphous cells, of which *p* sends its axon towards the surface and *q* its axon into the medullary centre; 5, white or medullary centre, receiving axons from cells in the grey matter, and including also afferent fibres (*r*, *r*), ending in the grey matter.

cortex from the white matter. Most of the vertically disposed fibres are the nerve-fibre processes of the pyramidal and polymorphous cells, and have taken origin in the cortex; others, including the oblique fibres just mentioned, are passing into the cortex, largely from the thalamus, to end in close arborisations amongst the cells (fig. 681).

Besides these vertical strands of fibres there are others lying in planes parallel to the surface of the cortex, and derived partly from the fibres which enter the cortex from the white matter, partly from the collaterals which are given off from the axis-cylinder processes of the cortical cells themselves. The planes in which these fibres occur are: (1) near the surface, in the plexiform (molecular) layer: this superficial stratum of white fibres is best marked in the hippocampal region; (2) in the layer of medium-sized pyramids: here the fibres give the appearance of a whitish line in the section of the grey matter (*outer line of Baillarger*, fig. 680, *b*). There is a particularly dense plexus of fibres in this situation in the visual region of the cortex (all over the occipital lobe in animals but in man only in the convolutions bounding the calcarine fissure), producing a very distinct line, known as the *line of Gennari* (fig. 680, *a*). This plexus of nerve-fibres is in intimate association with certain (large and small) stellate cells characteristic of the visual region. (3) In most regions of the brain, in the plane of the layer of large pyramids, another white line is seen; this is known as the *inner line of Baillarger* (fig. 680, *b*). The planes in which these white lines are found are characterised, especially in the occipital and temporal lobes, by the presence amongst

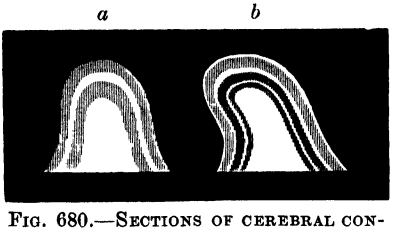

FIG. 680.—SECTIONS OF CEREBRAL CONVOLUTIONS. (After Baillarger.) Natural size.

a, from the neighbourhood of the calcarine fissure with only one white line clearly visible (the line of Gennari); *b*, ordinary type, with the superficial white layer and outer and inner lines of Baillarger shown.



FIG. 681.—PREPARATION SHOWING SOME OF THE AFFERENT FIBRES OF THE ASCENDING FRONTAL OR PRECENTRAL GYRUS. (R. y Cajal.)

A, part of second layer; B, close terminal plexus in layer of medium-sized pyramids; C to D, intermediate plexus of horizontal fibres; E, deep plexus of large oblique afferent fibres; a, b, afferent fibres arborising in the layer of middle pyramids, amongst which they form, along with fibres derived from cells in the cortex itself, the dense plexus which is shown in the left half of the figure. The efferent fibres are not shown in this figure.

the pyramids of great numbers of very small nerve-cells, amongst which the white fibres of the layers ramify and probably terminate. According to Cajal, in the brain of man as compared with the lower mammals, there is a marked preponderance in the grey matter of the cortex cerebri of cells with a short axis-cylinder ramifying near the cell body. Such cells are most numerous amongst the stellate cells and the small pyramids.

The axis-cylinder processes of the pyramidal cells pass into the white centre (fig. 682). Here some of them are continued into the corpus callosum and through this to the cortex of the opposite hemisphere as *commissural fibres*; others form *association fibres* which eventually pass again into the grey matter of other parts of the same hemisphere; whilst others again,

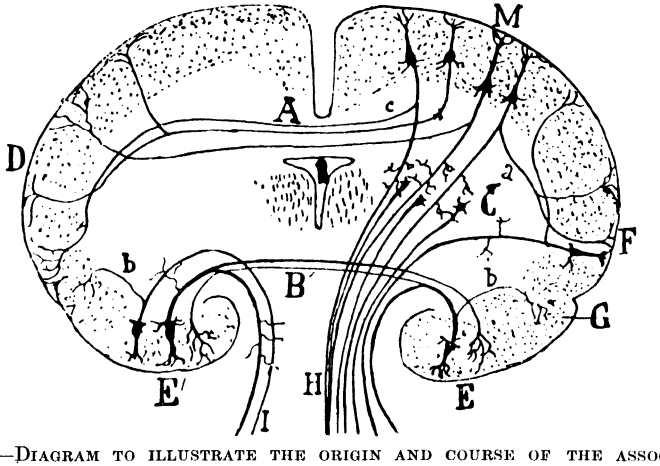

FIG. 682.—DIAGRAM TO ILLUSTRATE THE ORIGIN AND COURSE OF THE ASSOCIATION, COMMISSURAL AND PROJECTION FIBRES OF THE CEREBRAL CORTEX. (R. y Cajal.)

A, commissural fibres connecting cells of the motor cortex, M, with the opposite hemisphere; B, commissural fibres connecting the opposite sensory regions of the cortex; C, cells in basal ganglia giving origin to descending fibres and receiving collaterals from projection fibres, H, of cells of the motor cortex; D, E, endings of commissural fibres in grey matter; F, G, endings of association fibres in grey matter; I, a projection fibre from sensory (hippocampal) cortex; a, b, c, collaterals.

especially those of the largest pyramidal cells, extend downwards as *projection fibres* through the corona radiata and internal capsule. These include the fibres of the pyramid-tract and of the cortico-pontine tract. As the projection fibres pass through the grey and white matter of the hemisphere they give off collateral fibres to the adjacent grey matter, to the corpus callosum, and to the corpus striatum and optic thalamus, and some probably end in these masses of grey matter.

The **neuroglia of the cortex cerebri,** like that of the cerebellum, contains the types of glia-cell already described on p. 525. The ependyma cells of the ventricles are prolonged, like the cells of the central canal of the cord, in the form of long neuroglia-like fibres far into the adjacent grey matter.

SPECIAL FEATURES OF CERTAIN PARTS OF THE CORTEX.

There is, as already stated, a great amount of variation met with in the relative extent of development of the above layers. This is exemplified in

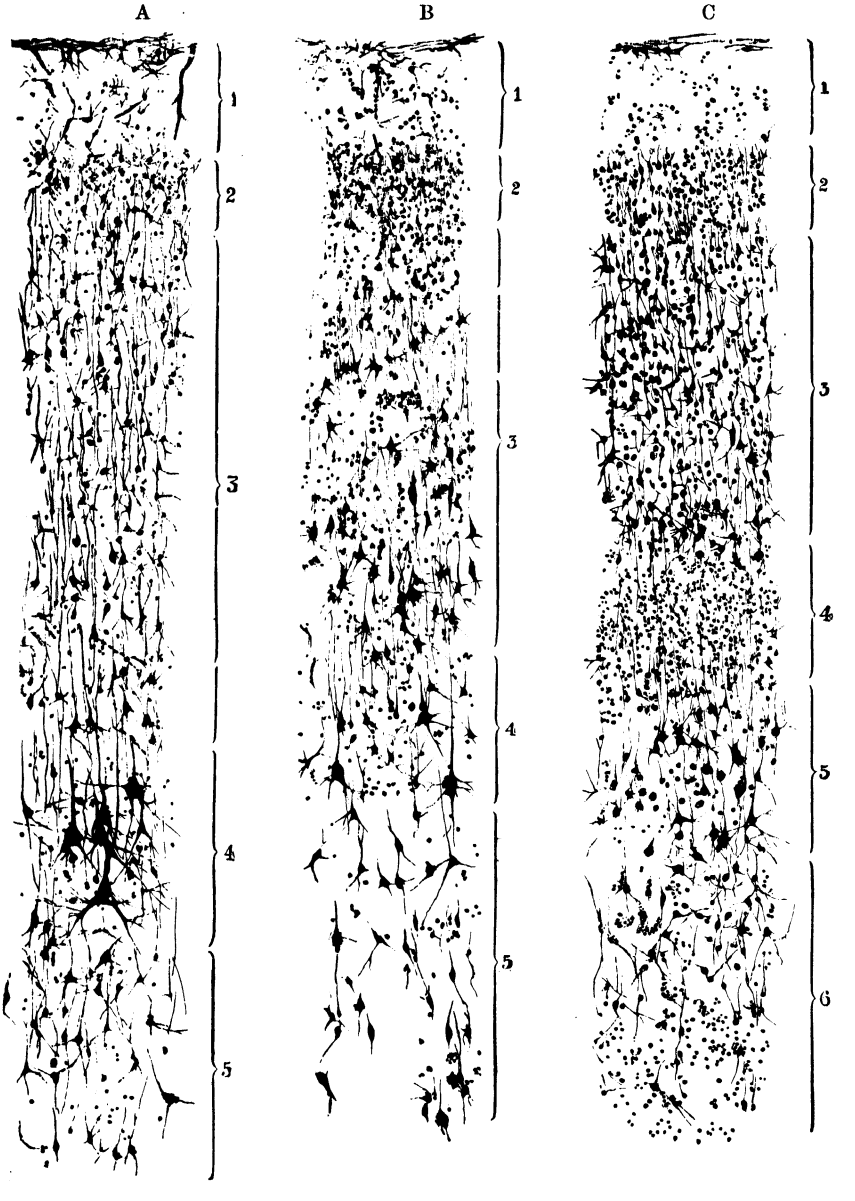

FIG. 683.—STRUCTURE OF DIFFERENT REGIONS OF THE CEREBRAL CORTEX OF THE MONKEY. (Bevan Lewis.) × 145.

A, precental gyrus; B, prefrontal cortex; C, temporal cortex.

In A and B.—1, plexiform layer; 2, small pyramids; 3, medium pyramids; 4, large pyramids; 5, polymorphous cells.

In C.—1, plexiform layer; 2, small pyramids; 3, medium pyramids; 4, small stellate cells; 5, large pyramids; 6, polymorphous cells.

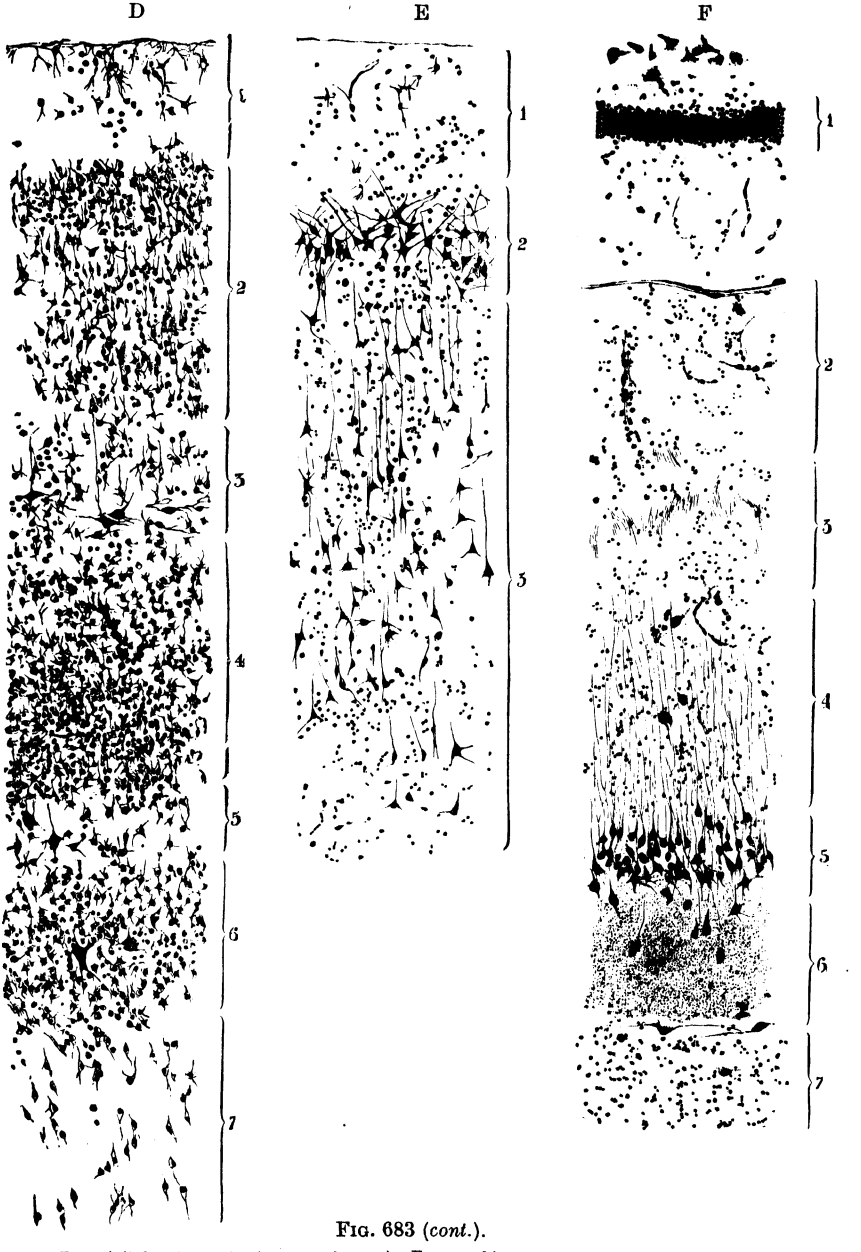

FIG. 683 (*cont.*).

D, occipital cortex (calcarine gyrus in man); E, gyrus hippocampi; F, hippocampus major.

In D.—1, plexiform layer; 2, small pyramids; 3, large stellate cells; 4, small stellate cells; 5, large pyramids; 6, small stellate cells; 7, polymorphous layer.

In E.—1, plexiform layer; 2, large stellate cells; 3, pyramids with small stellate cells interspersed amongst them.

In F.—1, fascia dentata; 2, stratum granulosum; 3, stratum laciniosum; 4 and 5, pyramids 6, polymorphous or molecular layer; 7, alveus.

the accompanying drawings by Bevan Lewis (fig. 683) from different regions of the monkey's brain. From these it will be seen that smaller-sized cells prevail in certain regions of the cortex (occipital, temporal); larger and fewer cells in others (frontal, parietal, limbic). Nests or groups of 'giant' cells are characteristic of the excitable region (precentral gyrus and paracentral lobule in man and anthropoid apes); these cells give origin to the fibres of

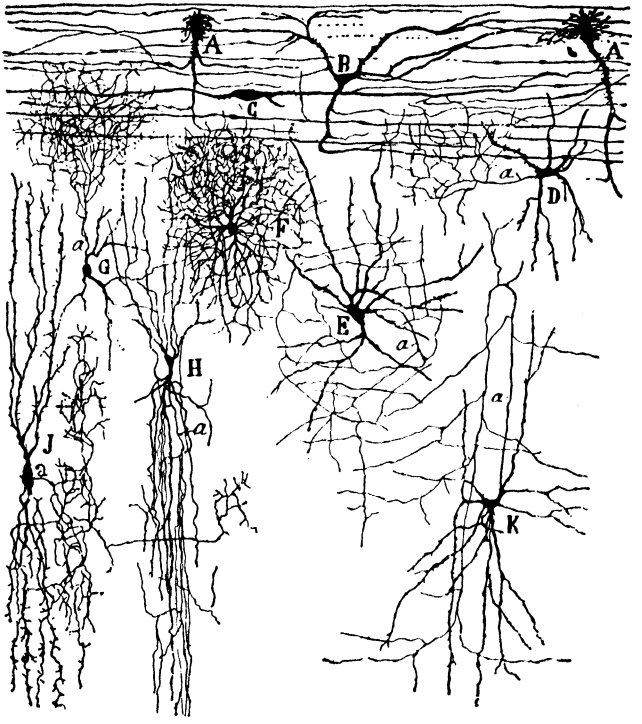

FIG. 684.—SUPERFICIAL LAYERS OF MOTOR CORTEX OF CHILD: GOLGI METHOD. (Cajal.)
A, B, C, cells of Cajal in plexiform layer; D to K, cells of type II of Golgi (with axons (*a*) ramifying near cell-body); H, J, 'double-brush' types of cell.

the pyramid-tract, and undergo Nissl degeneration when those fibres are severed (Page May). The occipital region (in man, the neighbourhood of the calcarine fissure) is especially characterised by containing a great number of the small stellate cells and by the presence in the layer superficial to these of a stratum of very large stellate cells with long spreading dendrons: amongst these small and large stellate cells the optic fibres from the lateral geniculate bodies ramify. A preponderance of small stellate cells is also seen, but to a less extent, in sections of the temporal lobe. In the prefrontal and parietal regions they are less numerous, and least in the motor cortex. The first temporal gyrus is characterised by the presence in nearly all the layers, but especially the deepest, of special large cells with widely spreading dendrons and an axon passing towards the white substance but

giving off many collaterals in the grey matter. There are also in this gyrus very many cells, with their axons ramifying in a most complex manner near the cell-body, mainly in a plane vertical to the surface. The hippocampal gyrus has groups or islets of stellate cells (groups of small cells alternating with groups of larger) in the plexiform layer. The cortex of the insula has special cells similar to those in the first temporal gyrus, and is further characterised by the peculiar spindle-shape of many of the large pyramids.

The size and number of the myelinate fibres of the grey matter vary in different regions. In some they are large and numerous (precentral part of frontal lobe, calcarine area, hippocampal area), in others fine and much less conspicuous (gyrus fornicatus, temporal area, parietal area, prefrontal area, insula and lobus pyriformis), while an intermediate condition presents itself in man in the occipital area (except the calcarine region), the transverse temporal gyri and superior temporal gyrus, and the part of the frontal lobe immediately in front of the excitable region. These differences have been employed by Campbell in an attempt to correlate the functions of the various cerebral regions by a comparison of their structure.

The **rhinencephalon** (olfactory region of the telencephalon)—on account of the peculiarities of its structure, its importance in most animals, and the fact that it has been the part of the telencephalon to appear first in phylogenetic development—merits a special description, although in man and Primates generally, and in some other (microsmatic) mammals, it is reduced to a comparatively rudimentary condition. In the so-called osmatic (macrosmatic) mammals the rhinencephalon consists of a large hollow *olfactory bulb*, the cavity of which communicates with the lateral ventricle. It forms the anterior termination of a thick *olfactory lobe* which broadens out behind and becomes continuous with the *hippocampal gyrus* and *hippocampus*. The whole forms a pyriform mass, separated from the rest of the cortex by a well-marked fissure—the *limbic fissure*—and has special connexions through the anterior commissure and fornix with other parts of the brain on the same and on the opposite side.

In man the rhinencephalon consists anteriorly of the small *olfactory bulb* from which the thin *olfactory tract* extends backwards to the grey matter at the base of the brain and to the hippocampal region. Posteriorly the cortex of the rhinencephalon is doubled in so as to form a projection (*hippocampus major*) in the descending cornu of the lateral ventricle: its edge here thins off and is continued merely as a thin layer of epithelium covering the choroid plexus of the pia mater, which is invaginated into the ventricle. At this thin edge the white matter comes to the surface as the *fimbria* which is continued on each side into the commissural band known as the *fornix*. Lying along the fimbria is the small and half-concealed *dentate gyrus*, which is formed by the sharp bending of the grey matter, and is traceable round into the hippocampus major, the hippocampal fissure being between them: the hippocampus major is continuous externally with the *gyrus hippocampi*. The olfactory tract is connected directly with the hippocampal region by a lateral root, whilst a mesial root passes into the anterior commissure and

forms a connexion with the rhinencephalon of the opposite side. The structure and connexions of all these parts as they occur in man may be briefly given.

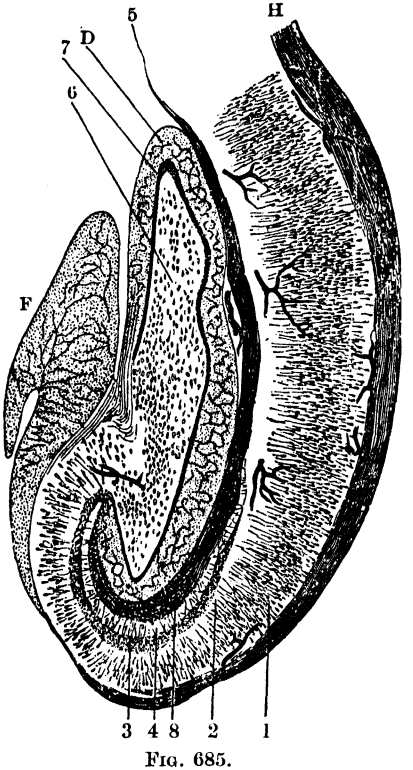

FIG. 685.

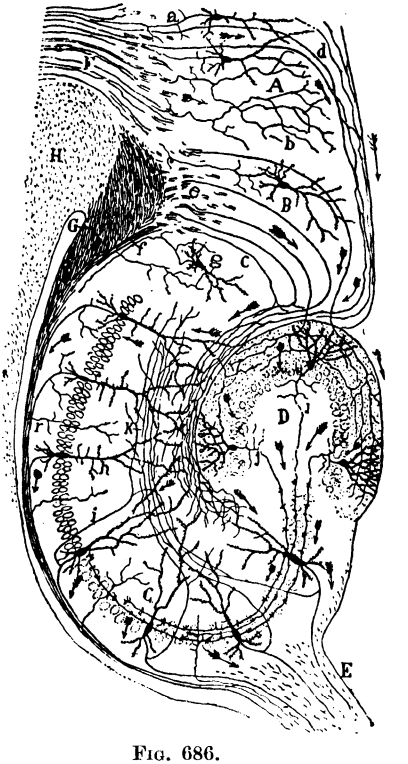

FIG. 686.

FIG. 685.—SECTION ACROSS THE HIPPOCAMPUS MAJOR, DENTATE FISSURE, DENTATE FASCIA AND FIMBRIA. (W. Krause.)

D, fascia dentata, or dentate convolution; F, fimbria, composed of longitudinal fibres here cut across; H, medullary centre of the hippocampal gyrus prolonged around the hippocampus, as the so-called alveus, into the fimbria; 1, layer of large pyramidal cells; 2, their processes (stratum radiatum); 3, stratum granulosum; 4, plexiform layer (stratum laciniosum); 5, superficial white layer; 6, nerve-cells of fascia dentata; 7, stratum granulosum of fascia dentata; 8, termination of superficial white layer, its fibres becoming longitudinal.

FIG. 686.—HIPPOCAMPAL REGION: GOLGI METHOD. (R. y Cajal.)

A, B, hippocampal gyrus; C, hippocampus major; D, dentate gyrus; E, fimbria; F, white matter of hippocampal gyrus; G, in lateral ventricle; the line points to the crossed spheno-hippocampal bundle; H, fibres of corpus callosum.

a, efferent fibres of hippocampal gyrus; b, afferent fibres of hippocampal gyrus; c, afferent fibres of hippocampus and dentate gyrus; d, others perforating grey matter of hippocampal gyrus; e, others cut obliquely; f, fibres of alveus; g, h, cells of hippocampus major sending their axons into the alveus and towards the fimbria; i, k, collaterals from these axons passing to the molecular layer; r, collateral fibres of alveus. The arrows indicate the probable course of the nerve impulses.

In the region of the hippocampus major (figs. 685, 686) the cortex is simpler in structure than elsewhere, and in the hippocampus major itself, which is an infolded part of the cortex, the pyramids are reduced to a single layer of large cells lying in the deeper portion and sending their apical dendronsas long fibres towards the plexiform layer. The plexiform layer and

the superficial white stratum overlying it are both very strongly marked, the plexiform layer having a distinctly reticular aspect, due partly to neuroglia-cells, partly to the arborescence of the dendrons of the pyramids. The plexiform layer is termed *stratum laciniosum*; internal to it nearer the dentate gyrus is a layer of closely packed small cells termed *stratum granulosum*. The pyramidal cells lie close to a white layer known as the *alveus*. This is the part of the hippocampus seen within the ventricle, and represents the white matter of the hemisphere, here greatly attenuated. The alveus is prolonged externally into the fimbria, in which its fibres become longitudinal in direction and are continued into part of the fornix.

In the dentate gyrus (*fascia dentata*, figs. 685, 686) the pyramidal cells (fig. 685, 6) are arranged in an irregularly radiating manner. They occupy the centre of the convolution, and are surrounded by a ring of closely packed small cells (*stratum granulosum* of fascia dentata, fig. 685, 7). External to these small cells is a thick plexiform layer (*stratum laciniosum*).

Del Rio-Hortega finds that many of the cells of the fascia dentata are peculiar in having numerous short feather-like secondary dendrons, coming off laterally from the primary dendrons and in some cases from the cell-body.

The anterior part of the hippocampal gyrus, known as the lobus pyriformis, receives the lateral root of the olfactory tract. It is characterised by the presence in the plexiform layer of peculiar nests of nerve-cells. The cells in these nests are of two types, viz. large polymorphous cells and small pyramidal cells, each being confined to its own nest. This part of the cortex is regarded by Cajal as the true olfactory region. In some animals the anterior perforated space forms a distinct prominence of the cortex (tuberculum olfactorium) and this is also characterised by cell-nests (*islets of Calleja*). They also occur in the cortex bounding the hippocampal fissure.

The **olfactory tract** is an outgrowth of the brain which was originally hollow, and remains so in many animals; but in man the cavity has become obliterated, and the centre is occupied by neuroglia, containing no nerve-cells. Outside the central neuroglia lies the white or medullary substance, consisting of bundles of longitudinal white fibres. Most external is a thin superficial layer of neuroglia.

The **olfactory bulb** (fig. 687) has a more complicated structure than the tract. Dorsally there is a flattened ring of longitudinal white bundles enclosing neuroglia (1, 2, 3), as in the olfactory tract, but below this ring several layers are recognised as follows:—

1. A *white or medullary layer* (fig. 687, 4, 5), characterised by the presence of a larger number of small cells ('granules') with reticulating bundles of myelinate nerve-fibres running longitudinally between them.

2. A *layer of large nerve-cells* (fig. 687, 6), with smaller ones ('granules') intermingled, the whole embedded in an interlacement of fibrils derived from the cell-dendrons. From the shape of most of the large cells of this layer (fig. 688, *m.c.*) it has been termed the 'mitral' layer. These cells send their axons upwards into the next layer; they eventually become fibres of the olfactory tract and pass along this to the base of the brain, giving off numerous collaterals into the bulb as they run backwards.

3. The *layer of olfactory glomeruli* (fig. 687, 7; fig. 688, *gl.*). This consists of rounded nest-like interlacements of fibrils which are derived on the one hand from the terminal arborisations of the amyelinate olfactory fibres which form the subjacent layer, and on the other hand from arborisations of dendrons of the large 'mitral' cells of the layer above. There are also a few small nerve-cells immediately external to and extending within the glomeruli (periglomerular cells). These are short-axoned cells and appear to connect neighbouring glomeruli.

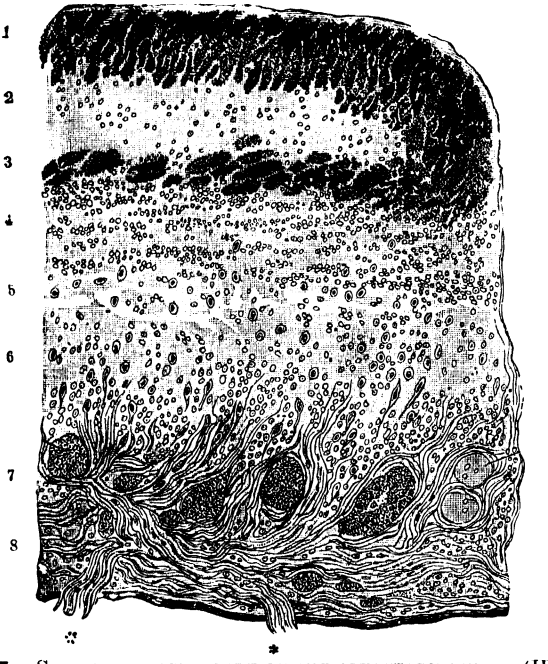

FIG. 687.—SECTION ACROSS A PART OF THE OLFACTORY BULB. (Henle.)

1, 3, bundles of very fine transversely cut nerve-fibres, forming the flattened medullary ring, enclosing the central neuroglia, 2: this ring is the anterior continuation of the olfactory tract; 4, 5, white layer with numerous small cells (granules); 6, mitral-cell layer; 7, layer of olfactory glomeruli; 8, layer of olfactory nerve-fibres, bundles of which are seen at * passing through the cribriform plate of the ethmoid bone.

The *layer of olfactory nerve-fibres* (fig. 687, 8; fig. 688, *olf.n.*). These are all amyelinate, and are continued from the olfactory fibres of the olfactory mucous membrane of the nasal fossæ. In this mucous membrane they take origin from the bipolar olfactory cells, which are characteristic of the membrane (see Lesson XLIX., p. 573, fig. 735), and they end in arborisations within the olfactory glomeruli, where they come in contact with the arborisations of the mitral cells. The relations of the olfactory cells and fibres to the mitral cells, and the continuation of the axis-cylinders of the latter upwards and backwards in the olfactory tract, are shown in the accompanying diagrams (figs. 688, 689). Besides the centripetal nerve-fibres there is a certain number of centrifugal fibres which end by ramifying in the olfactory bulb amongst the mitral cells (fig. 688, *n*).

As shown in fig. 689, many of the fibres of the olfactory tract pass to the hippocampal region of the brain, terminating by arborescence in the grey

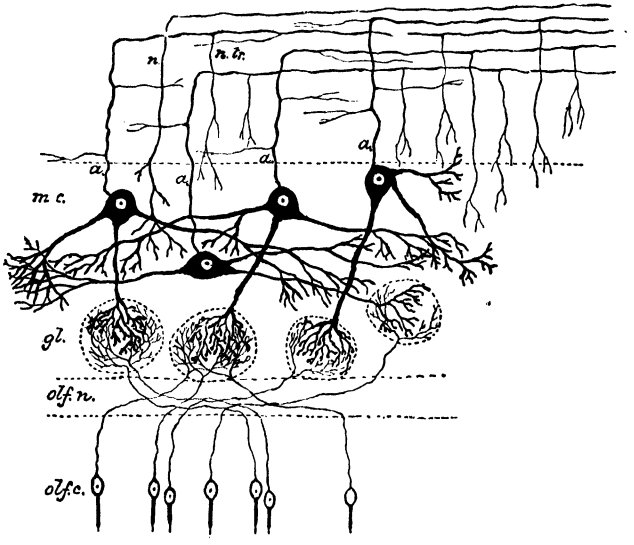

FIG. 688.—DIAGRAM TO SHOW THE RELATIONS OF CELLS AND FIBRES IN THE OLFACTORY BULB. (E. Sharpey-Schafer.)

olf.c., olfactory cells in the olfactory mucous membrane, sending their basal processes as (amyelinate) nerve-fibres into the deepest layer of the olfactory bulb (*olf.n.*); *gl.*, olfactory glomeruli with synapses between the terminal arborisations of the olfactory fibres and of dendritic processes from the mitral cells; *mc.*, mitral cells, sending dendritic processes down to the olfactory glomeruli, others laterally to end in free ramifications in the nerve-cell layer, and their axis-cylinder processes, *a*, *a*, upwards, to turn sharply backwards and become fibres of the olfactory tract (*a.tr.*). Numerous collaterals are seen coming off from these fibres; *n*, a nerve-fibre of the olfactory tract ending in a free ramification in the olfactory bulb.

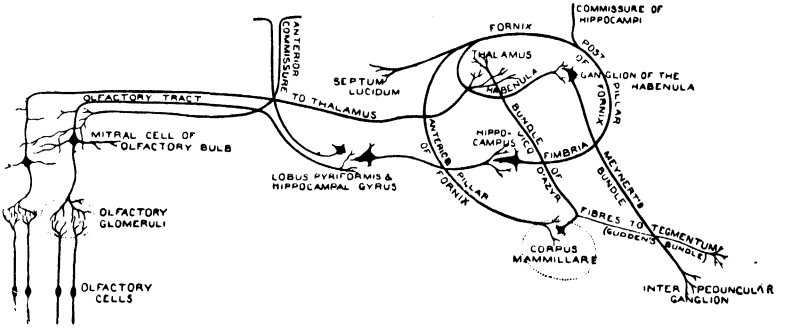

FIG. 689.—DIAGRAM OF THE OLFACTORY PATH IN THE BRAIN. (E. Sharpey-Schafer.) To simplify the diagram the various divarications of the olfactory path have been represented by branchings of individual fibres, although in some cases the divergence is brought about by the turning aside of bundles of entire fibres.

matter (molecular layer) of the base of the olfactory lobe in the region of the anterior perforated space, as well as in that of the uncus and the hippocampal gyrus. Fibres are also given off from the olfactory tract to the

anterior commissure which proceed to the opposite tract and bulb. Besides these the anterior commissure contains many fibres which are passing from the hippocampal region on one side to the corresponding region on the opposite side of the brain. From the pyramid-cells of the base of the olfactory lobe and hippocampal gyrus fibres pass to the grey matter of the hippocampus, and from the pyramid-cells of the hippocampus others proceed by way of the fimbria and fornix to the hippocampus of the other side, to the subcallosal gyrus and septum lucidum, to the ganglion of the habenula, and finally by the anterior pillar of the fornix to the corpora mammillaria.

CORPUS STRIATUM.

Besides the grey matter of the cerebral cortex the cerebral hemispheres conceal in their deeper parts certain other masses of grey substance (figs. 664, 665). The principal of these are the *corpus striatum*, consisting of *nucleus caudatus* (*n.c.*), and *nucleus lenticularis* (*n.l.*) and the *thalamus* (*th.*). Between them run the bundles of white fibres which are passing downwards to the crus cerebri, forming a white lamina termed the *internal capsule* (*i.c.*). Above the level of these nuclei the internal capsule expands into the medullary centre of the hemisphere. Below the thalami are the prominent ganglia known as *corpora albicantia* or *mammillaria*. Of these the optic thalami and corpora mammillaria have already been noticed.

The **nucleus caudatus** of the corpus striatum is composed of a reddish-grey substance containing nerve-cells, some with long others with short axon-processes, some of the cells with long processes being very large. It receives fibres from the part of the internal capsule which separates it from the nucleus lenticularis. Next to the lateral ventricle it is covered by a thin layer of neuroglia, and over this by the epithelium of the cavity (ependyma).

The **nucleus lenticularis,** which corresponds in position internally with the island of Reil externally, is divided by two white laminæ into three zones. It is separated from the nucleus caudatus and optic thalamus by the internal capsule, which consists of the bundles of fibres which are passing between the white centre of the hemisphere and the crus cerebri. Many of the nerve-cells of the nucleus lenticularis contain yellow pigment. No fibres have been found connecting the cerebral cortex to the corpus striatum, the nuclei of which are linked to one another by fine fibres traversing the internal capsule. The only fibres passing out of the corpus striatum are the fibres of the *ansa lenticularis* which arise from the *globus pallidus* and pass to the sub-thalamic region (p. 518).

The **internal capsule** is continued below into the *crusta*. It consists mainly of fibres connected with the cortex cerebri, and passing to (or from) the thalamus, mid-brain, pons, medulla oblongata, and spinal cord. A horizontal section across the internal capsule (fig. 665) shows it to be bounded laterally by the lenticular nucleus, mesially by the caudate nucleus, the stria medullaris, and the thalamus. Such a section shows a sharp bend in the plane of the capsule—the genu. Fibres from the motor

region of the cortex (pyramid-tract) pass down in the part of the capsule extending from the genu as far as the posterior limit of the lenticular nucleus. In this area the fibres for the head and eyes are massed chiefly in the anterior part: those for the lower limb in the posterior part, while those for the face, arm, and trunk occupy intermediate positions from before backwards, in the order named (Beevor and Horsley), but without being strictly confined to definite zones.

The fibres from the cortex to the thalamus lie mainly in the anterior limb of the internal capsule, while afferent fibres from the thalamus to the cortex occur in the posterior part of the posterior limb; but they extend forwards so as to mingle with the descending fibres of the pyramid-tract.

MEMBRANES OF THE BRAIN.

The membranes of the brain (fig. 690) are similar in general structure and arrangement to those of the spinal cord with which they are continuous through the occipital foramen. The dura mater is, however, more closely

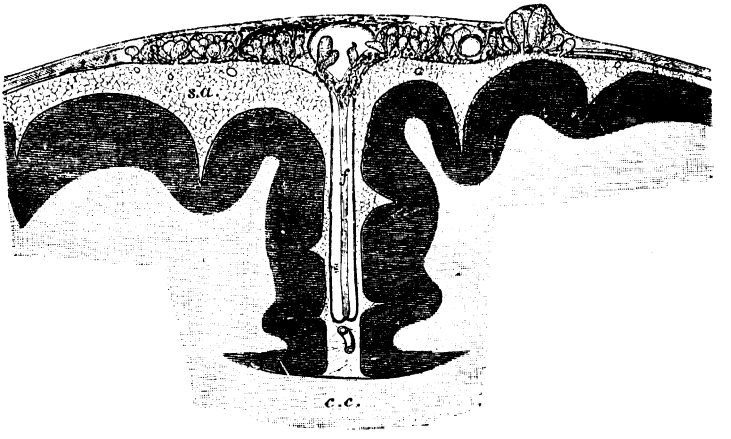

FIG. 690.—SECTION THROUGH THE UPPER PART OF THE BRAIN, TO SHOW THE RELATIONS OF ITS MEMBRANES. (Axel Key and Gustaf Retzius.)

c.c., corpus callosum; *f*, great longitudinal fissure between the hemispheres containing the projection of dura mater known as the falx cerebri; *s.a.*, subarachnoid space between pia mater which closely covers the surface of the brain and dura mater which lines the skull. The arachnoid is in this part close to the dura mater into which and into the great longitudinal venous sinus in the middle it sends villous projections (Pacchionian glands).

adherent to the inner surface of the bony enclosure than is the case in the vertebral canal, while the arachnoid is in most places close to the dura mater, and separated from the pia mater by a wide subarachnoid space, which is bridged across by finely reticulating bands of the same tissue. Numerous small villous processes of the arachnoid penetrate into the venous sinuses and veins in the dura mater; they serve to drain the cerebro-spinal fluid into the venous system. Some of these arachnoid processes increase in size with age and become denser in structure; they may eventually even pass

beyond the dura and become embedded in the skull. They are there known as the *Pacchionian glands.*

The pia mater is closely adherent to the surface of the brain, and dips into all the sulci. In it the blood-vessels ramify before passing into the substance of the brain. They are accompanied, as they thus enter the

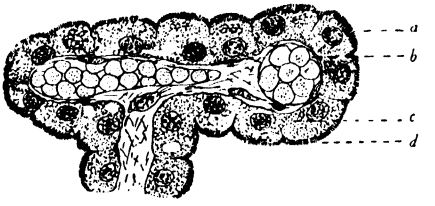

FIG. 691.—SECTION SHOWING STRUCTURE OF CHOROID PLEXUS: RABBIT. (W. J. Meek.) × 1000.

a, epithelium-cells, showing in each the nucleus and the Golgi apparatus; *b*, capillary, filled with blood-corpuscles; *c*, a fat-droplet; *d*, striated border of epithelium.

cerebral substance, by prolongations of the pia mater and arachnoid, which do not, however, closely invest them, but leave a clear space around each vessel, presumably for the passage of fluid (perivascular space). The capillary network is much closer in the grey than in the white matter. The large veins are contained within the dura mater, in which they run in certain parts in the form of sinuses; the chief of these are found at the lines of

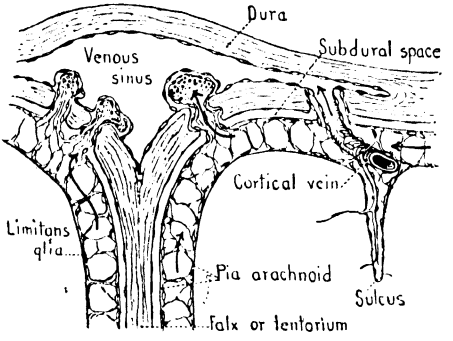

FIG. 692.—DIAGRAM TO SHOW THE PROBABLE COURSE OF CEREBRO-SPINAL FLUID FROM THE CORTEX TO THE VENOUS SINUSES OF THE DURA. (Harvey Cushing, modified from Weed.)

junction of the principal folds (falx, tentorium) with the main portion of the membrane.

The pia mater sends highly vascular infoldings into the ventricles known as the *choroid plexuses.* They are covered with cubical epithelium-cells (fig. 691), to which nerve-fibres have been traced (Stöhr).

The cerebro-spinal fluid, although often referred to as the lymph of the brain, differs from ordinary lymph in many respects. It contains only a minute amount of protein, consisting almost entirely of water and salts, with traces of nitrogenous

non-protein bodies and a small amount of a carbohydrate which reduces cuprous salts. The fluid is not a mere filtrate or dialysate from the blood but is mainly the secretion of the choroid plexuses. To this is added a watery fluid which enters it from the substance of the brain and cord along channels surrounding the blood-vessels as they emerge from the nervous substance to join the pia mater. This fluid is derived from the blood-vessels of the brain and cord and may be assumed to contain the waste products of metabolism of the nervous tissues. The cerebro-spinal fluid finds its way back into the blood, partly by absorption into the thin-walled veins of the pia mater, and partly into the venous sinuses of the brain through the arachnoidal villi, which act like valves in permitting a flow of fluid only in the direction of the sinuses. A flow of cerebro-spinal fluid is thus continually maintained, and follows a regular course which may properly be described as its ' circulation ' (fig. 692).

LESSONS XLVI., XLVII., AND XLVIII.

THE EYE.

1. CARE is needed in the preparation of sections of the whole globe. The organ may be fixed in 10 per cent. formol made with saline (0·6 per cent.). After twenty-four hours it is taken slowly through upgraded alcohols (twenty-four hours in each) to absolute alcohol. The celloidin method of embedding must be used.

2. Sections of the eyelid (fixed in susa) vertical to its surfaces and across its long axis.

Notice the long sacculated Meibomian glands lying in dense connective tissue close to the conjunctival surface, their ducts opening at the margin of the lid. External to these the small fibres of the orbicularis palpebrarum are cut across; a few of the fibres of the muscle lie on the conjunctival side of the duct. A short distance from the Meibomian gland may be observed a tolerably large sebaceous gland: outside this again are the eyelashes. In the skin covering the outer surface of the eyelid a few small hairs may be seen. At the attached part of the eyelid are some bundles of involuntary muscular fibres cut longitudinally in the section, and in the upper eyelid the fibrous insertion of the elevator muscle may be observed attached to the dense connective tissue.

Make a general sketch under a low power.

3. Sections through the posterior part of an eyeball (man or pig). These sections will show the relative thickness of the several coats and the layers of which each coat is formed. Sections which pass through the point of entrance of the optic nerve will exhibit the manner in which the nerve pierces the several coats to reach the inner surface of the retina. The modifications which are found in the neighbourhood of the yellow spot may be made out in sections of that region, but they must be from the human eye.

4. Sections of the anterior half of an eyeball. These sections should pass through the middle of the cornea. The lens may be left *in situ*, but this renders the preparation of the sections and the mounting of them difficult on account of the extreme hardness which is imparted to the lens-tissue by alcohol.

In these sections make a general sketch under a low power, showing the relations of the several parts one with another. Study carefully, and sketch in detail, the layers of the cornea, the junction of the cornea and sclerotic, the ciliary muscle, the muscular tissue of the iris, the mode of suspension of the lens, and the pars ciliaris retinæ.

5. Mount in glycerine thin tangential sections of a cornea stained with chloride of gold by Cohnheim's method; if from the frog, the cornea can be torn with fine forceps into thin lamellæ, which are mounted whole. Sketch three or four of the connective-tissue cells (corneal corpuscles). The arrangement and distribution of the nerve-fibres and their termination amongst the epithelium-cells, as shown in chloride of gold preparations, have been already studied (Lesson XIX.).

6. Mount in glycerine or, after dehydration and clearing, in dammar, sections of a cornea which has been stained with nitrate of silver. Notice the branched cell-spaces corresponding with the connective-tissue cells of the last preparation.

This silver-preparation is made by rubbing the surface of the cornea of a recently killed animal with lunar caustic, first scraping off the epithelium with a scalpel. After ten minutes (by which time the nitrate of silver will have penetrated the

thickness of the cornea) the eye is washed with distilled water, and exposed to the light. When brown, tangential sections may be made, for which purpose the stained cornea may either be hardened in alcohol or soaked with gum and cut frozen.

7. Remove the sclerotic from the anterior part of a human eye which has been preserved in Müller's fluid, and tear off thin shreds from the surface of the choroid, including among them portions of the ciliary muscle. Stain the shreds with hæmatoxylin and mount them in glycerine. Sketch the branched pigment-cells, the elastic network, the mode of attachment of the fibres of the ciliary muscle, etc.

8. Injected preparation of choroid and iris. Mount portions of the choroid coat and iris from an eye (preferably of an albino rabbit or rat), the blood-vessels of which have been injected. Make sketches showing the arrangement of the capillaries and veins.

9. Teased preparation of human retina. Break up with needles in a drop of glycerine a minute fragment of retina which has been placed in 1 per cent. osmic acid solution for some hours, and has subsequently been kept in dilute glycerine. Complete the separation of the retinal elements by tapping the cover-glass. Draw carefully under a high power some of the isolated elements—*e.g.* the rods and cones with their attached fibres and nuclei, the inner granules, the ganglion-cells, the fibres of Müller, hexagonal pigment-cells, etc. In some of the fragments the arrangement of the elements in the retinal layers may be made out even better than in actual sections. If fresh human retina from an eye removed in operation cannot be obtained, a pig's eye may be substituted.

Measure the length and diameter of some of the cones, the length of the cone-fibres and the diameter of some of the outer and inner nuclei.

10. Teased preparation of frog's retina. To be prepared in the same way as 9. Notice the very large rods, their outer segments breaking up into disks, and the relatively small cones. Also the pigment extending between the rods, the distance varying according as the eye has been kept in the dark or in the light before treatment with osmic acid.

A fresh frog-retina may also be teased in vitreous humour.

11. Sections of retina of ox or dog, prepared by Golgi's method. A curled-up piece of fresh retina is placed in osmium-bichromate mixture and is subsequently treated with nitrate of silver solution. (See Appendix. Cajal's reduced silver method may also be used.)

12. Teased preparation of lens. Separate in water the fibres of a crystalline lens which has been macerated for some days in 2 per cent. potassium bichromate. Sketch some of the fibres, together and separate.

THE EYELIDS AND LACRIMAL GLANDS.

The **eyelids** (fig. 693) are covered externally (anteriorly) by skin, and internally (posteriorly) by a mucous membrane, the *conjunctiva*, which is reflected from over the globe of the eye. They are composed in the main of connective tissue, which is dense and fibrous under the conjunctiva, where it forms what is known as the *tarsus*.

Embedded in the tarsus is a row of long sebaceous glands (the *Meibomian glands*, *e*), the ducts of which open at the edge of the eyelid. The rest of the thickness of the eyelid is composed of a somewhat loose connective tissue, which contains the bundles of the *orbicularis muscle* (*b*). In the upper eyelid the *levator palpebræ* is inserted into the tarsus by a fibrous expansion; some bundles of involuntary muscle are also present near the attachment of the eyelid. The skin has the usual structure; it includes small sweat glands and the follicles of small hairs, and, in addition, at the edge of the eyelid,

the large hair-follicles from which the eyelashes grow. The epithelium of the conjunctiva palpebræ is columnar, passing at the edge of the lid into the stratified epithelium of the skin; it also becomes stratified in the part

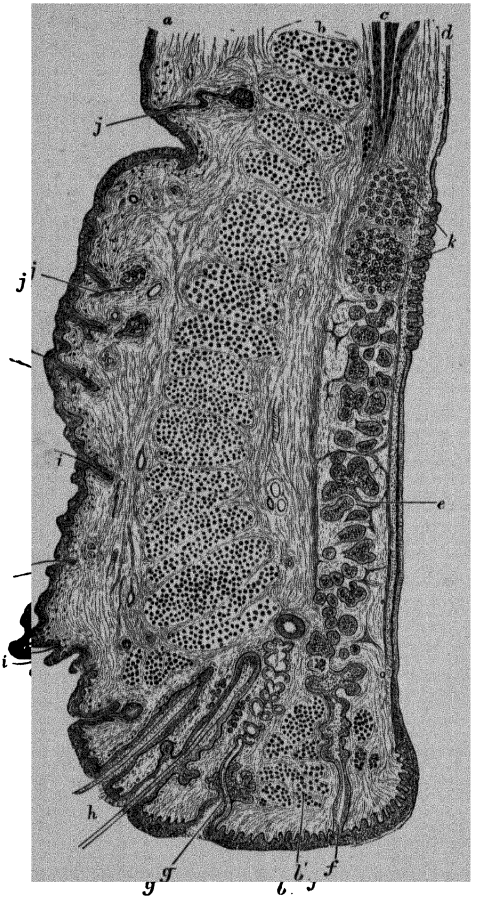

FIG. 693.—VERTICAL SECTION THROUGH THE UPPER EYELID. (Waldeyer.)

a, skin; *b*, orbicularis; *b'*, ciliary bundle; *c*, involuntary muscle of eyelid; *d*, conjunctiva; *e*, tarsus with Meibomian gland; *f*, duct of the gland; *g*, sebaceous gland near eyelashes; *h*, eyelashes; *i*, *i*, small hairs in outer skin; *j*, *j*, sweat glands; *k*, posterior tarsal glands.

terminate for the most part in end-bulbs, which in man are spheroidal, and formed chiefly of a small mass of polyhedral cells; but in the calf and most animals they are elliptical (see Lesson XIX.).

The **lacrimal glands.**—These are compound racemose glands situated at the outer upper angle of the orbit; they yield a watery secretion. Their alveoli are lined by columnar or polyhedral cells (fig. 694), which are normally filled with granules, but, after profuse secretion, these disappear, and the

cells become shorter and smaller. The ducts, of which there are several, open at the upper fold of the conjunctiva near its outer extremity.

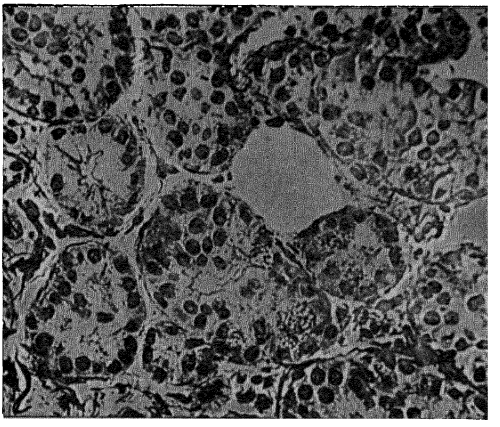

FIG. 694.—ALVEOLI OF LACRIMAL GLAND OF MAN. × 200. (E. Sharpey-Schafer.) Preparation by M. Heidenhain.

Some of the cells show secretion granules. In one or two situations the intercellular canaliculi which open into the lumen of the alveolus can be made out.

THE SCLEROTIC AND CORNEA.

The **globe of the eye** (fig. 695) is enclosed by three coats, the cornea-sclera, choroid-iris, and retina. It is filled by the vitreous and aqueous humours and the crystalline lens which lies between them.

The **sclerotic coat** (*sclera*) is composed of dense fibrous tissue, the bundles of which are intimately interlaced. It is thickest at the back of the eyeball. It is covered externally with a lymphatic endothelium, while internally it is lined by a layer of connective tissue containing pigment-cells, which give it a brown appearance (*lamina fusca*). At the entrance of the optic nerve the sclerotic is prolonged into the sheath of that nerve, the bundles of which, piercing the coat, give a sieve-like aspect to the part (*lamina cribrosa*).

The **cornea** (figs. 696, 697) consists of the following layers (enumerated from before back) :—

1. A *stratified epithelium* continuous with the epithelium of the conjunctiva.

2. A lamina of homogeneous connective tissue (*membrane of Bowman*), upon which the deepest cells of the epithelium rest.

3. A thick layer of fibrous connective tissue which forms the *proper substance* of the cornea. This is continuous laterally with the tissue of the sclerotic. It is composed of bundles of white fibres arranged in regular laminæ, the direction of the fibres crossing one another at right angles in the alternate laminæ. Between the laminæ lie flattened connective-tissue cells (fig. 698). These are branched and united by their processes into a

continuous network; there is, of course, a corresponding network of cell-spaces (fig. 699). In vertical sections the cells appear narrow and spindle-shaped. In the superficial laminæ near the margin there are a few bundles of fibres which run obliquely towards the surface (fig. 696, *a*).

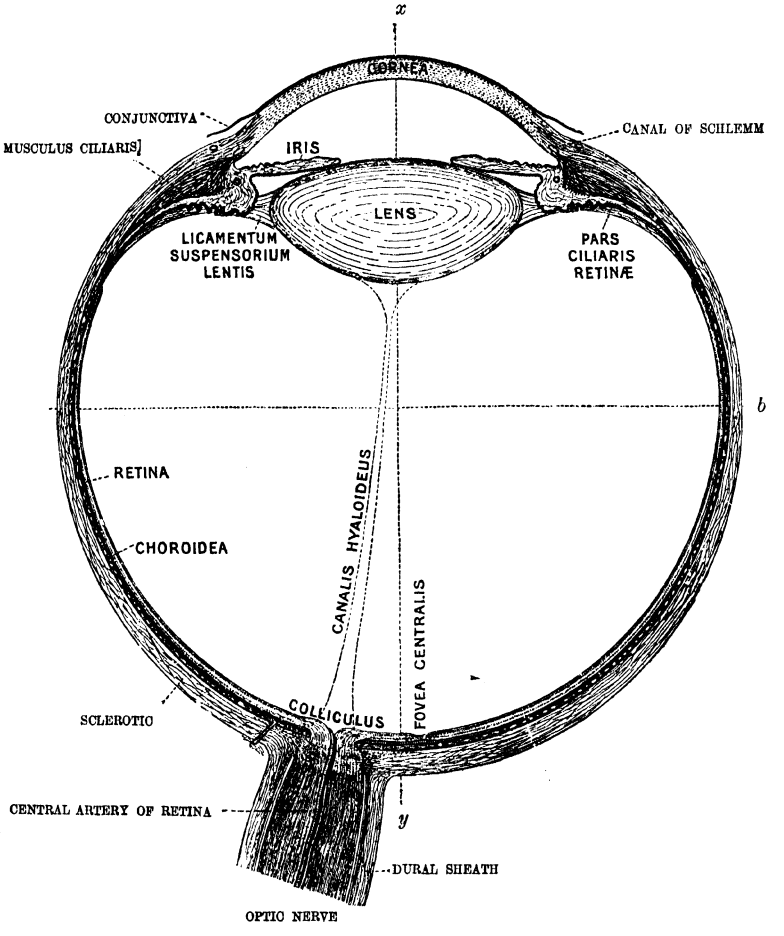

FIG. 695.—DIAGRAM OF A SECTION THROUGH THE (RIGHT) HUMAN EYE PASSING HORIZONTALLY NEARLY THROUGH THE MIDDLE. (E. Sharpey-Schafer.) × about 4.

a, *b*, equator; *x*, *y*, optic axis.

4. A homogeneous elastic layer (*membrane of Descemet*). This completely covers the back of the cornea, but near the angle which the cornea forms with the iris it breaks up into separate fibres (*ligamentum pectinatum*) which are partly continued into the iris as the *pillars of the iris*.

5. A layer of pavement-epithelium (*endothelium of Descemet's membrane*) covering the posterior surface of the elastic lamina, and lining the front of

the anterior chamber of the eye (fig. 696, 5). At the sides it is continued over the ligamentum pectinatum into a similar endothelium covering the

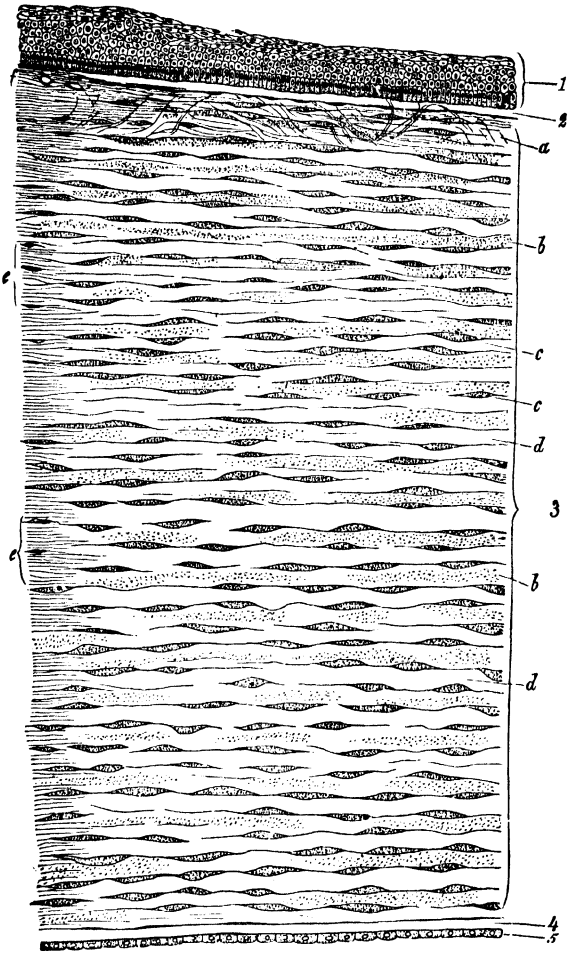

FIG. 696.—VERTICAL SECTION OF HUMAN CORNEA FROM NEAR THE MARGIN. (Waldeyer.) Magnified.

1, epithelium; *2*, anterior homogeneous lamina; *3*, substantia propria corneæ; *4*, posterior homogeneous (elastic) lamina; *5*, endothelium of the anterior chamber; *a*, oblique fibres in the anterior layer of the substantia propria; *b*, lamellæ with their fibres cut across, producing a dotted appearance; *c*, corneal corpuscles appearing fusiform in section; *d*, lamellæ with their fibres cut longitudinally; *e*, transition to the sclerotic, with more distinct fibrillation, and surmounted by a thicker epithelium; *f*, small blood-vessels cut across near the margin of the cornea.

anterior surface of the iris. The cells of the endothelium of Descemet's membrane are separated from one another by intercellular spaces which with suitable treatment may be seen to be bridged across by bundles of fibrils which pass through the cells (fig. 700).

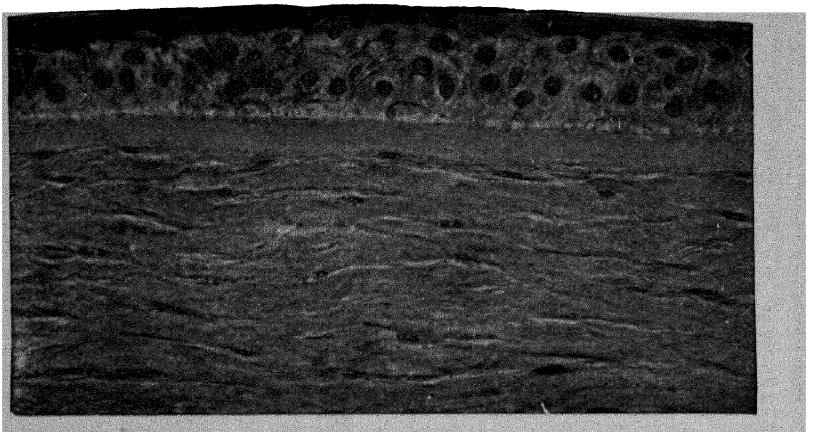

FIG. 697.—SECTION OF HUMAN CORNEA, SHOWING THE STRATIFIED EPITHELIUM, THE MEMBRANE OF BOWMAN, AND THE SUPERFICIAL LAYERS OF THE PROPRIA. (E. Sharpey-Schafer.) Photograph.

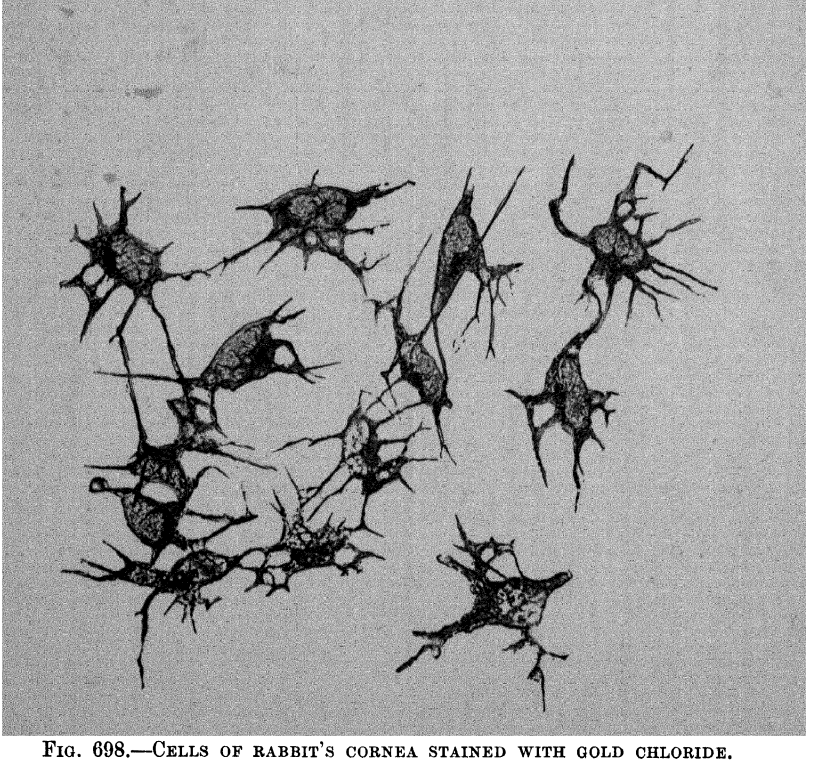

FIG. 698.—CELLS OF RABBIT'S CORNEA STAINED WITH GOLD CHLORIDE. (E. Sharpey-Schafer.) × 300. Photograph.

The nerves of the cornea pass in from the periphery, losing their myelin sheath as they enter the corneal substance. They form a primary plexus in the substantia propria, a secondary or subepithelial plexus immediately

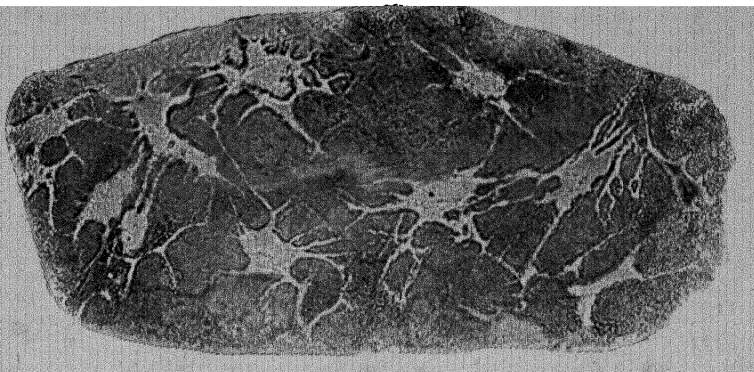

FIG. 699.—CELL-SPACES OF RABBIT'S CORNEA TREATED WITH SILVER NITRATE. (E. Sharpey-Schafer.) × 300. Photograph. Preparation by H. Pringle.

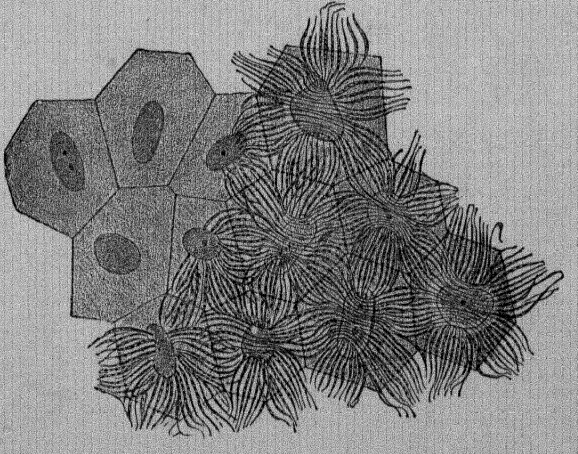

FIG. 700.—EPITHELIUM-CELLS OF DESCEMET'S MEMBRANE. (Smirnow.)

under the epithelium which covers the anterior surface, and a terminal plexus of fine fibrils which pass from the subepithelial plexus in pencil-like tufts and become lost between the epithelium-cells (fig. 701). In some animals (*e.g.* frog) there is also a plexus of fine fibrils near the posterior surface under the endothelium of Descemet's membrane (fig. 702). There are no blood-vessels or lymphatics in the cornea, although they come close up to its margin.

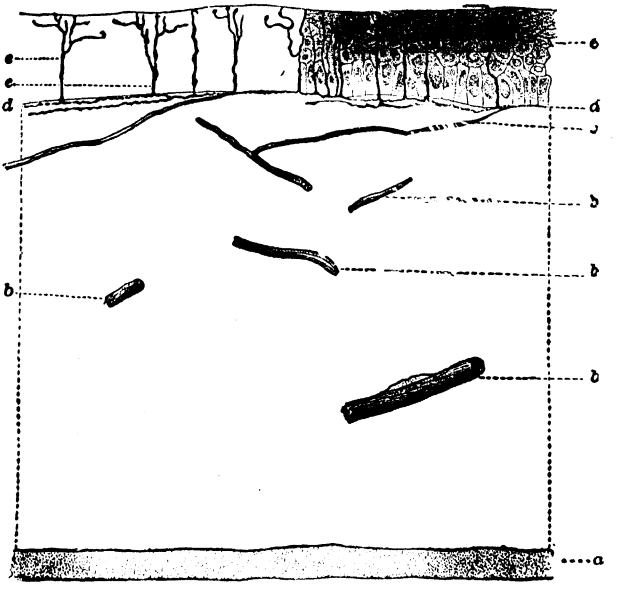

FIG. 701.—VERTICAL SECTION THROUGH THE CORNEA. (Cohnheim.)

The corneal corpuscles and the cells of Descemet's membrane are not represented; the anterior epithelium is represented only in part. *a*, Descemet's membrane; *b*, part of nerve plexus in substantia propria; *c*, branches going to the epithelium; *d*, fibres of the subepithelial layer; *e*, vertical fibrils with horizontal outrunners.

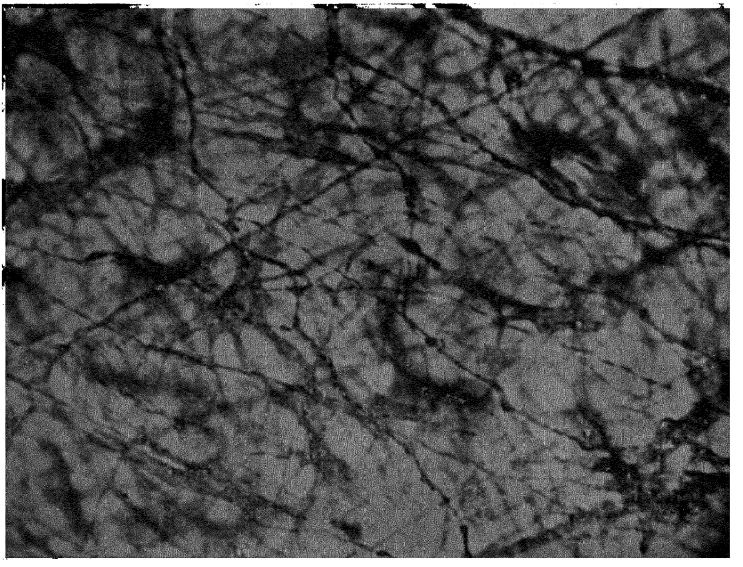

FIG. 702.—NERVE-FIBRILS NEAR POSTERIOR SURFACE OF FROG'S CORNEA. (E. Sharpey-Schafer.) Photograph. Gold preparation.

THE CHOROID AND IRIS.

The **choroid** or **vascular coat** of the eye is of a black colour in many animals, but in the human eye it is brown. It is composed of connective tissue, the cells of which are large and filled with pigment (fig. 703). It contains in its inner layer a close network of blood-vessels, and in its anterior part the involuntary muscular fibres of the ciliary muscle, which pass backwards from their origin at the junction of the cornea and sclerotic, to be inserted into the choroid. The choroid is separable into the following layers (enumerated from without in) :—

1. The *lamina supra-choroidea* (fig. 703, *l.s.*). This is a loose membrane composed of delicate connective tissue pervaded by a network of fine elastic

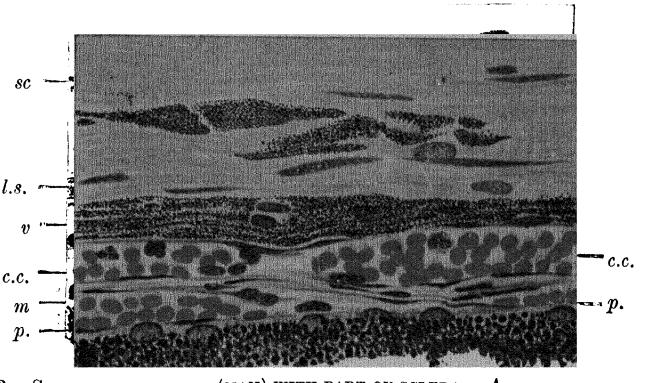

FIG. 703.—SECTION OF CHOROID (MAN) WITH PART OF SCLERA. ATTACHED TO THE INNER SURFACE OF THE CHOROID IS A PORTION OF THE RETINAL PIGMENT. (E. Sharpey-Schafer.) × 200.

sc, lamina fusca of sclera ; *l.s.*, lamina suprachoroidea ; *v*, larger blood-vessels of choroid ; *c.c.*, chorio-capillaris ; *m*, basement membrane (membrane of Bruch) ; *p*, portions of retinal pigment-cells.

fibres, and containing many large branched pigment-cells and lymph-corpuscles (fig. 114, p. 99). It is covered superficially by a lymphatic endothelium, and is separated from the lamina fusca of the sclerotic by a cleft-like lymph-space which is bridged across here and there by nerves, and by bands of connective tissue.

2. The *vascular layer* of the choroid (fig. 703, *v* and *c.c.*) resembles the suprachoroidea in structure, but contains the blood-vessels of the coat. In its outer part are the larger vessels (arteries and veins), the veins having a peculiar vorticose arrangement ; in its inner part (chorio-capillaris) are the capillaries, which form an extremely close network with elongated meshes, the capillaries radiating from the extremities of the small arteries and veins in a highly characteristic manner (fig. 704). In the ciliary processes the vessels have for the most part a longitudinal direction, but there are numerous convoluted transversely disposed capillaries uniting the longitudinal vessels (fig. 711, *d*).

3. Lining the inner surface of the choroid is a thin transparent membrane known as the *membrane of Bruch* (fig. 703, *m*).



FIG. 704.—INJECTED BLOOD-VESSELS OF THE CHOROID COAT. (Sappey.)
1, one of the larger veins; 2, 2, small anastomosing vessels; 3, 3, branches connected with capillary network.

The sclera, lamina suprachoroidea and vascular layer of the choroid bear the same relation to the retina—which is developed as a hollow outgrowth of the

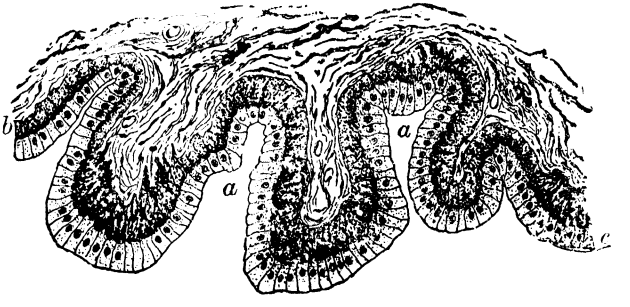

FIG. 705.—SECTION ACROSS THE POSTERIOR PART OF THREE CILIARY PROCESSES. (Piersol.)
× 155.

a, *a*, recesses between the ciliary processes; *b*, the deeper (pigmented) layer of epithelium; *c*, the superficial layer of non-pigmented columnar cells. These two layers of epithelium form what is termed the pars ciliaris retinæ.

primitive brain—that the dura mater, arachnoid, and pia mater bear to the brain itself.

Ciliary processes.—Anteriorly the choroid coat becomes thickened, partly by the appearance of radially arranged pleats or ridges (ciliary processes with intervening grooves), partly by the development of a ring of muscle

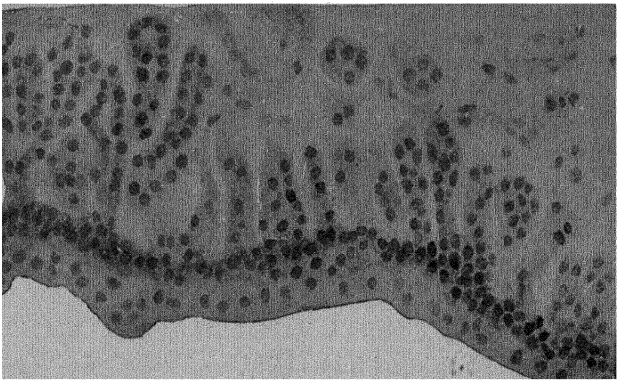

FIG. 706.—GLANDS OF THE CILIARY PROCESSES AS SEEN AFTER BLEACHING THE PIGMENT COVERING THEM. (E. Treacher Collins.)

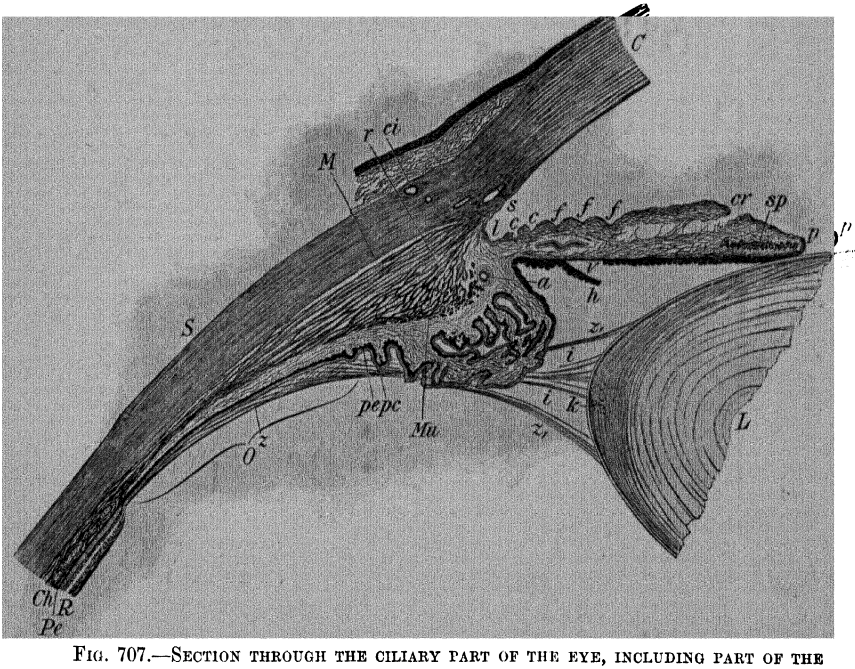

FIG. 707.—SECTION THROUGH THE CILIARY PART OF THE EYE, INCLUDING PART OF THE CORNEA, THE ORA SERRATA, THE IRIS AND THE EDGE OF THE LENS WITH ITS SUSPENSORY LIGAMENT. (Fuchs.)

C, cornea; *S*, sclerotic; *Ch.* choroid; *R*, retina; *Pe*, its pigmented epithelium; *O*, pars ciliaris: this is continued over the choroid processes; *pe*, *pc*, pigmented and non-pigmented layers of pars ciliaris; *L*, lens; *M*, ciliary muscle; *r*, its radiating (meridional) fibres passing from their origin at the corneo-sclerotic junction; *Mu*, circular ciliary muscle; *ci*, artery of sclerotic; *s*, vein (canal of Schlemm); *z*, fibres of zonula of Zinn passing between choroid processes into the suspensory ligament of the lens (z_1); *l*, angle of anterior chamber; *sp*, sphincter pupillæ; *p*, edge of pupil; *h*, pigmented epithelium of iris (accidentally detached at this point and showing, *v*, layer of dilatator pupillæ); *c*, *c*, *f*, *f*, creases and folds of anterior surface of iris; *cr*, a fissure in this surface (accidental); *a*, artery at insertion of iris; *k*, capsule of lens; *i*, *i*, fibres of suspensory ligament inserted into it at the equator.



FIG. 708.—SEGMENT OF THE IRIS, SEEN FROM THE POSTERIOR SURFACE AFTER REMOVAL OF THE UVEAL PIGMENT. (Iwanoff.)

a, sphincter muscle; *b*, dilatator muscle of the pupil.

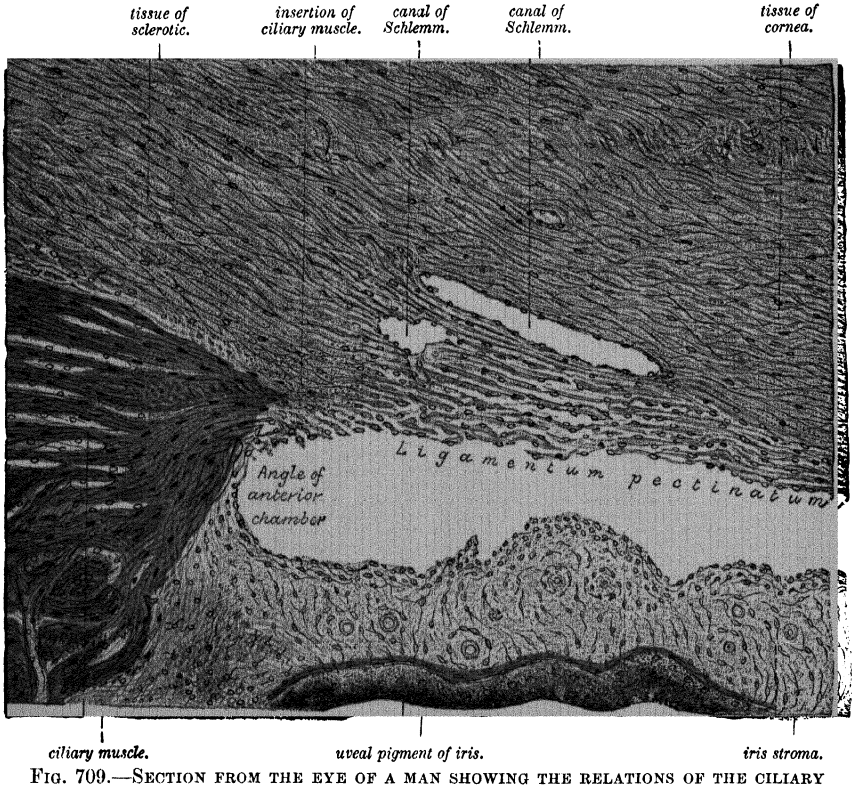

FIG. 709.—SECTION FROM THE EYE OF A MAN SHOWING THE RELATIONS OF THE CILIARY MUSCLE TO THE SCLEROTIC, THE IRIS, AND THE CAVERNOUS SPACES NEAR THE ANGLE OF THE ANTERIOR CHAMBER. (E. Sharpey-Schafer.)

The figure, which is from a photograph, includes a small portion of the ciliary muscle, the fibres of which are seen to be converging to a point immediately anterior to the angle of the anterior chamber. Here they are attached through the medium of a band of the fibrous tissue of the sclerotic (consisting mainly of circular bundles) to the outer part of the ligamentum pectinatum, which forms a loose tissue with open meshes lying between the canal of Schlemm and the anterior chamber. In the right half of the figure the fibres of the ligamentum pectinatum are seen to be gradually converging towards the posterior surface of the cornea, and somewhat beyond the part shown in this figure they merge into the membrane of Descemet. A communication of the canal of Schlemm, which is double in this section, with the endothelium-lined spaces of the ligamentum pectinatum, is apparent, and also communications between the last-named spaces and the anterior chamber.

(ciliary muscle) which encircles the globe at this part, lying between the sclera and choroid. The ciliary processes are formed like the rest of the choroid of highly vascular pigmented connective tissue, but, in place of retina, they are covered internally by two layers of epithelium, the outer layer being thickly pigmented (fig. 705). In the middle and anterior parts the epithelium dips down into the connective-tissue corium in the form of glandular tubes, which in all probability assist in the secretion of the aqueous humour. In order to bring these *ciliary glands* distinctly into view, it is necessary to bleach the pigment (fig. 706).

The **ciliary muscle** consists of involuntary muscular bundles which arise at the corneo-sclerotic junction, and pass meridionally backwards to be inserted in the choroid (fig. 707, *M*). Many of the deeper-seated bundles

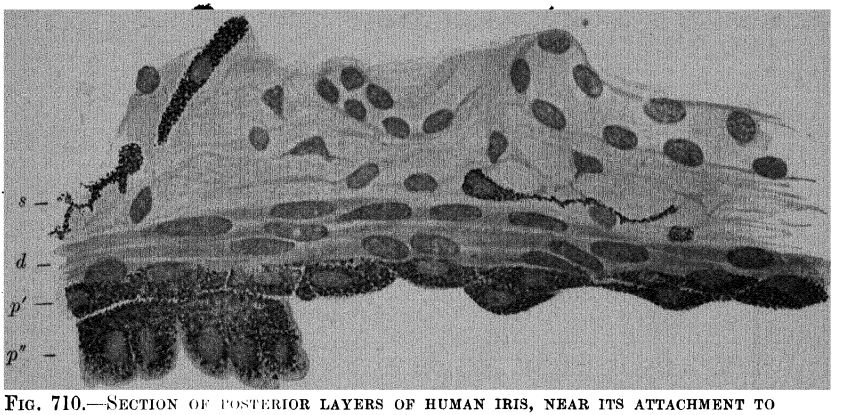

FIG. 710.—SECTION OF POSTERIOR LAYERS OF HUMAN IRIS, NEAR ITS ATTACHMENT TO THE CHOROID. (E. Sharpey-Schafer.) × 600.

s, iris stroma, with connective tissue, branched pigment-cells, and blood-vessels; *d*, dilatator pupillæ; *p′*, deeper layer of uveal pigment; *p″*, superficial layer of uveal pigment; this layer is broken away from the larger part of the section.

take an oblique direction, and these pass gradually into others which run around the circumference of the iris, on a level with the ciliary processes. This set of circularly arranged bundles constitutes the *circular ciliary muscle* of H. Müller (*Mu*); it is most marked in hypermetropic eyes.

The **iris.**—The iris is that part of the vascular coat of the eye which extends in front of the lens. It is continuous with the choroid and has a somewhat similar structure, but its pigment-cells often contain variously coloured pigment. Besides the delicate connective tissue with numerous elastic fibres and blood-vessels of which it is chiefly composed, it contains two sets of plain muscular fibres. The one set forms the *sphincter pupillæ* (figs. 707, *sp.*; 708, *a*), which encircles the pupil; the other set consists of a flattened layer of radiating fibres which extend from the attachment of the iris nearly to the pupil, lying close to the posterior surface and constituting the *dilatator pupillæ* (figs. 708, *b*; 709 and 710).

The muscular tissue of the iris is developed from the epithelium at the back of the iris.

The back of the iris is covered by a thick double layer of pigmented epithelium (*uvea*) (fig. 710) continuous with the epithelium of the pars ciliaris retinæ.

The blood-vessels of the iris (fig. 711, *e*) converge towards the pupil. Near the pupil the small arteries form an anastomotic circle, from which capillaries arise and pass still nearer the pupil, around which they form a close capillary network.

A large number of nerve-fibres are distributed to the choroid and iris,

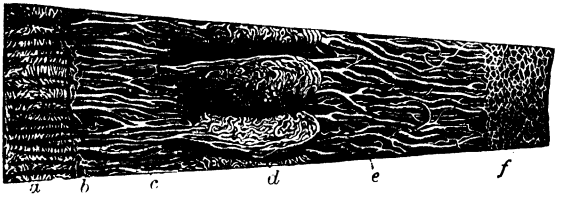

FIG. 711.—VESSELS OF THE CHOROID, CILIARY PROCESSES AND IRIS OF A CHILD. (Arnold.) × 10.

a, capillary network of the posterior part of the choroid, ending at *b*, the ora serrata; *c*, arteries of the corona ciliaris, supplying the ciliary processes, *d*, and passing into the iris, *e*; *f*, the capillary network close to the pupillary margin of the iris.

chiefly to the muscular tissue of those parts (ciliary muscle and sphincter and dilatator pupillæ).

THE RETINA.

The **retina** consists of the eight layers shown in the accompanying diagram (fig. 712), numbered as they occur from within out.

The inner surface of the retina rests upon the hyaloid membrane of the vitreous humour. It is formed of the united bases of the fibres of Müller, which will be afterwards described. The outer surface abuts against the choroid coat (fig. 713).

1. The *layer of nerve-fibres* is formed by the expansion of the optic nerve after it has passed through the coats of the eye (fig. 714). The optic nerve differs from other cerebro-spinal nerves in being made up not of separate cylindrical bundles of funiculi, but of one large bundle, covered with a thick sheath and subdivided by numerous interlacing septa into portions of irregular size and shape (fig. 715). A section across the nerve taken near its entrance into the globe shows a central strand of connective tissue containing the central retinal artery and vein which pass obliquely into the nerve a few millimetres from the back of the eyeball. The sheath of the nerve has a composite structure, being formed externally of a thick fibrous membrane continuous proximally with the dura mater and distally with the sclera, internally of a membrane continuous proximally with the pia mater, while between the two is a space containing a prolongation of the arachnoid; the space itself is continuous with the subdural and subarachnoid spaces of the cranial cavity. The nervous tissue is greatly diminished

at the lamina cribrosa owing to the disappearance of the myelin sheath of the nerve-fibres; these are continued into the retina as axis-cylinders only. At its entrance the nerve forms a slight eminence (*colliculus nervi optici*) with a central depression. The layer of nerve-fibres becomes gradually thinner towards the anterior part of the retina.

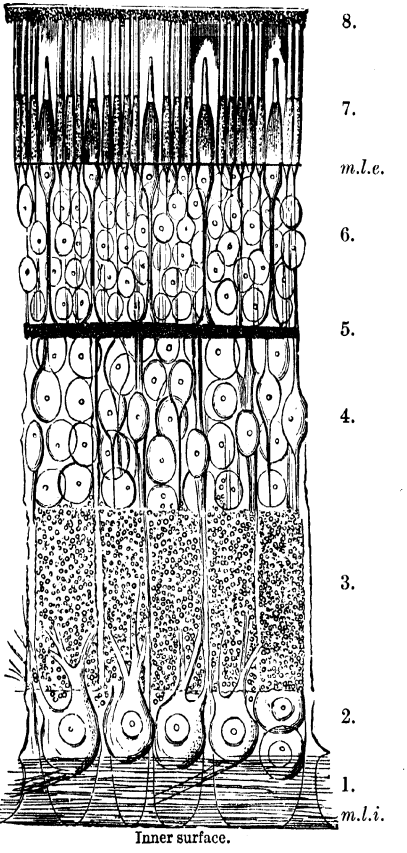

FIG. 712.—DIAGRAMMATIC SECTION OF THE HUMAN RETINA. (M. Schultze.)

1, Layer of optic nerve-fibres; 2, layer of optic nerve-cells; 3, inner synapse or molecular layer; 4, layer of inner granules or bipolars; 5, outer synapse or molecular layer; 6, layer of outer granules (outer nuclear layer); 7, layer of rods and cones; 8, layer of pigment-cells; *m.l.i.*, membrana limitans interna; *m.l.e.*, membrana limitans externa.

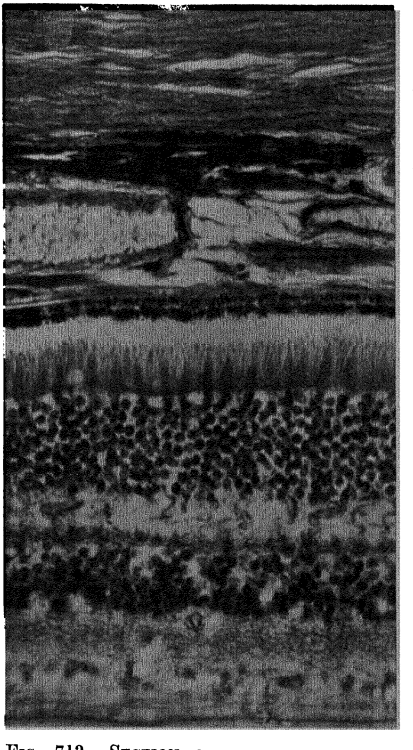

FIG. 713.—SECTION OF RETINA, CHOROID AND PART OF SCLEROTIC: MAN. (W. Chesterman.) Low power.

1 to 8, the layers of the retina, as enumerated in the previous figure; 9, choroid; 10, lamina supra choroidea; 11, sclera.

The nerve-fibres are connected with (derived from) the cells of the next layer (ganglionic layer) and are passing centripetally to enter the brain, but some are centrifugal and are derived from cells in the brain: these traverse the ganglionic and molecular layers to form a terminal arborisation in the inner nuclear layer (fig. 716, *i*, *j*, *m*, and fig. 717).

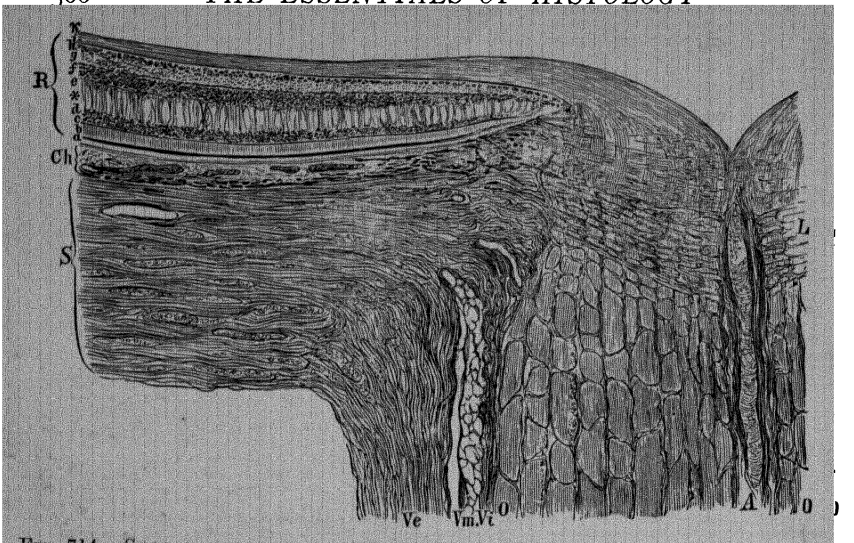

FIG. 714.—SECTION THROUGH THE COATS OF THE EYEBALL AT THE ENTRANCE OF THE OPTIC NERVE. (Toldt.)

Ve, dural sheath; *Vm*, arachnoidal sheath, and *Vi*, pia-matral sheath of the optic nerve, with lymph-spaces between them; *O*, *O*, nerve bundles; *L*, lamina cribrosa; *A*, central artery; *S*, sclerotic; *Ch.*, choroid; *R*, retina. The small letters refer to the various parts of the retina, *b* being the layer of rods and cones, * rod- and cone-fibres, *i*, optic nerve-fibres, and *k* the hyaloid membrane of the vitreous humour.

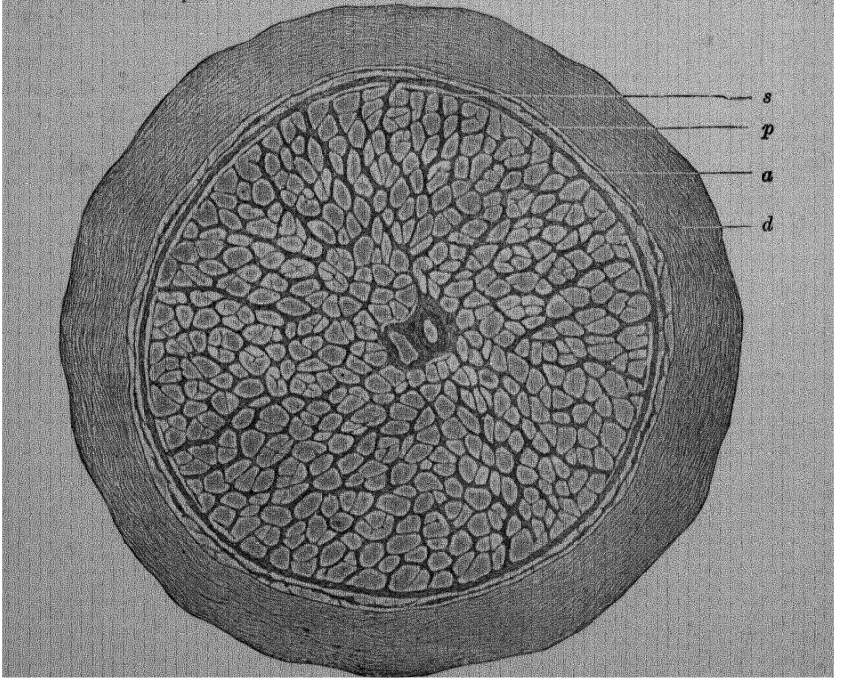

FIG. 715.—SECTION OF OPTIC NERVE: MAN. (Greeff.) × 24.

The section is taken near the junction with the globe. *d*, sheath derived from dura; *a*, sheath from arachnoid; *p*, from pia mater; *s*, a layer of superficial neuroglia.

2. The *layer of optic nerve-cells*, or *ganglionic layer*, is composed of nerve-cells somewhat like the cells of Purkinje of the cerebellum. They vary in

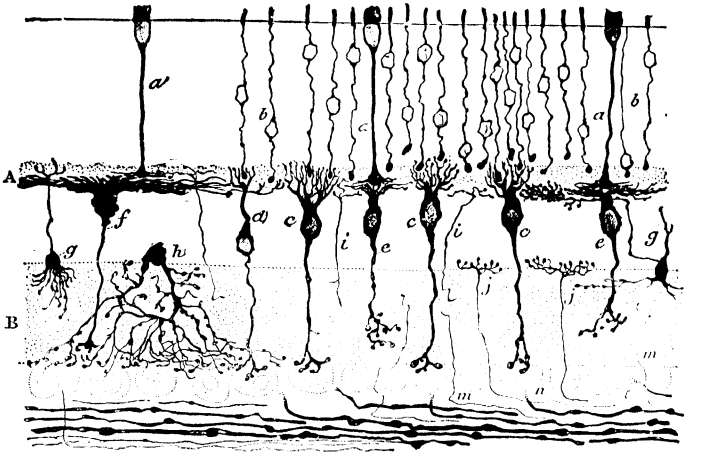

FIG. 716.—SECTION OF DOG'S RETINA, PREPARED BY GOLGI'S METHOD. (R. y Cajal).

a, cone-fibres; *b*, rod-fibres and nuclei; *c*, *d*, bipolar cells (inner granules) with vertical ramifications of their outer processes or dendrons: in the centre of the ramification lie the enlarged ends of rod-fibres; *e*, other bipolars with flattened ramifications abutting against ramified ends of cone-fibres; *f*, large bipolar with flattened ramifications; *g*, inner granule-cell sending an axon towards the rod- and cone-fibres; *h*, amacrine cell with diffuse arborisation of its processes in inner molecular layer; *i*, *j*, *m*, centrifugally conducting nerve-fibrils passing respectively to outer molecular, inner nuclear, and inner molecular layers; *n*, ganglionic cells with axons passing into nerve-fibre layer; A, outer synapse layer; B, inner synapse layer.

size, although those of large size are prevalent in most parts of the retina. But in the yellow spot smaller nerve-cells are met with, and here they

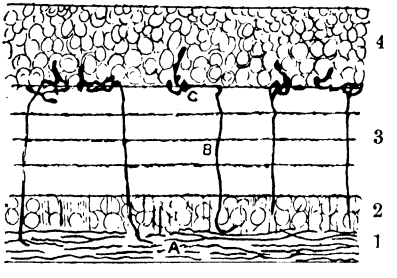

FIG. 717.—SECTION THROUGH THE INNER LAYERS OF THE RETINA OF A BIRD, PREPARED BY GOLGI'S METHOD. (R. y Cajal.)

A, nerve-fibres of optic nerve layer; B, some of these fibres passing through the inner molecular layer to end in an arborisation (C) at the junction of the inner synapse and inner nuclear layers. The layers in this and in the two succeeding cuts are numbered in correspondence with the layers in fig. 712.

may be several deep. The cells have a fine axis-cylinder process prolonged into a fibre of the layer of optic nerve-fibres and a thick branching process, the ramifications of which terminate in the inner synapse layer in flattened arborisations at different levels (fig. 718, A, B, C).

3. The *inner synapse layer* (*inner molecular layer*) is comparatively thick. It has an appearance very like parts of the grey matter of the nerve-centres. A few small cells are scattered through it, but it is mainly occupied by processes of the optic nerve-cells and of the inner granules which form synapses within it; it is also traversed by centrifugal fibres from the optic nerve layer, as well as by the fibres of Müller.

4. The *layer of inner granules* (also termed *inner nuclear layer*) is mainly composed of bipolar nerve-cells containing large nuclei. One process (the axon) of each of these cells (fig. 716) extends inwards into the inner molecular layer where it spreads out into a terminal arborisation. These arborisations occur at different levels in the layer, forming synapses with the optic nerve-cells. Another process (dendron) is directed outwards, and arborises in the outer molecular layer, where it forms synapses with the terminations of the rod- and cone-fibres. It has been shown by Ramón y Cajal that there are two kinds of bipolars, one kind (*rod-bipolars*, fig. 716,

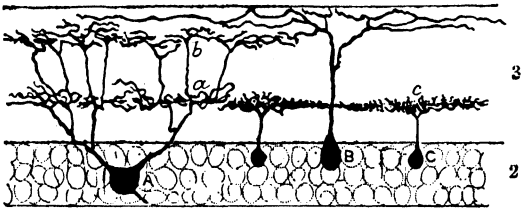

FIG. 718.—SECTION ACROSS THE MOLECULAR AND GANGLIONIC LAYERS OF A BIRD'S RETINA, PREPARED BY GOLGI'S METHOD. (R. y Cajal.)

Three or four ganglionic cells, A, B, C, and the terminal arborisations of their dendrons, *a*, *b*, *c*, in the molecular layer, are shown.

c and *d*) being connected externally with the rods of the retina, and passing inwards to ramify over the bodies of the nerve-cells; whilst the others (*cone-bipolars*, *e*) are connected with the cone-fibres, and ramify in the middle of the inner molecular layer. The outwardly directed processes of the cone-bipolars are, in some animals, but not in mammals, continued as far as the external limiting membrane, where each ends in a free extremity (*fibre of Landolt*, fig. 719, E). Besides these bipolar nerve-cells, there are other larger inner granules (spongioblasts of some authors) which are different in character, having ramified processes which extend into the inner molecular layer (figs. 716, *h*; 719, A, B, C), in which also their bodies are often partly embedded. The cells in question have been regarded as of the nature of neuroglia-cells, but according to Cajal they are probably nerve-cells. He termed them *amacrine-cells*, since he believed them to be destitute of an axon-process; but some of the amacrine-cells have since been noticed to give off, besides the branching processes or dendrons, which ramify in the molecular layer, an axis-cylinder process extending into the nerve-fibre layer. There are also certain cells in the outer part of the granule layer which send their processes entirely into the outer molecular layer (fig. 719, H, I). These are the *horizontal cells* of Cajal (spongioblasts of outer molecular layer of some

authors). The fibres of Müller have nucleated enlargements (fig. 719, J) amongst the bipolars of this layer.

5. The *outer synapse layer* (*outer molecular layer*) is thin, and is composed mainly of the arborisations of the inner granules and of the rod- and cone-fibres, as well as of the horizontal cells, which all form synapses in it (figs. 716, 719).

6 and 7. The *outer nuclear layer* and the *layer of rods and cones* are composed of elements which are continuous through the two layers, and they should properly, therefore, be described as one. It has been termed the *sensory epithelium of the retina* (fig. 720). The elements of which this nerve-epithelium consists are elongated cells of two kinds. The most

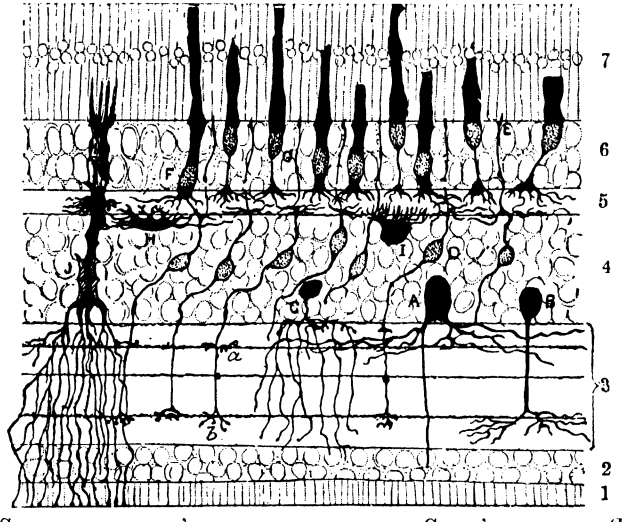

FIG. 719.—SECTION OF A BIRD'S RETINA, PREPARED BY GOLGI'S METHOD. (R. y Cajal.)

A, large (amacrine) cell of inner nuclear layer; B, C, smaller amacrine cells; D, small bipolar nerve-cells with the one process ramifying in the inner molecular layer, and the other one ramifying in the outer molecular layer and extending (E) as far as the rods and cones as a fibre of Landolt; F, G, rod- and cone-nuclei respectively; H, I, cells with dendrons ramifying in outer molecular layer; J, fibre of Müller.

numerous, which may be termed the *rod-elements*, consist of peculiar rod-like structures (*retinal rods*) set closely side by side, each of which is prolonged internally into a fine varicose fibre (*rod-fibre*) which swells out at one part of its course into a nucleated enlargement, and ultimately ends (in mammals) in a minute knob within the outer molecular layer, where it is embedded in the ramifications of the dendrons of the rod-bipolars. The rod consists of two segments, an outer cylindrical and transversely striated segment which during life has a purplish-red colour if the eye has not been recently exposed to light, and an inner, slightly bulged segment which in part of its length is longitudinally striated. The nucleus of the rod-element in some animals, but according to Flemming not in man, has a transversely shaded aspect in the fresh condition (fig. 720). The *cone-elements* are formed of a conical tapering external part, the *retinal cone*, which rests directly upon a nucleated enlargement, from the further side of which the

cone-fibre (fig. 721), considerably thicker (in mammals) than the rod-fibre, passes inwards, to terminate by an expanded arborisation in the outer molecular layer; here it comes into relation with a similar arborisation of the dendrons of a cone-bipolar. The cone, like the rod, is formed of two segments, the outer of which, much the smaller, is transversely striated; the inner, bulged segment being streaked longitudinally. The inner ends of the rod- and cone-fibres, as already stated, form synapses with the peripheral arborisations of the bipolars, and through the latter elements and their synapses in the inner synapse layer connexion is brought about with the nerve-cell and nerve-fibre layers.

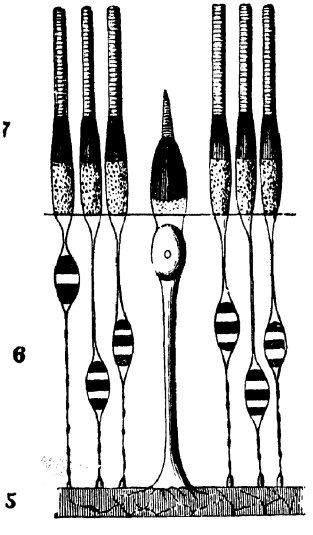

FIG. 720.—DIAGRAMMATIC REPRESENTATION OF THE ROD- AND CONE-ELEMENTS OF THE RETINA. (Schwalbe.)

The designation of the numbers is the same as in fig. 712.

The connexion of the retinal elements with one another and through the optic fibres with the central nervous system (anterior corpora quadrigemina and lateral geniculate bodies) is shown diagrammatically in fig. 722.

The rods outnumber the cones, although there is considerable local variation. The cones are most numerous at the yellow spot: at the fovea itself cones only are present. They are fewer in number, and the rods are proportionately more numerous, in all other parts (fig. 723). At the anterior part there are very few cones, but they are nowhere altogether absent.

In birds, reptiles, and amphibia a small oil-globule, often brightly coloured red, yellow, or green, is found in the inner segment of each cone. Many other variations of structure are met with in different animals.

8. The *pigmentary layer* forms the most external part of the retina. It consists of hexagonal epithelium-cells (fig. 724), which are smooth externally where they rest against the choroid, but are prolonged internally into thin lamellæ which extend between the rods. The pigment-granules, many of which are in the form of minute crystals, lie in the inner part of the cell, but after prolonged exposure to light they are found extending along the cell-processes between the rods (Kühne), their function being connected with the restoration of the purple colouring matter, which has been bleached by the light. This extension of the pigment is accompanied by a shortening of the cones (Engelmann) (fig. 725), and, according to Arey, by a lengthening of the rods.

Fibres of Müller.—The fibres of H. Müller (fig. 719, J, and fig. 726) are long neuroglia-cells (such as are found in some parts of the nerve-centres) which pass through several of the retinal layers. Commencing at the inner surface of the retina by expanded bases which unite with one another to form the so-called internal limiting membrane (fig. 727), they pass through all the

layers in succession, until they reach the outer granule layer. Here they branch and expand into a sort of honeycomb tissue (fig. 726) which serves to

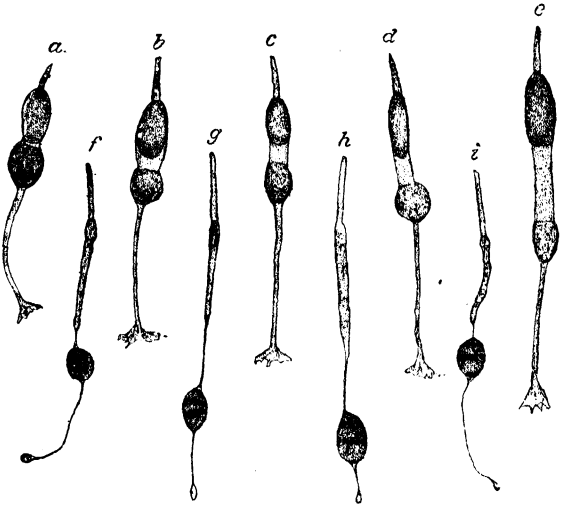

FIG. 721.—ROD- AND CONE-CELLS OF PIG'S RETINA, ISOLATED AFTER FIXATION BY OSMIC ACID. (Kölliker.) × 720.

a to *e*, cone-cells; *f* to *i*, rod-cells. The elements were all detached and it is an accident of the drawing that the rod- and cone-elements are placed in the figure at different levels.

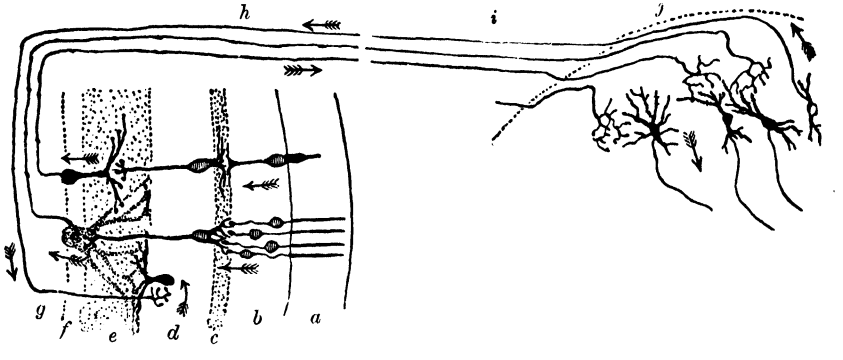

FIG. 722.—DIAGRAM OF THE CONNEXIONS OF THE RETINAL ELEMENTS WITH ONE ANOTHER AND WITH THE CENTRAL NERVOUS SYSTEM. (Cajal.)

a to *g*, layers of retina; *a*, rods and cones; *b*, outer granule layer; *c*, outer synapse layer; *d*, inner granule layer; *e*, inner synapse layer; *f*, nerve-cells giving origin to fibres of optic nerve; *g*, *h*, *i*, a centrifugally conducting fibre, arising from a cell in the brain, and with its terminal arborescence in the retina; *j*, grey matter of corpus quadrigeminum (or of lateral geniculate body).

support the fibres and nuclei of the rod- and cone-elements. At the bases of the rods and cones this sustentacular tissue ceases, being here bounded by

a distinct margin which has been called the *external limiting membrane* (fig. 726, *m.l.e.*); delicate sheaths pass from it around the bases of the

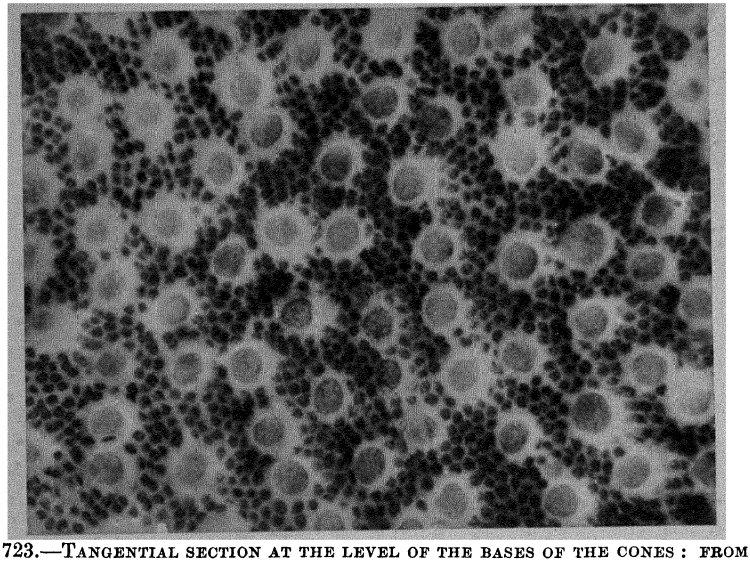

FIG. 723.—TANGENTIAL SECTION AT THE LEVEL OF THE BASES OF THE CONES: FROM THE BACK OF THE RETINA (HUMAN) NEAR THE MACULA LUTEA. (E. F. Fincham.) × 1000.

rods and cones. Each Müllerian fibre, as it passes through the inner granule layer, has a nucleated enlargement (*b*), indicating the cell-nature of the fibre.

There are two parts of the retina which call for special description.

The **macula lutea (yellow spot)**, with its **central fovea,** is the part of the

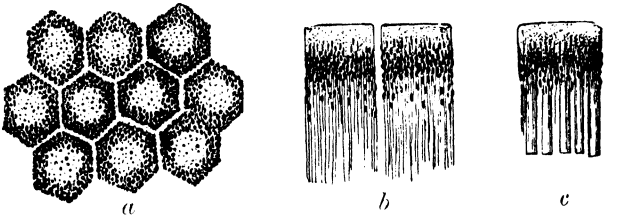

FIG. 724.—PIGMENTED EPITHELIUM OF THE HUMAN RETINA. (M. Schultze.) Highly magnified.

a, cells seen from the outer surface with clear lines of intercellular substance between; *b*, two cells seen in profile with fine offsets extending inwards; *c*, a cell still in connexion with the outer ends of the rods.

retina which is immediately concerned with direct vision. It is characterised, first, by its greater thickness (except at the middle of the fovea); second, by the large number of its ganglion-cells, which are relatively small; and third, by the number of cones it contains as compared with the rods. In the central fovea itself (figs. 728, 729) there are no rods, and

the cones are very long and slender, measuring not more than 2μ in diameter; all the other layers become gradually thinned down almost to complete disappearance, so that the middle of the central fovea is the thinnest part of the retina. Since there are few rods, the outer granule layer loses in great measure its appearance of being composed of closely packed nuclei, and the cone-fibres are very distinct, forming the so-called *fibrous layer*. Except at the very centre the direction of these fibres is oblique in this part of the retina.

The pigmentary layer is thickened over the fovea, and there is also

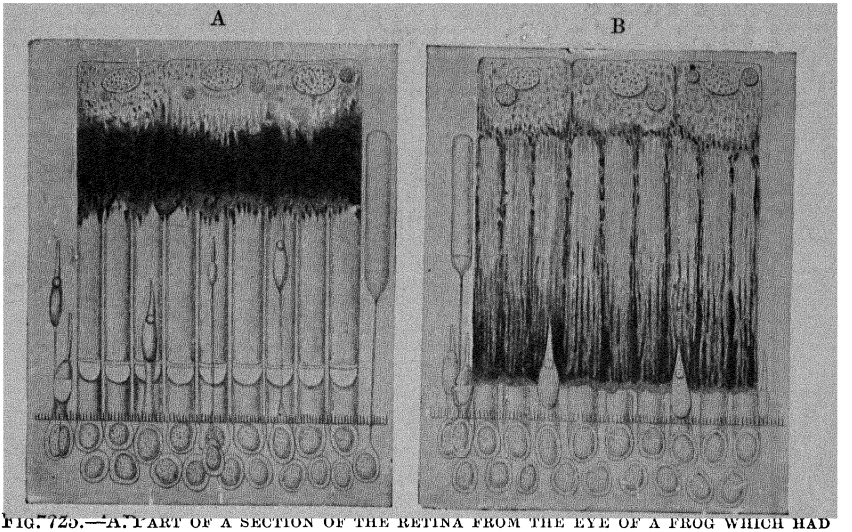

FIG. 725.—A. PART OF A SECTION OF THE RETINA FROM THE EYE OF A FROG WHICH HAD BEEN KEPT IN THE DARK FOR SOME HOURS BEFORE DEATH. (v. Genderen-Stort.)

The pigment is collected towards the outer ends of the rods, which were red, except the outer detached rod, which was green. The cones, which in the frog are much smaller than the rods, are mostly elongated.

B. A SIMILAR SECTION FROM A FROG WHICH HAD BEEN EXPOSED TO LIGHT.

The pigment is extended between the rods, and is accumulated near their bases. The rods were colourless. All the cones were contracted.

a thickening in the choroid coat here, due to a large accumulation of capillary vessels.

The **pars ciliaris retinæ**, which commences at the *ora serrata*, where the retina proper abruptly ends (fig. 730), is composed of two epithelial layers without nervous structures. Of the two layers, the external is a thick stratum of pigmented epithelium formed of rounded cells and continuous with the pigmentary layer of the retina on the one hand, and with the uvea of the iris on the other; the inner is a layer of columnar cells (fig. 705; fig. 730, *a*, *k*).

Vessels of the retina.—The retina contains relatively few blood-vessels. The central artery enters and the vein leaves it in the middle of the expansion of the optic nerve. The larger vessels ramify in the nerve-fibre layer. There are capillary networks in this layer and in the inner nuclear layer. Perivascular lymph-spaces surround the veins and capillaries. The

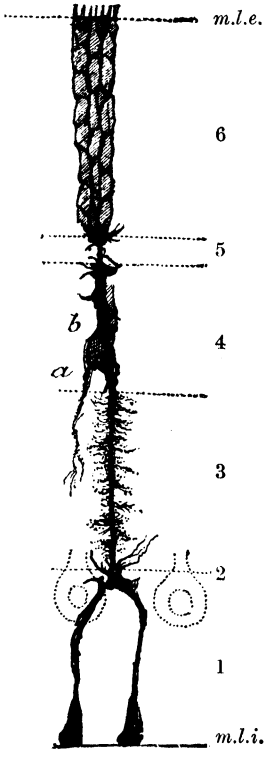

FIG. 726.—A FIBRE OF MÜLLER FROM THE DOG'S RETINA: GOLGI METHOD. (R. y Cajal.)

1, nerve-fibre layer; 2, nerve-cell layer; 3, inner synapse layer; 4, inner granule layer; 5, outer synapse layer; 6, outer granule layer; *b*, nucleus of the fibre; *a*, a process extending into inner synapse layer; *m.l.i.*, membrana limitans interna; *m.l.e.*, membrana limitans externa.

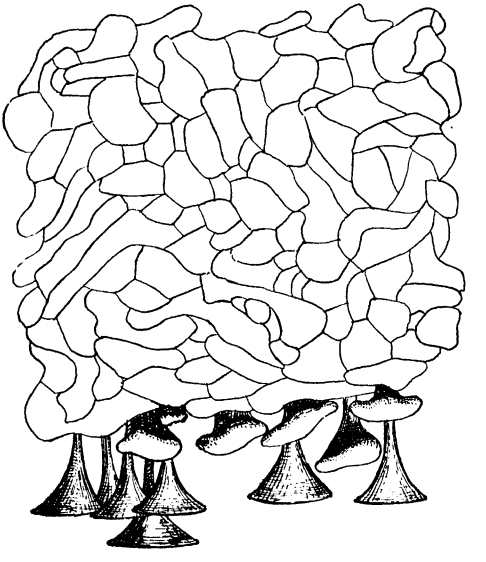

FIG. 727.—INTERNAL LIMITING MEMBRANE OF RETINA TREATED WITH SILVER NITRATE, SHOWING THE OUTLINES OF THE BASES OF THE FIBRES OF MÜLLER. (G. Retzius.)

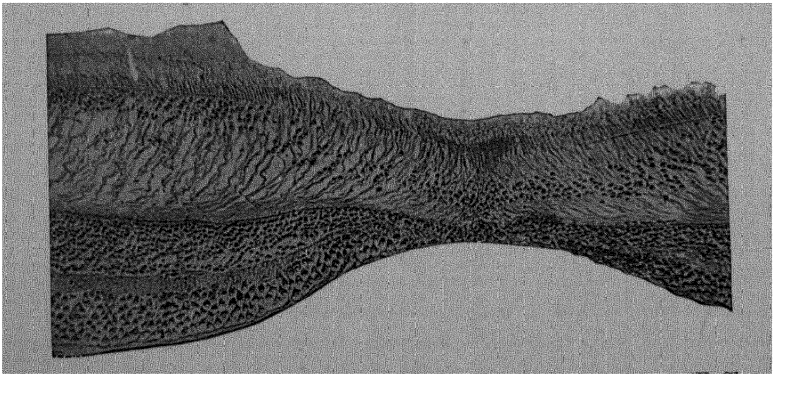

FIG. 728.—SECTION THROUGH THE CENTRAL PART OF THE FOVEA CENTRALIS. (E. Sharpey-Schafer.) × 200. Photograph. Preparation by C. H. Golding-Bird.

sensory epithelium (rod- and cone-cells, and retinal pigment cells) receives no blood-vessels; it is nourished from the vessels of the choroid.

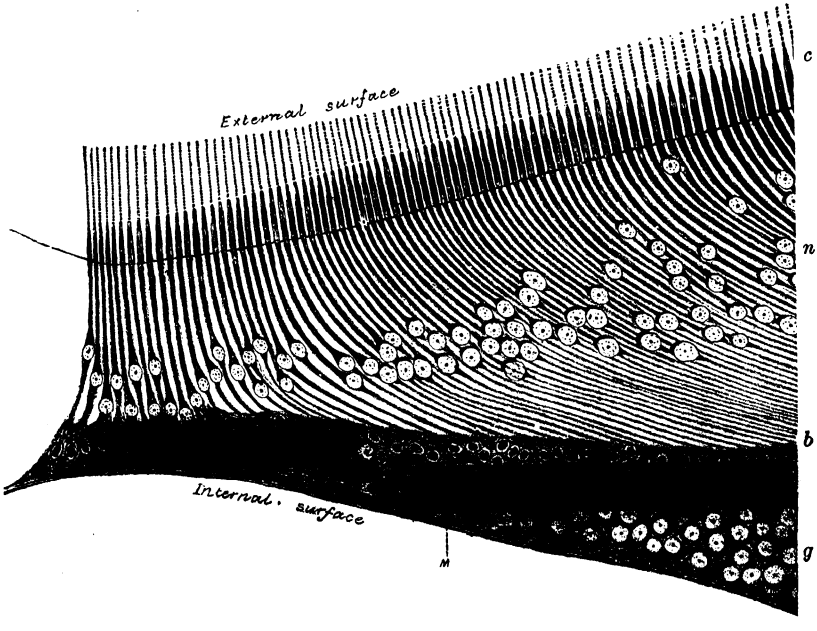

FIG. 729.—DIAGRAM OF THE ARRANGEMENT OF THE RETINAL ELEMENTS AT THE CENTRAL FOVEA. (E. Sharpey-Schafer.)

M, bases of Müllerian fibres; *g*, ganglion-cells; *b*, nuclei of inner granules (bipolars); *n*, cone-fibre nuclei; *c*, cones.



FIG. 730.—SECTION OF HUMAN RETINA AT ORA SERRATA, SHOWING THE ABRUPT TERMINATION OF THE USUAL RETINAL LAYERS AND THE CONTINUATION OF THE RETINAL SHEET AS TWO LAYERS OF CELLS, WHICH FORM THE PARS CILIARIS RETINÆ. (Piersol.)

a, *a*, pigment layer; *b*, rod- and cone-layer; *c*, outer nuclear layer; *d*, outer synapse layer; *e*, inner nuclear layer; *f*, inner synapse layer; *g*, ganglion-cell and nerve-fibre layers; *h*, section at transition line; *k*, columnar cells of pars ciliaris; *i*, a cyst such as occurs occasionally here.

THE LENS AND VITREOUS HUMOUR.

The lens.—The lens is a laminated fibrous body enclosed by a transparent elastic capsule to which, around the circumference, the fibres of

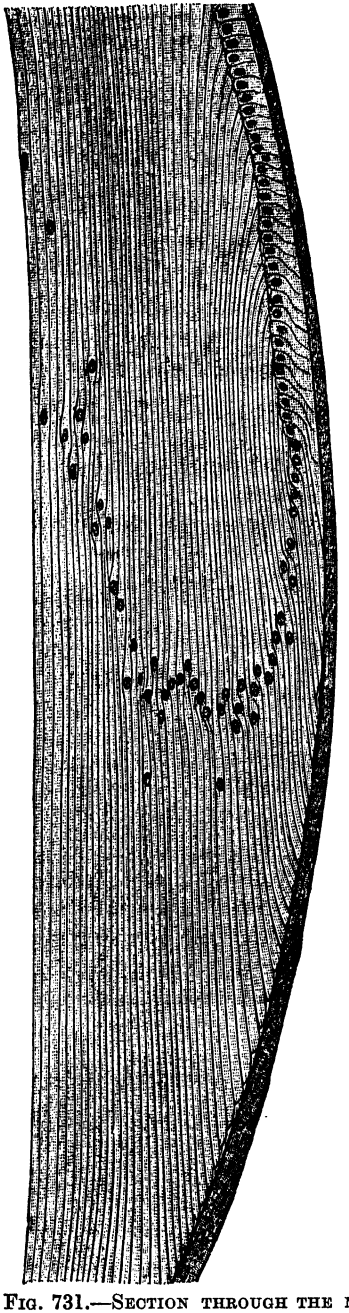

FIG. 731.—SECTION THROUGH THE MARGIN OF THE RABBIT'S LENS, SHOWING THE TRANSITION OF THE EPITHELIUM OF THE CAPSULE INTO LENS-FIBRES. (Babuchin.)

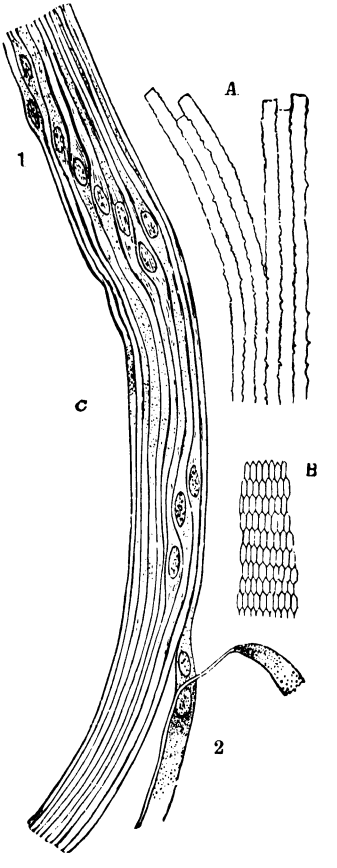

FIG. 732.—FIBRES OF THE CRYSTALLINE LENS. × 350.

A, longitudinal view of the fibres of the lens of the ox, showing the serrated edges. B, transverse section of the fibres of the lens of the human eye. C, longitudinal view of a few of the fibres from the equatorial region of the human lens. Most of the fibres in C are seen edgewise, and towards 1, present the swellings and nuclei of the 'nuclear zone'; at 2, the flattened sides of two fibres are shown. (A and B from Kölliker; C from Henle.)

the suspensory ligament are attached (fig. 707). Immediately within the capsule, in front and at the sides, there is a layer of cubical epithelium

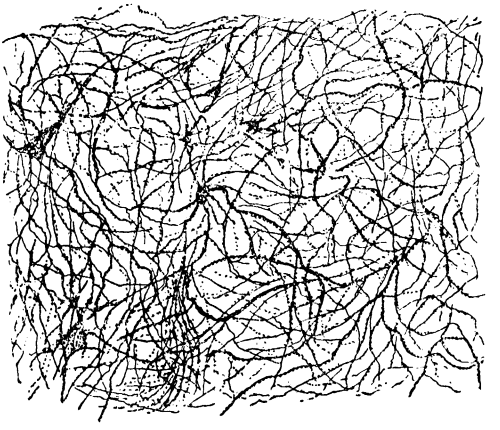

FIG. 733.—FIBRES OF VITREOUS HUMOUR. (G. Retzius.) × 400.

termed the epithelium of the capsule, but at the margin of the lens the cells become longer and pass by a gradual transition into the lens-fibres (fig. 731). The *fibres* which compose the lens are long and riband-shaped, with finely serrated edges (fig. 732, A); their transverse sections are prismatic (B). Many of the superficial fibres are nucleated (C), the lens-fibres having originally been developed by the elongation of epithelium-cells.

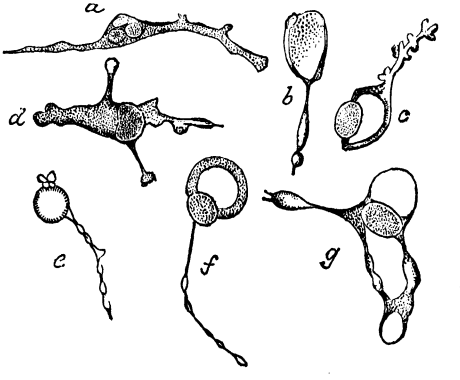

FIG. 734.—CELLS OF VITREOUS HUMOUR. (G. Schwalbe.)
a and *d*, without vacuoles; *b*, *c*, *e*, *f*, *g*, vacuolated.

The vitreous humour.—This is composed of soft gelatinous tissue, apparently structureless when examined in the fresh condition, but containing fibres (fig. 733) and a few scattered cells, the processes of which are often long and varicose, and the cell-bodies distended by large vacuoles (fig. 734). The *hyaloid membrane*, which invests the vitreous humour, is homogeneous and structureless except in the region of the ciliary processes, where it is fibrous in structure, forming the zonule of Zinn and spreading out into the suspensory ligament of the lens (fig. 707). This part of the hyaloid membrane is connected with an annular fibrous portion of the vitreous humour which serves to give additional firmness to the attachment of the fibres of the suspensory ligament of the lens.

LESSONS XLIX. AND L.

THE NOSE AND EAR.

1. VERTICAL sections of the nasal mucous membrane. The sections may be carried either across the upper turbinate bone, after decalcification, or across the upper part of the nasal septum. Make a sketch under the low power. Notice the difference in the character of the epithelium in the olfactory and respiratory parts of the membrane.

2. Teased preparation of the epithelium of the olfactory mucous membrane. A piece of the membrane is placed quite fresh in osmic acid (1 per cent.) for a few hours, and is then macerated for two days or more in thymol water. The epithelium is broken up in dilute glycerine; the cells easily separate from one another on tapping the cover-glass. Notice the two kinds of cells. Sketch some of the cells under a high power.[1]

3. Sections of the external ear (these have been already studied for the cartilage, Lesson XII.).

4. Sections across the cartilaginous part of the Eustachian tube. These may be included in the same preparation that furnishes sections of cochlea. Sketch under the low power.

5. Preparation of the membrana tympani. A piece of the membrane, stained with acid fuchsin and gentian violet (see Lesson IX., § 2), is mounted flat in dammar. Determine the composition of the membrane—*i.e.* the several layers composing it—by focussing carefully with the high power.

6. Sections across one of the membranous semicircular canals of a fish (skate).

7. Longitudinal sections through the ampulla of a semicircular canal (skate).

Preparation 6 and 7 may be fixed in chromic and osmic acid (see below under 10) and embedded in celloidin.

8. Golgi preparations of the macula of the utricle from the skate.

9. Teased osmic preparations (§ 2) of the auditory epithelium of an ampulla and of the macula of the utricle from the skate.

10. Vertical sections through the middle of the cochlea of a mammal (guinea-pig). The part of the petrosal containing the cochlea is put quite fresh into 0·2 per cent. chromic acid containing one-fifth its volume of 1 per cent. osmic acid, or into undiluted Flemming's solution, or into 10 per cent. neutral formol. It is left in the fixative two days or more. Decalcification can be effected by the use of the phloroglucin-nitric acid fluid, or by sulphurous acid. (See Appendix.) When decalcified, the preparation is thoroughly washed with running water, and then transferred to alcohols of gradually increasing strength.

The semicircular canals and their ampullæ may also be seen cut across in these sections of the petrosal.

In preparing sections of the membranous labyrinth it is advisable, in order that the epithelium should be kept in position, to embed in celloidin. If the paraffin method of embedding is used, the sections are fixed to the slide by the white of egg process. The preparation may be stained in bulk.

11. Teased osmic preparations (§ 2) of the epithelium of the organ of Corti from the guinea-pig.

Make sketches from all these preparations under the high power.

[1] The connexion of the olfactory cells with the olfactory nerve-fibres is displayed in embryos, the method of Golgi being employed.

THE OLFACTORY MUCOUS MEMBRANE.

The **olfactory region** of the nasal fossæ includes in man the upper and middle turbinate processes and the upper third of the septum. It is covered by a soft vascular mucous membrane of a yellow colour. The remainder of the nasal mucosa is reddish and covered with ciliated epithelium interspersed with goblet cells.

The epithelium of the olfactory mucous membrane (fig. 736, *a*) is very

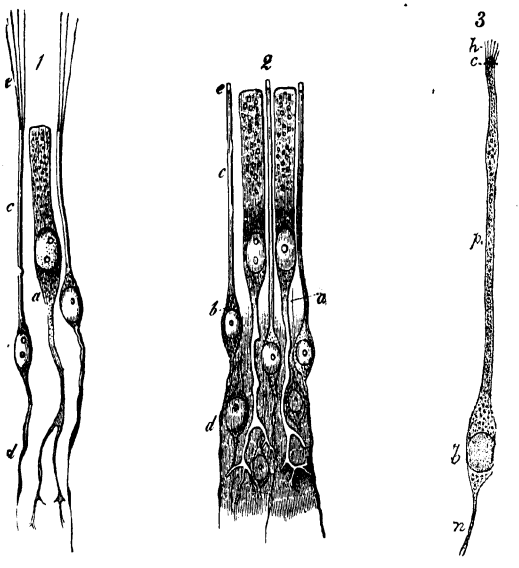

FIG. 735.—CELLS AND TERMINAL NERVE-FIBRES OF THE OLFACTORY REGION. Highly magnified.

1, from the frog; *2* and *3* from man. In *1* and *2*: *a*, sustentacular cell, extending deeply into a ramified process; *b*, olfactory cells; *c*, their peripheral processes; *e*, the extremities of these, seen in *1* to be prolonged into fine hairs; *d*, their central filaments. In *3*:—*h*, hairlets; *c*, free border of cell; *p*, peripheral process; *b*, body of cell; *n*, nerve-fibre. *1* and *2* from M. Schultze; *3* from v. Brunn.

thick and is composed of long cells, set closely side by side and bounded superficially by a cuticular lamina, through which the free ends of the cells project. The cells are of two kinds: 1. Long, narrow, spindle-shaped, or bipolar nerve-cells, consisting of a larger part or body (fig. 735) containing the nucleus, and of two processes or poles, one straight and cylindrical and extending to the free surface, the other very delicate and varicose, passing down towards the corium. Neuro-fibrils are present in the body and processes of the cell. The position of the nuclear enlargement varies, and with it the relative length of the two processes. The distal or free process terminates in a small clear projection, which passes beyond the cuticular membrane; in amphibia, reptiles, and birds, and perhaps also in mammals, it bears fine stiff hair-like filaments (fig. 735, *1*, *3*). The proximal or varicose

process becomes lost in the plexus of olfactory nerve-fibres at the base of the epithelium. It is continuous with one of these fibres, and ultimately passes through the cribriform plate of the ethmoid to end in an arborisation within an olfactory glomerulus (see diagram, fig. 688, p. 539). These cells have been termed the *olfactory cells*. 2. Long columnar epithelium-cells (fig. 735, *a*), with comparatively broad cylindrical nucleated cell-bodies placed next to the free surface, and forked, branching, tail-like processes extending down to the corium. These are regarded not as sensory epithelium-cells, but merely as serving to support the proper olfactory cells. The yellow colour of the olfactory mucosa is due to the lipoid granules that these cells contain at their free ends. They are termed *sustentacular cells*.

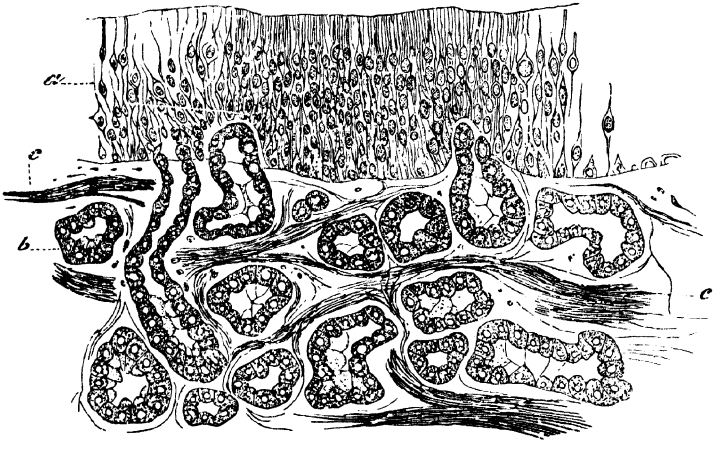

FIG. 736.—SECTION OF OLFACTORY MUCOUS MEMBRANE. (Cadiat.)
a, epithelium; *b*, glands of Bowman; *c*, *c*, nerve-bundles.

3. Tapering cells are present, at least in some animals, in the deeper part of the epithelium. They rest by their bases upon the corium, and project between the other cells, which they assist to support.

The corium of the olfactory mucous membrane is also thick (fig. 736). It contains, besides numerous blood-vessels and bundles of the olfactory nerve-fibres (which are amyelinate), a large number of granular-looking serous glands known as *Bowman's glands* (*b*), which open upon the surface by ducts passing between the epithelium-cells.

THE EXTERNAL AND MIDDLE EAR.

The **external ear** proper (*pinna*) is composed of elastic fibro-cartilage, invested by a thin closely adherent skin. The skin is covered by small hairs, and connected with these are the usual sebaceous follicles. In the lobule there is a considerable amount of adipose tissue; voluntary muscular

fibres are in places attached to the cartilage of the pinna, and are seen in sections.

The **external auditory meatus** is a canal formed partly of cartilage continuous with that of the pinna, partly of bone. It is lined by a prolongation of the skin and is closed by the membrana tympani, over which the skin is prolonged as a very thin layer. Near the orifice the skin has hairs and sebaceous glands; the meatus is also provided throughout the cartilaginous part with convoluted tubular glands of a brownish-yellow colour, which yield a waxy secretion (*ceruminous glands*). They represent

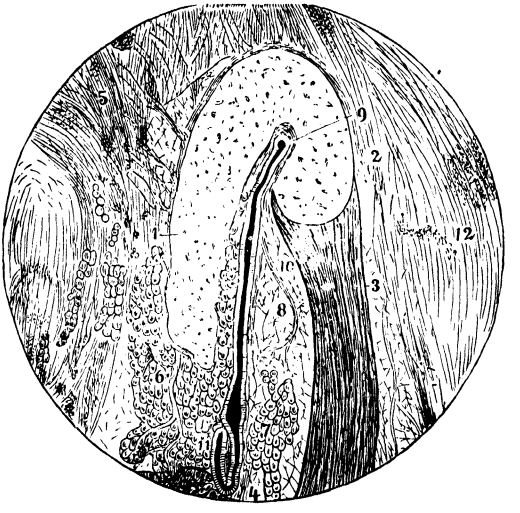

FIG. 737.—SECTION ACROSS THE CARTILAGINOUS PART OF THE EUSTACHIAN TUBE. (Rüdinger.)

1, 2, bent cartilaginous plate; 3, musc. dilatator tubæ; to the left of 4, part of the attachment of the levator palati muscle; 5, fibrous tissue uniting the tube to the base of the skull; 6 and 7, mucous glands; 8, 10, fat; 9 to 11, lumen of the tube; 12, connective tissue on the lateral aspect of the tube.

modified sweat glands of the larger type such as found in the axilla. Like these the secretion is formed by the partial disintegration of the free ends of the cells. Their structure has already been considered (see p. 310 and figs. 414 and 415).

The **tympanum** is lined by a mucous membrane which is continuous through the Eustachian tube with the mucous membrane of the pharynx; it is also prolonged into the mastoid cells. The epithelium is cubical and ciliated in some parts, but in others—*e.g.* roof, promontory, ossicles, and membrana tympani—there is a pavement-epithelium.

The **membrana tympani** is a thin membrane formed of fibrous bundles which radiate from a central depression (umbo). Within the radial fibres are a few annular bundles. Covering the fibrous membrane externally is a thin layer continuous with the skin of the meatus; covering it internally is another thin layer, derived from the mucous membrane of the tympanic

cavity. A few blood-vessels and lymphatics are distributed to the membrane, chiefly in the cutaneous and mucous layers.

The **auditory ossicles** are formed of compact bone covered externally by hyaline cartilage.

The **Eustachian tube** is the canal leading from the tympanum to the pharynx. It is formed of bone near the tympanum, but below, near the pharynx, it is bounded partly by a bent piece of cartilage (fig. 737, 1, 2), partly by fibrous tissue. The latter contains numerous mucous glands (6, 7), which open into the tube, and on the other side a band of muscular tissue (3) which joins the tensor palati. The epithelium is ciliated.

Lymphoid tissue is found in the wall of the tube in its pharyngeal portion —especially in children.

THE INTERNAL EAR.

The **labyrinth,** which is the essential part of the auditory organ, consists of a complex membranous tube lined by epithelium and filled with

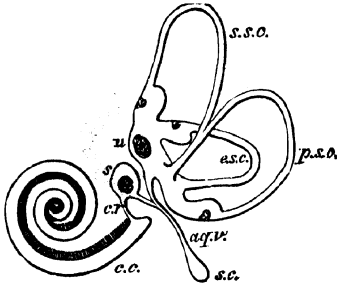

FIG. 738.

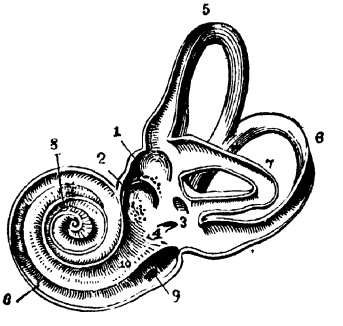

FIG. 739.

FIG. 738.—PLAN OF THE RIGHT MEMBRANEOUS LABYRINTH VIEWED FROM THE MEDIAL ASPECT. (E. Sharpey-Schafer.) × 2½.

u, utricle, with its macula; *s.s.c.*, *p.s.c.*, and *e.s.c.*, the three semicircular canals with their ampullæ; *s*, saccule; *aq.v.*, aquæductus vestibuli; *s.e.*, saccus endolymphaticus; *c.r.*, canalis reuniens; *c.c.*, canal of the cochlea.

FIG. 739.—VIEW OF THE INTERIOR OF THE LEFT OSSEOUS LABYRINTH.

The bony wall of the labyrinth is removed superiorly and externally. 1, fovea hemielliptica; 2, fovea hemisphærica; 3, common opening of the superior and posterior semicircular canals; 4, opening of the aqueduct of the vestibule; 5, the superior, 6, the posterior, and 7, the external semicircular canals; 8, spiral tube of the cochlea; 9, scala tympani; 10, scala vestibuli.

endolymph, contained within a bony tube—the osseous labyrinth—of corresponding complexity of shape (figs. 738, 739). The membranous labyrinth does not wholly fill the bony cavity, part of the space being occupied by perilymph. The membranous labyrinth (fig. 738) is composed of the *utricle* (*u*), the three *semicircular canals* (each with an enlargement or *ampulla* at one end), the *saccule* (*s*), and the *canal of the cochlea* (*c.c.*). The cochlea is the actual organ of hearing; the utricle, saccule and semicircular canals are organs of equilibration.

The branches of the auditory nerve pass to certain parts only of the

membranous labyrinth, viz. the maculæ of the utricle and saccule, the cristæ of the ampullæ, and along the whole length of the canal of the cochlea (the shaded parts in fig. 738). At these places the lining epithelium is specially modified to form a sensory or nerve-epithelium; elsewhere it is a simple pavement-epithelium.

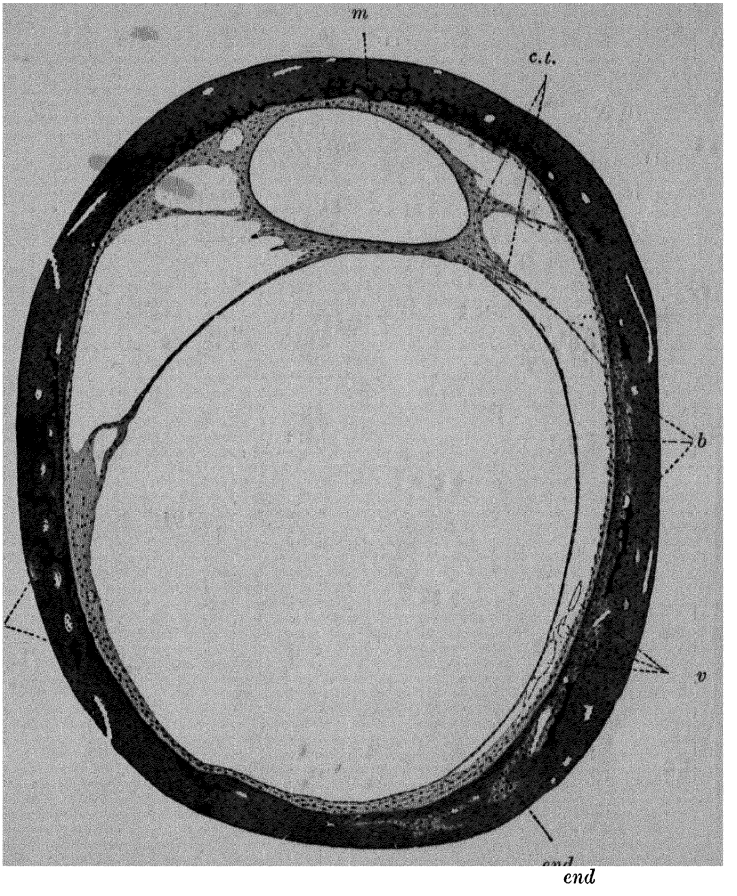

FIG. 740.—SECTION OF SEMICIRCULAR CANAL: NEW-BORN CHILD. (Sobotta.) × 55.

c.t., connective-tissue strands, between membranous canal and endosteum of bony canal; *m*, membranous canal; *b*, wall of bony canal; *c*, remains of fœtal cartilage; *end*, endosteum; *v*, blood-vessels.

The **membranous semicircular canals** and the **utricle** and **saccule** are composed of fibrous tissue, which is adherent along one side to the endosteum of the bony canal; from the opposite side bands of fibrous tissue pass across the perilymph (fig. 740). Within the fibrous membrane is a thick clear tunica propria, which, in the semicircular canals, may form papilliform elevations in the interior of the tube.

The places of entrance of the nerve-fibres are marked in each ampulla

by a transverse, inwardly projecting ridge (*crista*, figs. 741, 742), in the saccule and utricle by a broader thickening of the tunica propria (*macula*). The epithelium at these places is formed of flask-shaped cells (fig. 743), which are surmounted by long, stiff, tapering hairlets (fig. 741, *h*; fig. 743). Around these *hair-cells* the axis-cylinders of the nerve-fibres ramify (fig. 743); they are therefore—like the gustatory cells of the taste-buds—sensory epithelium-cells. Between them are a number of thin and somewhat rigid nucleated

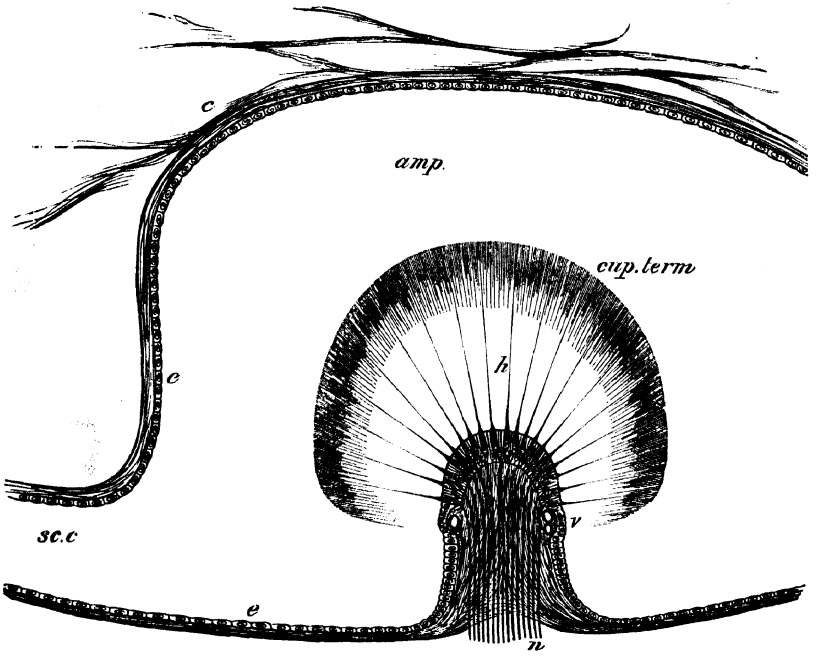

FIG. 741.—LONGITUDINAL SECTION OF AN AMPULLA OF A FISH THROUGH THE CRISTA ACUSTICA (DIAGRAMMATIC).

amp., cavity of the ampulla; *sc.c*, semicircular canal opening out of it; *c*, connective tissue attached to the wall of the membranous ampulla and traversing the perilymph; *e*, *e*, flattened epithelium of ampulla; *h*, hairs projecting from the columnar cells of the epithelium into the cupula, *cup.term*; *v*, blood-vessels; *n*, nerve-fibres entering the base of the crista and passing into the columnar epithelium.

cells (*fibre-cells* of Retzius), which rest upon the basement-membrane, and are connected at their free extremity with a cuticular membrane, through which the above-mentioned hairs project.

The hairs do not jut freely into the endolymph, but into a soft mucus-like substance, of a dome-like form in the ampullæ (*cupula terminalis*, fig. 741), but nearly cylindrical in shape in the saccule and utricle where there are a number of crystalline calcareous particles (*otoliths*) embedded in it. In bony fishes these particles are aggregated into a hard polished 'otolith' of considerable size, which rests upon the hairlets.

The cochlea consists of a bony tube coiled spirally around an axis which is known as the *columella* (figs. 744, 745). The tube is divided along its

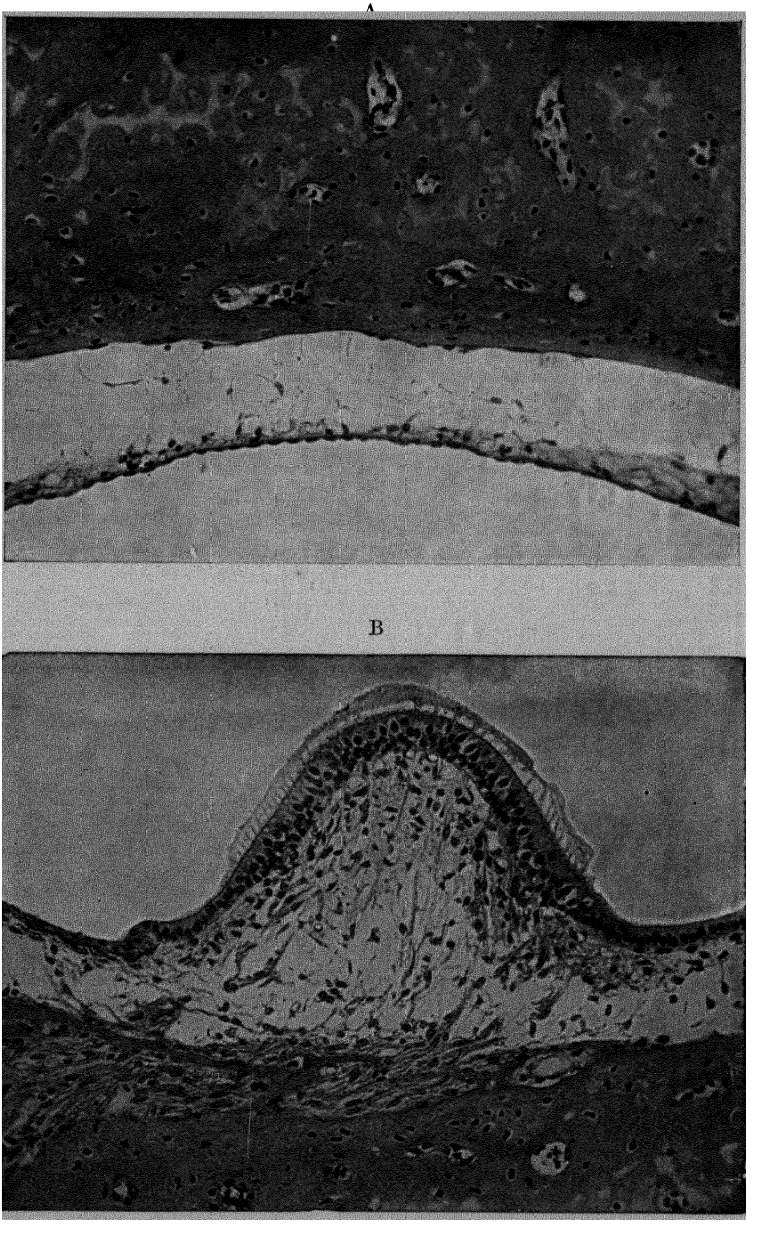

FIG. 742.—LONGITUDINAL SECTION OF AMPULLA OF GUINEA-PIG. Photograph. Preparation by H. Pringle.

In A.—The bony wall of the ampulla is seen above, separated from the thin endothelium lining the membranous tube by delicate connective tissue. [A and B are parts of the same section.]

In B.—*e*, epithelium becoming columnar over the crista, where the cells are furnished with hairlets; *c*, corium of delicate connective tissue, with the nerve-fibres passing to the epithelium; *b*, bone, with canals containing bundles of nerve-fibres.

length by a partition—formed partly by a projecting lamina of bone (*spiral lamina*), partly by a flat membrane (*basilar membrane*)—into two parts (*scalæ*); the upper (supposing the cochlea resting base downwards) being termed the *scala vestibuli*, the lower *scala tympani*; the latter is closed near its lower end by the membrane of the fenestra rotunda through which, in the macerated bone, the cavity of the tympanum communicates with the scala tympani. The scalæ are lined by endosteum, and are filled with perilymph, continuous with that of the rest of the labyrinth at the commencement of the scala vestibuli; they communicate with one another at the apex of the cochlea by an opening, the *helicotrema*.

The scala vestibuli does not occupy the whole of that part of the bony tube of the cochlea which is above the partition just mentioned. Its outer

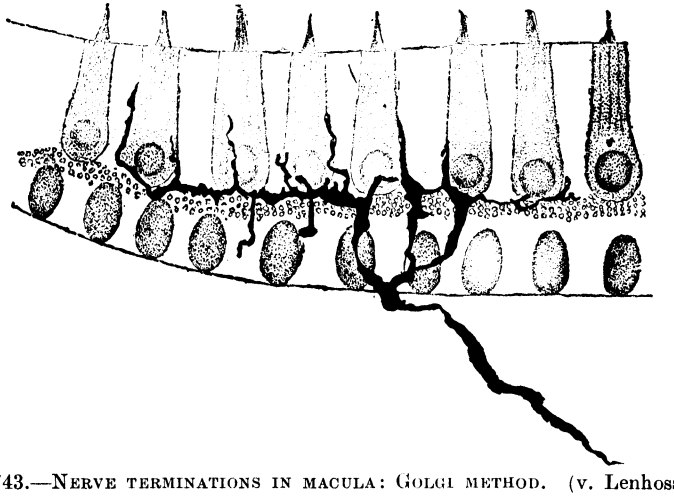

FIG. 743.—NERVE TERMINATIONS IN MACULA: GOLGI METHOD. (v. Lenhossék.)

and lower third is cut off by a delicate connective-tissue membrane (*membrane of Reissner*, fig. 744, *mR*, fig. 746, *R*), which springs from near the end of the spiral lamina and passes upwards and outwards to the outer wall, thus separating a canal (*d.c*) triangular in section, which is lined by epithelium; this canal represents the membranous labyrinth of the cochlea (*duct or canal of the cochlea*).

The floor of the canal of the cochlea is formed (1) of the extremity of the spiral lamina, which is thickened above by a peculiar kind of connective tissue, forming an overhanging projection known as the *limbus* (fig. 746, *l*); and (2) of the basilar membrane (*b.m*), which stretches across from the end of the bony lamina to the outer wall, and is attached to this by a projection of reticular connective tissue termed the *spiral ligament* (*l.sp*).

The *basilar membrane* is composed of stiff straight fibres, which extend from within out, and are embedded in a homogeneous ground-substance. The membrane is covered below by a layer of connective tissue continuous with the endosteum of the scala tympani; the modified epithelium which

forms the organ of Corti rests upon its upper surface. It becomes gradually broader in the upper turns of the cochlea (rather more than twice as broad in the uppermost as compared with the lowermost turn), and its constituent fibres become therefore gradually longer.

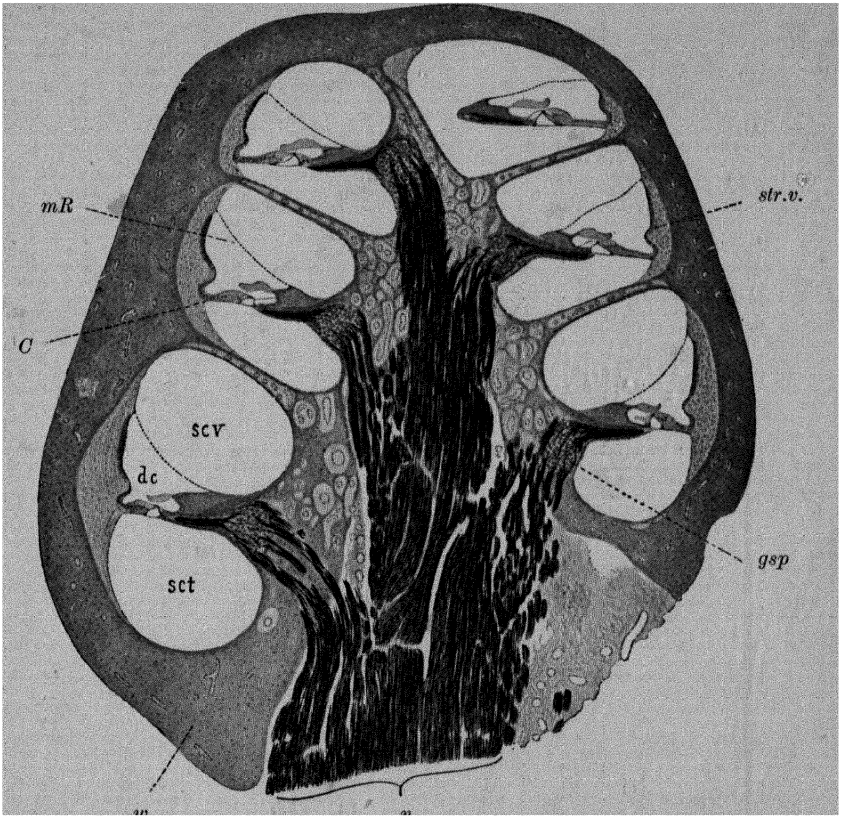

FIG. 744.—SECTION THROUGH THE COCHLEA OF THE CAT. (Sobotta.) × 25.

dc, duct of cochlea; *scv*, scala vestibuli; *sct*, scala tympani; *w*, bony wall of cochlea; *C*, organ of Corti on membrana basilaris; *mR*, membrane of Reissner; *n*, nerve-fibres of cochlear nerve; *gsp*, ganglion spirale; *str.v.*, stria vascularis.

The **organ of Corti** (fig. 747) consists of the following structures:—

1. The *rods of Corti*, two series (inner and outer) of stiff, striated structures, of a peculiar shape, the inner somewhat like a human ulna, the outer like a swan's head and neck (fig. 748). They rest by one extremity (the foot) on the basilar membrane a short distance apart, and are inclined towards one another, their larger ends (heads) being fixed together; the series of rods thus encloses a sort of tunnel, the floor of which is formed by a part of the basilar membrane (fig. 749). Close to their feet may usually be seen the remains of the cells from which they have been formed. The inner rods are narrower and rather more numerous than the outer.

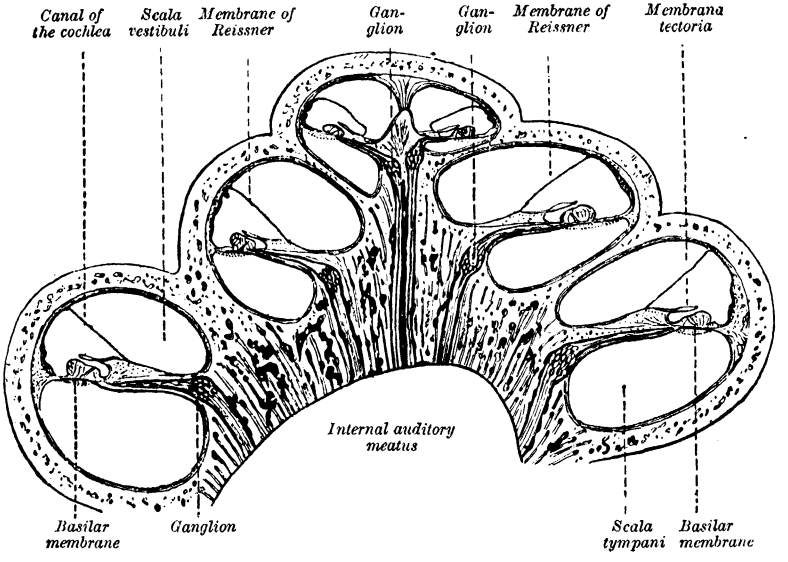

FIG. 745.—VERTICAL SECTION THROUGH THE MIDDLE OF THE HUMAN COCHLEA. (E. Sharpey-Schafer.)

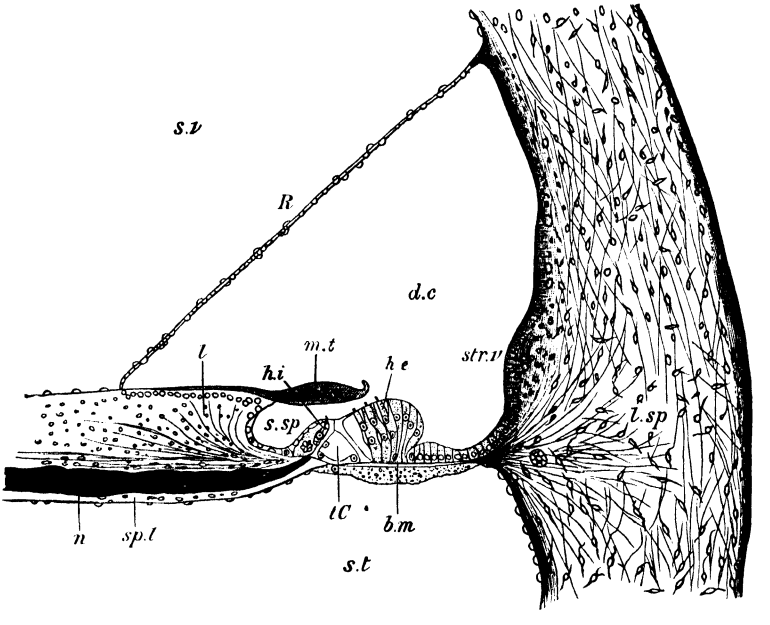

FIG. 746.—VERTICAL SECTION OF THE FIRST TURN OF THE HUMAN COCHLEA. (G. Retzius.)

s.v, scala vestibuli; *s.t*, scala tympani; *d.c*, canal or duct of the cochlea; *sp.l*, spiral lamina; *n*, nerve-fibres; *l.sp*, spiral ligament; *str.v*, stria vascularis; *s.sp*, spiral sulcus; *R*, section of Reissner's membrane; *l*, limbus laminæ spiralis; *m.t*, membrana tectoria; *tC*, tunnel of Corti; *b.m*, basilar membrane; *h.i*, *h.e*, internal and external hair-cells.

The head of each outer rod has a process which extends outwards and is known as the phalangeal process. This forms part of the reticular lamina.

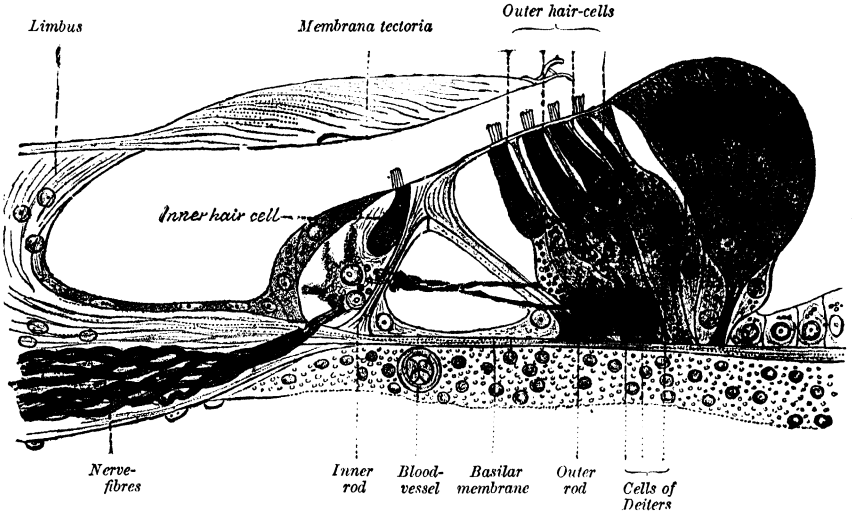

FIG. 747.—SECTION THROUGH THE ORGAN OF CORTI OF THE HUMAN COCHLEA. (G. Retzius.) Highly magnified.

2. A *reticular lamina* (fig. 749, *l.r.*), a cuticular structure extending like a wire net over the outer epithelium-cells of the organ of Corti, composed of two or three series of stiff fiddle-shaped rings (*phalanges*) cemented together in such a manner as to leave square or oblong apertures through which the hairlets of the outer hair-cells project.

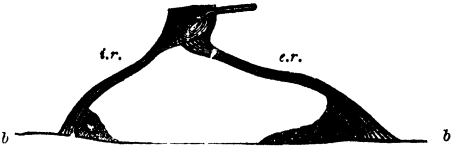

FIG. 748.—A PAIR OF RODS OF CORTI, FROM THE RABBIT'S COCHLEA, IN SIDE VIEW. (E. Sharpey-Schafer.) Highly magnified.

b, *b*, basilar membrane; *i.r.*, inner rod; *e.r.*, outer rod. The nucleated protoplasmic masses at the feet, which represent the cells from which the rods have been formed, are also shown.

3. The *outer hair-cells* placed external to the rods of Corti. These are flask-shaped cells, forming three series in most mammals but four in man (fig. 747) except in the upper part of the cochlea, where there are five rows. The free extremity of each cell is surmounted by a bundle of short *auditory hairlets*, and projects through one of the apertures in the reticular lamina; the fixed extremity is prolonged into a stiff cuticular process, which is attached to the basilar membrane. Between the hair-cells are other

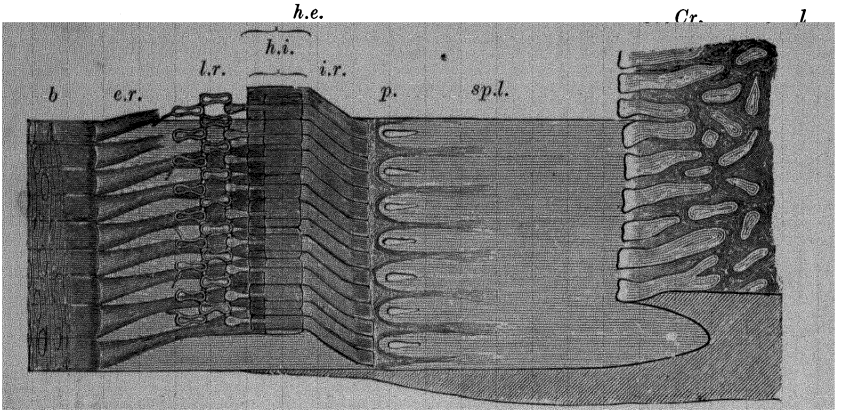

FIG. 749.—SEMI-DIAGRAMMATIC VIEW OF PART OF THE BASILAR MEMBRANE AND TUNNEL OF CORTI OF THE RABBIT, FROM ABOVE AND THE SIDE. (E. Sharpey-Schafer.) Much magnified.

l, limbus; *Cr.*, extremity or crest of limbus with tooth-like projections; *b*, basilar membrane; *sp.l.*, spiral lamina with, *p*, perforations for transmission of nerve-fibres; *i.r.*, fifteen of the inner rods of Corti; *h.i.*, their flattened heads seen from above; *e.r.*, nine outer rods of Corti; *h.e.*, their heads, with the phalangeal processes extending outward from them and forming, with the two rows of phalanges, the lamina reticularis, *l.r.*

(sustentacular) cells which are tapered in the same manner, but rest by their larger end upon the basilar membrane, and are prolonged above into a cuticular process which is attached to the reticular lamina (*cells of Deiters*, figs. 747, 750).

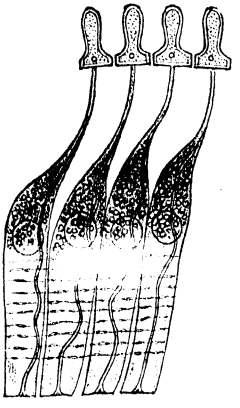

FIG. 750.—FOUR CELLS OF DEITERS FROM THE RABBIT. (G. Retzius.) Highly magnified.

The varicose lines are nerve-fibrils. The phalangeal processes are attached above to a portion of the lamina reticularis.

4. The *inner hair-cells* (fig. 747), placed internal to the rods of Corti. They form a single series of columnar cells surmounted by auditory hairlets, lying in close apposition to the inner rods. The number of hairlets per cell, in both inner and outer series, is estimated for man at about 100, and at 60 for anthropoids; but there are only 8 to 12 in the lower mammals.

The remaining epithelium-cells have no important characteristics. They are long and columnar next to the outer hair-cells, but soon diminish in size and become cubical; in this form they are continued over the outer wall of the cochlear canal. Here they cover a very vascular membrane (*stria vascularis*, fig. 746, *str.v*), which is frequently pigmented; its capillary blood-vessels penetrate between the epithelium-cells. Internal to the inner hair-cells the epithelium also soon becomes cubical: it is prolonged over the limbus of the spiral lamina into the epithelium of Reissner's membrane which is of the pavement variety.

The *membrana tectoria* (figs. 746, 747, 751) is a soft, fibrillated structure, which is attached along the upper surface of the limbus where it is thin:

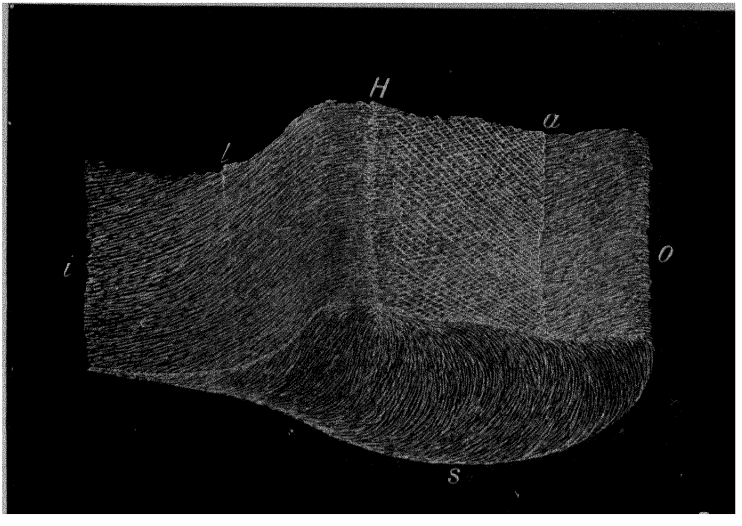

FIG. 751.—PORTION OF MEMBRANA TECTORIA OF PIG, DISPLAYING THE UNDER SURFACE AND A CROSS SECTION. (Hardesty.)

i, thinner edge by which it is attached to the limbus; *o*, distal edge; *s*, section showing arrangement of crossed fibres; *l*, line impressed by edge of limbus; *H*, line of Hensen, which overlies the heads of the rods of Corti; *H* to *a*, latticed layer on under surface. The thin prolongation at the distal edge is not shown.

it lies like a pad over the organ of Corti. It has a thin distal prolongation which is reticular in appearance when seen on the flat. According to



FIG. 752.—GENERAL VIEW OF THE MODE OF DISTRIBUTION OF THE COCHLEAR NERVE, ALL THE OTHER PARTS HAVING BEEN REMOVED. (Arnold.)

Retzius this thin part is attached to the lamina reticularis. The lower surface of the membrane rests on the epithelium of the organ of Corti during

life, although in sections it usually appears raised a short distance above the auditory hairs.

The fibres of the cochlear branch of the auditory nerve enter the base of the columella, and run in canals through its substance (figs. 744, 745), being gradually deflected outwards as they pass through it into the spiral lamina (fig. 752); at the base of this they pass into a continuous ganglionic cord (*spiral ganglion, ganglion of the cochlea*). It is from the bipolar cells of this ganglion that the auditory fibres originate.



FIG. 753.—ENDING OF SOME OF THE FIBRES OF THE COCHLEAR NERVE AMONG THE HAIR-CELLS. (G. Retzius.)

This preparation is made by Golgi's method, and is viewed from above. *g*, a cell belonging to the spiral ganglion.

The peripheral fibres (fig. 753) pass out from the other side of the ganglion-cells. Traversing the spiral lamina they emerge in bundles, and, having lost their myelin sheath, enter the inner hair-cell region. Here some of them turn at a right angle and are directly applied to the inner hair-cells, while others cross the tunnel of Corti, to become applied in like manner to the outer hair-cells and the cells of Deiters (fig. 747). The nerve-fibrils apparently lie in close contact with these cells, but it is usually stated that there is no direct continuity between the fibrils and the cell-substance. But some authors affirm that they can be traced into the cytoplasm of the cells of Deiters and that the same is true for the nerve-fibres which end in the cristæ of the ampullæ of the semicircular canals, and in the maculæ of the saccule and utricle (Kolmer).

APPENDIX

METHODS USED IN HISTOLOGY.

In most cases, before tissues and organs are ready to be examined with the microscope, they must be fixed. In fixation the preservation of the cell-structure in as life-like a condition as possible is aimed at.

Since the cells and tissues are usually colourless, and their components are often of rather similar refractive indices, it is advantageous to stain the constituents by dyes after fixation.

It is also generally necessary to reduce the thickness of tissues before they can be microscopically examined. This may be done in various ways, viz.:—

1. By *smearing* the tissue elements in a very thin layer on to a glass slide. This method is employed for fluids containing cells, such as blood.

2. By *dissociating* the tissue elements by mechanical means (teasing), or by chemical agents.

3. By *cutting* the organ or tissue into very thin sections; one, or, at most, two or three cells thick. This method has the advantage that the relationship of the cells is not disturbed. Sections are made with a microtome. It is needful to support the tissue while being cut; with this object, it is embedded, after fixation, in some medium which is applied to it in the fluid condition and becomes solid on standing. Either the embedding substance can simply enclose the tissue, or the tissue may be soaked in it; the latter method is the one nearly always employed.

Finally, the tissue, which may have been stained, is mounted on a slide in a preservative medium of suitable refrangibility. It is then ready for examination.

MOUNTING SOLUTIONS.

Normal salt solution.—A 0·6 to 0·9 per cent. solution of common salt is used in place of serum for mounting fresh tissues for immediate examination. The lower percentage is used for frog tissues, the higher for mammals.

Ringer's solution may be substituted for normal salt solution with advantage. The composition of Ringer's solution for mammalian tissues is as follows: NaCl, 0·9 grm.; KCl, 0·042 grm.; $CaCl_2$, 0·024 grm.; $NaHCO_3$, 0·01 grm.; in 100 c.c. distilled water. (See note, p. 32.) For frog tissues 0·6 grm. NaCl. Preparations mounted in salt solutions cannot be preserved permanently.

Glycerine, diluted with an equal quantity of water. The cover-glass should be fixed by gold size.

Farrant's solution.—This is made by dissolving 10 grm. of clear picked gum arabic in 10 c.c. distilled water and mixing with 5 c.c. glycerine. A piece of camphor is added to prevent the growth of moulds. As a mounting medium Farrant's solution has the advantage over glycerine of setting firm at the edges of the cover-glass.

Canada balsam, from which the volatile oils have been driven off by heat, dissolved in xylol.

Dammar solution, made by dissolving dammar resin in xylol. The solution is filtered through paper wetted with chloroform. This is used for the same purpose as xylol balsam and has the advantage of remaining colourless, whereas Canada balsam becomes yellow with keeping, and sections stained with hæmatoxylin eventually lose their colour in it.

Acetate of potassium, a nearly saturated aqueous solution. This may be used for mounting osmic preparations and is also employed to preserve the iodine-stain of glycogen within cells. The cover-glass is fixed by water-glass or by gold size.

FLUIDS USED FOR FIXATION.[1]

Formol.—This is a 40 per cent. solution of formaldehyde. It may be made up with water as a 10 per cent. solution (*i.e.* 1 volume of commercial formol to 10 volumes of water). Formol penetrates readily and hardens tissues quickly. Commercial formol contains acid impurities, which render it unsuitable for the fixation of certain tissues. This may be overcome by employing formol exactly neutralised with sodium hydrate or carbonate, or by keeping it in a bottle containing fragments of calcium carbonate. Excess of alkalinity is harmful.

Tissues are fixed by formol in a few hours to a few days ; after fixation they are transferred to alcohol.

For rapid fixation a very small piece of the tissue is placed in 10 per cent. formol and warmed to a temperature of about 45° C. At this temperature it will be sufficiently fixed in half an hour for sections to be made by the freezing method (p. 596). Or the piece may be transferred from the formol solution, first to weak and then to increasing strengths of alcohol, and finally to xylol, so that it is ready for embedding in paraffin in an hour.

Sometimes black granules (of tri-oxymethylene) make their appearance in formol-fixed specimens. They can be got rid of by treatment with 1 to 5 per cent. ammonia in 70 per cent. alcohol.

Mercuric chloride.—This is employed in saturated aqueous solution, alone or in combination, as in susa and Mann's fluid. The following may also be used :—

Mercuric chloride (sat. aq. sol.) . .	90 c.c.
Commercial formol	10 c.c.

Thin pieces of tissue must be used. They should be left in the fixative for from six to forty-eight hours.

[*Note.*—All fixatives containing mercuric chloride demand after-treatment with iodine in order to remove the precipitate of the mercury salt. To effect this, transfer the tissue from the fixative to 90 per cent. alcohol to which has been added sufficient of a 2 per cent. solution of iodine and 3 per cent. potassium iodide in 90 per cent. alcohol to confer a dark brown colour upon the alcohol. After some hours the colour may disappear, in which case more iodine should be added.

For dense or large pieces of tissue the above treatment may need to be supplemented by treating the sections on the slide with a 0·5 per cent. solution of iodine in

[1] The ideal method of fixation of an organ, unless it is desired to preserve the blood-corpuscles, is to perfuse the vessels with Ringer's solution in order to wash out the blood, and to follow with the fixative, which is thus brought into immediate contact with the tissue elements. It is, however, in most cases not possible to employ the perfusion method. Failing this method, only a small piece of the fresh organ should be taken, so that the fixative may penetrate it as rapidly as possible.

90 per cent. alcohol. As iodine is harmful to many stains the excess is then removed by rapidly rinsing with a 0·25 per cent. solution of sodium thiosulphate ('hypo') in water.]

Susa.—The most useful general fixative is that devised by M. Heidenhain and termed by him 'susa.' This is made as follows:—

Distilled water saturated with mercuric chloride	50 c.c.
Trichloracetic acid	2 grm.
Formol	20 c.c.
Acetic acid (glacial)	4 c.c.
Distilled water	30 c.c.

The acetic acid and trichloracetic acid counteract the tendency to shrinkage caused by mercuric chloride. Tissues are cut more easily after susa fixation than after alcohol, formol, or Zenker; the staining qualities are uniformly good. Fix for several hours; then transfer to iodised alcohol (see note above).

Mann's fluid.—This is a good general fixative. It has the following composition:

Mercuric chloride	2·5 grm.
Picric acid crystals	1·0 grm.
Water	100·0 c.c.
Formol (commercial)	10 to 25 c.c.

The formol should be added shortly before use. The time required for fixation and the after-treatment are much as for Bouin's solution.

Bouin's solution.—This has the following composition:—

Picric acid, saturated solution	75 c.c.
Formol	25 c.c.
Glacial acetic acid (or saturated solution of citric acid)	5 c.c.

Place the tissue in this solution for eighteen to twenty-four hours, then for several hours in 80 per cent. alcohol to which have been added a few drops of a saturated solution of lithium iodide or carbonate to wash out the picric acid, changing the fluid occasionally.

This fixative penetrates well and equally. Some of the details of cell-structure are better preserved than after formol alone, and the tissues stain well, provided the picric acid has been thoroughly removed. They can be dehydrated and embedded in the usual way, or they may first be stained in bulk with hæmatoxylin and eosin (see p. 605).

'Bouin' is unsuitable for kidney, salivary glands, or for any cells containing mucigen, which become greatly swollen by the acetic acid. Mitochondria and lipoids are not preserved by it.

Flemming's fluid.—This is useful for showing the structure of nuclei; fat is likewise preserved and stained by it. When used without acetic acid (Gatenby's modification), mitochondria and other cytoplasmic bodies are preserved. Its formula is as follows:—

Chromic acid, 1 per cent.	15 c.c.
Osmic acid, 2 per cent.	4 c.c.
Acetic acid (glacial)	1 c.c.

The solution does not keep long. Very thin pieces of tissue (preferably not more

than 3 mm. in thickness) are fixed in from eighteen to twenty-four hours. To diminish shrinkage, 2 to 5 volumes of distilled water may be added to the fixative. After its action the tissues are washed for several hours in running water and then transferred to 50 per cent. alcohol.

Osmic acid solution.—This is sometimes used alone in 0·5 to 2 per cent. solution, or as vapour. It fixes protoplasm well, but tends to swell most tissues slightly. Fix for 1½ hours in the vapour from a 2 per cent. solution at 37° C. Follow by placing the tissue in 1 per cent. osmic acid in distilled water for several hours. Wash thoroughly and transfer to 50 per cent. alcohol.

Osmic acid does not penetrate readily and is therefore only suitable for the fixation of very small pieces. Its vapour is irritating to the eyes; it must therefore be used with care and covered up. Since the action of light tends to reduce it, its solutions are kept in the dark and in bottles covered with black paper, the stoppers sealed with paraffin. After osmic acid fixation, staining is difficult, but if the sections are treated with a solution of hydrogen peroxide, they stain well (*e.g.* with Delafield's hæmatoxylin). Pal's solution (p. 610) may be used instead of hydrogen peroxide.

Heidenhain's iron-hæmatoxylin and certain aniline dyes (*e.g.* saffranin and gentian-violet) are useful for staining after fixation with fluids containing osmic acid.

Carnoy's fluid.—This has the following composition:—

Absolute alcohol	60 c.c.
Chloroform	30 c.c.
Acetic acid (glacial)	10 c.c.

Carnoy's fluid is in many cases excellent for cell-structure and cell-division, and is very rapid in its action. For soft and delicate objects it is probably the best fixing reagent, *e.g.* it can be used with advantage for the fœtal brain, which shrinks in most fixatives. It is also useful for fixing glycogen in cells. Carnoy's fluid is not indicated for such cytoplasmic components as fat, mitochondria, and Golgi-bodies, since these are dissolved by it.

After half an hour to three hours in Carnoy's fluid, the preparation is transferred to several changes of absolute alcohol to remove the acid, after which it is ready for embedding.

Zenker's fluid has the following composition:—

Mercuric chloride	5 grm.
Potassium bichromate	2·5 grm.
Sodium sulphate	1·0 grm.
Distilled water	100 c.c.
Acetic acid (glacial)	5 c.c.

A stock solution is kept, minus the acetic acid, which is added just before use. 5 c.c. formol may take the place of acetic acid (Zenker-formol). 'Zenker' is a good general fixative requiring from three to twenty-four hours. The tissue is washed in running water for several hours, then transferred to iodised alcohol.

Picric acid is used in saturated aqueous solution. Fix for from three to twenty-four hours. Thoroughly wash out the picric acid with a few changes of 70 to 90 per cent. alcohol (not water).

Potassium bichromate, widely used in the form of Müller's fluid, is employed as a 2·5 per cent. solution, chiefly as a preliminary to certain methods for the nervous system (methods of Golgi, p. 608, and Marchi, p. 610). Prolonged fixation—at least a fortnight—is necessary.

Müller's fluid has the formula:—

Potassium bichromate	2·5 grm.
Sodium sulphate	1 grm.
Water	100 c.c.

Alcohol causes least alteration in the proteins of the tissues. It is useful as a fixative for certain histochemical reactions, *e.g.* for glycogen or iron; it is also employed for special methods for the nervous system. Pure rectified spirit or absolute alcohol is used. The rapid dehydration of the tissues, which occurs as the result of fixation by alcohol alone, generally causes much shrinkage. It is best to use small pieces of tissue and not to leave them more than two to three hours in alcohol before proceeding to embed in paraffin.

The addition of 10 per cent. chloral hydrate to alcohol is an improvement on pure alcohol for certain purposes.

Acetone.—This is used for very rapid fixation. Small pieces of tissue are dropped into a large amount of pure acetone, which not only fixes and hardens, but also dehydrates and clears. The acetone should be changed once. For embedding, the tissue can be transferred direct from the second acetone to molten paraffin.

Better results are got by first placing in warm 10 per cent. formol for thirty minutes, and then transferring to acetone.

Acetone may be used instead of alcohol for dehydrating preparations stained with dyes which are very soluble in alcohol, such as methylene-blue.

PRESERVATION OF TISSUES AFTER FIXATION.

When it is inexpedient to proceed with dehydration and embedding as soon as the tissues are fixed, they may be kept in alcohol of 70 per cent. Formol-fixed tissues may be preserved in more dilute formol than that used for fixation (3 per cent.) until required. Note, however, that organs become tough and difficult to cut into sections if preserved too long and that staining reactions are hampered, especially after long preservation in formol. It is best, therefore, to embed as soon as possible after fixation; the blocks may then be kept indefinitely without deterioration.

METHODS OF DECALCIFICATION.

A tissue is usually fixed in susa or some other general fixative before decalcifying.

Phloroglucin-nitric acid solution.—This is made as follows: Add slowly 10 c.c. nitric acid to 1 grm. phloroglucin. Make up to 100 c.c. with distilled water. More nitric acid (up to 10 c.c.) may be added if required to complete the decalcification.

Small pieces of bone are decalcified in a few hours; they are then washed in running water for twenty-four hours. Decalcification is complete when the bone has acquired a gutta-percha-like consistency and can easily be pierced with a needle.

Sulphurous acid.—Tissues, after fixation in formol, are placed, until decalcified, in a solution of commercial SO_2 (5 per cent.) and subsequently thoroughly washed in running water.

Trichloracetic acid.—A 5 per cent. solution in water fixes and decalcifies at the same time. (Formol may be added up to 10 per cent.) Larger pieces will take from eight to ten days to become decalcified, although forty-eight hours may be sufficient for small objects; test with a needle. Wash out the acid with 96 per cent. alcohol, changing three times at intervals of some hours. [*Note.*—Water must not be used

for this, since, after trichloracetic acid, it causes swelling of the tissues.] The tissue is then dehydrated with absolute alcohol and embedded in celloidin; the sections are stained and passed through alcohol and xylol-creosote (xylol 2 parts, creosote 1 part) to be mounted in dammar.

DEHYDRATION.

Water is immiscible with the two common embedding media, paraffin and celloidin. Complete dehydration, for which absolute alcohol is used, is therefore necessary. Further, tissues are often still too soft after many fixatives for satisfactory sectioning, and the right degree of hardening is attained by treating them with the higher grades of alcohol.

Begin dehydration with 50 per cent. alcohol unless otherwise stated under 'fixation.' Pass through 70 per cent., 90 per cent., 96 per cent. (rectified spirit) into absolute alcohol. For routine work a sojourn of several hours in each grade is required. For rapid work very thin pieces of tissue are placed for one hour only in each grade, and the lower grades—50 per cent. and 70 per cent.—may be omitted, usually at the cost of some shrinkage. If the pieces are large or the tissue dense, the final absolute alcohol bath should be once or twice renewed.

EMBEDDING IN PARAFFIN.

Paraffin wax, of a melting point of about 50° C., is generally used. In a hot climate, or for hard tissues, a paraffin of 55° C. melting point may be required, while in cold weather a paraffin melting at 45° C. will give the best results.

Before the tissue can be impregnated with paraffin the alcohol must be removed, since it is immiscible with paraffin. It is therefore replaced by a substance in which both alcohol and molten paraffin wax are miscible; this treatment is known as 'clearing.' The process is considered complete when the tissues have become translucent and the diffusion currents between the alcohol and the clearing medium have ceased. The latter should always be once changed, in order to remove all traces of alcohol from the tissue.

Clearing fluids.—Xylol.—Although freely miscible with alcohol, ether, resins and paraffin, xylol takes up no water. Therefore very perfect dehydration is necessary, and it is advisable to proceed from absolute alcohol through a mixture of equal parts of absolute alcohol and xylol (or equal parts of creosote and xylol) before transferring the tissue to pure xylol. Xylol, being chemically inert, is suitable for the embedding of material impregnated with silver, gold, or osmium, as it does not affect these. Some clearing fluids, such as turpentine and cedar-wood oil, oxidise and are unsuitable for metal-impregnated tissue. A tissue must not be left too long in xylol, especially if much connective tissue or plain muscle is present, since the hardening it produces in them may make cutting difficult. Thin pieces of tissue are cleared by xylol in one to two hours; bulky specimens may require twenty-four hours.

Toluol.—This is a useful clearing reagent for routine work. It is rather slower in action than xylol, but renders tissues less hard for cutting.

Bergamot oil.—This may be used as an intermediate clearing medium, for it has the advantage that it will mix, on the one hand, with rectified spirit—thus getting rid of the necessity of using the expensive absolute alcohol—and on the other hand, with xylol or toluol.

Spirit of turpentine.—This is miscible with both alcohol and xylol, and can take up a small amount of water, but it interferes with the action of some stains and is not suitable for tissues stained in bulk with hæmatoxylin. It penetrates well and makes connective tissue and smooth muscle easy to cut. It is useful for large (topographical) sections, and for dense tissues such as the uterus, prostate, scalp, etc.

It is not easily extracted in the paraffin bath, but if a trace remains it does no harm, and has the advantage of making the tissue more easy to cut.

Carbon disulphide and tetrachloride.—In embedding through carbon tetrachloride and carbon disulphide, tissues are passed from absolute alcohol into a mixture of absolute alcohol and carbon tetrachloride, equal parts, then into pure carbon tetrachloride for twenty-four hours. They are given two baths of carbon disulphide, twenty-four hours in each, and embedded, through paraffin saturated with carbon disulphide, in pure paraffin. Even if the purest carbon disulphide obtainable is used, brown granules will be found in the periphery of the tissue. But if carbon tetrachloride is used first, the tissue remains free from granules, and carbon disulphide is then used to ensure that the tissue will cut easily. Complete dehydration is essential. Since carbon disulphide has an objectionable smell, it should be kept in tightly stoppered bottles. It penetrates readily and is easily replaced by paraffin. It is possible to cut very thin sections (2 to 3 μ) by using these fluids for clearing.

Chloroform.—For delicate objects fixed in Carnoy's fluid, chloroform may usefully serve as intermediary between absolute alcohol and paraffin. The tissue is transferred from absolute alcohol to a mixture of equal parts of absolute alcohol and chloroform, and from this to pure chloroform; thence to the molten paraffin wax.

IMPREGNATION WITH PARAFFIN.

When the clearing process is completed, the tissue is ready for impregnation with molten paraffin, to which it is now transferred either directly or after passing through a bath of equal parts of the clearing fluid and paraffin. The temperature of the paraffin bath should be only very little above the melting point of the paraffin; if the bath is too hot excessive hardening and shrinkage ensue and the tissue is spoiled.

Thin pieces of tissue may be impregnated in an hour; large, dense objects may require up to twenty-four hours. The paraffin bath should be changed once to eliminate the clearing medium, unless the vacuum type of embedding bath is used. When thoroughly impregnated with paraffin, the object is placed in a paper mould, or in a metal capsule which has been filled with molten paraffin; a solid layer rapidly forms on the bottom, and the piece is arranged on this layer, using a warmed needle or forceps, after which the whole is allowed to cool quickly. A square block of the paraffin containing the tissue is then cut out and oriented on a microtome, for the preparation of sections.

If it is desired to cut a riband of successive sections, and the paraffin used prove too hard for them to stick to one another at the edges, a paraffin of lower melting point (40° C.) is smeared over the opposite sides of the block; the sections then adhere together as they are cut.

EMBEDDING IN CELLOIDIN.

Celloidin is a form of collodion (gun-cotton). Two solutions should be kept, a thick and a thin. The thick solution is prepared by dissolving 15 grm. of dry celloidin in 100 c.c. of a mixture of equal parts of absolute alcohol and ether in a well-corked bottle; the thin, by diluting the thick solution with an equal bulk of the alcohol-ether mixture.

Celloidin supports tissues during sectioning better than paraffin, hence its use is indicated for large and brittle objects. It also has the advantage of causing much less shrinkage. Against it are the time required (several days), the thickness of the

sections (it is hardly possible to get sections thinner than 15 to 30 μ), and the difficulty of keeping the sections in series.

The piece to be embedded should not be thicker than 2 mm. to 3 mm. and should be thoroughly dehydrated with absolute alcohol. Place it (1) in ether-alcohol mixture for a day; (2) in the thin celloidin solution for two or three days: the thicker and denser the tissue the longer the treatment required; (3) in the thick solution for three days. It is now ready for preparing the block for sectioning. (4) Orientate the piece in a small paper box filled with thick solution. (5) Solidify the celloidin by allowing the alcohol-ether slowly to evaporate. For this, place the box in a small desiccator, or beneath an inverted glass dish, and add more thick celloidin solution from time to time, as may be necessary. The mass is sufficiently hard when it has 'attained a consistency such that the ball of the finger (not the nail) no longer leaves an impression on it' (Bolles Lee). (6) Trim the celloidin round the tissue and preserve the block in alcohol of 70 per cent. to 80 per cent.

[*Note.*—During the later stages of the process the setting of the celloidin may be hastened by pouring chloroform on a piece of wool and placing this in the recipient containing the block.]

For sectioning, the celloidin blocks are attached to pieces of wood or roughened vulcanite, which are fixed in the microtome-holder. Smear one surface of the wood or vulcanite with thick celloidin; press the celloidin block on this and allow it partially to harden. Then harden the union still further by exposing to chloroform vapour.

Fish's modification.—This consists in taking the tissues from absolute alcohol into pure acetone; they are then impregnated first with 4 per cent. and then with 8 per cent. solution of celloidin in acetone. The remaining stages of preparation are similar to those above described.

CUTTING OF SECTIONS.

Microtomes.—A section-cutting apparatus (microtome) is essential for histological work. A useful instrument for class-work—for objects which have been embedded in paraffin—is the **tripod microtome**; being inexpensive each student can possess one.

It consists of a metal frame (fig. 754) in which a razor is securely clamped, provided with a micrometer screw, by which the height of the razor-edge is adjusted. The paraffin block containing the tissue is fixed by the aid of heat on to a piece of plate-glass over which the tripod slides. The block should be cut with square, parallel edges after being fixed on the glass. The razor-edge is lowered after each successive section by turning the micrometer screw at the back of the frame from left to right to exactly the same extent each time. In this way either single sections or a series can be cut. For the latter the opposite edges of the block should be smeared with softer paraffin than that used for making the block.

More elaborate instruments for paraffin-embedded tissues are the **rocking microtome** of the Cambridge Scientific Instrument Company (fig. 755) and rotary microtomes such as those designed by **Minot** (fig. 756) and by **Delépine**. Delépine's is also arranged for freezing with liquid CO_2. The action of all these is automatic, *i.e.* every movement of the handle not only cuts a section of the tissue of definite thickness, but also moves either the knife or the block in such a manner that another section of exactly the same thickness is cut by the next movement, and so on indefinitely. By employing a rectangular block of paraffin of the proper consistency, a long series of sections of the same object, of equal thickness, can be obtained and made to adhere together in a riband (as shown in fig. 755). Such sections can be mounted in series upon a slide in any desired number.



FIG. 754.—TRIPOD MICROTOME. (Birch's pattern.) The paraffin block should be cut with square edges.



FIG. 755.—ROCKING MICROTOME WITH SIMPLE OBJECT-HOLDER.

For celloidin-embedded preparations it is necessary to cut the sections with a knife kept wetted with 70 to 80 per cent. alcohol. For this purpose a sliding microtome (fig. 757), in which the knife is moved horizontally over the tissue, with the edge obliquely inclined to the direction of movement, is used. The best arrangement

for this purpose, especially for large sections, such as those of brain, is one in which the celloidin-soaked object is immersed in or flooded with spirit during the process of cutting.



FIG. 756.—MINOT'S AUTOMATIC ROTARY MICROTOME.

For every kind of microtome it is all-important that the edge of the knife or razor should be in perfect order: to secure this, constant stropping is necessary. If the razor-edge has any irregularities every section will be scored by them.

It is sometimes desired to prepare rapidly a section of fresh tissue or of a fixed tissue without the elaborate preparations and time necessary for embedding in



FIG. 757.—INCLINED PLANE MICROTOME.

paraffin or celloidin. The simplest instrument for this purpose is the Cathcart freezing microtome (fig. 758). The tissue, either quite fresh or, if fixed, after being soaked in fairly strong gum arabic or dextrine solution, is placed on the metal plate of the microtome and is frozen by playing an ether or other refrigerating spray on the under surface of the plate. The plate is moved upwards by a finely-cut micrometer screw, and the knife or plane used to cut the sections is guided over

the plate by passing over plate-glass slips. When using a freezing microtome, especially for the nervous system, it is important that the tissue should not be

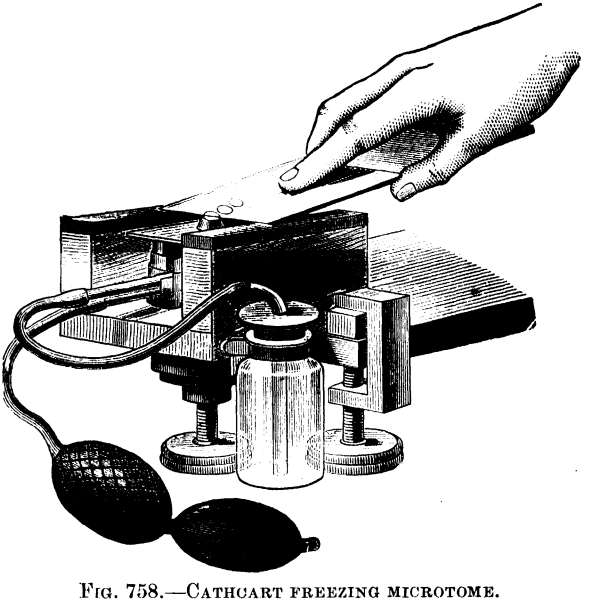

FIG. 758.—CATHCART FREEZING MICROTOME.

frozen too hard, otherwise the sections will roll up and crack. In such a case the surface can be temporarily thawed just before cutting by breathing upon it.

GENERAL TREATMENT OF SECTIONS.

Treatment of sections cut from paraffin.—The sections, after being cut with a microtome, are fixed to a glass slide, as a preliminary to being treated with stains and other fluids.

The procedure is as follows: The slide, after having been cleaned with spirit, is smeared very lightly with fresh white of egg, using the thinnest part of the albumen; or with a mixture of equal parts of egg-white and water to which a little phenol has been added as a preservative. The smearing can be done with the finger or with a clean rag; the albumenised slide is then put aside to dry, protected from dust. A dilute solution of agar jelly, 1 grm. per 1000 c.c. distilled water, may be used in place of white of egg. It is convenient to prepare a large number of slides at a time, and to keep them at hand in a dust-proof receptacle. When required for use a little water is poured on to the slide and the riband of sections is placed on the water, which is then warmed on a hot plate or over a small flame until the paraffin becomes flattened out, without actually melting. It is not always necessary to use albumenised slides for fixing the sections. For many objects, especially those fixed with formol and alcohol, an ordinary well-cleaned slide answers the purpose, the section or sections being, as before, flattened out in a drop of warmed water. In either case the water is then drained off; the slide put aside if necessary in a warm place, but not warm enough to melt the paraffin. After the remainder of the water has evaporated (this will take at least half an hour), the slide is heated just sufficiently to melt the paraffin. The slide is next immersed in xylol (which should be changed at least once) to remove the paraffin, after which the sections may, if already stained, be mounted at once in

dammar. If not stained, the slide is transferred from xylol to absolute alcohol and then to gradually lower grades of alcohol (75 per cent. to 50 per cent.). From 50 per cent. alcohol it is passed into distilled water and from this transferred to the stain. After the staining is completed it is passed back, through water, alcohol (in grades, ending with absolute alcohol), and xylol, into dammar. For many sections some of the grades of alcohol can be omitted, but it is always well to employ 50 per cent. alcohol and 96 per cent. alcohol between water and absolute alcohol, and to wipe off excess of moisture before placing the slide in the absolute alcohol.

Another method of fixation, and one which, in most cases, answers the purpose, is to place the riband or the individual sections cut from paraffin on the surface of water in a basin, the water being just sufficiently warm to flatten out the paraffin, but not to melt it. Then pass a perfectly clean slide under the surface of the water and float the sections on to it; remove, drain off the water, and put the slide and sections aside, in an incubator if necessary, until completely dry. The sections will have adhered firmly to the slide. They may be yet more firmly fixed by drawing a brush moistened with solution of celloidin in oil of cloves over them. The paraffin can now be removed by washing the slide with xylol or immersing it in xylol. If not previously stained the sections can then be passed through alcohols and stained and mounted as above described. After certain hardening solutions have been used (bichromates or osmic acid) the sections cannot be fixed by the water-method alone, but albumenised slides must be employed.

The following table epitomises the procedure to be adopted for the treatment of paraffin-cut sections or ribands of sections:—

1. Float on to a slide in warm water: the slide may previously have been albumenised.
2. Drain off water and dry *completely* in the warm but without letting the paraffin melt.
3. Warm until paraffin is just melted.
4. Dissolve paraffin away with xylol.

If tissue is already stained in bulk.	If tissue is not already stained.
5. Mount in dammar.	5. Absolute alcohol; and 6. Descending grades of alcohol ending with 50 per cent. distilled water. 7. Staining solution. 8. Water. 9. Ascending grades of alcohol; ending with absolute. 10. Xylol (this may be preceded by bergamot oil). 11. Mount in dammar.

It is convenient to keep the several solutions which are required for removing the paraffin and for staining, dehydrating, and clearing the sections after they are fixed to the slide, in grooved glass or porcelain receptacles arranged in a regular row upon the working table, the slide being transferred from one to the other in succession. Such a series would be (1) xylol; (2) absolute alcohol; (3) 96 per cent. alcohol; (4) 50 per cent. alcohol; (5) distilled water; (6) staining solution; (7) tap water; (8) distilled water; (9) 50 per cent. alcohol; (10) 70 per cent. alcohol; (11) absolute alcohol; (12) xylol. The changes are sometimes effected by pouring the solutions over the sections from drop bottles and draining off.

After the paraffin has been removed from the sections by xylol they must never, on any account, be allowed to dry, or they will inevitably be spoiled.

Treatment of frozen sections.—The sections are removed from the knife with a camel-hair pencil and placed in a dish of normal saline if fresh, or water if fixed. They must be transferred with care from one solution to another: small metal spatulæ are useful for this purpose. If the tissue has already been stained in bulk, the sections are put through Nos. 9, 10, and 11 of the scheme on p. 598. If the tissue has not already been stained begin at No. 7.

Treatment of celloidin sections.—As already mentioned, while cutting these, the knife is kept wet with 70 to 80 per cent. alcohol; the sections are transferred to a dish of alcohol of the same grade. Celloidin sections may be manipulated like frozen material; they, however, stand transference better. They are treated according to the scheme on p. 598 with the following important reservations:—

Alcohol of a higher grade than 95 per cent. must be avoided; so also must oil of cloves, since celloidin is soluble in these fluids. Therefore, dehydrate in 95 per cent. alcohol and pass the sections through a medium capable of absorbing the remaining water. The following mixture is recommended:—

Acetone (anhydrous)	1 volume
Xylol	4 volumes

After a few minutes in this, the sections are cleared in pure xylol and mounted in dammar. Origanum oil or bergamot oil can be used in place of acetone-xylol mixture.

STAINING METHODS.

Staining by dyes is dependent partly upon the physical processes of osmosis and adsorption, partly upon chemical affinities. The theory of stains has been treated of at great length by various authors: it would occupy too much space to discuss the matter in this work. The methods of staining employed for teased preparations have already been dealt with under the several tissues.

INTRA VITAM STAINING.

It is sometimes desirable to stain cells or tissues by injecting colouring matters into a blood-vessel during life, such dyes being employed as will be taken up from the circulating fluid by special constituents of the cells, for which the dyes in question have a special affinity.

The **basic dyes** which have been chiefly used for this purpose are *methylene-blue*, which has a special affinity for nerve-fibres, and is treated of in dealing with methods of staining nerve-endings (p. 614), *neutral red*, *Janus green*, and *vesuvin*.

Neutral red.—This is a basic dye of a neutral tint, converted by alkalies to yellow and by acids to red. It is relatively non-poisonous, and can be used for *intra vitam staining* as a concentrated solution in normal saline, about 12 c.c. being injected hourly into a rabbit until the skin is deep red. It brings to view the cell-vacuoles, and colours certain cell-granules intensely. Bensley has used it as a dilute solution for exhibiting by its selective stain the islets of Langerhans of the pancreas.

Janus green.—This is a basic aniline dye readily soluble in water. It can be employed either in strong solution in small amount or in a very dilute solution in normal saline for intravenous injection. It is used for staining nerves intravitally, and for selectively colouring granules in cells. Bensley has employed it, as well as neutral red, for showing the islets of Langerhans. It is recommended for staining mitochondria in living cells, the fresh tissue being placed in a solution of 1 in 5000 in saline.

Vesuvin.—This is used as a 0·3 per cent. solution in saline. The tissue can subsequently be fixed with 0·2 per cent. chromic acid, or 1 per cent. osmic acid, and prepared for sectioning in the usual way.

The **acid dyes** which have been used for vital staining differ from the basic dyes in being more selective. They are taken up mainly, or entirely, by a particular class of cells, viz. those belonging to the reticulo-endothelial system of Aschoff (p. 105). The stains which have been chiefly used for this purpose are **lithium carmine, trypan blue,** and **pyrrhol blue.** They are injected into the vascular system in dilute solution in normal saline. The animal is killed usually after repeated injections, and the tissues examined either in the fresh condition in saline or after fixation by various agents and subsequent sectioning.

STAINING OF SECTIONS.

The fluids most commonly employed for the staining of sections are: (1) Solutions of hæmatoxylin and alum; (2) solutions of carmine with or without alum; (3) certain aniline dyes. The time of immersion in the staining fluid varies according to the strength of the fluid and the mode by which the tissue has been hardened.

The necessity of staining sections may in some cases be avoided by staining the tissue in bulk before embedding (p. 605). For this purpose a small piece of fixed tissue, well washed with distilled water, is placed for twenty-four hours or more in dilute solution of Delafield's hæmatoxylin, or of Ehrlich's hæmatoxylin or borax-carmine. The tissue is then passed through ascending grades of alcohol into absolute and then through xylol saturated with alcohol-soluble eosin into paraffin, the sections being mounted in dammar.

If to be cut by the freezing method the tissue is soaked in gum after being stained. The sections are placed in water to remove gum, floated on to a slide, and the excess of water allowed to drain off. Alcohol (50 per cent.) is dropped on them from a drop bottle and the sections pressed flat with blotting or tissue paper. This fixes them to the slide. They are then dehydrated by absolute alcohol and passed through xylol into dammar.

If the tissue has not been stained in bulk the sections are stained after being fixed on the slide as described on p. 598. The most useful general method for class purposes is to immerse the slide on which the sections from paraffin are fixed, and which has been carried through xylol and alcohol into distilled water, in Delafield's hæmatoxylin solution for some minutes; after rinsing with tap water they are counterstained with aqueous solution of eosin for a few minutes, and then carried through alcohol and xylol into dammar.

HÆMATOXYLIN STAINS.

Hæmatoxylin is generally combined with alum in staining solutions. Good general fixatives prior to staining with hæmatoxylin are formol, mercuric chloride-formol, susa, and Bouin. Sections are stained until the nuclei stand out clearly and the protoplasm and connective tissues are still almost colourless when viewed with a low magnifying power. But it is sometimes well to overstain and then differentiate with 0·5 per cent. HCl in aqueous solution till the above condition is attained. Tissues fixed with Flemming or other chrome-osmium mixtures are very resistant to hæmatoxylin (but see p. 590).

Delafield's hæmatoxylin.—This is made as follows: To 150 c.c. of a saturated solution of potash alum in water add 4 c.c. of a saturated solution of hæmatoxylin in alcohol. Let the mixture stand eight days, then decant, and add 25 c.c. of glycerine and 25 c.c. of methyl alcohol. The solution must stand a few days before it is ready for use. It is kept as a stock-solution.

For use the stock-solution is diluted with water, 1 in 5. *Distilled water, not tap water,* must be used. The activity of the stain increases for a few months, but after that decreases. The time necessary for staining sections varies with the sample of stain and the fixative which has been employed. Sections stained with Delafield may be counterstained with eosin (p. 602); this is the usual class method of preparing sections for microscopic examination. When the requisite depth of hæmatoxylin stain has been attained, the sections are well washed in tap water. The slight alkalinity of the tap water neutralises any acid present; the sections become bluer, losing any reddish tinge. The neutralisation may be effected more quickly by inverting the slide over dilute ammonia and exposing to the vapour for a second, then washing thoroughly in water.

Ehrlich's hæmatoxylin.—Dissolve 2 grm. hæmatoxylin in 100 c.c. alcohol; add 100 c.c. water, 100 c.c. glycerine, and 10 c.c. glacial acetic acid: also potash alum to saturation. This solution will keep almost indefinitely: it is valuable for staining in bulk, since it does not easily overstain. For sections the solution may be diluted either with distilled water or with a solution containing one part alcohol to two parts distilled water. After the sections have been stained they must be thoroughly washed with tap water. Since this stain contains acetic acid, a longer time is required to blue the sections than with Delafield.

Kultschitzky's hæmatoxylin.—Dissolve 1 grm. hæmatoxylin in a little alcohol, and add to it 100 c.c. of a 2 per cent. solution of acetic acid.

Hæmatëin.—Hæmatoxylin-alum solutions acquire their colouring properties only as the hæmatoxylin on keeping becomes oxidised into hæmatëin. The latter substance may, therefore, as recommended by Mayer, be used in place of hæmatoxylin if the stain is required immediately. The following is the mode of preparing the solution: Dissolve 50 grm. of ammonia alum in 1 litre of distilled water, and 1 grm. of hæmatëin in 100 c.c. of rectified spirit. Add the hæmatëin solution gradually to the alum. The mixture is ready for staining at once, either as it is or diluted with distilled water. A small piece of thymol or a little phenol should be added to prevent the growth of moulds.

Heidenhain's iron-hæmatoxylin method.—Fix sections to slide (pp. 597, 598); transfer to 2·5 per cent. solution of iron and ammonia alum in distilled water and leave a quarter of an hour or longer; rinse with distilled water; place in 0·5 to 1 per cent. pure hæmatoxylin in distilled water containing 10 per cent. alcohol, for a quarter of an hour; wash with water; differentiate in the iron and ammonia solution until nearly decolorised. The sections must be examined from time to time with a low power after washing away the iron alum with tap water, which interrupts

the differentiation. After differentiation wash for fifteen minutes in running water; dehydrate and mount in the usual way. This method is especially adapted for exhibiting the centrioles of cells and the alterations of the nucleus in cell-division. It is a good general method for staining sections.

Both the mordanting with iron-alum and the subsequent staining with hæmatoxylin may often with advantage be considerably prolonged (up to several hours). This is particularly the case for tissues fixed in chrome-osmium mixtures.

COUNTERSTAINS.

Eosin.—As already stated, it is the usual practice to counterstain hæmatoxylin-stained preparations with eosin. An aqueous solution (1 per cent.) is used. The sections are first stained with hæmatoxylin and rinsed with distilled water. They are now stained with the eosin solution, passed through 70 per cent. alcohol, and then through absolute alcohol—which is allowed to dissolve out some but not all of the eosin—into xylol: they are finally mounted in dammar. Erythrosin may be used in place of eosin.

Eosin colours hæmoglobin an orange-red, so that the blood-corpuscles are well shown when a fixing fluid (such as mercuric chloride, bichromate of potassium, or formol), which does not remove the hæmoglobin from them, has been employed.

Chromotrop 2R.—This is a good protoplasm stain to use after Delafield's hæmatoxylin. The sections are blued with ammonia vapour after the hæmatoxylin and then passed through dilute alcohols to absolute alcohol. They are placed for two minutes in a saturated solution of chromotrop 2R in absolute alcohol, rinsed in alcohol, transferred to xylol, and mounted in dammar. Chromotrop gives a beautiful colour contrast and a sharper staining of connective tissues than eosin; it is permanent.

Thiazin red.—This is a water-soluble, permanent aniline dye to be used after Delafield's hæmatoxylin, or Heidenhain's iron-hæmatoxylin. Sections stained in hæmatoxylin are placed for from two to five minutes in a solution of

Thiazin red, 0·5 per cent. in water . . .	45 c.c.
Concentrated picric acid	5 c.c.
Alcohol, 96 per cent.	15 c.c.
Distilled water	100 c.c.

They are then alkalinised by inverting over ammonia vapour, passed through water and alcohol into xylol, and mounted in dammar. Before counter-staining with thiazin red, Delafield-hæmatoxylin sections require only to be rinsed. Iron-hæmatoxylin sections must be washed for fifteen minutes in running or frequently changed tap water.

Carmalum.—This is useful either for sections or bulk staining. If the sections are subsequently passed through alcohol containing picric acid in solution a double stain is produced.

Carminic acid or carmine . . .	1 grm.
Ammonia alum	10 grm.
Distilled water	200 c.c.

Boil together, allow to cool, and filter. Add 1 c.c. formol or phenol to prevent the growth of moulds.

Borax-carmine.—Dissolve 4 grm. borax and 3 grm. carmine in 100 c.c. of water with the aid of heat. Add 100 c.c. of 70 per cent. alcohol, let stand two days or

more and filter. This solution improves on keeping. It is useful for staining in bulk. The piece of tissue can be left in it for several days or even weeks, and is transferred, without washing, to 70 per cent. alcohol containing 5 drops of hydrochloric acid to 100 c.c. in order to fix the colour: it should remain in this for two or three days. Then proceed with dehydration.

Van Gieson's stain.—This consists of a saturated solution of picric acid in water, with 5 c.c. of a 1 per cent. aqueous solution of acid fuchsin added to each 100 c.c. It stains the white fibres of connective tissue bright red; elastic fibres, muscle-fibres, and epithelium yellow. Sections are first stained deeply with hæmatoxylin, blued with tap water, then placed in Van Gieson for five minutes, then passed rapidly through 96 per cent. alcohol, absolute alcohol and clove oil or xylol, and mounted in dammar. The method is valuable for the nervous system, especially as a counter-stain in the Weigert-Pal method; for this it is recommended to increase the proportion of the acid-fuchsin solution to fifteen parts per cent.

ANILINE DYES.

These are used either in simple aqueous solution, or in 0·01 per cent. solution of caustic potash, or in water shaken up with aniline oil. It is usual to overstain a tissue with them, and subsequently to decolorise with absolute alcohol containing one-fifth its bulk of aniline oil. From this the sections pass through absolute alcohol and xylol into dammar. The aniline colours most used are the 'basic' dyes, methylene-blue, gentian violet, toluidin blue, thionin, saffranin, and vesuvin; and the 'acid' dyes, erythrosin, acid fuchsin, orange G, and methyl blue. Double staining is often carried out. Most of the following methods are of this character.

Alcohol-soluble eosin and methylene-blue.—The sections are stained for one minute in 1 per cent. alcohol-soluble eosin, and, after rinsing with water for another minute, transferred to 1 per cent. methylene-blue in water, after which they are again rinsed, and the slide wiped dry of moisture; they are then decolorised by absolute alcohol or acetone. If by absolute alcohol, the decolorisation is arrested by xylol.

Jenner's stain.—This is made by dissolving in pure methyl alcohol the precipitate which is produced when eosin solution is added to methylene-blue solution. It is valuable for blood-films, which may be stained for four or five minutes. Then wash dry, and mount in dammar.

Leishman's stain is also largely used for blood-films. It is made by dissolving 1 part pure methylene-blue in 100 parts of 0·5 per cent. sodium bicarbonate solution with the aid of heat and precipitating by five times its bulk of a 0·1 per cent. aqueous solution of yellow, water-soluble eosin. The precipitate is collected on a filter, and when dry is dissolved in methyl alcohol in the proportion of 0·1 grm. to 60 c.c. (Wright). The stain is applied undiluted for one minute to the film in order to fix it; an equal amount of distilled water is then added and mixed by rocking the slide; the diluted Leishman is left to stain for from five to fifteen minutes. The film may then be washed, dried and mounted.

Leishman's stain can be bought as a powder and dissolved as required for use.

Mann's double stain.—A good double stain for sections is the methyl blue-eosin of Mann. To prepare this take 35 c.c. of a 1 per cent. solution of methyl blue in distilled water, and 45 c.c. of a 1 per cent. solution of eosin in distilled water: mix and add 100 c.c. of distilled water. In sections it stains connective-tissue fibres and mucus-containing cells deep blue.

Muir's double stain.—Sections of formol-fixed tissue are stuck on a slide, a saturated solution of alcohol-soluble eosin in rectified spirit poured on and heated over a small flame. When nearly dry rinse with water, place for three minutes in

saturated solution of potash alum, and again rinse. Partially decolorise with alcohol containing a trace of ammonia. Wash again and stain with saturated methylene-blue solution for a few minutes; then rinse once more, pass through grades of alcohol and xylol; mount in dammar.

Acid fuchsin.—A 1 per cent. solution in 50 per cent. alcohol (to which 1 drop of 1 per cent. alcohol-solution of gentian violet may be added per cubic centimeter just before use) is an excellent stain for fresh connective tissue. For this purpose the mixture should be diluted twenty times with Ringer. It colours all the elements of the tissue, but most intensely the elastic fibres.

Mallory's stain.—Sections are treated for three minutes with acid fuchsin (1 per cent.); then washed in water and immersed for several minutes in phosphomolybdic acid. They are then again thoroughly washed in water, and placed for two minutes or more in the following solution:—

Aniline blue	0·5 grm.
Orange G	2·0 grm.
Oxalic acid	2·0 grm.
Water	100 c.c.

After being stained with this they are passed through water, alcohol, and xylol into dammar.

This is a good method for demonstrating connective tissue; it also shows the zymogen granules in gland-cells, and serves to display the various types of cell met with in the gastric glands.

Heidenhain's 'azan' stain.—This is a modification of Mallory's and for most tissues an improvement. Zenker's fluid, susa, or other sublimate mixtures are the best fixatives to employ for it, but good results are also obtained after Bouin and formol.

Place sections for one hour at 55° C. in 0·2 per cent. solution of azocarmine Gx acidified with 1 per cent. acetic acid. Rinse in distilled water. Differentiate in 0·1 per cent. aniline oil in 96 per cent. alcohol until protoplasm and connective tissue are pale pink and nuclei stand out sharply. The differentiation proceeds sufficiently gradually to allow of perfect control, but if too slow a few drops of distilled water may be added to the alcohol. Control the differentiation by rinsing in acid alcohol—96 per cent. alcohol with 1 per cent. glacial acetic acid. This interrupts the process momentarily. When differentiation is complete, rinse in this acid alcohol. Transfer to 5 per cent. phosphotungstic acid for two hours. In this the connective tissue and protoplasm become quite colourless. A pure nuclear stain in thus ensured, while the connective tissue is mordanted for the aniline blue. Rinse in distilled water. Counterstain with orange G and aniline blue. For this purpose a stock solution is prepared as follows:—

Orange G	2 grm.
Aniline blue, water-soluble (Grübler)	0·5 grm.
Acetic acid	8 c.c.
Distilled water	100 c.c.

Dilute for use with twice its volume of water. Stain until the very finest fibres of connective tissue are sharply stained; rinse with distilled water. Dehydrate quickly through 96 per cent. and absolute alcohol, clear in xylol, mount in dammar.

[*Note.*—Azocarmine Gx (Badische Anilin- u. Soda-Fabrik) is an acid aniline dye, obtained as a dark red powder, very insoluble in water. A 0·2 per cent. solution is made with boiling distilled water, filtered on cooling, and acidified to 1 per cent.

with acetic acid. This contains very fine needle crystals, but at the staining temperature they are in solution. In the counterstain Heidenhain has replaced the oxalic acid of ordinary Mallory with acetic acid, since oxalic acid is harmful to azocarmine.]

The azan method colours the nuclear chromatin red, protoplasm pink, connective tissue, including basement membranes and the fine reticular fibres of lymph-glands, blue; muscle yellow to red, according to the fixative; bone-corpuscles red; cell-granules red, yellow, or blue, according to their nature; neuroglia-cells red.

The method brings out very clearly the presence of small bundles of plain muscle-cells in much connective tissue. It is useful for embryonic tissues, for lymphatic structures, and for glandular organs, especially thyroid and ovary. It is very permanent.

Azocarmine B.—This is an acid, water-soluble aniline dye. Sections are first stained in Delafield's hæmatoxylin for ten minutes, rinsed in distilled water, and then placed for ten minutes in the following solution:—

Azocarmine B, 1 per cent. . . .	3 parts
Distilled water	6 parts
Acetic acid	a trace

Differentiate in 1 per cent. picric acid solution, rinse in distilled water, bring through alcohols to xylol, alkalise over ammonia, and mount.

This is a good and permanent stain after Delafield's hæmatoxylin. It is a selective stain for keratin, differentiation being continued until the red colour has faded from the other tissues. It is recommended for striated muscle.

Azocarmine Gx with indigo carmine and picric acid.—Sections fixed with susa are stained fifteen to thirty minutes in a solution of azocarmine Gx at 55°, and differentiated in aniline alcohol. They are rinsed in acid alcohol and placed for fifteen minutes in a solution of 0·2 per cent. of indigo carmine in a saturated aqueous solution of picric acid. They are dehydrated in absolute alcohol, cleared in xylol, and mounted in dammar.

STAINING IN BULK.

Tissues fixed in various ways, but especially in Bouin's solution, may be stained in bulk as follows: Transfer the tissue to Ehrlich's hæmatoxylin diluted with 3 parts of distilled water in the case of invertebrate and embryo material or with 2 parts of 2 per cent. acetic acid if the tissues are from adult vertebrates. The pieces remain in the dilute hæmatoxylin from two to four weeks or longer—according to their thickness, more or less compact structure, and state of development. The hæmatoxylin is changed at the end of the first week. After rinsing, the material is kept for two or three hours in 0·5 to 1 per cent. HCl in 70 per cent. alcohol, washed in tap water overnight, and then passed through the ascending series of alcohols up to 95 per cent. alcohol. This is replaced with a 1 per cent. solution of eosin in alcohol of the same strength, and the pieces are left therein for about a week. They are now washed for some hours in 95 per cent. alcohol, dehydrated in absolute alcohol, cleared in xylol, and embedded in paraffin.

An alternative method of obtaining the eosin counterstain is to add a little eosin to all the alcohols used for dehydrating.

Delafield's hæmatoxylin and borax carmine may also be used for staining in bulk.

Special Methods of Staining.[1]

FOR ELASTIC FIBRES.

Acid fuchsin.—This stains elastic fibres in films or teased preparations of connective tissue (p. 604).

Orcëin.—This is a dye obtained from lichens; it is used for staining elastic fibres in sections of organs. For this purpose 1 grm. orcëin is dissolved in 100 c.c. of 80 p.c. alcohol, containing 1 c.c. hydrochloric acid. The sections are placed in this solution for about an hour. They are dehydrated in alcohol, which removes the excess of stain; then passed through xylol into dammar. Saffranin may be employed as a counterstain.

FOR INTERCELLULAR SUBSTANCE.

Staining with nitrate of silver (v. Recklinghausen).—Wash the fresh tissue with distilled water; immerse in 1 per cent. nitrate of silver solution for from one to five minutes; rinse with distilled water and expose until just brown to bright sunlight. The tissue, if it is a thin membrane, may be mounted in glycerine. But a better plan is to spread it out flat in water on a slide, drain off the water, allow the tissue to dry completely, and then mount it in dammar. This method is used to exhibit endothelium, and generally to stain intercellular substance. It depends upon the fact that the chlorides of the tissues are almost exclusively confined to the intercellular substance. In using this method be careful to avoid any unnecessary manipulation of the tissue, either before or after staining.

FOR MITOCHONDRIA AND CENTRIOLES.

Heidenhain's iron-hæmatoxylin method.—Fix with Gatenby's fluid (p. 589); then proceed as on p. 601 but treat the sections from six to twenty-four hours with the alum and for an equal time with the hæmatoxylin solution.

Regaud's iron-hæmatoxylin method.—Small pieces of fresh tissue are fixed in a mixture of 4 parts of 3 per cent. potassium bichromate and 1 part of neutral formol for four days, changing the mixture every day. Mordant in 3 per cent. potassium bichromate for eight days, changing every second day. Wash in running water for twenty-four hours. Dehydrate in alcohols of increasing strength, from 30 per cent. to absolute, pass through equal parts of absolute alcohol and xylol, clear with xylol, embed in paraffin melting at 56° to 58° C. The sections must be as thin as possible and mounted by the albumen method. Pass them quickly through xylol and absolute alcohol down to water, and mordant in 5 per cent. iron-alum at 36° C. for twenty-four hours. Rinse in distilled water and stain for twenty-four hours in hæmatoxylin solution made by dissolving 1 grm. of hæmatoxylin (cryst.) in 10 c.c. of absolute alcohol and adding 10 c.c. of glycerine and 80 c.c. of distilled water. Differentiate in 5 per cent. iron-alum under microscopic control. Wash in tap water, dehydrate, clear and mount in the usual way. In successful specimens, besides mitochondria, nuclei and centrioles are stained.

Cowdry's method.—Treat the tissue as by Regaud's method until the slides with the sections on them are in distilled water. Pass them for about thirty seconds into 1 per cent. potassium permanganate, rinse in distilled water, and bleach in 5 per cent. oxalic acid for about thirty seconds; wash in several changes of distilled water; stain with aniline fuchsin prepared as follows (Altmann): Add aniline oil to 100 c.c. of distilled water, shake and filter. To the filtrate add 10 grm. of acid fuchsin;

[1] Special methods are also given in the instructions at the beginning of each Lesson.

shake vigorously and let stand for twenty-four hours: the solution must be used within a month. To stain, wipe the slide dry with a cloth, except the small area on which the section is placed; cover the section with the stain and heat over a flame until fumes come off; leave to cool for about six minutes; return the excess of stain to the bottle, and rinse the slide quickly in distilled water. Allow a little 1 per cent. methyl green in water to flow from a pipette over the section, holding the slide over a piece of white paper so that the colour may be seen. Apply the methyl green for five seconds at first and modify as required. Drain off excess of stain; plunge into 96 per cent. alcohol; rinse in absolute alcohol, clear in xylol or toluol; mount in dammar. In successful specimens the nuclei are green, while mitochondria and certain secretion granules (pancreas) are red.

Janus green is also recommended for mitochondria.

FOR GOLGI'S INTERNAL CYTOPLASMIC APPARATUS.

Cajal's uranium method.—Pieces of fresh tissue, 4 mm. thick, are placed for eight hours in the following solution:—

Uranium nitrate	1 grm.
Neutral formol	15 c.c.
Distilled water	85 c.c.

It is best to use tissue from young animals; rinse in distilled water and place in 1·5 per cent. silver nitrate solution for two or more days at room temperature. Wash quickly in distilled water and reduce for twenty-four hours in

Hydroquinone	1 grm.
Formol	5 c.c.
Distilled water	50 c.c.
Sodium sulphite	0·25 grm.

Rinse with water, dehydrate, and embed either in paraffin or celloidin.

Da Fano's cobalt method.—This is a modification of Cajal's method, and is recommended for routine work; it seldom fails. Pieces of quite fresh tissue no more than 4 mm. thick are fixed for six to eight hours in a solution made up as follows:—

Cobalt nitrate	1 grm.
Distilled water	100 c.c.
Formol	15 c.c.

The solution keeps indefinitely. The formol need not be neutralised unless strongly acid. For embryonic organs and in all cases in which a shrinkage of delicate tissues is to be feared, the quantity of formol may be reduced to 10, 8, or even 6 c.c. for every 100 c.c. of distilled water, particularly during the first one to two hours of fixation, after which the fixing fluid may be changed for one containing 15 per cent. of formol. The time of fixation may be reduced to four or even two hours for very small organs such as the spinal ganglia, pituitary body and suprarenals of mice and rats, as well as for small pieces of pancreas and the like. Pieces of spinal cord, cerebrum and cerebellum from adult mammals give the best results if fixed for ten to eighteen hours. If fixation is carried out in an incubator at 25° to 36° C., mitochondria are shown as well as the Golgi apparatus.

After fixation, the pieces are rinsed in distilled water and transferred to 1·5 per

cent. silver nitrate, where they are left for about two days at room temperature. Each piece is then split into halves and, after rinsing, passed into Cajal's reducing fluid as above.

Dehydrate through the ascending series of alcohols, clear with xylol or cedar-wood oil, and embed in paraffin. The sections can be stuck to slides in series, toned (p. 611), fixed, counterstained, and finally mounted in balsam or dammar in the usual way.

FOR FAT.

Fat is not preserved in paraffin sections, since it is dissolved by the fluids used in clearing. If, however, the material has been fixed in osmic acid, or in a mixture containing osmic acid, a relatively insoluble compound is formed.

Flemming's fluid.—Fix a very small piece in Flemming's fluid (p. 589), wash in water, and embed in paraffin, passing the tissue through the various stages of alcohol and xylol in as short a time as possible. Sections may be counterstained with saffranin or gentian violet on the slide.

Sudan III or Scharlach R.—Fix with 10 per cent. formol. [*Note.*—Formol, although fixing the tissues, does not render fat insoluble, hence fat solvents must be avoided after fixation.] Wash with water, soak in gum solution, and cut with a freezing microtome. Place the sections in 50 per cent. alcohol, stain for half an hour to an hour in Sudan III or Scharlach R, rinse the sections again in 50 per cent. alcohol, and mount in glycerine or in glycerine jelly. If desired, the cell-nuclei may be lightly stained with Delafield's hæmatoxylin after the fat has been stained by Sudan III or Scharlach R.

[*Note.*—Sudan III is employed as a saturated solution in 70 per cent. alcohol; Scharlach R as a saturated solution in equal parts of 70 per cent. alcohol and acetone.]

FOR MUCIN.

The most suitable fixatives are those containing mercuric chloride. Susa is especially indicated. Paraffin sections on the slide are stained for five to thirty minutes in Mayer's muci-hæmatëin ; this has the following composition :—

Hæmatëin	0·2 grm.
Aluminium chloride	0·1 grm.
Glycerine	40·0 c.c.
Distilled water	60·0 c.c.

The nuclei may be subsequently stained with a 1 per cent. aqueous solution of neutral red. Mucin is stained dark blue.

Thionin and methylene-blue also demonstrate mucin, staining it purple.

FOR NERVE-CELLS.

Golgi's chromate of silver methods.—These were originally employed for investigating the relations of cells and fibres. They were introduced by Golgi and improved by Cajal. The following modes of procedure, or modifications of them, are chiefly used :—

α. Very small pieces of the tissue, which has been hardened for some weeks in 3 per cent. bichromate of potassium or in Müller's fluid, are placed (without previous washing) for half an hour in the dark in 0·75 per cent. nitrate of silver solution, and are then transferred for twenty-four hours to a fresh quantity of the same solution, to which a trace of formic acid may be added. They are then placed in 96 per cent.

alcohol (half an hour), and sections, which need not be thin, are cut from celloidin with a microtome; or with the free hand after embedding (but not soaking) with paraffin. The sections should be placed in dammar on a cover-glass and the dammar allowed to dry in a uniform layer. The glass is inverted over a thin glass ring and fixed to a slide with the surface of the dammar dependent and exposed to air. Golgi-stained preparations must not be mounted and covered in the usual way.

β. Instead of being slowly hardened in bichromate, the tissue is placed at once in very small pieces in a mixture of bichromate and osmic acid (3 parts of 3 per cent. potassium bichromate or of Müller's fluid to 1 of osmic acid). In this it remains from one to eight days, a piece being transferred each day to 0·75 per cent. silver nitrate. The subsequent procedure is the same as described above.

For some organs it is found advantageous to repeat the process, replacing the pieces for a day or two in the osmic-bichromate mixture after silver nitrate and then putting them back into silver nitrate (Cajal's double method).

This method is not only more rapid than that in which potassium bichromate alone is used, but is more sure in its results.

A combination of the methods under α and β is often found advantageous. To employ this a number of very small pieces of the tissue are placed in 3 per cent. potassium bichromate as in α. Of these one is every day transferred to osmium-bichromate solution and allowed to remain in this for a few days, after which the silver treatment follows as before.

By these methods nerve-cells and their processes (neuroglia likewise) are stained a dense black.

Nissl bodies.—Fix in 96 per cent. alcohol (or formol followed by alcohol). Make thin paraffin sections. Stain in 1 per cent. methylene-blue, 1 per cent. toluidin blue, or in 0·5 per cent. thionin. Rinse in water and dehydrate rapidly in 90 per cent. alcohol. Then differentiate in Gothard's fluid, which has the following composition:—

Pure creosote	50 c.c.
Cajuput oil	40 c.c.
Xylol	50 c.c.
Absolute alcohol	150 c.c.

Control differentiation with the microscope, clear in xylol, and mount in dammar.

The Nissl bodies and the nucleoli are stained blue. Other cell components are unstained.

Chromotrop 2R (p. 602) may also be used to differentiate and incidentally furnishes a counterstain.

FOR NERVE-FIBRES.

For myelinate fibres. Weigert-Pal method (Schafer's modification).—By this method, normal myelinate nerve-fibres are stained black, while grey matter and sclerosed tracts of white matter are left uncoloured.

Pieces which have been fixed in Müller's fluid, or a day in formol followed by several days in Müller's fluid, are transferred to and kept a short time in alcohol (without previous washing in water). They are embedded in celloidin: sections are cut as thin as possible. As an alternative, sections may be made by the freezing method direct from Müller's fluid, the pieces to be cut being soaked in gum-water for a few hours. In either case, the sections are placed in water, and from this are transferred to Marchi's fluid (p. 610), in which they are left for six hours or more. They are then again washed in water and transferred to Kultschitzky's hæmatoxylin (p. 601). In this they are left overnight, by which time they will be completely black.

After again washing in water they are ready to be bleached. This is accomplished as follows: The overstained sections are placed first in 0·25 per cent. solution of potassium permanganate for five minutes (or in a weaker solution for a longer time), then rinsed with water, and from this transferred to the following bleaching solution (Pal):—

Sulphite of soda	1 grm.
Oxalic acid	1 grm.
Distilled water	200 c.c.

As an alternative diluted sulphurous acid (1 per cent.) may be advantageously employed to bleach the sections instead of Pal's solution.

The stain is usually sufficiently differentiated in a few minutes; but the sections can be left longer in the bleaching solution without detriment. If after half an hour they are not differentiated enough, they must be put again (after washing) into the permanganate for some minutes, and then again into the bleaching solution. When differentiated they are passed through water, grades of alcohol, and xylol to be mounted in dammar.

The advantages which this modification has over the original method are: (1) even the finest myelinate fibres are brought to view with great surety; (2) the staining of the fibres is jet black, and offers a strong contrast to the colourless grey matter; (3) the sections are easily seen and lifted out of the acid hæmatoxylin, which itself has very little colour; (4) it is difficult to overbleach the sections; (5) the stain is remarkably permanent.

For amyelinate fibres. Ranson's method.—This method, although primarily designed for staining amyelinate fibres, is useful for the central nervous system. Amyelinate fibres are stained black, the axons of myelinate fibres gold or brown. The method, which can be relied upon to give good results, is as follows:—

Fix the tissue for forty-eight hours in absolute alcohol containing 1 per cent. of ammonia (conc.). Rinse in distilled water. Place in pyridine for twenty-four hours. Wash the tissue thoroughly (until it barely smells of pyridine) in many changes of distilled water. Place in 2 per cent. silver nitrate for three days at 35° to 37° C. Rinse for fifteen seconds in distilled water. Reduce the silver by placing the tissue for twenty-four hours or more in the following solution:—

Formol, 5 per cent.	100 c.c.
Pyrogallol.	4 grm.

Dehydrate, clear and embed in paraffin.

For degenerated fibres. Marchi's method.—This is of value for staining nerve-fibres in the earlier stages of degeneration, before sclerosis sets in (eight to thirty days after the establishment of a lesion). The degenerated myelinated fibres are stained black, while the rest of the section remains almost unstained. In employing the method for the brain or cord the organ is first fixed and partially hardened by immersion in Müller's fluid for ten days. Pieces of the tissue about 2 mm. thick are then cut and are placed singly, resting on a little cotton-wool, in a relatively large quantity of a mixture of two parts of Müller's fluid and one part of 1 per cent. osmic acid in a glass-covered vessel. They are left in this for at least a week; the fluid should be changed once or twice. The pieces are then washed for several hours in running water. They are passed through ascending grades of alcohol and through xylol and embedded in paraffin. The duration of clearing and embedding must be kept as short as possible, the Marchi stain being slightly soluble in xylol. The sections are mounted—after removing the paraffin with xylol—in dammar without further staining.

Busch's method.—It is claimed that this method gives sharper staining than Marchi's. Fix in 4 or 5 per cent. formol for two to three days, wash in running water for an hour, and transfer thin pieces to the following solution:—

Sodium iodate	3 grm.
Osmic acid	1 grm.
Distilled water	300 c.c.

Leave in this for five to seven days; then dehydrate, clear and embed in paraffin.

FOR NEURO-FIBRILS.

Cajal's silver methods.—(α) A small piece of the tissue (brain, spinal cord, ganglion), not more than 4 mm. thick, and preferably from a young or fœtal animal, is placed in 50 c.c. rectified spirit. After four or five hours in this, followed by twenty-four hours in absolute alcohol, rinse with distilled water and place in a large quantity of 1·5 per cent. solution of silver nitrate, which is maintained at a temperature of about 35° C. After being five or six days in this, the piece is removed, rinsed for a few seconds in distilled water, and transferred for twenty-four hours to the following developing solution:—

Hydrokinone	1 to 1·5 grm.
Distilled water	100 c.c.
Formol	5 c.c.
Rectified spirit	10 c.c.

The piece is then washed in water for some minutes, transferred to alcohol, embedded in celloidin or paraffin, and sections are prepared and mounted in dammar.

(β) Instead of rectified spirit as in (α), absolute alcohol with the addition of from three to five drops of ammonia to each 50 c.c. is used. Fix for twenty-four hours and then proceed as in (α).

After the employment of either method it may be desired to tone the sections. For this purpose the following solutions are prepared:—

(*a*)	Sodium thiosulphate ('hypo')	3 grm.
	Ammonium sulphocyanate	3 grm.
	Distilled water	100 c.c.
(*b*)	Gold chloride	1 grm.
	Distilled water	100 c.c.

Equal parts of (*a*) and (*b*) are mixed just before use. The toning process strengthens the impregnation and substitutes a grey for the previously yellow background; it should only be used when it seems necessary to do this. If, after toning, the background is too dark, the sections can be bleached by Pal's solution (p. 610).

The sections are washed in distilled water, dehydrated with alcohol, cleared, and mounted in the usual way in dammar.

Bielchowsky's method.—Place small pieces of tissue in 12 per cent. formol for twenty-four hours; wash for several hours in distilled water, which should have been redistilled from potassium permanganate; cut sections by freezing method. Then proceed as follows: Place the sections in 2 per cent. nitrate of silver for twenty-four hours; wash in redistilled water for a few minutes. Now transfer them to 2 per cent. nitrate of silver, to every 20 c.c. of which three drops of a 40 per cent. solution of caustic potash are added, followed by enough ammonia to cause the disappearance of the brown precipitate produced. The sections may

be left in this silver nitrate solution for some time. They are then passed through redistilled water into 20 per cent. formol solution made with tap water. After twenty-four hours in the formol, the sections are washed with water, dehydrated and mounted in dammar. But it is sometimes preferable first to tone them with chloride of gold in the following manner:—

To a dish containing 30 c.c. of distilled water add, from a drop-bottle, as many drops of 1 per cent. solution of gold chloride as will give the water a bright yellow colour; then three drops of strong acetic acid. The sections, whether from celloidin or paraffin blocks or made by freezing, are transferred to this gold bath from distilled water and kept therein until the peculiar yellowish-brown colour of the untoned sections has disappeared. Microscopic control may be necessary. The operation may be carried out in daylight. Wash the sections in distilled water, pass them for a few minutes through 5 per cent. sodium thiosulphate ('hypo'), wash again, counterstain if desired, dehydrate, clear, and mount in balsam or dammar.

By this method neuro-fibrils are stained black; the background is yellow when the sections are untoned, violet if toned. Nerve-cells with all their processes are well shown.

FOR NEUROGLIA.

Cajal's gold-sublimate method.—Absolutely fresh material is placed for from two to fifteen days in a solution containing 15 c.c. neutral formol, 2 grm. ammonium bromide, and 85 c.c. distilled water. The shorter periods are for the neuroglia-cells of both grey and white matter; with the longer periods of fixation only the astrocytes of the white matter will be stained.

Sections are cut frozen, 25 to 30 μ in thickness, rinsed rapidly in distilled water and placed in the following solution:—

Gold chloride (brown variety), 1 p.c. solution	6 c.c.
Distilled water	35 c.c.
Mercuric chloride crystallised in needles .	0·5 grm.

Dissolve the mercuric chloride in the gold chloride solution at the moment of use. This amount is sufficient for about six large sections, which are treated individually, each being flattened out, by means of a glass rod, on the bottom of a crystallising dish sufficiently small to give a depth of about 1 cm. of fluid. After about five hours at 20° C. the sections take on an intense purple-red tone, and are then transferred to a bath of distilled water and left for several minutes. They are fixed in

Sodium thiosulphate, 5 per cent. . .	40 c.c.
Alcohol, 96 per cent.	10 c.c.

for from six to ten minutes. After washing for several minutes in one-third alcohol they are arranged on slides, dried by firm pressure with fine filter paper, then treated with absolute alcohol, origanum oil, and xylol, and mounted in dammar. The method gives good results with vertebrate tissues.

Neuroglia-cells are stained a reddish purple; nerve-fibres are relatively unstained.

Cajal's uranium method (p. 607) may also be used for neuroglia, but the tissue must be left in the uranium nitrate solution for from twenty-four to forty-eight hours.

The **Golgi silver chromate methods** (p. 608) are also useful for exhibiting the form, but not the structure, of neuroglia-cells.

FOR NERVE-ENDINGS.

Staining with chloride of gold.—Cohnheim's method.—Place small pieces of the fresh tissue for from thirty to sixty minutes (according to thickness) in a 0·5 per cent. solution of chloride of gold; then wash and transfer to a large quantity of water faintly acidulated with acetic acid. Keep for two or three days in the light in a warm place. This answers very well for the cornea. If it is principally desired to stain the nerve-fibrils within the epithelium, the cornea may be transferred after twenty-four hours (the outlines of the larger nerves should be just apparent to the naked eye) to a mixture of glycerine (1 part) and water (2 parts), and left in this for twenty-four hours longer (Klein). Avoid unnecessary manipulation both before and after staining.

Löwit's method.—Place small pieces of the fresh tissue in a mixture of 1 part of formic acid to 3 parts of water for one minute; then in 1 per cent. chloride of gold solution for fifteen minutes; then back again into the formic acid mixture for twenty-four hours, and into pure formic acid for twenty-four hours more. After removal from the gold, and while in the acid, the tissue must be kept in the dark. This method is especially good for motor nerve-endings in cross-striated muscles.

Ranvier's method.—Immerse in lemon-juice for ten minutes, then wash with water and place in 1 per cent. gold chloride solution for twenty minutes. Then treat either as in Cohnheim's or as in Löwit's method.

Gairn's method.—Mix three volumes of filtered lemon-juice with one volume of pure formic acid. Immerse the fresh tissue (*e.g.* muscle) in this until clear—say for about ten minutes. Pour off the fluid and place the piece of tissue on a clean cloth or on filter paper to drain, pressing gently. Then transfer it for fifteen minutes to 1 per cent. gold chloride solution (just sufficient to cover it). Again transfer it to filter paper to drain off excess of solution and place it in 25 per cent. formic acid in the dark. Transfer it once more to filter paper, to drain off the excess of formic acid, and place it in pure glycerine.

By the above methods nerve-endings are stained dark purple on a reddish background.[1]

Ruffini's method for nerve-endings in muscle and tendon.—Pieces of fresh tissue are immersed in a 25 per cent. solution of pure formic acid for ten to fifteen minutes, using the minimum quantity of fluid for complete immersion. They are then transferred from the acid and pressed gently between pieces of filter paper to absorb as much acid as possible. They are now placed in a 1 per cent. gold chloride solution —sufficient only to cover them thoroughly—for fifteen minutes, agitating until they become an even golden brown. After the excess of fluid is removed by filter paper, they are again placed in a minimum quantity of 25 per cent. formic acid and left in absolute darkness for twenty-four hours. The colour becomes reddish-purple; if still light red or yellow leave for a longer period; if very dark purple the tissue has been over-reduced and must be retoned in the gold solution. Remove the excess of fluid again as above, transfer to pure glycerine, and leave in ordinary light in a closed vessel. The longer the tissue is left in glycerine the clearer it becomes; the best results are got in tissue examined after several years. In both this and the next method the nerve-endings are stained black.

Kultschitzky's method for motor and sensory endings in muscle.—Small shreds of perfectly fresh muscle, preferably snake or lizard, are placed in 20 per cent. formic acid or in lemon-juice. Use as little fluid as possible in proportion to the

[1] For gold chloride and for all acid and metallic solutions rustless steel or non-metallic instruments must be used exclusively.

amount of tissue. Keep the tissue well under the surface, by touching with a glass rod, and leave until transparent (five to fifteen minutes, depending on size). Transfer to a glass plate and remove the excess of acid with filter paper. Place in

Gold chloride, 1 per cent. . . .	1 part
Formic acid, 20 per cent. . . .	3 parts

for half an hour, or until the tissue takes on a distinct yellow tone. Remove the excess of fluid again with filter paper, and keep in 20 per cent. formic acid in the dark, or in water acidulated with a few drops of acetic acid in the light. Leave in this for at least twenty-four hours, preferably two to three days. Transfer to glycerine and water equal parts, or glycerine, water, and alcohol, equal parts, and keep in this. Examine small pieces from time to time. It may be good immediately, but may improve up to one or two years. When good preparations are obtained they are mounted in glycerine and ringed with gold size, or in Apathy's fluid, which is made as follows :—

Pure gum arabic	50 grm.
Crystalline cane sugar . . .	50 grm.
Distilled water	50 c.c.

Dissolve over a water bath and add thymol 0·05 grm.

Kultschitzky's method for nerve-endings in tendon.—Small shreds of tendon with the ends of the muscle fibres are fixed and stained overnight in

Uranium nitrate, 3 per cent. .	100 c.c.
Osmic acid, 1 per cent. . . .	1 c.c.

They are then mounted in glycerine, in Apathy's fluid, or, after dehydrating and clearing, in dammar.

Methylene blue method.—This method is of value for exhibiting nerve-terminations, and the relation of nerve-cells to nerve-fibres. For its application the tissue should be living; it is therefore best applied (Ehrlich) by injecting a solution of methylene blue (1 part to 100 of warm Ringer) into a vein in an anæsthetised mammal until the whole blood is of a bluish colour. Or the injection may be made through the vessels of the part to be investigated, immediately after killing an animal. In that case the solution used should be 0·05 per cent. in Ringer. After half an hour cut the material to be investigated into thin pieces and expose to the air to 'blue' up. (Woollard.)

Good results can also sometimes be obtained by immersing small pieces of freshly excised living tissue in the same dilute solution.

In the case of the central nervous system, methylene blue powder may be dusted over a freshly-cut surface, allowing some time for it to penetrate, and then treating it with picrate of ammonia and Bethe's fluid (see next page).

In every case the tissue must be freely exposed to air when prepared for observation; only then does the blue colour appear in the nerve-cells and axis-cylinders, but in successful perparations they are stained to their finest ramifications. It is not, however, permanent, but after a time fades from the nerves, and other tissues then become coloured. To fix the stain in the nerve-endings, the tissue, the moment that the nerve-fibres are most distinctly seen, is placed for an hour in saturated solution of picrate of ammonia. The preparation can then be mounted in glycerine containing picrate of ammonia. But to allow of sections being prepared and dehydrated for mounting in balsam or dammar, the pieces of tissue

must, subsequently to the treatment with picrate of ammonia, be placed for some hours in Bethe's fluid, viz.:—

Molybdate of ammonia . . .	1 grm.
Chromic acid, 2 per cent. solution .	10 c.c.
Distilled water	10 c.c.
Hydrochloric acid	1 drop

This renders the colour insoluble in alcohol.

In Dogiel's modification the fresh tissue is placed in a glass vessel containing 1 per 1000 methylene blue and kept at 36° C. for two hours. It is then placed in 6 per cent. molybdate of ammonia for twenty-four hours; washed during four hours in distilled water; rapidly dehydrated with alcohol, and passed through xylol into dammar.

INDEX

Acetone, 591
Achromatic spindle, 20
Acid fuchsin, 604, 606
Acidophil leucocytes, 44
Acromegaly, 140
Adenoid tissue, 104
Adenoids, post-nasal, 263
Adipose glands, 100
Adipose tissue, 91, 100
Adrenal glands. *See* suprarenal capsules
Adrenaline, 271
Agglutination of blood-corpuscles, 59
of blood-platelets, 45
Agglutinins, 59
Air-bubbles, 30
Ameloblasts, 344
Amitotic division, 14
Amœba, 3, 41, 72
Amœboid movements, 3, 4
Angioblasts, 47, 49, 238
Aniline dyes, 603
Ansa lenticularis, 519, 540
Anus, 390
Aorta, 225
Appendix, vermiform, 388
Aqueduct of Sylvius, 505, 506
Arachnoid, 466, 541
Archoplasm, 7
Arcuate fibres, 483, 485
Areolar tissue, 91, 92
cells of, 96
fibres of, 92
Arneth count, 42
Arrector pili muscle, 307
Arteries, helicine, 420
vessels and nerves of, 230
structure of, 221
variation in structure of, 225, 228
and veins, smaller, structure of, 234
Articular corpuscles, 206
Association fibres, 531
Astrocytes, 198
Atresia of Graafian follicles, 441
Attraction particle, 3
Auditory hairs, 578, 583
meatus, 575
ossicles, 576
Auerbach's plexus, 377
Auriculo-ventricular bundle, 318
Autonomic nerves, 172
Axis-cylinder, 177, 181, 194
Axon, 177, 181, 200
Azan stain, 604
Azocarmine B, 605
Gx, 604

Bacteria, 31
Baillarger, lines of, 530
Bartholin, glands of, 459
Basement-membranes, 74, 112
Basicytes, 97
Basilar membrane, 580
Basiphil leucocytes, 42, 44, 64
Basket-cells, 522
Bechterew, nucleus of, 492, 493
Bellini, ducts of, 410
Bergamot oil, 592
Bethe's fluid, 615
Betz, giant-cells of, 528, 534
Bielchowsky's method for neuro-fibrils, 611
Bile-channels (bile-canaliculi), 397
Bile-ducts, 397
Bioplasm, 2
Bladder, urinary, 417
Blastoderm, 26
Blood, 32
Blood-corpuscles
action of reagents upon, 57, 61, 63
of man, 32
of Ovipara, 62
red or coloured, 36
agglutination of, 59
development of, 47
enumeration of, 34
hæmolysis of, 57
nucleated, 40
number of, 38, 63
size of, 37, 62
structure of, 36, 63
volume of, 39
white or colourless, 40
amœboid phenomena of, 69
development of, 49, 56
enumeration of, 34
granules of, 41
of man, 42
of Ovipara, 64
mobility of, 43

Blood-crystals, 32
Blood-film, 33
Blood-islands of Pander, 47
Blood-platelets, 36
  agglutination of, 45
  of man, 45
  number of, 46
  origin of, 55
  of Ovipara, 65
  structure of, 45
Blood-vessels, development of, 239
    structure of, 221, 234
Bone, 92, 127
    cells, 127, 131
    development of, 133
    ground substance of, 127
    lacunæ and canaliculi of, 127
    lamellæ of, 127
    marrow of, 52
    regeneration of, 141
Borax carmine, 602
Bouin's solution, 589
Bowman, glands of, 574
    membrane of, 547
Brain, 479. *See* cerebellum, cerebrum, medulla oblongata, mesencephalon, pons Varolii
    divisions of, 479
    membranes of, 541
Brain-sand, 228
Breast. *See* mammary glands
Bridging-fibrils, 75, 78
Bronchi, 326
Bronchial tubes, 326
Bronchioles, respiratory, 330
Brownian motion, 3
Bruch, membrane of, 554
Brünner, glands of, 380
Bundle. *See* tract
Büngner, strands of, 195
Burdach, tract of, 467, 468, 482
Busch's method for staining degenerated nerve-fibres, 611

Cajal, horizontal cells of, 528
Cajal's staining methods, 609, 611, 612
Calamus scriptorius, 483
Calleja, islands of, 499, 537
Canada balsam, 588
Canaliculi, bile, 397
    of bone, 127
    of nerve cells, 180
Capillaries, blood, 235
    circulation in, 236
    contractility of, 237
    lymphatic, 242
Carbon disulphide, 593
Carmalum, 602
Carnoy's fluid, 590
Carotid glands, 275
Cartilage, 92, 116
    articular, 118
    calcified, 119
    costal, 118, 121
Cartilage, development of, 124
    embryonic, 125
    fibro-, 116, 121
    hyaline, 116
    ossification of, 133
    parenchymatous, 125
    transitional, 118
    varieties of, 116
Cartilage-bone, 133
Cartilage-cells, 117
    capsules of, 117
Cathcart's freezing microtome, 596
Cell or cells
  division of, 14
    amitotic, 14
    heterotypical observation of, during life, 20
    reduction, 15
  embryonic, 1, 26
  membrane of, 3
  nucleus of, 2, 10, 14, 20, 23
  plate, 21
  structure of, 10
Celloidin, embedding in, 593
Cell-spaces, 92, 97
Cement of tooth, 339
    substance, 34, 74
Central canal of cord, 462, 464, 483, 484
    fovea of retina, 566
Centriole, 3, 5, 20
    methods for staining, 606
Centrosome, 6
Cerebellum, 520
    grey matter of, 522
    peduncles of, 525
      inferior, 525
      middle, 495, 526
      superior, 505, 507, 526
Cerebro-spinal fluid, 542
Cerebrum, 520, 527
    basal ganglia of. *See* corpus striatum and thalamus
    cortex of, 527
      structure of different parts of, 531
    peduncle of, 509
Ceruminous glands, 311
Chalice cells, 88
Chemotaxis, 3
Chloroform, 593
Cholesterol, 3
Chondrin-balls, 118
Chondriome, 7
Choroid coat of eye, 553
    plexuses, 542
Chromaffin or chromaphil bodies, 271
Chromatin, 11
Chromatolysis, 193
Chromomeres, 12
Chromosomes, 5, 11, 22
    in living cell, 20
    microdissection of, 5
    number of, 11, 12, 15, 22
    and sex, 12, 23

Chromotrop 2R, 602, 609
Cilia, 86
action of, 87
theories regarding, 88
Ciliary muscle, 557
processes, 554
Circulation, 233, 236
Clarke, column of, 472, 474, 476, 478
Clasmatocytes, 72, 96, 106
Claustrum, 528
Clearing fluids, 592
Clitoris, 458
Coccygeal gland, 277
Cochlea, 578
canal of, 576
Cœlom, 248
Cohnheim's areas, 150
method of staining nerve-endings, 613
Collagen, 95
Collaterals, 183
Colliculi, 510
Colliculus nervi optici, 559
Colloid substance of pituitary, 284
thyroid, 278
Colostrum-corpuscles, 312
Columella, 578
Commissural fibres, 513
Commissures of brain, anterior, 540
posterior, 513
v. Gudden, 514
spinal cord, 462
Conjunctiva, 546
Connective tissue or tissues
cells of, 96
development of, 113
features common to, 92
fibres of, 92
jelly-like, 112
origin of, 114
Cornea, 547
nerve-endings in, 551
Corpora albicantia s. mammillaria, 517, 540
amylacea, 288
geniculata, 515
quadrigemina, 510
Corpus albicans, 448
cavernosum, 419
luteum, 444
spongiosum, 419
striatum, 540
subthalamicum, 518
Corti, organ of, 581
rods of, 581
Cotton fibres, 30
Cowdry's staining method for mitochondria, 606
Cowper, glands of, 422
Crista acustica, 578
Crus cerebri, 509
Crusta, 509, 540
petrosa, 335, 339
Cupula terminalis, 578
Cutis vera, 291, 293
Cytology, 2
Cyton, 177
Cytoplasm, 2, 20

Da Fano's method for Golgi apparatus, 607
Dammar mounting medium, 588
Decalcification, 591
Decidua, 454
Decussation of pyramids, 479
Degeneration of nerves, 192
Dehydration, 592
Deiters, cells of, 584
nucleus of, 492, 497, 501
Delafield's hæmatoxylin, 601
Delépine, microtome of, 594
Dendrons or dendrites, 177, 182, 201
Dentine, 336
Derma, 291, 293
Descemet, membrane of, 548
Determination of sex, 23
Diapedesis, 44
Dilatator pupillæ, 557
Discus proligerus, 441
Division of cells. *See* cell, division of
Dobie, line of, 150
Dogiel's methylene blue method, 615
Doyère, eminence of, 219
Ductless glands, 79
Duodenum, 380
Dura mater, 460, 542
Dust in room, 30
lung, 332
lymph glands, 251

Ear external, 574
auditory meatus, 575
Middle, 574
Eustachian tube, 576
membrana tympani, 575
ossicles, 576
tympanum, 575
Internal, 576
cochlea, 576, 578
Corti, organ of, 581
labyrinth, 576
nerves of, 576, 586
saccule, 576
semicircular canals, 577
utricle, 576
v. Ebner, glands of, 349
granules of, 438
Ehrlich, hæmatoxylin stain of, 601
methylene blue method of, 614
Elastic tissue, 94, 108
Elastin, 95
Eleïdin, 291
Ellipsoids, 260
Embedding, methods of, 592
Embryonic cells, 1, 26
Enamel, 335
formation of, 342
organ, 345
End-bulbs, 205
Endocardium, 316
Endomysium, 149

Endoneurium, 174
Endoplasm, 4
Endothelium, 27, 78
lymphatic, 242
serous, 246
End-plates, 196
Enteric nervous system, 220
Eosin, 602
and methylene blue, 603
Eosinophil leucocytes, 42, 44
Ependyma, 464, 494
Epicardium, 316
Epidermis, 291
Epididymis, 426
Epineurium, 175
Epiphysis cerebri or pineal gland, 287
development of, 289
Epithelium, 73
ciliated, 82, 86
columnar, 82, 84
definition of, 73
germinal, 439, 443
glandular, 79
nerve-endings in, 213
pavement, 78
protective, 75
respiratory, 330, 332
scaly, 78
secreting, 75
stratified, 75
transitional, 76
varieties of, 74
Epitrichial layer, 292, 296
Eponychium, 299
Erectile tissue, 419
Erythroblasts, 49, 52
Erythrocytes, 36. *See also* blood-corpuscles, red or coloured
Eustachian tube, 576
Exoplasm, 4
Eye, 544
Eyelids, 545
Eye-piece of microscope, 28

FALLOPIAN tubes, 450
Farrant's solution for mounting objects, 587
Fascia dentata, 537
Fasciculus retroflexus, 510
solitarius, 488
Fat, 100. *See also* adipose tissue
absorption of, by intestine, 385
in cartilage cells, 117
methods for demonstrating, 607
Female pronucleus, 23
Fenestrated membrane, 224
Fibres. *See* connective tissue, muscle, nerve, etc.
Fibrin, 36, 45, 66
Fibroblasts, 96
Fibro-cartilage, elastic, 122
white, 116, 124
Fibrous tissue, 92, 108, 110
Fillet. *See* tract of fillet
Fimbria, 450
Fish's celloidin method, 594
Fixation of tissues, 588
Flechsig, method of, 467
tract of, 467, 485
Flemming, fluid of, 589
germ centres of, 252, 256, 262
stainable bodies of, 253, 256
Forel, decussation of, 509 (footnote)
Formatio reticularis, 446, 484, 485, 493, 497
Formol, 588
Fornix, 535
Fourth ventricle, 494
Freezing method for preparation of sections, 596
Funiculus cuneatus, 462, 482
gracilis, 462, 482

GAIRN'S method for staining nerve-endings, 613
Gall-bladder, 399
Gametes, 13
Ganglia, 177, 187
cells of, 187
development of, 200
spinal, 187
sympathetic, 190
Ganglion of cochlea, 586
glossopharyngeal nerve, 488
habenula, 510, 516
Scarpa, 490
vagus, 487
Gasserian, 498
geniculate, 497
interpeduncular, 510
Gatenby's modification of Flemming's fluid, 589, 606
Generative organs, male, 419
female, 439
Genes, 13
Genital corpuscles, 206
Gennari, line of, 530
Germ centres of Flemming, 252, 256, 262
Germinal epithelium, 439, 443
spot, 443
vesicle, 443
Giant-cells
centrioles of, 6
of bone-marrow, 54
cerebrum, 528, 534
lymph glands, 252
spleen, 256
thymus, 265
Gianuzzi, crescents of, 358
Giemsa's stain, 34
Van Gieson's stain, 603
Gland or glands
agminated, 380
anal, 390
of Bowman, 574
of Brünner, 380
carotid, 275
ceruminous, 311
classification of, 79
coccygeal, 277
Cowper's, 422

Gland or glands
ductless, 79
v. Ebner's, 349
endocrine, 79
externally secreting (or exocrine), 79
gastric, 366
hæmal, 253
internally secreting, 79
lacrimal, 546
of Lieberkühn, 379
of Littré, 422
lymph, 249
mammary, 312
Meibomian, 545
Pacchionian, 542
pineal, 287
pituitary, 282
racemose, 79
saccular, 79
salivary, 356
sebaceous, 308
secreting, 79
serous, 349, 358
solitary, 263
sweat, 310
thymus, 264
tubular, 79
Glia-cells. *See* neuroglia
Glisson, capsule of, 392
Globe of eye, 547
Globus pallidus, 540
Glomeruli of kidney, 408
olfactory, 538
Glycerine, 587
Glycogen, in cartilage cells, 117
colourless blood-corpuscles, 65
liver-cells, 395
Goblet-cells, 88
Gold methods for staining nerve-fibres, 613
Golgi, apparatus of, 3, 85, 171, 180, 275, 278, 365, 369, 388, 400, 426, 436, 441
methods for demonstrating, 607
cells of, 523
methods for staining nervous system, 608
organs of, 211
superficial reticulum of, 181
Golgi-Mazzoni, corpuscles of, 211
Goll, tract of, 467, 468, 482
Gothard's fluid, 609
Graafian follicles, 440
degeneration of, 441
Grandry, corpuscles of, 206
Granules of protoplasm, 9
colourless blood-corpuscles, 41
Ground-substance. *See* intercellular substance
v. Gudden, atrophy of, 197
commissure of, 514
tract of, 518
Gullet. *See* œsophagus
Gustatory cells, 351
organs, 349
Gustatory pore, 351
Gyrus dentatus, 535
hippocampi, 535

Habenula, 510, 516
Hæmacytometer, 34
Hæmal glands, 253
Hæmapoiesis, 47
Hæmatëin, 601
Hæmatin, 36
Hæmatoblasts, 56
Hæmatoidin, 36
Hæmin, 33, 36
Hæmocyanin, 37
Hæmoglobin, 36
Hæmolysins, 59
Hæmolysis, 57
Hæmophilia, 24, 46
Hair-cells of internal ear, 578, 583
Hair-follicle, structure of, 300
Hairs, 31, 299
development of, 307
growth of, 302
muscles of, 307
Hassal, concentric corpuscles of, 265
Haversian canals, 128, 131
fringes, 120
lamellæ, 128
spaces, 139
systems, 128, 139
Hayem's solution, 34
Heart, 315
conducting tissue of, 318
muscle of, 315
nerves of, 321
valves of, 321
vessels of, 322
Heidenhain's azan stain, 604
azocarmine stain, 605
iron-hæmatoxylin stain, 606
Helicotrema, 580
Henle, fenestrated membrane of, 224
layer of, 300
looped tubules of, 409
sheath of, 174, 209
Hensen, line of, 150, 152
Hepatic artery, 392
cells, 395
lobules, 392
veins, 230, 392
Herbst, corpuscles of, 210
Herring, bodies of, 285
Hippocampus major, 535
His, bundle of, 318
Histiocytes, 96, 106
Histogenesis, 26
Histology, meaning of term, 1
Holmgren, canaliculi of, 180
Huxley, layer of, 300
membrana preformativa of, 345
Hyaloid membrane, 571
Hypophysis cerebri or pituitary body, 282
development of, 287
Hypothalamus or subthalamus, 518

Ileum, 388
Insulin, 400
Intercellular channels, 75, 291
substance, 1, 2, 92, 96, 98, 113, 115
Internal capsule, 540
Interstitial cells of ovary, 444
testis, 428
Intestine, large, 388
small, 377
Intra vitam staining methods, 599
Iris, 557
Isthmus of spinal cord, 461

Janus green, 599, 600
Jejunum, 388
Jelly of Wharton, 114
Jelly-like connective tissue, 112
Jenner's stain, 603

Karyokinesis, 14
Karyosome, 13
Keith and Flack, node of, 320
Keratin, 293
Kerato-hyalin, 291
Kidney, 406
blood-vessels of, 413
development of, 416
Krause, membrane of, 150, 152, 153
Kultschitzky, cells of, 380
staining methods of, 613, 614
Kupffer, cells of, 106, 107, 394

Labyrinth of ear, 576
Lacrimal glands, 546
Lacteals, 243, 377, 383, 385, 388
Lacunæ of bone, 127
urethra, 422
Lacunar spaces, 245
Lamellæ of bone, 127
Lamellar cells, 96
Lamina cribrosa, 547
fusca, 547
reticularis, 583
suprachoroidea, 553
Landolt, fibre of, 562
Langerhans, islets of, 400
centro-acinar cells of, 404
Lanugo, 308
Larynx, 326
Leishman's stain, 603
Lens, of eye, 569
microscope, 28
Leucoblasts, 49
Leucocytes, 40. *See also* blood-corpuscles, white or colourless
Leucocytosis, 40
Leucopenia, 40
Levator palpebræ, 545
Lieberkühn, crypts of, 379
Ligaments, 111
Ligamentum pectinatum, 548
Ligula, 494
Limbus of cochlea, 580
Linen fibres, 30
Linin, 11
Lipoid substances, 3, 7, 36, 270
Liquor folliculi, 442
Lithium carmine, 600
Littré, glands of, 422
Liver, 391
blood-vessels of, 392
cells of, 395
ducts of, 397
intracellular canals of, 395
lobules of, 392
lymphatics of, 399
Löwit, chloride of gold method of, 613
Lung, 326
alveoli of, 331
blood-vessels of, 332
development of, 334
dust-cells of, 332
lymphatics of, 333
nerves of, 334
Luys, corpus subthalamicum of, 518
Lymph-corpuscles. *See* blood-corpuscles, white or colourless
Lymph-glands or lymphatic glands, 249
hæmal, 253
Lymph-plexuses, 245
Lymph-vessels or lymphatics, 241
connexion with cells of connective tissue, 98
development of, 245, 246
nerves of, 243
Lymphoblasts, 253
Lymphocytes, 42, 51, 56, 64
Lymphoid nodules, 250
tissue, 104
development of, 264

Macrocyte leucocytes, 42, 44, 64, 72, 106
Macrophages, 42, 256
Macrophagocytes, 96, 106
Macropolycytes, 45
Macula acustica, 578
lutea of retina, 566
Male pronucleus, 23
Mallory's stain, 604
Malpighi, pyramids of, 406
rete mucosum of, 291
Malpighian corpuscles of kidney, 408
spleen, 51, 255, 263
Mammary glands, 312
development of, 314
Mann's double stain, 603
Marcano's fluid, 34
Marchi's method for staining degenerated nerve-fibres, 610
Marrow, 51
Martinotti, cells of, 528
Mast-cells, 97
Mayer's hæmatëin stain, 601
mucihæmatëin stain, 608
Measuring objects, 29

Medulla oblongata, 479
nerves arising from, 486
Medullary rays, 408
Megakaryocytes, 55
Megaloblasts, 40, 49, 52
Meibomius, glands of, 545
Meissner's plexus, 377
Melanophores, 98
Membrana granulosa, 441, 447
tectoria, 585
tympani, 575
Membranæ propriæ, 112
Mercuric chloride, 585
Mesencephalon, 506
Mesenchyme, 27
Metaplasmic inclusions, 9
Metencephalon, 479
Methods of embedding, 592
fixation, 558
measuring microscopic objects, 29
cutting sections, 594
staining sections, 300
Methylene blue, 599, 608, 609, 614
Meynert, bundle of. *See* tract
decussation of, 509, 513
Microdissection, 4, 11
Microglia, 199
Micrometer, 29
Micron, 37 (footnote)
Microscope, 28
Microscopic work, requisites for, 28
Microtomes, 594
Mid-brain, 479, 495, 506, 513
Migration of colourless blood-corpuscles, 69
Milk, 31, 312
Minot's microtome, 594
Mitochondria, 3, 5, 7, 41, 85, 117, 171, 180, 277, 365, 369, 400, 402, 411
methods for demonstrating, 606, 607
Mitosis, 14
heterotypical, 15
in living cell, 20
reduction, 15
somatic, 15
Moist chamber, 83
Monocytes, 42
Mononuclear leucocytes, 42, 51, 106
Morgagni, ventricle of, 326
Moulds, 30
Mounting fluids, 587
Mouth, mucous membrane of, 352
Mucigen, 90, 358
Mucin, 88, 358
methods for demonstrating, 608
Mucoid cells, 369
Mucous cells, 358
Mucus, 84
Mucus-secreting cells, 90
Muir's staining method, 603
Müller, fibres of, 564
fluid of, 590
helicine arteries of, 420
muscle of, 557
Mummery, plexus of, 342
Muscle,
cardiac, 159
development of, 162
cross-striated, 146
blood-vessels and lymphatics of, 157
changes in contraction, 153
development of, 157
ending of, in tendon, 156
end-plates of, 217
of insects, 150
nerves of, 157, 217
nuclei of, 147
in polarised light, 154
pale, 149
red, 149
plain or non-striated, 163
development of, 164
nerves of, 220
Muscle-spindles, 215
Myelencephalon, 479
Myelin, 167
Myelination, 467
Myelocytes, 52
Myeloplaxes, 54
Myocardium, 315

Nails, 296
development of, 298
Nerve or nerves
abducens, 497, 498
autonomic, 172
chorda tympani, 498
cochlear, 490
eighth, 490, 497
facial, 497
glossopharyngeal, 488
hypoglossal, 486
motor, 514
optic, 513
spinal accessory, 487
trigeminal, 497, 498
vagus, 487
vestibular, 492
of Wrisberg, 497
Nerve-cells, 176
adendritic, 182
axon of, 177
bipolar, 182
collaterals of, 183
degeneration of, 192
dendrites of, 177, 182
development of, 199
Golgi apparatus of, 180
Golgi, superficial reticulum of, 181
Holmgren, canaliculi of, 180
mitochondria of, 180
multipolar, 182
neuro-fibrils of, 177
Nissl bodies of, 177
pigment of, 180
processes of, 181
of spinal ganglia, 187

Nerve-cells, staining methods for, 608
of sympathetic ganglia, 190
synapses of, 183, 185
trophospongium of, 180
unipolar, 182
Nerve-endings, 206
articular corpuscles, 206
degeneration of, 219
end-bulbs, 205
end-plates (motor), 217
free, 213
genital corpuscles, 206
Golgi-Mazzoni corpuscles, 211
Golgi organs, 211
Grandry's corpuscles, 206
Henle's sheath of, 209, 220
Herbst's corpuscles, 210
of involuntary muscle, 220
methods for staining, 613
muscle-spindles, 215
Pacinian corpuscles, 205, 208, 231, 297, 405, 420
Ruffini's organs, 210
tactile corpuscles, 205
tactile disks, 206, 213
telolemma of, 220
Nerve-fibres, 166
development of, 201
methods for staining, 609
amyelinate or non-medullated, 173
degeneration of, 194
Golgi apparatus of, 173
nuclei of, 173
myelinate or medullated, 167
axis-cylinder of, 167, 171
constricting band of, 167
degeneration of, 192
Golgi apparatus of, 171
mitochondria of, 171
myelin sheath of, 167
neuro-fibrils of, 171
neurokeratin of, 168
neurolemma of, 167, 169
nodes of, 167
nuclei of, 171
regeneration of, 194
sheath of Schwann of, 167
size of, 172
Nerve-ganglia, 177
Nerve-trunks, structure of, 175
Nerve-unit, 183
Nervi nervorum, 174
Neuraxon, 181
Neuroblasts, 200
Neuro-fibrils, 177, 187, 192
Neuroglia, 197
of cerebellum, 525
of cerebral cortex, 531
development of, 203
methods for staining, 612
of spinal cord, 463
types of, 198
Neurokeratin, 169
Neurolemma, 167, 169
Neurolemma, development of, 203
Neuron, 181
Neurone, 183
theory, 186
Neuro-synapse, 185
Neutral red, 599, 600, 608
Nissl bodies of nerve-cells, 177, 193
degeneration of, 193
method of staining, 609
Normoblasts, 49, 52
Nose, 572
Nucleic acid, 11
Nucleolini, 13
Nucleolus, 10, 13
Nucleus of cell, 2, 10
Nucleus or nuclei (nerve)
of abducens, 498
of accessory, 483, 487
accessory auditory, 491
ambiguus, 487
anterior (of thalamus), 515
of Bechterew, 492, 495
caudatus, 540
of cochlear nerve, 491
commissural, 488
cuneatus, 469, 482
outer, 494
of Deiters, 492, 497, 508
dentatus, 507, 520
descending, of facial, vagus and glossopharyngeal, 488
descending vestibular, 492
of facial, 497
of fasciculus teres, 487
of fillet, 509
of fourth nerve, 506
of glossopharyngeal, 484, 488
gracilis, 468, 482
of hypoglossal, 483, 486, 490
lateral, of medulla, 480
thalamus, 515
lenticularis, 540
mesial, of thalamus, 515
of oculomotor, 501, 506
olive, 480, 485, 494
of pons, 495
of posterior or dorsal longitudinal bundle, 508
pre-olivary, 496
red, of tegmentum, 508
semilunar, 496
of spinal accessory, 487
of Stilling, 476, 520
superior olivary, 492, 496
tecti (s. fastigii), 520
of thalamus, 515
of trapezium, 491
of trigeminal, 498
of vagus, 483, 487
of vestibular nerve, 485, 492

Odontoblasts, 341, 346
Œsophagus, 352

Olfactory bulb, 535, 537
cells, 574
glomeruli, 538
mucous membrane, 573
nerve-fibres, 538
tract, 537
Oligodendroglia, 199
Olive, 480, 484, 485
superior, 492, 496
Omentum, 247
Onychogenic substance, 297
Oocytes, 443
Oogenesis, 443
Opsonins, 70
Optic chiasma, 513, 514
nerves, 513
thalamus, 505, 514, 540
tract, 511, 512, 514, 515
Ora serrata, 567
Orbicularis muscle, 545
Orcëin, 606
Osmic acid, 590, 608
Ossification, endochondral, 133
membranous, 133, 141
Osteoblasts, 132, 134, 136, 137, 141
Osteoclasts, 137, 346
Osteogenic fibres, 137, 141
Otoliths, 578
Ovary, 439
human, 447
Oviducts, 452
Ovum, 23, 44, 443
division of, 21
and sex-determination, 23
Oxyntic cells, 369
Oxyphil leucocytes, 42, 44, 64

Pacchionian glands, 542
Pacinian corpuscles, 205, 208, 231, 297, 405, 420
Pancreas, 400
development of, 405
Paneth, cells of, 380
Papillæ foliatæ, 349
of hairs, 300
kidney, 406
skin, 295
tongue, 347
Paraffin embedding, 593
Paraganglia, 271
Parathyroids, 281
development of, 282
Parietal cells, 369
Pelvis of kidney, 406
Penicilli of Ruysch, 259
Penis, 419
Peptic cells, 369
Perforating fibres, 129
Pericardium, 316
Perineurium, 174
Periosteum, 127, 132
and ossification, 133
Pes pedunculi, 509
Peyer's patches, 263, 380
Pflüger's egg-tubes, 443
Phagocytes and phagocytosis, 69, 106, 253, 259, 332, 394
Pharynx, 352
Phloroglucin-nitric acid, 591
Phototaxis, 3
Pia mater, 460, 542
Pick, bundle of, 481
Picric acid, 590
Pigment and pigment-cells, 98, 256, 397
Pineal gland or epiphysis cerebri, 287
development of, 289
Pinna, 574
Pituitary body or hypophysis cerebri, 282
development of, 287
Placenta, 454
Plasma, 36
Plasma-cells, 97
Plasmosome, 13
Pleura, 343
Polar bodies, 22
Polymorph leucocyte, 42, 64
Pons Varolii, 495
nerves arising from, 497
tracts of, 501
Portal canal, 392
Precipitins, 59
Preservation of tissues, 591
Prickle-cells, 75
Projection-fibres, 531
Pronuclei, 23
Proprio-spinal fibres of cord, 469, 474
Prostate, 419, 422
Proteins, absorption of, 385
Protoplasm, 2
Pseudopodia, 69
Ptyalin, 360
Pulp of spleen, 255
Purkinje, cells of, 520, 522
fibres of, 317, 318
Pyramidal cells of cortex cerebri, 527
Pyramids of kidney, 406
of medulla oblongata, 479, 480, 485
Pyrrhol blue, 600

Ranson, silver stain of, 610
Ranvier, gold chloride method of, 613
constrictions of, 167
Raphe, 484
Raschkow, plexus of, 321
v. Recklinghausen, silver nitrate staining method of, 606
Reduction-division, 15, 17
Regaud's staining method, 606
Regeneration of nerves, 194
Reil, fillet of, 491, 504
island of, 528
Reissner, membrane of, 580
Remak, fibres of, 173
Restiform body, 485, 494, 525
Rete mucosum of Malpighi, 291

Rete testis, 424
Reticular or retiform tissue, 103, 255, 392
Reticulocytes, 39
Reticulo-endothelial system, 105
blocking of, 107
cells of, 104, 106, 395
functions of, 107
Retina, 558
macula lutea of, 566
pars ciliaris of, 567
sensory epithelium of, 563
Retzius, fibre-cells of, 578
Rhinencephalon, 535
Ringer's solution, 32 (footnote), 587
Rolando, tubercle of, 482
substantia gelatinosa of, 464, 476, 482
Rollett, method for staining muscle, 145
Rouget, cells of, 238
Rouleaux of blood-corpuscles, 32, 36, 37, 58
Ruffini, organs of, 210
staining method of, 613
Ruysch, penicilli of, 259

Sacculе, 576
Saliva, 73
Salivary corpuscles, 263
glands, 355
development of, 363
Salt solution, normal, 32 (footnote), 587
Sarcolemma, 146
Sarcomeres, 152
Sarcoplasm, 147
Sarcostyles, 147
Sarcous elements, 152
Scala tympani, 580
vestibuli, 580
Scarpa, ganglion of, 490
Scharlach R, 608
Schwann, sheath of, 167
Sclerotic coat of eye, 547
Sebaceous glands, 308
Sections, cutting of, 594
staining of, 600
treatment of, 597
Semicircular canals, 576
Seminiferous tubules, 431
Serous cells, 358
Serous membranes, 241, 246
development of, 248
Sertoli, cells of, 431
Sex-chromosomes. *See* chromosomes
Sharpey, fibres of, 129
Siliqua olivæ, 485
Silver-methods, 606, 607
Sinusoids, 239, 395
Skin, 290
appendages of, 296
development of, 296
Solitary glands, 263
Spermatogenesis, 435
Spermatozoa, 434
Sphincter ani, internal, 390
pupillæ, 557
Spinal bulb. *See* medulla oblongata
Spinal cord, 460
blood-vessels of, 464
cell-groups of, 474
central canal of, 464
characters in different parts of, 466
commissures of, 462
connexion of nerve-roots with, 462, 476
cornua of, 462, 476, 479
grey matter of, 460, 462, 464, 474
membranes of, 460
nerve-cells of, 468, 474
neuroglia of, 463
proprio-spinal fibres of, 469, 474
tracts of, 467
white columns of, 462, 467, 482
Spinal ganglia, 187, 477
Spindle, achromatic, 20, 21
Spiral ganglion, 586
lamina, 580
ligament, 580
Spleen, 255
development of, 261
Splenic cells, 69, 256
Spongioblasts, 200
Staining of sections, 600
Stanley Kent, fibres of, 318
Starch-granules, 30
Stilling, nucleus of, 476, 520
Stomach, 364
blood-vessels of, 371
glands of, 366
lymphatics of, 373
nerves of, 373
Stomata, 246
Stratum corneum, 292
granulosum, 291
lucidum, 291
Stria medullaris, 517
vascularis, 584
Stroma-theory of blood-corpuscle, 59
Substantia gelatinosa, 464, 476, 482
nigra, 509
Subthalamus, 518
Sudan III, 608
Sulphurous acid, 591
Suprarenal capsules, 270
development of, 274
Susa, 589
Sustentacular cells, olfactory, 574
of taste-buds, 351
Sweat glands, 310
development of, 311
Sylvius, aqueduct of, 505, 506
Sympathetic ganglia, 190
nerves, 172
Synapse, 185
Synapsis, 20
Syncytium, 2, 47, 113, 238
Synovial membranes, 116, 120

Tactile corpuscles, 205
disks, 206, 213, 302
Tænia, 494
pontis, 495
Taste-buds, 349
Tawara, node of, 320
Teeth, 335
cement (crusta petrosa) of, 339
dentine of, 336
development of, 342
enamel of, 335
nerves of, 341
pulp of, 341
structure of, 335
Tegmentum, 507, 508
Telencephalon, 479
Tendon, 97, 111
connexion with muscle, 156
nerve-endings in, 112
Tendon-cells, 111
Testicle, 424
intertubular tissue of, 428
Tetrads, 17
Thalamencephalon, 479, 495, 514
Thalamus, 514
Thermotaxis, 3
Thiazin red, 602
Thigmocytes, 65
Thigmotaxis, 3, 47, 67
Thionin, 608, 609
Thrombocytes, 36, 45, 55, 65
Thymocytes, 265
Thymus gland, 264
development of, 267
accessory, 280
Thyroid body, 277
development of, 280
Thyroxin, 278
Tissue-culture, 12, 20, 72, 126
Tissues, enumeration of, 1
formation from blastodermic layers, 24
Toluidin blue, 609
Toluol, 592
Tomes, enamel processes of, 345
Tongue, 347
Tonsils, 261
pharyngeal, 263
Tooth. *See* teeth
Torulæ, 30
Trachea, 323
Tract or tracts, methods of studying, 467
Tract or tracts or bundle
anterior (ventral) longitudinal. *See* tecto-spinal tract
antero-lateral (ventro-lateral) ascending. *See* tract of Gowers
antero-lateral (ventro-lateral) descending. *See* tract of Loewenthal
of Bechterew. *See* central tract of tegmentum
bulbo-spinal, 471
of Burdach, 467, 468, 482
central acoustic, 509, 516
of cranial nerves, 499, 505, 515
Tract, central, of tegmentum, 486, 502
cerebello-bulbar, 490
comma, 469
of cord, 467
cortico-bulbar, 501, 505
cortico-pontine, 495, 509
cortico-spinal. *See* pyramid tract
direct pyramid. *See* pyramid tract
dorsal or posterior longitudinal, 471, 485, 497, 501, 508
median triangular, 469
myelination of, 467
of fillet, 483, 502, 509, 515
of Flechsig, 467, 472, 485, 525
of Goll, 467, 468, 482
of Gowers, 467, 472, 474, 485 505
of v. Gudden, 518
of Helweg, 472
of Lissauer, 474, 478
of Loewenthal, 471
of Marie, 474
of Meynert, 508, 510, 517
of Monakow. *See* rubro-spinal tract
of Münzer, 508
of Pick, 481
of Vic d'Azyr, 518
olfactory, 517, 535, 537, 539
olivo-cerebellar, 486, 525
olivo-spinal, 472
optic, 512, 513, 514, 515
oval, 469
ponto-spinal, 471, 502
prepyramidal. *See* rubro-spinal tract
proprio-spinal, 469, 474
pyramid, 467, 469, 471, 477, 479, 480, 495, 501
rubro-spinal, 471, 502, 508
septo-marginal, 469
spino-cerebellar [dorsal]. *See* tract of Flechsig
[ventral]. *See* tract of Gowers
spino-tectal, 474
spino-thalamic, 474
sulco-marginal, 474
tecto-spinal, 472, 502, 508, 513
thalamo-olivary, 486
transverse peduncular, 514
ventral or anterior longitudinal. *See* tecto-spinal tract
vestibulo-motor. *See* dorsal or posterior longitudinal (above)
vestibulo-spinal, 502
Transitional leucocytes, 42, 44, 106
Trapezium, 491, 495
nucleus of, 496
Trichloracetic acid, 591
Trophospongium, 180
Trypan blue, 600
Tubercle of Rolando, 482
Tuberculum acusticum, 491
olfactorium, 537
Tunica albuginea, 424
vaginalis, 424

Turpentine, 592
Tympanum, 575

Uninuclear leucocytes, 42, 44
Ureter, 417
Urethra (male), 419, 420
(female), 459
Urinary bladder, 406, 417
Uriniferous tubules, 408
Uterus, 452
Utricle, 576

Vacuome, 9, 436
Vagina, 458
Vas deferens, 426
Vasa recta, 416
Vasa vasorum, 231
Vascular area, 48
Vasoformative cells, 49, 238
Veins, smaller, 234
structure of, 228
valves of, 229
variations in, 229
vessels and nerves of, 230
Venæ stellulæ, 414
Ventricle, fourth, 483, 492, 506
lateral, 514
third, 479, 514, 517
Vermiform appendix, 388
Vernix caseosa, 296
Vesiculæ seminales, 428
Vesuvin, 599, 600
Villi, arachnoidal, 541
chorionic, 454
of intestine, 381
of synovial membrane, 120
Vitreous humour, 571
Volkmann, canals of, 129, 131

Wallerian degeneration, 192, 467
Warm stage, 68
Weigert-Pal method for staining sections, 609
Wharton, jelly of, 114
White cells. *See* blood-corpuscles, colourless
Woollen fibres, 30
Wright's stain. *See* Leishman's stain
Wrisberg, nerve of, 497

Xanthophores, 98
Xylol, 592

Yeast, 31
Yolk, 10

Zenker's fluid, 590
Zinn, zonule of, 571
Zona pellucida, 443
Zygote, 13
Zymogen, 360, 469

Printed in England at The Ballantyne Press
Spottiswoode, Ballantyne & Co. Ltd.
Colchester, London & Eton