

**PAGES MISSING  
WITHIN THE  
BOOK ONLY**

UNIVERSAL  
LIBRARY

**OU\_162702**

UNIVERSAL  
LIBRARY







**ELEMENTS OF ZOOLOGY**

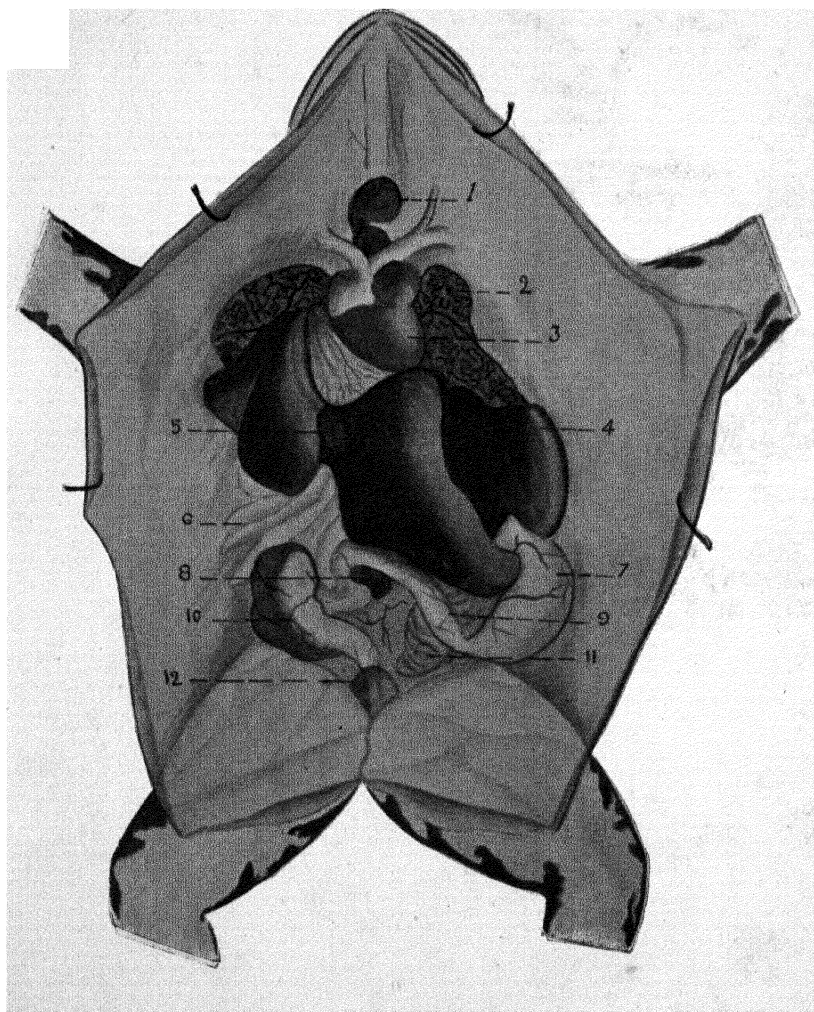
*Obtainable at*

**THE INDIAN CO-OPERATIVE  
INDUSTRIAL SOCIETY,  
Hyderabad Deccan.**

*or*

**MESSRS. BUTTERWORTH & Co.,  
Post Box No. 251,  
Calcutta.**





(Frontispiece).

DISSECTION OF FEMALE FROG.

1. Thymus, 2. Lungs, 3. Heart, 4. Liver, 5. Gall bladder, 6. Fat-body, 7. Stomach, 8. Spleen, 9. Duodenum, 10. Colon, 11. Ovary, 12. Bladder.

# ELEMENTS OF ZOOLOGY

A Text-book for Indian Students

BY

**H. HYDERALI KHAN, F.R.C.S.E.**

*Professor of Biology, Osmania Medical College  
Hyderabad Deccan*

— — —  
**SECOND EDITION**  
— — —

HYDERABAD DECCAN  
GOVERNMENT CENTRAL PRESS  
1925



## CONTENTS

	PAGE
INTRODUCTION .. .. .	1
HEREDITY AND EVOLUTION .. .. .	3
THE CELL .. .. .	6
AMŒBA .. .. .	9
PARAMŒCIUM .. .. .	12
HYDRA .. .. .	15
EARTHWORM .. .. .	20
PALINURUS .. .. .	29
COCKROACH .. .. .	42
MOSQUITO .. .. .	51
FROG .. .. .	62
PIGEON .. .. .	100
RABBIT .. .. .	114



## PREFACE TO THE SECOND EDITION

*In introducing this book to the students I felt the necessity of prefacing it with an apology for adding to the existing literature on the science of Zoology; but the rapid sale which the few hundred copies printed have had and the further demand which has necessitated the publication of the second edition within a year go to indicate that this book has to some extent succeeded in its mission—that of creating an interest in the study of Zoology by presenting the subject in a manner calculated to give a clearer interpretation to and a better comprehension of the theoretical knowledge contained in text books by the encouragement of practical work.*

*The second edition has been thoroughly revised and enlarged. The description of the pigeon and the rabbit as representing the Aves and Mammals has been included. Numerous diagrams, illustrations and plates by Mr. M. Rangam have been added. The works of Beddard, Calkins, Gilchrist and Bonds, Harmer and Shipley, Hegnar, Marshall and Hurst, Masterman, Mullan, Parker and Haswell, Powell, Thomson, and Wells and Davies have helped me a great deal in writing this book. My best thanks are due to Drs. Hunt, Sayeed, Hardikar and Mr. M.B. Mirza for their help and advice.*

H. HYDERALI KHAN

HYDERABAD (DECCAN)

FEBRUARY, 1925

## PREFACE TO THE FIRST EDITION

*An apology is necessary for adding one more volume to the already existing publications on Zoology. The reason that has prompted me to undertake this book is that Indian students usually experience great difficulty in getting a clear grasp of the subject as they have to rely upon two or three books written on different lines, and from different standpoints to be able to follow their lectures with advantage.*

*As far as I am aware there is no book which deals with the full course prescribed by some of the universities. I have, therefore, attempted to place before the students of Zoology a book which while it meets all their wants also places before them all the necessary information in as lucid and concise a manner possible. Particular care has been taken in the arrangement of this book so as to make it of practical value to the students. All instructions for practical work have been italicised.*

*I must in conclusion acknowledge my indebtedness to the various authors consulted, and express my thanks to friends who have rendered me much assistance.*

H. HYDERALI KHAN

HYDERABAD (DECCAN)

MARCH, 1924

## INTRODUCTION

**Z**OLOGY is that branch of Biology which deals with the science of animals. Zoology being a practical science, should be studied in as practical a manner as possible and not by mere reading and committing to memory as is often done by students. The student should always avail himself of the opportunity of observing the animals described, in their various phases of natural life, and of dissecting them whenever possible. Diagrams of the various stages of dissection should be carefully drawn and preserved for future reference.

This book is an attempt to guide the students to a system of study which will combine practical and theoretical knowledge. The dissections that have been described and recommended will explain the anatomy of the animals herein discussed and will also serve as indications for future work.

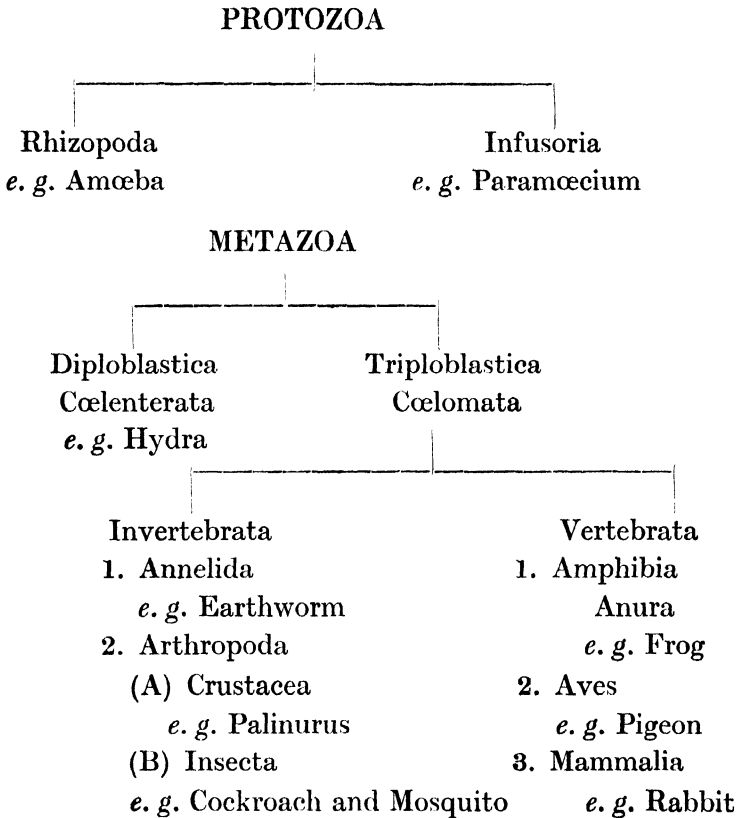
The animals dealt with in this book are representative types of certain selected classes. Animals are usually divided according to their common characteristics into subdivisions, phyla, classes and orders. They may however be broadly divided into two subdivisions, the Protozoa and the Metazoa.

The Protozoa are the simplest forms of organisms and they consist of cells with no functional differences. Each cell is a unit in itself and even when they group together forming a colony, each cell retains its own individuality.

The Metazoa are animals made up of many groups of cells, each group performing a different and definite function. The Metazoa are divided into those having two layers of cells constituting the ectoderm and the endoderm, and known as diploblastica, and those with three layers called triploblastica,

the third middle layer being the mesoderm. The triploblastica are further divided into invertebrata and vertebrata. The invertebrata have no dorsal axis and no gill slits but they usually have a ventral nerve cord and a dorsal heart. Their eyes are developed from the skin and not as outgrowths of the brain as in the case of the vertebrata.

The animals dealt with in this book, may be classified thus :—



## Hereditv and Evolution

THE laws of heredity and evolution are so complex in their nature and have so many different aspects that it is difficult if not impossible to condense within the scope of this book any detailed or analytical survey of them. We will however briefly consider those fundamental principles that affect and to some extent govern the study of our subject.

The law of heredity stated in a few words is that a resemblance exists both in appearance and characteristics between parents and their offsprings. This resemblance is however neither absolute nor complete because on closer examination and observation several dissimilarities which are technically called *variations* become apparent. There has been a great deal of controversy over the cause and effect of these variations. Some hold that these being purely accidental, sudden and insensible, do not play any important part in the cycle of evolution while others hold that these variations are the necessary reactions to environments and circumstances and that they have a vital significance in as much as they decide the fate of the animals concerned according to the immutable law of the “ *Survival of the fittest* ” in the “ *Struggle for existence.* ”

The two terms ‘ the struggle for existence ’ and ‘ survival of the fittest ’ have been so frequently and irresponsibly used that they have lost their true scientific connotation. The struggle for existence means the great competition for food, air and life that goes on incessantly and unceasingly in the animal and vegetable kingdoms, and the law of the survival of the fittest ordains that only those animals can live that possess the powers of adaptibility to existing conditions and of

protection and defence against external aggressive forces which very often are of the same species. Nature thus allows only those that are healthy and strong to live and multiply. This is known as *natural selection*. There is also another form of selection that takes place in higher animals called *sexual selection*. Here the female chooses her mate because of some particular characteristic, or as is more often the case, because of proved physical superiority over other males of the same species in order to ensure healthy progeny. It will be noticed that the whole trend of nature and of animal instinct is towards physical development and fitness.

Three of the many views put forward to explain the present state of living organisms are :—(1) that the past generation existed as such and that the present is merely a faithful reproduction of the past, (2) that the present generation has been created after a complete destruction of the past and (3) the Evolution Theory. The first two views are untenable, the first because several extinct and abnormal fossils have been found in rocks and caves whose replica do not exist at present, and the second because there is no concrete or convincing evidence either of a universal destruction or of the sudden appearance of living organisms.

In 1859 Charles Darwin enunciated the third or the Evolution Theory in his great book the “Origin of the Species.” Darwin held that the present state of life was the result of a systematic process of progressive evolution from the lowest unit of life, the various degrees of life development being dependent upon the stage of evolution reached. This great theory has received support and confirmation from Darwin’s time to the present and the three observations that substantiate this theory are the increasing complexity of structures as we ascend the scale of animal life, the rudimentary organs found in the present generation such as the gill slits and the pineal body, and the evidence of certain fossils which throw light upon the intermediate stages of life development and

form the missing links in the chain of evolution. The basic principles of the Evolution Theory have been accepted by all biologists but the details have been the subject of long controversies. Darwin believes that only those animals that possess the powers of protection and development can survive and multiply and that their progeny inherit those very powers and characteristics. Some biologists however hold the view advanced by Lamarck in 1815, that animals by adapting themselves to existing conditions acquire the necessary powers and characteristics to ensure survival and that offsprings inherit these acquired characteristics. It must be pointed out that Darwin not only did not contradict this theory but included and incorporated it in his larger and greater theory of the "Survival of the Fittest."

## The Cell

**A** CELL is the aggregate unit of living matter and consists of a mass of protoplasm usually enclosed in a cell wall. It contains in its centre a differentiated portion of protoplasm called the nucleus.

The cell wall varies considerably, being thick in some cells and thin in others, while some cells have no cell wall.

The shape of a cell is usually spherical but may get altered to fusiform, oval, stellate and cubical shapes according to its position, function and nutrition. Epithelial cells are flat and fit into one another thus making a complete covering for the body. The cells lining the alimentary canal are either cubical or cylindrical and secrete digestive juices, while the muscles which have to contract and elongate have fusiform cells. Some of the nerve cells with many processes are stellate.

The content of a cell apart from the nucleus is called cytoplasm and appears to be homogenous but on careful examination it presents a granular appearance. Its chemical constituents vary in different phases such as metabolism, which is the aggregate of the changes in the living body involving the building up of protoplasm and its breaking down; the former is called anabolism and the latter katabolism.

The chemical analysis of protoplasm has yielded carbon, hydrogen, oxygen, nitrogen and sulphur in the form of proteins, and also some other compounds in which calcium, phosphorus, sodium, potassium and iron are found in the form of salts. The exact chemical formula however has not yet been found.

It has recently been shown that protoplasm has a definite structure. According to one view, the *network*

*theory*, the protoplasm is disposed in a network of a denser formation such as a sponge, and that the granular structure is an optical illusion. The other view holds that the living material is a mass of frothy structure that can be demonstrated by a mixture of fine emulsion of fat and a solution of common salt. This is called the *foam theory*.

Certain spaces called vacuoles are also found in the cytoplasm.

The nucleus is a more or less spherical body embedded in the cytoplasm. It consists of a nuclear membrane surrounding the nucleo-hyaloplasm and a fine network called chromatin.

The nucleus is stained deeper and so is more distinct than the rest of the cell. The nucleus performs various functions such as nutrition and respiration and also plays an important part in the division of a cell.

One or more small round bodies called the nucleoli are found inside the nucleus.

On one side of the nucleolus there is a round body with a number of processes called the centrosphere enclosing a centrosome. This body acts as a magnetic centre for drawing the chromatin threads during cell division.

A cell divides either directly or indirectly. In either case the nucleus divides first and is followed by the division of the rest of the cell.

The binary fission, direct or amitotic division takes place by the nucleus dividing into two, and a constriction appearing in the cell which is also divided. These portions separate as daughter cells.

The indirect, mitotic or karyokinetic division consists of various changes which may be conveniently divided into five stages.

1. The nuclear network, chromatin, gets arranged in V-or U-shaped loops called chromosomes in the

form of a star, near the centre of the cell. This is known as the *aster* stage.

2. The V-or U-shaped loops of chromosomes and the centrosome divide into two simultaneously and each half moves over to the opposite pole of the cell.
3. The nuclear membrane disappears and the chromosomes lie in the cytoplasm.
4. Half of the divided chromosomes are attracted to one centrosome and the other half to the other. This presents the appearance of two stars and is known as the *diaster* stage.
5. The chromosomes are collected into two nuclei and the cytoplasm divides into two forming two daughter cells.

All organisms are composed of cells. Some of them such as the amœba, have only one cell which performs all the functions of life *i. e.*, movements, reaction to stimuli, metabolism and reproduction, while others have more cells than one, in which specialization takes place and groups of cells are adapted for the performance of special functions.

# Protozoa

**T**HE protozoon is the simplest and the most primitive *animal* and consists of one cell which forms a single unit. It feeds on decaying vegetable matter and other protozoa and multiplies by division into two or more daughter cells.

Protozoa are sub-divided into Rhizopoda, Infusoria and Sporozoa. Amœba is one of the types of Rhizopoda.

## AMŒBA

*Amœbae* are usually found amongst debris, deposits of mud, in fresh water pools and adhering to weeds and other submerged objects while some are parasites in the intestines of many of the higher animals. In size they may be large enough to be just visible to the naked eye but usually they are invisible. The protoplasm in this organism glides about by protruding finger like processes known as the *lobopods* or *pseudopodia*; these motile processes keep on constantly altering the shape of the cell.

*Place a drop of water containing amœba on a slide, and carefully place a coverslip over it, so as to avoid air bubbles. Examine it under the low and high powers of the microscope. Introduction of acetic acid will bring out the nucleus more clearly. Carefully note and draw the structure of the cell and mark its changes at regular intervals.*

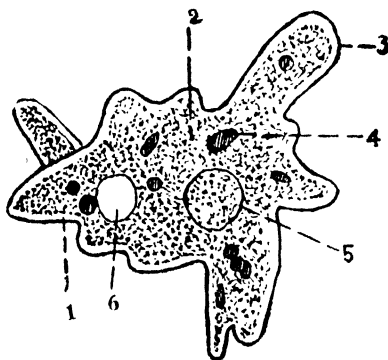


FIG. 1. AMŒBA, (highly magnified).

1. Ectoplasm, 2. Endoplasm, 3. Pseudopodium, 4. Food vacuole, 5. Nucleus, 6. Contractile vacuole,

*The Cell* consists of an outer clear but firm zone the *ectoplasm* and an inner granular fluid the *endoplasm*.

This endoplasm has a spherical nucleus and contains food and contractile vacuoles. The nucleus is denser than the surrounding cytoplasm and presents a reticulated appearance due to a delicate network of chromatin. Some round bodies called nucleoli are sometimes found inside the body of the nucleus.

The food vacuoles scattered about in the endoplasm contain ingested food and digestive fluids, while the contractile vacuoles contain a colourless fluid, the excretion of the amœba. As this excretory fluid accumulates the vacuole grows larger and rises to the surface of the amœba where it bursts and gets discharged from the body of the cell. A new vacuole is then created in a similar way and at the same spot to repeat the process of excretion.

The food of the amœba consists of minute algæ or other protozoa, and is taken in by the engulfing movements of the pseudopodia. In the cell, the food is acted upon by digestive juices in the food vacuoles and the excreta are removed by the agency of the contractile vacuole as mentioned above.

Under favourable conditions the amœba grows by dividing into two by simple fission, this division being initiated in the nucleus.

Under unfavourable circumstances the amœba becomes globular, secretes a chitinous cell wall around itself and thus encysting itself lies dormant. In this condition it may be carried away to long distances by the wind and be laid on a suitable soil. When a favourable opportunity arrives the cyst wall bursts, and the amœba emerges to assume its previous activities.

Although it is not possible to discuss here in detail the controversial theory that the amœba does not die by itself, we shall just mention the two points of view advanced. The first theory is that the amœba is immortal unless it be destroyed by some external agency. The advocates of the second

theory contend that the amœba after its division into two, is dead to all intents and purposes. We are inclined to favour the first view because death always leaves behind it a corpse or dead matter, whereas no dead matter results from the division of the amœba.

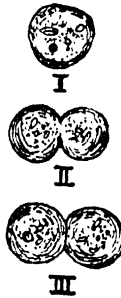


FIG 2. AMŒBA (Magnified).

I. Encysted. II. Dividing. III After division into two.

The amœba multiplies by division or fission which originally starts in the nucleus. After a certain number of fissions, however, the number varying according to the species, this mode of reproduction ceases and conjugation takes place in the following manner. Two amœbæ come into intimate contact with one another and the protoplasm of one merges into that of the other and their nuclei join. The amœbæ separate after conjugation and becoming rejuvenated continue their life cycle. Conjugation may sometimes result in the encystment of their protoplasm in a thin wall where they break up into numerous spores; after a time these spores throw off their coverings and attaining mature development, function as amœbæ. They grow, move about, respond to stimuli, feed, excrete and reproduce; in short they fulfil all the activities of living matter. Conjugation of the amœbæ should not be confused with the ingestion of one amœba by another; one is the outcome of love and the other the result of hunger. The distinction between hunger and love is very difficult to determine except by the net result of rejuvenation.

## PARAMÆCIUM

*Paramæcium* or the *slipper animalcule* is one of the types of infusoria and being ciliated belongs to the class of ciliated infusoria. It is a minute organism found in water in which decaying organic matter is present, such as the stale water of flower vases. A culture of paramæcia may be obtained by allowing hay to decay in water and adding to this infusion some weeds containing paramæcia.

Place a drop of water containing paramæcia on a slide and examine it under the low power of the microscope. The rapid movements of the paramæcia may be arrested by the introduction of a weak solution of cocaine hydrochloride; examine an inactive paramæcium under high power and make a sketch.

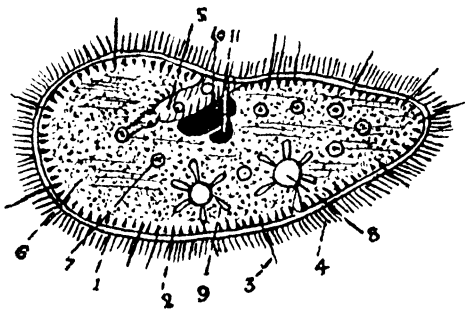


FIG. 3. PARAMÆCIUM, (highly magnified).

1. Ectoplasm, 2. Trichocyst layer, 3. Discharged threads, 4. Cilia, 5. Mouth and Gullet, 6. Endoplasm, 7. Food vacuole, 8. Contractile vacuole, 9. Contractile canal, 10. Macronucleus, 11. Micronucleus.

*Form and General Structure.* The paramæcium is oval in shape, is rounded anteriorly and ends in a blunt point posteriorly.

It consists of an outer ectoplasm or cortex and an inner endoplasm or medulla.

The ectoplasm consists of four layers :—

1. The pellicle, is the tough outermost layer which gives the shape to the animal ;
2. The contractile layer of myoneme threads which is the cause of the movements of the animal.
3. The trichocyst layer, consisting of spindle shaped saes arranged side by side which shoot out stiff threads when the animal is irritated. These threads are longer than cilia and their function is both aggressive and defensive.
4. The spongy layer is the innermost layer where the fluid excretion from the endoplasm gets collected into two contractile vacuoles situated on the dorsum. The fluid accumulates in the vacuole during its expansion or *diastole*. When the vacuole contracts or enters into *systole* the fluid is extruded through a series of canals.

Apart from the above, the cilia, the oral groove and the potential anus are also found in the ectoplasm. The cilia are numerous delicate filaments of about equal length found on the surface of the body. These move only in one direction and by their movements aid the animal in moving about and ingesting food. The oral groove or peristome, begins at the anterior end of the paramœcium and leads to the mouth and gullet. Food is carried to the mouth and gullet by the cilia, and from there to the endoplasm by means of food vacuoles.

The potential anus is situated between the mouth and the posterior end of the paramœcium and becomes visible when waste products are extruded. The endoplasm or medulla which forms the central portion of the body, is granular semi-fluid and contains the food vacuoles with food material ; the macronucleus, a large ovoid nucleus near the middle of the cell is concerned with the ordinary life of the animal.

The micronucleus which is situated near the macronucleus is concerned with reproduction.

The paramœcium derives its nourishment from proteins, starches and fats, and so it stands higher in the scale of animal life than the amœba.

Reproduction takes place by fission which starts with the division of the micronucleus by mitosis, and this is followed by the simple division of the macronucleus. A constriction appears in the body of the paramœcium and goes on increasing until the animal divides into two halves, each half sharing both the macro- and the micronucleus.

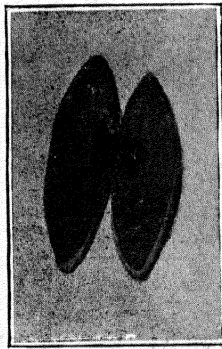


FIG. 4. PARAMŒCIA (magnified).

Separating after conjugation.

This mode of reproduction, after being repeated a certain number of times gives way to conjugation as the cell gets exhausted. Conjugation takes place by the intimate contact of their ventral surfaces and by the amalgamation of the protoplasm of their bodies. These animals swim about for sometime in this state of conjugation and after certain changes in their macro- and micronuclei separate, having become rejuvenated, that is, both once more become capable of binary fission.

## The Metazoa

**O**F the metazoa the *cœlenterata* are multicellular animals whose cells are arranged in a definite manner to form a covering for the body and a lining for the cœlomic cavity, the *enteron*. The external covering, the *ectoderm*, is continuous with the internal lining, the *endoderm*, at the only aperture of the body, the mouth; the substance existing between these two layers is known as the *mesoglaea*. Cœlenterata include the sea anemones, coral polyps, jellyfish, hydra, etc.

### *Diploblastica*

#### HYDRA

*Hydra* is an example of the cœlenterata. It is found in ponds and ditches, and also adhering to water-weeds in fresh water tanks and has different names according to its colour. The green variety is known as *Hydra viridis*; the brown as the *Hydra fusca* and the orange as *Hydra vulgaris* or *gresia*.

*Collect some water weeds from such a tank and place them with fresh water in a large vessel covered over with a dark paper having a small opening to admit light. The hydra will be found to collect near the opening as small sticky yellowish threads; take some of these with a pipette, place them on a slide and examine them under the microscope.*




FIG. 5. HYDRA FUSCA, ON A WATER PLANT (magnified).

The size of hydra when fully extended is from a quarter to half an inch in length ; it has a tubular body one end of which is attached to a circular disc ; the other is free and bears from four to ten tentacles. The digestive cavity or enteron which fills the whole body is also continued into the tentacles. The tentacles are found studded with stinging cells called nematocysts. At the top of the free end and surrounded by the tentacles is an elevation called the hypostome and in the centre of this is an oval opening, the mouth, which serves both for the ingestion of food and the excretion of waste material. Projections of various sizes may be seen at the

side of the hydra. These are the daughter buds at various stages of development. The testis is situated at the upper end and the ovary lower down, and so, it is obvious that the animal is a hermaphrodite. The animal moves about by elongating its body or contracting it into a nodule.

Hydra will be found to be covered over externally by a transparent ectoderm; the endoderm is inside while between the two is a supporting lamella, the mesogloea. The mesogloea should not be confused with the mesoderm or the middle layer of the triploblastic animals. The hydra has only two layers and is therefore called diploblastic.

Hydra prefers to be quiet. It feeds on small animals such as the cyclops and larvæ which it paralyses by the nematocysts of the tentacles and swallows them by bending the tentacles holding the prey towards the mouth sometimes assisted by other tentacles. Digestion is carried on by means of digestive fluids which liquify the food which thus gets into the cells either by means of osmosis or by the engulfment of solid particles by the endoderm cells. If a piece of hydra representing all the layers is cut, it grows into a new animal.

*Minute Structure.* The ectoderm is composed of conical epithelial cells with the stinging cells wedged in between them. A great number of the ectoderm cells have tapering contractile fibrils lying on the mesogloea and constitute the neuro-muscular apparatus. Interstitial cells will also be found in between the ectoderm cells, these sometimes proliferate and protrude externally being covered by the ectoderm and forming the testis or the ovary; the interstitial cells sometimes develop into cnidoblasts or stinging cells that contain fluid under great pressure and have hair that stick out and a thread or nematocyst that may either be straight or looped. When a hydra attacks an animal one of these threads pierces and remains inside the body of the prey, while the fluid acts as a poison. The hydra then develops new nematocysts. The digestion of a hydra is carried on

by means of digestive fluids, which liquify its food. This food gets into the cells by osmosis or by the endoderm cells engulfing the solid particles.

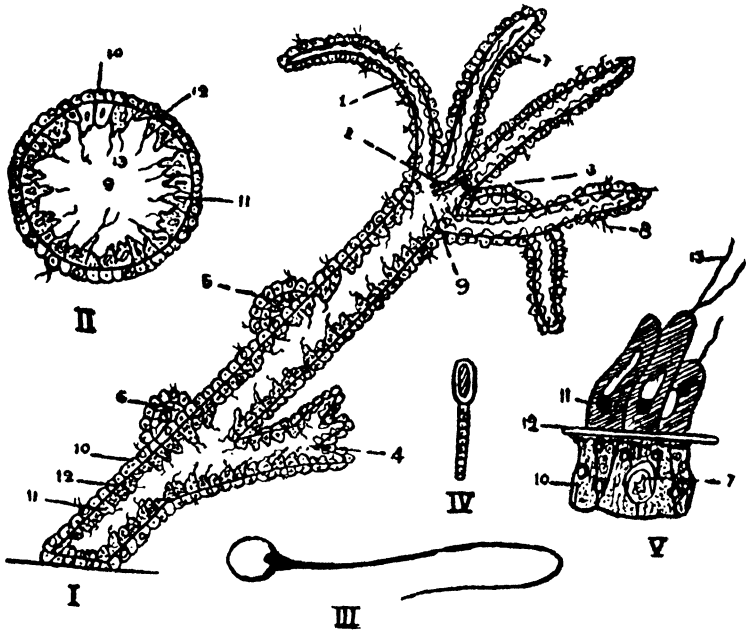


FIG. 6. HYDRA (highly magnified).

I. Longitudinal Section. II. Transverse Section. III. Nematocyst. IV. Small stinging thread, V. Cells.

1. Tentacle, 2. Hypostome, 3. Mouth, 4. Bud, 5. Testis, 6. Ovary  
7. Nematocyst, 8. Nematocyst thread, 9. Enteron, 10. Ectoderm, 11. Endoderm, 12. Mesogloea, 13. Flagella.

Reproduction takes place asexually by budding; a knob develops on the side of a hydra which gradually develops into a small animal. Sexual reproduction takes place under unfavourable circumstances.

Though the animal is hermaphrodite, self-fertilization seldom takes place as the sperm cells are discharged before the ovum becomes mature.

*Development.* A large cell, the ovum, develops in the ovary; this increases in size and extrudes two polar bodies. Rupture of the ectoderm takes place because of the increasing pressure

inside but the ovum remains attached to the parent, and gets fertilized by the spermatozoon entering the distal pole. This is followed by segmentation and the result is a mass of cells the morula, which in favourable circumstances develops into a young hydra and eventually separates from the parent cell. Sometimes the morula drops to the bottom and after breaking through its chitinous covering emerges as a young hydra.

*Symbiosis* is a phenomenon in which two types of organisms live together, neither of them being parasitic or detrimental to the other, but on the contrary both benefit by each others presence. A good example is furnished by *hydra virides* in which the green colour is due to the presence of minute unicellular plants, *Chlorella vulgaris*, which surround and encase the lower portion of the hydra. The plant and the hydra are mutually beneficial as the plant helps the hydra to get rid of its carbon dioxide and the hydra protects the plant and supplies it with carbon dioxide. A hydra can live without these green plants but its vitality becomes very poor.

*Triploblastica*

Triploblastic animals are those that are formed by the three layers, the ectoderm, the mesoderm and the endoderm. The simplest of these are the segmented coelomate worms, the *annelids*, which are bilaterally symmetrical, and possess a nervous and a circulatory system. We shall examine one of its common types, the earthworm.

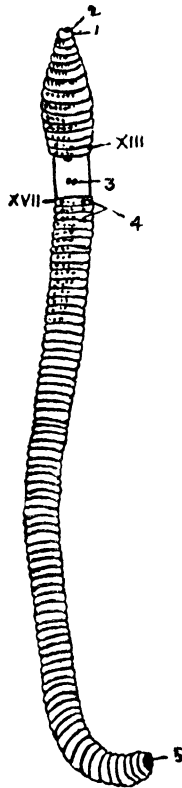


FIG 7. EARTHWORM.

1. Buccal cavity, 2. Prostomium, 3. Female genital aperture, 4. Male genital aperture, 5. Anus.

## EARTHWORM

The earthworm or *Perichæta posthuma* lives in moist earth and eats its way through the ground thereby swallow-

ing large quantities of mud with small particles of vegetable and organic matter which passes through the alimentary canal and gets digested and absorbed. This forms the food of the animal. The animal moves about by the alternate contraction and elongation of its body. It is usually colourless, but the parts that are exposed to light are darker in colour. Although the earthworm has no eyes it is sensitive to light which it avoids and is nocturnal in its habits. It is hermaphrodite but usually the sperm of another worm fertilises the ovum.

The earthworm measures anything from three inches to a foot and has a cylindrical body that tapers in front, is flattened behind and is marked by transverse grooves that divide the body into segments. There are from a hundred to a hundred and fifty of these segments. The segmentation is complete and the segments of the posterior two thirds of the body which resemble each other are known as *metameres* or *somites*. The extreme anterior end forms the *prostomium* or the cephalic lobe. Situated posteriorly on the fourteenth, fifteenth and sixteenth segments is a thickening of the skin due to the development of glands which aid in the formation of cocoons for the eggs. In some worms this thickening forms a band, the *cingulum*, while in others it is undefined on the ventral aspect and presents the appearance of a saddle. This is called the *clitellum* and its position varies with the species. The cuticle of the earthworm is delicate and invests the whole body. In nearly every segment the cuticle develops four pairs of bristles known as *setæ* which help in the movements of the animal. Between each of the hinder segments dorsally there is an opening called the dorsal pore which forms an aperture of communication between the cœlom and the exterior.

*Dissection.* Kill the worm either by chloroform or methylated spirits and pin it down carefully on to a lead bottomed cork under salt solution with its dorsal surface upwards. Cut open the whole cœlomic cavity carefully so as not to injure the various organs and remove the dorsal flap.

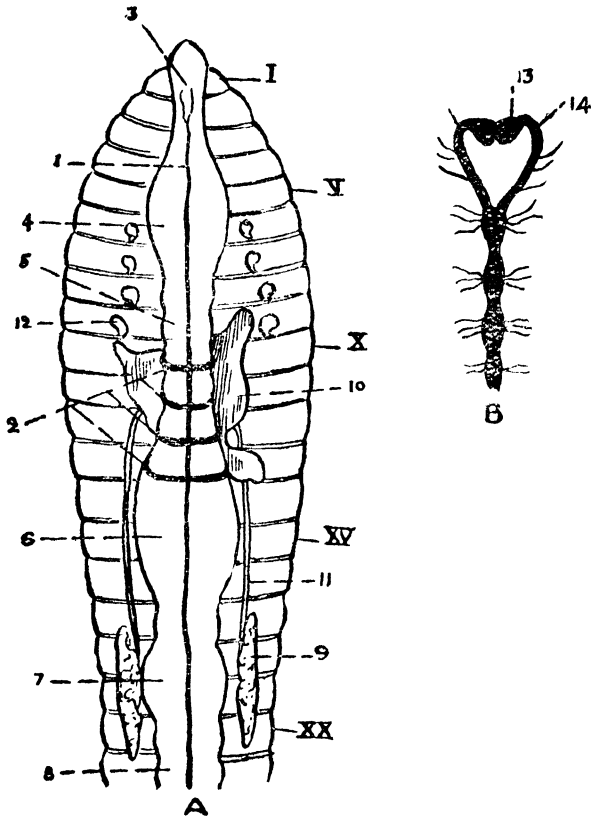


FIG. 8. EARTHWORM (enlarged).

A. After removal of dorsal wall, B. Nervous System.

1. Dorsal blood vessel 2. Hearts, 3. Buccal cavity, 4. Pharynx, 5. Oesophagus, 6. Crop, 7. Gizzard, 8. Intestine, 9. Seminal receptacle, 10. Seminal vesicle, 11. Vas deferens, 12. Spermatheca, 13. Suprapharyngeal ganglion, 14. Circumpharyngeal commissure.

*The earthworm has a body cavity, the cœlom, across which partitions or septa separate the different segments but not completely. Some fluid is found in this cavity with cellular elements. The cavity in all probability communicates with the exterior by means of the dorsal pores and the excretory tubes.*

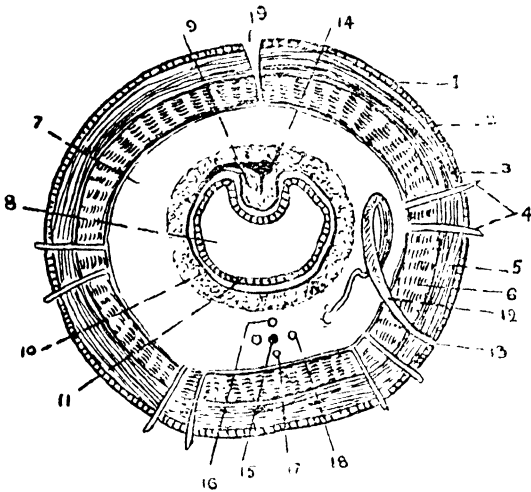


FIG. 10. TRANSVERSE SECTION OF EARTHWORM.

1. Cuticle, 2. Epidermis, 3. Dermis, 4. Setae, 5. External muscular layer, 6. Internal muscular layer, 7. Cœlom, 8. Intestine, 9. Typhlosole, 10. Muscular layer, 11. Columnar epithelium, 12. Nephridium, 13. Nephropore, 14. Dorsal vessel, 15. Ventral nerve cord, 16. Subneural vessel, 17. Supraneural vessel, 18. Lateral neural vessel, 19. Dorsal pore.

*Transverse Section of the Earthworm.* The section is round; anterior to each somite there is an opening called the dorsal pore; which throws the cœlom in communication with the exterior.

A. *The integument consists of :—*

1. The cuticle which is a thin superficial layer.
2. The epidermis which lies underneath the cuticle with a single layer of columnar cells with basal nuclei, some of them being goblet cells.
3. The dermis which is beneath the epidermis (a thin layer).
4. The setae which are invaginations of the skin into the body. These are cuticular and are moved by special muscles.

B. *The muscular layer.*

1. The external muscular layer consists of circular muscular fibres round the body.

2. The internal muscular layer is very thick and consists of longitudinal fibres.
- C. The coelomic cavity is lined by peritoneum which is reflected on to the gut. The peritoneum consists of flat epithelial cells. Some portion of the gut however has a covering of large cells called yellow cells on account of the pigment they contain. The cavity contains a fluid with amœboid corpuscles.
- D. The intestine is in the middle of the section and forms one half of the coelomic cavity together with :
1. The typhlosole, a fold on the dorsal wall of the intestine.
  2. The epithelium consisting of a single layer of columnar cells.
  3. The muscular layer being a thin layer of circular fibres.
- E. The nephridia are seen on either side of the alimentary canal cut in various forms.
- F. The septa may be found cut across in places. They are incomplete because of their obliquity.






PLATE I. FEMALE PALINURUS (dorsal view).

*To face page 20]*

lengths, that contain grains of sand or *otoliths*. These otoliths because of the force of gravity press on different bristles in different positions thereby stimulating them and making the animal conscious of its exact position. If the otoliths be replaced by particles of iron, the effect on the animal remains the same, but if a strong magnet is brought near, the balance of the animal gets upset on account of the displacement of the iron particles.

The antennæ have a common triangular base formed by the fusion of the coxocerites and on the ventral aspect of this base, there is an opening of the green gland or the kidney on each side. There is no exocerite and the endocerite consists of two basal joints with a very long annulated flagellum. The space between the coxocerite and the endocerite is filled in by the basicerite.

The mandible is a strong transverse protognathite with a three jointed palp, the endognathite. The proximal part of the palp is the basignathite. The upper lip or labrum lies in front and the hinder portion of the mandible articulates with the base of the epimeron.

The first maxilla is a trifoliate structure situated behind a soft slip known as the *metastoma*. The inner segment is the coxognathite, the middle the basignathite, and the outer the endognathite.

The second maxilla is overlapped by the first and consists of two lamellar plates, the outer is the more important one and is called the *scaphognathite*. The scaphognathite is situated in the branchial chamber and moves in such a way as to cause the renewal of water in the gill chamber.

*The Appendages of the Thorax.* These consist of eight pairs; the first three pairs are the maxillipeds and the last five are the walking legs. The maxillipeds possess a well developed exopodite which the legs do not, and they have an epipodite attached to the coxopodite that runs up to the gills.

The first maxilliped is modified, and consists of a protopodite with two thin plates, the inner border of which is set with hairs. The epipodite is thin and has no gill connected with it. The endopodite which is also thin is oval while the exopodite is very large.

The second maxilliped which may be taken as a typical limb is made up of a proximal protopodite consisting of a coxopodite and a basipodite. On the outer surface of the coxopodite there is a new structure, which runs up to the gill chamber, and has a gill and a leaflike structure, the *epipodite*. The basipodite forms a movable joint with the coxopodite but is ankylosed (forms a fixed joint) with the endopodite. The exopodite is a long, many jointed, flat filament.

The third maxilliped is larger than the second. The epipodite is well developed but the exopodite is completely suppressed; otherwise it would serve as a typical appendage.

The legs consist of a short coxopodite with a small epipodite a basipodite firmly united with an ischiopodite, a long meropodite with a short carpopodite, a setose propodite and a hairy dactilopodite. The first leg though short is strong and has a distinct epipodite. The second leg is longer and thinner than the first. The third is the longest, and its dactylopodite ends in a claw with two rows of setæ and the female palinurus has a pinhole opening of the oviduct on the ventral surface of its coxopodite. The fifth leg has no epipodite; on the ventral surface of the coxopodite in the male, there is a large opening for the *vas deferens*. In the female, the protopodite is prolonged into a spine which in apposition with the dactylopodite forms a pincer. This is the only structure in the palinurus that represents the forceps of the lobster, crayfish and crab.

*Abdominal legs.* The first abdominal somite has no appendages. The first four pairs of abdominal appendages are

called *swimmerets* or *pleopods* and the last pair is called the *uropods*. The swimmeret consists of a two jointed protopodite with a flattened endopodite and an exopodite. In the female the swimmerets have numerous hairs which serve as carriers of eggs.

*The Muscular System.* (*vide Fig. 11*) The muscles consist of white fleshy masses made up of muscular fibres with transverse striations, and these are inserted into the inner surface of the cuticle. The four important muscular groups are (1) the *extensor* muscles on the dorsum, which straighten the tail, (2) the *flexor* muscles on the ventral aspect which are very powerful and which by their contraction bring the tail underneath the thorax thus causing the backward darting movements of the animal, (3) the muscles which move the appendages, (4) the muscles which work the gastric mill.

*The Vascular System. Dissection.* Remove the dorsal part of the carapace by two parallel cuts with the scissors from the posterior margin of the thorax to the orbital margin in front and detach this portion of the carapace with the rostrum. Remove the terga of the abdominal segments and observe the pigmented integument lining the carapace internally.

The heart which is spongy inside is situated dorsally in the thorax under the carapace, in a non-muscular pericardial sinus. The walls of the heart are muscular. Six openings or *ostia* guarded by valves will be seen; a pair on the dorsal aspect, a pair on the ventral aspect and one on each side. These valves admit blood from the pericardium but prevent its return.

The arterial system consists of a median ophthalmic artery which runs forward over the stomach and supplies the eyes and the anterior part of the head. On either side is an antennary artery which supplies the antenna and the green gland of its side. Lower down is a pair of hepatic arteries

which supply the digestive (hepatic) gland. A large artery issues posteriorly which soon divides into a dorsal abdominal and a sternal artery. The dorsal abdominal artery runs backwards to supply the intestine and the dorsal muscles while the sternal artery runs downwards and passing through an opening in the large *thoracic* ganglion divides into two branches, the *ventral thoracic* that supplies the legs, jaws and other neighbouring structures, and the *ventral abdominal* that supplies the swimmerets and the ventral muscles.

When the heart dilates or passes into diastole, blood from the pericardial sinus rushes into the heart through the ostia ; in systole or contraction of the heart the blood passes along the arteries, being prevented by the valve from re-entering the pericardial sinus. From the arteries the blood passes into the arterioles ; then into capillaries where it collects in the blood sinuses and finally gets into a large median sternal sinus. From the sternal sinus blood passes by the *afferent branchial vessels* to the gills where it gets oxygenated and is brought back by the *efferent branchial vessels* which unite into six *branchiocardiac* vessels and open into the pericardial sinus.

The blood consists of a fluid called plasma and a few amœboid cells. The plasma contains a respiratory pigment known as hæmocyamine.

*The Digestive System.* The alimentary canal consists of three parts. The foregut or stomodæum which is an invagination of the ectoderm in the anterior region ; this joins the midgut anteriorly ; the midgut is the original cavity of the gastrula and is lined by the endoderm ; and the hindgut or proctodæum, which is an invagination of the ectoderm posteriorly and which, joins the midgut behind.

The mouth is an opening on the ventral aspect behind a quadrangular plate, the labrum, and in front of the meta-

## Arthropoda

Arthropoda which are so called because they possess jointed limbs, constitute more than half the known species of animals and include insects, spiders and prawns. The arthropoda are bilaterally symmetrical, they are segmented externally and are covered with a chitinous cuticle which is continued into the alimentary canal and is cast off periodically. The chief classes of the arthropoda are Crustacea, Insecta and Arachnida.

### PALINURUS

The palinurus or spiny lobster belongs to the class Crustacea. It is usually found in the sea and in India on the rocky places on the coast. It swims and darts forwards or backwards in the sea and walks while at the bottom.

The surface of the palinurus is covered over with a hard spiny cuticle, which is chitin impregnated with lime. This chitin continues through the mouth, gullet, stomach, through the greater part of the intestine and the anus. The whole of this chitinous covering is periodically shed off (*ecdysis*). Between each somite the cuticle, which is called the *apodeme*, is soft and folds on itself.

*External appearance.* The front part is covered over by a continuous plate, the cephalothoracic plate or carapace. This is adherent dorsally but is free at the sides that cover the gills and is called the *branchiostegite*. One of its sides is marked by a groove, the *branchio-cardiac groove*. Dorsally the division of the head and the thorax is marked out by a furrow, the cervical groove, behind which is a quadrilateral area, the cardiac area, covering the heart. The lateral margins called the *endrophragmal system* are prolonged into the body where they form an archway for the thoracic nerves and some of the vessels. The thorax is protected ventrally by five pieces which together form the breast plate.

Each of these pieces is known as the sternum. The body of the palinurus may be divided into three groups of segments ; the head consisting of five segments, the thorax of eight and the abdomen of six. There is also a terminal segment the *telson* which has the anal opening but does not bear appendages. The other segments, with the exception of the first abdominal segment bear a pair of appendages. The stalked eyes are situated in front and move freely, on either side of the head ; a spine projects forward between them called the *rostrum*.

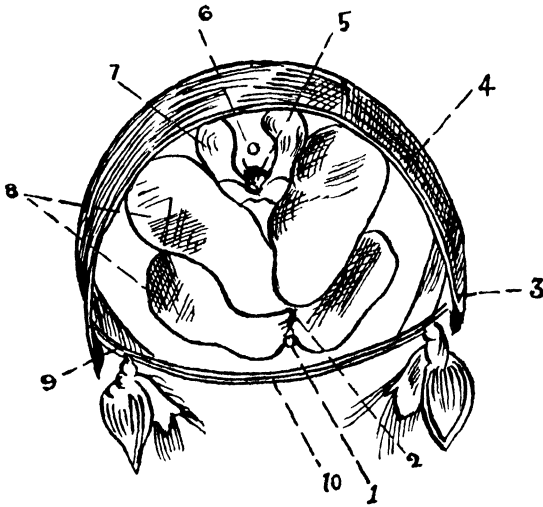


FIG. 11. TRANSVERSE SECTION OF SECOND ABDOMINAL SEGMENT OF PALINURUS

1. Sternal artery, 2. Nerve cord, 3. Pleuron, 4. Tergum, 5. Intestine, 6. Dorsal Aorta, 7. Extensor muscles, 8. Flexor muscles, 9. Epimeron, 10. Sternum.

The examination of a typical abdominal somite shows an arch shaped structure consisting of a hard covering on the back called the *tergum*. Each of these terga overlaps the tergum behind, but the second also overlaps the first tergum. The tergum is prolonged downwards laterally as the *pleuron* and the floor of the arch is formed by the sternum. A small area between the pleuron and the appendage is

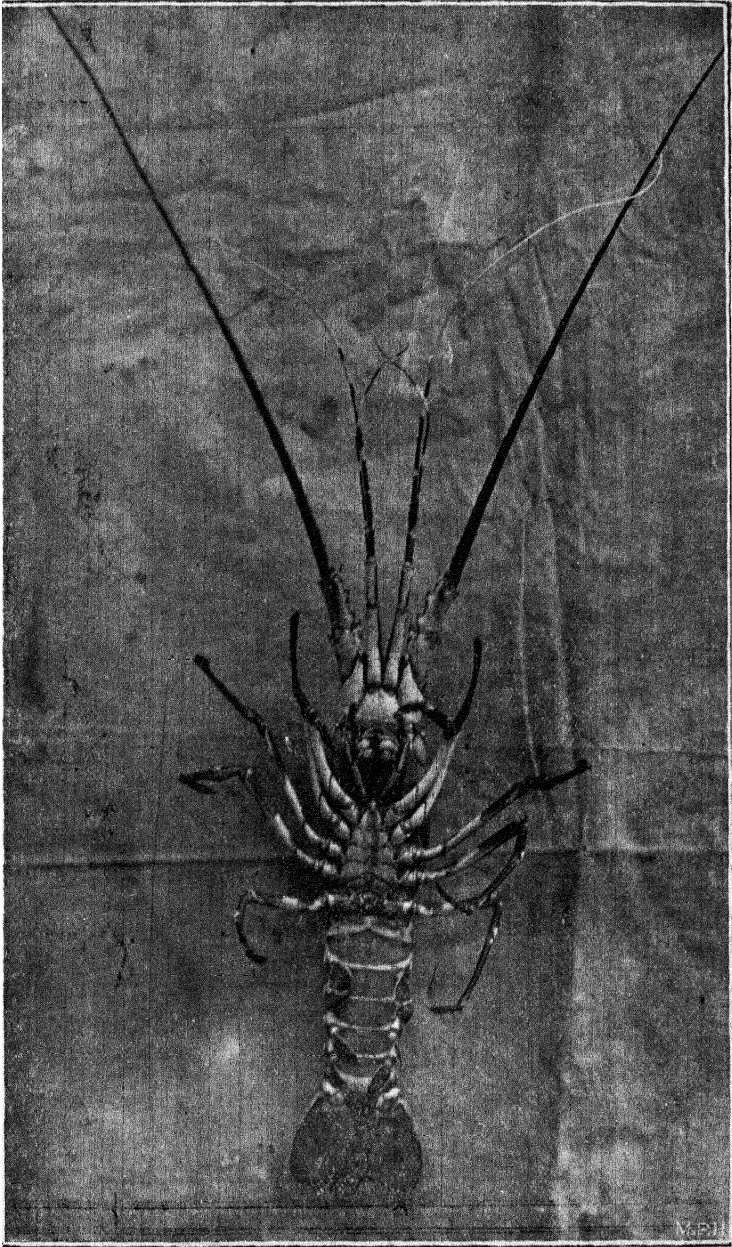


PLATE II. FEMALE PALINURUS (ventral view).

[To face page 80





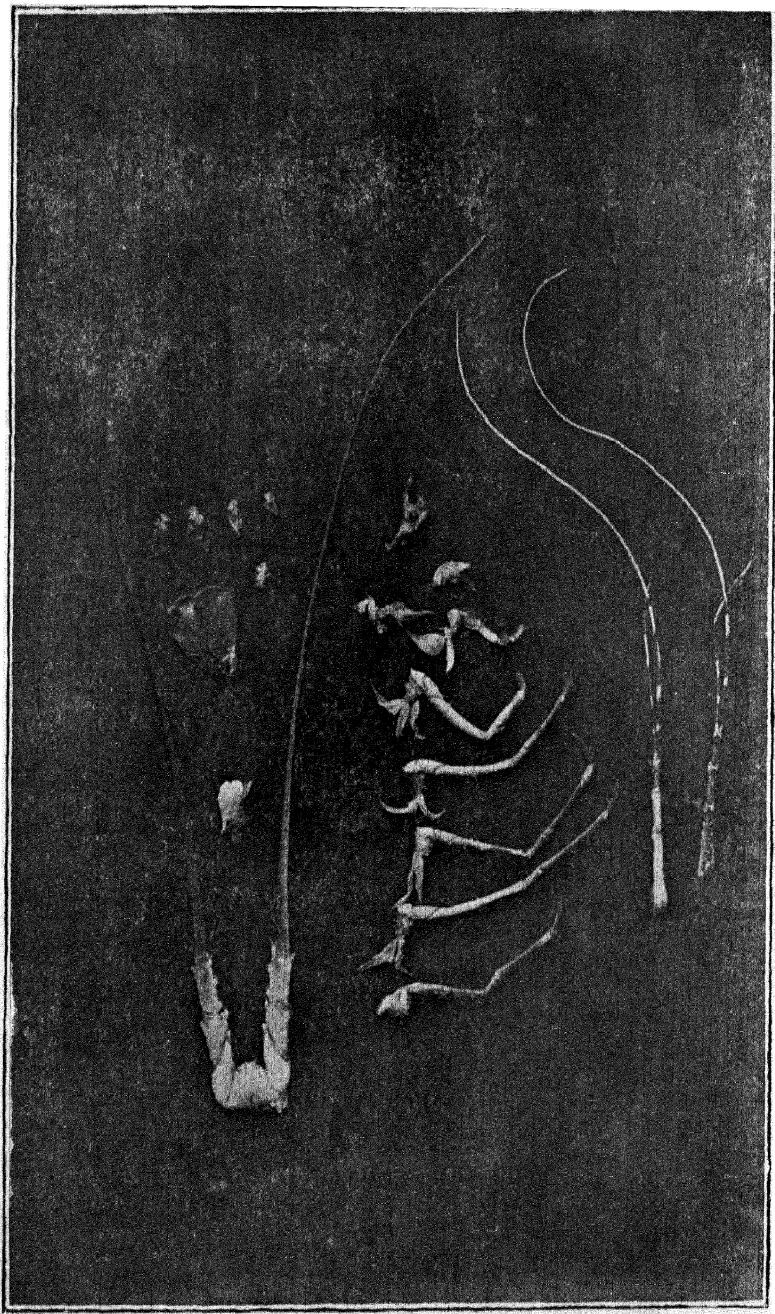


PLATE III. APPENDAGES OF PALINURUS.

*To face page 31]*

known as the *epimeron*. The integument between the sterna is soft and permits of free movements.

On each side the tergum fits into the anterior margin of the next sternum by means of hinge-joints; this arrangement allows movements only in the vertical direction.

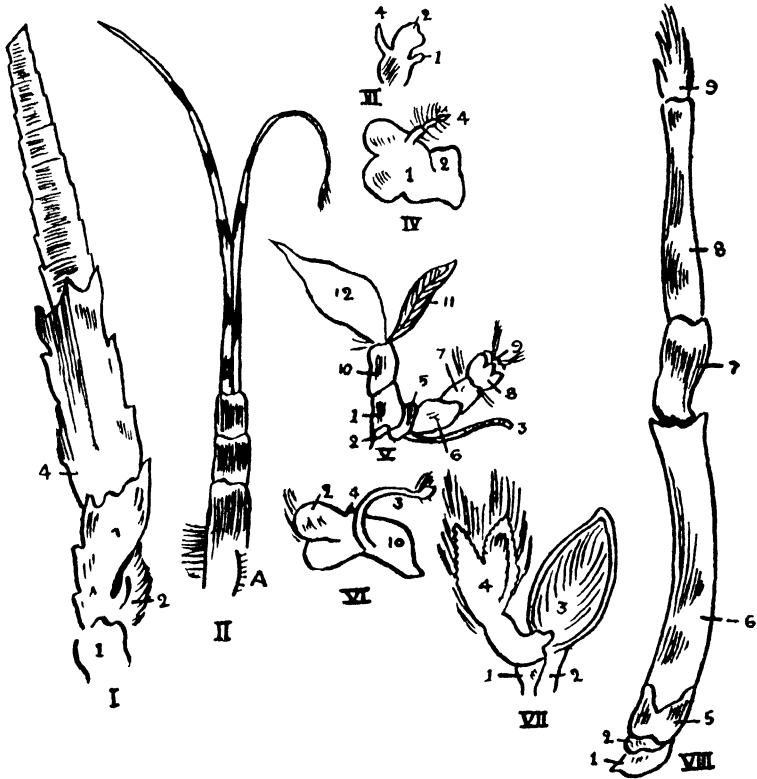


FIG. 12. APPENDAGES OF PALINURUS.

I. Antenna. II. Antennule. III. Maxilla. IV. Mandible. V. Second Maxilliped. VI. First Maxilliped. VII. Pleopod of Second abdominal Somite. VIII. Fifth walking leg of female.

1. Coxopodite, 2. Basipodite, 3. Exopodite, 4. Endopodite, 5. Ischiopodite, 6. Meropodite, 7. Carpopodite, 8. Propodite, 9. Dactilopodite, 10. Epipodite, 11. Gill, 12. Lamella.

*Appendages.* A typical appendage is made up of a *protopodite* with two joints, a *coxopodite* and a *basipodite*. Two jointed branches arise from the protopodite, one internal, the

*endopodite* and the other external, the *exopodite*. The endopodite has five parts: the *ischiopodite*, the *meropodite*, the *carpopodite*, the *propodite* and the *dactilopodite*.

The parts of an appendage may be changed in adaptation to the function it has to perform either by modification or change in their shape, atrophy or their shrinking, suppression or total disappearance, hypertrophy or excessive development, or by their union.

The termination *podite* is used for the leg, *cerite* is used for the feeler (antenna) *e.g.*, protocerite, and *gnathite* is used for the jaw *e.g.*, protognathite.

The head appendages consist of the following five pairs; the antennules, the antennæ, the mandibles, the first maxillæ and the second maxillæ.

The antennules consist of a three jointed base, the protocerite, and two very long terminal annulated feelers representing the endocerite and the exocerite, the inner one being the longer of the two. On the dorsal surface of the proximal joint is the auditory opening of the *statocyst*.

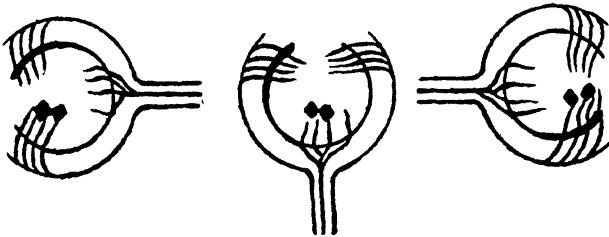


FIG. 18. DIAGRAM OF STATOCYST SHOWING THE NERVES STIMULATED BY OTOLITHS.

*The ventral portion of the proximal joint should be cut away and the cyst should be searched among the muscles, and dissected out.*

On examination with a magnifier it will be found that the inner surface of the sac is lined with bristles of various

stoma. It is bounded on the lateral side by the mandibles and leads into a short œsophagus which opens into the gizzard or stomach. The stomach occupies a large part of the anterior body cavity, and consists of a dilated anterior portion, the cardia, and a narrow posterior portion, the pylorus. The stomach is lined by a thin chitinous layer and is raised in the form of ridges, teeth and ossicles which aid in tearing and crushing the food ; while the pylorus is covered with stiff hair which strain the undivided food and allow only the smaller particles to enter the mesenteron or midgut. The midgut has a lining of secretory cells which continue through the hepatic ducts which open on the floor of the midgut. The liver or hepato-pancreas is situated next to the stomach and secretes ferments which act on proteins, starches and fats converting them into peptones, sugars and emulsions respectively. The hindgut is the last portion of the alimentary canal and is formed of an ingrowth of the ectoderm ; it is lined by chitinous cuticle which is thrown into longitudinal ridges. The opening of the hindgut or anus is situated on the ventral surface of the telson.

*The Excretory System.* The green glands or *nephridia* which excrete nitrogenous waste are situated at the bases of the antennæ ; each gland consists of a coiled tube and opens into a bladder which serves for the storage of urine and opens on the ventral aspect of the antenna.

*The Respiratory System* consists of the gills, which are vascular outgrowths of the body wall covered over by a thin cuticle. They are situated between the wall of the thorax internally and the branchiostegite externally. Each gill consists of a midrib with branches of hollow filaments arranged like a feather. The midrib contains the efferent and afferent branchial vessels.

*The Nervous System. Dissection.* Cut the gut across through its middle and raise the two ends ; remove the abdominal muscles

*carefully and define the nerve cord lying on the abdominal sterna in the middle line. The thoracic portion of the nerve cord should be exposed by removing the endophragmal skeleton which surrounds the cord. The brain will be found in front of the œsophagus.*

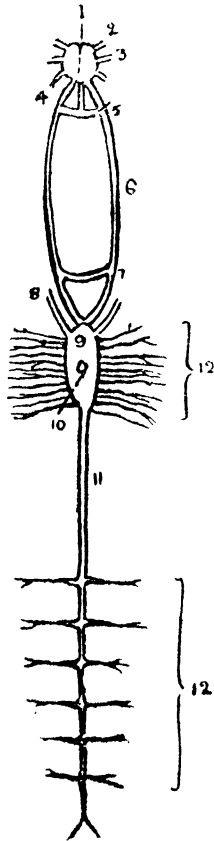


FIG. 14. NERVOUS SYSTEM OF PALINURUS.

1. Brain, 2. Ophthalmic, 3. Antennillary, 4. Antennary, 5. Anterior œsophageal commissure, 6. Para-œsophageal commissure, 7. Post-œsophageal commissure, 8. Mandibular, 9. Thoracic ganglion, 10. Opening of the sternal artery, 11. Thoraco-abdominal, 12. Nerves to segments.

The nervous system of the palinurus consists of the brain or supra-œsophageal ganglion and a nerve cord, both of which

are made up of nerve cells. These nerve cells are the originators of impulses, while the nerve fibres which are given off from the brain and nerve cord serve to transmit these impulses to the periphery. The nervous system in the cephalothoracic region is concentrated. The brain or *supra-oesophageal* ganglion is bilobed and each lobe gives off nerves to supply the eye, antenna and the antennule of its side. In the thorax an elongated ganglionic mass is connected with the *supra-oesophageal* ganglion by means of two nerve fibres, the *para-oesophageal commissures*. The *para-oesophageal* commissure is connected both in front and behind the gullet. The thoracic ganglionic mass gives off eleven pairs of nerve fibres to the eleven somites; it is therefore assumed that the thoracic mass is made up of eleven ganglia. In the centre of the thoracic ganglion there is an opening for the sternal artery. The thoracic ganglion is continued posteriorly as a nerve cord with six ganglia into the abdomen; each ganglion gives off a pair of nerves to each of the abdominal somites and the last ganglion supplying the telson gives out a nerve, the *posterior visceral nerve*, which supplies the hindgut.

*The Organs of Special Sense.* The organs of special sense in the palinurus consist of the antennæ, the antennules, the organs of sight and the auditory organs. The antenna, the antennules and the chief portion of the auditory organs, the statocyst, have been described above.

The compound eyes are supported on movable stalks and each eye is made up of a number of elements, the *ommatidea* which are covered over by a transparent cornea. Below the cornea are epidermal cells which form a new cornea and below this is the crystalline cone which is secreted by crystal cells. Below the crystalline cone is the retinula, which secretes a spindle, the *rhabdome*. The cones are separated

distally by means of pigment cells and behind these is the optic ganglion which is connected to the brain by the *optic nerve*.

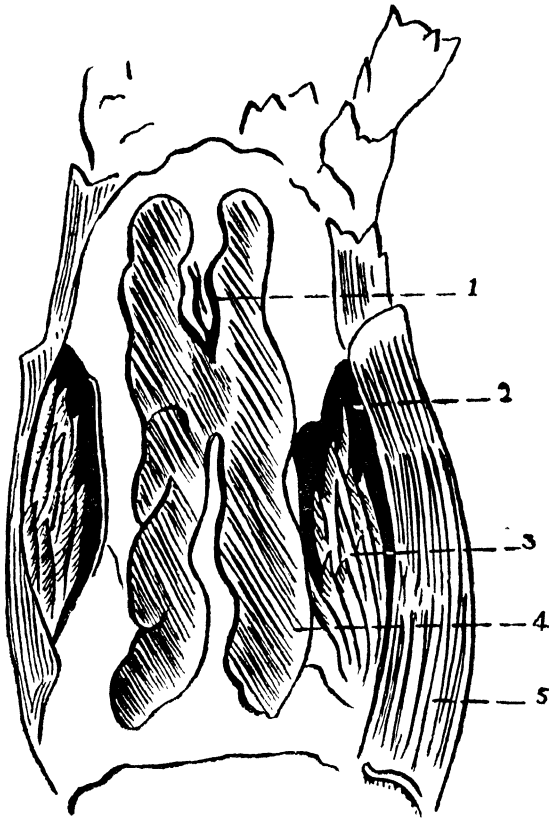


FIG. 15. PALINURUS AFTER REMOVAL OF THE DORSAL PLATE.

1. Remains of the pericardium, 2. Branchial chamber, 3. Gills, 4. Ovary, 5. Branchiostegite.

*The Reproductive System.* The *gonads* or reproductive glands of both the sexes resemble each other. They are situated beneath the pericardial sinus and are continuous with their ducts which open externally. The cœlomic cavity in the palinurus is limited only to the gonads and the green glands; the rest of the body cavity is continuous with the blood vessels and is called the *hæmocœle*.

The testes in the male are united by a horizontal piece and from the side of each testis is given off a convoluted tube, the *vas deferens*, which ends in a dilatation that acts as a receptacle for sperm. The dilated portion ends in a narrow opening on the ventral aspect of the coxopodite of the fifth walking leg. The ovaries are similarly situated as the testes; and from each is given off a short oviduct which opens on the ventral aspect of the coxopodite of the third walking leg.

The eggs laid by the female are very numerous; they are of a dark red colour and stick to the swimmerets. An egg consists of an outer covering, yolk granules, nucleus and nucleolus. Fertilization takes place outside the body by the male spermatozoon entering the ovum. Segmentation commences soon after. The nuclei divide and redivide, come to the surface and form the *germinal layer*. The embryo is then represented as a hollow vesicle formed of a single layer of cells, and is called the *blastoderm*. At one pole of the blastoderm a thickening of the cells appears, called the *germinal disc*, in which is seen a depression that becomes deeper, and forms a pouch, the *gastrula*. This pouch deepens until it forms a tube and constitutes the *archenteron* or the *primitive gut*, leaving an opening dorsally called the *blastopore*. The cells which line the archenteron are called hypoblast cells and the other cells which cover the gastrula are called the epiblast cells. It is from these cells that the skin and the nervous system develop. Next to the blastopore a fresh mass of cells known as the mesoblast makes its appearance, and it is from these cells that the muscles, connective tissue, vessels and the reproductive organs develop. The eggs are fertilised outside the body of the animal, the larva probably undergoes metamorphosis into a *phyllosoma* which is commonly known as a glass crab, and consists of a large head which is distinct from the thorax, well developed eyes, antennules, antennæ, the third pair of maxillipeds and three walking legs.

## Insecta

Insects constitute the largest group in the animal kingdom. An insect is characterised by a well defined head, a thorax and an abdomen. The head bears a pair of antennæ, a pair of mandibles and two pairs of maxillæ. The thorax is defined into three segments, the prothorax, the mesothorax and the metathorax; each of these segments bears a pair of walking legs. The mesothorax and metathorax have wings in some insects. The abdomen is devoid of appendages and consists of from five to ten segments. The respiratory system consists of the tracheæ which communicate with the external atmosphere by means of laterally placed stigmata ; this distribution makes the animal lighter and enables it to fly about. The vascular system is not well defined and the excretory system consists of Malpighian tubes which grow from the gut. The nervous system consists of a large cerebral ganglion and two nerve cords, which give off branches to various structures. Insects include ants, bees, butterflies, fleas, mosquitoes, bugs, lice, cockroaches, etc.

### COCKROACH

The cockroach belongs to the order *orthoptera*, and is in Europe popularly known as the black beetle. There are many varieties of cockroaches, of these the *Periplanata americana* and the *Stylopyga orientalis* are very common in India. The cockroach is found in kitchens, storerooms and bath rooms. It is nocturnal in its habits and is omnivorous eating anything from books and clothes to boots, vegetables and any organic matter.

*Cover a cockroach with a glass vessel and watch its movements, the way it walks, how it uses its antennæ and maxillary palp to feel the surface on which it moves. Note how it moves its mandibles and maxilla: from side to side while eating and also watch its respiratory movements. The animal may be killed by dropping a few drops of chloroform or petrol on it.*

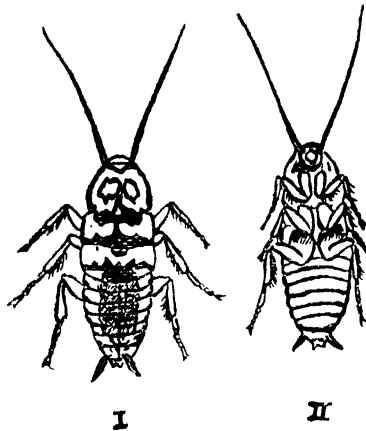


FIG. 16. FEMALE COCKROACH.

I Dorsal view. II Ventral view.

*External Features.* The body is covered over by a chitinous cuticle and is divided into a head, a thorax, and an abdomen.

The head is connected with the thorax by a small neck. The segmentation is not clear but probably there are six segments for the head one bearing the eyes, one bearing the antennæ and one each for the premandibular, the mandibular, the first maxillary and the second maxillary somite.

The head is broad from side to side and is prolonged downwards into a process bearing the jaws. The dorsum and the back of the neck are covered over by the epicranium, which is bisected by a median fissure. This fissure bifurcates in front, and each runs into a white spot, the fenestra. Below the epicranium is a broad plate, the clypeus, from the lower

edge of which hangs the labrum or the anterior wall of the mouth. Situated above on each side is the eye below which is the gena or cheek. The eyes are kidney shaped and are large and compound having numerous hexagonal facets. On the inner side of each antenna is the fenestra. When the head is severed from the neck an elongated aperture, the *occipital foramen* will be found on its posterior aspect.

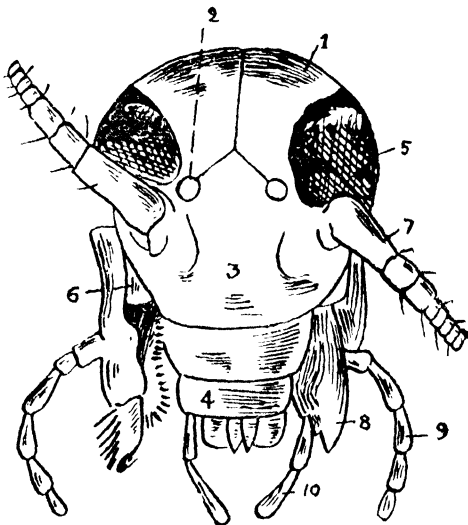


FIG. 17. Head of *Сокроаши* (enlarged).

1. Epicranium, 2. Fenestra, 3. Clypeus, 4. Labium, 5. Eye, 6. Gena, 7. Antenna, 8. Mandible, 9. Maxillary palp, 10. Labial palp.

The head appendages consist of four pairs, the antennæ, the mandibles, the first maxillæ and the second maxillæ. The antennæ are attached to the head, to the two antennary fossæ situated below the eyes and external to the fenestra. They are very long, slender, movable and many jointed filaments; their surfaces are covered with bristles and they are the organs of touch and probably of smell and hearing.

*Fix the animal on its back either by means of pins or melted wax, examine the parts in situ, remove the labrum thereby exposing the mandibles which are attached by two processes to the*

*epicranium and the clypeus ; remove the mandible, study the first maxilla in situ and then remove it.*

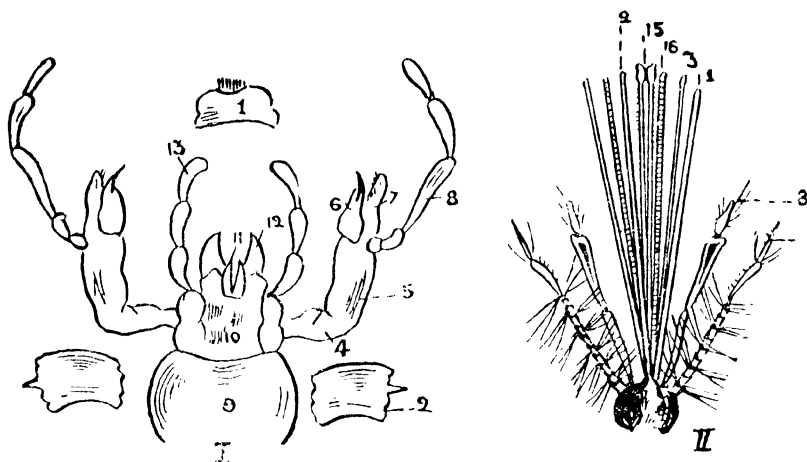


FIG. 18. MOUTH PARTS OF COCKROACH AND MOSQUITO.

1. Labrum, 2. Mandible, 3. First maxilla, 4. Cardo, 5. Stipes, 6. Lacinia, 7. Galea, 8. Maxillary palp, 9. Submentum, 10. Mentum, 11. Glossa, 12. Paraglossa, 13. Labial palp, 14. Antenna, 15. Labium, 16. Hypopharynx.

The mandibles are stout, and have teeth on their inner margins ; they work sideways and are situated below the genæ and articulate with the clypeus and the epicranium.

The first pair of maxillæ, it has been noticed is situated behind the mandibles. Each maxilla consists of (1) a protognathite with a proximal piece *cardo* and a distal one the *stipes*, (2) an endognathite with an inner lacinia which is setose on its inner end, and an outer elongated and soft *galea*, and (3) an exognathite which is known as the maxillary palp and has five joints.

The second pair of maxillæ resembles the first pair in shape but is smaller and fuses in the middle line by the protognathite to form the labium or the lip. This fusion forms a two jointed plate, the submentum proximally and the mentum distally which bear the endopodites and the exopodites. The endopodite consists of an inner lacinia or glossa and an outer paraglossa corresponding to the galea. The paraglossa and the

glossa form the ligula. The exopodite which is called the labial palp is three jointed and is attached to a stump of the mentum called the *palpiger*.

*The Thorax* is made up of three segments. The first segment, the prothorax, is the largest, its tergum which is called the pronotum is the longest and projects forwards over the neck, and backwards over the tergum of the second segment, the mesonotum. The mesothorax or the second segment is smaller than the first and from its anterior end spring the elytra, which cover the wings behind and also the mesonotum. The metathorax, or the last segment of the thorax, bears a pair of wings, which are membranous and thin, and are instrumental in the flight of the animal. These wings are spread out while flying and when not in use remain folded and covered over by the elytra.

Each of the thoracic segments bears a pair of legs, with which the animal walks about. A walking leg consists of a flat coxa to which is attached a triangular trochanter; a bristly femur with a long tibia articulating with the trochanter; the foot which is attached to the tibia consists of six pieces; the last one is clawed and has a pad called the *pulvillus*.

*The Abdomen* is broad sideways, the female having a broader abdomen than the male. The abdomen is made up of ten segments, each of which consists of a dorsal tergum and a ventral sternum. The segment behind overlaps the segment in front, the eighth and the ninth segments being hidden from view by the seventh tergum, and the last tergum is marked by a deep groove. The anus is situated underneath the tenth segment and has a pair of small *podical* plates, on each side. A pair of styles called the *cerci* are attached under the tenth tergum.

*Dissection.* Remove the legs and the wings of the cockroach and fix it either with melted wax or pins with its ventral surface downwards. Cut through the whole length of the junction of the terga and sterna on each side and raise the terga without injuring

*the structures underneath. The body cavity containing the white fatty body all round the heart and the tracheæ is thus exposed. Carefully separate the alimentary canal from the fatty body, preserving the salivary glands, the Malpighian tubes and the reproductive organs.*

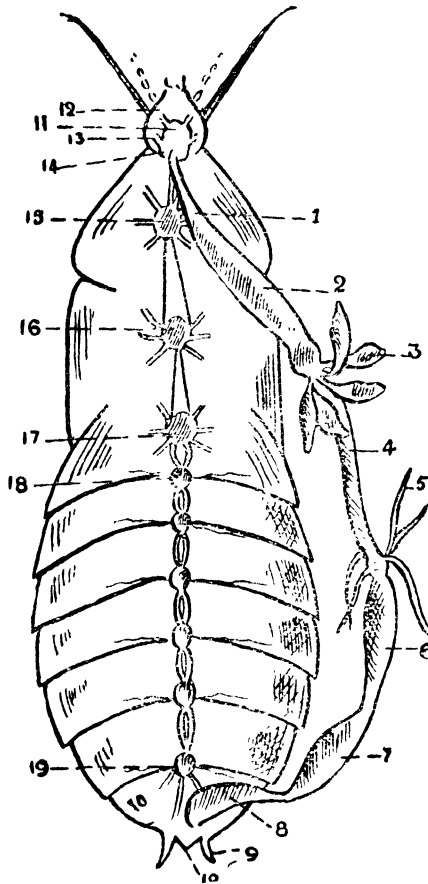


FIG. 19. DISSECTION OF COCKROACH:

1. Oesophagus, 2. Crop, 3. Hepatic cœca, 4. Stomach, 5, Malpighian tubules. 6. Ilium, 7. Colon, 8. Rectum, 9. Anal cerci, 10. Anal styles, 11. Cerebral ganglion, 12. Optic nerve, 13. Antennary nerve, 14. Sub-oesophageal ganglion, 15. Prothoracic ganglion, 16. Mesothoracic ganglion 17. Metathoracic ganglion, 18. First abdominal ganglion, 19. Sixth abdominal ganglion.

*The Circulatory System.* The heart lies in a sinus called the pericardial sinus in the middle line below the terga of the thorax and the abdomen. It consists of thirteen chambers that correspond to the somites. Each chamber narrows itself anteriorly and forms a valve allowing the flow of blood only in the forward direction, while on each side are openings called *ostia*, connecting with the pericardium. The musculature of the heart undergoes rhythmic contraction by means of which blood is taken in from the pericardium through the ostia and forced forwards into an aorta which opens into the general body cavity to supply nutriment to the various organs.

*The Digestive System.* The alimentary canal is a convoluted tube which may be divided into three regions according to its development :—The stomodæum, lined by chitin which invests the body, and developed by a dimpling in the anterior region of the cockroach which goes on deepening till it reaches the mesenteron or midgut into which it opens. The proctodæum which is also lined by chitin is developed similarly by a dimpling in the posterior region. The middle portion of the alimentary canal, the mesenteron, is the only portion lined by the endoderm.

The stomodæum consists of the buccal cavity, the œsophagus, the crop and the gizzard. The buccal cavity is situated most anteriorly and presents an elevation, behind which is the tongue or lingua. The salivary glands are two white lobes which lie next to the œsophagus whose ducts unite into one, and open in front of the tongue. The œsophagus is the continuation of the buccal cavity and is a narrow tube which passes through a nerve ring along the neck and opens into a large pyriform sac, the crop. The crop is followed by a short proventriculus or gizzard which contains six raised folds of cuticle, the *teeth*. Behind these are six elevations covered over with setæ which act as strainers of food that passes from the gizzard to the stomach. The stomach, which is developed from the midgut or the mesenteron, is a short narrow tube which is

provided in its anterior extremity with eight diverticula, the hepatic cæcæ, which probably secrete digestive juices. This is the only portion of the alimentary canal that is lined with endoderm and in which absorption of the digested food takes place. The *proctodæum* is the last portion of the alimentary canal and may be divided, into the *ileum*, the *colon* and the *rectum*, all these being lined with chitin. The ileum is narrow and receives the opening of the Malpighian or excretory tubes. The colon is wider and is marked off from the rectum by a constriction. The interior of the rectum is raised into six ridges.

*The Excretory System* consists of a number of long Malpighian tubes arranged in six sets and opening into the anterior part of the ileum.

*The Respiratory System* consists of a series of tracheal tubes which commence as stigmata on the side of the thorax and the abdomen. The tracheal tubes are lined with chitin and reinforced by a spiral thickening. The tubes ramify most elaborately and so if a tube to a certain part is blocked, other tracheal tubes carry out its function. Expiration is affected by the contraction of the transverse muscles which drive out the air from the body, while the relaxation of these muscles causes the external air to rush into the patent tracheal tubes. The circulation of air throughout the body in this manner obviates the necessity of a complicated circulatory system.

*The Nervous System* (*vide* fig. 19) is made up of metameric paired ganglia that are united together by double *connectives*; the upper ganglia are coalesced.

*Remove the cranial plate carefully, displace the alimentary canal to one side or cut it out altogether and then define the nervous system throughout the body.*

The nervous system consists of eleven pairs of ganglia which are united together both longitudinally and transversely by means of nerve fibres. The first pair or the supra-oesophageal ganglia which are situated above the oesophagus

constitute the brain and give off several branches, one of which the optic nerve, forms the nervous element of the eye, and the others supply the antennæ. The connectives to the second pair or the sub-œsophageal ganglia lie on each side of the œsophagus and are known as the para-œsophageal commissures. These commissures communicate with a distinct visceral system which supplies the alimentary canal and ramifies in its substance. The sub-œsophageal ganglia are situated below the œsophagus and supply branches to the mandibles, the maxillæ and the labrum. They communicate with each other laterally, with the supra-œsophageal ganglia above, and the first thoracic ganglia below. The thorax consists of three pairs of ganglia and the abdomen of six. These pairs communicate with each other and supply their respective segments. The last pair of abdominal ganglia also supplies the posterior segments of the body.

*The Sense Organs.* The antennæ, the maxillary palps and the labial palps are the organs of touch, and have already been examined. The eyes are large compound organs with hexagonal facets. The fenestra are probably homologous to the ocelli or simple eyes of some insects.

*The Reproductive System.* The male has a pair of *testes* placed behind the fifth tergum of the abdomen and embedded in the fatty body; these are present only in the young ones and atrophy very soon. From each testis a duct issues forth to the *vesicula seminalis* of the same side. The vesiculæ seminales are mushroom shaped glands opening into a short stalk, the *ejaculatory duct*, which opens just below the anus. Ventral to the ejaculatory duct is situated the *accessory* or *conglobate* gland whose function is not known. Surrounding the genital aperture are chitinous hooks, the *gonapophyses*.

The female has a pair of ovaries in the posterior abdominal region. Each ovary consists of eight tubes, which show bulgings of the ova inside. The ovum as it traverses the tube becomes mature and passes into the oviduct. Each tube gives

off one egg and so eight eggs pass through each oviduct. The two oviducts unite into a small uterus which opens by an aperture on the eighth abdominal theca. The sixteen ova lie in a chitinous capsule with several holes through which the spermatozoa enter. The spermathecae are small sacs which open on the ninth sternum, their function being to store the semen after copulation. The colleterial glands which are tubular in structure secrete a cement-like substance covering the egg shell and open behind the spermathecae. A series of *gonapophyses* which aid in carrying the eggs, are situated between the genital aperture and the anus. The egg case is carried for a few days by the female half protruding from the genital pouch where the eggs are fertilized by the spermatozoa from the spermathecae. After fertilisation the case is deposited in a secluded spot and the young ones come out of the egg case as small white wingless nymphs. These acquire their brown colour by exposure to light and air, and their wings appear after a series of moultings.

## MOSQUITO

Mosquitoes abound in India, and are important from a hygienic point of view because they are the carriers of various diseases. Like the cockroach they are nocturnal in their habits and are found in cool dark places and behind hanging clothes. They seem to have especial affinity for clothes that have recently been worn.

The mosquitoes may be caught by carefully inverting a glass tumbler over them and slipping a piece of stiff paper underneath. They may also be obtained by developing the larvæ which are found in collections of water containing organic substances, in pools and in slow running streams. Eggs of the mosquito usually float as small dark particles on water but they sometimes sink.

The mosquito belongs to a class of insects which is called *diptera*, *i.e.* having two wings. Some of the more important

varieties of the mosquitoes are the *Culex*, the *Anopheles* and the *Stegomyia fasciata*. Human malaria is conveyed by the *Anopheles*, bird malaria and *Filaria bancrofti* which causes elephantiasis are carried by the *Culex*, while *yellow fever* is transmitted by the bite of *Stegomyia fasciata*.

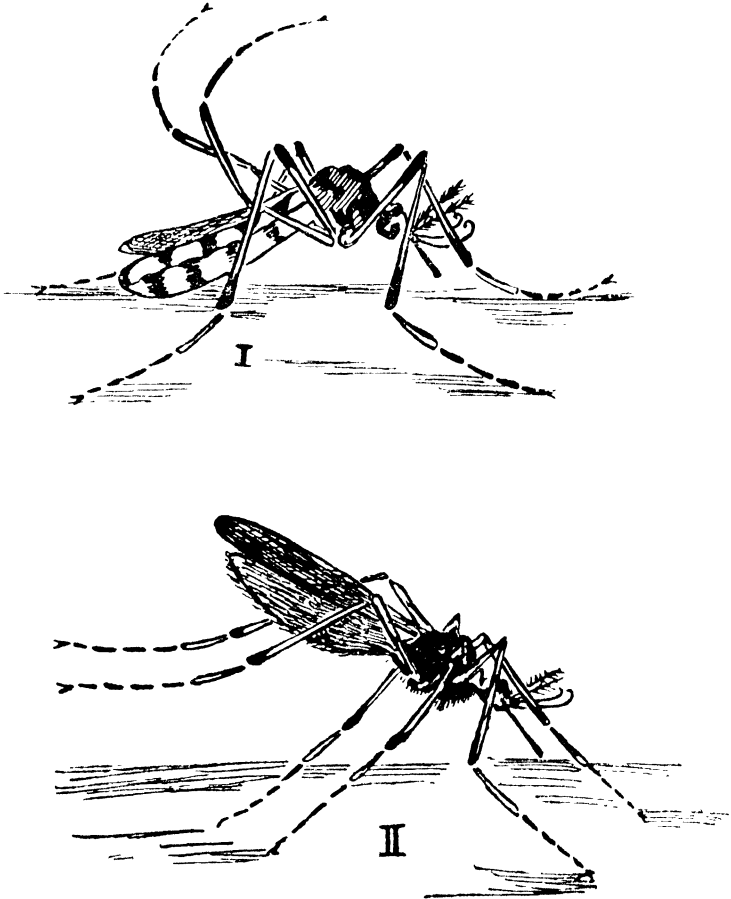


FIG. 20. MOSQUITO (ENLARGED).

I. *Culex*. II. *Anopheles*.

*General Appearance.* The head is almost wholly occupied by the large compound eyes, the rest of the surface being covered over with chitin. A triangular area, the *clypeus*, is prolonged in front of the eyes below which are the *genæ* or

cheeks. The head is connected to the thorax by means of a neck. There are four pairs of appendages for the head, the antennæ, the mandibles, the first maxillæ and the second maxillæ. The second maxillæ are fused together and are called the labium.

The antennæ are attached in front of the eyes and are composed of fifteen segments; the first or basal segment is expanded. Hair encircle the joints of these segments, being more profuse in the case of the male.

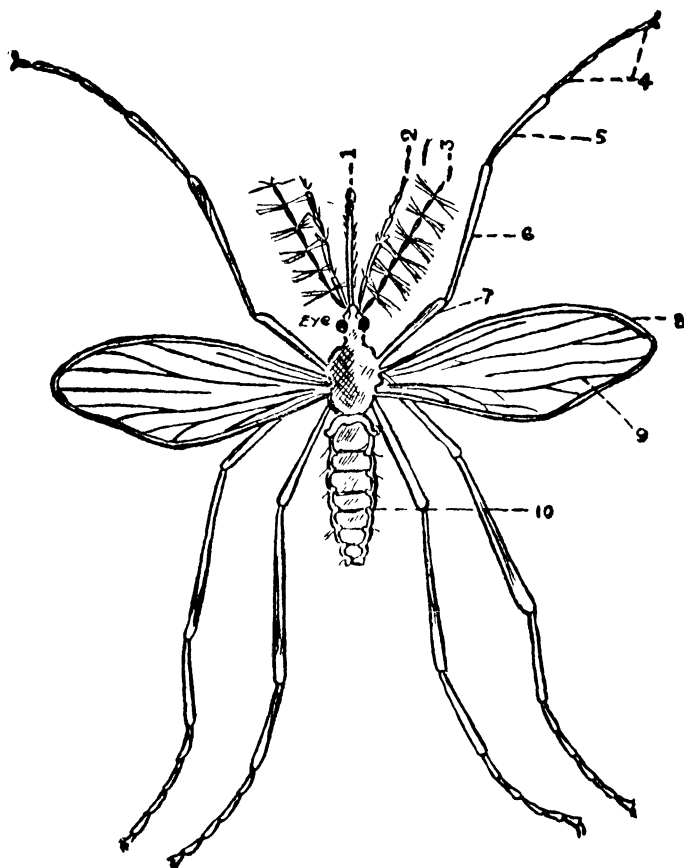


FIG. 21. Mosquito (enlarged).

1. Proboscis, 2. Maxillary palp. 3. Antenna, 4. Tarsus, 5. Tibia, 6. Femur, 7. Coxa, 8. Costa, 9. Nervures, 10. Spiracle.

The *proboscis* or the snout of the mosquito consists of the *labrum*, the *hypopharynx*, two *mandibles*, two *maxillæ* and the *labium*.

The labrum, is situated anteriorly and consists of a hollow cylinder with an open slit on its posterior side. Its inner surface is continuous with the œsophagus, and so the sucked blood passes through this tube into the œsophagus.

The hypopharynx or tongue is hollow so as to enable the animal to suck blood, but it is also flattened for its application to the labrum by means of which it gets converted into a tube. The salivary duct unlike that of the cockroach, is carried to the tip of the hypopharynx where it opens.

The mandibles are a pair of stylets each bearing a row of saw-like teeth at their terminations.

The first maxilla is curved and has a short joint proximally, the protognathite.

The second pair of maxillæ unite into a *labium* or lower lip so as to form a grooved receptacle for the piercing organs.

When the mosquito bites, the labrum and the hypopharynx pierce the skin and the labium which acts only as a director gets bent backwards.

*The Thorax* is the largest part of the body and consists, as in other insects, of the prothorax, the mesothorax and the metathorax. In the mosquito, the terga in these parts are called the *pronotum*, the *mesonotum* and the *metanotum*. The pronotum is very small and is scarcely visible. The mesonotum is very large, and gives rise to the wings. The metanotum which is situated behind is small and gives attachment to the halteres, which represent the metathoracic wings of other insects. There are two pairs of tracheal openings, the anterior being larger than the posterior ones, and are situated below the halteres.

*The Appendages of the Thorax* consist of three pairs of legs, a pair of wings, and a pair of halteres. The legs consist of a

short coxa, a trochanter, a long femur, a tibia and a tarsus with five joints, the last joint of which is bent. The legs are differently pigmented in different species.

The wings arise from the ventral side of the mesonotum; they, unlike the elytra of the cockroach, possess a flying function. The wings which in some species are spotted consist of scaly or feathery nervures that support a clear membrane between them. The border of the wing is called the *costa*. The veins or nervures are longitudinal; some of them are forked at their extremities. The longitudinal nervures are reinforced by transverse ones.

The halteres or balancers arise from the metanotum and are the vestiges (traces) of the second pair of wings found in the insects.

The abdomen is made up of eight segments, each segment having a tergum and a sternum joined at the sides by a pleural membrane, into which open a pair of stigmata for each segment.

Situated posteriorly on the last segment are the openings of the anus and the genitals between appendages called *gonapophyses*, which help in the laying of eggs.

*Dissection.* Kill the animal by means of chloroform, petrol or tobacco smoke and fixing it by passing needles through the thorax detach the wings and legs and with a camel hair brush remove the scales, then make two cuts with a fine knife on the sides of the abdomen and pull its ventral surface back with a needle. The white intestines and the Malpighian tubes will be clearly seen against a dark background. Take another mosquito and having killed it and taken out its wings and legs, lay it in a drop of saline on a glass slide. On pulling the head from the thorax carefully it will be found that a part of the œsophagus and the salivary glands have come out with the head.

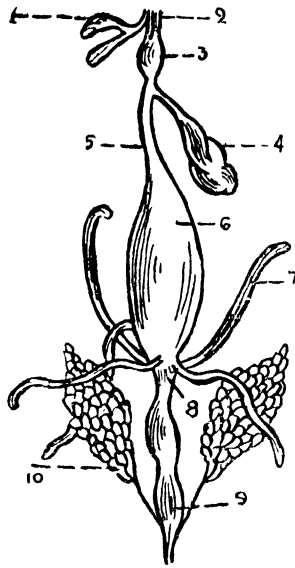


FIG. 22. DISSECTION OF MOSQUITO (magnified).

1. Salivary glands, 2. Pharynx, 3. Bulb, 4. Diverticulum, 5. Œsophagus, 6. Midgut, 7. Malpighian tubes, 8. Pylorus, 9. Rectum, 10. Ovary.

*The Digestive System.* The alimentary canal consists of the foregut, the midgut and the hindgut. The foregut forms the mouth, the pharynx and the œsophagus and is lined by the epiblast cells but the mouth and pharynx have only a chitinous covering. The midgut or the mesenteron forms the stomach while the hindgut or the proctodæum constitutes the intestine and the rectum.

The salivary glands lie three on each side in the anterior portion of the thorax. The ducts of the three glands unite into one, which with a similar duct of the opposite side forms a common duct that runs throughout the length of the hypopharynx and opens at its apex. In mosquitoes infected with malaria the sporozoites will be found in the salivary glands.

The œsophagus is a delicate tube from which three diverticula arise; these probably act as reservoirs of air for balloon-

ing the insect and thus make it lighter for flying about. The gizzard is absent in the mosquito, whose food is chiefly liquids. The œsophagus opens into a pyriform sac, called the proventriculus, which is the anterior portion of the midgut; the posterior portion joins the hindgut and the Malpighian tubes open at this junction. The hindgut opens externally on the last segment as the anus. The Malpighian tubes are five in number and excrete nitrogenous waste.

*The Circulatory System* is poorly developed and consists of a longitudinal dorsal vessel beneath the abdominal terga.

*The Respiratory System.* The respiratory system consists of a network of tracheæ lined with chitin and having their lumens open. The tracheæ serve a double purpose that of respiration and that of making the animal lighter for flight; The ramification of the tracheæ is so perfect that the destruction of any of the tracheæ does not in any way affect the respiration of the animal as its function is undertaken by the other tracheæ. Expiration is effected by the contraction of the transverse muscles which causes the air to be forced out. The inrush of air through the open mouths of the tracheæ when the muscles are relaxed constitutes inspiration.

*The Nervous System.* The nervous system consists of a dorsal supra-œsophageal ganglion connected to a sub-œsophageal ganglion by means of a para-œsophageal commissure on each side, and a series of paired ganglia which are connected with each other as in the case of the above ganglia and also with the sub-œsophageal ganglion and supply their respective segments; these ganglia give off branches to the sense organs, the alimentary canal and other organs. The three thoracic ganglia fuse into one large mass of nerve cells.

*The Reproductive System.* In the male the testes, a pair of dirty white bodies are situated in the last two segments; the *vas deferens* arises from the hinder portion of each testis and communicating with a seminal vesicle by means of a short

duct, unites with it to form an ejaculatory duct which opens in a fleshy penis on the last segment. The last segment projects backwards on each side of the penis and is called *gonapophysis*. The female has a pair of whitish elongated ovaries, which though small at first grow to a considerable size in a full grown mosquito. The ovary is made up of a number of follicular tubules that open into the *oviduct*. The oviducts on each side unite into a *common oviduct* and open below the rectum. The ducts of the three spermathecae in which spermatozoa are stored after copulation, and the duct of cement glands which secrete the cement substance for the eggs to stick together, open into the common oviduct before it opens externally. The gonapophyses project from the posterior part of the last segment and help in launching the egg-boats.

After copulation, which takes place whilst flying, the semen is stored in the spermathecae of the female and is utilized to fertilize the eggs as they come out. When the eggs come out they are held vertically by the *ovipositors* (gonapophysis) and are covered over by a cement substance which sets on exposure to air. In this manner hundreds of eggs are united in the form of a raft and launched on the surface of water.

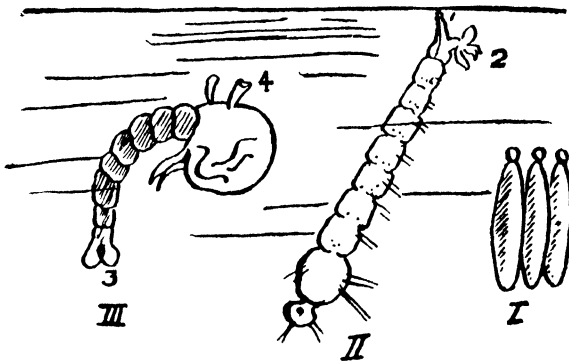


FIG. 23. CULEX (magnified).

I. Eggs. II. Larva. III. Pupa.

1. Syphon, 2. Anal papilla, 3. Tail fins, 4. Respiratory trumpets.

The eggs of the anopheles are boat shaped and are not united but possess certain kinds of floats, while those of the culex

are elongated and united into bundles without having any floats. The *Stegomyia* however do not have rafts for their eggs. The time taken for the eggs to be hatched is determined by the environment.

*The Larva* comes out of the egg, grows rapidly and casts its skin several times. The body of the larva consists of head, thorax and abdomen.

The head is large and round, having the epicranium on its dorsum, the compound eyes on each side and behind, and the antennæ in front. The clypeus is situated between the antennæ; a pair of feeding brushes are situated beneath the clypeus; the labrum is situated between the brushes and bears a tuft of short hairs. The brushes and the labrum are hinged on to the head. The mandibles and the maxillæ are strong and have teeth. The mouth is overlapped posteriorly by the labium, the anterior part of which is dentated and is called the mental plate.

The thorax is round, the three divisions of its terga and sterna are not clearly defined and there are no limbs.

*The Abdomen* is made up of nine segments. The upper seven segments have a pair of palmate hair which resemble the *tari* palm, the eighth segment has the openings of the trachea above, and the ninth segment has a set of stout hairs which project behind and act as a rudder. At the end of the ninth segment is the opening of the anus with a pair of papillæ on either side.

*The Alimentary Canal* of the larva consists of a buccal cavity an œsophagus near which lie the salivary glands; a midgut into which the four pairs of hepatic cæca, open. The midgut is followed by the hindgut. The Malpighian tubes are given off at the termination of the midgut into the hindgut in the sixth abdominal segment.

The dorsal vessel is visible in the living larva behind the gut as a longitudinal tube with bulgings at each segment.

The brain of the larva is very small, the thorax contains three separate ganglia and the abdomen eight.

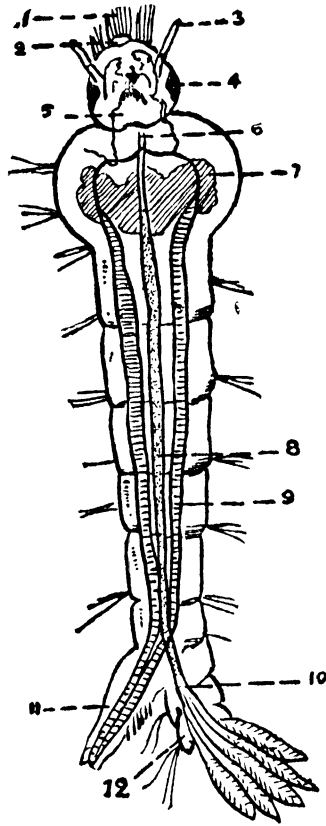


FIG. 24. LARVA OF MOSQUITO (magnified).

1. Feeding brush, 2. Labrum, 3. Antenna, 4. Eye, 5. Mental plate, 6. Oesophagus, 7. Hepatic caeca, 8. Midgut, 9. Trachea, 10. Hindgut, 11. Syphon, 12. Anal papilia.

Moulting of the outer cuticle and the inner tracheal lining takes place repeatedly.

*Habits of the Larva.* The larva of the anopheles lies in a horizontal position while that of the culex lies in a vertical position just near the surface of water with its bristles sticking out ; it can thus turn its head so that the mouth is uppermost

into which it sweeps in, with the aid of the brushes, small insects from the surface of water. If the larva is disturbed it changes its position on the surface or descends into the water by jerky movements.

*The Pupa* is a stage of rest and corresponds to the chrysalis stage of the butterflies, with this difference that the pupa of the mosquito is active. It has no mouth or anus but two respiratory trumpets communicating with the tracheæ one on each side of the head. The outer covering protects the body which undergoes a complete rearrangement ; the mouth which is a masticating apparatus becomes converted into a sucking proboscis. The legs, wings, halteres, anus and gonapophysis develop soon after.

The pupa is shaped like a comma with a large head, a thorax and a tail-like appendage ; this appendage represents the abdomen and is made up of nine segments.

The pupa remains with the respiratory trumpets sticking outside, just below the surface of water when undisturbed. The pupal stage lasts from one to five days, after which the outer covering splits from the prothorax and the imago (fully grown winged mosquito) comes out.

# Amphibia

Amphibia are a class of animals belonging to the sub-division *vertebrata*, or animals, which possess a backbone or vertebral column, which apart from its supporting function protects the alimentary canal.

Vertebrata are divided into six classes: *the primitive vertebrates (cyclostomata)*, *fishes (pisces)*, *amphibia*, *reptilia*, *birds (aves)* and *mammalia*,

The amphibia are at home both on land and in water. Many of them have no gill slits, while the fin rays are absent in all of them. The skin is soft and glandular, and serves as an accessory organ of respiration. The heart has three chambers, the auricles being divided into two. The vertebræ possess *zygapophyses*, a feature that distinguishes them from the fish.

The gut ends in a *cloaca* into which the ducts of the kidney and the reproductive organs open. The ova are pigmented. They are small and are laid in water. The amphibia are divided into the following four orders.

1. *Urodela* which retain their tails throughout life and have weak limbs.
2. *Anura* which have no tail in the adult life, (the frog belongs to this order).
- 3 *Gymnophiona* which are both without limbs and tails.
4. *Stegocephali* are tailed amphibians now extinct.

## FROG

*Rana tigrina*, the frog most commonly found in India is a fairly large sized animal. Ordinarily, it is three to six inches in length, but frogs as long as one foot have been seen. They






PLATE IV. FROG (*Rana tigrina*).

(The tympanic membrane is very conspicuous).

are found wherever there is stagnant fresh water, especially in the rainy season, but in the cold and hot weather they bury themselves in mud and remain there in an inactive condition of hibernation when all the functions of the body are reduced to a minimum. The frog swims in water and leaps about on land, being at home in these two places. It feeds on insects and other smaller animals which are flicked into the mouth by means of the sticky tongue.

*External Features.* The frog appears to have a curved spine when sitting, but the backbone is quite straight. The head merges into the body without the intervention of a neck, this condition being specially adapted for swimming. The adult frog has no tail, and its extremities resemble those of man with the exception that the hand has no thumb. The ankle is very long and the foot is clawed. The skin is richly coloured and may change in adaptation to the surroundings. It is glandular, moist and slippery and a great deal of respiration is carried on its surface. The eyes project out of the head instead of being beset in orbital cavities as in other animals; this compensates for the absence of the neck. The frog has no external ears but the tympanic membranes situated just behind the eyes are flush with the skin. The mouth is very wide extending practically from one ear to the other; the cheeks and lips are absent. The external nares are seen in their usual position and the anus and the urogenital opening are represented by the cloaca posteriorly.

*The frog is either chloroformed by placing it in a closed vessel that contains a chloroform swab, or is pithed by cutting through the junction of the skull and the first vertebra and introducing a probe into the skull to destroy the brain with a few side to side movements and then by passing the probe through the spinal canal to destroy the spinal cord. After preparing the frog by either means open the mouth wide and study the slender maxillary teeth on the roof of the mouth and the vomerine teeth which prevent insects from slipping out of the mouth. Then observe the*

*internal nares, the pair of Eustachian apertures near the angle of the mouth, the tongue, the glottis that leads from the lungs and lastly, the gullet.*

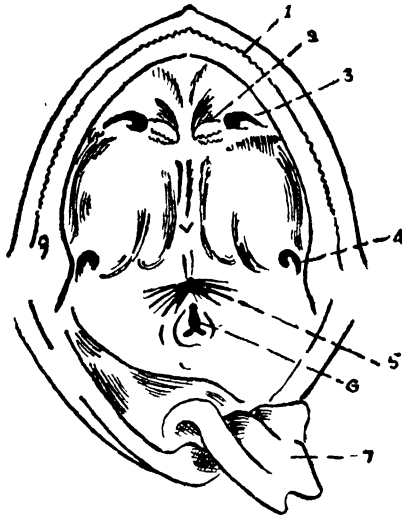


FIG. 25. FROG'S MOUTH LAID OPEN.

1. Maxillary teeth, 2. Vomerine teeth, 3. Internal nares, 4. Eustachian aperture, 5. Gullet, 6. Glottis, 7. Tongue.

The tongue, which is large and viscid, is attached to the floor of the mouth by its anterior end ; the posterior end of the tongue is free and can be flicked out instataneously on to small objects such as insects and worms. The salivary glands are absent and the internal nares open in the same situation as the external nares, there being no nasal cavity or palate.

*Dissection.* The frog should be laid on its back on a board and fixed by passing strong pins through its extended limbs. Pinch a portion of the skin with a pair of forceps and make a small nick with a pair of scissors in the middle line. Cut the whole length of the skin from the mouth to the cloaca extending the cut towards the extremities. The skin will be found to be quite loose owing to the subcutaneous lymph space which it covers,

*except at certain places where some of the muscles are inserted into the skin ; these muscles must be cut near the skin. Pin the skin flaps thus reflected and study the muscles of the abdomen, jaw, arm and thigh thus exposed. The muscles are*

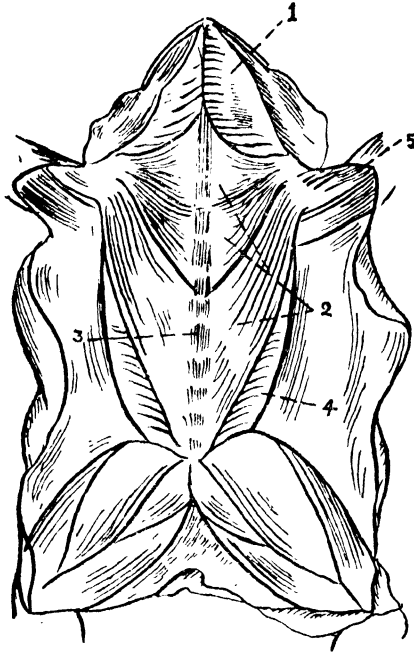


FIG. 26. MUSCLES OF FROG.

1. Mylohyoid, 2. Pectoralis, 3. Rectus abdominis, 4. External Oblique, 5. Deltoid.

(1) *The mylohyoid muscles under the jaw.*

(2) *The deltoid muscle of the arm.*

(3) *the pectorales muscles which arise partly from the sternum and partly from the outer side of the rectus muscle and are inserted into the humerus.*

(4) *The recti muscles on each side of the middle line of the linea alba ; these muscles are segmented.*

(5) *The external oblique muscles on the side of the recti, underneath the abdominal portion of the pectorales muscles.*

If the skin flaps have been carefully raised, the following veins will also be seen : the musculocutaneous vein underneath the pectoralis muscle, the abdominal vein between the recti muscles and the brachial vein of the arm accompanying the brachial nerve.

*Having examined these structures carefully and having made drawings of them, divide the abdominal wall slightly to the right of the middle line taking care to separate the abdominal vein. The muscles covering the clavicle and coracoid should then be removed and the bones cut. The xiphisternum is next raised and dissected out and the arms well stretched to give a better view of the cælom or the body cavity. This cavity is the pleuro-peritoneal cavity and is lined by the pleuro-peritoneal membrane. The abdomen and thorax are not separated by a diaphragm as in the case of mammals. (Frontispiece).*

*The Digestive System.* The mouth is continuous with the throat which narrows back into the œsophagus ; this is continuous with the stomach. The stomach is thrown into longitudinal folds in its interior, thus increasing the surface. Glands are found here secreting pepsin and hydrochloric acid. These secretions break down the proteins of the food into digestible peptones thereby enabling the small intestines to absorb them. The stomach is continuous with the small intestines, a sphincter being present at the junction of the two. This regulates the quantity of food which passes into the duodenum which is the first part of the small intestines, the second part being called the ileum. The duodenum receives the secretion of the liver and the pancreas. Bile, the secretion of the liver, is alkaline and emulsifies the fat of the food ; the pancreatic secretion is also alkaline and contains three ferments, trypsin which converts proteins into soluble peptones, amylase which changes starch into sugar, and lipase which breaks up fat into fatty acids and glycerine. These products are absorbed by the blood vessels, any indigestible or

undesirable material passes on into the large intestines, where a portion of water and salt is absorbed and the rest voided from the cloaca as fæces.

The liver is a large dark reddish organ consisting of a right and a left lobe. Under the liver will be found the small spherical dark green gall bladder ; the duct from the gall bladder after its union with the hepatic ducts passes on to the duodenum surrounded by a tubular gland, the pancreas, as the common bile duct, and receiving the duct of the pancreas opens into the duodenum.

The ileum is continuous with the large intestine without the intervention of a cæcum. The large intestine is short and ends into the cloaca into which the bladder opens in front and the urinary and genital ducts behind.

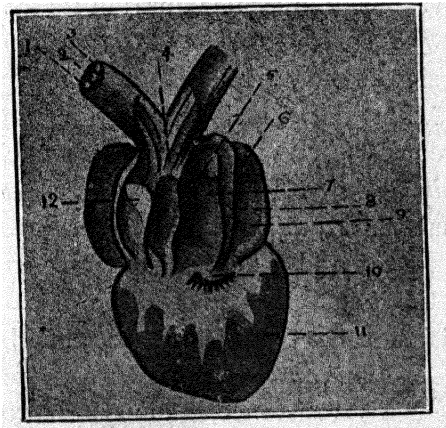


FIG 27. HEART OF FROG LAID OPEN.

1 Pulmocutaneous artery, 2. Systemic artery, 3. Carotid artery, 4. Truncus arteriosus, 5. Opening of the sinus venosus, 6. Opening of the pulmonary vein, 7. Right auricle, 8. Inter-auricular septum, 9. Left auricle, 10. Auriculo-ventricular valve, 11. Ventricle, 12. Longitudinal spiral valve.

*The Circulatory System.* The heart is invested by a thin pericardium which consists of a *visceral* layer in intimate contact with the heart, and a *parietal* layer which forms a loose sac with a little serous fluid to facilitate the movements of the heart ; the two layers are continuous with each other at

the root of the blood vessels of the heart. Movements of the heart can be seen even when cut out from a recently killed frog; the contraction begins at the *sinus venosus*, spreads thence like a wave to the auricles, ventricle and *truncus arteriosus*. The frog's heart consists of two auricles separated by an inter-auricular septum, and only one ventricle, the interior of which is rendered spongy by muscular strands.

The sinus venosus which collects venous blood from the venæ cavæ opens into the right auricle; arterial blood from the lungs enters through the pulmonary veins into the left auricle. The two auricles open into the ventricle by means of the auriculo-ventricular aperture; this is guarded by a valve which sticks into the ventricle; the valve possesses fine cords attached to its edges called the chordæ tendinæ. The ventricle contains spongy muscular fibres in its interior and thus does not allow of a ready mixture of the two currents of blood. On the right side of the ventricle, there is an opening guarded by a valve of three flaps, leading into the truncus arteriosus. The truncus consists of a *conus arteriosus* or *pylangium* proximally and a *bulbus arteriosus* or *synagnium* distally, and has a longitudinal spiral valve. The bulbus arteriosus soon divides into a right and a left trunk; each trunk is further divided into three compartments in its interior, marking the ultimate division of the truncus into three arches, the *pulmo-cutaneous*, the *systemic* and the *carotid*. The pulmo-cutaneous arch has the least resistance, while the carotid arch, on account of the carotid gland has the most.

The cardiac muscle consists of small spindle shaped fibres with distinct cross striations.

The nerves supplying the heart are the right and the left vago-sympathetic nerves, which enter the heart at the sinus, and join a collection of nerve cells at the sino-auricular junction which is known as *Remack's ganglion*; from this, nerve fibres pass to two ganglia at the auriculo-ventricular

junction, the *Bidder's* ganglia ; nerve fibres issue from these ganglia and terminate in the muscular fibres, but the apex of the heart is free from nerves.

In vertebrates there are usually two kinds of blood vessels that carry blood to and from the heart. The arteries convey blood from the heart to the different parts of the body. All arteries contain oxygenated blood except the pulmonary artery which carries de-oxygenated blood from the right ventricle to the lungs where it gets oxygenated. Arteries divide and branch off into smaller arteries, arterioles and capillaries which are distributed all over the body. The blood that they carry gets de-oxygenated in the tissues and is sent back to the heart from the various parts of the body through venous capillaries, small veins, veins and the vena cava or the caval veins. The pulmonary veins on the other hand convey pure oxygenated blood from the lungs to the right auricle.

Circulation is controlled by the rhythmic contraction of the heart. Contraction starts from the sinus venosus and spreads as a wave to the auricles, ventricles and the truncus arteriosus. The right auricle contracts and sends its venous blood into the right side of the ventricle simultaneously with the left auricle which by its contraction sends its arterial blood into the left side of the ventricle. The ventricle then contracts and sends its blood into the truncus arteriosus ; the first quantity of blood pumped out, is the venous blood from the right ventricle, and this finds its way into the least resisting pulmocutaneous arch. As soon as the arch is full the longitudinal spiral valve prevents any further influx of blood in this direction. The next quantity of mixed blood gets into the systemic arch, and when, this is also full, the last quantity of blood, which is oxygenated passes into the carotid arch. It will be seen from the above arrangement that venous blood passes through the pulmocutaneous arch to the lungs and the skin, where it takes in oxygen and gives out carbon dioxide, it is then returned *via* the pulmonary

veins to the left auricle. Mixed blood passes through the systemic arch to the trunk and the extremities, while the last oxygenated portion of blood goes to supply the most important part of the body, the brain.

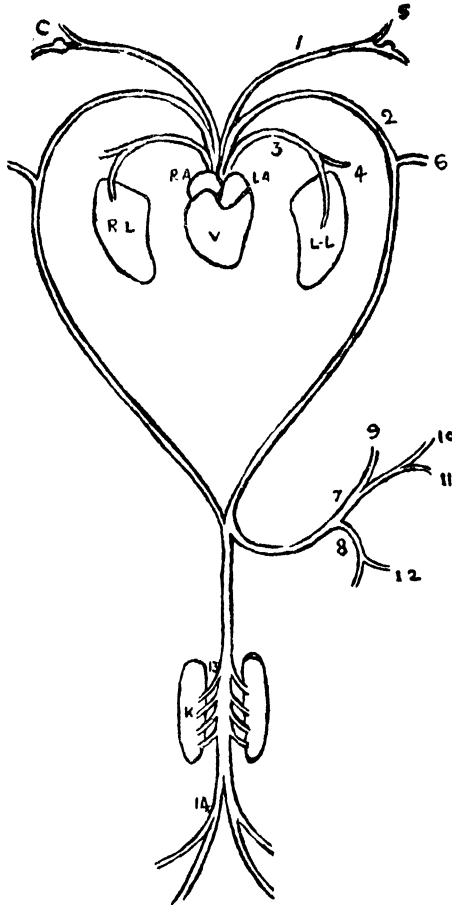


FIG. 23. ARTERIES OF FROG.

R. A. Right Auricle. L. A. Left Auricle. V. Ventricle. R. L. Right Lung. L. L. Left Lung. C. Carotid Gland. K. Kidney.

1. Carotid arch, 2. Systemic arch, 3. Pulmocutaneous arch, 4. Cutaneous, 5. Lingual, 6. Subelavian, 7. Cœliac, 8. Mesenteric, 9. Hepatic, 10. Gastric, 11. Pancreatic, 12. Splenic, 13. Renal, 14. Iliac.

*The Arteries.* The truncus arteriosus divides into a right and a left trunk, each trunk dividing again into three arches,

the anterior carotid arch, the middle systemic arch and the posterior pulmocutaneous arch.

The carotid arch gives off a lingual artery just in front of the carotid gland. The pulmocutaneous arch divides into the pulmonary artery which runs along the outer surface of the lung, and the cutaneous artery, which, passing through the back muscles supplies a large portion of the skin on the back. The systemic trunk gives off a subelavian artery to supply the shoulder and forelimb, the occipio-vertebral artery to supply a part of the head and vertebral column, and joining with the systemic arch of the opposite side forms the dorsal aorta. Soon after the formation of the dorsal aorta it gives off the cœliaco-mesenteric artery which divides into the cœliac and the mesenteric branches. The cœliac artery breaks up into the hepatic, to supply the liver, the gastric, to supply the stomach and the pancreatic arteries, to supply the pancreas. The mesenteric artery supplies the duodenum, the ileum and the large intestine and sends a splenic branch to the spleen. The lower part of the large intestine is supplied by the posterior mesenteric which is given off by the dorsal aorta. The dorsal aorta in its passage downwards between the kidneys gives off an artery on each side to the gonads and renal arteries to the kidneys. The dorsal aorta ends by dividing into the two iliac arteries each of which gives off a hypogastric artery to the bladder and continues into the leg as the sciatic artery which divides above the knee into the peroneal and the tibial arteries supplying the leg and the foot.

*The Veins* consist of the systemic veins and the hepatic portal, the renal portal and the pulmonary systems.

The Systemic Veins consist of three *caval* veins, the *right precaval*, the *left precaval* and the *postcaval*; these unite into the sinus venosus. Each precaval vein is formed of the external jugular, secondly the innominate which is the result of the union of the internal jugular and the subscapular and

thirdly the subclavian which is formed by the brachial and cutaneous veins. The postcaval receives the hepatic, the genital and the renal veins on each side ; the veins of the lower extremities do not pass directly into the postcaval vein.

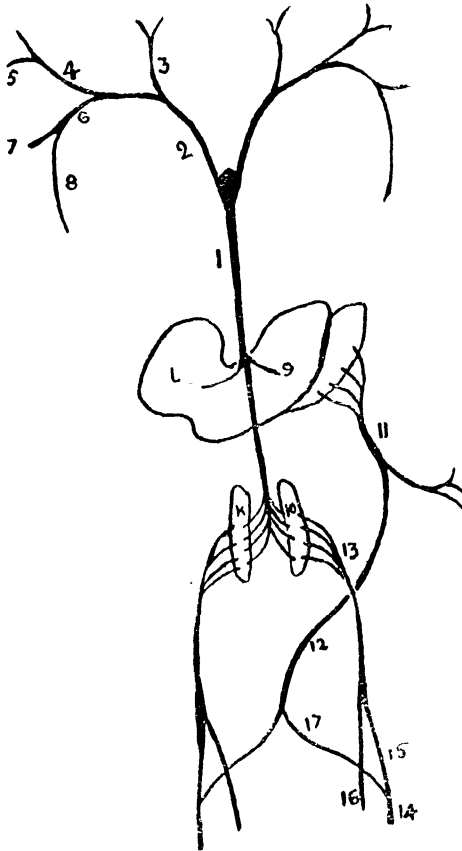


FIG. 29. VEINS OF FROG.

1. Postcaval, 2. Precaval, 3. External jugular, 4. Internal jugular, 5. Subscapular, 6. Subclavian, 7. Brachial, 8. Cutaneous, 9. Hepatic, 10. Renal, 11. Hepatic portal, 12. Abdominal, 13. Renal portal, 14. Femoral, 15. Femoro-renal, 16. Sciatic, 17. Pelvic.

The hepatic vein is formed of the gastric vein from the stomach, the spleno-mesenteric vein from the spleen and intestines, and the anterior abdominal vein. The anterior abdominal vein is formed by the two pelvic veins each of

which is one of the two terminal branches of the femoral vein, the other terminal branch being the femoro-renal vein.

The renal portal vein is the continuation of the femoro-renal vein. It receives the sciatic and the dorso-lumbar veins, and passing to the outer border of the kidney, gives a series of branches to the kidney tubules. The glomeruli of the kidney are supplied by the renal artery. Blood from the lower limb therefore does not proceed directly to the heart but passes by the pelvic and abdominal veins through the liver or by the femoro-renal and renal portal veins through the kidney.

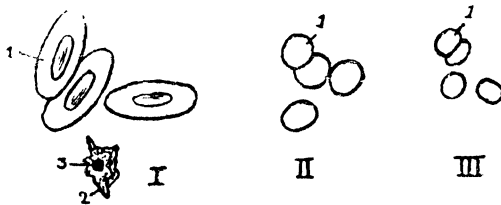


FIG. 30. BLOOD CORPUSCLES (Magnified).

Blood of I Frog, II Rabbit, III Man.

1. Red blood corpuscle, 2. White blood corpuscle, 3. Nucleus.

The blood of the frog consists of a colourless plasma in which white and red corpuscles float. The white corpuscles are colourless, and are few in number; they are nucleated and exhibit amoeboid movements. The red corpuscles are much larger in size than the human red corpuscles; they have an oval shape and large nuclei, and are coloured red on account of the colouring matter, hæmoglobin, which is the pigment concerned in absorbing oxygen. Nourishment however passes on to the tissues by means of the blood plasma, and the excretory products of the tissues pass into the plasma to be got rid of by the kidneys and the lungs.

*The Lymphatic System* of the frog consists of sinuses. A large subvertebral sinus exists between the dorsal part of the peritoneum and the vertebral column. Other subcutaneous

lymph sinuses are situated underneath the skin causing the loose condition of the skin. It is obvious that the lymph flow is very much retarded owing to the large surface it has to traverse and so two pairs of lymph hearts are provided ; one of them is situated anteriorly between the third and the fourth vertebræ and pumps the lymph into the subscapular vein, and the other lies posteriorly on each side of the urostyle and forces its lymph into the femoral veins. Lymph is an exudate of plasma from the capillaries ; it carries nourishment to the tissues and through it the waste material is excreted.

*The Respiratory System.* The glottis opens into the *laryngo-tracheal* chamber situated in front of the throat ; this chamber opens directly into the lungs without the intervention of the trachea as the frog has no neck. The lungs are not solid as in the mammals but consist of a pair of sacs on each side, with a mesh of arterial network on their surfaces. Exchange of gases takes place through the thin walls of these sacs ; oxygen is taken in by the hæmoglobin, and carbon dioxide is given out.

The mechanism of respiration consists of alternate depression and elevation of the floor of the mouth which constitute inspiration, and the elastic recoil of the lungs which constitutes expiration. In inspiration the sternohyoid muscle which is attached to the hyoid cartilage in the floor of the mouth, and the sternum, contracts, causing an increased capacity in the mouth cavity into which air rushes through the open nares. Soon after the inrush of air the nares close, the glottis opens, and elevation of the floor of the mouth by means of contraction of the petrohyoid muscle which is attached to the hyoid and the petrous of the skull, causes the air in the mouth to be forced into the lungs. Expiration is carried out by the elastic recoil of the lungs driving the air through the open glottis and the nares.

Apart from the ordinary respiration by the lungs the skin of the frog is an important surface for respiration. The

cutaneous branch of the pulmocutaneous artery sends a fairly big quantity of venous blood to the skin to be oxygenated and this blood is returned by the cutaneous vein to be mixed up with the venous blood of the body.

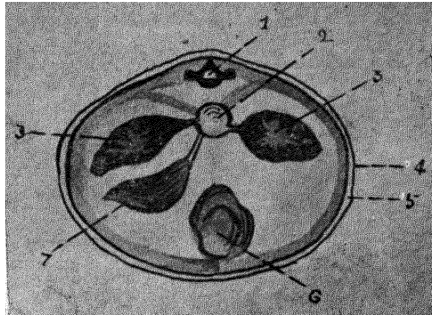


FIG. 31. TRANSVERSE SECTION THROUGH THE ANTERIOR PART OF A SMALL FEMALE FROG.

1. Vertebra, 2. Œsophagus, 3. Lungs, 4. Skin, 5. Subcutaneous lymph space, 6. Pericardium and heart, 7. Liver.

*To study the transverse section of the frog, it should be either frozen in ice or hardened for a few days in a weak solution of formalin. Sections should then be made in the anterior region passing through the lungs and the heart, and through the posterior region passing through the kidneys.*

In both these sections the skin and the subcutaneous lymph space will be clearly visible. In the anterior section, the vertebra containing the spinal cord and surrounded by muscles is situated dorsally and the pleuro-peritoneal cavity containing the lungs, the heart, the oesophagus and the liver is situated ventrally. In the posterior section will be found the urostyle, the kidneys the blood vessels, the gonads and the alimentary canal.

*The Skeletal System.* The bones of the frog consist of the vertebral column, the skull, the mandible and the hyoid, the pectoral and pelvic girdles, and the limbs; this constitutes the endoskeleton. A frog, unlike the cockroach and the palinurus does not possess an exoskeleton.

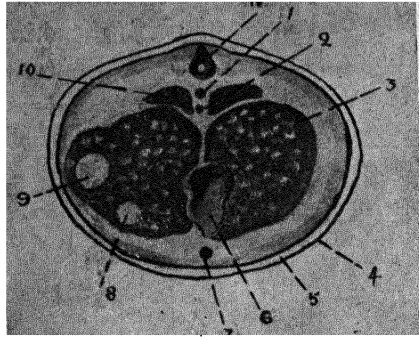


FIG. 32. TRANSVERSE SECTION THROUGH THE POSTERIOR PART OF A SMALL FEMALE FROG.

1. Dorsal aorta, 2. Postcaval vein, 3. Ovary, 4. Skin, 5. Subcutaneous lymph space, 6. Large intestine, 7. Abdominal aorta, 8. Duodenum, 9. Stomach, 10. Kidney, 11. Urostyle.

The vertebral column consists of nine vertebræ and an unsegmented *urostyle*.

A vertebra consists of a body or centrum, a neural arch, anterior and posterior articular processes or *zygapophyses*, two transverse processes and a spinous process. The anterior surface of the centrum is concave, the posterior convex; the convexity of the centrum in front fits into the concavity of the centrum behind; such a centrum is called *procelous*. The neural arch is a bony ring surrounding the spinal cord. The anterior and posterior borders of the arch possess two small facets for articulation; the transverse processes arise from each side of the base of the arch. The first vertebra or atlas has an ill-defined centrum and has no anterior articular facets, nor the transverse processes. Anteriorly, it articulates with the occipital bone by two facets, posteriorly it articulates with the second vertebra which is not called an axis as in the higher animals, on account of the absence of rotation of the head in the frog.

The eighth vertebra is of the *amphicæulous* type, its centrum being concave at both the ends. The ninth vertebra has the concavity either in front or behind, posteriorly it articulates

with the urostyle, and presents two facets for articulation with the pelvic girdle. The urostyle is a rod of bone formed by the fusion of several vertebræ, and it articulates with the ninth vertebra by means of two facets. The neural canal continues only for a short distance in the urostyle.

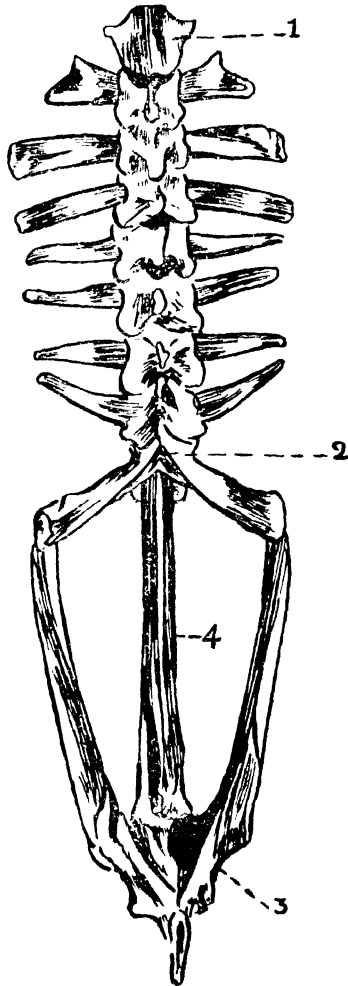


FIG. 33. VERTEBRAL COLUMN AND PELVIC GIRDL E OF FROG.  
1. Atlas, 2. Sacral vertebra, 3. Acetabulum, 4. Urostyle.

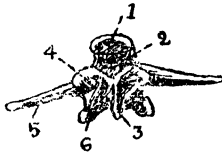


FIG. 34. FOURTH VERTEBRA OF FROG. (back view).

1. Centrum, 2. Neural canal, 3. Spinous process, 4. Anterior articular process (zygapophysis), 5. Transverse process, 6. Posterior articular process.

Bones are formed either by an inlay of cartilage or directly in a membrane. In the former case it is *cartilage bone* and in the latter it is called *membrane bone*. Both these varieties are found in the skull. A long bone is usually a cartilage bone and has a primary centre from which ossification starts; this is known as the *diaphysis*, a separate centre may also develop called the *epiphysis* and this unites later on.

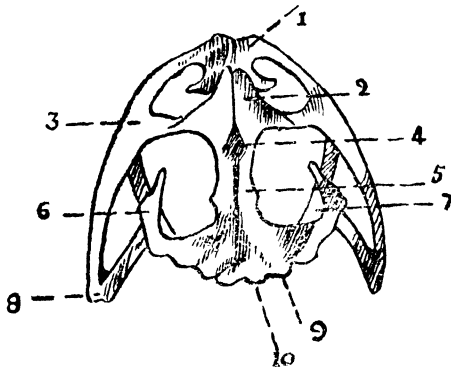


FIG. 35. SKULL OF FROG.

1. Premaxilla, 2. Nasal, 3. Maxilla, 4. Spheno-ethmoid, 5. Fronto-parietal, 6. Squamosal, 7. Pterygoid, 8. Quadro-jugal, 9. Ex-occipital, 10. Occipital condyle.

The skull consists of a bony cage enclosing the brain; it is developed in the first place from a cartilaginous tube, the *chondro-cranium*, a part of which remains cartilaginous, and a part ossifies to form cartilage bones; secondly by the investment of membrane bones and thirdly by associated visceral arches. The anterior half of the cartilaginous tube ossifies to form the *spheno-ethmoidal*; the posterior part is ossified on

each side and forms the *ex-occipital* with its condyles, leaving the foramen magnum. A cartilage bone covers the auditory capsule and is called the *pro-otic*. A large gap, the *fontanelle*, is found on the roof of the chondrocranium. The membrane bones consist of the fronto-parietal dorsally, the nasal ventrally, the premaxilla and maxilla which bears the teeth, in front, the squamosa laterally, a *quadrato-jugal* at the angle of articulation with the jaw, a pair of vomerine with teeth on the ventral aspect, a pair of palatines, a pair of pterygoids and a median *parasphenoid*.

The upper jaw develops from a rod of cartilage which unites anteriorly; the anterior portion of the rod is called the *palatopterygoid* cartilage and the posterior portion is called the quadrate cartilage and connects the lower jaw with the skull.

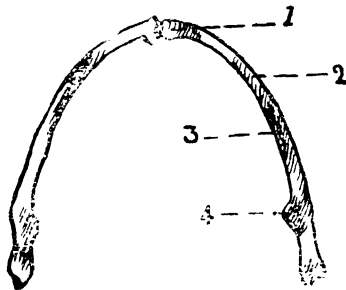


FIG. 36. MANDIBLE OF FROG.

1. Mento-meckelian, 2. Dentary, 3. Angulo-splénial, 4. Coronary process.

The lower jaw or mandible is formed from the first or mandibular arch formed of two cartilaginous rods, the Meckel's cartilage; anteriorly the rods become ossified and are called the *mentomeckelian*; laterally, two membrane bones invest themselves, the anterior and outer one is called the *dentary* while the posterior and inner one is called the *angulo-splénial*; behind the angulo-splénial is an elevation, the coronary process, while the posterior extremity articulates with the quadrate cartilage.

The second or the hyoid arch forms the greater part of the hyoid apparatus; the hyoid cartilage becomes attached to

the otic capsule. A part of it together with the remains of the first, third and fourth branchial arches is called the hyoid apparatus; this consists of a body which is a thin plate readily felt in the floor of the mouth, a pair of anterior cornua attached to the otic capsule above, a pair of posterior cornua projecting backwards from the body, and the *columella*, a delicate rod attached to the inner surface of the tympanic membrane and to the fenestra ovalis of the internal ear.

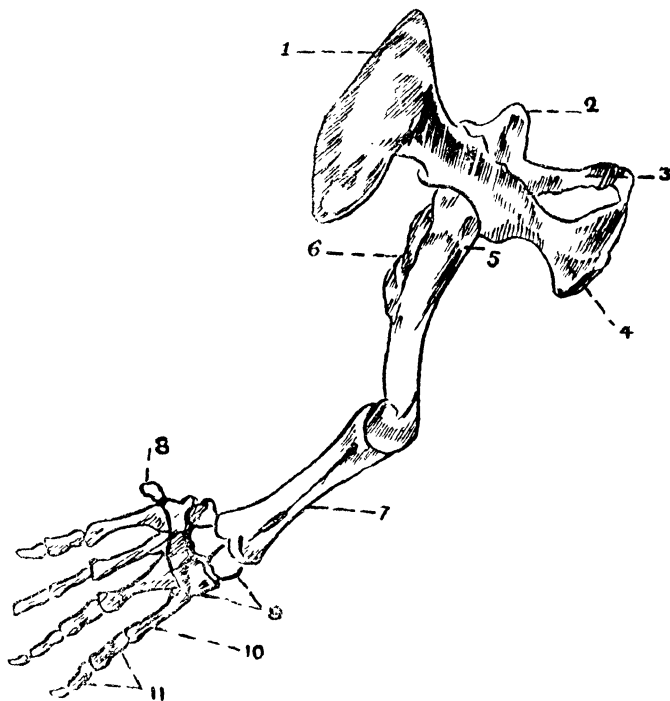


FIG. 37. BONES OF THE UPPER EXTREMITY OF FROG.

1. Suprascapula, 2. Scapula, 3. Clavicle, 4. Coracoid, 5. Humerus, 6. Deltoid ridge, 7. Radio-ulna, 8. Rudimentary metacarpal of the thumb, 9. Carpal, 10. Metacarpal, 11. Phalanges.

The shoulder girdles with the aid of the upper vertebræ form a protection for the heart and the lungs, provide a strong basis for the fore-limb, and serve for the attachment of various muscles. The dorsal portion of the shoulder girdle is formed of the bony scapula and the cartilaginous suprascapula. The ventral portion consists of a coracoid and a precoracoid to

which the clavicle articulates ; the interval between the coracoid and the precoracoid gives exit to a nerve of the brachial plexus. The coracoids and precoracoids do not meet in the middle line but are joined together by means of a cartilage the *epicoracoid*. A big articular cavity, the *glenoid cavity*, is situated at the junction of the scapula and the coracoid ; to this cavity the humerus articulates. Behind the epicoracoids is a symphysis called the sternum, which consists of a cartilaginous anterior portion the *episternum*, a cartilaginous *omosternum*, a partly cartilaginous and partly bony *mesosternum* and a cartilaginous *xiphisternum*. It is doubtful whether this is a real sternum as of the mammals as the ribs are absent. The arm bone consists of a humerus which is short and thick, articulating with the glenoid cavity, and having a strong deltoid ridge but no olecreon fossa. The bone of the forearm consists of a fused radio-ulna, a distal groove marking out the fusion ; a concave articular and an olecreon fossa may be seen proximally. The wrist consists of two rows of bones containing three carpal bones in each ; the proximal carpal bones articulate with the radio-ulna and the distal with the metacarpus. The hand has four metacarpal bones with a small metacarpal for the thumb. The phalanges are ten in number, there being no phalanx for the thumb ; there are two for the first finger, two for the second, three for the third and three for the fourth. These numbers are indicated in a formula, the digital formula, which in the case of a frog's hand is 02233.

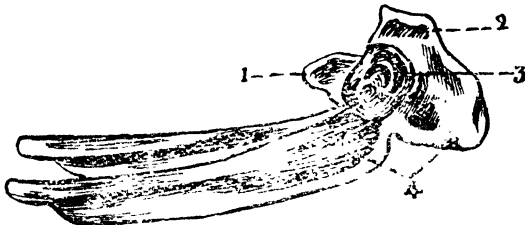


FIG. 38. PELVIC GIRDLE OF FROG.

1. Pubis, 2. Ischium, 3. Acetabulum, 4. Ilium,

The pelvic girdle is highly specialized in adaptation to the frog's leaping habits : it consists in the first place of a pair of long ilia running parallel to one another, their posterior ends meeting in a symphysis, secondly of a pair of small ischia which also meet in the middle line, and thirdly of the cartilaginous pubes which lie in the middle line ; all these three structures partake in the formation of a cavity, the acetabulum to which articulates the femur. The hind limb is

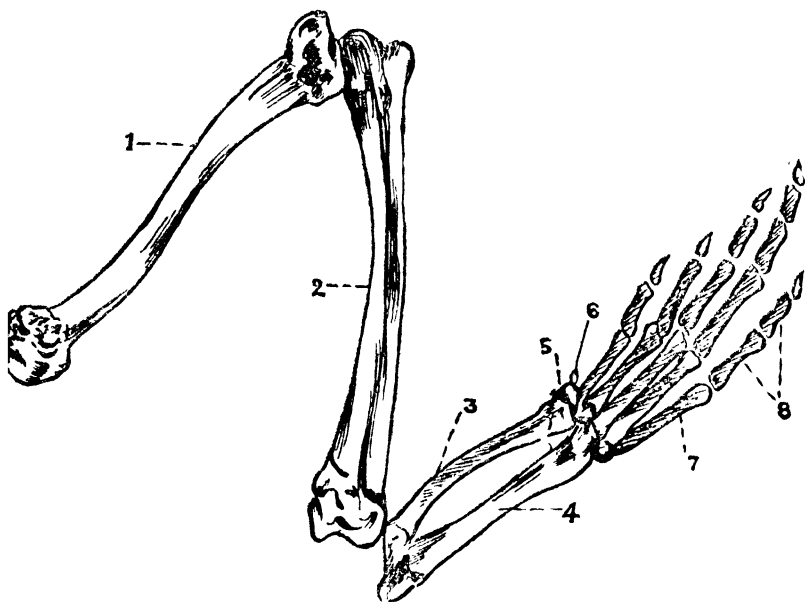


FIG. 39. BONES OF THE LOWER EXTREMITY OF FROG.

1. Femur, 2. Tibio-fibula, 3. Astragalus, 4. Calcaneum, 5. Tarsus, 6. Calcar, 7. Metatarsus, 8. Phalanges.

formed of the femur which is a long bone with a doubly, curved shaft, a head for articulation with the acetabular cavity and a broad lower extremity for articulation with the tibio-fibula. The tibio-fibula in the frog is a single bone, its double nature is detected by means of a groove in the upper and lower ends of the bone, the upper extremity is stout, the lower extremity articulates with the astragalo-calcaneum,

a bone which constitutes the first row of the tarsus ; the second row consists of two tarsal bones ; these articulate with five metatarsal bones ; a small bone, the calcar, is situated on the inner side of the halux (big toe) and is supposed to be the remnant of the sixth toe. The phalanges consist of fourteen bones and the digital formula is 22343.

*The Muscular System.* Muscles are made up of striated fusiform cells and constitute the flesh of the animal which by its contraction brings about and regulates the movements of the body as a whole and of its various parts. A muscle has three parts, a central fleshy belly and two extremities one or both of which may be tendinous. One of the attachments is usually fixed to a bone while the other is attached to an object which has to be moved and which may either be a bone, a cartilage or a sheath of fibrous tissue called aponeurosis. The first attachment is known as the *origin* of the muscle and the second as its *insertion*. Muscles are of two kinds : *voluntary* when they work by the exercise of the will, such as the muscles of the leg, and *involuntary* when the muscles are not under the direct control of the will, such as the heart muscle.

Some of the voluntary muscles of the abdomen and the upper extremity have already been mentioned and described in the foregoing dissection. The following are the more important muscles of the thigh and the leg.

*Cut the skin over the thigh and leg down to the foot and remove it completely. Place the limb with the dorsal surface uppermost, define the thick semimembranosus muscle on the inner side of the thigh and the vastus lateralis on the outer side. The biceps muscle lies under cover of the two. Separate the biceps and the semimembranosus and find the sciatic nerve with its accompanying vessels ; define the branches distributed to the various muscles. Having studied all the dorsal muscles of the limb, define and study the ventral muscles.*

*Muscles of the dorsal surface of the thigh.*

1. *The triceps extensor cruris* is an extensive muscle that is formed by the rectus femoris anterior, the vastus lateralis and the vastus medialis. The origin of these muscles will be mentioned when considering the muscles separately. The combined muscle is inserted into the upper portion of the tibio-fibula.
2. *The rectus femoris anterior* is situated on the outer dorsal surface, it arises from the ilium and covers the vastus medialis. This muscle forms the middle division of the triceps.
3. *The vastus lateralis* is situated in the middle of the thigh, arises from the ilium and forms the dorsal division of the triceps.
4. *The semi-membranosus* is a thick muscle on the inner side and arises from the ischium. It is inserted into the upper part of the tibio-fibula.
5. *The biceps* that lies under the vastus lateralis and the semimembranosus muscle, arises from the ilium and is inserted into the distal end of the femur and the head of the tibia.

*Muscles on the ventral aspect of the thigh.*

1. *The sartorius* is a flat muscle which arises from the ilium and is inserted into the inner side of the tibia.
2. *The vastus medialis* that lies partly under the sartorius, arises from the anterior border of the acetabulum and forms the ventral division of the triceps.
3. *The rectus*, which is partly covered by the sartorius arises from the ischium and is inserted into the head of the tibia.

4. *The adductor magnus* is a large muscle which arises from the pubis and ischium and is inserted into the distal third of the femur where it is partly covered over by the sartorius and the rectus muscles.

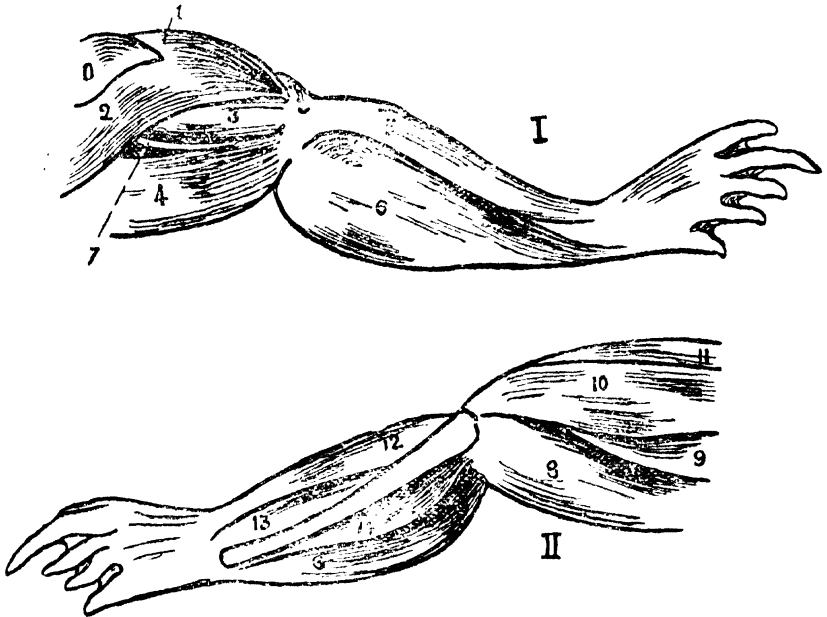


FIG. 40. MUSCLES OF THE RIGHT LOWER LIMB OF THE FROG.

I. Dorsal Aspect. II. Ventral Aspect.

O. Gluteus, 1. Rectus femoris, 2. Vastus lateralis, 3. Biceps, 4. Semi-membranosus, 5. Peroneus, 6. Gastrocnemius, 7. Sciatic nerve, 8. Rectus medialis, 9. Adductor magnus, 10. Sartorius, 11. Vastus medialis, 12. Tibialis anterior, 13. Extensor cruris, 14. Tibialis posterior.

### *Muscles of the leg.*

- 1 *The gastrocnemius* which forms the calf arises from the lower and back part of the femur and ends in the lower portion of the leg into a long slender tendon called the *tendo achillis*. This passes into the sole of the foot and ends into the strong plantar fascia.

2. *The tibialis posterior* lying under cover of the gastrocnemius arises from the posterior aspect of the tibio-fibula and is inserted into the astragalo-calcaneum.
3. *The tibialis anterior* lies on the outer and ventral aspect of the leg and arises from the lower end of the femur getting inserted into the astragalo-calcaneum.
4. *The extensor cruris* lies under the tibialis anterior and arises from the lower condyle of the femur ; it is inserted into the tibio-fibula.
5. *The peroneus* lies on the outer aspect of the leg with the tibialis anterior ventrally and the gastrocnemius dorsally. It arises from the femur and is inserted into the tibia and calcaneum.

*The Nervous System.* The nervous system consists of a central, a peripheral and a sympathetic nervous system. The central nervous system comprises the brain and the spinal cord. The peripheral nervous system consists of the nerves which are distributed to the muscles (motor nerves), to the skin (sensory nerves), and to the other tissues. The sympathetic nervous system is distinct, supplies various viscera, and communicates with the central nervous system.

*Place the frog on its abdomen and divide the skin over its head in the middle line, cut through the junction of the skull and the atlas, if this has not been already done for pithing the frog ; introduce a pair of bone pliers through the opening in the skull and cut the bone on each side of the middle line, remove the plate of bone and cut away all projecting pieces of bone, expose the brain fully and study its dorsal surface ; next sever all connections and the cranial nerves near the skull and remove the brain, (the brain may be hardened in formalin solution for a better examination); examine the ventral surface of the brain. The spinal cord should then be exposed. Cut through the neural arches and trace the nerves to and from the cord.*

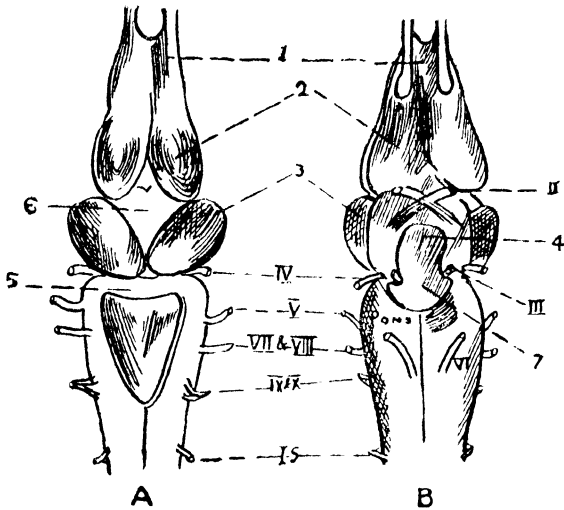


FIG. 41. BRAIN OF FROG. (Enlarged).

A. Dorsal view. B. Ventral view.

1. Olfactory lobe, 2. Cerebral hemisphere, 3. Optic lobe, 4. Infundibulum, 5. Cerebellum, 6. Thalamencephalon, 7. Pituitary, I.S. 1st spinal nerve, I to X cranial nerves.

The brain of the frog is covered with a pigmented layer of pia mater and consists of five parts—

1. The cerebral hemispheres which are elongated and have the olfactory lobes in front are connected together by the anterior and the posterior commissures. Each hemisphere encloses a cavity, the *lateral ventricle*, which communicates with another cavity, the *third ventricle*, by means of the *interventricular foramen*.
2. The *thalamencephalon* that encloses the *third ventricle* is covered over by the *anterior choroid plexus* and gives attachment to a small structure, the *pineal body* above, and the *pituitary body* below, which is attached to a prolongation, the *infundibulum*.
3. The *optic lobes* are a pair of oval bodies each of which forms the lateral boundary of the *third ventricle*.

4. *The Medulla oblongata* contains the fourth ventricle and is covered over by the posterior choroid plexus. It communicates with the third ventricle by a passage called the *iter* anteriorly, and is continuous with the central canal of the spinal cord behind.
5. *The cerebellum* is a narrow band that runs transversely above the fourth ventricle and controls the co-ordination of the body. The frog having a stable equilibrium does not require an elaborate or well developed cerebellum as the rabbit or man does.

The cranial nerves are ten pairs of nerves which emerge from the cranium at various levels. They are named according to their position and function they have to perform and are as follows.

The first or the *olfactory* nerve is a sensory nerve from the nose to the olfactory lobe and conveys the sensation of smell.

The second or the *optic nerve* is a sensory nerve from the eye to the brain and conveys the sensation of sight. Half of this nerve crosses over to the opposite side.

The third or the *oculomotor nerve* is a motor nerve which supplies four muscles of the eye-ball *e.g.* the superior rectus, the internal rectus, the inferior rectus and the inferior oblique muscles.

The fourth or the *pathetic nerve* is a motor nerve and supplies the superior oblique muscle of the eye.

The fifth or the *trigeminal nerve* is a mixed nerve containing both motor and sensory fibres to the jaws and face respectively ; it divides into three branches, the ophthalmic, the maxillary and the mandibular.

The sixth or the *abducens nerve* is a motor nerve that supplies the external rectus muscle of the eye.

The seventh or the *facial nerve* is a motor nerve supplying the face muscles and communicates with the fifth nerve.

The eighth or the *auditory* which arises in company with the seventh, is a sensory nerve and carries sensations of hearing and position from the ear.

The ninth or the *glossopharyngeal* is a mixed nerve which supplies the tongue and pharynx and communicates with the tenth nerve.

The tenth or the *vagus* is a motor nerve and supplies the heart, the lungs and the stomach.

The spinal cord is a tubular continuation of the brain and gives off ten pairs of nerves which emerge from the posterior part of the corresponding vertebra. The first pair of spinal nerves in the frog corresponds to the hypoglossal nerve of the higher animals and is distributed to the muscles of the tongue. The spinal cord thickens in the region of the second and third nerves forming the brachial plexus which supplies the upper limb, and in the region of the seventh, eighth and ninth nerves which unite to form the lumbosacral plexus, from which arises the great sciatic nerve to supply the lower limb. The fourth, fifth and sixth nerves supply the segments of the body situated below the upper limb, and the tenth spinal nerve supplies the cloaca as well.

*The Sympathetic System* consists of ten pairs of ganglia situated in the form of a chain on each side of the vertebral column. It communicates with the fifth nerve, the vagus and the spinal nerves and gives off branches to the blood vessels, heart, lungs and other viscera.

*Development of the Nervous System.* At an early period of embryonic life a groove appears in the epiblast in the dorsal region of the embryo. This groove becomes deeper and its sides rise up in the form of ridges called the *neural folds*. The groove soon gets converted into the neural tube and the epiblastic cells which constitute this tube become nerve cells, which soon develop many processes. One of these processes becomes elongated and is called the *axon*, the other smaller

processes being known as *dendrons*. The axon serves as the conductor of impulses and sometimes terminates in specialized nerve endings which convey various sensations. The dendrons form a medium for the transmission of impulses from one cell to another. A nerve cell with all its processes is known as a *neuron*.

The neural tube gives off nerves which supply the corresponding segments and forms the central nervous system; the nerves that are given off constitute the peripheral nervous system. The cephalic end of this neural tube expands and forms the brain while the remaining portion forms the spinal cord. The lumen of the tube becomes the cavities of the brain in the expanded cephalic region and is retained as the central canal of the spinal cord in the hinder region. The expanded cephalic portion of the neural tube is defined into three portions which are known as the anterior, the middle and the posterior cerebral vesicle, and which constitutes the forebrain, the midbrain and the hindbrain respectively. As development proceeds the cerebral hemispheres develop in the anterolateral region on each side of the forebrain. Each of these hemispheres encloses a cavity called the lateral ventricle which communicates with the original cavity of the forebrain. The forebrain expands and becomes the third ventricle, on each side of which develops a rounded mass of nerve tissue called the optic lobe. The midbrain does not develop to such an extent, and its cavity which is called the *isthmus* serves as a passage between the third ventricle in front and the fourth ventricle which is the cavity of the hindbrain behind.

Some epiblast cells get detached from both sides of the neural tube and form the sympathetic ganglia. These are linked with the central and peripheral nervous systems and supply the blood vessels, the alimentary canal and the involuntary muscles.

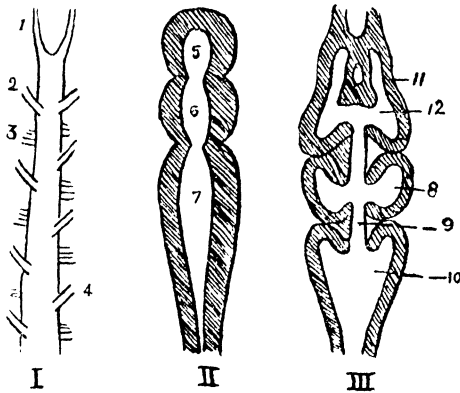


FIG. 42. BRAIN OF I. AMPHIOXUS, II. FISH, AND III. FROG.

1. First cranial nerve, 2. Second cranial nerve, 3. Ventral nerve, 4. Dorsal nerve, 5. Anterior cerebral vesicle, 6. Middle cerebral vesicle, 7. Posterior cerebral vesicle, 8. Third ventricle, 9. Ister, 10. Fourth ventricle, 11. Cerebral hemisphere, 12. Lateral ventricle.

*Morphology.* In the amphioxus the central nervous system remains as a simple tube with nerves emerging from various levels. In the fish this tube is expanded in its cephalic region into the three cerebral vesicles, while in the frog the hemisphere and the optic lobes are developed and the lateral ventricles are also formed, the cerebellum being only rudimentary. In pigeons, the cerebellum is well developed and the semicircular canals are very large. In rabbits we find a more complicated formation, and as we ascend the scale of animal life the extent of the brain surface gets larger not only by brain matter but also by the addition of fissures and sulci.

*Sense Organs.* As in the higher animals the frog possesses five sense organs, those of sight, smell, hearing, taste and touch. The nerve cells concerned with these senses are modified to receive the particular sensation and to transmit it to the brain.

The eyes project on the top of the head instead of being set in bony cavities. They are protected by the eyelids. The eyeball moves in all directions by means of six muscles, the

superior rectus, the internal rectus, the inferior rectus and the inferior oblique muscles, supplied by the third or oculomotor nerve, the superior oblique muscle supplied by the fourth or trochlear nerve and the external rectus muscle supplied by the sixth or abducent nerve. The secretory glands of the eyes are very small. The eye-ball has a strong white fibrous outer coat, the *sclerotic*, the anterior portion of which is transparent and is called the *cornea*. Under cover of the sclerotic is a vascular layer, the *choroid*, which forms the iris in front and contains a horizontal elliptical opening, the pupil. (*Vide* rabbit's eye *fig.* 54).

The *retina* which resembles that of the *rabbit* (*vide fig.* 55) is the innermost layer of the eye and consists of nervous elements with three series of neurons, each neuron possessing a cell with two processes on each side; the innermost neurons being the layer of rods and cones, the cells of which are adapted to translate visual impulses. The rods and cones look like square and conical bottles under the high power of the microscope. One of the processes of the rod or cone cells dips into the most external layer of the retina, the pigmented cell layer; while the other arborises with the axon of the middle layer cell, the bipolar cell. The second process of the bipolar cell arborises with the axon of the innermost layer cell, the nerve cell, the other process of which curves towards a spot, the *blind spot*, and then dips into the layers of the eyeball to come out as the optic nerve.

The globular lens is situated just behind the iris; it is transparent and throws the external rays in a convergent manner on to the retina. In front of the lens is a small cavity containing watery fluid called the aqueous humour and behind the lens is a large cavity containing a viscid fluid the vitreous humour.

*The organ of hearing.* In rabbits the organ of hearing consists of an external, a middle and an internal ear. The external ear consists of a large auricle to collect air waves

from different directions, and an external auditory meatus to conduct the air waves on to the tympanic membrane which is stretched across the middle ear. The middle ear is a bony chamber which communicates with the external air by means of the Eustachian or auditory tube ; it contains a series of ossicles the first of which is attached to the tympanic membrane, and the last to an opening in the internal ear, the fenestra ovalis, thus communicating the vibrations of the tympanic membrane to the internal ear. The internal ear contains fluid and special cells which translate the air waves and transmit them through the auditory nerve to the brain. In frogs the auricle and the external auditory meatus are suppressed and the tympanic membrane is exposed directly to the external air. The middle ear communicates with the external air by means of the Eustachian tube, and instead of a series of ossicles there is a rod shaped structure which is partly bony and partly cartilagenous called the *columella*, which is attached to the tympanic membrane on one side and the fenestra ovalis on the other.

The internal ear or labyrinth is a complicated structure and consists of two sets of apparatus, one for hearing and the other for detecting the change of position. The auditory apparatus is made up of the auditory capsule containing perilymph, inside which is a membranous labyrinth containing endolymph. The apparatus for detecting the change of position consists of a utricle that communicates with three semicircular canals placed in three different planes at right angles to one another, and a saccule. The saccule is connected by means of a wide aperture to the utricle and gives off a blind tube, the endolymphatic duct and a small pouch, the cochlea. The semicircular canals contain the endolymph and the otolith which moves in accordance with the change of position of the animal and stimulates the spherical cells from which the impulse is conducted through the auditory nerve to the brain thus making the animal conscious of its exact position.

The organ of smell consists of an olfactory passage lined with olfactory cells. One of the processes of these cells is hairy, and translating the sensation of smell, transmits it to the brain through the olfactory nerve.

*The Sensations of Touch* are carried from special nerve endings in the skin to the brain by means of sensory nerves.

*The Excretory System.* The kidneys are a pair of cylindrical bodies which are dark red in colour, lie one on each side of the urostyle and are covered on their anterior aspect by the peritoneum; from the outer border of each kidney arises a ureter which carries the excreted urine into the cloaca. Attached to the kidney anteriorly is a yellowish body, the adrenal body. The kidney is made up of a number of tubules that start from a globular structure called *glomerulus* containing blood vessels; the tubules are convoluted and carry their contents on to the ureter. The blood which passes through the glomerulus is derived from the renal artery, while the blood to the tubules is supplied by the renal-portal vein. The ureters open in the cloaca just opposite the bladder and so a certain amount of urine collects in the bladder before it is voided.

*The Reproductive System.* The male frog possesses a pad on its first finger with which it clasps the female for days; in the breeding season ova which are passed out by this pressure get fertilised in water.

The testes are yellow bodies situated in front of the kidneys. A series of tubules, the vasa efferentia, carry the spermatozoa to the kidneys from where they are conducted into the Wolffian ducts (ureters) which serve as a common passage for the spermatozoa and urine. In *Rana tigrina* the beginning of the ureter is dilated.

The female frog possesses two ovaries that are situated in front of the kidneys. The ovary is a large sac containing ova in various stages of development; the immature ova being

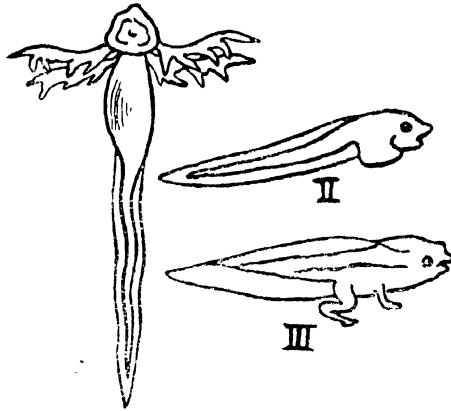


FIG. 45. METAMORPHOSIS OF FROG.

I. Tadpole. II, Tadpole without external gills, III. Young Frog with a tail.

Rudimentary limbs next appear, and two pouch like out-growths from the œsophagus develop into the lungs. At this stage the tadpole comes to the surface of water to breathe and enjoy the air. The heart which at this stage is two chambered, drives its blood to the gills whence it is collected by means of six efferent branchial arteries by two aortæ which later fuse into one. The fourth branchial artery gives rise to the pulmo-cutaneous artery. Blood to the gills stops as development proceeds and the pulmonary system is developed. The auricle divides into two by a septum. The tadpole begins to develop and change rapidly. The mouth becomes wide, the eyes are exposed, the limbs appear, and the tadpole begins to feed on small animals and may even devour its own kind. This change in diet causes the shrinking of the intestine and the abdomen and the enlargement of the liver and the stomach. The tail shortens and gradually gets absorbed. Metamorphosis now takes place and the tadpole sheds its skin and the horny plates of the jaws and becomes a frog.

## Aves—Birds

Birds belong to one of the highest order of the vertebrates. They are warm blooded animals and lay eggs. The exoskeleton is represented by the feathers which encase the body and end in a tail at the root of which the green gland lies dorsally. The wings of birds are the modification of fore-limbs which are used in flight. The eyes are usually placed at the sides and are covered with eyelids; while a third well marked eyelid known as the nictitating membrane also exists. The pinna is practically absent and the tympanum communicates with the internal ear by means of a bony rod, the columella. The bones contain air sacs which communicate with the lungs. The sternum is well developed and generally has a keel. The heart is four chambered and has a single right aortic arch. The lungs are not expansile. The alimentary canal possesses only a gizzard and ends in a cloaca.

### PIGEON

The pigeon (*columba*) is a bird very common in India and found in abundant variety. It measures about ten inches from the head to the tip of its tail and weighs approximately three quarters of a pound. It possesses a powerful pair of wings which enable it to fly over long distances.

*External Features.* The head is elongated and is prolonged in front into a horny beak, at the base of which is a soft elevated area, the *cere* and the external nares. Above the nares the two eyes are situated laterally.

Behind the eye and concealed by short feathers is found the external auditory meatus. The mouth is a transverse aperture between the beak and encloses an angular tongue. Behind the tongue on the floor of the mouth is the glottis and lower down is the gullet or œsophagus. The internal nares are situated on the roof of the mouth and behind them is a median opening, the Eustachean aperture. The neck is long, elegant and flexible. The trunk is compressed sideways, prolonged ventrally and ends in a tail behind.

*The Limbs.* The fore-limbs are modified as wings and are provided with feathers and two alar membranes at the armpit and shoulders. The leg is devoid of feathers in the distal portion and is covered with horny scales, the proximal part being covered over with small feathers. The feathers are the most distinguishing features of birds. They perform a threefold function: first they enable the animal to fly and balance itself in the air, secondly they act as a protection against heat, cold and moisture, and thirdly they act as a medium of sexual attraction. Feathers may be classified into five sets.

- (1) The *remiges* or wing-quills constituting the eleven primaries attached to the hand and twelve secondaries attached to the ulna.
- (2) The *ala spuria* consisting of a small tuft of feathers attached to the first digit on the anterior border of the wing.
- (3) The *rectrices* forming the tail and used in steering.
- (4) The *contour feathers* covering the general surface of the body.
- (5) The *coverts* are small feathers covering the base of the quills of wings and tail.

A large feather consists of an *axis* which is divided into a lower or hollow portion, the *calamus* or quill and an upper solid portion the *rachis* which forms the axis of the vane.

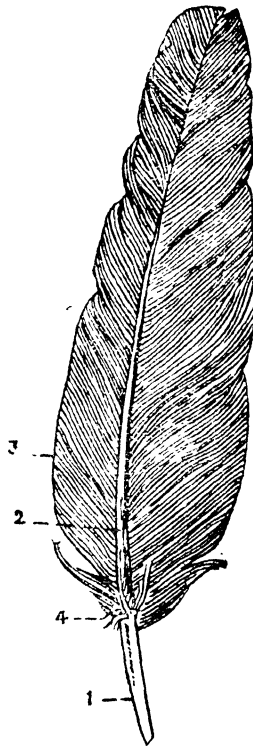


FIG. 46. A LARGE FEATHER OF PIGEON.

1. Calamus, 2. Rachis, 3. Vane, 4. After-shaft.

The *vane* consists of parallel rows of lateral barbs linked together by barbules. At the termination of the vane there is a tuft of down called the after-shaft. The quill is socketted in a follicle of the skin from which muscular fibres pass to it and produce movements.

*Dissection.* Kill the pigeon with chloroform, pluck all the feathers with the exception of the wings, make a median incision into the skin and reflect it on either side avoiding injury to the crop which overlies the trachea, then define the interclavicular air sac which lies between the clavicles. The pectorales major muscles are thus exposed on each side of the keel; these are powerful muscles which depress the wings and are chiefly

*instrumental in flight. Turn each muscle laterally towards its insertion into the humerus by cutting through its origin from the lower half of the keel, the clavicle and the sternum; the pectoralis minor muscle together with the pectoral artery and vein will thus be brought into view. Detach the pectoralis minor from the upper half of the keel and sternum; it will be seen that its tendon passes through an opening, the foramen triosseum, formed by the coracoid, the clavicle and the scapula; this opening acts as a pulley for the tendon of the pectoralis minor which by its contraction raises the wings. After reflecting the pectoralis minor, the coracobrachialis with its origin from the coracoid and its insertion into the top of the humerus will be exposed; its action consists of aiding the pectoralis major in depressing the wings. Finally detach this muscle and open the abdominal cavity; in doing so note the thin walled air sac lying dorsally in the body cavity and communicating with the bronchi. A fold of peritoneum, the omentum, will come into view. This covers many of the viscera in the abdomen. In the upper part of the cavity is the heart lying in the pericardium. Behind the heart are the lungs. The liver, a solid dark organ, is situated lower down. The œsophagus opens in the proventriculus which opens on the left side of the strong flat gizzard situated below the liver. On the right side of the gizzard arises the U-shaped duodenum with the pancreas embedded in it. The intestine is coiled and opens into the cloaca. Lift up the viscera and the coils of intestine and find the ovary with its oviduct in the female or the testes and the vas deferens in the male, lying on the lobulated kidneys.*

**The Digestive System.** The buccal cavity leads into an œsophagus the lower portion of which dilates into a thin walled sac, the crop, in the posterior part of the neck; the œsophagus continues downwards and opens in the proventriculus or the stomach which again opens into the gizzard on the left side. On the right the duodenum will be seen emerging from the strong muscular gizzard. The spleen, a reddish small organ, lies to the right of the stomach. The duodenum

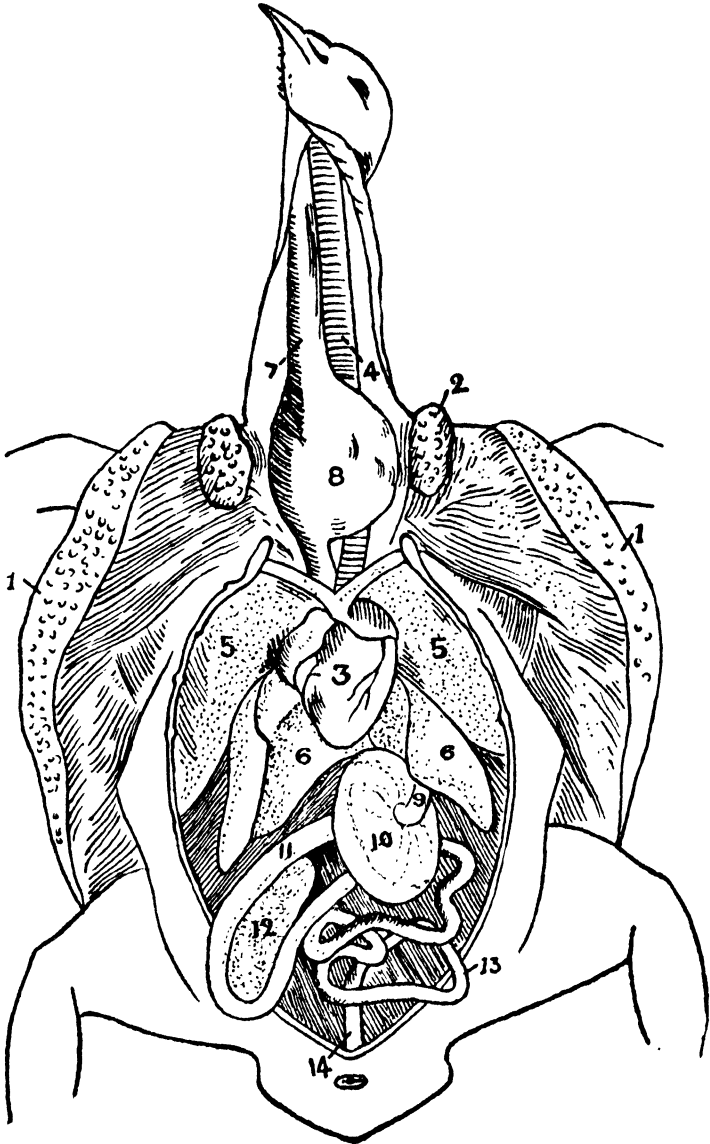


FIG. 47. DISSECTION OF PIGEON.

1. Pectoralis major, 2. Pectoralis minor, 3. Heart, 4. Trachea,  
 5. Lung, 6. Liver, 7. Œsophagus, 8. Crop, 9. Proventriculus, 10. Gizzard  
 11. Duodenum, 12. Pancreas, 13. Intestine, 14. Rectum.

is a bent tube containing the pancreas in its bend and continuous with the small intestine, a long and convoluted tube which continuing into the rectum opens into the cloaca. The ducts of the pancreas and of the liver open directly into the duodenum. There is no gall bladder in the pigeon and the liver consists of a large right and a small left lobe, marked on its surface by the heart, duodenum and the gizzard.

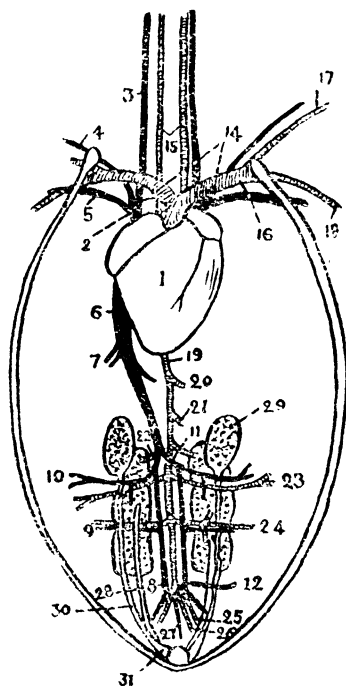


FIG. 48. DISSECTION OF PIGEON.

1. Heart, 2. Anterior vena cava, 3. External jugular vein, 4. Brachial vein, 5. Pectoral vein, 6. Posterior vena cava, 7. Hepatic vein, 8. Renal portal vein, 9. Sciatic vein, 10. Femoral vein, 11. Common iliac vein, 12. Coxygeo-mesenteric vein, 13. Aortic arch, 14. Innominate artery, 15. Common carotid artery, 16. Subclavian artery, 17. Brachial artery, 18. Pectoral artery, 19. Dorsal aorta, 20. Median cœliac artery, 21. Anterior mesenteric artery, 22. Anterior renal artery, 23. Femoral artery, 24. Sciatic artery, 25. Internal iliac artery, 26. Posterior mesenteric artery, 27. Caudal artery, 28. Ureter, 29. Testis, 30. Vas deferens, 31. Vesicula seminalis.

*Cut through the œsophagus and the rectum and remove the alimentary canal taking care of the coxygeo-mesenteric*

*vein and the liver. Open the pericardium and define the heart, the arteries and the veins carefully; then cut open the anterior wall of each auricle and having washed it and studied its interior cut across the ventricles and note their size, shape and appearance.*

*The Circulatory System.* The heart is conical in shape and is enclosed in the pericardium. The pericardium consists of two layers—the visceral and the parietal; these two layers are continuous with each other at the root of the heart where the large vessels take their origin. The heart is situated with its base pointing forwards. The auricles which form the base present a groove, filled with fat defining the right auricle from the left and another groove which marks the separation of the auricles from the ventricles. There is no sinus venosus. The right side of the heart receives venous blood while the left side receives arterial blood. The auricular cavity is divided by the inter-auricular septum into the right and left auricles. The right auricle has the openings of the venæ cavæ which pour their blood into the right auricle and from thence to the right ventricle; from the right ventricle the blood passes by the pulmonary arteries to the lungs to be oxygenated, whence it is brought back into the left ventricle and is pumped into the aorta to be distributed to the head, neck and the body.

The arteries consist of the pulmonary arteries and the aorta. The pulmonary artery arises from the anterior portion of the right ventricle and divides into the right and left pulmonary branches which enter into the right and left lungs respectively.

The aorta arises from the base of the left ventricle and arching to the right proceeds backwards as the dorsal aorta. At its origin it gives off a right and a left innominate artery; each of this divides into first, a common carotid which after giving off the vertebral artery divides into the external and the internal carotid arteries, and secondly the subclavian

artery which gives off the brachial to the wings and the large pectoral to the great pectoral muscles. From the dorsal aorta arise the median cœliac to the stomach, gizzard and the anterior portion of the intestine, the anterior mesenteric to the intestine, a pair of anterior renal to the anterior lobes of the kidneys, a pair of femorals to the thighs, a pair of sciatic arteries to the legs from which are given off the middle and the posterior renal arteries to the middle and posterior lobes of the kidneys, a pair of internal iliac arteries to the pelvis, a pair of posterior mesenteric arteries to the rectum and cloaca, and a caudal artery to the tail.

The veins converge towards the right auricle in the form of the three venæ cavæ, the right, the left, and the posterior vena cava. Each anterior vena cava is formed of three veins, the external jugular, the brachial, and the pectoral vein. The posterior vena cava receives blood from the posterior portion of the body; it is formed of the two common iliac veins and runs upwards through the liver, receives a hepatic branch soon after its emergence and enters the posterior portion of the right auricle.

The common iliac vein receives its blood from one of the two branches of the caudal vein which arises from the tail and branches into the two portal veins. The renal portal vein receives a small internal iliac vein and passes through the kidneys where it receives the sciatic and femoral veins from the legs and emerges from the kidneys as the common iliac vein, having received the small renal veins from the kidneys.

The coccygeo-mesenteric vein arises at the origin of the renal portal vein and having collected blood from the cloaca and the large intestine joins the hepatic portal vein.

The hepatic portal vein is formed of the gastro-duodenal and the anterior and posterior mesenteric veins, and enters the liver.

The pulmonary veins from the lungs open into the left auricle.

*The Respiratory System.* Cut through the large vessels of the heart, remove it and define the trachea and lungs.

The trachea is a rigid tube guarded by rings which are partly ossified. It commences at the glottis, lies ventral to the œsophagus and then to the left side of it while in the thorax it again lies ventral to the œsophagus where it divides into two bronchi which enter the lungs on each side and also communicate with the air sacs. The terminal portion of the trachea is dilated into the syrinx or the organ of voice. The lungs are two spongy bodies covered over by the pleuræ. There is no definite diaphragm in the pigeon.

*The Skeletal System.* The bones of birds are lighter in weight than those of other animals because of the air cavities which they contain. The long bones have no epiphyses. The bones consist of the vertebral column, the skull, the mandible, the hyoid and the pectoral and the pelvic girdles with their limbs.

The vertebral column consists of fourteen cervical vertebræ, the middle ten bearing rudimentary ribs which are attached to the centrum and the transverse process. The cervical vertebra has a centrum concave from side to side and convex from above downwards anteriorly, the posterior surface showing a reverse curvature; this type is called *heterocælus*.

The atlas is the first cervical vertebra. It presents a ring like appearance and has no centrum of its own; it bears on its anterior surface a single articular facet for the occipital condyle. The second cervical vertebra or axis has an odontoid process which fits into the atlas and a part of it forms the centrum of the atlas. The thoracic vertebræ are five in number. With the exception of the fourth all the rest are fused together. Each vertebra has a pair of ribs

which reach the sternum anteriorly. The sacral vertebra consists of thirteen fused vertebræ and are called the synsacrum. The caudal vertebræ consist of six free vertebræ while in the posterior region, a bone, the *pygostyle*, is formed by the last four caudal vertebræ.

The skull is high and elongated in front to form the long facial region ; this in the case of birds is movable. The orbits are large, are situated anteriorly and are separated by the inter-orbital septum, having the lacrymal bones in front. On the posterior aspect the skull presents a large opening, the foramen magnum, which is surrounded by the basioccipital in front, the two ex-occipitals on the sides, and the supra-occipital behind ; a single condyle, for articulation with the atlas, is present on the ex-occipital.

The roof of the cranium is formed by the two parietals, the frontals, and the nasals ; on the side is situated the tympanic cavity with the squamosal above and the basi-temporal below.

The base of the cranium is formed by the basi-sphenoid and the rostrum.

The roof of the mouth is formed by the bony palatines, the maxillæ, the premaxillæ and the pterygoids.

The tympanic membrane is connected with the fenestra ovalis of the internal ear by means of a single bony rod, the *columella*.

The jaws bear no teeth but have horny sheaths. The upper jaw is tri-radiate and consists of the premaxilla, maxilla and the quadrato-jugal. The lower jaw consists of the dentary, the splenial, the supra-angular, angular and the articular. The two dentaries form the symphysis in front.

The hyoid is partly ossified, being situated in the floor of the mouth and consists of a flat body with an anterior and a posterior cornu.

The pectoral girdle consists of the scapula, the coracoid and the clavicle, which together enclose the foramen triosseum through which passes the tendon of the pectoralis minor and which acts as a lever for the tendon to play upon. The scapula is situated dorsally, the coracoid is a stout process, which articulates with the sternum, and the clavicles are joined together by means of the interclavicle. The sternum has two xiphoid processes and is marked laterally by the sternal ribs.

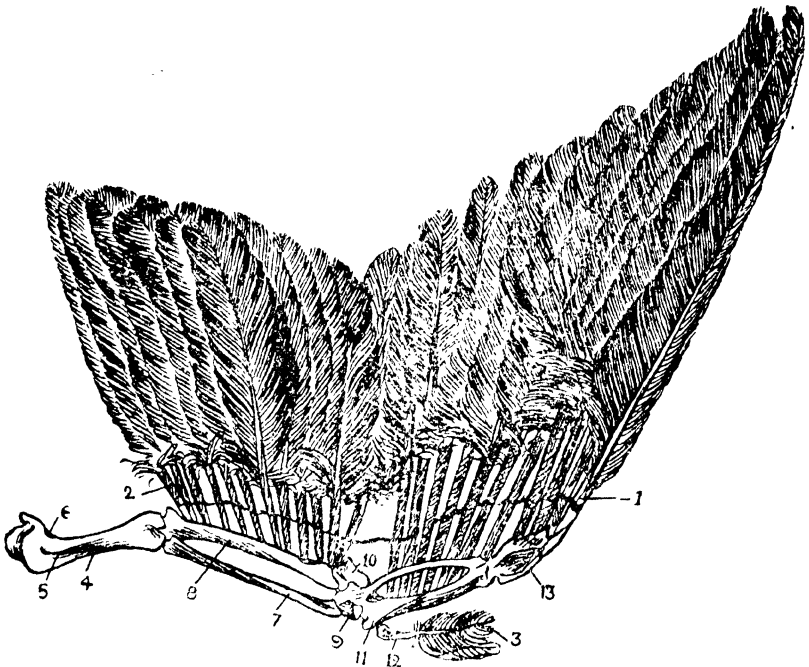


FIG. 49. RIGHT WING OF PIGEON DISSECTED.

1. Primaria, 2. Secundaria, 3. Ala spuria, 4. Humerus, 5. Deltoid ridge, 6. Pneumatic foramen, 7. Radius, 8. Ulna, 9. Radiale, 10. Ulnare, 11. Carpo-metacarpal, 12. First digit, 13. Digits.

The skeleton of the wing consists of a stout humerus, a radius with a long ulna, two carpals, a carpo-metacarpal, and three digits. The thumb has one joint, the first finger two, and the second finger one.

The pelvic girdle is made up of the ilia, the sacrum, the ischia and the pubes ; the acetabulum is incomplete and the symphysis is absent. The hind limb is made up of a stout femur, a tibia and a fibula, a tibio-tarsus, three fused metatarsals, a free metatarsal and four toes the digital formula being 2345.

*The Muscular System.* The most important muscles are those of the wings, and these have already been discussed. The muscles of the hind limb do not possess any peculiarity worth describing. The musculature of the alimentary canal consists of involuntary muscular fibres. Those of the gizzard are well developed.

*The Nervous System.* Cut away the roof and side of the skull and expose the brain. Cut through the spinal cord and the various nerve roots and separate the brain. Harden the brain carefully by placing it for a few days in a bottle of spirits or a dilute formalin solution. After studying the external features of the brain divide it into two equal halves and study the cavities.

The brain fills the entire cranial cavity. The cerebral hemispheres are elongated bodies with a smooth surface. The cerebellum is an elongated oval body in contact with the cerebrum above and continuous with the medulla oblongata and the spinal cord below. The olfactory lobes are poorly developed ; they project from the anterior end of the hemispheres. The pineal body is a small protuberance behind the hemispheres. The optic lobes are situated laterally below the hemispheres. The base of the brain presents for examination the optic chiasma which is formed by the crossing of the optic nerves and the infundibulum (which gives attachment to the pituitary body) behind the optic chiasma.

The cavities of the brain comprise of the third ventricle, the lateral ventricles and the fourth ventricle. The third ventricle is the original cavity of the anterior cerebral vesicle.

The lateral ventricles are the outgrowths from the forebrain; the fourth ventricle is the cavity of the hindbrain and is situated in the medulla. The third ventricle is connected with the lateral ventricles by means of a foramen on each side. The third ventricle communicates with the fourth ventricle behind by means of a narrow passage called the *iter a tertio ad quartum ventriculum*; this passage is the only remaining portion of the cavity of the mid-brain.

*The Sense Organs.* The sense of taste and smell are not well developed in the pigeon. The sense of hearing is acute and the auditory apparatus consists of the external auditory meatus, the tympanum and the internal ear. The tympanic cavities communicate with the external air by means of the Eustachian tubes which run forwards from the anterior angle of the cavity and after uniting open as a single aperture into the roof of the mouth. The tympanic membrane is stretched on the outer surface of the tympanic cavity and communicates the external vibrations of the air to the internal ear by means of a bony rod, the columella. The cochlea is well developed.

*Remove the spongy portion of the hinder part of the skull from the more compact bone containing the auditory organ and note the three semicircular canals placed in different planes, e.g., the anterior vertical, the posterior vertical and the horizontal.*

The eye has three eyelids, the third eyelid being the nictitating membrane which moves by means of two muscles, the *quadratus* and the *pyramidalis*. The eyeball is moved by the four recti and the two obliqui muscles. The general structure resembles that of the frog's eye with the following exceptions: first, the pecten, a vascular fold, projects into the eye from the orbit; secondly, the lens is flatter, and thirdly, the sclerotic plates consist of a ring of small bones just behind the sclero-corneal junction.

*The Excretory System.* The kidneys are a pair of elongated dark red bodies, and consist of three lobes. The ureter comes out in front and passes down into the cloaca. In front of each kidney will be found a small yellowish gland, the adrenal body.

*The Reproductive System.* In the male the reproductive system consists of a pair of testes in front of the kidneys. Each gives off a convoluted tube, the *vas deferens*. The *vas deferens* runs down through the seminal vesicle and opens into the cloaca.

In the female two ovaries are present in the embryo but later on only the left ovary and its oviduct persists. The duct carries the eggs to the cloaca, which is a depression below the tail and into which the rectum, the ureters and the genital ducts open.

## Mammalia

Mammals, one of the six classes of vertebrates, are nearly always quadrupeds. They have a well defined head, a neck, a trunk and in most cases a tail. Hair is invariably present together with certain skin glands which secrete sweat and sebum. They also produce milk on which their young ones are fed. The thorax is completely separated from the abdomen by means of a diaphragm which is the chief muscle of respiration. Most of the skull bones are united by means of sutures. The brain which is much convoluted, is united by the corpus callosum and covers the optic lobes and sometimes even the cerebellum. The heart is four chambered and has one aortic arch. The mature red blood corpuscles are not nucleated and the blood remains uniformly warm.

### RABBIT

The rabbit (*Lepus cuniculus*) is a type of mammalia with features too well known to need any description.

*External Features.* The head is joined to the body by means of a neck, and has two long external ears. The eyes are covered by the two eyelids, and a third eyelid, the nictitating membrane, helps in cleaning the cornea. The mouth is covered by two soft lips, the upper one being cleft in the middle and forming the typical harelip. The nostrils are two slits above the mouth.

The trunk is made up of an anterior part the thorax, and a posterior one, the abdomen. The anus and the perineal glands which emit a peculiar smell open in the hinder region. The urogenital apparatus consisting of the vulva in the female,

and the penis with the scrotal sacs in the male is situated just in front of the anus. A row of five teats leading to the mammary glands on each side of the abdomen and on the ventral aspect of the thorax will be seen in the female.

The fore limbs consist of an arm, a forearm and a hand. The hand consists of four digits. The hind limbs which are longer than the fore limbs consist of a thigh, a leg and a four clawed foot.

The skin is covered all over with hair and possesses the sweat and sebaceous glands which secrete a sort of fat, the lachrymal glands of the eyes which produce tears, the perineal glands behind, which emit a peculiar odour, and the mammary glands which are really sweat glands and which secrete milk. The panniculus carnosus, a thin layer of muscle, lies under the skin and is responsible for its twitching.

The buccal cavity is exposed by cutting one of the mandibles. The tongue is long and behind it is the glottis with an overhanging epiglottis while the pharynx is situated further back. The buccal cavity is separated from the nasal cavity by means of a palate and the internal nares open behind it while the Eustachian apertures are situated laterally on each side of it. There are four pairs of salivary glands which pour their secretion, the saliva, into the mouth and by virtue of the ferment ptyalin which it contains, help the digestion of starch. These glands are the infra-orbital, situated below the eyes; the parotid which lie below the ear; the submaxillary which are placed below the mandible, and the sublingual gland found below the tongue. The jaw bears a pair of first and second incisors in front, and six molar teeth for the crushing and chewing of food at the sides. and between these pairs of teeth there is a toothless portion of the jaw called the *diastema*. Situated in the bone between the nasal cavity and the mouth, is a small pair of tubular bodies, the *organ of Jacobson*.

*Dissection.* The rabbit should be killed by chloroform and fixed on a board by means of stout pins or nails. A vertical incision should be made from the chin to the anus and the skin reflected on each side, thereby exposing the *panniculus carnosus*, which lies just under the skin. The abdominal wall should be divided in the middle line with a pair of scissors taking care of the structures in the abdominal cavity which is thus laid open. The position of the various viscera and the diaphragm should be studied, and the thorax should be opened by cutting through the side of the ribs, the sternum, and the diaphragm and by removing the breast plate while leaving the first rib intact.

The thorax is lined by a thin membrane, the pleura, which also covers each lung. The thymus will be seen in the upper region ventral to the great vessels of the heart. Below this is the heart with the lungs on each side of it. The heart is enclosed in a pericardium. The diaphragm is a muscular partition which separates the thorax from the abdomen. The œsophagus with the vagus nerve and the sympathetic ganglia lie behind.

The abdominal cavity is lined with peritoneum which is suspended from the posterior abdominal wall as the mesentery supporting the alimentary canal. The liver is situated in the upper part of the abdominal cavity and the stomach, intestines and bladder in the lower part. The spleen is situated under the stomach. The kidneys, the adrenals, the blood vessels and the cœliac ganglion lie on the posterior abdominal wall.

*The Digestive System.* The œsophagus is a soft tube which passes down the neck and thorax, continues through the diaphragm and opens on the left side of the stomach which is a dilated sac with a broad portion, the cardia, and a narrow one, the pylorus. At the junction of the pylorus with

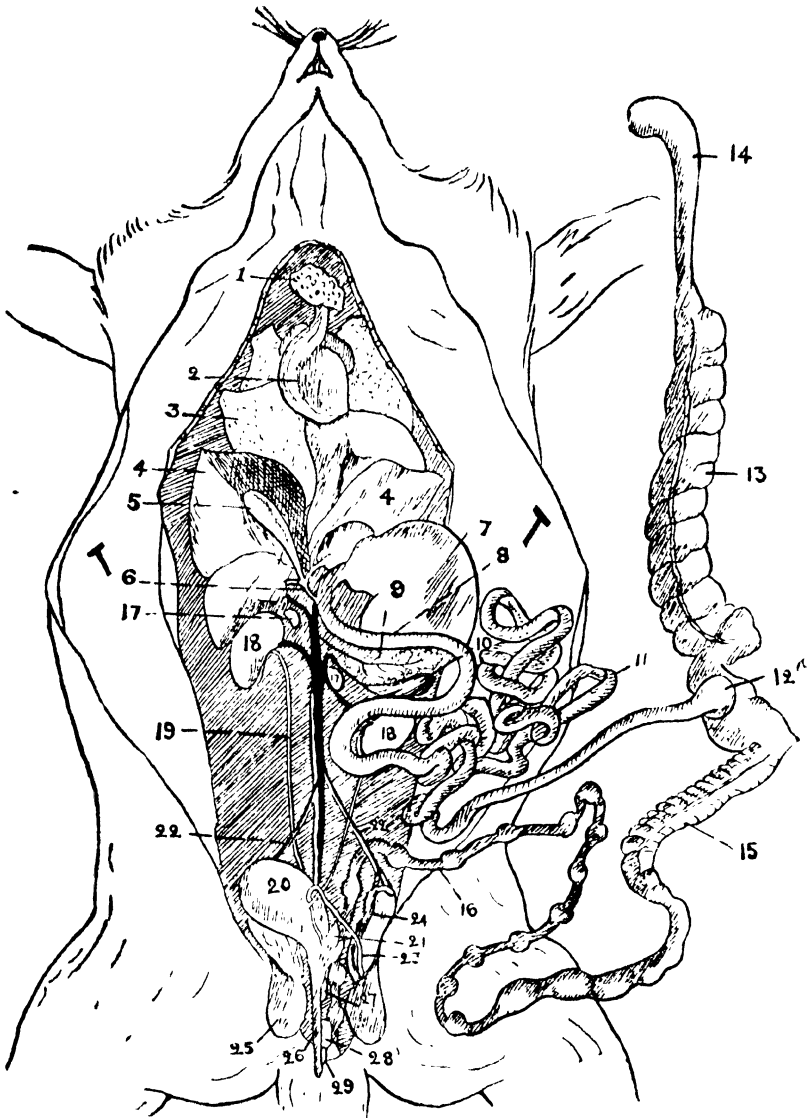


FIG. 50. DISSECTION OF MALE RABBIT

1. Thymus, 2. Heart, 3. Right lung, 4. Liver, 5. Gall bladder, 6. Bile duct, 7. Stomach, 8. Duodenum, 9. Pancreas, 10. Spleen, 11. Ilium, 12. Sacculus rotundus, 13. Cœcum, 14. Vermiform appendix, 15. Colon, 16. Rectum, 17. Suprarenal, 18. Kidney, 19. Ureter, 20. Bladder, 21. Uterus masculinus, 22. Spermatic vessels, 23. Vas deferens, 24. epididymis, 25. Testis, 26. Penis, 27. Prostate, 28. Cowper's gland, 29. Perineal gland.

the duodenum there is a muscular sphincter controlling the entry of food. The duodenum is the first part of the small intestine which is about nine feet long; its distal end opens into a pouch, the sacculus rotundus, which is continuous with a very large cæcum and a large vermiform appendix. The cæcum is continuous with the colon which is about a couple of feet long and terminates into the rectum which contains pellets of fæces and opens externally at the anus.

The liver is a large organ consisting of five lobes; its upper surface is convex and lies immediately in contact with the diaphragm, being supported by a double fold of peritoneum known as the suspensory ligament. Its posterior surface is concave and has a fossa for the gall bladder and the stomach. The size of the liver is large because it stores glycogen and controls the portal circulation. The gall bladder lies under the right middle lobe of the liver. It is an elongated thin walled sac of a greenish colour with a duct that joins the ducts of the liver and forms a bile duct, which opens in the beginning of the duodenum. The pancreas will be found in the duodenal loop along with the blood vessels. All the ducts of the pancreas unite into one and open into the distal loop of the duodenum.

*The stomach and the intestines should be removed after ligaturing and cutting through the œsophagus and the last portion of the rectum. The mesentery should also be cut near the intestines. The alimentary canal thus separated should be slit open under water and the structures studied carefully.*

The stomach and the intestines will be found to consist of three layers, the external peritoneal or serous layer, the middle muscular layer and the internal mucous layer. The inner mucous layer is thrown into folds. The mucous membrane of the stomach is thrown into longitudinal folds while the mucous membrane of the intestines is raised into villi and presents Peyer's patches which are collections of lymphoid

tissue underneath the mucous membrane. The mucous membrane of the rectum is smooth and has no marked folds.

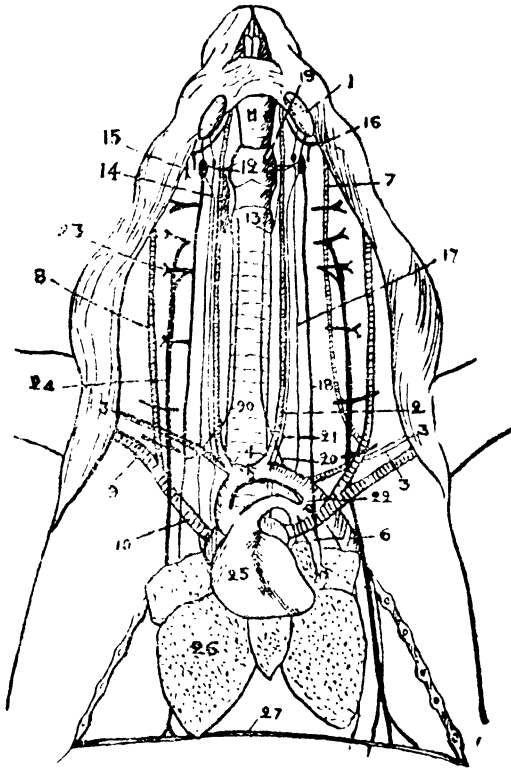


FIG. 51. DISSECTION OF RABBIT.

1. Submaxillary gland, 2. Common carotid artery, 3. Subclavian artery, 4. Innominate artery, 5. Arch of the aorta, 6. Left pulmonary artery, 7. External jugular vein, 8. Internal jugular vein, 9. Subclavian vein, 10. Pre-caval vein, 11. Larynx, 12. Thyroid cartilage, 13. Cricoid cartilage, 14. Thyroid gland, 15. Spinal accessory nerve, 16. Hypoglossal nerve, 17. Cervical sympathetic nerve, 18. Vagus, 19. Superior laryngeal nerve, 20. Inferior laryngeal nerve, 21. Depressor nerve, 22. Ductus arteriosus, 23. Fourth cervical nerve, 24. Phrenic nerve, 25. Heart, 26. Right lung, 27. Diaphragm.

Digestion is carried on, in the mouth by the admixture of saliva with the food. The starch particles are acted upon by the ferment ptyalin which converts it into dextrose. The rest of the digestive functions are similar to those of the frog. The rabbit being herbivorous, its food is large in quantity and gets absorbed slowly, chiefly in the cæcum, where

it gets stored. Fæces are passed through the anus as round pellets.

*To expose the heart the thymus should be removed and the parietal pericardium cut through, but in doing so care should be taken to avoid the nerves, the pulmonary and aortic arches and the ductus arteriosus; the last should be cleaned to define the left recurrent laryngeal nerve, which hooks round it.*

*The Circulatory System.* The heart is enveloped by the two layers of the pericardium, the parietal and the visceral layers. It consists of four chambers and is divided by septa which are marked externally by grooves wherein some fat is embedded. The upper portion of the heart consists of the auricles and the lower portion of the ventricles. The ventricles, specially the left, are much thicker than the auricles. The right side of the heart contains deoxygenated blood and the left side oxygenated blood; the venæ cavæ open into the right auricle and carry blood from the body; the opening between the auricle and the ventricle is guarded by a valve with three cusps called the tricuspid valve. The interior of the ventricle is studded with muscular columns called the papillary muscles, and to these are attached the chordæ tendineæ which pull the valve and keep it from getting pushed into the auricles. The right ventricle has the opening of the pulmonary artery in its upper and anterior aspect guarded by the semilunar valves. The left ventricle has the opening of the aorta in its anterior aspect guarded by the semilunar valves and the auriculo-ventricular opening guarded by the mitral or bicuspid valve.

The aorta in its passage to the left forms an arch which is placed in front of the arch formed by the pulmonary artery. These two arches are connected together by means of a fibrous cord which remains patent in the fœtus, thereby connecting the pulmonary artery with the aorta. Thus

the blood passing from the right ventricle through the pulmonary artery gets into the aorta as the lungs are not active in the foetus, but as soon as the rabbit is born and the lungs become active the ductus arteriosus is closed and dwindles into a fibrous cord. Such a remnant of a once active structure is called a *vestige*.

Circulation of blood is kept up by the rhythmic contraction, *systole*, and dilatation, *diastole*, of the heart. Blood passes from the right auricle into the right ventricle, thence through the pulmonary arteries to the lungs where it gets oxygenated and is returned by means of the pulmonary veins to the left auricle, and then to the left ventricle. From here it is pumped into the aorta and is distributed by means of arteries, arterioles and capillaries to the various parts of the body. It then collects in the venules, veins and the *venæ cavæ* and is returned to the right ventricle of the heart.

The heart is made up of striated muscular fibres which have the inherent quality of rhythmic contraction. The heart is innervated by the vagus and the sympathetic nerves which control its movements. The blood supply is derived from the coronary arteries which arise from the aorta close to its origin.

The pulmonary circulation is carried out by the pulmonary arteries and veins as already noted. The systemic circulation is carried out by the aorta which arches to the left and continues through the diaphragm as the abdominal aorta. The arch gives off the innominate, the left common carotid and the left subclavian arteries. The innominate artery divides into the right subclavian which goes to the upper extremity, and the common carotid which leads to the head. The common carotid artery gets further divided into the internal and the external carotid arteries which supply the head and brain, the side of the face and the neck respectively. The left carotid and subclavian correspond to the distribution of the right side. The abdominal aorta passes back

ventral to the vertebral column through the diaphragm and terminates by dividing into the two common iliac arteries. In its passage backwards through the abdomen the dorsal aorta gives off a phrenic artery to the diaphragm, a cœliac artery to the stomach, liver and spleen, an anterior mesenteric to the intestine and pancreas, a posterior mesenteric to the rectum, a pair of renals to the kidneys, a pair of testicular or ovarian supplying the testes or the ovaries, and a caudal median artery arising at the apparent division of the aorta. The common iliac arteries pass down to the hind limbs as the femoral artery after giving out in the abdomen the ilio-lumbar branch to the abdominal wall behind, the internal iliac to the pelvic cavity and a vesical branch to the bladder.

*The Veins.* Three main vessels, the right and left precaval or the superior venæ cavæ and the postcaval or the inferior vena cava enter the right auricle of the heart. The surface of the head and face is drained by means of the anterior and posterior facial veins into the external jugular. This vein receives the internal jugular and the vertebral from the brain, at the root of the neck. Here it unites with the subclavian, a continuation of the brachial vein from the upper limb, and forms the precaval vein. A small vein, the azygos lying lateral to the vertebral column joins the right precaval vein.

The internal iliac drains the blood from the pelvis and forms the postcaval vein after receiving the two femorals from the hind limb, the two ilio-lumbar from the back, the genitals from the gonads, the renals from the kidneys, the dorso-lumbar from the dorsal muscles, the hepatics from the liver, and the phrenics from the diaphragm.

*The Portal System.* Venous blood from the stomach, spleen, duodenum and the intestine converges by the gastric, splenic, duodenal, anterior and posterior mesenteric veins into a large vein called the portal vein which runs into the liver and divides into numerous branches.

The blood of the rabbit consists of blood plasma with red and white blood corpuscles. The red blood corpuscles are disc shaped and are not nucleated. They are smaller in size than the red blood corpuscles of the frogs. The white blood corpuscles are nucleated, possess amœboid movements and present many varieties.

*The Lymphatic System.* Small lymphatic vessels converge to the two thoracic ducts lying on either side of the vertebral column. Each thoracic duct opens into the precaval vein of the same side.

*The Respiratory System.* Each lung is enclosed in a thin membrane, known as the visceral layer of the pleura. This layer is reflected on to the thoracic wall and is called the parietal pleura. The lungs are spongy and not saccular as in the frog. They are elastic and always tend to contract.

*Mechanism of Respiration.* The diaphragm is a muscular dome with its convexity towards the thorax. Its contraction causes a flattening of the dome and an increase in the capacity of the thoracic cavity. The ribs are attached to the spine and they slant downwards obliquely. To the ribs are attached the intercostal muscles whose contraction causes the elevation of the ribs and also an increased capacity of the thorax. The contraction of the intercostal muscles and diaphragm results in an increased capacity in the thorax causing expansion of the lungs. Inspiration is caused by air rushing in through the nostrils and filling the expanded lungs, while the relaxation of the muscles and the elastic recoil of the lungs drives the air out and causes expiration.

*The Skeletal System.* The skull of the rabbit is formed of cartilage and membrane bones; they are arranged in the form of superimposed segments and as bony coverings of some of the sense organs. The most posterior or the occipital segment consists of a basi-occipital which surrounds the foramen magnum in front, the pair of ex-occipitals which also

enclose the foramen magnum and forms the condyle, and the supra-occipital. The sphenoid segment consists of the two parietals, the interparietal, and the pair of alisphenoids. The parietals lie above the basi-sphenoid, the interparietals lie laterally to them and the pair of alisphenoids are attached to them. The sphenoid segment consists of the frontal bone above, the orbito-sphenoid laterally and the pre-sphenoid below. The ethmoid segments consist of the nasals above and the mesethmoids below. The bones of the sense capsules are in intimate relation with the skull; the auditory bones situated between the occipital and the sphenoid ring on each side consist of periotic, which is prolonged into the mastoid process and contains the internal ear, and the tympanic, forming the auditory bulla and the auditory meatus. The eyes are enclosed in an orbit which consists of the alisphenoid, the orbito-sphenoids, the frontals and the lachrymals. The bones of the nose, called the turbinals, are thin and twisted

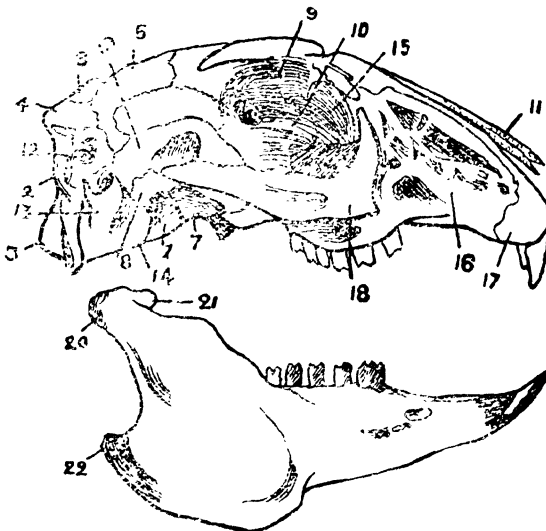


FIG. 52. SKULL OF RABBIT.

1. Basi-occipital, 2. Exoccipital, 3. Occipital condyle, 4. Supra-occipital, 5. Parietal, 6. Interparietal, 7. Basi-sphenoid, 8. Alisphenoid, 9. Frontal, 10. Orbito-sphenoid, 11. Nasal, 12. Periotic, 13. Tympanic, 14. Auditory bulla, 15. Lachrymal, 16. Maxilla, 17. Premaxilla, 18. Zygoma, 19. Squamosal, 20. Condyle of mandible, 21. Coronoid process, 22. Angular process.

and are attached to the ethmoid, the nasal and the maxilla and are hence called the ethmo-turbinals, the naso-turbinals and the maxillo-turbinals respectively.

The facial region consists of the maxilla and the premaxilla on each side; and the zygomatic arch is situated in front. The vomers are situated above the palatine and pterygoid in the roof of the mouth. The squamosal is situated between the auditory bones and the sphenoid ring and has the glenoid cavity for articulation of the condyle of the lower jaw. The premaxilla has two incisors and the maxilla three premolars and three molars. The mandible consists of a horizontal body and ramus. The body bears two incisors in front, two premolars and three molars behind. The ramus is formed behind by a process bearing a condyle for articulation with the glenoid cavity. In front and above the condyle is the coronary process and below is the angular process which is situated behind.

The middle ear consists of three bones, the malleus, the incus and the stapes. The hyoid bone consists of a body and two pairs of cornua.

The vertebral column is made up of seven cervical, twelve thoracic, seven lumbar, the sacrum and fifteen caudal vertebræ.

The cervical vertebræ are seven in number. They have small centra. Their transverse processes have fused ribs forming a foramen for the vertebral artery. The first vertebra, the atlas, is ring-shaped and has no centrum, the two anterior articular processes articulate with the condyles of the skull. The second vertebra or axis has a broad centrum which projects forward and forms the centrum of the atlas.

The thoracic vertebræ are twelve to thirteen in number and bear moveable ribs. Their centra are more or less rounded and the neural spine is long.

The lumbar vertebræ are seven in number ; they are large, with well developed processes and no ribs. The ventral spines are short and in some of them there is a midventral process, the hypapophysis.

The sacrum consists of three or four fused vertebræ and supports the pelvis by winglike expansions.

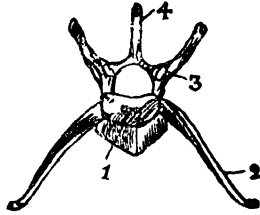


FIG. 53. LUMBAR VERTEBRA OF RABBIT.

1. Centrum, 2. Transverse process, 3. Articular process, 4. Spine.

The caudal vertebræ consist of about sixteen bones which lose their processes as they are traced backwards.

The ribs are twelve or thirteen pairs of elongated and curved bones, which articulate by means of articulating processes with the heads and the transverse processes of the thoracic vertebræ. The first seven articulate with the sternum by means of an articular cartilage, and the eighth and ninth with the cartilage of the rib in front. The rest are free.

The sternum is segmented and the first segment or manubrium is keeled while the last segment, the xiphisternum, ends in a cartilage.

The pectoral girdle consists of a flat triangular scapula with a glenoid cavity for articulating with the humerus, a cartilaginous supra-scapula and the clavicle which connects the supra-scapula to the sternum. The scapula has a long bony ridge dorsally, called the spine. It terminates in an overhanging process the acromion. Another process that projects inwards is called the coracoid.

The upper extremity of the humerus articulates with the glenoid cavity of the scapula and has two tubercles between

which is a groove for the tendon of the biceps muscle. The lower extremity or the trochlea, articulates with the radius and the ulna, and is pierced through by the supra-trochlear foramen which joins the fossa in front, and the olecranon fossa, behind. The bones of the fore-arm, the radius and the ulna, are distinct but closely united, the ulna is prolonged above in the coronoid process, and with the radius articulates with the trochlea of the humerus. Below these the carpal bones, which are arranged in two rows, articulate with the bones of the wrist. The first row of carpal bones consists of the radiale (scaphoid) the intermedium (lunar) and the ulnare (cuneiform) along with a centrale and a small pisiform; the second row consists of the trapezium, the trapezoid, the os magnum and the unciform. The manus or hand consists of five metacarpal bones each of which bears a digit; the first digit has two phalanges and the rest three. The digital formula is 23333.

The pelvic girdle consists of a symphysis, the pubis, ventrally, which by uniting with the ischium encloses a foramen, the obturator foramen. The ilia are elongated caudally and form the greater part of the acetabulum and articulate with the sacrum. The acetabulum is formed mainly of the ilium and the ischium and to some extent of the pubis. The femur is a long bone with a shaft and two extremities; the upper extremity has a head for articulation with the acetabulum and three trochanters for the attachment of muscles. The lower extremity has two condyles for articulation with the tibia. The patella is a small bone developed in the tendon of the extensor muscles of the legs; such bones which develop in the tendon of muscles are called sesamoid bones. Behind the knee joint are small sesamoid bones known as the fabella. The tibia and fibula join distally and articulate with the astragalus and the calcaneum. The tarsus consists of two rows of tarsal bones, the proximal row consisting of the astragalus medially and the calcaneum laterally; the latter is prolonged

behind to form a heel. The distal row consists of the navicular and the cuboid. The navicular has the three cuneiform bones in front. The pes or foot consists of the four metatarsals each having a digit with three phalanges. The first metatarsal and its digit are absent and the digital formula is 03333.

*The Muscular System.* The flexor and the extensor muscles of the back, the masseters of the jaw and the muscles of the hind limbs are well developed. The plantaris muscle of the foot is large and has a tendon about the size of the tendo-achilles of the gastrocnemius.

*The Nervous System. Dissection.* Remove the roof and the side of the skull carefully by means of a bone forceps. Cut through the dura-mater and expose the brain, then lift the posterior part of the brain and cut the distal portion of the spinal cord. Raise the brain still further and divide the various nerves that lie close to the skull. Having thus separated the brain, harden it for a few days in a dilute solution of formalin.

The brain is invested by a thin membrane, the pia mater and is covered with a tough dura mater. The hemispheres of the brain are large and are connected together by means of a transverse band, the corpus callosum. A pair of olfactory lobes project from underneath the cerebrum. The thalamencephalon and the corpora quadrigemina or the optic lobes are covered by the cerebral hemispheres. The cerebellum situated below the hemispheres is of a large size and below the cerebellum is the medulla oblongata which is continuous with the spinal cord. The pineal body is situated above the thalamencephalon and the pituitary is attached to the infundibulum below. The optic thalami are situated on either side. Twelve pairs of nerves arise from the brain, ten of which have been already discussed while dealing with the nervous system of the frog. The tenth or vagus nerve is interesting as it gives off a superior laryngeal nerve

to the trachea, a depressor nerve to the heart, and a recurrent laryngeal. This last arises in the root of the neck and hooks round the subclavian artery on the right side and the ductus arteriosus on the left and proceeding forward supplies the muscle of the larynx. The eleventh or the accessory nerve lies near the vagus, and is a motor nerve supplying some of the muscles of the neck. The twelfth or the hypoglossal nerve lies next to the accessory nerve and supplies the muscles of the tongue and some of the muscles of the neck. The spinal nerves are distributed to the skin and muscles of their respective segments; they are about thirty seven in number. Eight of these are cervical, twelve thoracic, seven lumbar, four sacral, and six coccygeal. The third cervical nerve sends a large branch, the great auricular nerve, to the ear. A branch of the fourth after receiving a branch from the fifth and the sixth forms the phrenic nerve which runs backwards along the precaval vein and the heart and supplies the diaphragm. The fifth, sixth, seventh and eighth cervical nerves together with the first thoracic form the branchial plexus from which the nerves of the upper extremity take origin. The last four lumbar and the first sacral nerves unite to form a lumbo-sacral plexus which supplies nerves to the hind limb.

The sympathetic nerve is a ganglionated cord lying between the vagus and the accessory in the neck and along the vertebral column lower down. It supplies the heart, vessels and viscera and communicates with the accessory nerve and the vagus.

*The Sense Organs.* Although the structure of all the nerves is the same each nerve has a definite sensation to convey, and it does so irrespective of the stimulation that it receives. The optic nerve furnishes a good illustration as it carries the sensation of light when light plays upon it, a blow be administered to the eyeball or the nerve be cut with a pair of surgical scissors.

A nerve is usually given out of a cell, and a nerve cell with all its processes is called a neuron. One of the processes in nerves carrying sensations is modified according to the particular impulse it has to translate and the other is a conducting process which conducts the impulse to the brain either directly or by means of other connecting neurons.

The nerves of special sense are the olfactory, the optic, the auditory and the glossopharyngeal nerves.

Sensation is conveyed by sensory nerves which arborise round the base of the cell of the epithelium and sometimes develop into a special structure called the touch corpuscle.

Smell is carried by special nerve endings into the nasal mucous membrane by the olfactory nerve.

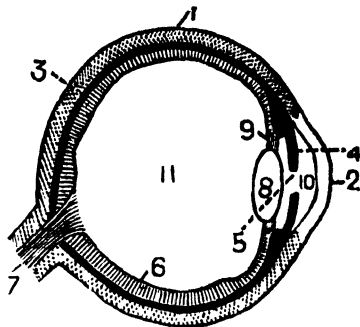


FIG. 54. EYE OF RABBIT. (Diagrammatic).

1. Sclerotic, 2. Cornea, 3. Choroid, 4. Iris, 5. Pupil, 6. Retina, 7. Optic nerve, 8. Lens, 9. Suspensory ligament, 10. Anterior chamber, 11. Posterior chamber.

*Sight.* The eye or the organ of sight is more or less globular and consists of three coats. The outer coat is the sclerotic which is white, tough and fibrous and covers the eyeball; it extends behind as the sheath of the optic nerve and forms the transparent cornea in front. The second coat is the choroid; it is pigmented and vascular and forms the iris in front, which is perforated by the pupil. The third layer which is the retina lines the posterior three-fourths of the eye and consists of the nervous elements, the rods and cones, which are special nerve endings for sight. From the retina the nerve

fibres emerge behind and form the optic nerve. The crystalline lens is situated just behind the iris and is supported by means of a fibrous structure called the suspensory ligament. In front of the lens is a cavity, the anterior chamber, which is full of the aqueous humour and behind it is the posterior chamber with the vitreous humour.

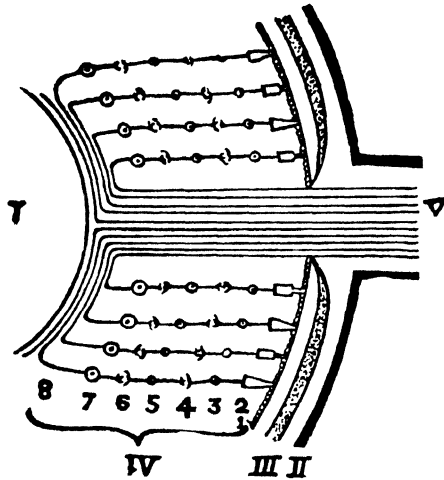


FIG 55. DIAGRAM OF RETINA.

I. Posterior Chamber. II. Sclerotic, III. Choroid, IV. Retina.  
V. Optic Nerve.

1. Pigment layer, 2. Layer of rods and cones, 3. Outer nuclear layer, 4. Outer molecular layer, 5. Inner nuclear layer, 6. Inner molecular layer. 7. Layer of nerve cells, 8. Layer of nerve fibres.

The retina has three sets of neurons, the layers of rods and cones, the layer of bipolar cells and the inner layer of nerve cells, which together constitute eight visible bands called (1) the pigment layer into which the rod and cones dip, (2) the layer of rods and cones, which is the layer that translates the impulse of light, (3) the outer nuclear layer which shows the nuclei of the rod and cone cells, (4) the outer molecular layer which shows the arborization of the processes of the rod and cone cells and the bipolar cells, (5) the inner nuclear layer which shows the nuclei of the bipolar cells (6) the inner molecular layer consisting of the arborization of the

processes of the bipolar cells and those of the nerve cells (7) the layer of nerve cells, (8) the layer of nerve fibres which consist of processes of the nerve cells that go out to form the optic nerve. The rays of light pass through the cornea, the pupil and the lens on to the retina where it gets translated and then the impulse is carried on to the brain by means of the optic nerve.

*Hearing.* The ear of the rabbit is divisible into three parts, the external, the middle and the internal ear. The external ear is the largest but the least important as regards function. It consists of a very large pinna and an auditory canal ; the first collects the air waves and the second conducts them to the tympanic membrane which is stretched tightly across the middle ear. The middle ear or tympanum is a conducting chamber and contains three bony ossicles, the malleus, the incus, and the stapes. The malleus is attached to the tympanic membrane on one side and is connected to the incus on the other, the incus is attached to the stirrup shaped stapes which is itself attached to a small opening in the internal ear, thereby communicating the vibrations from the tympanic membrane to the fluid in the internal ear which moves and stimulates the nerve endings there ; these translate the impulses and send them across to the brain through the auditory nerve. The internal ear or the labyrinth, is a membranous structure enclosed in the periotic bone. It consists of the saccule or the organ of hearing which has a coiled outgrowth called the cochlea. This joins another sac the utricle by means of a Y-shaped tube. The utricle is the organ of orientation which keeps the animal informed of its sense of position and this has three semicircular canals at right angles to each other, and contains a fluid that moves with the movements of the animal and stimulates the particular nerve endings. The impulse is carried to the brain by means of the auditory nerve.

*Taste.* The organ of taste is formed by the epithelium of the tongue collecting together in small groups called papillæ. There are two large papillæ, one on each side of the tongue behind, called the foliate papillæ and a series of round papillæ behind the tongue known as the circumvallate papillæ; nerve fibres emerge from these and pass through the glossopharyngeal nerve to the brain.

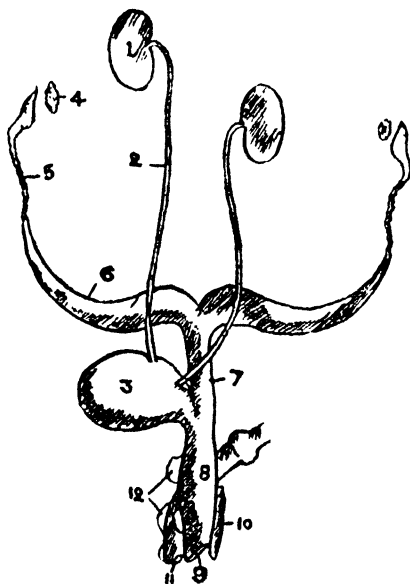


FIG. 56. UROGENITAL SYSTEM OF FEMALE RABBIT.

1. Kidney, 2. Ureter, 3. Bladder, 4. Ovary, 5. Fallopian tube, 6. Uterus, 7. Vagina, 8. Vestibule. 9. Vulva, 10. Clitoris, 11. Anus, 12. Glands.

*The Urinary System.* The kidneys are a pair of elongated bodies situated on each side of the vertebral column in the abdomen. A narrow duct, the ureter, proceeds backwards from each kidney and opens in the urinary bladder where the urine is collected and voided at intervals through the urethra. The structure of the kidney consists of an outer cortex and an inner medulla. Just at the point where the ureter emerges from the kidney there is a large cavity called the pelvis. The kidney consists of a conglomeration of

secretory tubules which open into the pelvis at one end, and at the other, end blindly and come in contact with the capillaries. The tubules start from a round structure called the glomerulus where the capillaries are covered with the epithelium through which the watery portion of the blood is filtered. The tubules by themselves perform a selective function and remove the urea and salts from the blood. A solution of the urea and salts in water from the glomerulus forms urine and this is sent into the bladder at regular intervals.

*The Reproductive System.* In the male the testes lie in the abdomen just near the kidney at an early stage of life. When however the animal attains maturity the testes get pushed back through the inguinal canal into the scrotum and get fixed there by means of a fibrous cord the *gubernaculum*. Even then the testes can be pulled back into the abdomen. The testis measures about an inch in length and on its lateral side is found the epididymis which is a series of tubules, having two parts, the *caput epididymis* in front and the *cauda epididymis* behind. From the *cauda epididymis* a duct, the *vas deferens*, passes through the inguinal canal into the abdomen and in company with the spermatic artery and veins forms the spermatic cord. This cord forms a loop over the ureter in the abdomen and passing behind the bladder opens into a median sac, the *uterus masculinus*. This sac opens into the urethra which runs through the penis. The prostate glands are situated on the side of the *uterus masculinus* while the Cowper's glands are situated a little behind. The penis is situated behind the pubis and is covered over by a fold of skin, the *prepuce*. The perineal glands are situated on each side of the anus.

In the female the ovaries are situated behind the kidneys. Opposite each ovary is an oviduct with a wide mouth to receive the ova. The oviduct is divided into three parts,

the narrow Fallopian tube, the uterus on each side opening separately into the third portion, the vagina which is a single structure and opens into the vestibule into which the bladder also opens and forms a short urogenital canal. This canal opens externally into the vulva. On the ventral side of this is a small rod-like body, the clitoris, which is homologous to the penis of the male. The Cowper's and the perineal glands are situated behind the vestibule on either side.

The ovary is studded on its surface with clear projections called the Graafian follicles which enclose the ova. When mature the Graafian follicle bursts and the ovum is carried through the mouth of the oviduct into the Fallopian tube. If the ovum is fertilised it develops in the uterus and becomes connected with it by means of a placenta which provides the embryo with the requisite nutrition by means of its vascularity.

*The Ductless Glands.* The majority of the glands such as the salivary glands possess ducts through which they pour out their secretions. Some glands, however, not possessing ducts pour their secretions which are called hormones directly into the blood and control various functions such as metabolism. The more important ductless glands are the pituitary situated under the brain, the thyroid in the neck, the thymus in the upper thoracic region and the adrenal lying in front of the kidney. There are other glands such as the testes, the ovaries and the pancreas which have a combined function and which use both the direct and the indirect routes of pouring in their secretions. The ductless glands form a most elaborate and perfect system which is of vital importance to the development of animal life.



# INDEX

- Abdomen cockroach, 46  
    " larva, 59  
Acetabulum, 82, 111, 127  
Acromian, 124  
Adrenal, 94, 95, 113, 116  
After-shaft, 102  
Air cavities, 108  
Ala spuria, 101  
Alimentary canal, 59  
Alimentary system, 24, 116  
Alisphenoid, 124  
Amœba, 8, 9  
Amphibia, 62  
Amphicœlous, 76  
Amphioxus, 91  
Amylase, 66  
Anabolism, 6  
Angular, 109  
Angulo-splenic, 79  
Annelida, 20  
Anopheles, 51, 58  
Antenna, 32, 39, 41, 42, 44, 53, 59  
Antennule, 32, 39, 41  
Anura, 62  
Anus, 24, 57, 59, 110, 118  
    " potential, 13  
Aorta, 106, 121  
    " dorsal, 71, 106  
    " abdominal, 116  
Aperture, auriculo-ventricular, 68  
Apodeme, 29  
Appendages, 31  
Aqueous humour, 92, 131  
Arachnida, 29  
Arch, aortic, 120  
    " branchial, 98  
    " hyoid, 98  
    " mandible, 98  
    " pulmonary, 120  
    " visceral, 98  
Archenteron, 41, 97, 98  
Arteries, 69, 70  
    " frog, 70, 71  
    " palinurus, 35, 36  
    " pigeon, 106, 107  
    " rabbit, 121, 122  
Arterioles, 36, 121  
Arthropoda, 29  
Articular, 76, 109  
Aster, 8  
Astragalus, 127  
Astragalo-calcaneous, 82  
Atlas, 76, 108  
Atrophy, 82  
Auditory apparatus, 93  
    " bulla, 124  
    " capsule, 93  
    " meatus, 124  
    " tube, 93  
Auricle, 68, 93, 106, 111  
Aves, 100  
Axon, 89, 90  
Barb, 102  
Barbule, 102  
Basicerite, 33  
Basignathite, 33  
Basi-occipital, 109, 123  
Basipodite, 31  
Basi-sphenoid, 124  
Beak, 100  
Bile, 66  
Bile duct, 118  
Birds, 100  
Bladder, 94, 116, 133  
Blastoderm, 41  
Blastopore, 41, 97  
Blind spot, 92  
Blood, 73, 123  
Blood vessels, 69  
Bone, carpal, 82, 110, 127  
    " hyoid, 125  
    " metacarpal, 81, 127  
    " metatarsal, 83, 128  
    " sesamoid, 127  
    " tarsal, 83, 127  
Brachial plexus, 89, 129  
Brain, amphioxus, 91  
    " fish, 91  
    " frog, 87, 91  
    " larva, 60  
    " pigeon, 111  
Branchiocardiac vessel, 36  
Branchiostegite, 29  
Bronchi, 108  
Bulbus arteriosus, 68  
Buccal cavity, 48, 103, 115  
Cæca, 24, 48  
Cæcum, 118  
Calamus, 101  
Calcaneum, 127  
Calcar, 83  
Calciferous glands, 24  
Canal, auditory, 132  
    " semicircular, 93  
Capillaries, 36, 121  
Carapace, 29

## ELEMENTS OF ZOOLOGY

- Cardia, 37, 116  
 Cardio, 45.  
 Carpo-metacarpal, 110  
 Carpodite, 32  
 Carpals, 110.  
 Cartilage, bone, 78  
 Cavity Buccal, 103  
   ,, cœlomic, 15, 97  
   ,, tympanic, 109  
 Cell, 6, 17  
   ,, bipolar, 92  
   ,, olfactory, 94  
   ,, spherical, 93  
   ,, wall, 8  
 Central nervous system, 86  
 Centrale, 127  
 Centrosome, 7  
 Centrosphere, 7  
 Centrum, 75, 108  
 Cephalothorax, 29  
 Cerci, 46  
 Cere, 100  
 Cerebellum, 88, 91, 110, 128  
 Cerebral hemispheres, 87, 111  
   ,, vesicle, 90  
 Cervical groove, 29  
 Chitin, 29, 49  
 Chlorella vulgaris, 19  
 Chondrocranium, 78  
 Chordæ tendineæ, 68, 120  
 Choroid, 92, 130  
   ,, plexus, 87  
 Chromatin, 7, 10  
 Chromosomes, 8  
 Chrysalis, 61  
 Cilia, 13  
 Cingulum, 21  
 Circulation, 69, 131  
 Circulatory system, cockroach, 47  
   ,, ,, frog, 67  
   ,, ,, mosquito, 57  
   ,, ,, pigeon, 106  
   ,, ,, rabbit, 112  
 Classes, 1  
 Clavicle, 80, 110, 126  
 Clitellum, 21  
 Clitoris, 135  
 Cloaca, 94, 99, 100, 113  
 Clypeus, 43, 52, 59  
 Cnidoblast, 17  
 Cochlea, 93, 112  
 Cockroach, 42  
 Cocoon, 26  
 Cœlenterata, 15  
 Cœlom, 15, 100  
 Cœlomata, 20  
 Columba, 80, 109  
 Colon, 49, 118  
 Columella, 80, 109, 112  
 Commissure, para-œsophageal, 39, 50  
 Conus, arteriosus, 68  
 Condyle, 109, 124, 125  
 Conjugation, 11, 14  
 Contour, feathers, 101  
 Contractile, layer, 13  
   ,, vacuole, 10, 13  
 Coracoid, 80, 110, 126  
 Cornea, 92  
 Cornu, 100  
 Coronary process, 125  
 Corpora quadrigemina, 128  
 Corpus, callosum, 114, 128  
 Corpuscles, red, 73, 123  
   ,, touch, 130  
   ,, white, 73, 123  
 Costa, 55  
 Coverts, 101  
 Coxa, 55  
 Coxocerite, 33  
 Coxognathite, 33  
 Coxopodite, 31  
 Crop, 24, 48, 103  
 Crustacea, 29  
 Cuboid, 127  
 Culex, 51, 52, 56  
 Cuneiform, 127  
 Cuticle, 27  
 Cyclostomata, 62  
 Cyst, 10  
 Cytoplasm, 6  
 Dactilopodite, 32  
 Darwin, 4, 5  
 Deltoid ridge, 81  
 Dendrons, 90  
 Dentary, 79, 109  
 Dermis, 27  
 Development, 89  
 Dextrose, 119  
 Diaphragm, 66, 114, 123  
 Diaster, 8  
 Diastema, 115  
 Diastole, 121  
 Digestion, 119  
 Digestive system, cockroach, 48  
   ,, ,, earthworm, 24  
   ,, ,, frog, 66  
   ,, ,, mosquito, 56  
   ,, ,, palinurus, 36  
   ,, ,, pigeon, 103  
   ,, ,, rabbit, 116  
 Digital formula, 81, 111, 128  
 Digits, 110  
 Diploblastica, 1, 15

## INDEX

- Diptera, 51  
 Dorsal pore, 27  
 Duct, bile, 118  
   " common bile, 67  
   " duodenum, 105  
   " ejaculatory, 50, 57  
   " endolymphatic, 93  
   " genital, 67  
   " hepatic, 37, 67  
   " pancreas, 67, 105, 119  
   " salivary, 54  
   " thoracic, 123  
   " Wolfian, 94  
 Ductless glands, 95, 135  
 Ductus arteriosus, 121  
 Duodenum, 66, 103, 118  
 Dura mater, 128  
  
 Ear, external, 92, 93, 132  
   " internal, 93, 112, 132  
   " middle, 93, 125, 132  
 Earthworm, 20  
 Ecdysis, 29  
 Ectoderm, 1, 15, 17, 97  
 Ectoplasm, 10, 12, 13  
 Efferent branchial vessels, 36  
 Egg boats, 38  
 Elytra, 46  
 Embryo, 18  
 Endocerite, 33, 52  
 Endoderm, 1, 15, 97  
 Endognathite, 33, 45  
 Endolymph, 93  
 Endophragmal system, 29  
 Endoplasm, 10, 12  
 Endopodite, 32, 45  
 Endoskeleton, 75  
 Enteron, 15  
 Epiblast, 41, 56, 97  
 Epicranium, 43, 52  
 Epidermis, 27  
 Epicoracoid, 81  
 Epididymis, 134  
 Epimeron, 31  
 Epiphysis, 108  
 Epipodite, 33  
 Episternum, 28, 51  
 Epithelial cells, 17  
 Eustachian aperture, 34, 101, 115  
   " tube, 93  
 Evolution, 3  
 Excretory system, cockroach, 49  
   " " earthworm 25  
   " " frog, 94  
   " " palinurus, 37  
   " " pigeon, 112  
 Ex-occipital, 79, 109, 123  
  
 Exocerite, 33, 52  
 Exognathite, 45  
 Exopodite, 32, 45, 96  
 Exoskeleton, 75, 100  
 Expiration, 57, 74  
 Extensor muscles, 35  
 External features, frog, 63  
   " " pigeon, 100  
   " " rabbit, 114  
 Eye, cockroach, 44, 50  
   " frog, 91  
   " mosquito, 58, 59  
   " pigeon, 100, 101, 112  
   " rabbit, 114, 124, 130  
 Eyelid, 112  
  
 Fabella, 127  
 Facial nerve, 88  
   " region, 109  
 Fæces, 120  
 Fallopian tube, 134  
 Fat-body, 95  
 Fatty acids, 66  
 Feeding brushes, 59  
 Femur, 46, 55, 82, 111, 127  
 Fenestra, 43, 50  
   " ovalis, 93, 109  
 Ferments, 66  
 Fertilisation, 26  
 Fibula, 111, 127  
 Filaria bancrofti, 51  
 Fishes, 62  
 Fission, 7  
 Fissures, 91  
 Flexor muscles, 35  
 Foam theory, 7  
 Fontanelle, 79  
 Food, 10, 17, 21, 37  
 Foot, 128  
 Foramen, interventricular, 87  
   " magnum, 109, 123  
   " orbital, 127  
   " supratrochlear, 126  
   " triosseum, 109, 110  
 Forearm, 127  
 Fore-brain, 90  
 Fore-limb, 112  
 Frog, 62  
 Frontal bone, 124  
 Frontoparietal, 79  
  
 Galea, 45  
 Gall bladder, 67, 118  
 Ganglia, Bidder's 69  
   " Remack's 68  
   " Supra-pharyngeal, 39  
   " sympathetic, 39

## ELEMENTS OF ZOOLOGY

- Ganglia, thoracic, 39  
 Gastrula, 41  
 Gena, 44, 52  
 Germinal layer 41  
   " spot, 26  
   " vesicle, 26  
 Gill, 37, 98  
 Girdle, pectoral, 110  
   " pelvic, 115  
 Gizzard, 24, 36, 48, 100, 103  
 Glands, 66  
   " accessory, 50  
   " cement, 58  
   " cowper's, 134  
   " ductless, 95, 135  
   " green, 33, 37  
   " infra-orbital, 115  
   " lachrymal, 115  
   " mammary, 115  
   " parotid, 115  
   " perineal, 114, 115, 134, 135  
   " preen, 100  
   " prostate, 134  
   " salivary, 56, 59, 115  
   " sebaceous, 115  
   " sublingual, 115  
   " submaxillary, 115  
   " sweat, 114  
 Glenoid cavity, 81, 125, 126  
 Glomerulus, 94, 134  
 Glossa, 45  
 Glottis, 74, 101, 115  
 Glycerine, 66  
 Glycogen, 118  
 Gonads, 40  
 Gonapophysis, 50, 51, 53, 55  
 Graafian follicle, 135  
 Gubernaculum, 134  
 Gullet, 101  
 Gymnophiona, 62  
  
 Hæmocœle, 40  
 Hæmocyanine, 36  
 Hæmoglobin, 24, 73  
 Hair, 126  
 Halteres, 54, 55  
 Halux, 83  
 Hand, 127  
 Harelip, 114  
 Head, larva, 59  
 Hearing, 132  
 Heart, 36, 67, 106, 116, 120  
 Hearts, 24  
   " lymph, 74  
 Hemispheres, 90, 111, 128  
 Hepatic cœca, 59  
 Hepatopancreas, 37  
  
 Heredity, 3  
 Hermaphrodite, 17, 21  
 Heterocœlous, 107  
 Hibernation, 63  
 Hindbrain, 90  
 Hindgut, 52, 57  
 Hindlimb, 111  
 Hormones, 135  
 Humerus, 81, 110, 126  
 Hydra, 15  
 Hyoid, 79, 109, 125  
   " apparatus, 125  
 Hypapophysis, 125  
 Hypoblast, 41, 97  
 Hypopharynx, 54  
 Hypostome, 16  
  
 Ileum, 67  
 Iliac, 82, 111, 127  
 Ilium, 49, 66, 67  
 Imago, 61  
 Incisors, 125  
 Incus, 125  
 Infraneural vessel, 24  
 Infundibulum, 87, 111, 128  
 Infusoria, 12  
 Insecta, 29, 42  
 Insertion, 83  
 Inspiration, 57, 74  
 Involuntary muscles, 83  
 Integument, 27  
 Intermedium, 127  
 Interparietal, 124  
 Interstitial cells, 17  
 Intestine, 24, 116  
   " large, 67  
   " small, 66  
 Invertebrata, 2  
 Iris, 92, 130  
 Ischiopodite, 32  
 Ischia, 82, 111, 127  
 Iter, 88, 90, 112  
  
 Jaw, 115.  
 Junction, Sclero-corneal, 112  
  
 Karyokinesis, 7  
 Katabolism, 6  
 Keel, 100  
 Kidney, 33, 94, 112, 116, 133  
  
 Labial, palp, 46  
 Labium, 44, 54, 59, 116  
 Labrum, 36, 54, 59  
 Labyrinth, 93, 132  
 Lachrymal, 115  
 Lacinia, 45

## INDEX

- Lamarck, 5  
 Larva, 51, 59, 60  
 Laryngo-tracheal chamber, 74  
 Lateral neural vessel, 24  
 Layers of retina, 131, 132  
 Legs, 54  
 Lens, 92, 112, 131  
 Lepus, 114  
 Ligula, 46  
 Lipase, 66  
 Liver, 67, 105, 116, 118  
 Lobopods, 7.  
 Lumbosacral plexus, 89, 129  
 Lunar, 127  
 Lungs, frog, 74  
   "  pigeon, 108  
   "  rabbit, 116, 123  
 Lymph hearts, 74  
 Lymphatic system, 73, 123  
  
 Macronucleus, 13  
 Malaria, 51  
 Malleus, 125, 132  
 Malpighian tubes, 42, 44, 57, 59  
 Mammalia, 62, 114  
 Mandible, 42, 44, 45, 53, 54, 59, 125  
 Manus, 125  
 Maxillæ, 42, 44, 45, 53, 54, 59, 79, 125  
 Maxilliped, 34.  
 Meatus, external auditory, 93, 101  
   112  
 Mechanism of respiration, 123  
 Meckel's cartilage, 79, 98  
 Medulla oblongata, 88, 111, 128  
 Membrane bone, 78  
 Membrana nictitans, 100  
 Mental plate, 59  
 Mentomeckelian, 79  
 Meropodite, 32  
 Mesenteron, 48, 56  
 Mesentry, 116  
 Mesethmoid, 124  
 Mesoblast, 41, 97, 98  
 Mesoderm, 2  
 Mesogloea, 15 17  
 Mesonotum, 46, 54  
 Mesosternum, 81  
 Mesothorax, 42, 46, 54  
 Metabolism, 6  
 Metanotum, 46, 54  
 Metacarpals, 81, 127  
 Metameris, 21  
 Metamorphosis, 99  
 Metastoma, 33, 36  
 Metatarsals, 83, 111, 128  
 Metathorax, 42, 46, 54  
 Metazoa, 1, 15  
  
 Micronucleus, 14  
 Midbrain, 90  
 Midgut, 56  
 Milk, 114  
 Mitotic, 7  
 Modification, 32  
 Molars, 125  
 Morphology, 91  
 Morula, 19  
 Mosquito, 51  
 Mouth, 16, 56, 66, 100  
 Muscles, cardiac, 68  
   "  cockroach, 49  
   "  eye, 92  
   "  frog, 65, 83, 84, 85, 86  
   "  papillary, 120  
   "  pigeon, 102  
   "  rabbit, 128  
 Muscular, layer, 28  
 Muscular system earthworm, 23  
   "  "  frog, 83  
   "  "  palinurus, 35  
   "  "  pigeon, 111  
   "  "  rabbit, 128  
 Myoneme threads, 13  
  
 Nares, 63, 64  
 Nasal, 79, 124  
 Natural selection, 4  
 Navicular, 127  
 Nematocyst, 17  
 Nephridia, 8, 25, 28, 37  
 Nephropore, 24  
 Nephrostome, 24  
 Nerves, cranial, 88, 94, 130  
   "  frog, 88, 89  
   "  pigeon, 111  
   "  rabbit, 128  
 Nerve cells, 39  
 Nervous system, cockroach, 49  
   "  "  earthworm, 23  
   "  "  frog, 86  
   "  "  mosquito, 57  
   "  "  palinurus, 37  
   "  "  pigeon, 111  
   "  "  rabbit, 128  
 Nervures, 55  
 Neural arch, 76  
   "  folds, 87, 97  
   "  groove, 97  
   "  vessels, 24  
 Neurenteric canal, 98  
 Neuron, 129  
 Nictitating membrane, 100, 112  
 Notochord, 97, 98  
 Nourishment, 73, 74  
 Nucleohyaloplasm, 7

## ELEMENTS OF ZOOLOGY

- Nucleoli, 7 10, 95  
 Nucleus, 7, 95  
  
 Occipital foramen, 44  
 Odontoid 108  
 Œsophagus, 24, 37, 48, 54, 57, 66  
     102, 104, 116  
 Olecranon fossa, 81  
 Olfactory lobes, 111, 128  
 Ommatidia, 39  
 Omosternum, 81  
 Optic chiasma, 112, 128  
     ,, lobe, 87, 90  
     ,, tract, 128  
 Oral groove, 13  
 Orbito-sphenoid, 124  
 Orbits, 109, 124  
 Orders, 1  
 Organ, auditory, (hearing), 39, 92, 93  
     ,, Jacobson, 115  
     ,, smell, 94  
     ,, special sense, 39  
 Origin, 83  
 Orthoptera, 42  
 Os magnum, 127  
 Ossicles, 37, 93  
 Ostia, 35, 38  
 Otic capsule, 80  
 Otoliths, 33, 93  
 Ovary, 17, 18, 26, 50, 58, 94, 112  
     134, 135  
 Oviduct, 50, 58, 95, 112, 134  
 Ovipositors, 58  
 Ovum, 18, 26, 41, 95  
  
 Palate, 115  
 Palatine, 79  
 Palatopterygoid, 98  
 Palinurus, 29  
 Palmate hair, 59  
 Palpiger, 46  
 Pancreas, 105, 118, 135  
 Pancreatic secretion, 66  
 Panniculus carnosus, 115  
 Papillæ, 59, 133  
 Paraglossa, 45  
 Para-œsophageal commissure, 39  
 Paramœcium, 12  
 Para-sphenoid, 79  
 Parietal, 109, 124  
 Patella, 127  
 Pecten, 112  
 Pectoral girdle, 110  
 Pellicle, 13  
 Pelvic girdle, 82, 111, 127  
 Pelvis, 133  
 Penis, 57, 115, 184  
 Pepsin, 66  
  
 Peptones, 66  
 Pericardium, 35, 47, 48, 67, 106, 116  
     120  
 Perichœta, posthuma, 20  
 Perilymph, 93  
 Peri-otic, 124  
 Peripheral nervous system, 86  
 Periplanata americana, 42  
 Peritoneum, 116  
 Pes, 128  
 Peyer's patch, 118  
 Phalanges, 81, 83, 127, 128  
 Pharynx, 24, 56, 115  
 Phyla, 1  
 Phyllosoma, 41  
 Pia mater, 87, 128  
 Pigment, cell layer, 92  
 Pineal, 87, 111, 128  
 Pinna, 100  
 Pisces, 62  
 Pisiform, 127  
 Pituitary, 87, 111, 128  
 Placenta, 135  
 Plasma, 109, 123  
 Pleopods, 35  
 Pleura, 108, 116, 123  
 Pleuron 30  
 Pleuro-peritoneal cavity, 66  
 Podical plates, 46  
 Polar bodies, 95  
 Pore, dorsal, 21  
 Post caval vein, 122  
 Precaval vein, 122  
 Precoracoid, 80  
 Premaxilla, 79, 125  
 Prepuce, 134  
 Primaries, 101  
 Primitive gut, 41, 97  
     ,, vertebrates, 62  
 Proboscis, 54, 61  
 Process, articular, 76  
     ,, spinous, 76  
     ,, transverse, 76  
 Proctodœum, 48, 49, 98  
 Pronotum, 46, 54  
 Pronucleus, 95  
 Pro-otic, 79  
 Propodite, 32  
 Prostomium, 21  
 Proteins, 66  
 Prothorax, 42, 46, 54  
 Protocerite, 32  
 Protognathite, 33, 45, 54  
 Protoplasm, 1, 9  
 Propodite, 31  
 Protozoa, 1, 9  
 Proventriculus, 103  
 Pseudopodia, 9

## INDEX

- Pterygoid, 79  
 Ptyalin, 119  
 Pubis, 82, 127  
 Pulmo-cutaneous arch, 68  
 Pulvillus, 46  
 Pupa, 61  
 Pupil, 92, 130  
 Pygostyle, 109  
 Pylangium, 68  
 Pylorus 37, 116  
  
 Quadro-jugal, 79  
 Quill, 101  
  
 Rachis, 101  
 Radio-ulna, 81  
 Radius, 110, 127  
 Radiate, 127  
 Rana, 62  
 Rectrices, 101  
 Rectum, 49, 118  
 Rejuvenation, 11  
 Remiges, 101  
 Reproduction, 11, 18  
 Reproductive system, cockroach, 50  
     "    "    earthworm, 25  
     "    "    frog, 94  
     "    "    mosquito, 57  
     "    "    palinurus, 40  
     "    "    pigeon, 114  
     "    "    rabbit 134  
 Respiration, 25, 74  
 Respiratory system, cockroach, 49  
     "    "    earthworm, 25  
     "    "    frog, 74.  
     "    "    mosquito, 57  
     "    "    palinurus, 37  
     "    "    pigeon, 108  
     "    "    rabbit, 123  
 Respiratory trumpets, 61  
 Retina, 92, 130, 131  
 Rhabdom, 39  
 Rhizopoda, 9  
 Ribs, 108, 126  
 Rods and cones, 92, 131  
 Rostrum, 30, 109  
  
 Sacculus rotundus, 118  
 Saccule, 93, 132  
 Sacrum, 111  
 Salivary glands, 48  
 Scaphognathite, 33  
 Scaphoid, 127  
 Scapula 80, 110, 126  
 Sclerotic, 92, 130  
 Sclerotic plates, 112  
 Sebum, 114  
 Secondaries, 101  
  
 Segment, ethmoid, 124  
     "    occipital, 123  
     "    sphenoid, 124  
 Semicircular canal, 93  
 Semen 58  
 Seminal duct, 26  
 Seminal vesical, 113  
 Sense organs, frog, 91  
     "    "    pigeon, 112  
     "    "    rabbit, 129  
 Septum, 109  
 Sesamoid bones, 127  
 Setæ 21, 27, 48  
 Sexual selection 4  
 Shoulder girdle, 80  
 Sight, 130  
 Sinus, subcutaneous, 73  
     "    venosus, 68, 71  
 Skeletal system, frog, 75  
     "    "    pigeon, 108  
     "    "    rabbit, 123  
 Skin, 75, 116  
 Skull, 78, 109, 122  
 Slipper animalcule, 12  
 Smell, 130  
 Snout, 54  
 Somatic, 98  
 Somites, 21  
 Spawn, 95  
 Species, 4  
 Spermathecæ, 26, 51, 58  
 Spermatic cord, 113  
 Spermatozoa, 19, 26, 95  
 Sphenethmoid, 79  
 Sphincter, 118  
 Spiders, 29  
 Spinal, cord, 111  
 Spine, 126  
 Spleen, 95  
 Splenial, 109  
 Spongy layer, 13  
 Sporozoites, 56  
 Squamosal, 79, 125  
 Stapes, 132  
 Starch, 66  
 Statocyst, 32  
 Stegomyia, 51, 52, 59  
 Sternal sinus, 36  
 Sternum, 30, 126  
 Stomach, 36, 66, 103, 116  
 Stomodæum, 36, 48, 98  
 Streak, primitive, 97.  
 Stylopyga orientalis, 42  
 Stipes, 45  
 Subcutaneous lymph space, 75  
 Sub-oesophageal ganglion, 19, 50  
 Sugars, 37  
 Sulci, 91

## ELEMENTS OF ZOOLOGY

- Suppression, 82  
 Supra-angular, 109  
 Supraneural vessel, 24  
 Supra-occipital, 109, 124  
 Supra-œsophagonal ganglion, 39, 49  
 Suprascapular 80, 126  
 Sweat, 114  
 Swimmerets, 35  
 Symbiosis, 19  
 Symphysis, 82, 109, 111  
 Sympathetic system, 86, 89  
 Synangium, 68  
 Synsacrum, 109  
 Syrinx, 108  
 Systemic, 68  
 Systole, 121
- Tadpole, 98  
 Tail, 100  
 Tarsus, 55  
 Taste, 132  
 Teats, 115  
 Teeth, 48  
 Telson, 30  
 Tendo achilles, 85  
 Tentacles, 16, 17  
 Tergum, 30  
 Testes, 50, 57, 94, 113, 134, 135  
 Testis, 17, 25, 57  
 Thalamencephalon, 87, 128  
 Thorax, 46, 54, 59, 116  
 Thymus, 95, 116, 139  
 Thyroid, 95, 135  
 Tibia, 46, 55, 111, 127  
 Tibio-fibula, 82  
 Tongue, 64, 101, 115  
 Touch, 93  
 Trachea, 109  
 Tracheæ, 42, 49, 57  
 Transverse process, 109  
 Trapezium 127  
 Trapezoid, 127  
 Trichocyst layer, 3  
 Triploblastica, 1, 2, 17, 20  
 Trochanter, 46, 55, 127  
 Trochlea, 126  
 Truncus arteriosus, 68  
 Trunk, 114  
 Trypsin, 66  
 Tube, auditory, 93  
   " Eustachian, 93  
   " Fallopian, 134  
   " Malpighian, 42, 57  
 Tubules, 94  
 Turbinal, 124  
 Tympanic membrane, 63, 93, 109  
   112, 132  
 Tympanum, 100, 112, 132
- Typhlosole, 24, 28  
 Trypsin, 66
- Ulna, 110, 127  
 Ulnare, 127  
 Unciform, 127  
 Union, 32  
 Urea, 134  
 Ureter, 94  
 Urethra, 133  
 Urinary system, 133  
 Urine, 94, 133  
 Urodela, 52  
 Uropods, 34  
 Urogenital, apparatus, 114  
 Urostyle, 77  
 Uterus, 50, 134  
   " masculinus, 134  
 Utricle, 93
- Vacuole, 7  
   " contractile, 10, 13  
   " food, 10, 13  
 Vane, 101, 102  
 Vagina, 134  
 Valves heart, 68, 69, 120  
 Variation, 3  
 Vasa efferentia, 94  
 Vascular system, 24, 35  
 Vas deferens, 34, 41, 57, 112, 134  
 Veins, 69.  
   " frog, 71, 72, 73  
   " pigeon, 107  
   " rabbit, 122  
 Vena cava, inferior, 122  
 Venæ cavæ, 120  
 Ventricles, 68, 87, 90, 106, 111, 112,  
   120  
 Venules, 121  
 Vermiform appendix, 118  
 Vertebrae, 71, 125, 126  
 Vertebral column, 108, 125  
 Vertebrata, 2, 62  
 Vesiculæ seminales, 26, 50  
 Vessels, afferent branchial, 36  
 Vessel, dorsal, 59  
 Vestibule, 135  
 Vestiges, 55, 121  
 Villi, 118  
 Visceral arches, 98  
 Vitreous humour, 92, 131  
 Voluntary muscle, 83  
 Vomarine, 79  
 Vomeres, 125  
 Vulva, 114, 134
- Walking legs, 33  
 Wings, 54, 65, 100, 111

## INDEX

Wolffian duct, 94

Xiphisternum, 81, 125

Yellow, fever, 52

Yellow cells, 79

Yolk cells, 79

Yolk plug, 97

Zygapophysis, 76

Zygote, 95

Zygomatic arch, 125









